American College of Radiology™

BI-RADS®

v2025 Manual

Breast Imaging Reporting and Data System



BI-RADS v2025 printing. December 2025

ACR BI-RADS® v2025

Breast Imaging Reporting and Data System



Mary S. Newell, MD, Editor and Chair, Committee on BI-RADS®

Stamatia V. Destounis, MD, Chair, Subcommittee on BI-RADS® Mammography

Jessica W. T. Leung, MD, Chair, Subcommittee on BI-RADS® Ultrasound

Wendy B. DeMartini, MD, Chair, Subcommittee on BI-RADS® MRI

Carol H. Lee, MD, Chair, Subcommittee on BI-RADS® Contrast Enhanced Mammography

Peter R. Eby, MD, Chair, Subcommittee on BI-RADS® Auditing and Outcomes Monitoring

Valerie C. Kasdan, MS, ACR staff member

Lauren J. Attridge, MSHA, ACR staff member

Lisa R. Pampillonia, ACR staff member

Mythreyi B. Chatfield, PhD, ACR staff member



American College *of* Radiology™

BI-RADS® v2025 MANUAL USER TERMS AND CONDITIONS

All Users

These terms and conditions shall apply to all users of the American College of Radiology's BI-RADS® v2025 Manual, whether they use its print or digital versions.

Copyright Notice/Permission

Copyright© 1992, 1993, 1995, 1998, 2003, 2013, 2025 American College of Radiology. All rights reserved.

No part of this document may be reproduced or transmitted in any form or by any means, electronic or mechanical, including photocopy, recording or any information storage or retrieval system, without the prior written consent of the American College of Radiology.

The American College of Radiology is a registered trademark and service mark of the American College of Radiology.

Exception to Requirement for Express Written Consent

An individual physician or group of physicians may use this document in the creation of data collection and/or reporting forms and associated software ("related works") without the express written consent of the American College of Radiology as long as:

(1) any portion of the document so utilized is reproduced in its entirety without modification; and

(2) the related works are used solely by the physicians licensed hereby for their internal use, for communications with patients, other physicians and healthcare personnel.

If you would like information on entering into a copyright licensing agreement with the American College of Radiology to incorporate BI-RADS® into commercial software, contact the American College of Radiology at RADS@acr.org.

Disclaimer

The American College of Radiology (ACR) Breast Imaging Reporting and Data System Manual (BI-RADS® Manual) is the product of a collaborative effort among members of various committees of the American College of Radiology.

BI-RADS suggests a standardized method for breast imaging reporting. This system is not meant to dictate individual case management decisions.

All referring physicians and radiologists should be aware of the benefits and limitations of the application of imaging techniques. Imaging techniques classified as investigational by the FDA have not been considered in developing the BI-RADS Manual; however, study of new equipment and applications should be encouraged. The ultimate decision regarding breast imaging procedures and treatment must be made by the referring physician and radiologist in light of all the circumstances presented in an individual examination.

Warranty

Warranty limitations: (i) ACR BI-RADS is provided on an "as is" basis, without warranties of any kind, either express or implied, including, but not limited to, warranties of title, or implied warranties of merchantability or fitness for a particular purpose; (ii) the use of BI-RADS is at your own risk; (iii) neither the American College of Radiology nor anyone else involved in creating, producing, or delivering ACR BI-RADS shall be liable for any direct or indirect, incidental, special, consequential, or punitive damages arising out of your use of ACR BI-RADS.

The ACR Breast Imaging Reporting and Data System (BI-RADS®) suggests a standardized method for breast imaging reporting. This system is not meant to dictate individual case management decisions.

eBook User Additional Terms and Conditions

Your Rights

Every ACR product ("eBook version of BI-RADS® v2025 Manual) purchased by a user is licensed to run on up to 5 (five) devices held by that end user.

License and Access

Subject to your compliance with these Conditions of Use and your payment of any applicable fees, American College of Radiology (ACR®) or its content providers grant you a limited, non-exclusive, non-transferable, non-sublicensable license to access and make personal and non-commercial use of our service. This license does not include any resale or commercial use of the ACR BI-RADS® v2025 Manual eBook version, or its contents; any collection and use of any product listings, descriptions, or prices; any derivative use of any ACR product or its contents; any downloading or copying of account information for the benefit of another merchant; or any use of data mining, robots, or similar data gathering and extraction tools; or any use of artificial intelligence (AI), machine learning models, or automated systems to access, analyze, reproduce, or generate derivative works based on the content of this Manual. All rights not expressly granted to you in these Conditions of Use or any Service Terms are reserved and retained by ACR or its licensors, suppliers, publishers, rights holders, or other content providers. No ACR product, nor any part of any ACR product, may be exploited for any commercial purpose without express written consent of ACR. You may not frame or utilize framing techniques to enclose any trademark, logo, or other proprietary information (including images, text, page layout, or form) of ACR without express written consent. You may not use any meta tags or any other "hidden text" utilizing ACR's name or trademarks without the express written consent of ACR. You may not misuse the ACR products. You may use the ACR products only as permitted by law.

ACR reserves the right to monitor usage of its products and services to ensure compliance with these Conditions of Use. ACR may, at its discretion, monitor usage of any ACR product or service to detect unauthorized use, including use involving artificial intelligence (AI), machine learning, or automated systems. Any violation of these Conditions, including unauthorized use of AI technologies, shall constitute a material breach of this license. Upon breach, ACR may pursue any legal or equitable remedies available, including injunctive relief, damages, and recovery of legal fees. The licenses granted by ACR terminate if you do not comply with these Conditions of Use or any Service Terms.

Disclaimer of Warranties and Limitation of Liability

To the full extent permissible by applicable law, ACR disclaims all warranties, express or implied, including, but not limited to, implied warranties of merchantability and fitness for a particular purpose. ACR does not warrant that the ACR products, information, content, materials, products (including eBooks) or other products included on or otherwise made available to you through ACR, ACR's servers or electronic communications sent for ACR are free of viruses or other harmful components. ACR will not be liable for any damages of any kind arising from the use of any ACR product, or from any information, content, materials, products (including eBooks) or other products included on or otherwise made available to you through any ACR service, including, but not limited to direct, indirect, incidental, punitive, and consequential damages, unless otherwise specified in writing.

Certain state laws do not allow limitations on implied warranties or the exclusion or limitation of certain damages. If these laws apply to you, some or all of the above disclaimers, exclusions, or limitations may not apply to you, and you might have additional rights.

Applicable Law

By using any ACR product, you agree that the applicable federal law and the laws of the Commonwealth of Virginia, without regard to principles of conflict of laws, will govern these Conditions of Use and any dispute of any sort that might arise between you and ACR.

BI-RADS® v2025 Manual, Institutional User Licenses

Please contact American College of Radiology at RADS@acr.org for information on obtaining an institutional user license.

BI-RADS® v2025 Manual Citations

The American College of Radiology recommends using the following citations to acknowledge the source, appropriate section, and authors:

To cite the entire Manual:

Newell, MS, Destounis SV, Leung, JWT, DeMartini, WB, Lee, CH, Eby, PR. ACR BI-RADS v2025 Manual. Reston, Virginia, American College of Radiology; 2025.

To cite Mammography:

Destounis, SV, Friedewald, SM, Grimm, LJ, Poplack, SP, Sung, JS. Mammography. In: ACR BI-RADS v2025 Manual. Reston, VA American College of Radiology; 2025

To cite Ultrasound:

Leung, JWT, Baker, JA, Hooley, R, Loving, VA, Raelyea, JA. Ultrasound. In: ACR BI-RADS v2025 Manual. Reston, VA American College of Radiology; 2025

To cite MRI:

DeMartini, WB, Strigel, RM, Pinker, K, Rahbar, H, Wang, LC. Magnetic Resonance Imaging. In: ACR BI-RADS v2025 Manual. Reston, VA American College of Radiology; 2025

To cite CEM:

Lee, CH, Phillips, J, Sung, JS, Lewin, JM, Newell, MS. Contrast Enhanced Mammography. In: ACR BI-RADS v2025 Manual. Reston, VA American College of Radiology; 2025

To cite AOM:

Eby, PR, Bennett, DL, Cohen, EO, Plecha, DM, Sickles, EA. Auditing and Outcomes Monitoring. In: ACR BI-RADS v2025 Manual. Reston, VA American College of Radiology; 2025

Acknowledgements

The American College of Radiology gratefully acknowledges the individuals who contributed to the development of the BI-RADS® v2025 Manual.

We extend our sincere thanks to those who reviewed the draft documents prior to publication, offering valuable insights and feedback:

Beatriz E. Adrada, MD, Catherine M. Appleton, MD, Andrea L. Arieno, BS, Alexandra S. Athanasiou, MD, MSc, Lora D. Barke, DO, Wendie A. Berg, MD, PhD, Ann L. Brown, MD, Jung Min Chang, MD, Paola Clauser, MD, PhD, Phoebe E. Freer, MD, Jennifer A. Harvey, MD, Thomas H. Helbich, MD, MSc, MBA, Samantha L. Heller, PhD, MD, Debra M. Ikeda MD, Bonnie N. Joe, MD, PhD, Rasha M. Kamal, MD, Janie M. Lee, MD, MSc, Alana A. Lewin, MD, Ana P. Lourenco, MD, Kathryn P. Lowry, MD, Laurie R. Margolies, MD, Ellen B. Mendelson, MD, MA, Maria Helena S. Mendonca M.D., Ph.D., Debra L. Monticciolo, MD, Wookyung Moon, MD, PhD, Linda Moy, MD, Bethany L. Niell, MD, PhD, Derek L. Nguyen, MD, Haydee Ojeda-Fournier, MD, Pamela A. Propeck MD, Stephen J. Seiler, MD, Nisha Sharma, Dr, MBChB, BSc(hons), MRCP, MSc, Priscilla J. Slanetz MD MPH, Georgia G. Spear, MD, MS, A. Thomas Stavros, MD, Daymen S. Tuscano, MD, Gary J. Whitman, MD, Margarita L. Zuley, MD.

Special thanks to the skilled ACR staff who contributed to the production of the BI-RADS® v2025 Manual:

David A. Kurth, MPH, MS, Cassandra M. Vivian-Davis, Connor H. Clyne, PMP, William E. Creech, Sigala Gang, Phoebe W. Liu, MPH, David O'Brien, Jennifer L. Walter, BSMITS.

And to our publisher:

Circle Graphics, Inc., Copy General, and BookIT Digital Technologies Private Limited for making this Manual possible.

ACR BI-RADS® v2025
TABLE OF CONTENTS

Preface – BI-RADS® Chair xv

Chapter on Mammography 1

PREFACE 4

INTRODUCTION 5

I. TYPES OF MAMMOGRAPHIC STUDIES 7

II. BREAST IMAGING LEXICON — MAMMOGRAPHY 9

III. BREAST DENSITY 11

IV. FINDINGS 19

A. MASSES 20

B. CALCIFICATIONS 47

C. ARCHITECTURAL DISTORTION 107

D. ASYMMETRIES 111

E. LYMPH NODES 122

F. SKIN LESIONS 128

G. DILATED DUCTS 130

H. ASSOCIATED FEATURES 132

I. SPECIAL CASES 139

J. LOCATION OF FINDING 147

V. REPORTING SYSTEM 149

A. ASSESSMENT CATEGORIES 149

B. REPORT ORGANIZATION 154

C. WORDING OF REPORT 157

VI. GUIDANCE 159

A. MAMMOGRAPHY LEXICON 159

B. REPORT ORGANIZATION 162

VII. FREQUENTLY ASKED QUESTIONS 166

APPENDIX A — MAMMOGRAPHIC VIEWS 171

APPENDIX B — MAMMOGRAPHY LEXICON SUMMARY FORM 173

Chapter on Ultrasound 183

PREFACE 186

INTRODUCTION 188

I. GENERAL CONSIDERATIONS 190

A. BREAST ANATOMY 190

B. IMAGE QUALITY 201

C. LABELING AND MEASUREMENT 220

D. DOCUMENTATION 223

E. HANDHELD VS. AUTOMATED AND PHYSICIAN- VS. TECHNOLOGIST-PERFORMED 225

II. BREAST IMAGING LEXICON — ULTRASOUND 227

A. TISSUE COMPOSITION 229

B. MASSES 242

C. NON-MASS LESIONS 350

D. CALCIFICATIONS 374

E. ASSOCIATED FEATURES 383

F. SPECIAL CASES 418

G. LYMPH NODES 452

H. LOCATION OF FINDING 471

III. REPORTING SYSTEM 472

A. ASSESSMENT CATEGORIES 472

B. REPORT ORGANIZATION 476

C. WORDING OF REPORT 480

IV. GUIDANCE 481

A. TISSUE COMPOSITION 481

B. BREAST ULTRASOUND LEXICON 481

C. LYMPH NODES 483

V. FREQUENTLY ASKED QUESTIONS 484

APPENDIX A — ULTRASOUND LEXICON SUMMARY FORM 488

Chapter on Magnetic Resonance Imaging 499

PREFACE 502

INTRODUCTION 503

I. ACQUISITION PARAMETERS 504

II. BREAST IMAGING LEXICON — MRI 508

A. AMOUNT OF FIBROGLANDULAR TISSUE (FGT) 510

B. BACKGROUND PARENCHYMAL ENHANCEMENT (BPE) 513

C. MASSES 519

D. NON-MASS ENHANCEMENT (NME) 548

E. ENHANCEMENT KINETICS 577

F. LYMPH NODES 584

G. ASSOCIATED FEATURES 605

H. OTHER FINDINGS — TYPICALLY BENIGN 627

I. LOCATION OF FINDING 654

J. IMPLANTS AND OTHER TYPES OF AUGMENTATION 655

III. REPORTING SYSTEM 702

A. ASSESSMENT CATEGORIES 702

B. REPORT ORGANIZATION 710

C. WORDING OF REPORT 713

IV. GUIDANCE 714

V. FREQUENTLY ASKED QUESTIONS 716

APPENDIX A — MRI LEXICON SUMMARY FORM 717

Chapter on Contrast Enhanced Mammography 725

PREFACE 728

INTRODUCTION 729

I. GENERAL CONSIDERATIONS 731

II. BREAST IMAGING LEXICON — CEM 733

III. IMAGE EXAMPLES 738

IV. REPORTING SYSTEM 780
A. ASSESSMENT CATEGORIES 780
B. REPORT ORGANIZATION 783
C. WORDING OF REPORT 787
V. GUIDANCE 788
VI. FREQUENTLY ASKED QUESTIONS 792
APPENDIX A — LEXICON SUMMARY FORM FOR RECOMBINED IMAGES 795

Chapter on Auditing and Outcomes Monitoring 801

PREFACE 804
INTRODUCTION 806
I. GLOSSARY 808
II. THE BASIC CLINICALLY RELEVANT AUDIT 816
A. BI-RADS CATEGORY 3 AUDITING. 822
B. BENCHMARKS AND ACCEPTABLE RANGES 826
C. IMPORTANT CONSIDERATIONS 830
III. THE MORE COMPLETE AUDIT 833
IV. EXAMPLES OF HOW TO CLASSIFY EXAMINATIONS AS TRUE-POSITIVE, TRUE-NEGATIVE, FALSE-POSITIVE, AND FALSE-NEGATIVE. 840
A. BI-RADS ASSESSMENT CONCORDANT WITH MANAGEMENT RECOMMENDATION 840
B. BI-RADS ASSESSMENT DOES NOT MATCH MANAGEMENT RECOMMENDATION 845
C. AUDITING OF INITIAL BI-RADS CATEGORY 3 ASSESSMENT. 846
V. AREAS OF CONFUSION IN THE DATA COLLECTION PROCESS 849
A. WHAT NOT TO AUDIT 849
B. DOUBLE READING 850
C. THE "SCREENING" VERSUS THE "DIAGNOSTIC WORK-UP" RADIOLOGIST. 851
D. CANCER IDENTIFIED AT SCREENING EXAMINATION LESS THAN 1 YEAR AFTER THE PREVIOUS NEGATIVE SCREENING EXAMINATION 851
E. THE GROUP OF EXAMINATIONS ASSESSED AS PROBABLY BENIGN (BI-RADS CATEGORY 3) WITH A RECOMMENDATION FOR SHORT-INTERVAL FOLLOW-UP AND SURVEILLANCE IMAGING 852

VI. FREQUENTLY ASKED QUESTIONS AND GUIDANCE CONCERNING BREAST IMAGING AUDITS 853

A. ALL BREAST IMAGING MODALITIES 853

B. MAMMOGRAPHY 855

C. ULTRASOUND 855

D. MRI 856

VII. INITIAL METHOD OF DETECTION 858

General BI-RADS Frequently Asked Questions 869

Online BI-RADS Resources 875

PREFACE

The illustrated BI-RADS® v2025 Manual is an extension of the 5th Edition of the BI-RADS Atlas. The v2025 Manual, like its predecessor, includes sections on mammography, ultrasound and magnetic resonance imaging (MRI) of the breast as well as the auditing and outcomes monitoring section (AOM), formerly referred to as follow-up and outcomes monitoring. The contrast enhanced mammography (CEM) section, previously an Atlas supplement, is now included in the Manual proper.

One immediately obvious difference is the change in overall naming of the BI-RADS project. The switch from "edition" to dated versioning allows for harmonization across all the ACR® RADS programs, which are currently using the versioning nomenclature. Since the BI-RADS project includes a wealth of written information in addition to numerous pictorial examples, the term "manual" rather than "atlas" is felt to be a better descriptor of the breadth of content.

As you will see, the number of examples has been increased significantly throughout all sections of the Manual, and now includes newer technologies (e.g., digital breast tomosynthesis, synthetic mammography, automated whole-breast ultrasound). Also, whenever possible, the authors have placed an emphasis on ensuring consistency in terms and definitions among the four lexicons.

There are several changes and expanded definitions within BI-RADS v2025. Each section preface outlines them in detail. Especially notable are the addition of the new finding type "non-mass lesion" in ultrasound, which will be extremely useful in detecting and describing abnormalities that present as focal asymmetries on mammography and/or non-mass lesions on MRI, and new audit categories (including initial B3 findings and additional MR findings detected on exams performed for extent of disease assessment). Additionally, the concept of method of detection is introduced in the AOM section. Some additions were approached as introductory concepts, with the knowledge that they will likely be included more robustly in future iterations (e.g., the short discussion around the clinical importance of breast arterial calcifications; the idea that surgical excision may not be the only form of "definitive local treatment" available to patients, assessment and quantification of glandular tissue component with ultrasound).

The use of structured clinical indications in report creation is emphasized in BI-RADS v2025. Radiologists are encouraged to use at least the major indication categories and preferably the optional subcategory structured terminology as well. These structured categories should be used for all modalities and will be expected to aid in report clarity, outcomes monitoring and determination of method of cancer detection.

Major Indication	Optional Subcategory Indication	Relevant History to Report, if known
Asymptomatic Screening	• Elevated risk • Dense breasts • Prior breast cancer, treatment completed • Other	• Gene mutation • Estimated cancer risk • Prior breast cancer history
Diagnostic Work-up	• Clinical findings • Imaging findings • Follow-up category 3 • Follow-up after biopsy • Implant assessment • Other	• Clinical finding type • Imaging finding type
Diagnostic: Current Breast Cancer	• Extent of disease before treatment/ therapy • Response during or after neoadjuvant therapy • Other	• Location and size of cancer on prior imaging evaluation

As before, figure legends will designate the defined feature in capital letters. Obviously, many of the illustrations will display several features, for example, "ROUND, circumscribed, high-density mass." Cases will be fully described using lexicon terminology where appropriate; therefore, many of the examples will highlight more than one feature. However, the capitalized terms will indicate the feature that is chosen for illustration. In some cases, several descriptors within a single feature category may be listed (e.g., different forms of calcium) for the purpose of illustration. One must remember that management recommendations should be based on the most worrisome of the features. Thus, while the image legends may include more than one descriptor for any given category (e.g., amorphous *and* fine pleomorphic calcifications), an actual clinical report would include a statement recommending biopsy due to the presence of fine pleomorphic forms.

When feasible, within any given category, lexicon terminology is presented from least suspicious to most suspicious. While this approach works well for many categories due to strong evidence (e.g., positive predictive value for suspicious calcification morphology and distribution), for other categories the presentation hierarchy is based more on expert consensus. For others still, a hierarchy does not make practical sense (e.g., associated features).

The BI-RADS v2025 Manual is the culmination of a few years of collaborative efforts between the subsection heads and their committees, the ACR, and, importantly, input from users of these lexicons. A diverse group of external reviewers offered valuable and thoughtful commentary, and their suggestions were incorporated when appropriate. The manual is designed for everyday practice and should make it possible to issue unambiguous breast imaging reports and meaningfully evaluate our performance. This will enable us to improve our practices and compare ourselves to other breast imaging facilities worldwide. We all sincerely hope that this document helps breast imagers everywhere better understand and evaluate our subspecialty.

BI-RADS, now more than ever, is intended to be a dynamic and evolving document that will adapt to changes in the practice of breast imaging and be of practical use to radiologists. The move toward an interactive electronic format will allow more frequent updates. As always, the BI-RADS

committee encourages comments and/or suggestions from its users and requests these in writing to the American College of Radiology (ACR). However, prior to submitting comments or suggestions, please visit the ACR BI-RADS web page which displays Committee-approved responses to suggestions already submitted at: https://www.acr.org/Clinical-Resources/Clinical-Tools-and-Reference/Reporting-and-Data-Systems/BI-RADS

Committee on BI-RADS®
American College of Radiology
E-mail: RADS@acr.org

Mary S. Newell, MD, FACR, FSBI
Chair, Committee on BI-RADS®



ACR BI-RADS® v2025

Mammography

Stamatia V. Destounis, MD, Chair

Sarah M. Friedewald, MD
Lars J. Grimm, MD, MHS
Steven P. Poplack, MD
Janice S. Sung, MD



American College of Radiology™

TABLE OF CONTENTS

PREFACE 4

INTRODUCTION 5

I. TYPES OF MAMMOGRAPHIC STUDIES 7

II. BREAST IMAGING LEXICON — MAMMOGRAPHY. 9

III. BREAST DENSITY 11

IV. FINDINGS 19

A. MASSES 20

B. CALCIFICATIONS 47

C. ARCHITECTURAL DISTORTION 107

D. ASYMMETRIES. 111

E. LYMPH NODES 122

F. SKIN LESIONS 128

G. DILATED DUCTS 130

H. ASSOCIATED FEATURES 132

I. SPECIAL CASES 139

J. LOCATION OF FINDING 147

V. REPORTING SYSTEM 149

A. ASSESSMENT CATEGORIES 149

B. REPORT ORGANIZATION 154

C. WORDING OF REPORT. 157

VI. GUIDANCE. 159

A. MAMMOGRAPHY LEXICON 159

B. REPORT ORGANIZATION 162

VII. FREQUENTLY ASKED QUESTIONS 166

APPENDIX A — MAMMOGRAPHIC VIEWS 171

APPENDIX B — MAMMOGRAPHY LEXICON SUMMARY FORM 173

PREFACE

The BI-RADS® v2025 Manual of Mammography is an extension of the previous 5th Edition (2013). This new version retains much of the prior content but also contains changes that reflect recent literature and some lexicon updates. The purpose of the mammography lexicon and of structured reporting are to standardize the language used in mammography reports. Consistent use of BI-RADS assessment categories coupled with use of management recommendations will help referring clinicians understand the disposition of their patients and aid in the auditing of patients undergoing breast imaging. Prior editions of the Manual included definitions and illustrations of morphologic features primarily derived from film screen and digital mammography. In this sixth version, the lexicon and illustrations have been updated and expanded with examples primarily from digital mammography (DM), including digital breast tomosynthesis (DBT) and synthetic mammogram (SM) images. Each legend describes several features of the imaging finding, with those capitalized signifying the dominant feature being illustrated. Additional descriptors in the legend will be included in lower case (e.g., "ROUND, circumscribed, high density mass"). Where possible, the biopsy-proven pathology of the finding will be included. Occasionally, multiple finding types are depicted in the illustration and will be additionally described in the legend. For example, a group of calcifications may include both "round" and "amorphous" morphologies. While more than one type may be described, a single management recommendation should be made based on the most suspicious finding(s) present. In this new version of the Manual, the lexicon descriptors within a given category that cross the BI-RADS modalities, are arranged from least to most suspicious, where appropriate.

The Guidance chapter was first introduced in the 4th Edition in response to questions and suggestions concerning terminology and auditing. The goal of this chapter is to help the interpreting radiologist with the management of certain scenarios and imaging findings that occur in the clinical setting to improve consistency across breast imaging practices. Changes are explained, noted with rationale. This chapter has been updated to incorporate new frequently asked questions, particularly with the recent adoption of DBT. Much of the guidance outlined in the prior editions has been incorporated into the body of the current Manual as now-standard knowledge.

All mammography reporting system vendors licensed to use BI-RADS terminology in their software will have access to the files for this version of the Manual in sufficient time to update their applications within the 180 days stipulated by the signed license agreement they have with the American College of Radiology (ACR). Users should verify that their equipment has been updated with the most recent software or request updates from their vendors to ensure that their automated reporting is up to date and accurate.

The BI-RADS v2025 Manual is designed for everyday practice and should make it possible to issue meaningful and unambiguous breast imaging reports. BI-RADS was always intended to be a dynamic and evolving document that would adapt to changes in the practice of breast imaging and be of practical use to interpreting physicians. Therefore, the Committee on BI-RADS welcomes any comments and/or suggestions from its users and requests that these be submitted in writing or electronically to the ACR. However, prior to submitting comments or suggestions, please first visit the ACR BI-RADS web page at: https://edge.sitecorecloud.io/americancoldf5f-acrorgf92a-productioncb02-3650/media/ACR/Files/RADS/BI-RADS/Mammography-FAQ.pdf, which displays committee approved responses to suggestions already submitted.

ACR Committee on BI-RADS®
American College of Radiology
RADS@acr.org

Stamatia V. Destounis, MD, FACR, FSBI
Chair, Subcommittee on BI-RADS® Mammography

INTRODUCTION

The ACR BI-RADS® v2025 chapter on Mammography is divided into seven sections with two appendices.

SECTION I: Types of Mammographic Studies

SECTION II: Breast Imaging Lexicon — Mammography

SECTION III: Breast Density

SECTION IV: Findings

SECTION V: Reporting System

SECTION VI: Guidance

SECTION VII: Frequently Asked Questions

APPENDIX A — Mammographic Views

APPENDIX B — Mammography Lexicon Summary Form

The following is a brief description of each section.

I. Types of Mammographic Studies

The two main categories of mammographic studies include screening and diagnostic examinations. The purpose of each type of study is discussed and evidence-based data regarding efficacy is presented. In addition, with improvements in acquisition and display of mammograms, developing technologies and methods of acquisition are reviewed.

II. Breast Imaging Lexicon — Mammography

The terminology (Table 1) used to describe mammographic findings has evolved over many years. The descriptive terms and definitions that follow have been approved by the ACR Committee on BI-RADS as well as representative stakeholders, with the expectation that only these terms will be used to generate clear, concise, and standardized reports. These terms provide a reasonably complete evidence-based categorization of mammographic findings. Any proposed substantive changes should be submitted to the ACR for review by the Committee on BI-RADS, as indicated in the Preface.

III. Breast Density

Breast density is defined and its clinical significance is described, as are updates to Food and Drug Administration (FDA) reporting requirements enacted in 2024.

IV. Findings

Lexicon terminology is described in detail and imaging examples are provided for illustration. Changes in terminology from the 5th Edition are explained. Terms are arranged from least to most suspicious, where feasible.

V. Reporting System

The reporting system is designed to provide an organized approach to image interpretation and reporting. Not only is the use of approved terminology critical to produce an understandable

breast imaging report, but the order in which the information is conveyed is also important. Standardized reporting facilitates clear and concise communication across disciplines and permits simultaneous data collection for future outcomes review (i.e., medical audit, tumor registry). Although not required, a structured reporting system will allow individual interpreting physicians and mammography facilities to monitor their own results and appraise the accuracy of image interpretation so that they can adjust interpretive thresholds appropriately. Note that use of ACR-approved computer-based reporting software is required for participation in the ACR National Mammography Database (NMD) (https://nrdr.acr.org/Portal/NMD/Main/page.aspx).

VI. Guidance

Over the years of continued BI-RADS usage, the Committee has received many questions related to the various sections that comprise BI-RADS. The guidance chapter addresses these concerns, introduces changes in terminology and assessments, and explains the reasons for these changes. New or expanded definitions and terminology in the lexicon and the explanation for their inclusion are added. At present, some of the changes do not have supportive data other than expert consensus; however, the Committee believes that their inclusion is necessary to make the lexicon a more practical document. As was the case with previous BI-RADS editions, data accrue in mammography literature, and as this occurs, evidence-based changes are made. In some cases, introduction of new terminology may spur investigation of outcomes and efficacy.

VII. Frequently Asked Questions

Frequently asked questions are addressed.

APPENDICES

Appendix A contains a table of standardized terminology and abbreviations for mammography views.

Appendix B provides a useful summary form that can be used for quick reference and as a teaching resource.

I. TYPES OF MAMMOGRAPHIC STUDIES

There are two major categories of mammography studies: screening and diagnostic.

Screening Mammography

The major role for screening mammography is early detection of breast cancer in asymptomatic patients. The efficacy of mammographic screening has been well established by randomized controlled trials and case-controlled studies. Significant reductions in breast cancer mortality have been achieved for patients undergoing screening mammography because mammography detects breast cancer at a smaller size and earlier stage than in control groups of patients not undergoing screening. Seven of the eight randomized control trials demonstrated mortality reduction in women who were invited to screen, with an overall 24% reduction in mortality [1]. Additionally, case-control studies have shown an even greater benefit of screening, with a decrease in death by 49% [2]. Since 1990, screening mammography has contributed to a 45.3%–58.3% reduction in age adjusted breast cancer specific mortality in the United States [3].

Mammographic screening as performed in the United States involves the performance of the mediolateral-oblique (MLO) and craniocaudal (CC) x-ray projections of each breast with film mammography, DM and/or DBT. With DBT, multiple low dose mammographic images of the breast are obtained as the x-ray tube moves across the breast in an arc. The images are then reconstructed to produce a volume rendering of the breast. A "synthetic" mammogram (SM) image may be generated from the DBT source images and appears similar to a standard DM image. Some facilities use the SM image in place of a DM image to eliminate a second exposure (i.e., DBT + SM vs DBT + DM).

Use of DBT improves cancer detection while simultaneously reducing the rate of false positive examinations by reducing the adverse effects of overlapping tissue. When used for screening, DBT decreases the recall rate by 15–37% [4–6]. Additionally, DBT increases the cancer detection rate by 1.2–2.7 per 1000 examinations, mainly for invasive breast cancer, without a significant increase in DCIS detection [4–6]. DBT also improves visualization of a lesion's margin and improves the ability to localize findings within the breast, even when a lesion is seen in only one standard mammographic projection. Additionally, the increased conspicuity and localization of lesions with DBT may obviate the need for additional diagnostic mammographic views, allowing patients to proceed directly from screening mammography to diagnostic ultrasound for finding characterization [7, 8].

By definition, screening involves imaging of an asymptomatic patient. Patients with any new and/or suspicious clinical symptoms, an incomplete prior evaluation, or requiring follow-up of previous findings should undergo diagnostic imaging regardless of patient and referring provider preference. It is important to note that screening mammography refers to the patient as a whole and not an individual breast. For example, a patient cannot have a screening mammogram on the left breast while simultaneously undergoing a diagnostic mammogram of the right breast.

The goal of screening is to identify the subset of patients who require further diagnostic imaging evaluation among the much larger group of asymptomatic patients for whom periodic (annual, per ACR recommendations) screening is recommended. In some clinical practice settings, additional mammographic images and/or adjunctive breast imaging studies will be undertaken immediately to solve a question raised on a screening examination (i.e., online screening), with that added work-up constituting a diagnostic exam. In a more common scenario, involving the "off-line" or batch reading of screening examinations, the patient will be recalled for further evaluation to be performed at a later date for a possible abnormality detected on the screening mammogram.

Diagnostic Mammography

Diagnostic mammography is a tailored imaging study designed to answer a specific question. Multiple specialized views may be obtained at the discretion of the radiologist to gain further information regarding the findings or clinical situation in question. Patients presenting for a diagnostic mammogram include those who have been recalled for additional imaging following a screening examination (to confirm, characterize and localize the potential finding); patients who present with breast symptoms, such as a palpable abnormality, clinically suspicious nipple discharge, focal pain or skin changes; and patients undergoing serial diagnostic imaging to ensure that a finding previously determined to be probably benign is stable in size and appearance over a sufficient follow-up period (e.g., 2 years) to eventually be considered benign. Patients with a personal history of breast cancer may be undergoing post-treatment surveillance using diagnostic mammography, although this is institution specific. However, if, in this latter scenario, only routine mammogram views are obtained, the exam is considered screening for the purpose of the audit.

Although mammography detects breast cancer at an earlier size and stage than physical examination at the population level, ***there is no test or group of tests that ensure that an individual does not have breast cancer.*** Management decisions following an appropriate diagnostic breast evaluation must incorporate clinical findings, as breast cancer may be mammographically occult, especially for patients with denser breasts. Clinically guided biopsy for a palpable finding following a negative diagnostic work-up may thus be appropriate.

II. BREAST IMAGING LEXICON — MAMMOGRAPHY

Table 1. BI-RADS® Mammography Lexicon Overview

Breast Tissue	Terms	
Breast density[1]	(A) The breasts are almost entirely fatty	
	(B) There are scattered areas of fibroglandular density	
	(C) The breasts are heterogeneously dense, which may obscure small masses	
	(D) The breasts are extremely dense, which lowers the sensitivity of mammography	
Findings	**Terms**	
A. Masses	1. Shape	a. Oval
		b. Lobulated
		c. Round
		d. Irregular
	2. Margin	a. Circumscribed
		b. Obscured
		c. Indistinct
		d. Spiculated
	3. Density	a. Fat-containing
		b. Low density
		c. Equal density
		d. High density
B. Calcifications	1. Typically benign	a. Skin
		b. Vascular
		c. Coarse
		d. Large rod-like
		e. Round
		f. Rim
		g. Layering
		h. Suture
	2. Suspicious morphology	a. Amorphous
		b. Coarse heterogeneous
		c. Fine pleomorphic
		d. Fine linear or fine linear-branching
	3. Distribution	a. Diffuse
		b. Regional
		c. Grouped
		d. Linear
		e. Segmental
C. Architectural distortion		
D. Asymmetries	1. Global asymmetry	
	2. Asymmetry	
	3. Focal asymmetry	

E. Lymph nodes	1. Intramammary	a. Normal b. Abnormal
	2. Axillary	a. Normal b. Abnormal
F. Skin lesions		
G. Dilated ducts	1. Multiple 2. Solitary	
H. Associated features	1. Skin retraction 2. Nipple retraction 3. Skin thickening 4. Trabecular thickening	
I. Special cases	1. Gynecomastia 2. Implants and other forms of augmentation 3. Mastectomy	
J. Location of finding	1. Laterality 2. Location in breast 3. Depth and/or distance from the nipple	

[1]In July 2025, the FDA approved an alternative standard that would allow the interpreting physician to provide an overall assessment of breast density that is phrased in the singular phrasing. The singular phrasing is intended to be used in reports of unilateral mammograms. Please see the Guidance section for more information.

III. BREAST DENSITY

Breast density is defined as the relative proportion of breast parenchyma to fat within the breast. Mammographically, breast parenchyma is radiodense relative to radiolucent fat. There are four categories of breast density (Table 2): the breasts are almost entirely fatty, there are scattered areas of fibroglandular density, the breasts are heterogeneously dense which may obscure small masses, and the breasts are extremely dense which limits the sensitivity of mammography. Reporting breast density is required by Food and Drug Administration (FDA) legislation as of September 2024. Language included in the report both to the referring physician and the patient must follow the federal guidance.

People with heterogeneously dense or extremely dense breasts are considered to have dense breasts, while those with almost entirely fatty breasts or scattered areas of fibroglandular density are considered to be non-dense. Most commonly, the interpreting radiologist subjectively categorizes the breast density using visual inspection of the breast parenchyma on the craniocaudal and mediolateral DM or SM views, although FDA-approved automated density measurement software is available. With the BI-RADS 5th Edition, the classification of breast density changed from an evaluation of the percentage of dense tissue to an assessment based on the likelihood that overlying tissue may obscure a cancer. This classification continues in v2025. If tissue in one region is dense and potentially masking an underlying cancer, then the breast density classification should be based on an assessment of this region, rather than the overall amount of parenchymal tissue. If each breast falls into a different density category, the greater density of the two is assigned to that examination. Breast density can be variable from year to year, depending on multiple factors such as weight gain or loss, estrogen replacement therapy, menopause, etc. Therefore, breast density is updated at each examination to accurately reflect the current breast density.

Breast density is significant for two reasons: mammographic accuracy and breast cancer risk. The impact of breast density on mammographic accuracy is due to the masking effect of dense fibroglandular tissue. With film-screen mammography, sensitivity declines significantly from fatty breasts to extremely dense breasts [9]. The masking effect caused by dense breast tissue has been reduced by advances in technology, first with the adoption of digital mammography, and, more recently, with DBT. In the DMIST trial, the sensitivity of mammography in women with dense breasts increased from 55% with film mammography to 70% with digital mammography [10]. With DBT, the interpreting radiologist can scroll through images of the breast slice by slice, further reducing the masking effect of dense breast tissue. In women with dense breasts, the cancer detection rate increased from 4.5 per 1000 women screened with digital mammography to 5.8 per 1000 women screened with DBT ($p<0.001$) [11].

As with increasing age, pathogenic genetic variants, family history, and reproductive factors, having dense breasts confers an increased inherent risk for developing breast cancer. Compared to the breasts of women with scattered fibroglandular tissue, the odds ratio of breast cancer is 0.6 for almost entirely fatty, 1.4 for heterogeneously dense, and 1.6 for extremely dense breasts [12].

Table 2. Breast Density Categories[1]

(A) The breasts are almost entirely fatty
(B) There are scattered areas of fibroglandular density
(C) The breasts are heterogeneously dense, which may obscure small masses
(D) The breasts are extremely dense, which lowers the sensitivity of mammography

[1] In July 2025, the FDA approved an alternative standard that would allow the interpreting physician to provide an overall assessment of breast density that is phrased in the singular phrasing. The singular phrasing is intended to be used in reports of unilateral mammograms. Please see the Guidance section for more information.

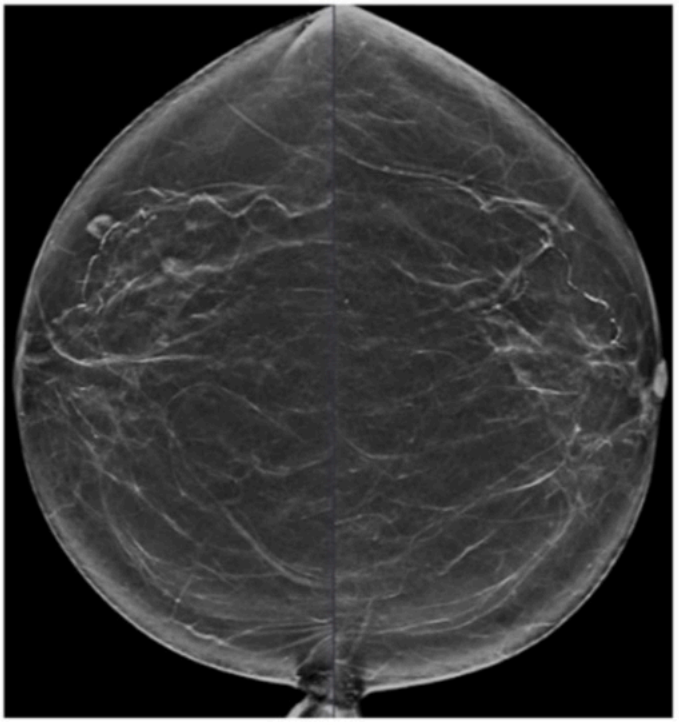

Figure 1 – Breast Density: BI-RADS breast composition category A, almost entirely fatty (SM).

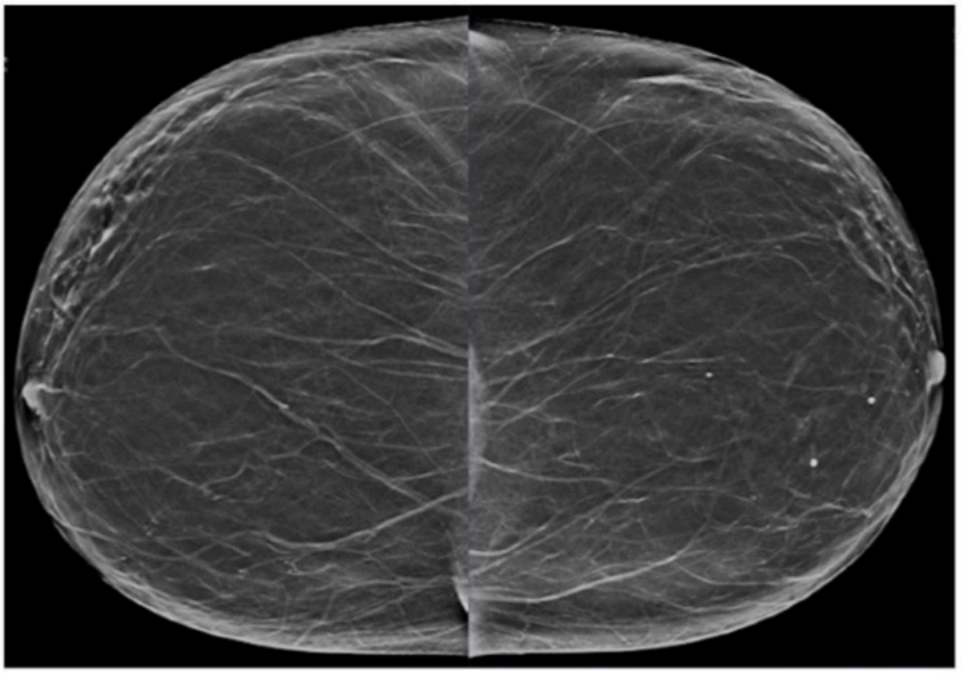

Figure 2 – Breast Density: BI-RADS breast composition category A, almost entirely fatty (SM).

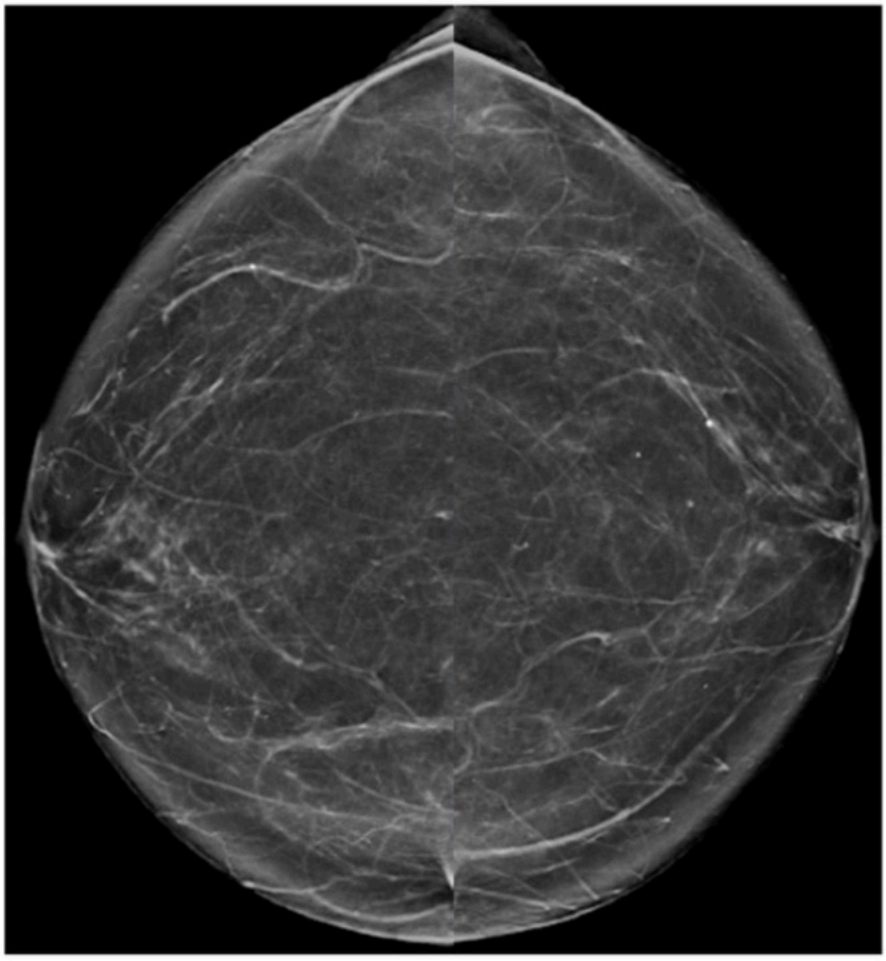

Figure 3 – Breast Density: BI-RADS breast composition category A, almost entirely fatty (SM).



Figure 4 – Breast Density: BI-RADS breast composition category A, almost entirely fatty (DM).

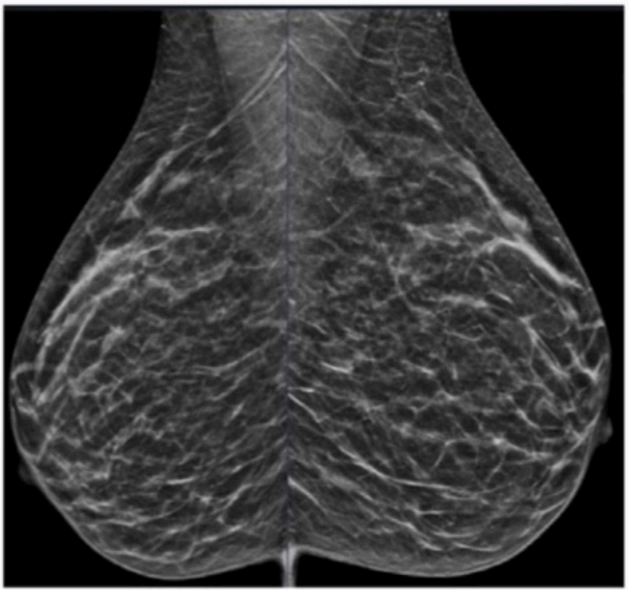

Figure 5 – Breast Density: BI-RADS breast composition category B, scattered areas of fibroglandular density (SM).

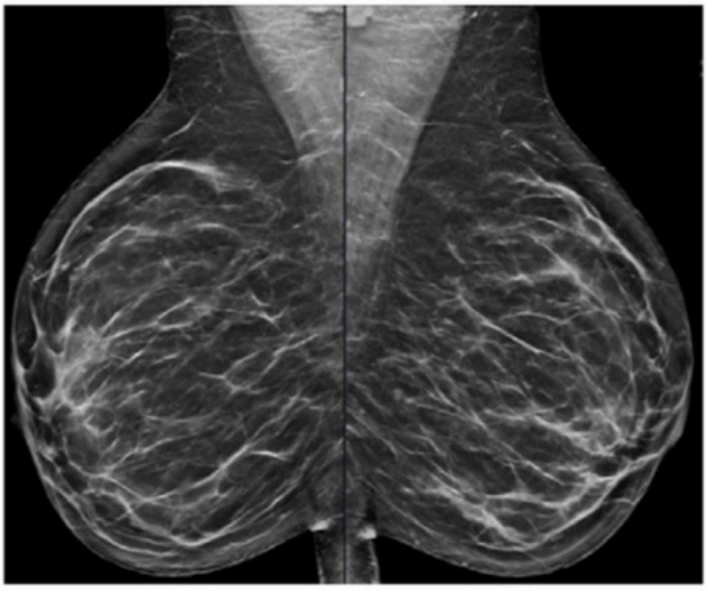

Figure 6 – Breast Density: BI-RADS breast composition category B, scattered areas of fibroglandular density (SM).

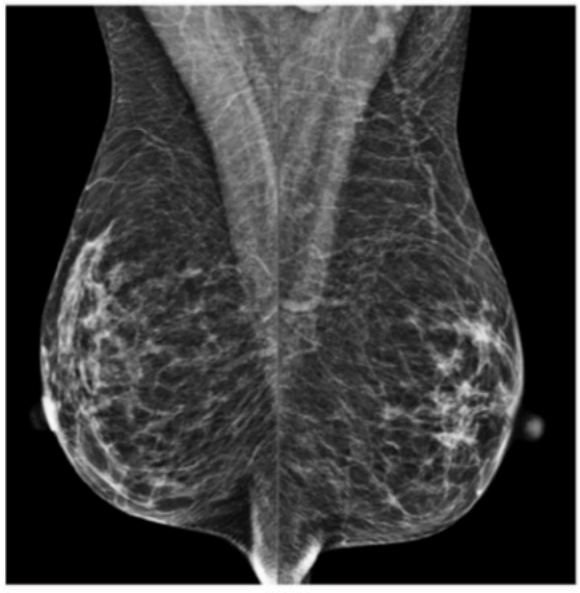

Figure 7 – Breast Density: BI-RADS breast composition category B, scattered areas of fibroglandular density (DM).

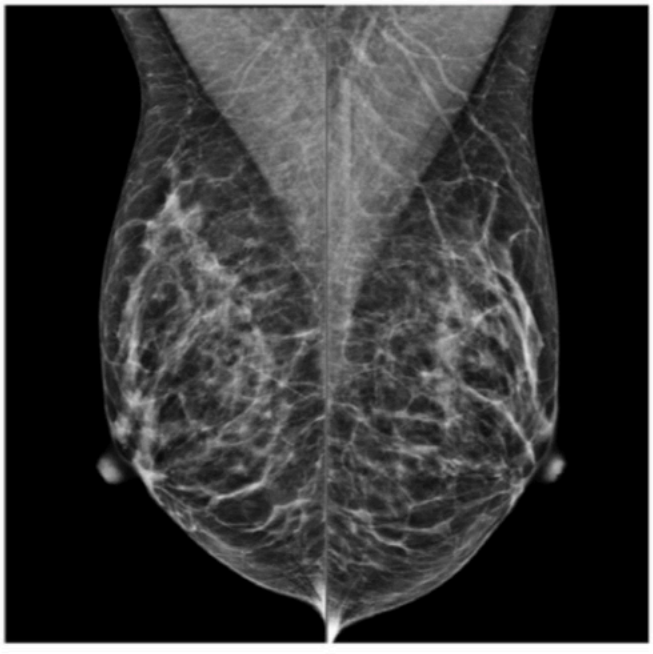

Figure 8 – Breast Density: BI-RADS breast composition category B, scattered areas of fibroglandular density (DM).

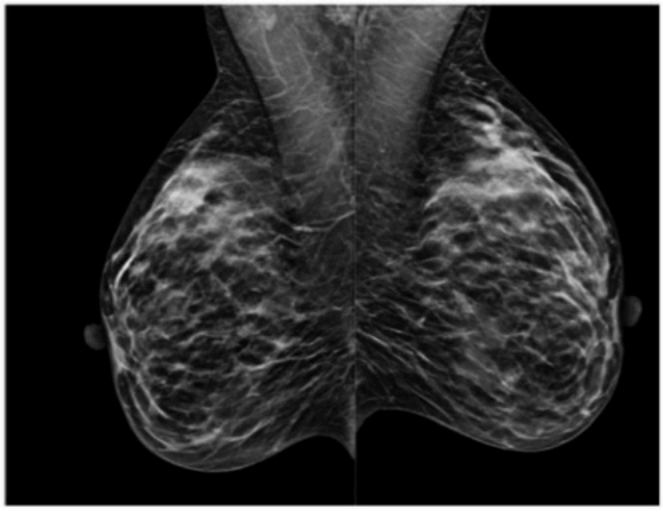

Figure 9 – Breast Density: BI-RADS breast composition category C, heterogeneously dense, which may obscure small masses (DM).

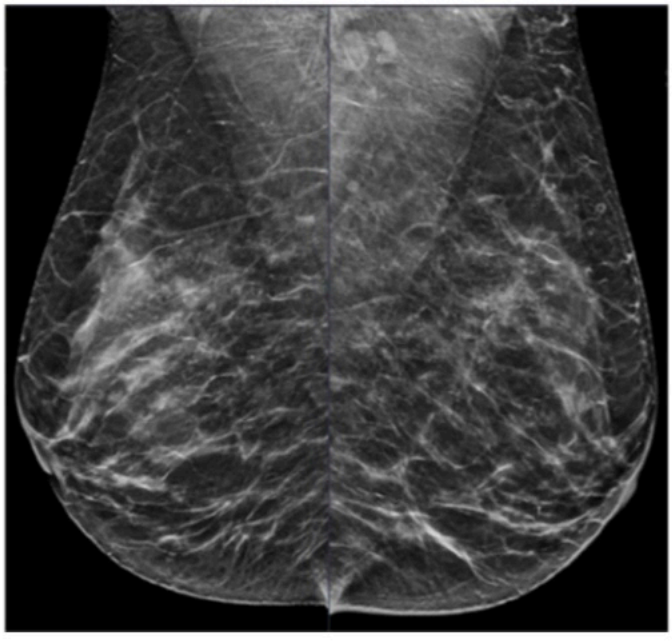

Figure 10 – Breast Density: BI-RADS breast composition category C, heterogeneously dense, which may obscure small masses (SM). Note that although the overall volume of dense tissue is not large, a cancer could be obscured in areas containing dense breast tissue.

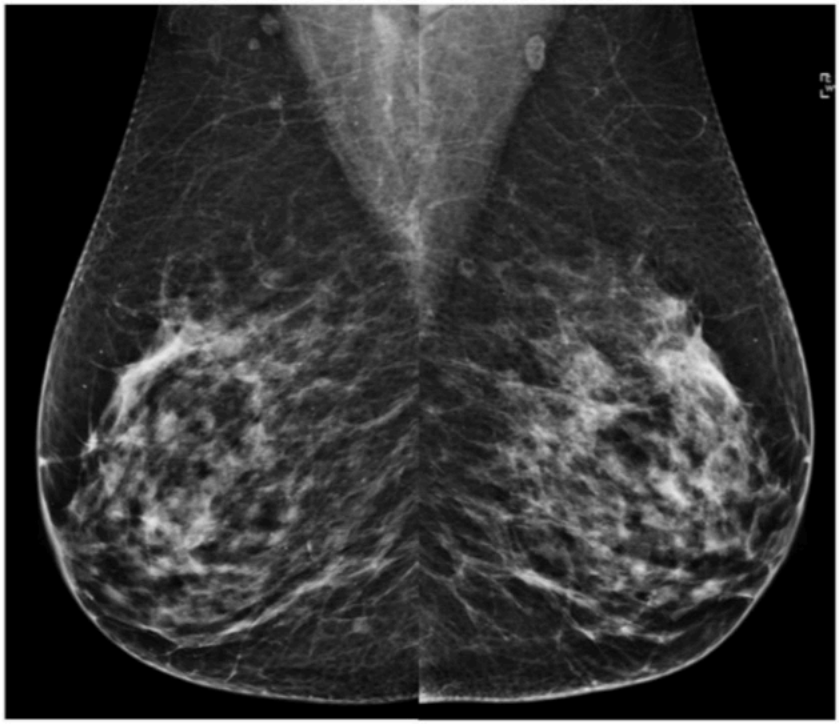

Figure 11 – Breast Density: BI-RADS breast composition category C, heterogeneously dense, which may obscure small masses (DM).



Figure 12 – Breast Density: BI-RADS breast composition category C, heterogeneously dense, which may obscure small masses (DM).

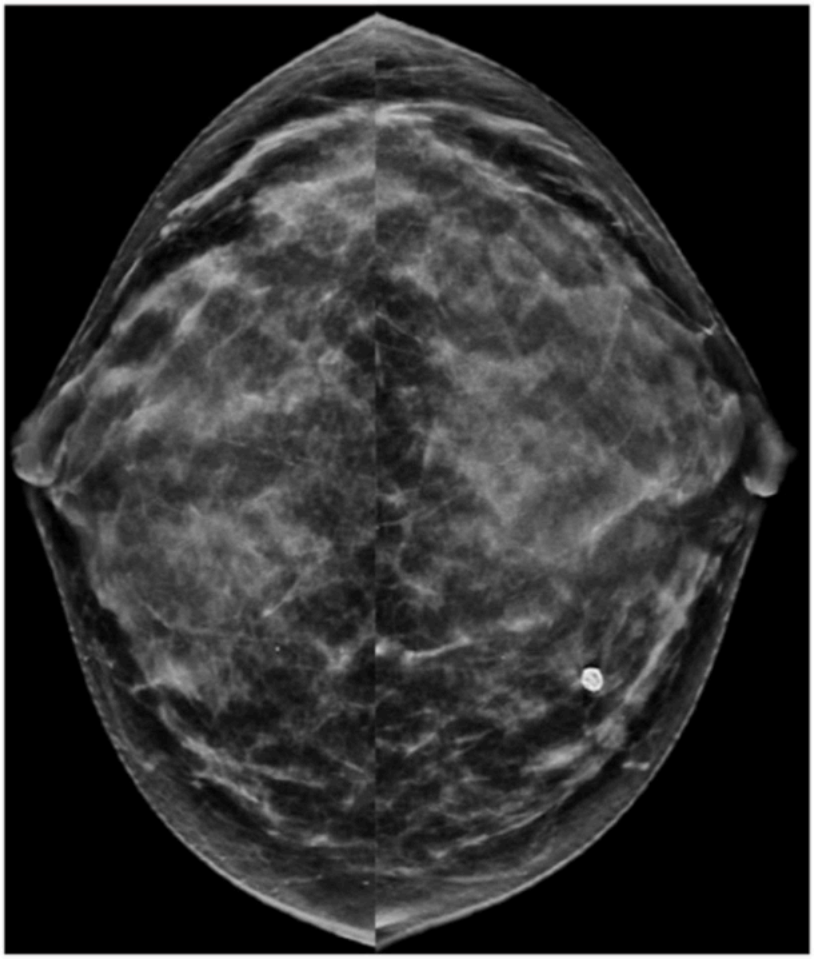

Figure 13 – Breast Density: BI-RADS breast composition category D, extremely dense, which lowers the sensitivity of mammography (SM).

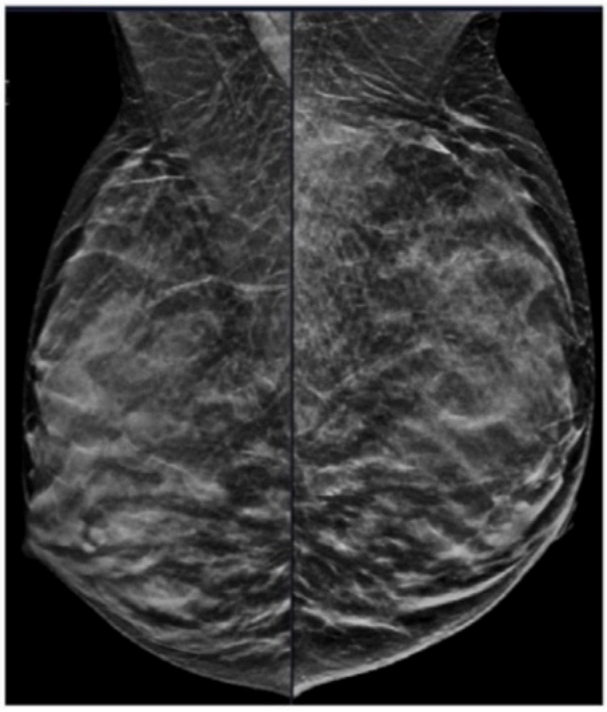

Figure 14 – Breast Density: BI-RADS breast composition category D, extremely dense, which lowers the sensitivity of mammography (SM).



Figure 15 – Breast Density: BI-RADS breast composition category D, extremely dense, which lowers the sensitivity of mammography (SM).



Figure 16 – Breast Density: BI- RADS breast composition category D, extremely dense, which lowers the sensitivity of mammography (SM).

IV. FINDINGS

A. MASSES

A mass is a 3-dimensional, space-occupying structure. It has completely or partially convex margin and, when radiodense, appears denser in the center than at the periphery. Historically, a mass, by definition, had to be visualized on two mammographic projections. However, all the requirements used to define a mass may be apparent on a single projection when imaged on DBT. Visualization of a mass on only one view may occur if there is obscuring fibroglandular tissue or the mass is out of the field of view on the other projection. In such cases, it may be appropriate to use the mass descriptor despite visibility on only a single view.

1. SHAPE

   a. Oval

      An oval mass is elliptical with one axis longer than the other two.

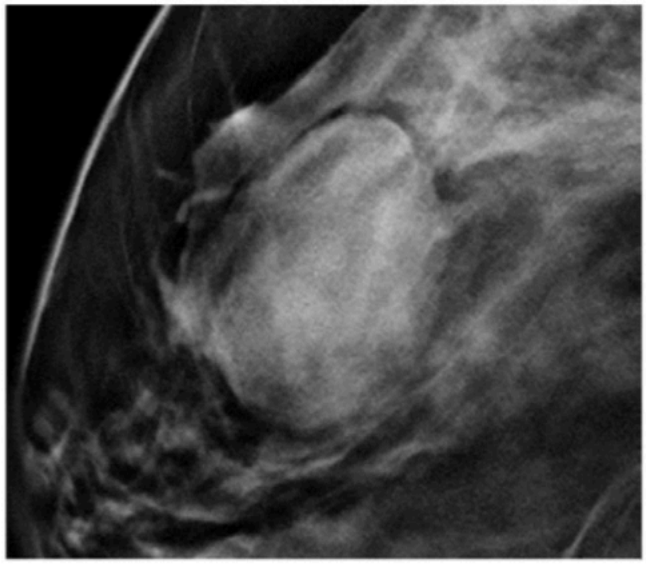

Figure 1 – OVAL, obscured, equal density mass (DBT). Simple cyst.

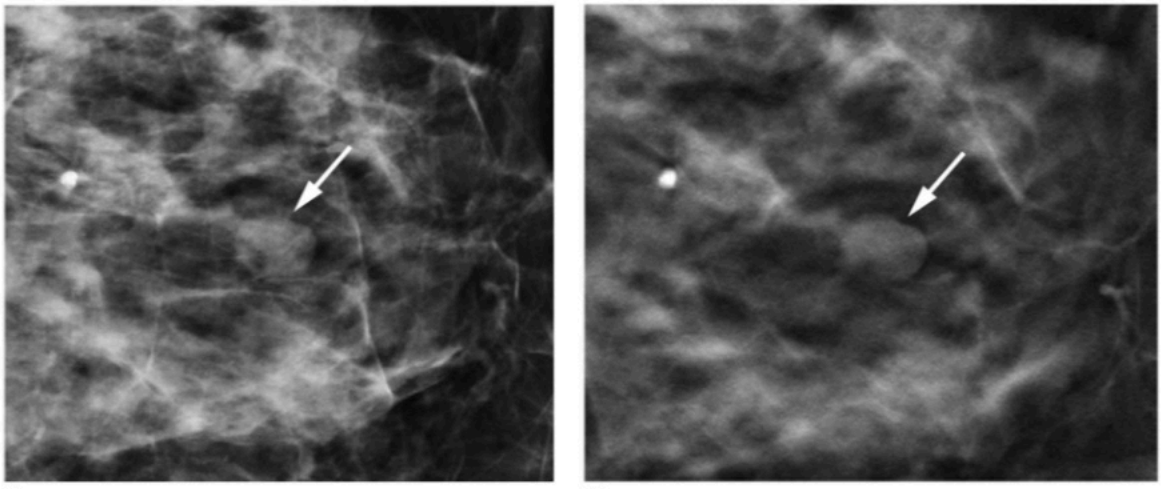

A B

Figure 2 – OVAL, circumscribed, equal density mass (arrows). (A) DM (B) DBT. Pathology: Invasive ductal carcinoma and DCIS.

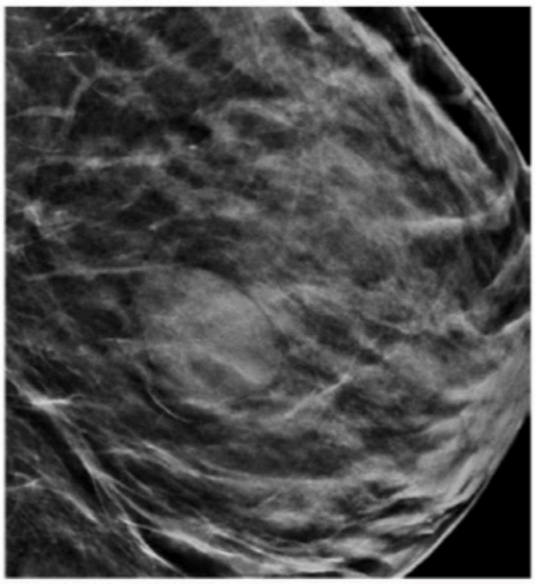

Figure 3 – OVAL, obscured, equal density mass (SM). Simple cyst.

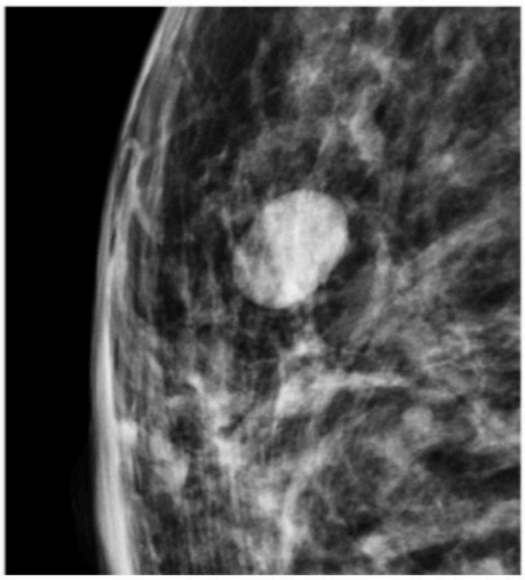

Figure 4 – OVAL, circumscribed, high density mass (DM). Simple cyst.

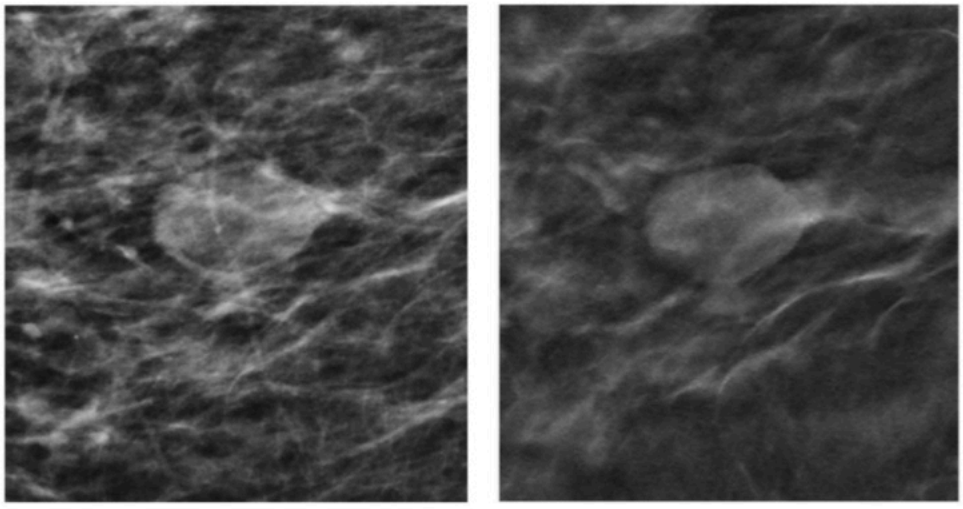

A B

Figure 5 – OVAL, obscured, equal density mass (A)(DM). The margin of this mass is better characterized on DBT (B) compared with the corresponding DM view. Stable mass, presumed cyst.

A. MASSES

1. SHAPE

   b. Lobulated

   A lobulated mass displays one or more indentations resulting in an undulating contour. While still usually benign, it is considered slightly more suspicious than an oval mass and this new shape descriptor is useful in adding nuance to mass shape [13–15] (see Guidance section).

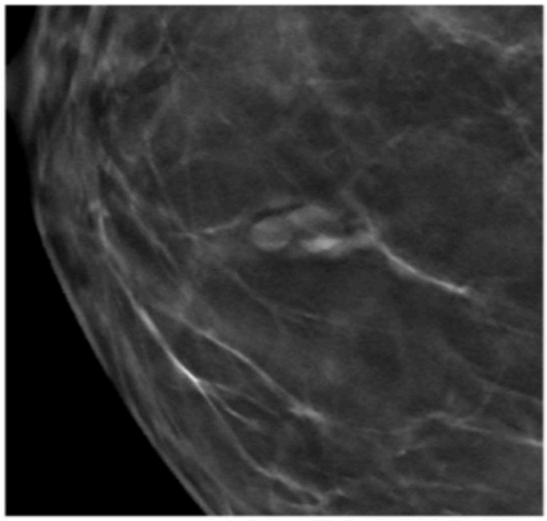

Figure 1 – LOBULATED, circumscribed, equal density mass (DBT). Pathology: Fibroadenoma.

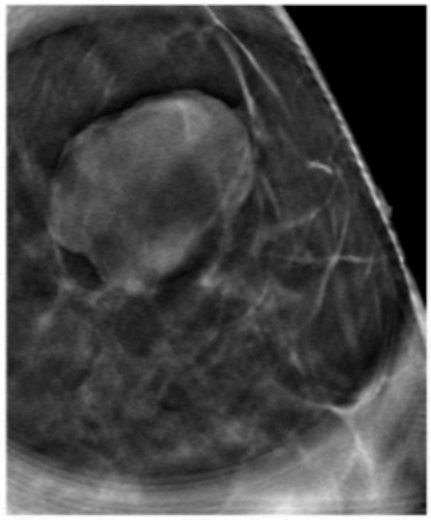

Figure 2 – LOBULATED, circumscribed mass (DBT). Pathology: Fibroadenoma.

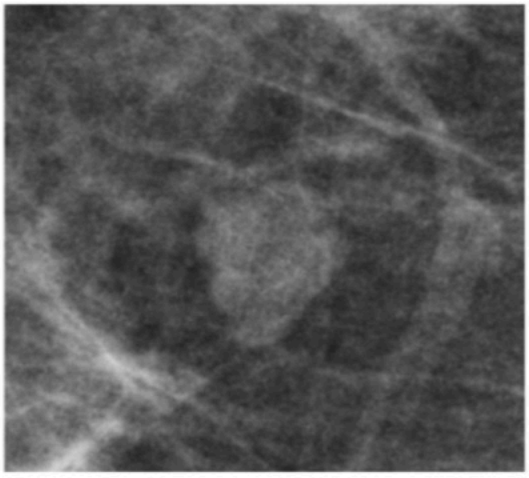

Figure 3 – LOBULATED, circumscribed, equal density mass (DM). Clustered microcysts.

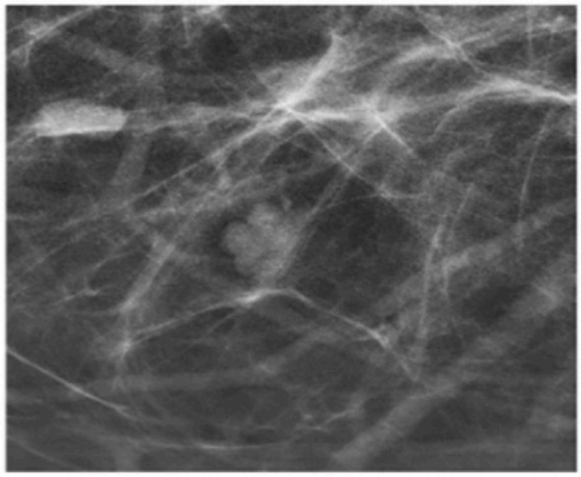

Figure 4 – LOBULATED, circumscribed, equal density mass (DM). Clustered microcysts.

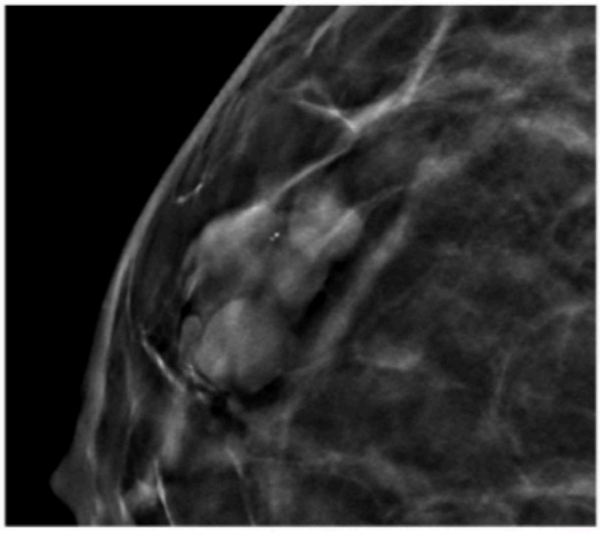

Figure 5 – LOBULATED, circumscribed, high density mass (DBT). Stable mass, presumed fibroadenoma.

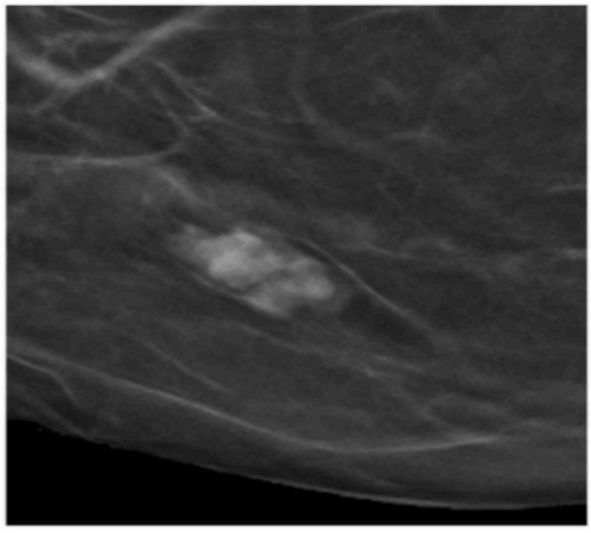

Figure 6 – LOBULATED, circumscribed, high density mass (DBT). Stable mass, presumed fibroadenoma.

A. MASSES

1. SHAPE

   c. Round

   A round mass is spherical or circular in shape with all three axes roughly the same length. Of note, a mass with an oval shape on one view and a round shape on another view should be classified as oval. A round mass may be either malignant or benign.

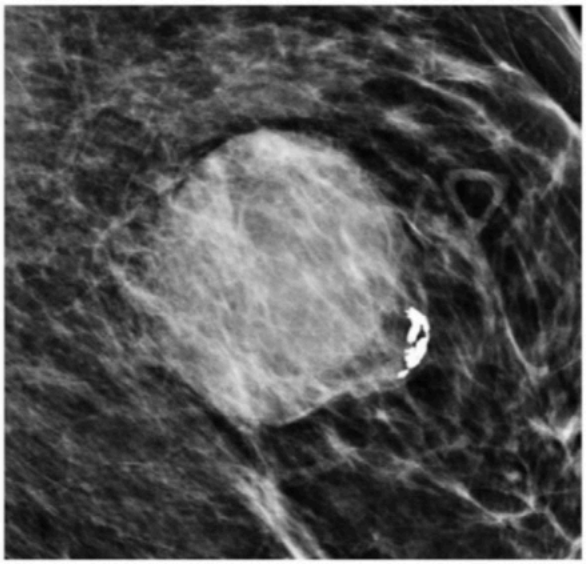

Figure 1 – ROUND, obscured, high density mass (DM). Pathology: Benign phyllodes tumor.

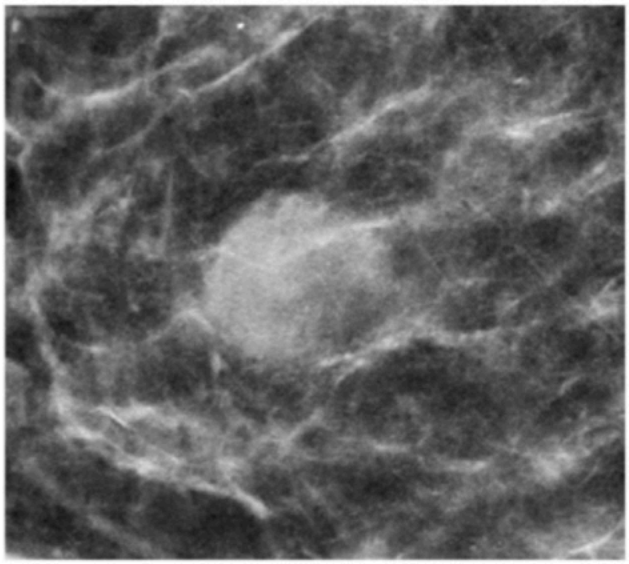

Figure 2 – ROUND, indistinct, high density mass (SM). Pathology: Fibroadenoma.

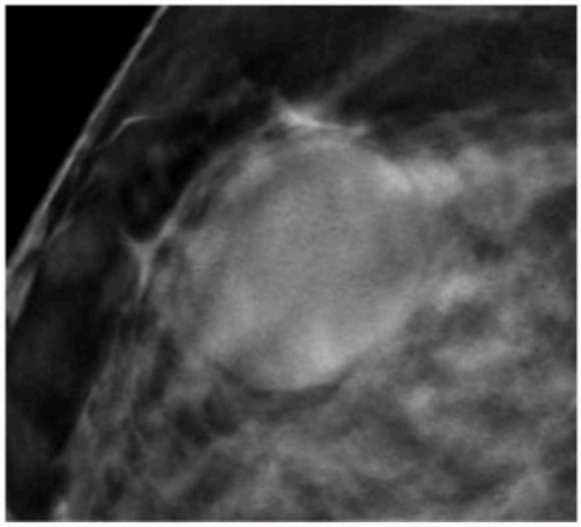

Figure 3 – ROUND, circumscribed, high density mass (DBT). Pathology: Simple cyst.

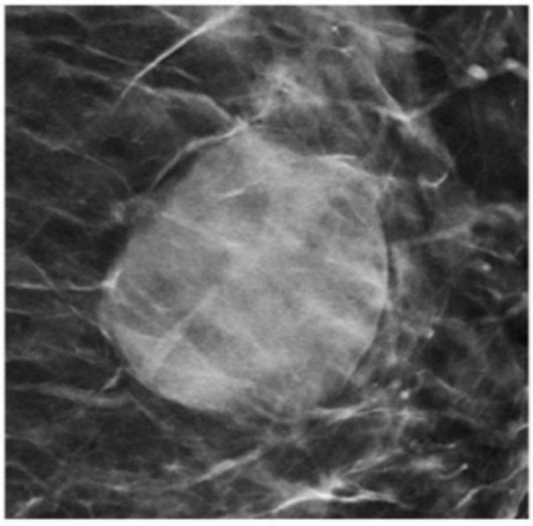

Figure 4 – ROUND, circumscribed, high density mass (SM). Pathology: Simple cyst.

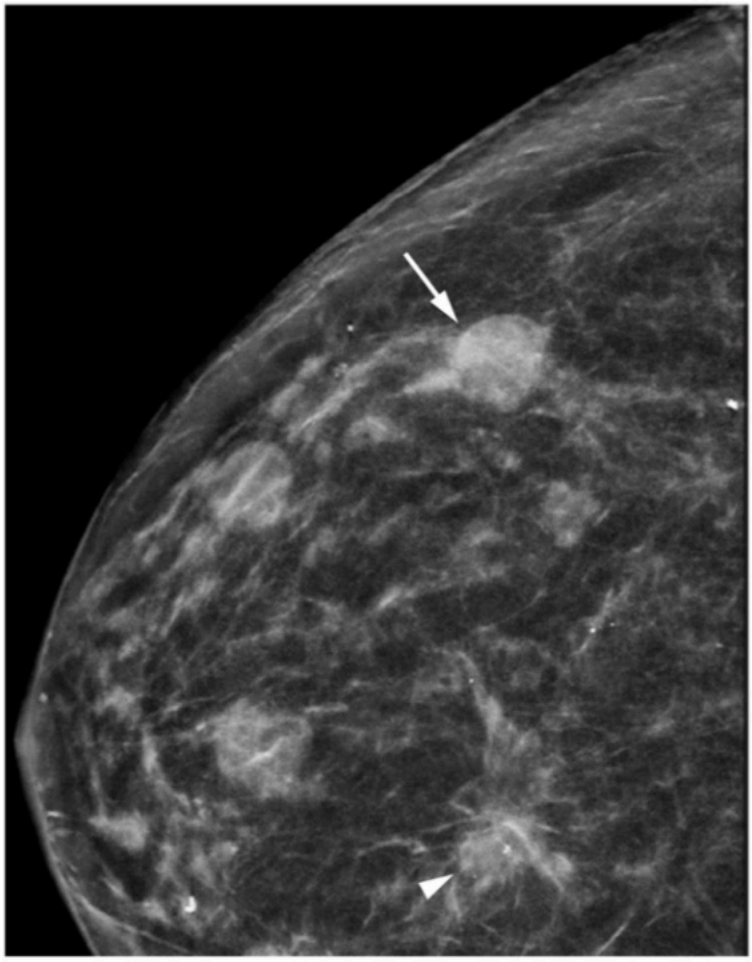

Figure 5 – ROUND, obscured, high density mass (arrow). Multiple additional masses are present, including an irregular, spiculated mass (arrowhead) (SM). Pathology: Simple cyst (arrow); invasive ductal carcinoma on biopsy (arrowhead).

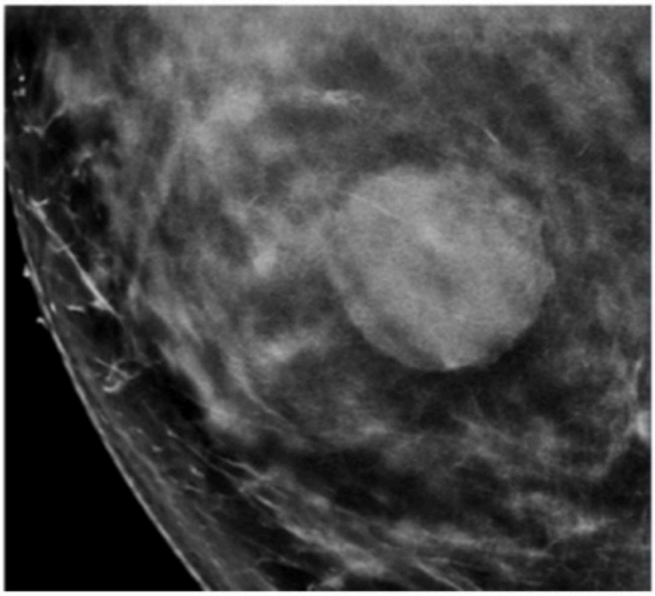

Figure 6 – ROUND, indistinct, high density mass (SM). Pathology: Triple negative invasive ductal carcinoma.

A. MASSES

1. SHAPE

   d. Irregular

   An irregular mass is neither round, lobulated, nor oval, and shows acute-angle protruding portions. The use of this descriptor usually implies a suspicious finding. A mass with numerous angular or deep lobulations should be described as irregular in shape.

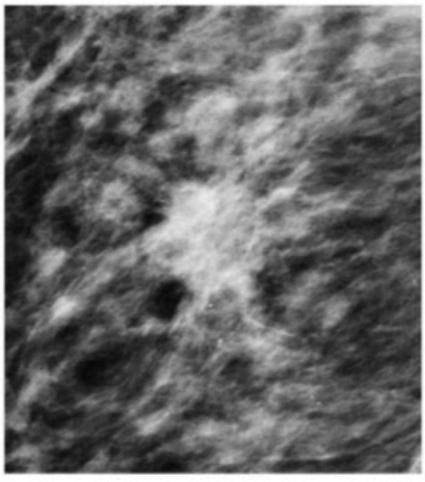

Figure 1 – IRREGULAR, spiculated, high density mass (DM). Pathology: Invasive ductal carcinoma.

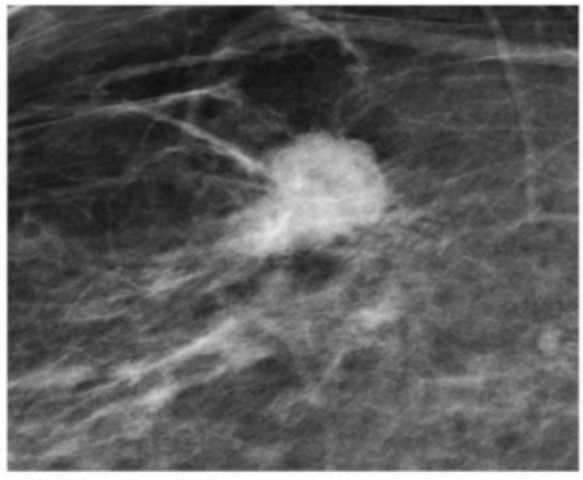

Figure 2 – IRREGULAR, indistinct, high density mass (SM). Pathology: Invasive ductal carcinoma.

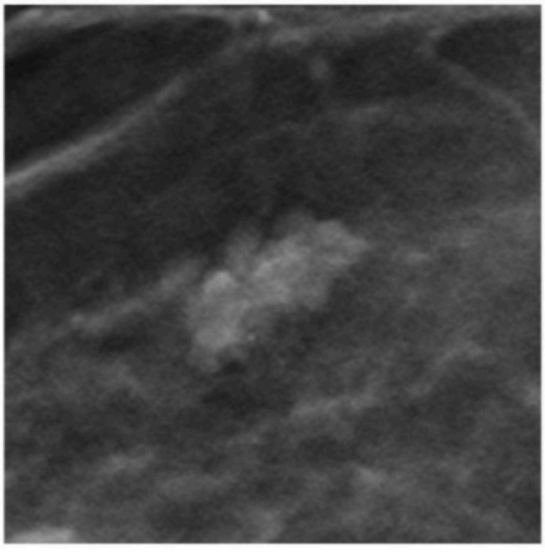

Figure 3 – IRREGULAR, indistinct, high density mass (DBT). Pathology: Clustered microcysts.

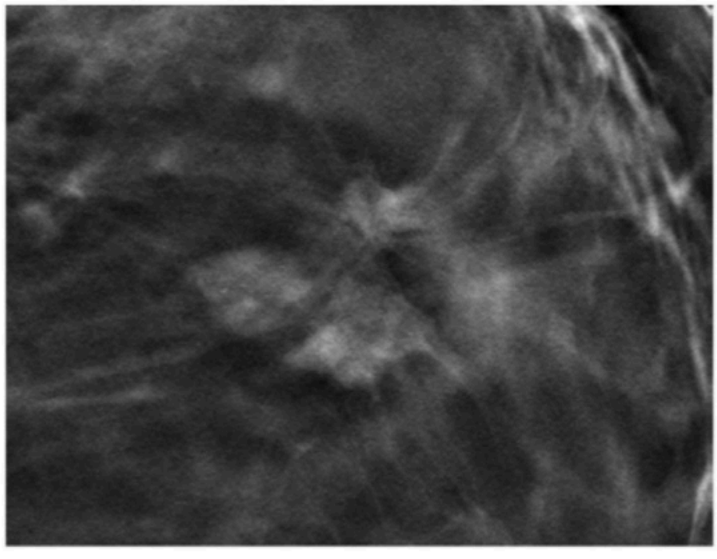

Figure 4 – IRREGULAR, spiculated, equal density mass (DBT). Pathology: Invasive lobular carcinoma.

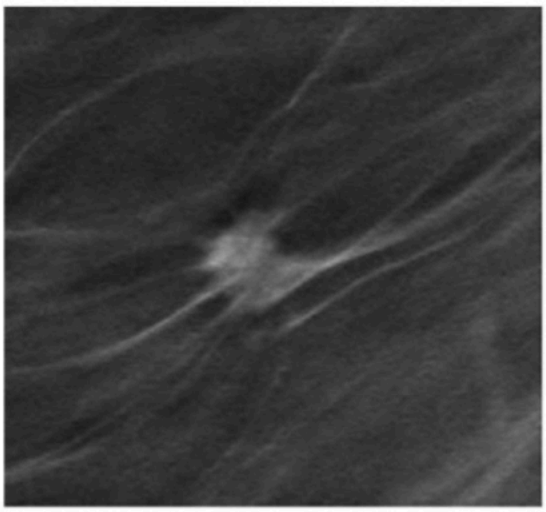

Figure 5 – IRREGULAR, spiculated, high density mass (DBT). Pathology: Invasive ductal carcinoma.

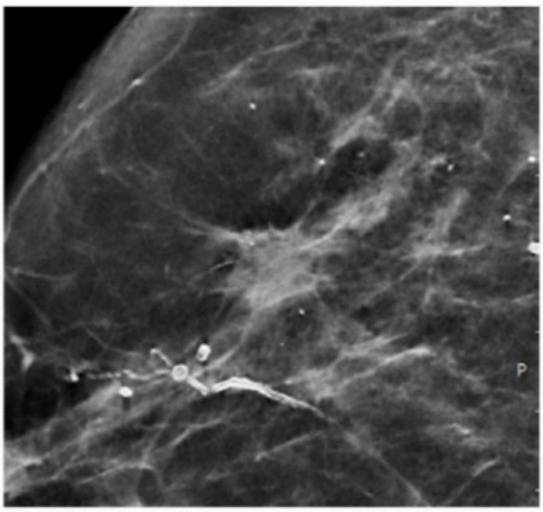

Figure 6 – IRREGULAR, spiculated, high density mass (SM). Pathology: Invasive ductal carcinoma.

A. MASSES

2. MARGIN

The margin is the edge or border of a mass. Margin descriptors, like shape descriptors, are important predictors of whether a mass is benign or malignant.

Margins on tomosynthesis: DBT provides improved characterization of mass margins compared to DM due to reduced tissue superimposition. As a result, the mass margin should typically be characterized on DBT slice images, when available, rather than on the DM images. For example, if a mass margin appears obscured on the two-dimensional DM or SM view but is circumscribed on the DBT images, the mass margin should be described as circumscribed (see Figure 5 in Masses: oval).

a. Circumscribed

A circumscribed margin is sharply demarcated with an abrupt transition between the mass and the surrounding tissue. Circumscribed margins are typically associated with benign masses but can be present in some malignancies. Multiple margin descriptors may be apparent on an individual mass. If part of the margin is obscured, but at least 75% of the margin is circumscribed, the mass should be described as circumscribed. A mass for which ***any*** portion of the margin is indistinct or spiculated should be classified on the basis of the most suspicious component (i.e., indistinct or spiculated).

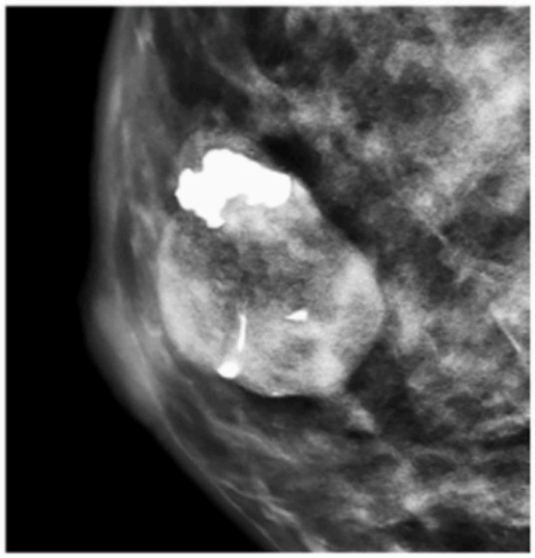

Figure 1 – Oval, CIRCUMSCRIBED, equal density mass with coarse calcifications (DM). Pathology: Fibroadenoma.

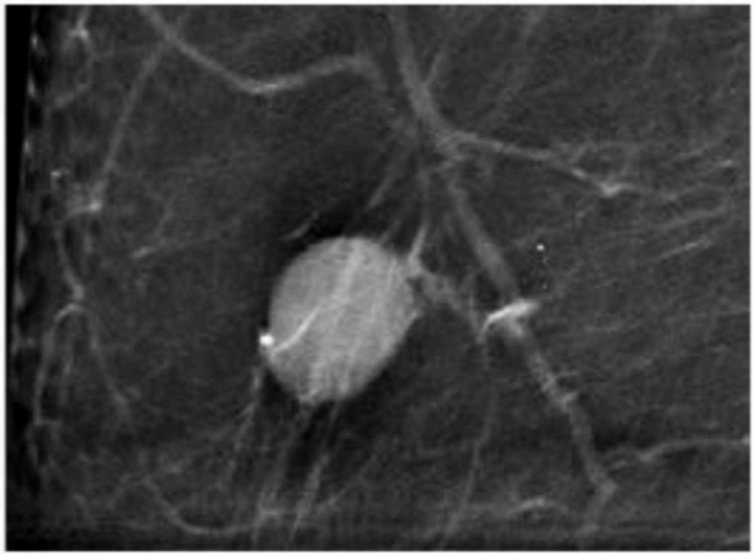

Figure 2 – Oval, CIRCUMSCRIBED, high density mass (DBT). Pathology: Low grade B-cell Non-Hodgkin's Lymphoma.

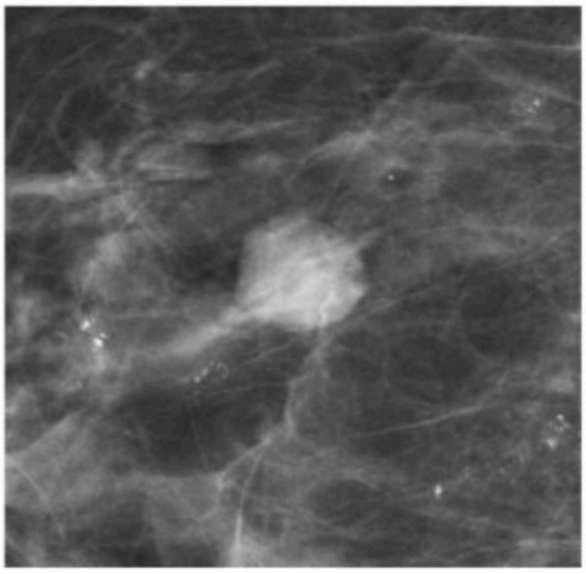

Figure 3 – Oval, CIRCUMSCRIBED, high density mass (DM). Simple cyst.

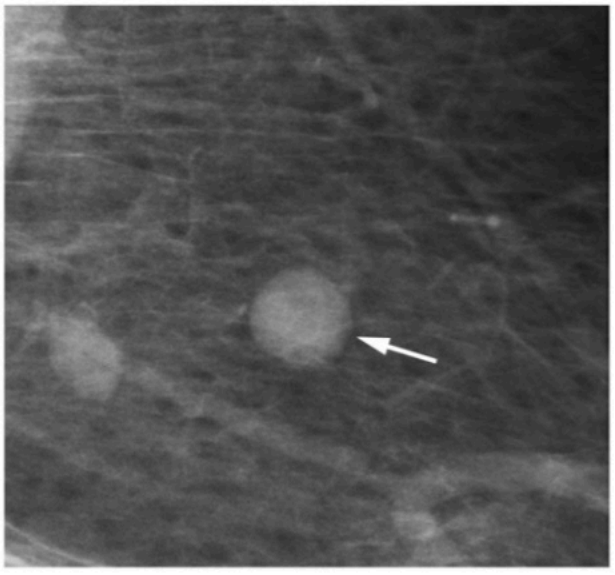

Figure 4 – Round, CIRCUMSCRIBED (arrow), high density mass (SM). Simple cyst.

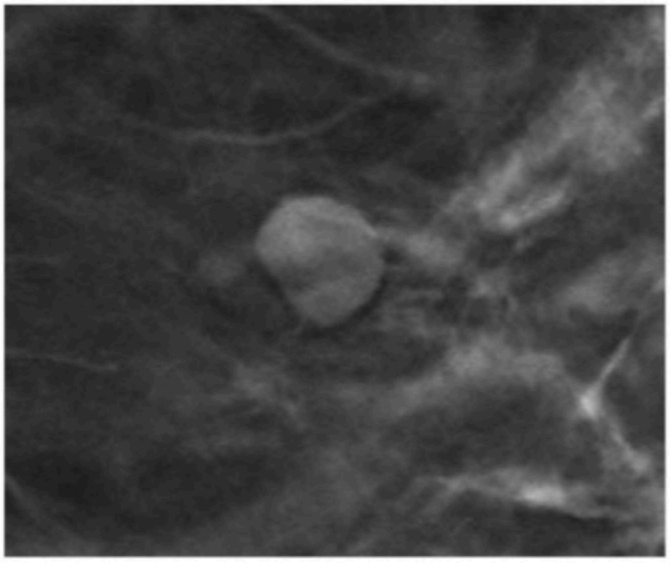

Figure 5 – Oval, CIRCUMSCRIBED, high density mass (DBT). Simple cyst.

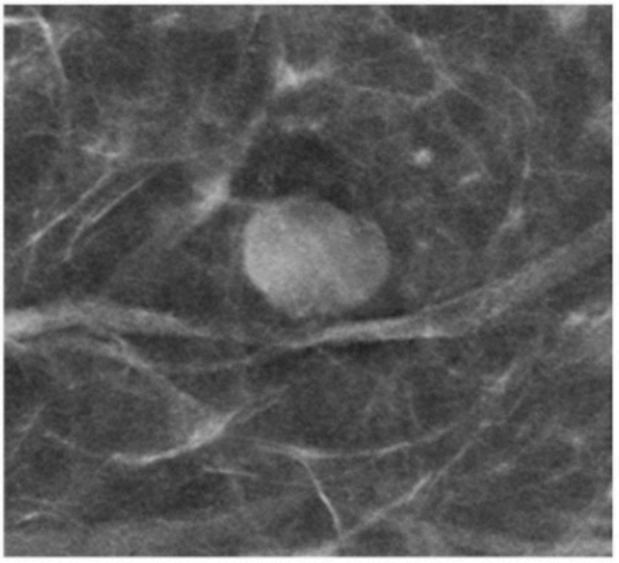

Figure 6 – Oval, CIRCUMSCRIBED, high density mass (SM). Simple cyst.

A. MASSES

2. MARGIN

b. Obscured

An obscured margin is hidden by superimposed or adjacent fibroglandular tissue. It is often used when some of the mass margin is circumscribed but the rest (> 25%) is not visible. By definition, an obscured margin descriptor should not be used when the margin is adjacent to fat. In this case the "indistinct" descriptor should be used (i.e., the margin is visible but not well-defined [see Margin-c. Indistinct]). An obscured margin at screening DM should be reclassified at diagnostic mammography (e.g., spot compression views or at DBT) if an alternative descriptor is more accurate. Obscured margins do not imply either benignity nor suspicion, only that adequate characterization of the margin of the mass cannot be made. In such cases, evaluation of the margin on spot compression views, DBT or ultrasound may provide clarity.

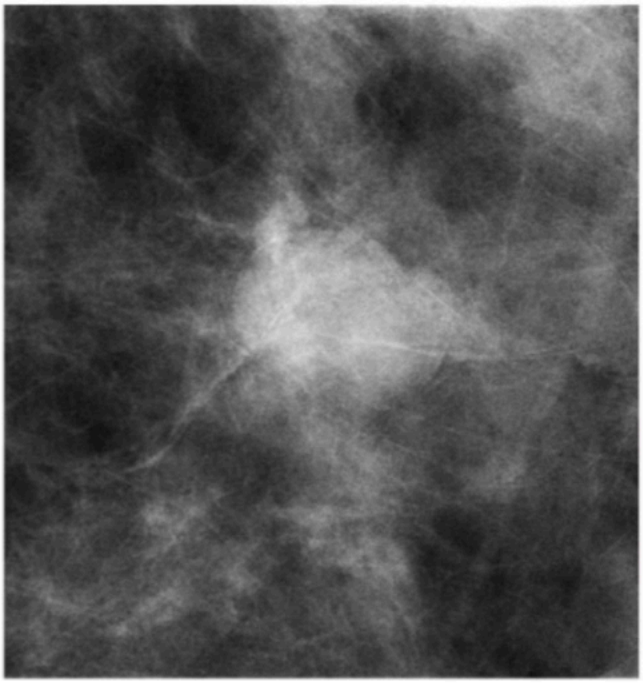

Figure 1 – Irregular, OBSCURED, high density mass (DM).
Pathology: Invasive ductal carcinoma.

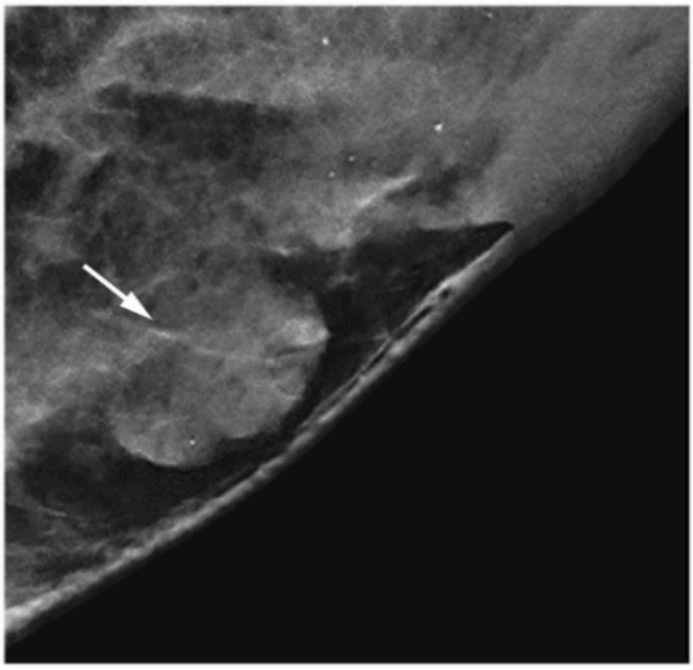

Figure 2 – Lobulated, OBSCURED (arrow), equal density mass (SM). Pathology: Cyst.

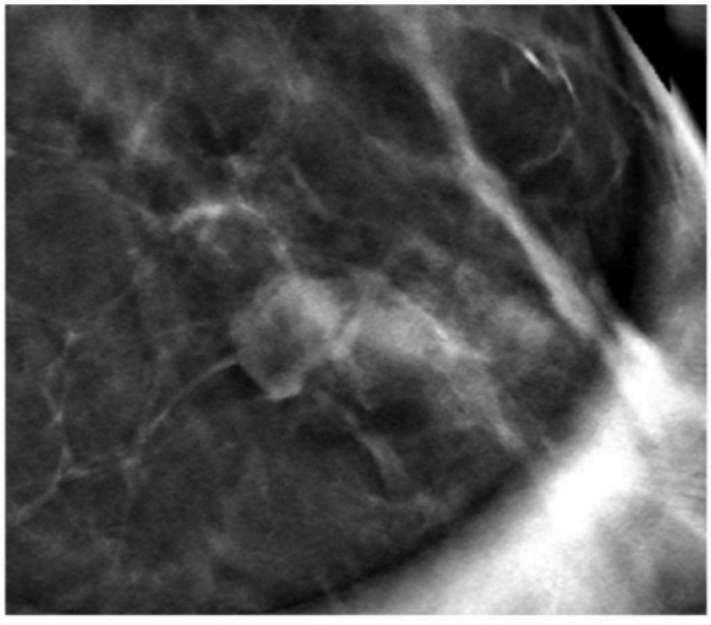

Figure 3 – Oval, OBSCURED equal density mass (DBT). Pathology: Invasive ductal carcinoma.

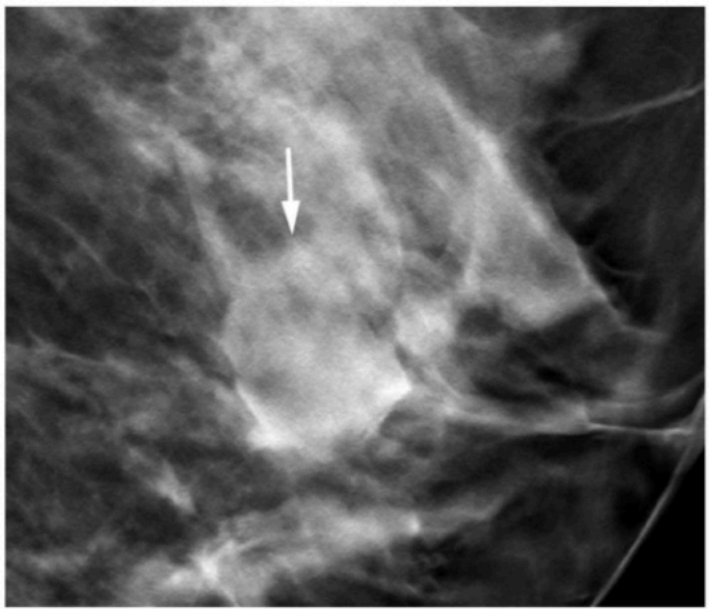

Figure 4 – Oval, OBSCURED (arrow delineates obscured portion of margin), high density mass (DBT). Pathology: Cyst.

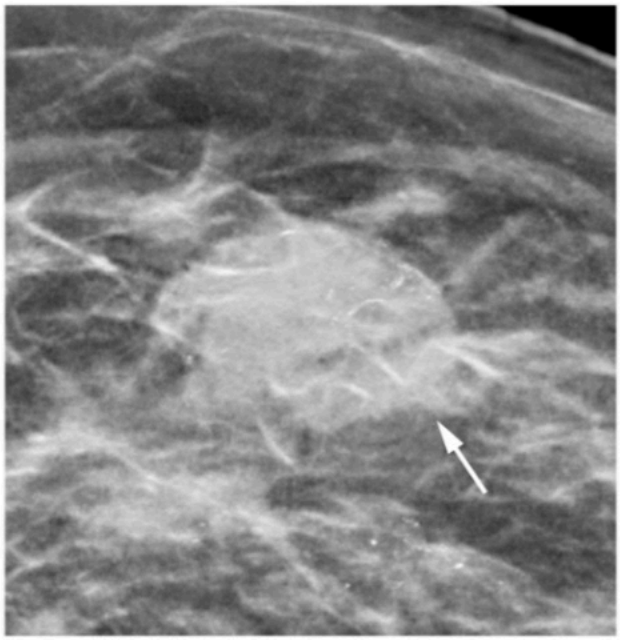

Figure 5 – Oval, OBSCURED high density mass (arrow) (SM). Pathology: Fibroadenoma.

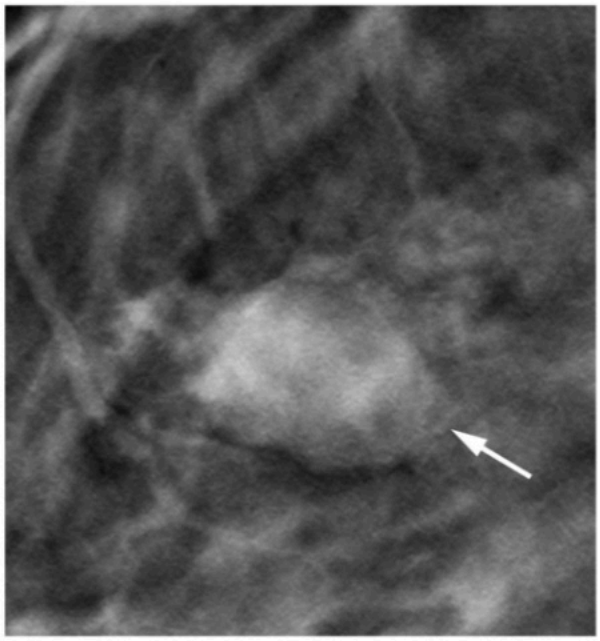

Figure 6 – Oval, OBSCURED, equal density mass (arrow) (DBT). Pathology: Fibroadenoma.

A. MASSES

2. MARGIN

c. Indistinct

An indistinct margin indicates lack of sharp demarcation of the entire margin, or any part of the margin, from surrounding tissue. For mammography, this descriptor should not be used when the interpreting physician believes it is likely due to immediately adjacent breast tissue, in which case it would be considered obscured. An indistinct margin implies a suspicious finding.

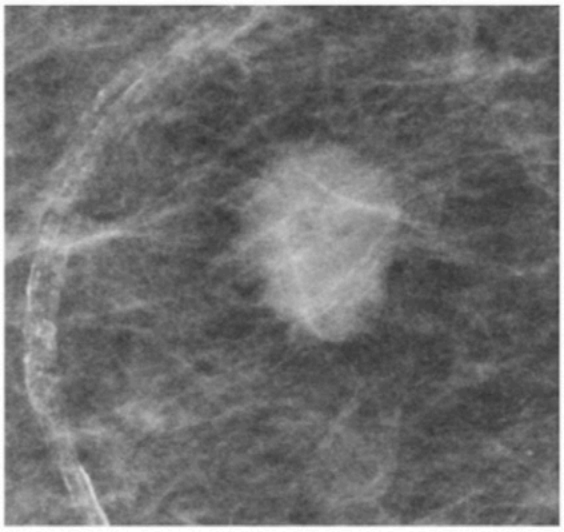

Figure 1 – Oval, INDISTINCT high density mass (DM). Pathology: Invasive ductal carcinoma.

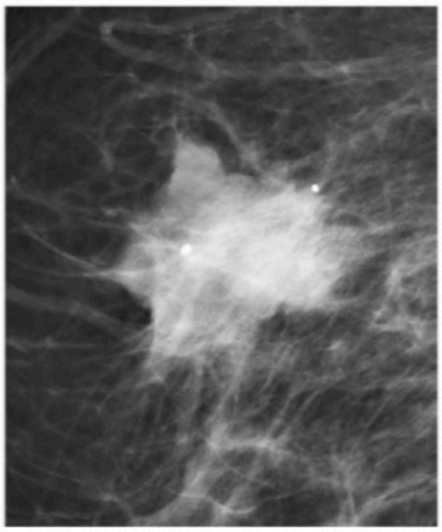

Figure 2 – Irregular, INDISTINCT, high density mass (DM). Pathology: Invasive ductal carcinoma.

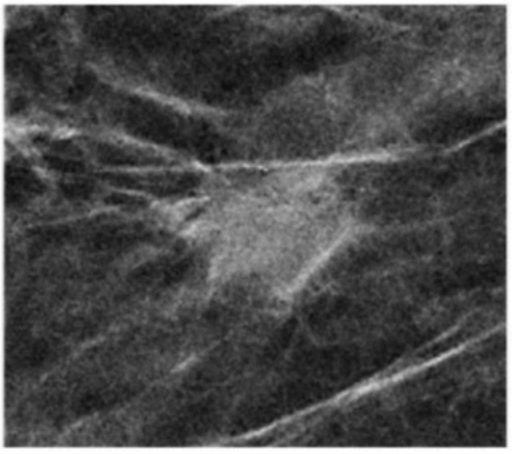

Figure 3 – Irregular, INDISTINCT, equal density mass (SM). Pathology: Invasive ductal carcinoma.

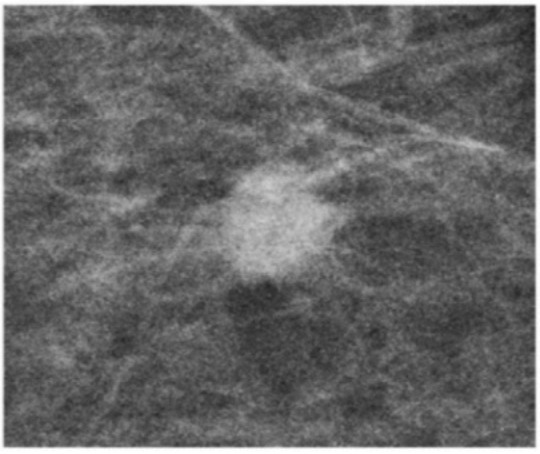

Figure 4 – Round, INDISTINCT, equal density mass (SM). Pathology: Invasive ductal carcinoma.

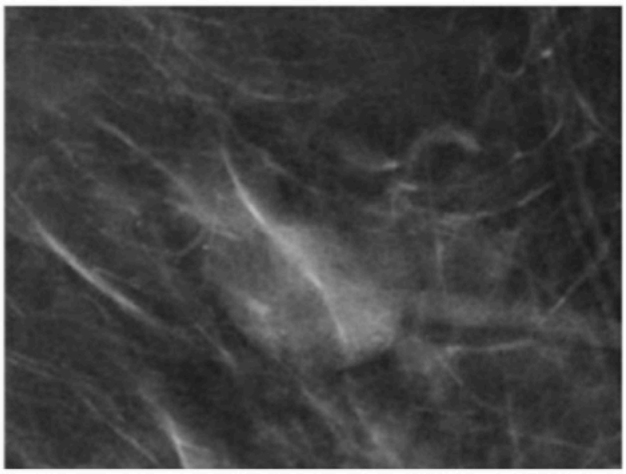

Figure 5 – Oval, INDISTINCT, equal density mass (SM). Pathology: Pseudoangiomatous stromal hyperplasia (PASH).

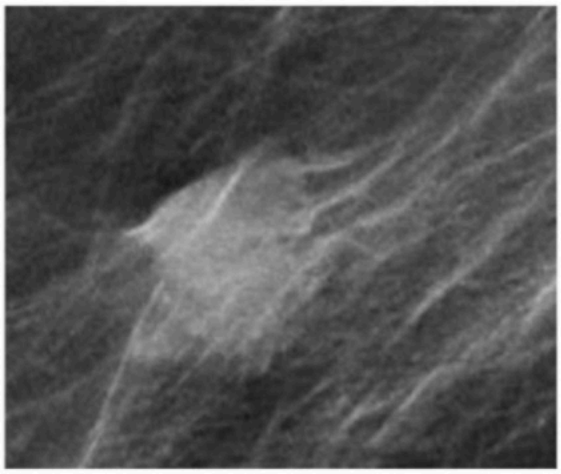

Figure 6 – Irregular, INDISTINCT, high density mass (SM). Pathology: Invasive ductal carcinoma with mucinous features.

A. MASSES

2. MARGIN

d. Spiculated

A spiculated margin is characterized by lines radiating from the mass. Use of this descriptor implies a suspicious finding. Although architectural distortion may appear similar to a spiculated mass, architectural distortion lacks a 3-dimensional, space-occupying structure centrally. A mass with spiculated margins should not be described as architectural distortion.

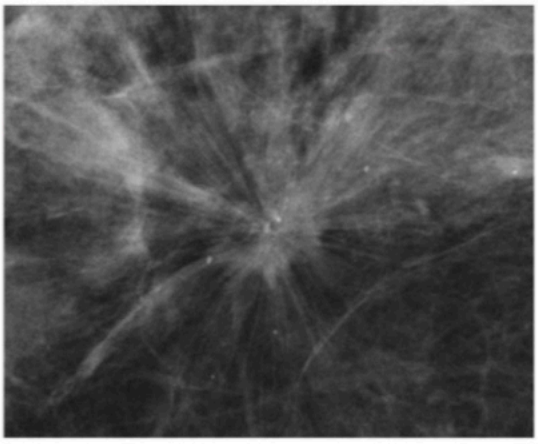

Figure 1 – Irregular, SPICULATED, equal density mass (DM). Pathology: Invasive ductal carcinoma.

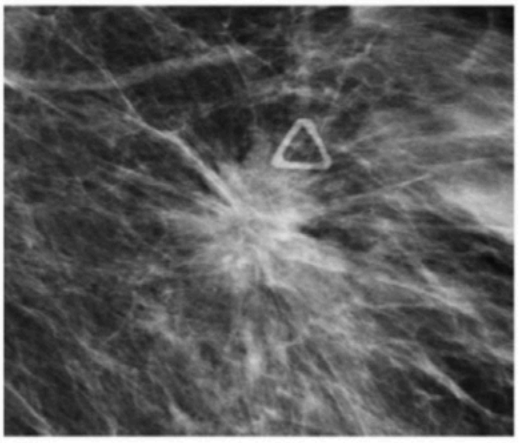

Figure 2 – Irregular, SPICULATED, high density mass (DM). Pathology: Invasive ductal carcinoma.

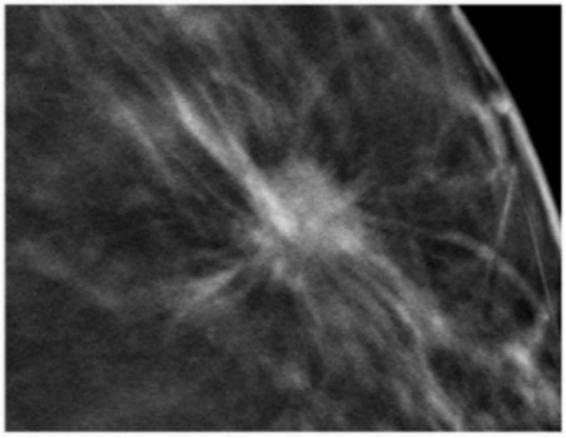

Figure 3 – Round, SPICULATED, high density mass (DBT). Pathology: Invasive ductal carcinoma.

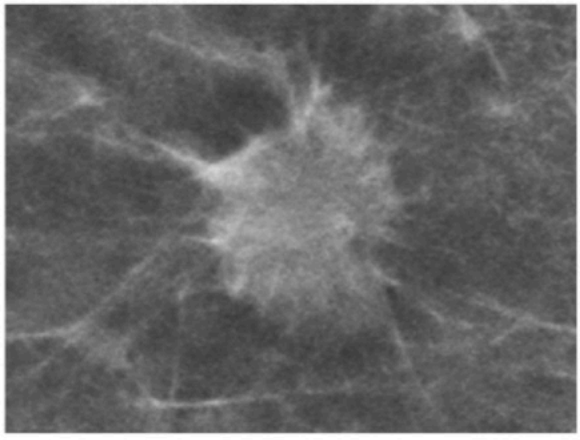

Figure 4 – Oval, SPICULATED, equal density mass (DBT). Pathology: Invasive ductal carcinoma.

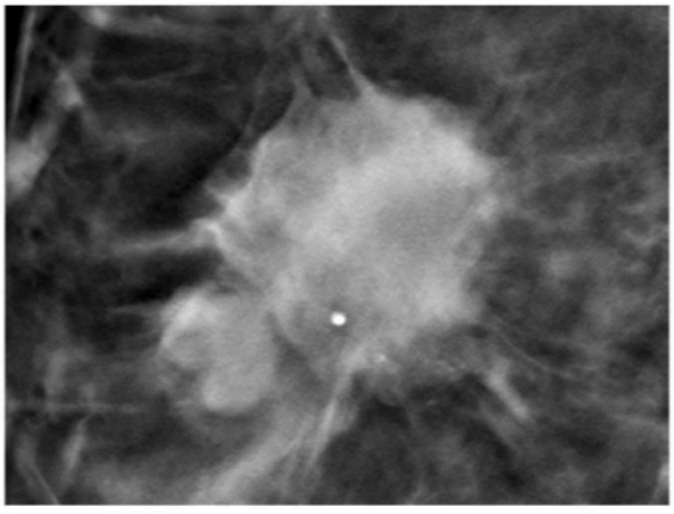

Figure 5 – Irregular, SPICULATED, high density mass (SM). Pathology: Invasive ductal carcinoma.

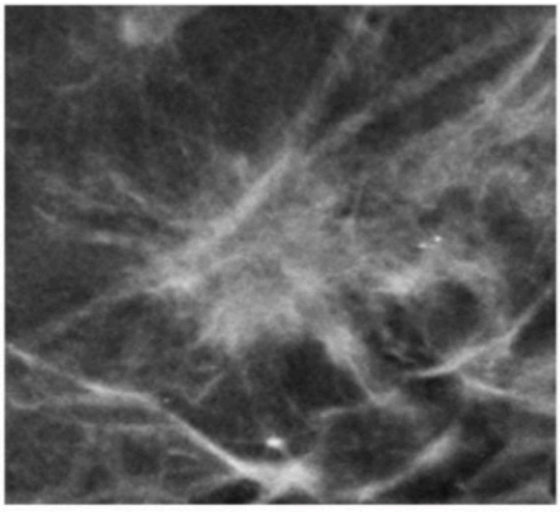

Figure 6 – Irregular, SPICULATED, equal mass density (SM). Pathology: Invasive ductal carcinoma.

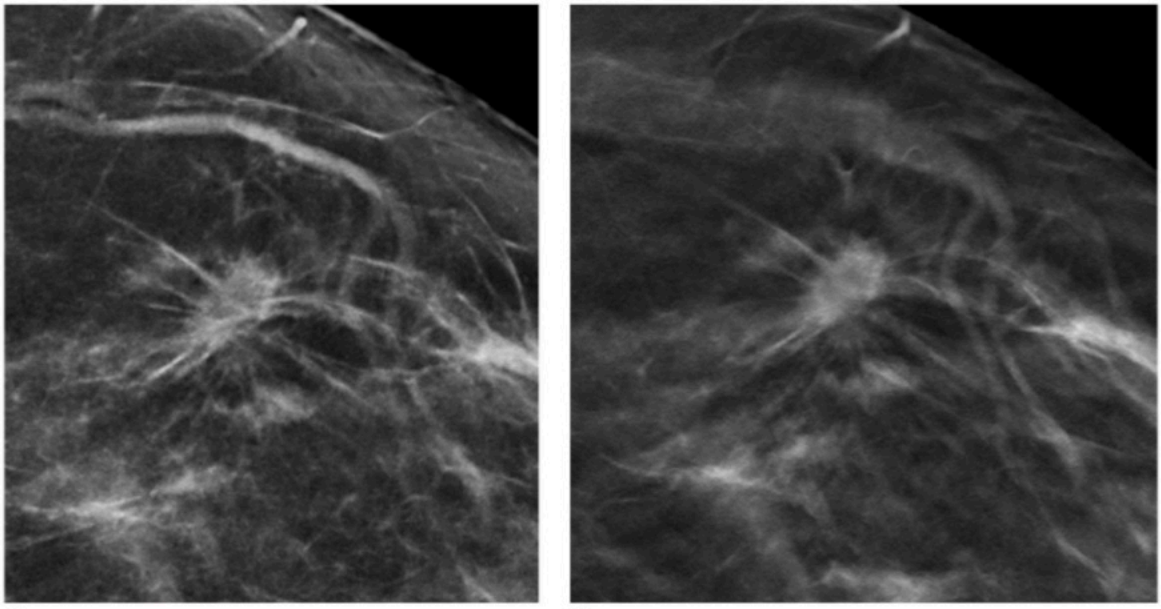

A B

Figure 7 – Irregular, SPICULATED, equal density mass: (A) SM and (B) DBT. Pathology: Invasive ductal carcinoma.

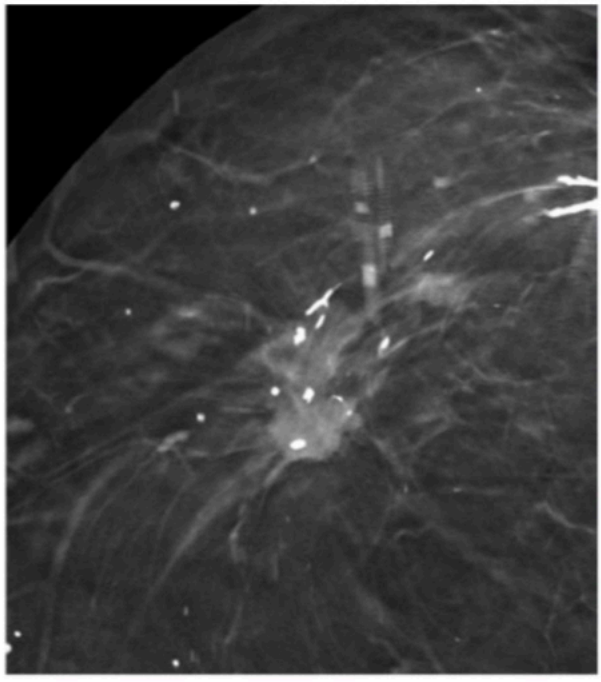

Figure 8 – Irregular, SPICULATED, high density mass (DBT). Pathology: Fat necrosis.

A. MASSES

3. DENSITY

Density is used to define the x-ray attenuation of a mass relative to the expected attenuation of an equal volume of normal fibroglandular tissue. Most breast cancers that present as a mass are of equal or higher density than an equal volume of normal fibroglandular tissue. The likelihood of malignancy for a high density mass (70%) is significantly greater than that for equal- and low-density masses (22%) [16]. It is rare — although not impossible — for breast cancer to be low density. Mass density is a subjective evaluation that is the least reliable of the mammographic mass descriptors (i.e., compared to shape and margin).

a. Fat-Containing

This category includes masses that are completely fat, such as oil cysts and lipomas, as well as mixed-density fat-containing masses, such as hamartomas. A fat-containing mass with circumscribed margins is benign. However, both benign and malignant (especially when imaged with DBT) masses may contain fat. In malignant masses, the radiolucent portion represents areas of entrapped fat.

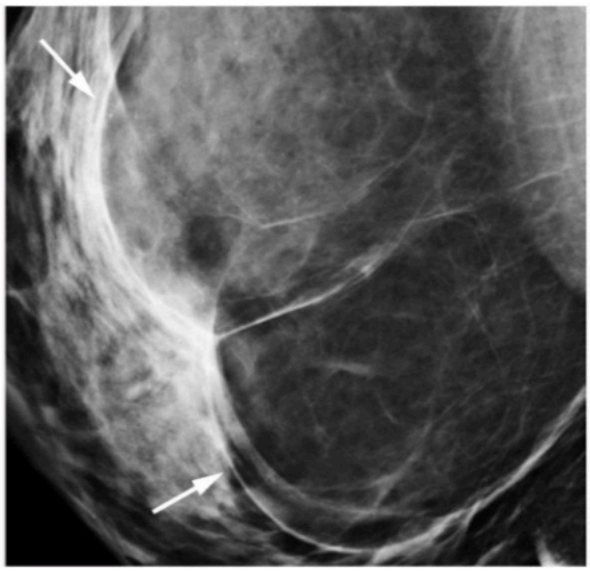

Figure 1 – Oval, circumscribed, FAT-CONTAINING mass (arrows) (DM). This mass appears to consist entirely of fat. Pathology: Lipoma.

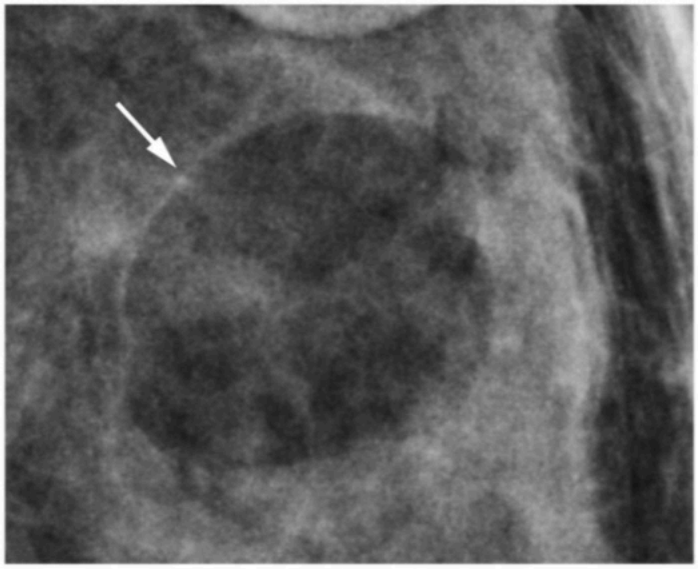

Figure 2 – Oval, circumscribed, FAT-CONTAINING mass (arrow) (DM). This mass appears to consist entirely of fat. Pathology: Lipoma.

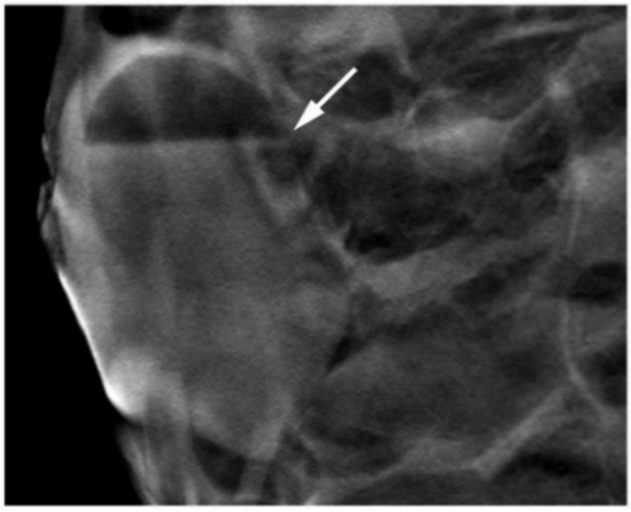

Figure 3 – Oval, obscured, FAT-CONTAINING mass (DBT). Note the fat-fluid level (arrow), indicating that this mass contains fat and non-fatty liquid components, characteristic of a galactocele. Pathology: Galactocele.

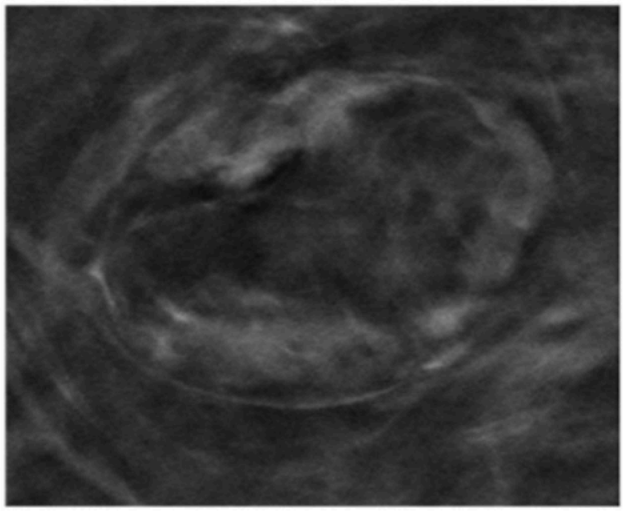

Figure 4 – Oval, circumscribed, FAT-CONTAINING mass (DBT). There are both fatty and soft tissue components within this mass, in keeping with a hamartoma. Pathology: Hamartoma.

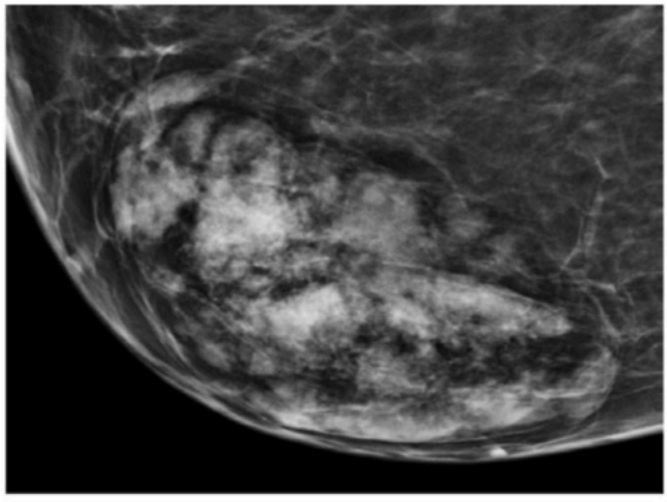

Figure 5 – Oval, circumscribed, FAT-CONTAINING mass (DM). Pathology: Hamartoma.

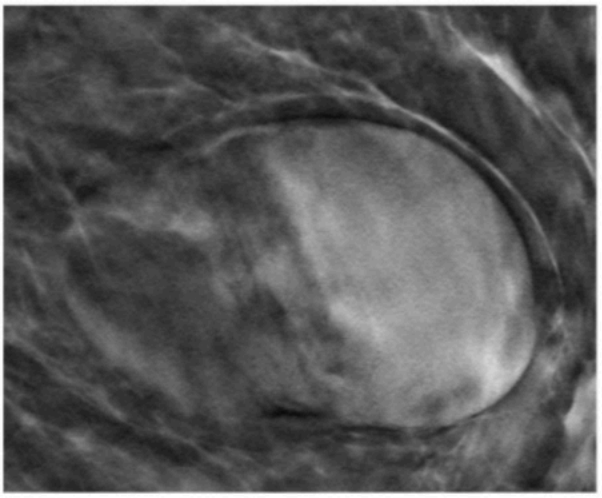

Figure 6 – Oval, obscured, FAT-CONTAINING mass (DBT). Pathology: Hamartoma.

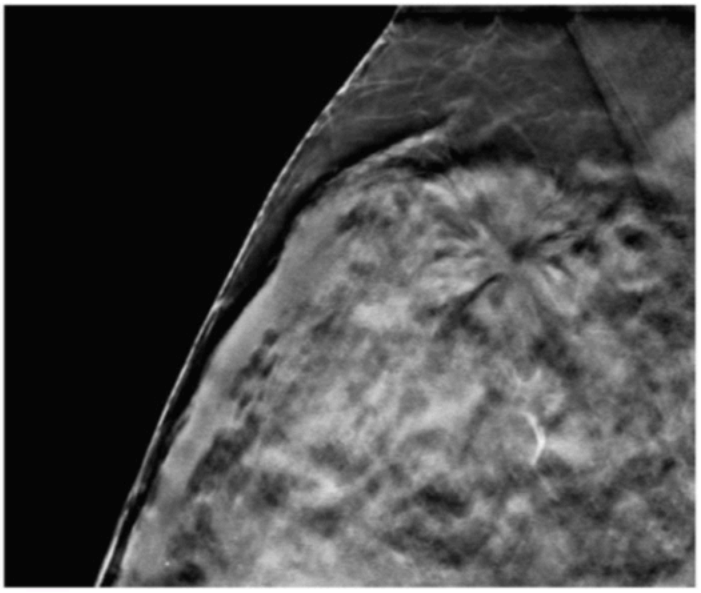

Figure 7 – Irregular, spiculated, FAT-CONTAINING mass (DBT). The fat associated with this mass is entrapped by developing cancer rather than intrinsic to the lesion. Not all fat-containing masses are benign. Pathology: Invasive ductal carcinoma.

A. MASSES

3. DENSITY

b. Low Density

X-ray attenuation of the mass is less than the expected attenuation of an equal volume of fibroglandular tissue.

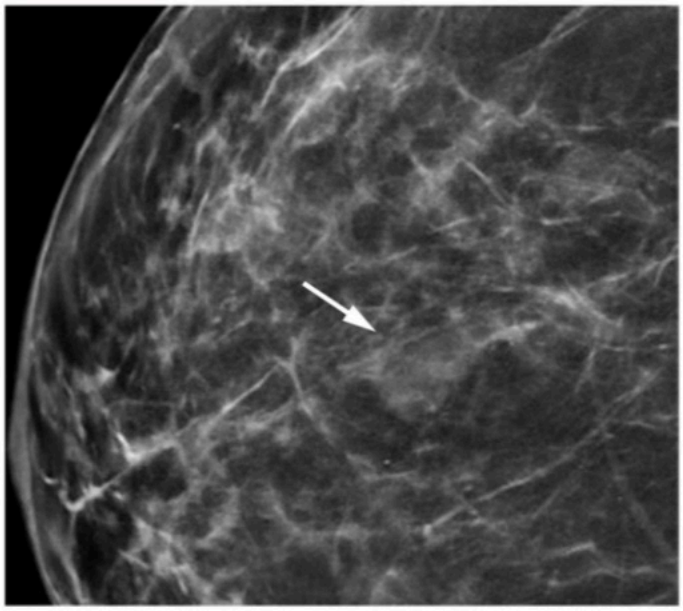

Figure 1 – Oval, indistinct, LOW DENSITY mass (arrow) (SM). Stable, benign.

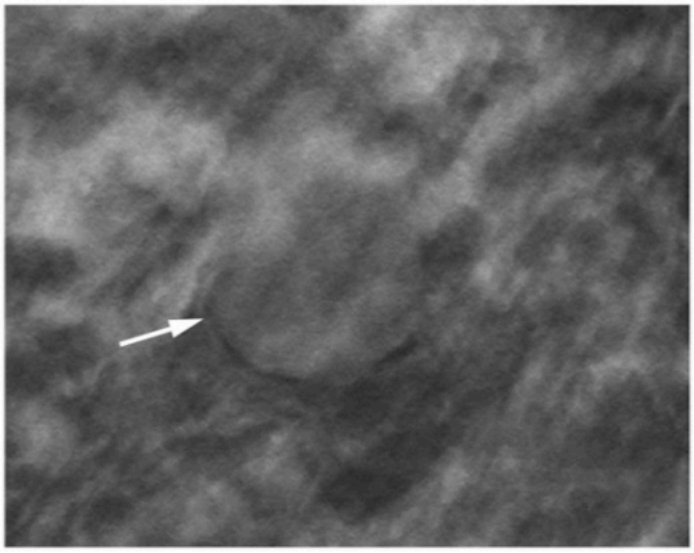

Figure 2 – Oval, obscured, LOW DENSITY mass (arrow) (DBT). Pathology: Simple cyst.

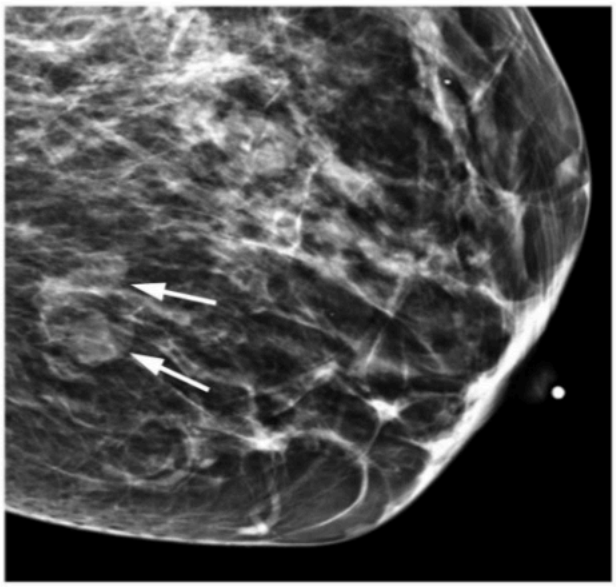

Figure 3 – Oval, indistinct, LOW DENSITY (DM). Two adjacent masses (arrows). Stable, benign.

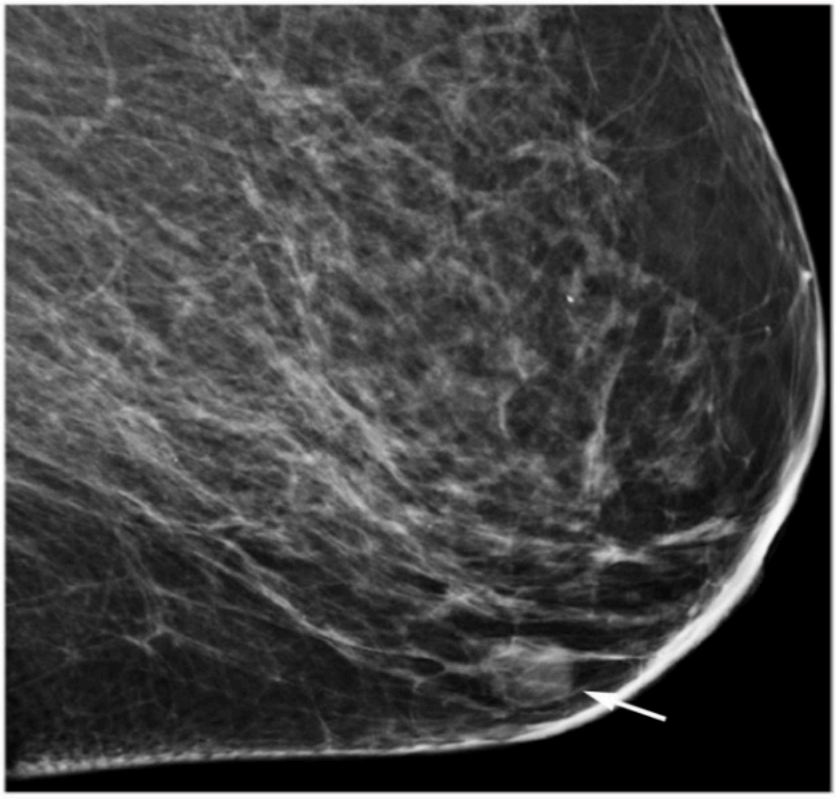

Figure 4 – Oval, circumscribed, LOW DENSITY mass (arrow) (DM). Stable, benign.

A. MASSES

3. DENSITY

c. Equal Density

X-ray attenuation of the mass is the same as the expected attenuation of an equal volume of fibroglandular tissue.



Figure 1 – Round, circumscribed, EQUAL DENSITY mass (SM). Pathology: Simple cyst.

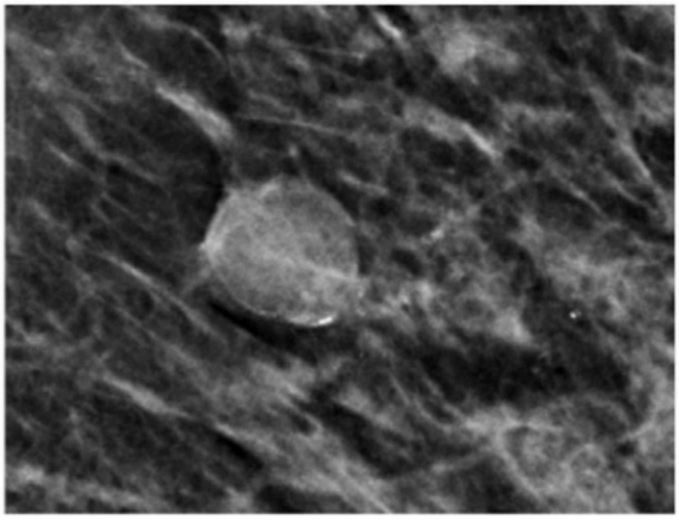

Figure 2 – Oval, circumscribed, EQUAL DENSITY mass (SM). Pathology: Fibroadenoma.

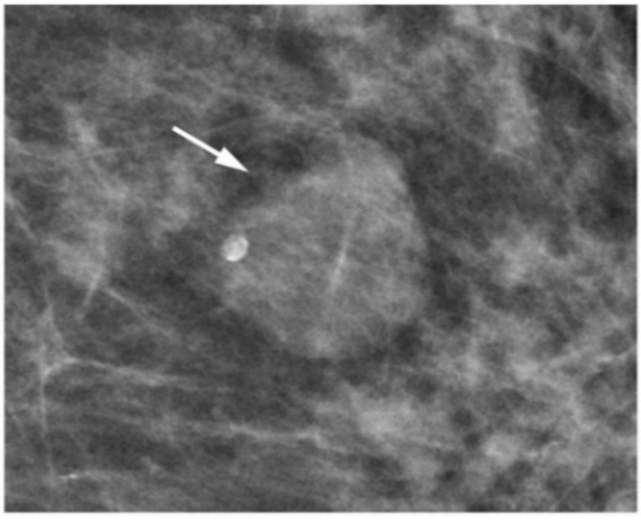

Figure 3 – Round, indistinct, EQUAL DENSITY mass (SM). While most of the margin is circumscribed, part is indistinct (arrow); the mass should therefore be characterized as indistinct. Pathology: Fibroadenoma.

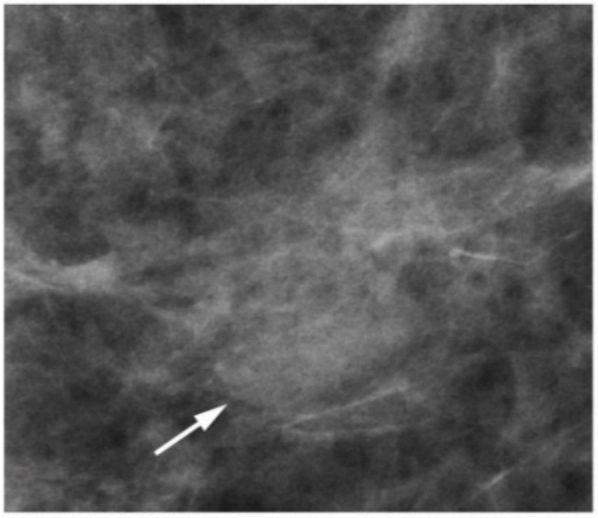

Figure 4 – Oval, obscured, EQUAL DENSITY mass (arrow) (SM). Pathology: Fibroadenoma.

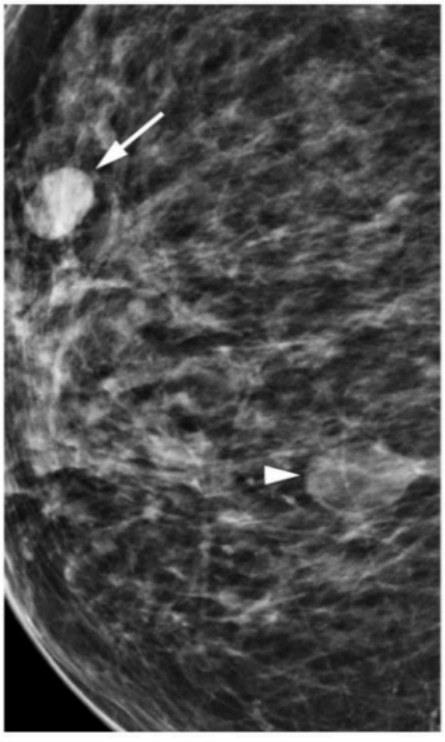

Figure 5 – Oval, obscured, EQUAL DENSITY mass (arrowhead). Also shown: oval, circumscribed, high density mass (arrow) (DM). Pathology: Simple cysts.

A. MASSES

3. DENSITY

d. High Density

X-ray attenuation of the mass is greater than the expected attenuation of an equal volume of fibroglandular tissue.

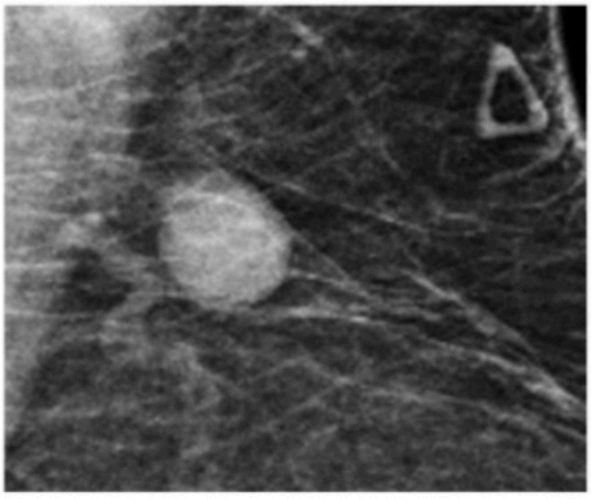

Figure 1 – Round, indistinct, HIGH DENSITY mass (DM). The triangular marker indicates that this mass was palpable. Pathology: Benign reactive lymph node.

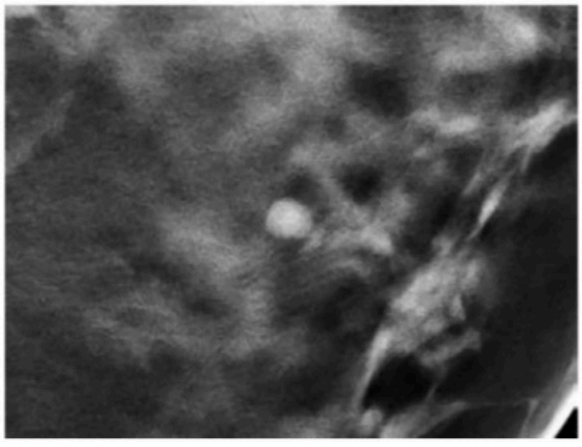

Figure 2 – Round, circumscribed, HIGH DENSITY mass (DBT). Despite its small size, it is denser than adjacent fibroglandular tissue. Stable, benign.

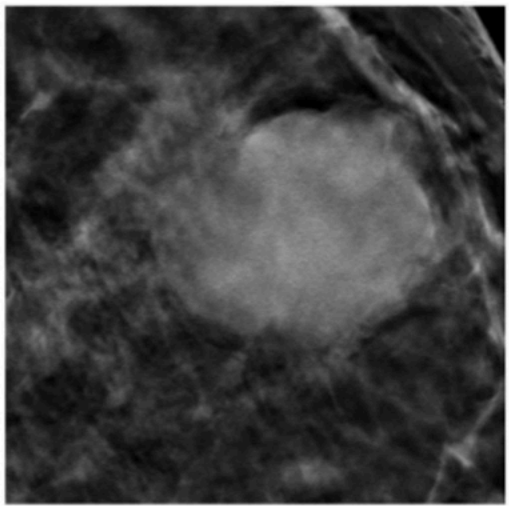

Figure 3 – Oval, indistinct, HIGH DENSITY mass (DBT). Pathology: Invasive ductal carcinoma.

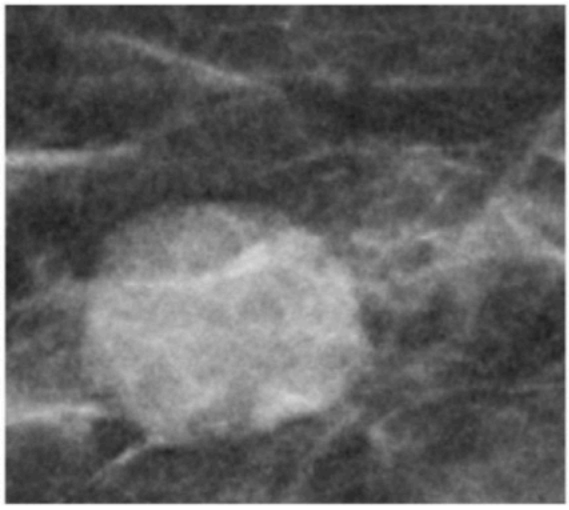

Figure 4 – Oval, indistinct, HIGH DENSITY mass (SM). *Note:* In the BI-RADS 5th Edition, this mass would have been described as microlobulated. Pathology: Fibroadenoma.

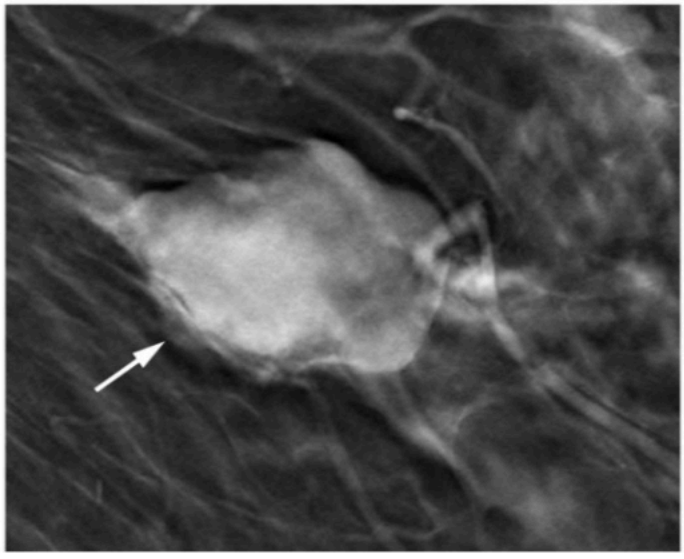

Figure 5 – Irregular, indistinct, HIGH DENSITY mass (DBT). *Note:* Even if the majority of a mass margin is circumscribed, if any portion is indistinct (arrow), the margin should be classified as indistinct. Pathology: Invasive lobular carcinoma.

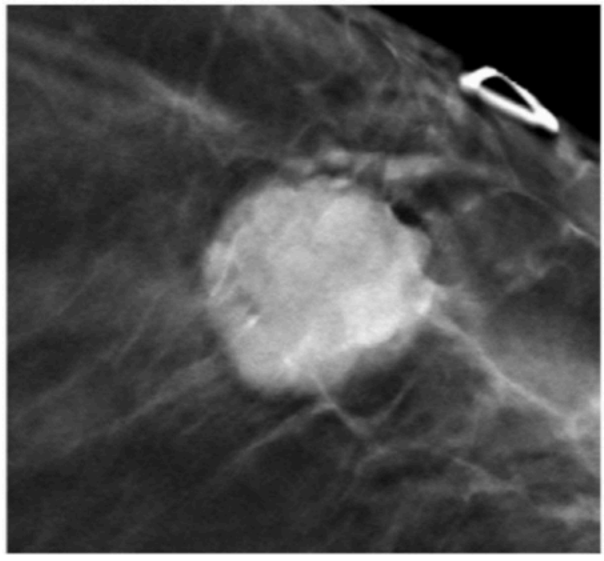

Figure 6 – Round, indistinct, HIGH DENSITY mass (DBT). Pathology: Invasive lobular carcinoma.

B. CALCIFICATIONS

Breast calcifications are radiodense calcium deposits primarily composed of calcium hydroxyapatite and calcium oxalate. They may be associated with both benign and malignant breast lesions [17]. Calcifications assessed as benign on mammography are typically larger, coarser, rounder (with smooth margins), and more conspicuous than malignant calcifications. Calcifications associated with malignancy (but also many benign calcifications) are usually very small (< 0.5 mm) and often require the use of magnification views to be well seen. Magnification views often reveal additional calcifications that are not appreciated on full-field views and should be performed prior to a recommendation for biopsy, and should include 90° lateral and craniocaudal magnification views. When a specific, typically benign etiology cannot be assigned, description of the calcifications should include the morphology, span, location (including distance from nipple), and distribution. Calcifications that are obviously benign need not be reported, especially if the interpreting physician is concerned that the referring provider or patient might infer anything other than absolute confidence in benignity.

It is important to recognize that the algorithms used to reconstruct SM images from the tomosynthesis acquisition may enhance or sometimes alter the appearance of calcifications. Calcifications may appear more conspicuous and coarser on SM. SM views may also contain artifacts that mimic calcifications, termed “pseudocalcifications” [18]. Pseudocalcifications are typically not visible on the DBT slices, confirming their artifactual nature. Faint and/or malignant microcalcifications may sometimes appear less well defined on the SM images due to lower image spatial resolution compared to conventional mammography. As a result, calcification morphology on SM may be incompletely evaluated, necessitating dedicated magnification views for accurate characterization.

B. CALCIFICATIONS

1. TYPICALLY BENIGN

   a. Skin

   Skin calcifications are usually lucent-centered and pathognomonic in their appearance. They are most commonly seen along the inframammary fold, parasternally, overlying the axilla, and around the areola. The calcifications are usually tightly grouped and < 5 mm in greatest dimension. If suspicious-appearing calcifications are seen adjacent to a skin surface on a given mammographic view, they may still be dermal (hence benign) in nature and tangential-view mammography (with or without magnification) or tomosynthesis (with calcifications in question positioned near detector), should be done if there is uncertainty prior to any intervention to avoid unnecessary biopsy. Calcifications seen on the first few or last few DBT slices (1 mm thick) are typically dermal. However, calcifications seen on subsequent superficial DBT slices may also be dermal if the calcifications lie in skin not touching the compression paddle or detector due to the curvature of the breast. These may also require tangential views to confirm their location.



Figure 1 – SKIN calcifications (DM). A few lucent-centered, round calcifications are seen in the inferior breast, including some imaged in tangent (arrow), confirming their dermal nature.

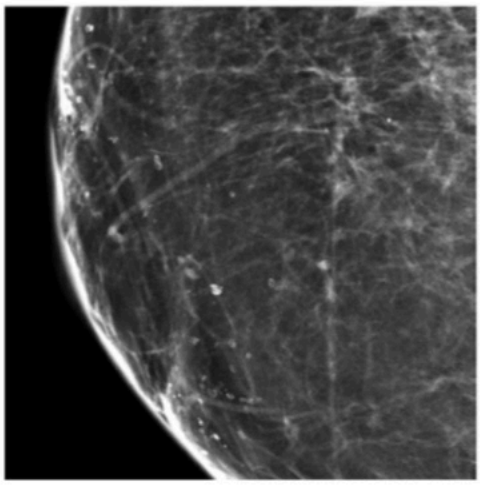

Figure 2 – SKIN calcifications (DM). Multiple lucent-centered calcifications are present, concentrated in the peri-areolar region of this breast that underwent prior reduction surgery.

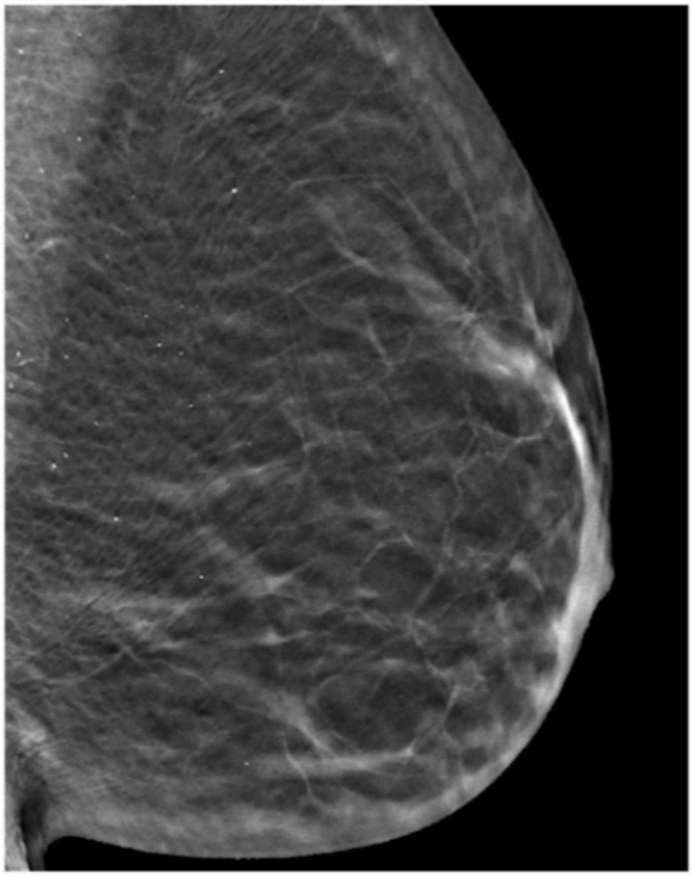

Figure 3 – SKIN calcifications (DBT). Multiple round calcifications are noted to be in focus on DBT slice #1, confirming that they lie in the skin.

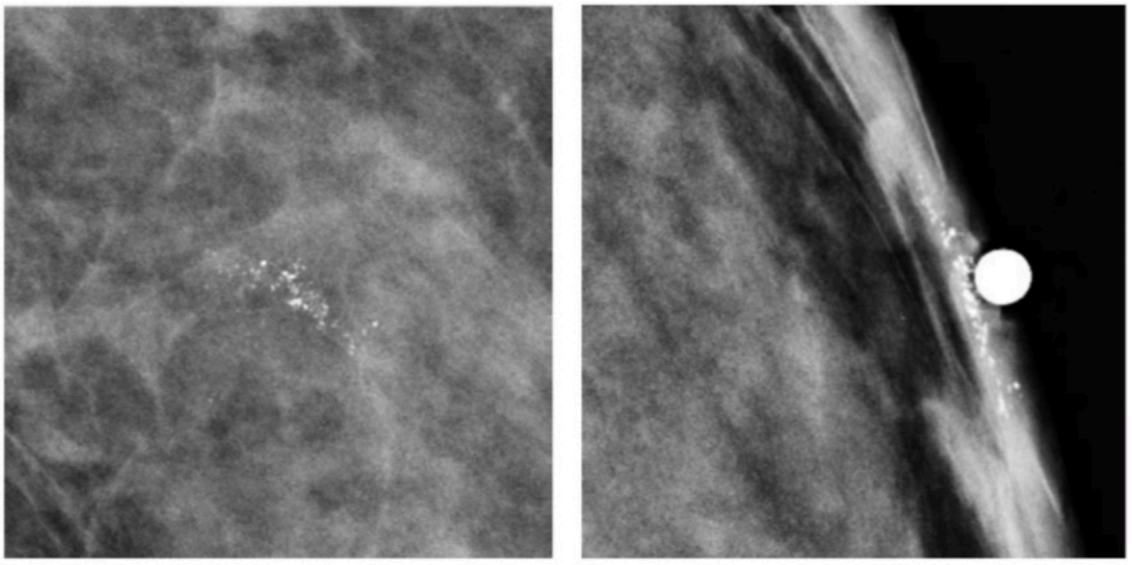

A B

Figure 4 – (A) Grouped SKIN calcifications (CC SM). These calcifications do not have a classic lucent-centered morphology typical of skin calcifications. (B) However, on the tangential view, the calcifications are shown to lie directly under the BB placed on the skin as part of a skin calcium work-up, confirming their dermal nature (tangential view DM).

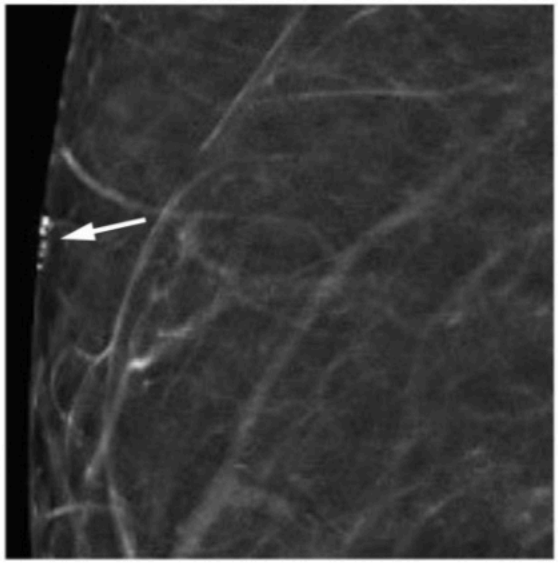

Figure 5 – SKIN calcifications (arrow) (SM MLO).

B. CALCIFICATIONS

1. TYPICALLY BENIGN

b. Vascular

Vascular calcifications present as parallel calcific tracks and are usually clearly associated with arteries. The parallel lines of calcium and the associated vessel may be better depicted on DBT than DM. Vascular calcifications are typically bilateral or seen in more than just an isolated area in one breast. Rarely, if only a few discontinuous calcifications are visible and association with a tubular structure is questionable, additional spot magnification views or a spot compression DBT may be necessary to confirm the relationship with a blood vessel.

Recent evidence suggests that the presence of breast arterial calcifications (BAC) is correlated with increased risk of cardiovascular disease. Therefore, while a benign finding, the presence of vascular calcifications is of clinical significance [17, 18]. Literature continues to accumulate and there is growing discussion around creating standardized reporting language for BAC, though at this time there is not a consensus on whether the presence of BAC should routinely be reported.

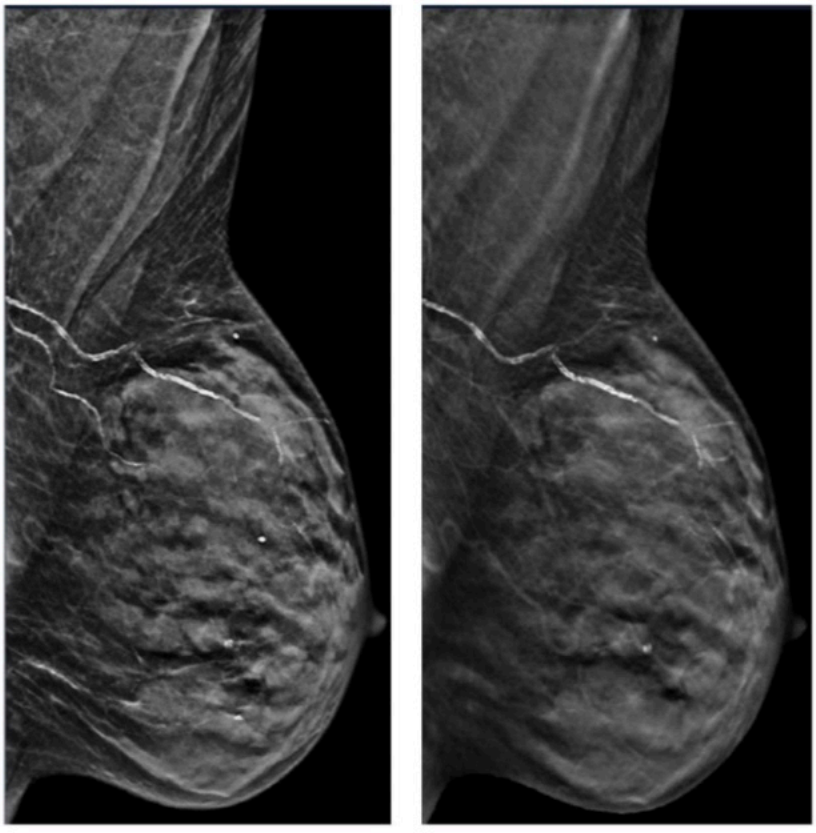

A B

Figure 1 – VASCULAR calcifications (A) SM and (B) DBT.

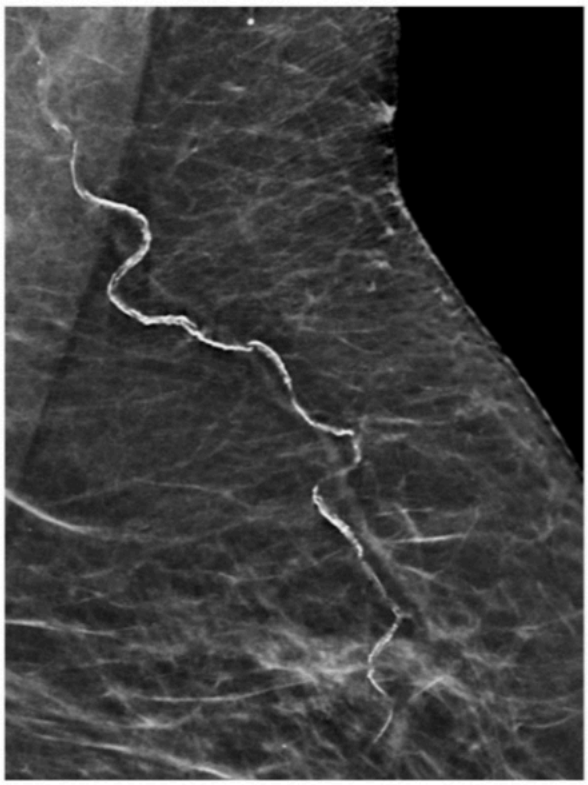

Figure 2 – VASCULAR calcifications (SM).

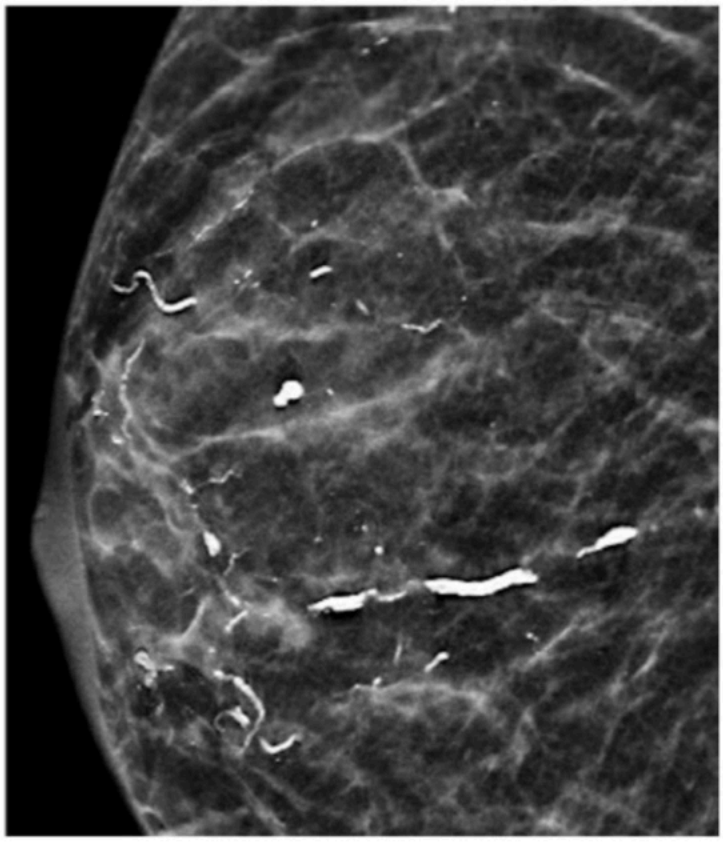

Figure 3 – VASCULAR calcifications (SM). Regional round calcifications are also present.

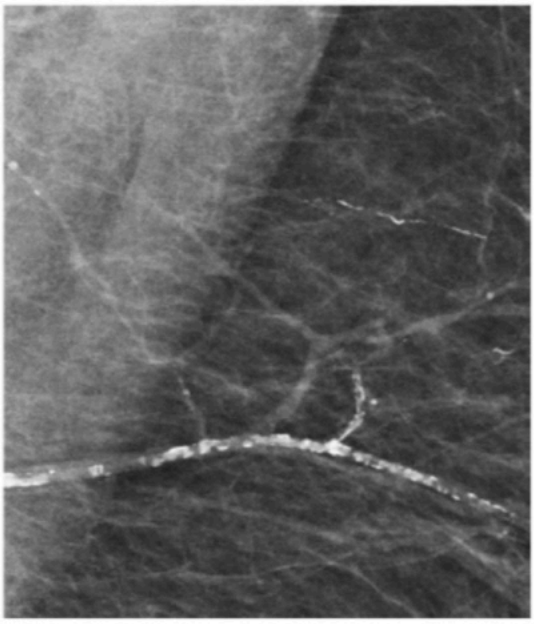

Figure 4 – VASCULAR calcifications (DM). While most vascular calcifications are easily recognizable, some may be more subtle in appearance.

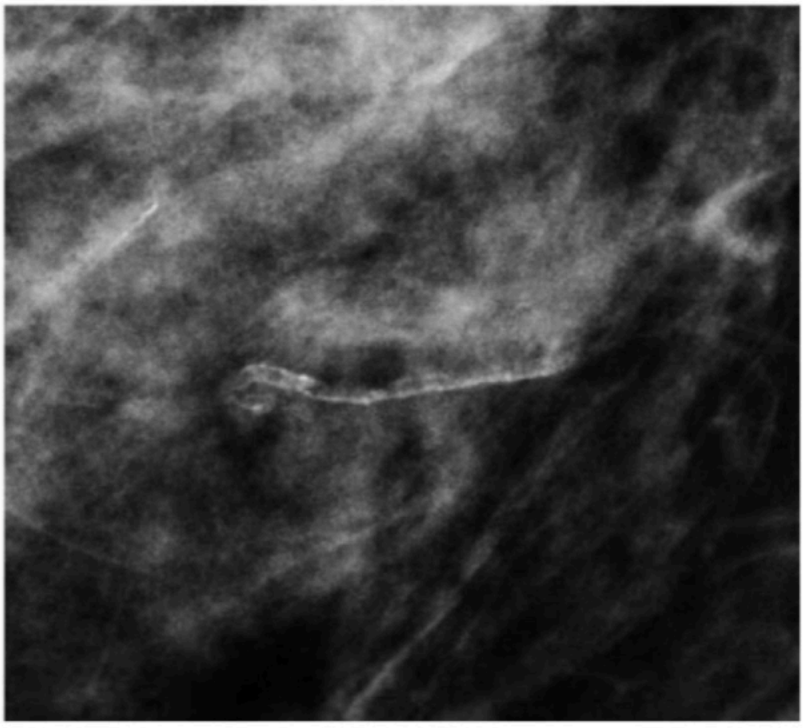

Figure 5 – VASCULAR calcifications (DM).

B. CALCIFICATIONS

1. TYPICALLY BENIGN

c. Coarse (previously "popcorn-like;" now also includes "dystrophic" - see Guidance section)

Coarse calcifications are typically large (e.g., > 2–3 mm in greatest diameter), dense, and confluent with other similar calcifications. There may be irregular margins of individual calcifications, but the prevailing appearance is a smooth margin. Historically, coarse calcifications were described as 'popcorn-like'. This term has been discontinued. Dystrophic was previously a stand-alone term that is now discontinued and is to be included under the Coarse category.

Coarse calcifications may be produced by an involuting fibroadenoma and over time may coalesce to become a single very large single calcification. An involuting fibroadenoma may or may not be associated with a mass or focal asymmetry. This category can also include coarse calcifications that form in the irradiated breast or following trauma, infection, or surgery. There may be associated lucent tissue due to fat necrosis.

There can be overlap in the appearance of the typically benign descriptor "coarse" and the suspicious descriptor "coarse heterogeneous," but coarse calcifications are typically larger with smoother margins.

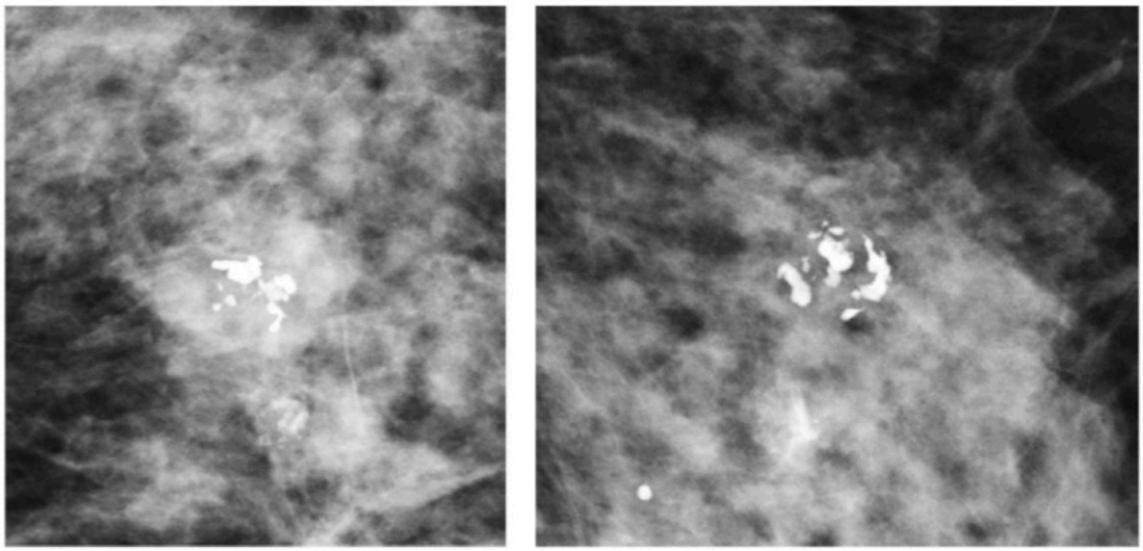

A B

Figure 1 – Grouped COARSE calcifications (DM). (A) CC and (B) MLO. The calcifications are approaching confluence. Stable, presumed calcified fibroadenoma.

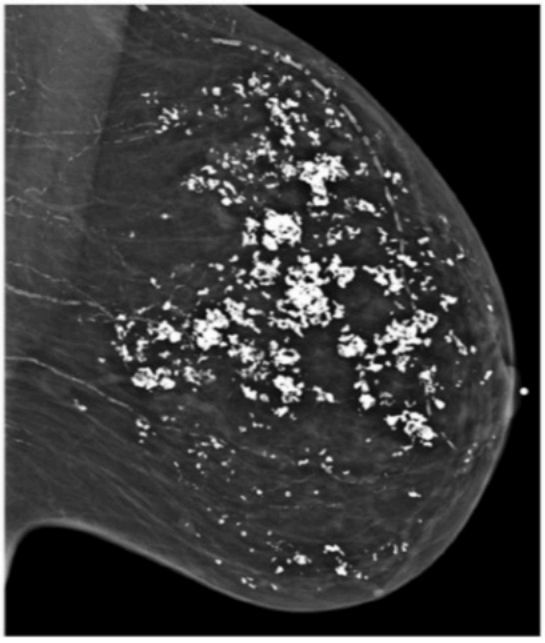

Figure 2 – Diffuse COARSE calcifications (DM). Vascular calcifications are also present. Stable, most likely due to multiple calcified fibroadenomas.

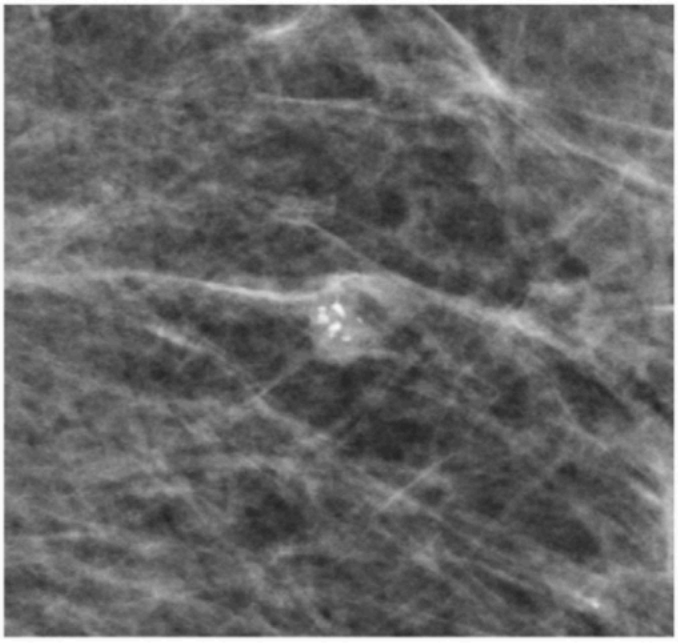

Figure 3 – Grouped COARSE calcifications within an obscured, oval, equal density mass (SM). The appearance is not as classic for fibroadenoma as seen in Figure 1. Without prior exams to confirm stability, additional work may be required in a case like this. Stable, presumed calcified fibroadenoma.

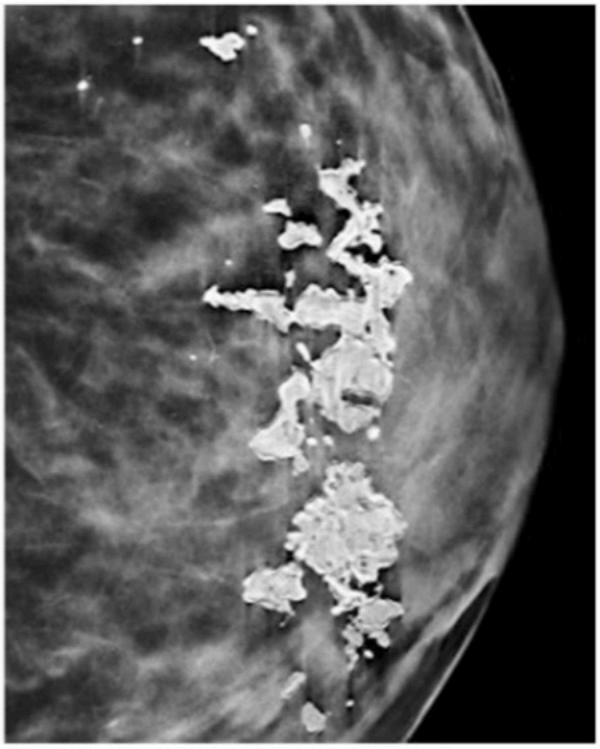

Figure 4 – COARSE calcifications (SM).

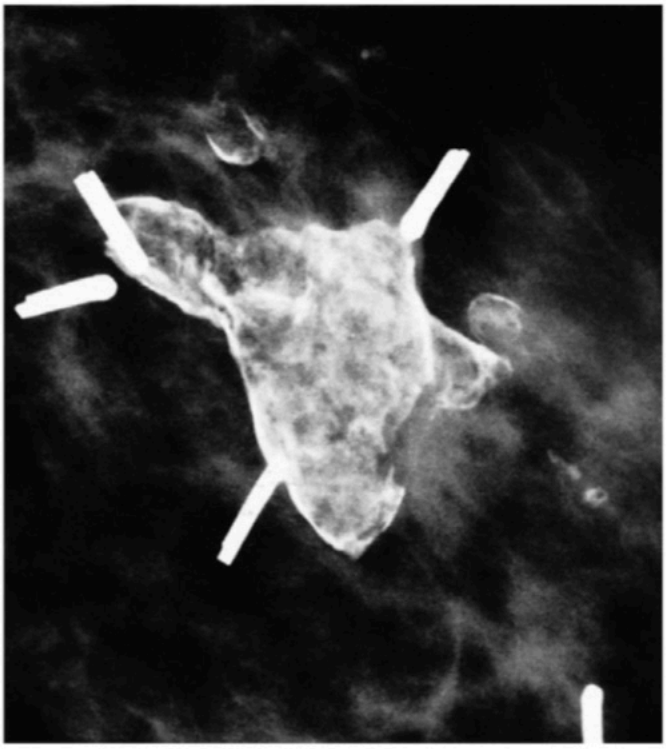

Figure 5 – COARSE calcifications (DM), typically benign, at the site of previous surgical excision, marked by several metallic clips.

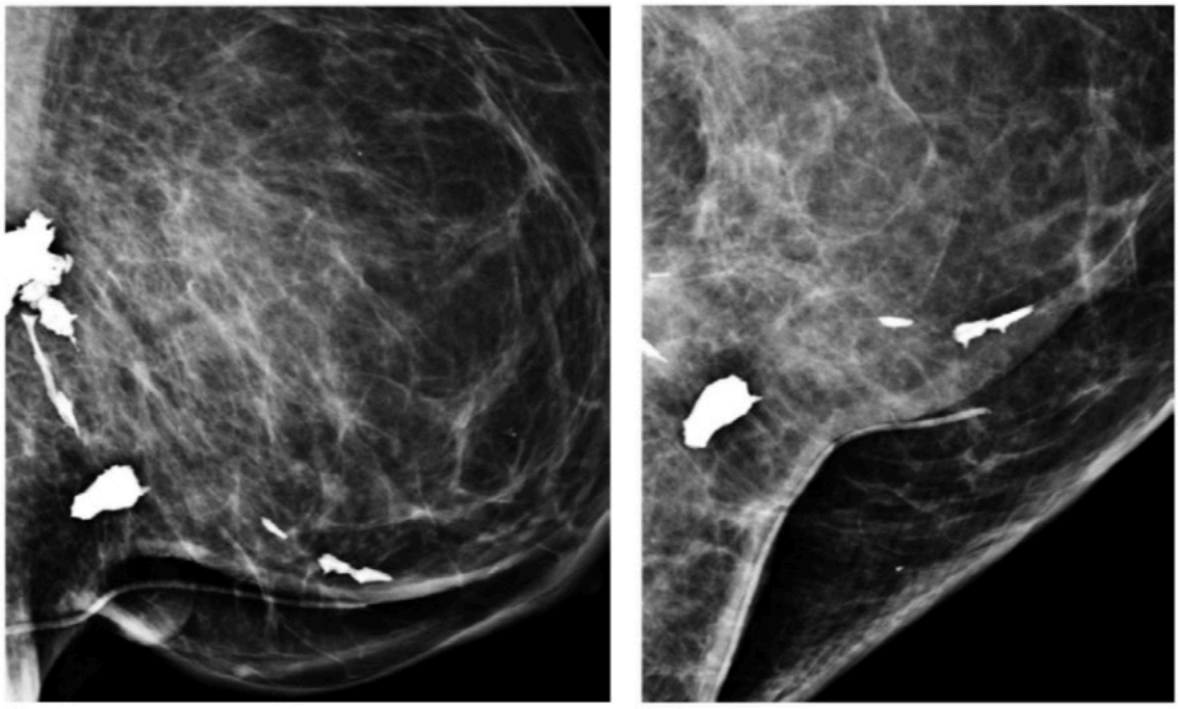

A B

Figure 6 – COARSE calcifications (SM). (A) MLO and (B) CC. Status post breast-conserving treatment. These calcifications were historically referred to as dystrophic but are now combined into coarse descriptor (see Guidance section).

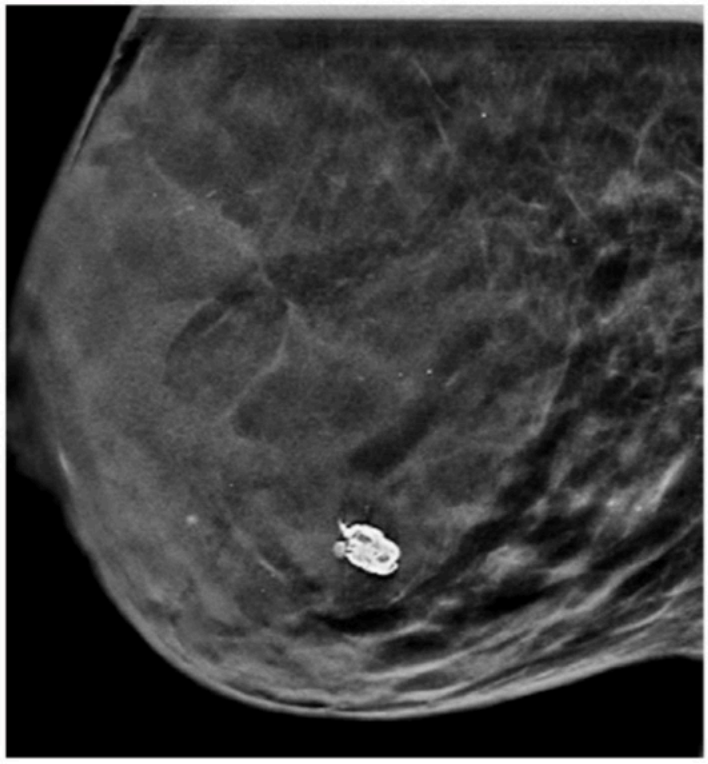

Figure 7 – COARSE calcification. A few diffuse round calcifications are also present. Fat necrosis (SM).

B. CALCIFICATIONS

1. TYPICALLY BENIGN

d. Large Rod-Like

Large rod-like calcifications appear as solid or discontinuous linear rods with well-defined smooth margins and tapering ends. A small percentage of these calcifications may be lucent-centered if the calcium is located in the wall of the duct, but most form within the lumen of the duct. All large rod-like calcifications follow a ductal distribution, converging toward the nipple, occasionally branching, and may be associated with ductal ectasia. These calcifications are typically bilateral, although they may initially be seen in only one breast. Large rod-like calcifications are usually seen in women older than 60 years [19]. Other terms such as plasma cell mastitis or secretory calcifications have been used to describe this type of calcification. However, here and elsewhere, the BI-RADS lexicon describes the morphology rather than the pathophysiologic etiology of the finding.

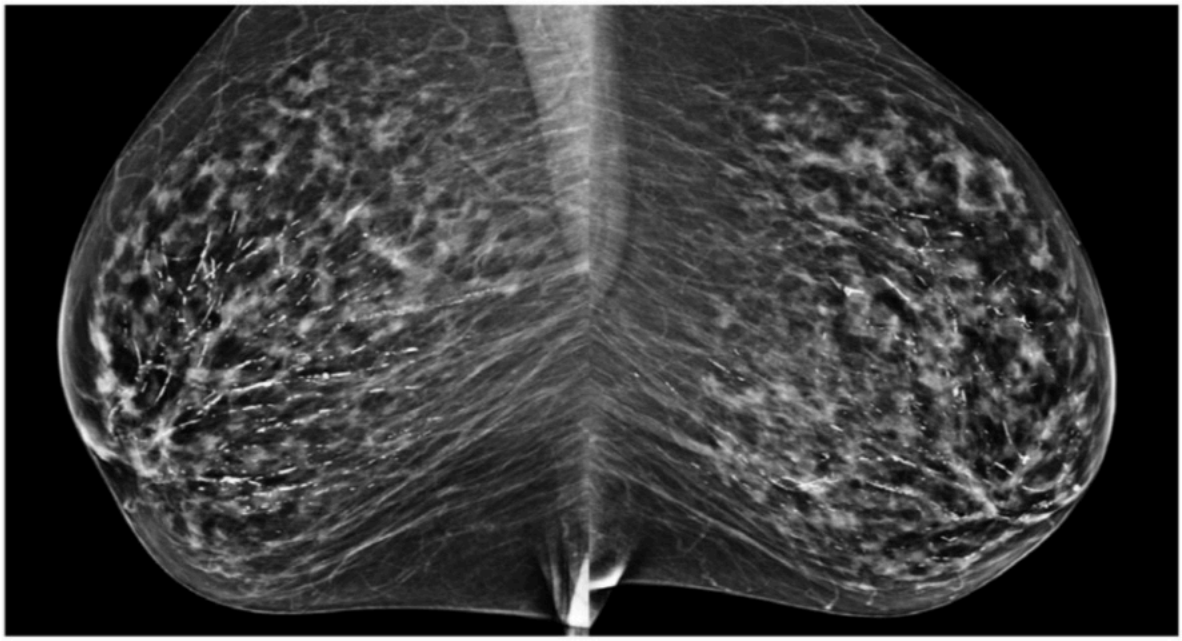

Figure 1 – LARGE ROD-LIKE calcifications (DM). As expected, these calcifications are bilateral and follow a ductal distribution, converging toward the nipple. They are smooth in contour and often show tapering at their ends, unlike calcifications associated with DCIS.

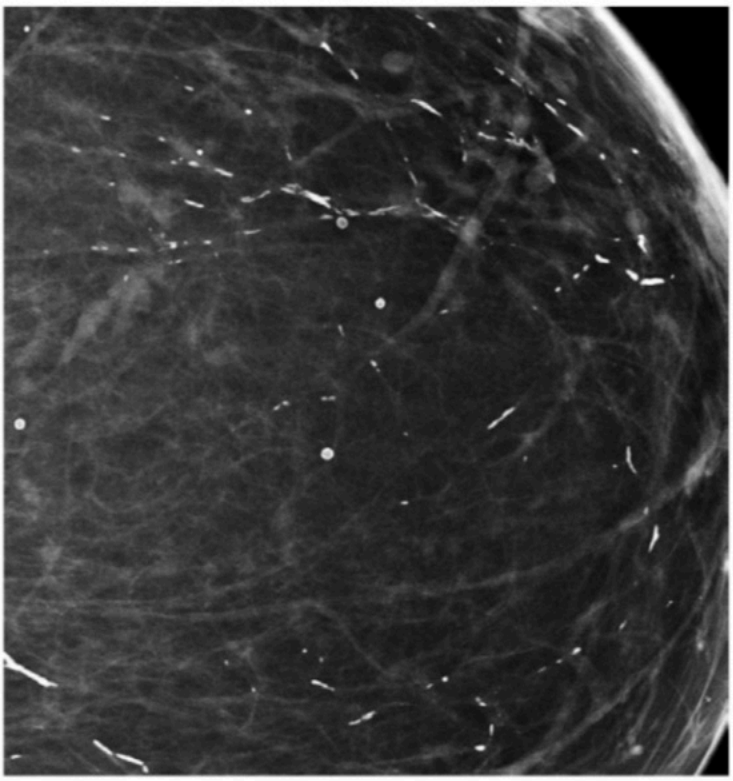

Figure 2 – LARGE ROD-LIKE calcifications (SM).

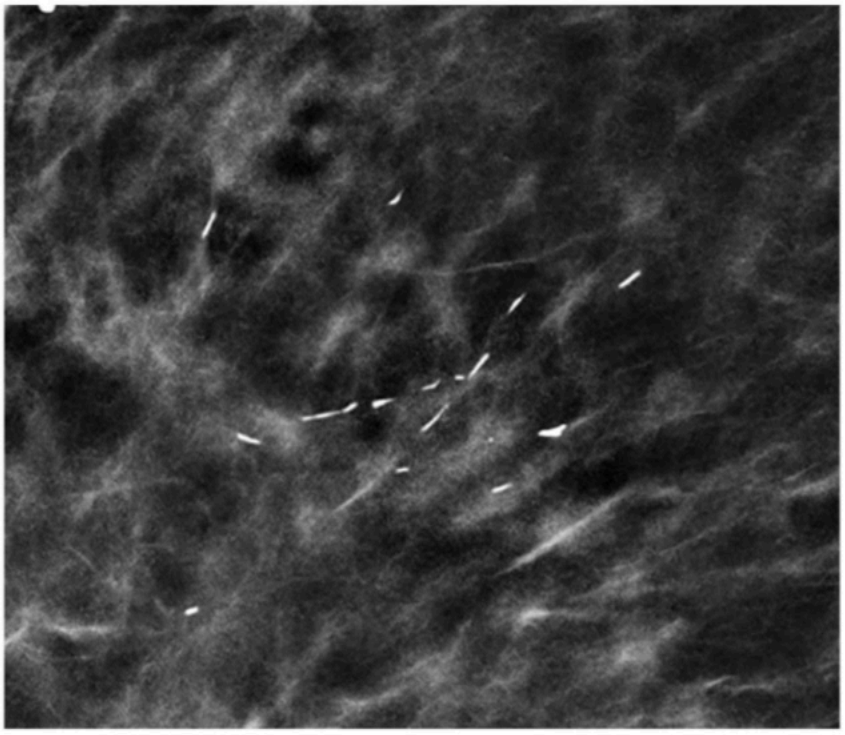

Figure 3 – LARGE ROD-LIKE calcifications (SM). Although discontinuous and sometimes branching, these calcifications are larger, smoother and often taper at the ends, which helps to distinguish them from malignant calcifications.

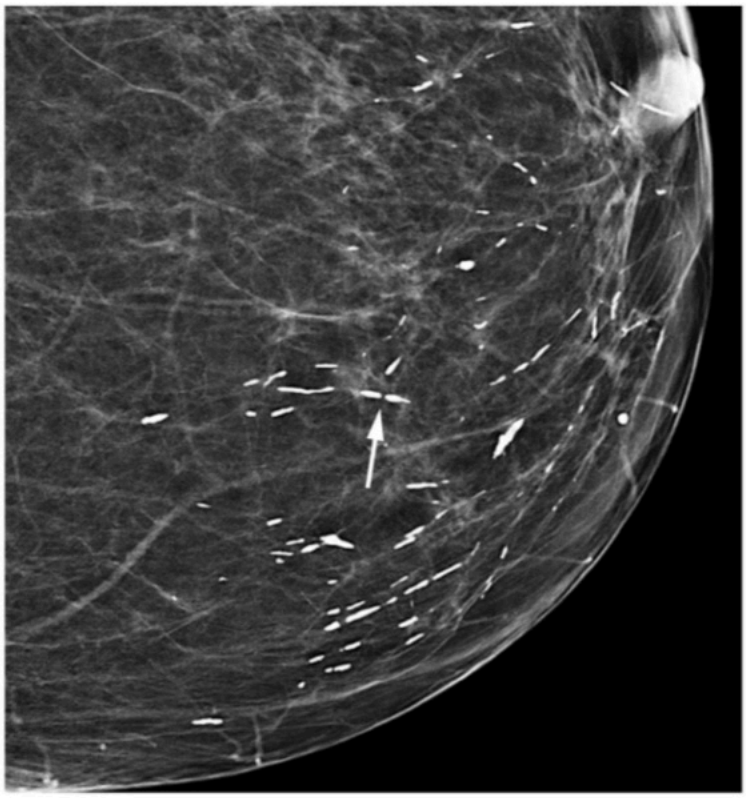

Figure 4 – LARGE ROD-LIKE calcifications (DM). Sometimes these calcifications surround the duct wall instead of lying within the duct (arrow).

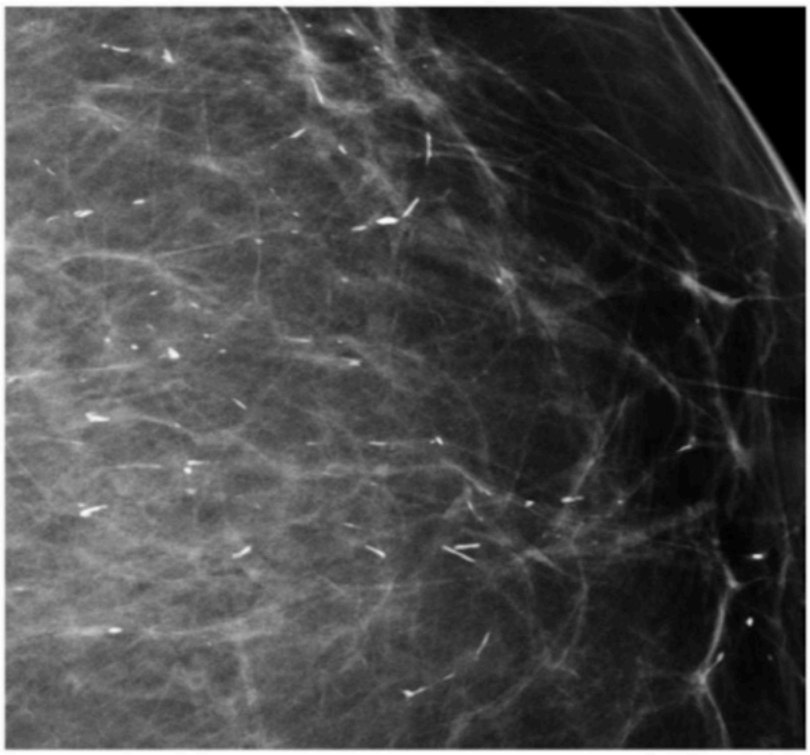

Figure 5 – LARGE ROD-LIKE calcifications (DM).

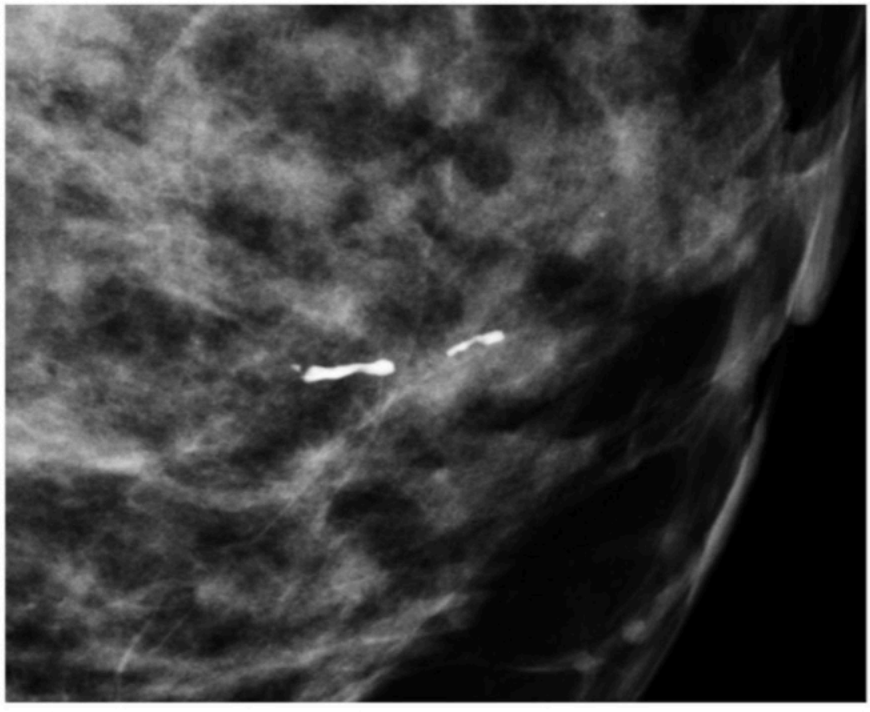

Figure 6 – Unusual presentation of LARGE ROD-LIKE calcifications (DM). Although most often bilateral and diffuse or regional in distribution, large rod-like calcifications may be few in number early in their development. Calcifications such as these may require additional evaluation as the appearance is not classic for large rod-like calcifications. Pathology on stereotactic core biopsy: Benign calcifications.

B. CALCIFICATIONS

1. TYPICALLY BENIGN

e. Round (includes calcifications previously referred as punctate-see Guidance section)

Round calcifications are smooth and typically small (< 1 mm) in size. When multiple, they may vary in size and therefore in radiodensity. They frequently form in the acini of lobules and present as multiple similar groups, although diffuse distributions are often seen as well. When bilateral with diffuse or multiple-group distribution, round calcifications can be considered benign. An isolated group of round calcifications on a baseline mammogram or if no prior comparisons are available, and confirmed on magnification views, may warrant a probably benign (BI-RADS category 3) assessment and mammographic surveillance. Image-guided biopsy may be indicated if the round calcifications are new, increasing, linear or segmental in distribution. Biopsy should also be considered if there is a known ipsilateral cancer and stability cannot be confirmed. The term "punctate," historically a subset of round calcifications < 0.5 mm in size, has been removed given the impracticality of measuring the size of minute individual calcifications.

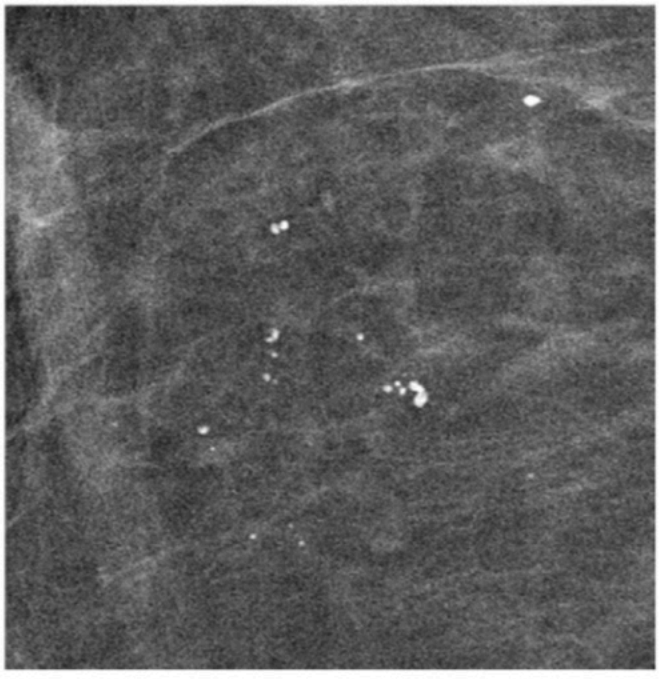

Figure 1 – Grouped ROUND calcifications (DBT). Benign, stable over several years.

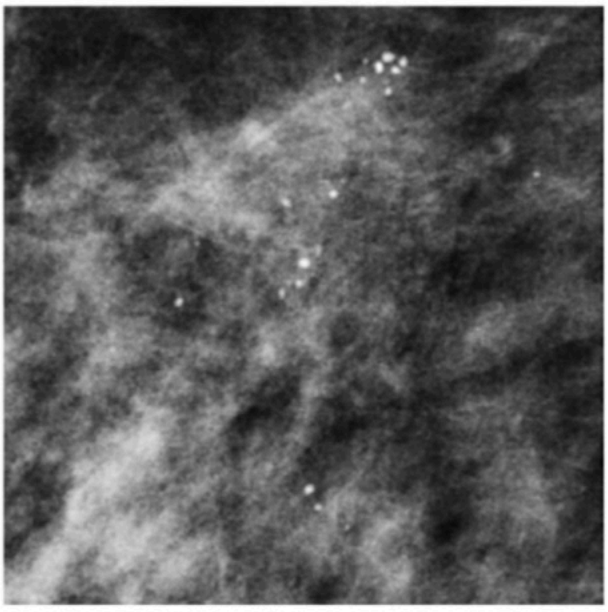

Figure 2 – Grouped ROUND calcifications (SM). Benign, stable over many years.

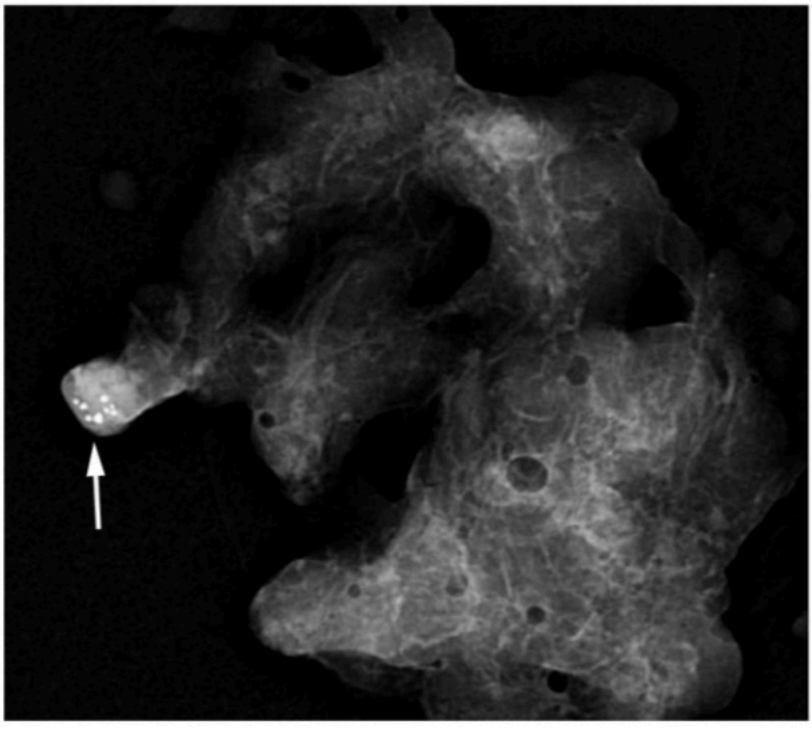

Figure 3 – ROUND calcifications (DM specimen radiograph). These calcifications (arrow) had increased in number over time and thus biopsy and subsequent surgical excision were recommended. Pathology: Pleomorphic LCIS.



Figure 4 – Regional ROUND (arrow) and amorphous (arrowheads) calcifications (DM). Stable, benign.

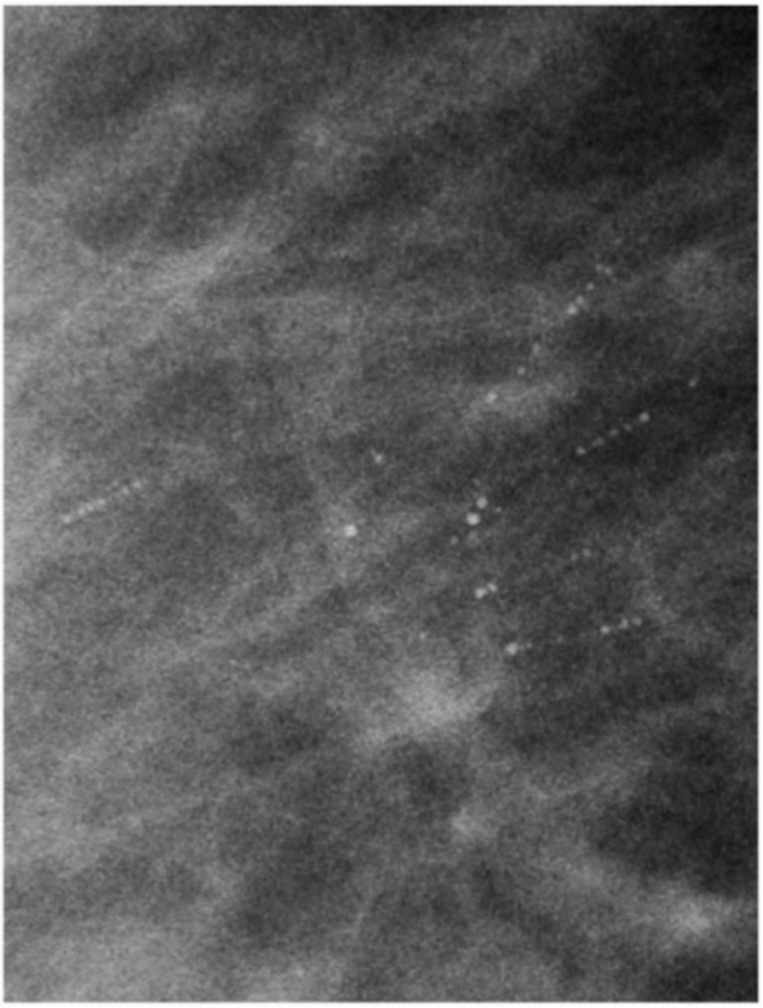

Figure 5 – Segmental ROUND calcifications (DM). Although round morphology usually prompts a benign or probably benign assessment, the segmental distribution in this case prompts a suspicious assessment instead. Pathology: Ductal carcinoma in situ (DCIS).

B. CALCIFICATIONS

1. TYPICALLY BENIGN

f. Rim

Rim calcifications are thin calcifications that are deposited on the surface of a sphere. The calcifications are usually < 1 mm in thickness when viewed on edge. Rim calcifications may form around lucent-centered masses smaller than 1 mm to several centimeters in size. Fat necrosis and calcifications in the walls of cysts are the most common cause of rim calcifications. On occasion, rim calcifications forming in oil or simple cysts may be more extensive and thicker.

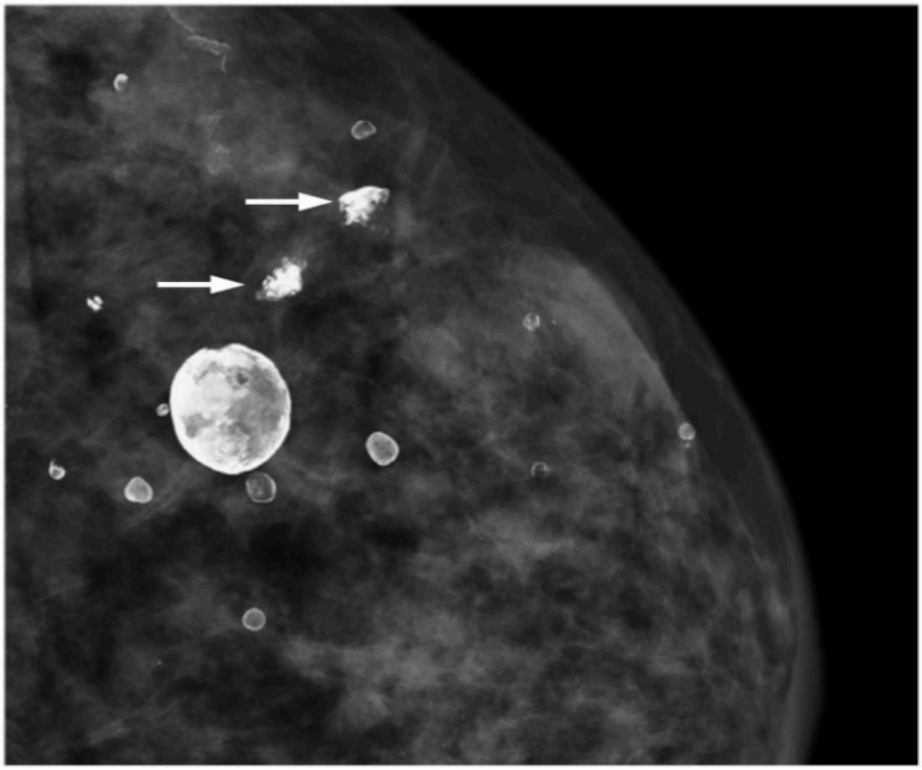

Figure 1 – RIM calcifications (SM). Some coarse calcifications are present as well (arrows). The findings suggest prior breast trauma and have a typically benign appearance, in keeping with fat necrosis.

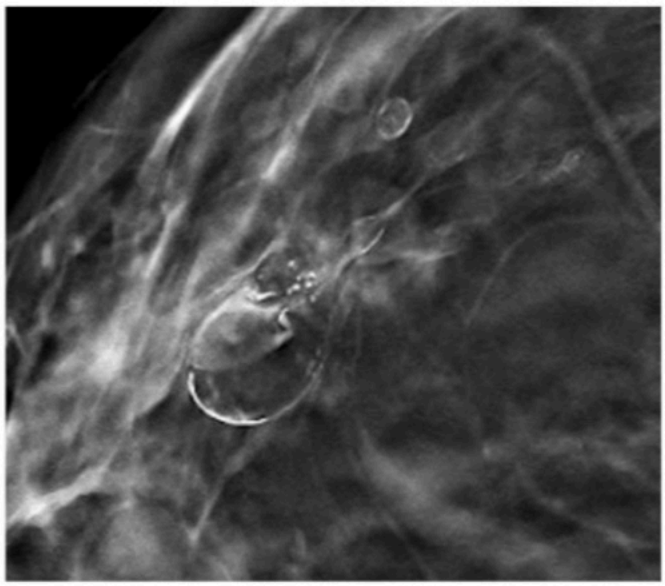

Figure 2 – RIM calcifications (DBT). Fat necrosis.

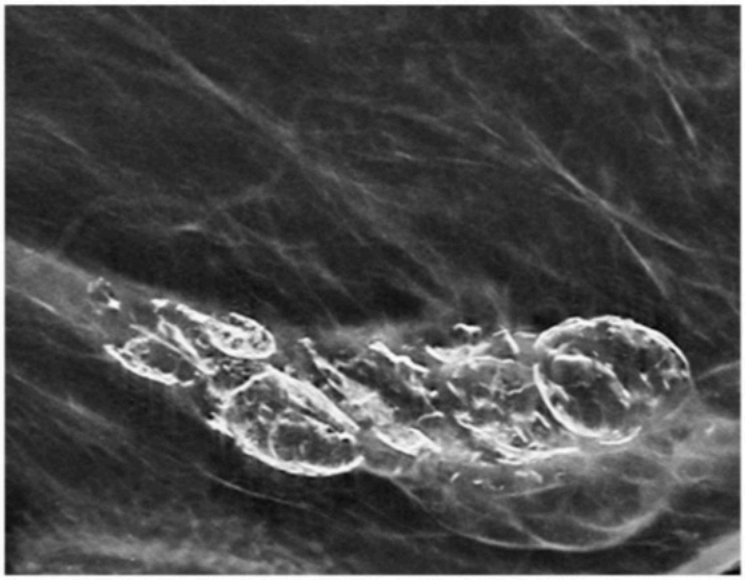

Figure 3 – RIM calcifications (SM). Prior trauma, fat necrosis.

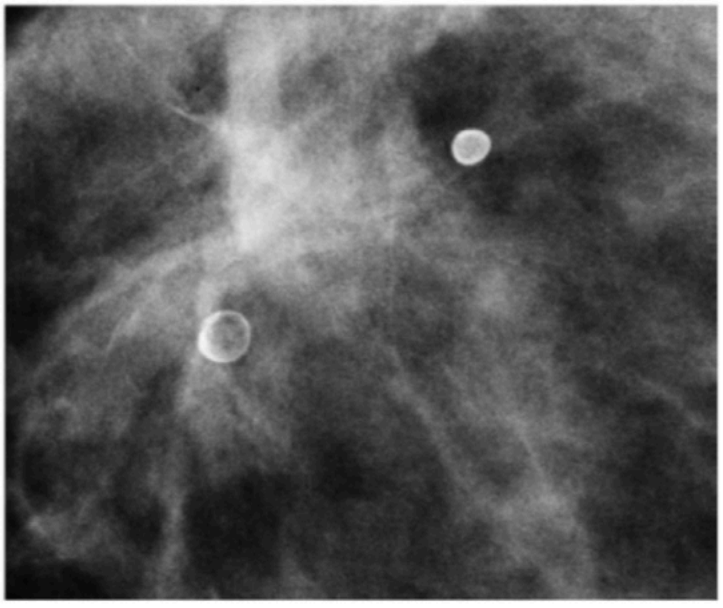

Figure 4 – RIM calcifications (DM).

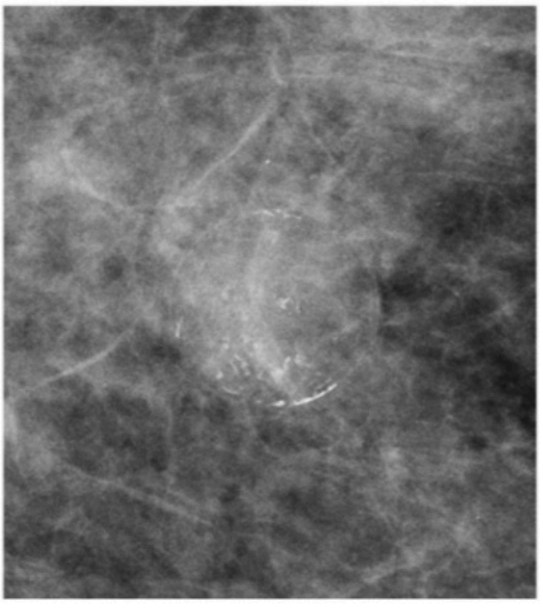

Figure 5 – RIM calcifications (DM). Early or developing rim calcium may not be pathognomonic but close inspection here confirms calcifications forming at the periphery of a sphere. Oil cyst.

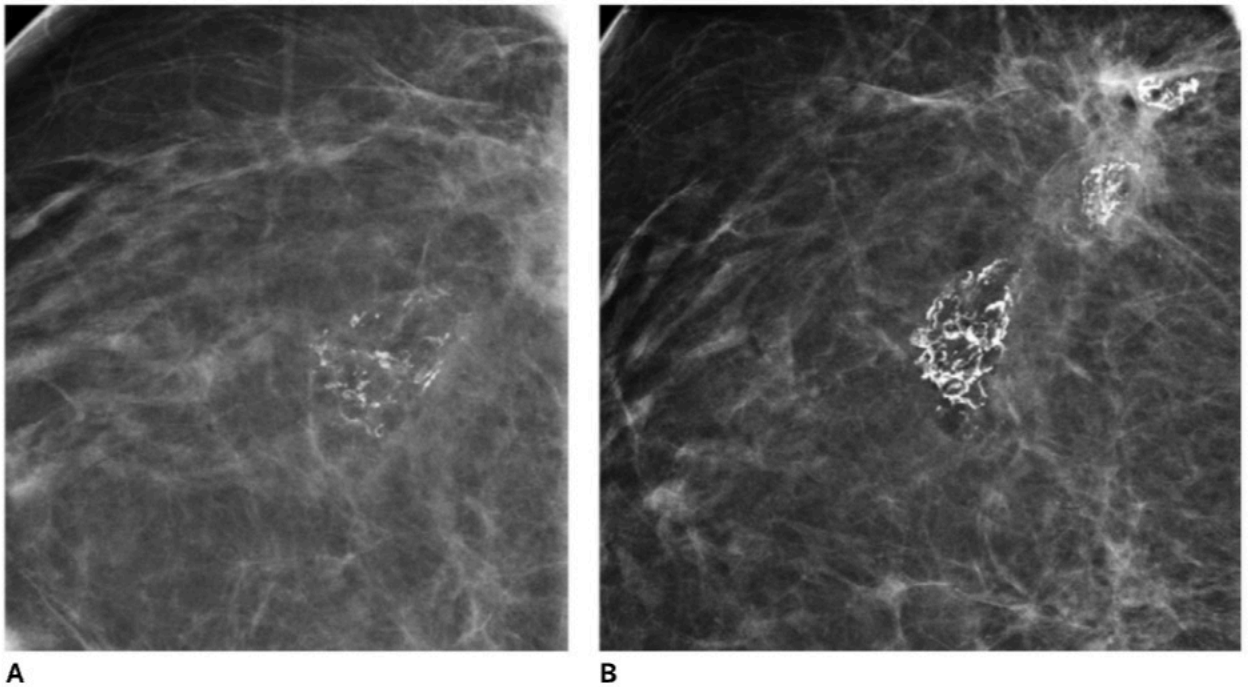

A B

Figure 6 – Evolving RIM calcifications (DM). One year after benign surgery (A) these calcifications were suggestive of evolving rim calcifications but not entirely characteristic. Surveillance was selected as the management option. Six months later (B), the calcifications have taken on a more classic RIM appearance, the surgical site has contracted in size, and additional rim calcifications are seen nearby. Benign postsurgical change.

B. CALCIFICATIONS

1. TYPICALLY BENIGN

g. Layering (historically "milk of calcium")

The term "milk of calcium" is replaced in this version with the term "layering" to describe the appearance rather than the etiology of the calcifications. Layering calcifications are semilunar, crescent shaped, curvilinear (concave up), or linear on mediolateral oblique (MLO) or 90° lateral (LM/ML) views. On craniocaudal (CC) views they are often less evident and appear as round, smudgy deposits. The most important feature of these calcifications is the apparent change in morphology of the calcifications on different mammographic projections (i.e., CC versus the LM/ML views). Layering calcifications represent sedimented calcifications in macro- or microcysts and are usually, but not always, grouped. Layering calcifications may infrequently be seen adjacent to suspicious calcifications. It is thus important to recognize any co-existent suspicious morphologies, especially those that do not change shape from the 90° lateral (i.e., ML/LM view) projection to the CC projection, to make management decisions based on the most suspicious calcifications identified.

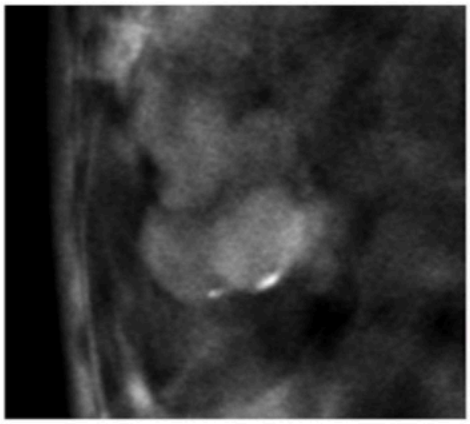

Figure 1 – LAYERING calcifications ML views (DBT). Calcium can be seen collecting in the dependent portion of two adjacent circumscribed masses, in keeping with complicated macro-cysts containing calcific debris.

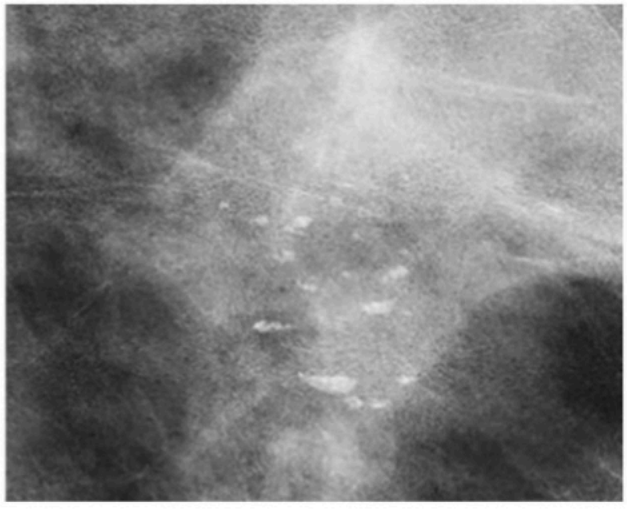

Figure 2 – Grouped LAYERING calcifications (DM ML view). Their inferior aspect is curvilinear while their upper aspect is horizontal in orientation as they layer along the dependent portion of grouped microcysts.

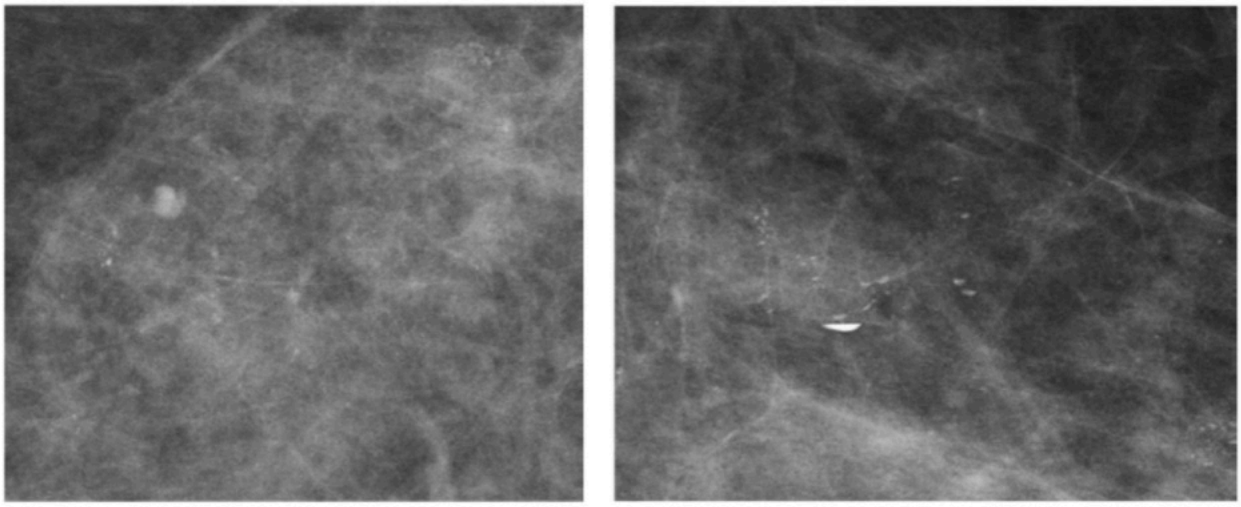

A B

Figure 3 – LAYERING calcifications (A) DM CC and (B) DM ML. The calcifications are smudgy on CC view and display layering on ML view, diagnostic of benign layering calcifications.

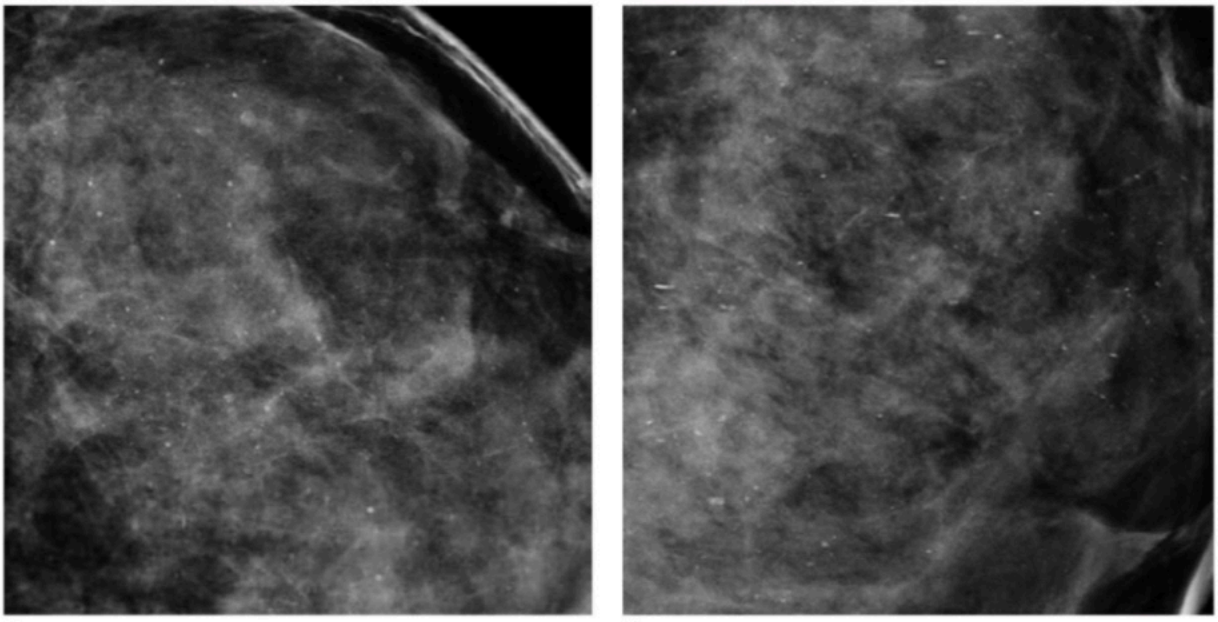

A B

Figure 4 – LAYERING calcifications (A) DM CC and (B) DM ML. Some of the calcifications may appear linear on ML imaging but their nature can be surmised by noting adjacent layering calcifications combined with their smudgy (non-linear) morphology on CC view.

B. CALCIFICATIONS

1. TYPICALLY BENIGN

h. Suture

Suture calcifications are typically linear, curvilinear or tubular in appearance. They represent calcifications in suture material and, when present, knots may be visible. Suture calcifications can occur after benign surgery or radiation treatment [20].

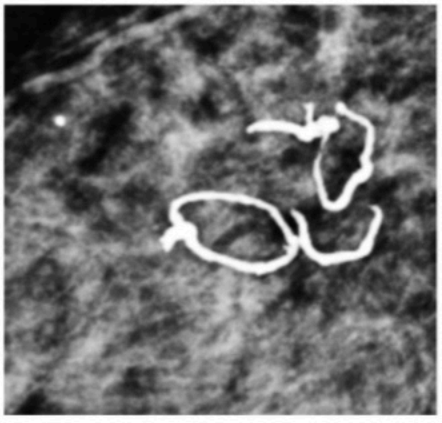

Figure 1 – Grouped SUTURE calcifications (DM).

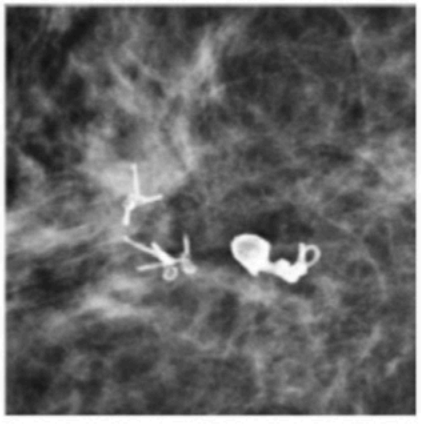

Figure 2 – Grouped SUTURE calcifications (DM).

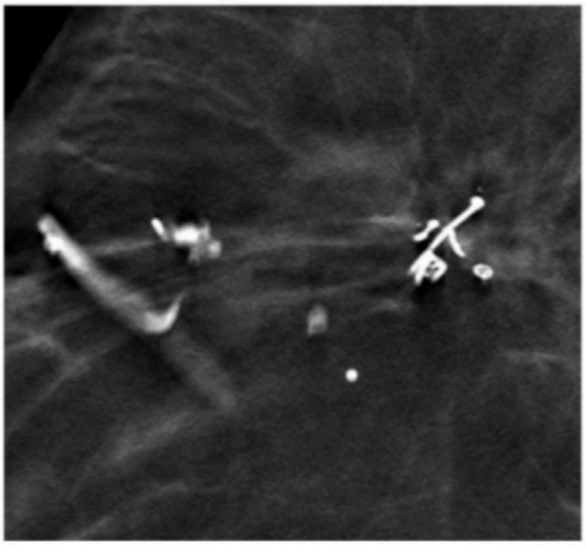

Figure 3 – Grouped SUTURE calcifications (DBT). Postsurgical architectural distortion is also noted.



Figure 4 – Grouped SUTURE calcifications (DM).

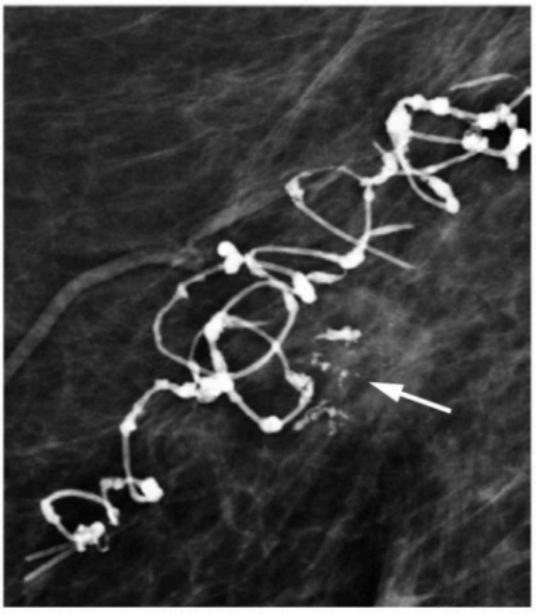

Figure 5 – SUTURE calcifications. Also present: grouped coarse heterogeneous and fine pleomorphic calcifications (arrow) (SM). Pathology: Recurrent IDC (associated with the non-suture calcifications).

B. CALCIFICATIONS

2. SUSPICIOUS MORPHOLOGY

Classification of breast calcifications by morphology is useful to predict the likelihood of malignancy. There are four calcification morphology descriptors that usually indicate sufficient suspicion for malignancy to prompt a biopsy recommendation.

Table 3. Positive Predictive Value of Malignancy of Breast Calcifications Based on Morphology

Morphology Descriptor	Choi et al. 2020 [21]	Park et al. 2019 [22]	Kim et al. 2015 [23]	Bent et al. 2010 [24]	Burnside et al. 2007 [25]
Amorphous	9.1%	15.9%	7.9%	20%	13%
Coarse Heterogeneous	16.1%	31.7%	17.8%	20%	7%
Fine Pleomorphic	78.8%	58.2%	63.2%	28%	29%
Fine Linear or Fine Linear-Branching	78.6%	90.6%	100%	70%	53%

B. CALCIFICATIONS

2. SUSPICIOUS MORPHOLOGY

a. Amorphous

Amorphous calcifications are small, hazy and, by definition, essentially formless such that a more specific morphology cannot be assigned. Amorphous calcifications in a regional (if new or increasing), grouped, linear, or segmental distribution are of intermediate suspicion and generally warrant biopsy [26]. Bilateral diffuse amorphous calcifications may usually be dismissed as benign. Amorphous calcifications do not change shape between views or layer on 90° lateral (LM/ML) magnification views, as is seen with layering calcifications (see above).

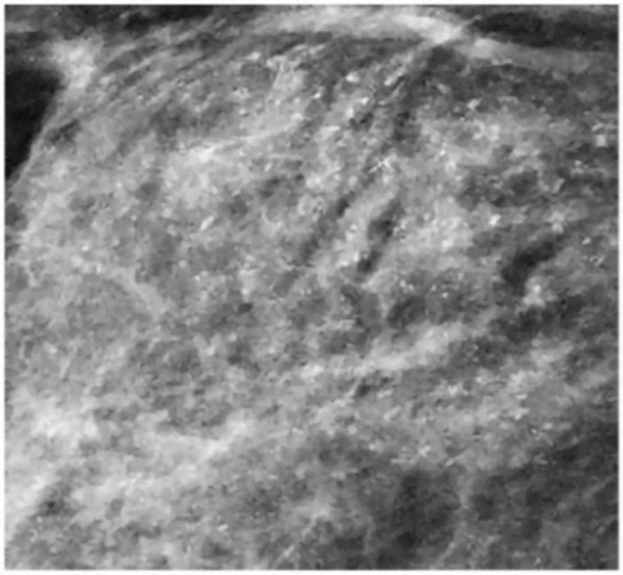

Figure 1 – Regional AMORPHOUS calcifications. Note that their individual shape is hard to characterize, as they are (by definition) essentially formless (DM). Pathology: Benign fibrocystic changes.

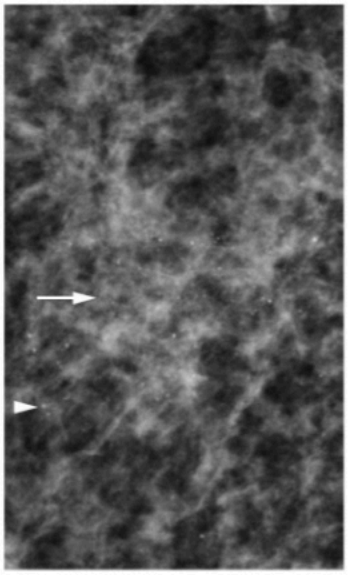

Figure 2 – Regional AMORPHOUS calcifications (arrow). Some round calcifications are present as well (arrowhead), not uncommon (DM magnification view). Pathology: ADH and DCIS.

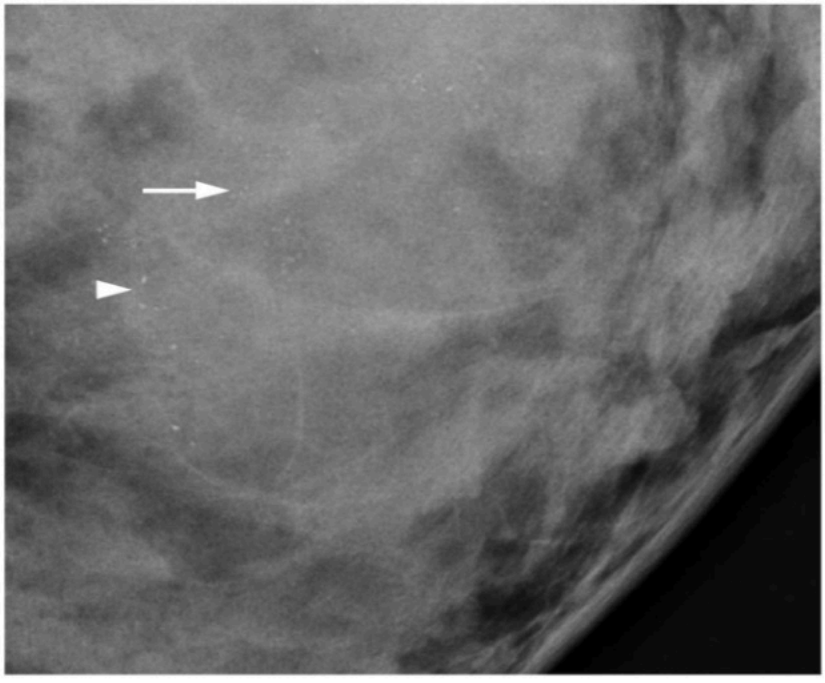

Figure 3 – Regional AMORPHOUS calcifications (arrow), with associated grouped fine pleomorphic calcifications (DM) (arrowhead). Biopsy of the fine pleomorphic calcifications yielded DCIS. Areas of amorphous calcifications should be thoroughly inspected to exclude the presence of more suspicious forms. Pathology: DCIS.

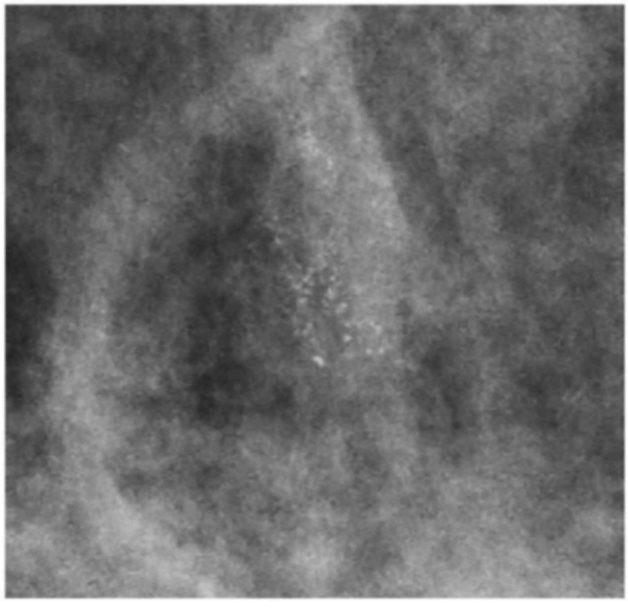

Figure 4 – Grouped AMORPHOUS calcifications (DM). Pathology: Calcifications in benign epithelium.

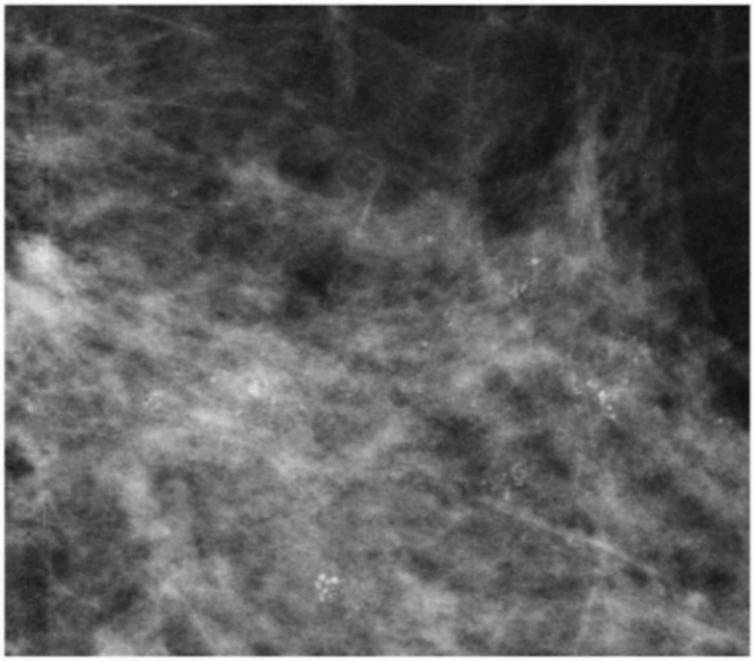

Figure 5 – Regional AMORPHOUS calcifications (DM). Pathology: Atypical ductal hyperplasia and flat epithelial atypia.

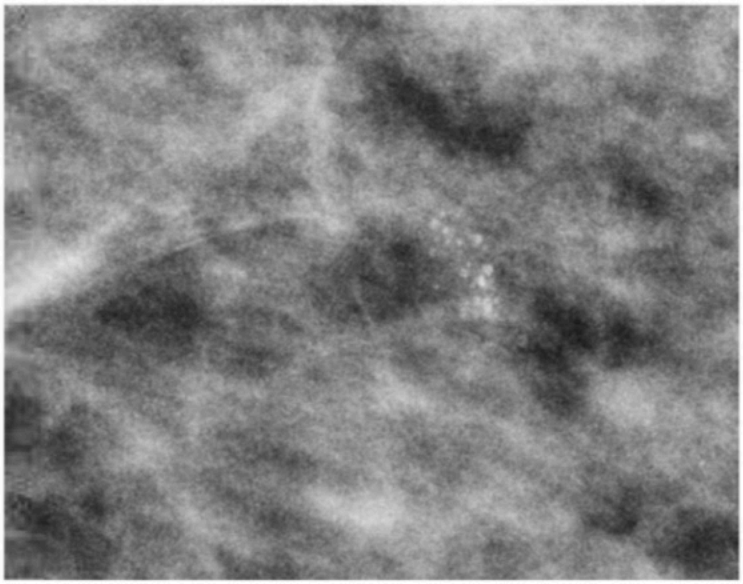

Figure 6 – Some round and some AMORPHOUS grouped calcifications (DM). Pathology: Atypical ductal hyperplasia.

B. CALCIFICATIONS

2. SUSPICIOUS MORPHOLOGY

b. Coarse Heterogeneous

Coarse heterogeneous calcifications are irregular in shape, generally 0.5 mm to 1 mm in size, and tend to coalesce. Coarse heterogeneous calcifications are smaller than typically benign coarse calcifications. Coarse heterogeneous calcifications are of intermediate suspicion for malignancy especially when found in a grouped, linear, or segmental distribution, or are new or increasing. Numerous bilateral groups of coarse heterogeneous calcifications can often be dismissed as benign due to their multiplicity and bilaterality.

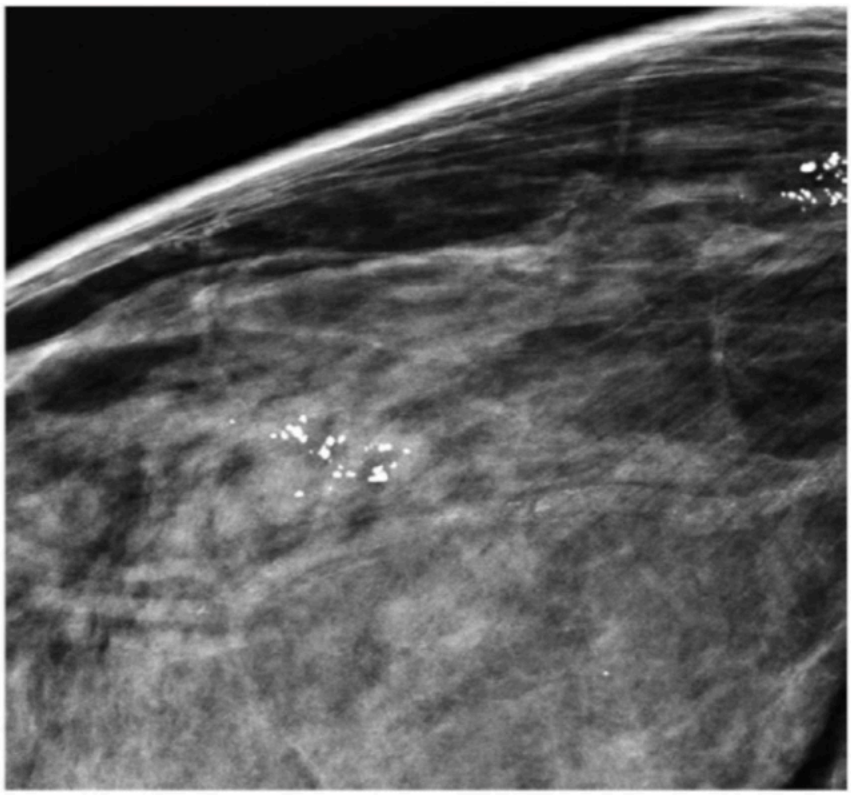

Figure 1 – Grouped COARSE HETEROGENEOUS calcifications (DM). In this patient, there were multiple bilateral similar groups. Stable, benign.

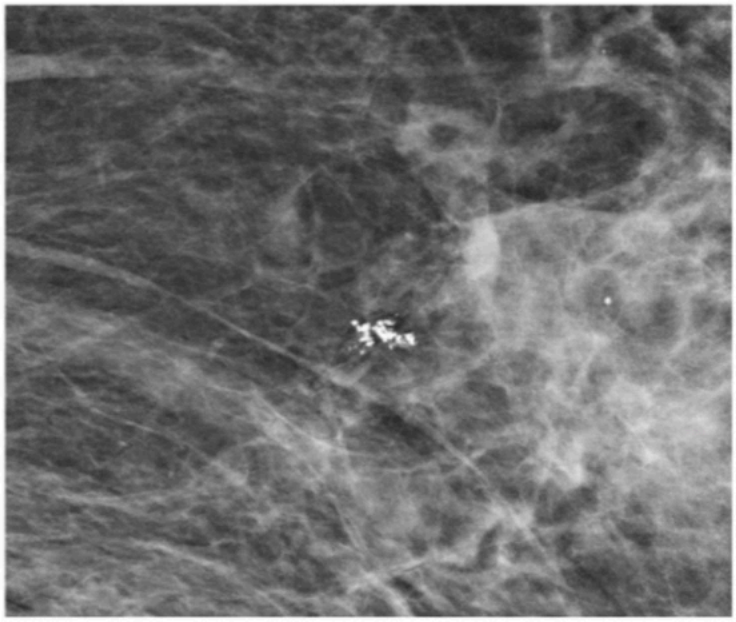

Figure 2 – Grouped COARSE HETEROGENEOUS calcifications (DM). Pathology: Fibroadenoma.

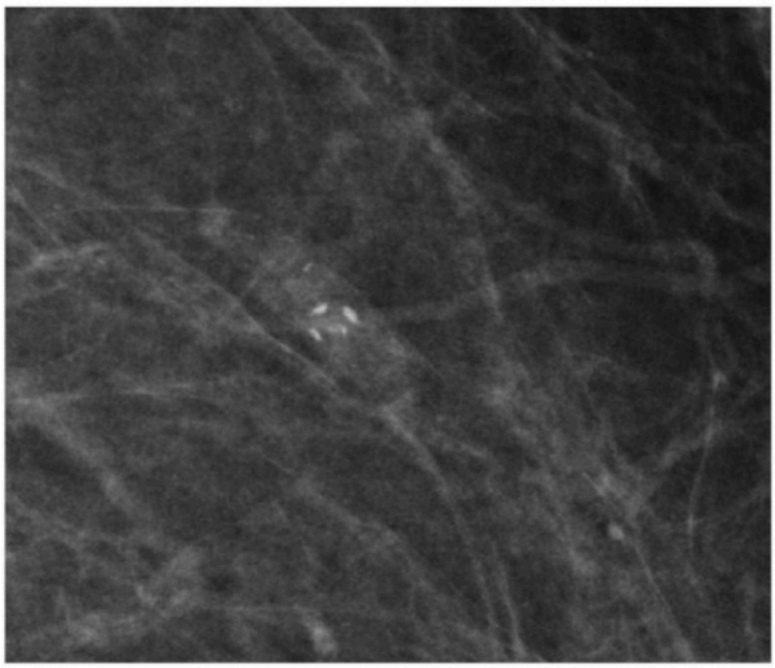

Figure 3 – Grouped COARSE HETEROGENEOUS calcifications (DM). Pathology: Sclerosing fibroadenomatous change.

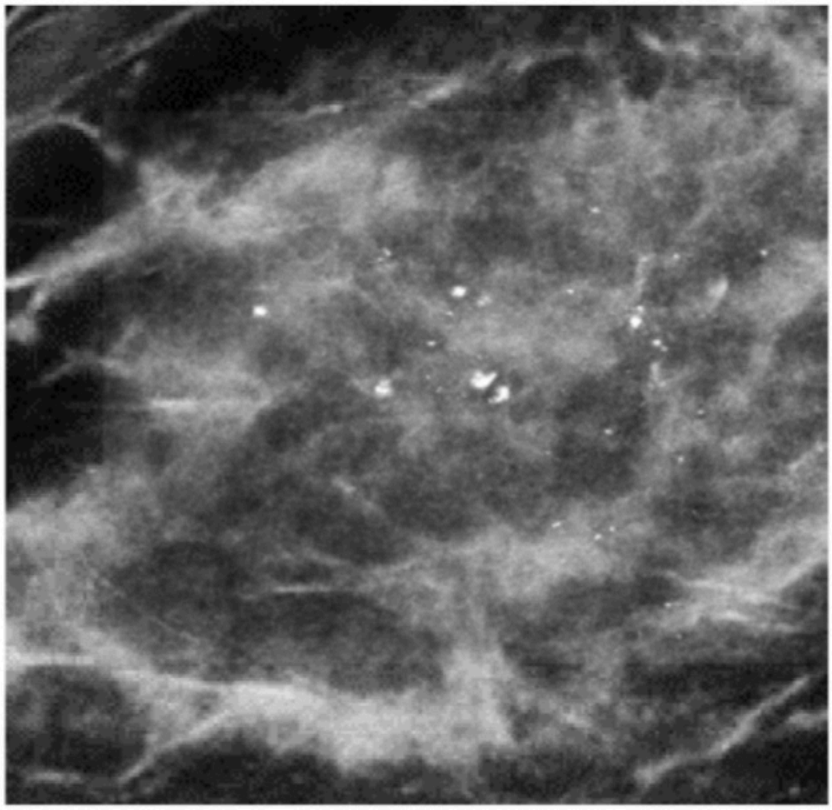

Figure 4 – Grouped COARSE HETEROGENEOUS calcifications (SM). Pathology: DCIS.

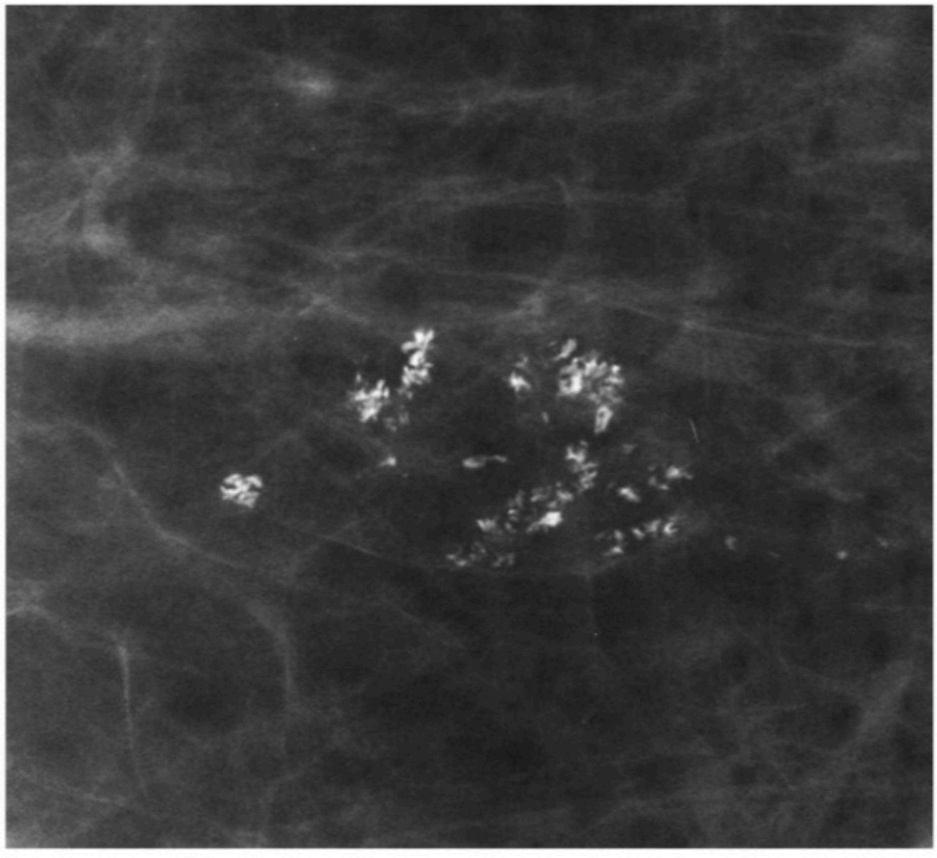

Figure 5 – Grouped COARSE HETEROGENEOUS calcifications (DM). Core biopsy: Fibroadenomatoid change.

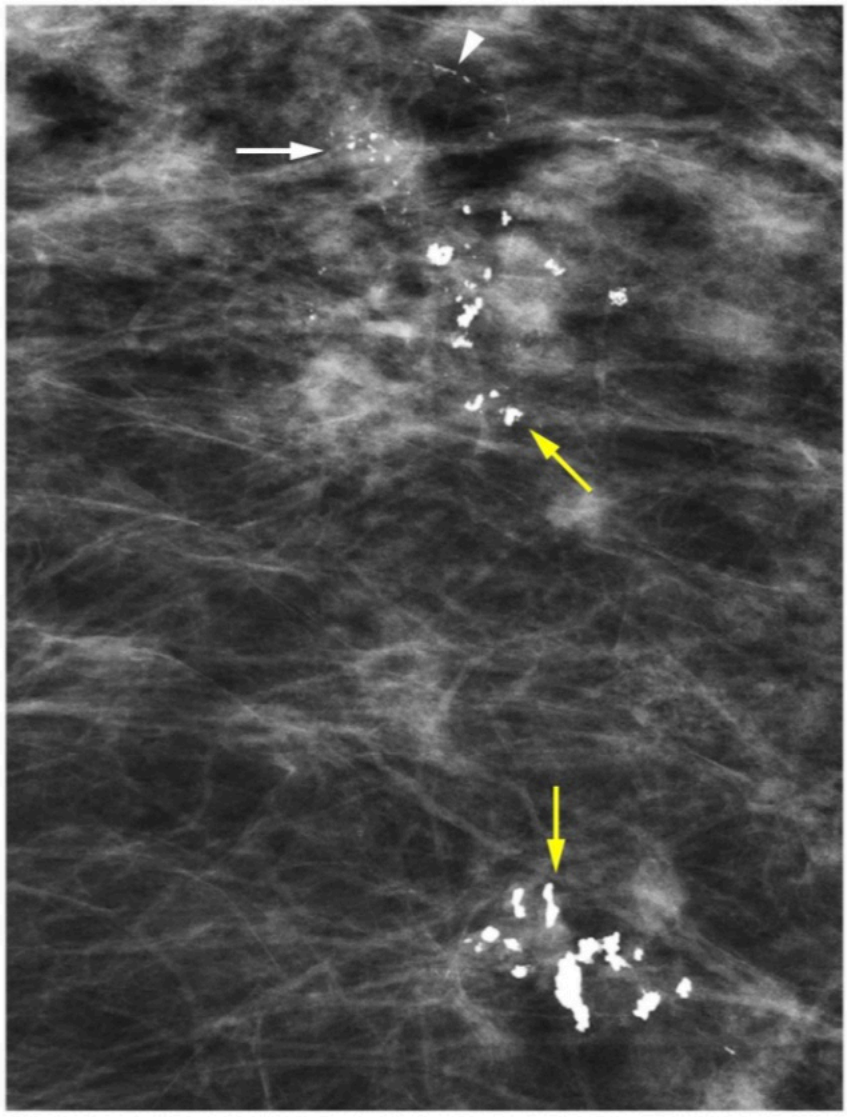

Figure 6 – Grouped COARSE HETEROGENEOUS calcifications (white arrow). Note the co-existing fine linear calcifications in a linear distribution (arrowhead) as well as the grouped coarse calcifications (yellow arrows) (DM). When multiple different morphologies are present, management should be based on the most suspicious form. Pathology: Invasive ductal carcinoma and DCIS (fine linear calcifications); fibroadenoma (coarse and coarse heterogeneous calcifications).

B. CALCIFICATIONS

2. SUSPICIOUS MORPHOLOGY

c. Fine Pleomorphic

Fine pleomorphic calcifications vary in size and shape but are usually < 0.5 mm in diameter. Compared to amorphous calcifications, they are more conspicuous and have discrete shapes. Although variable in shape, they lack the linearity present in fine linear and fine linear-branching morphologies. They have a higher likelihood of malignancy than amorphous or coarse heterogeneous calcifications.

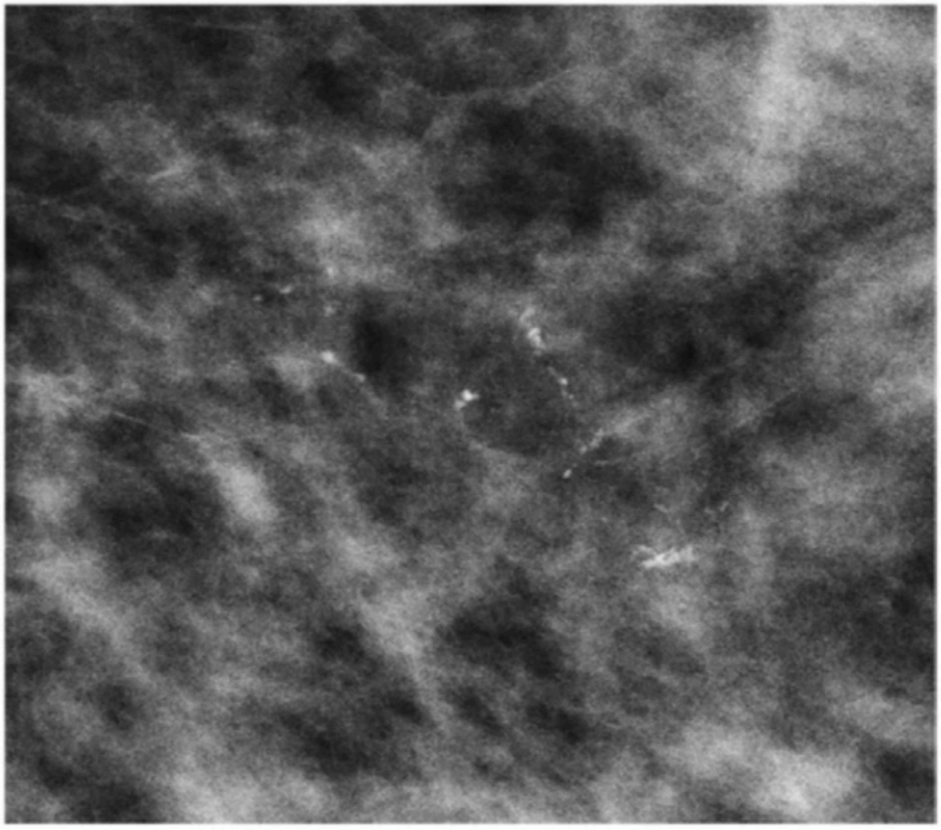

Figure 1 – Grouped FINE PLEOMORPHIC calcifications (DM). Pathology: Invasive ductal carcinoma and DCIS.

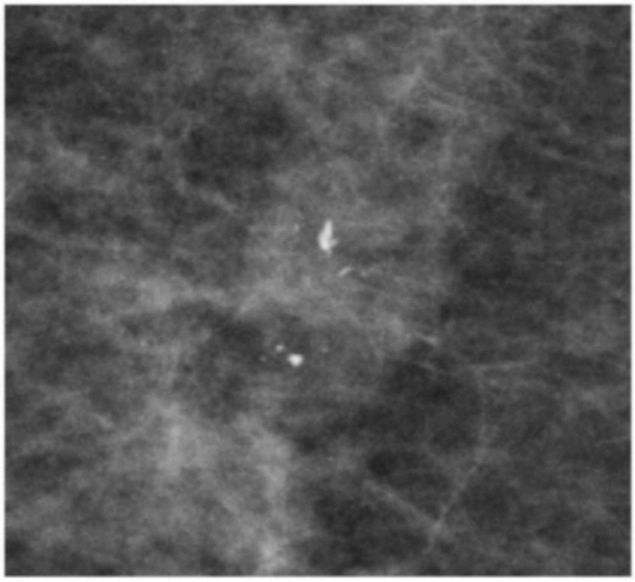

Figure 2 – Grouped FINE PLEOMORPHIC calcifications (DM). Pathology: Fibroadenoma.

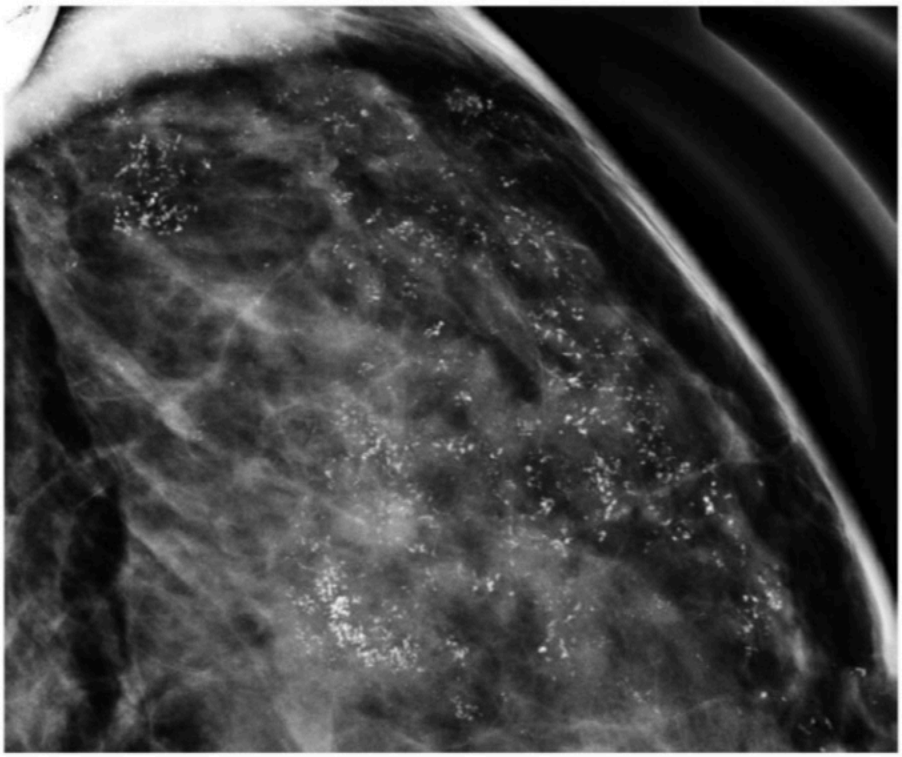

Figure 3 – Segmental FINE PLEOMORPHIC calcifications (SM). Pathology: Invasive ductal carcinoma and DCIS.

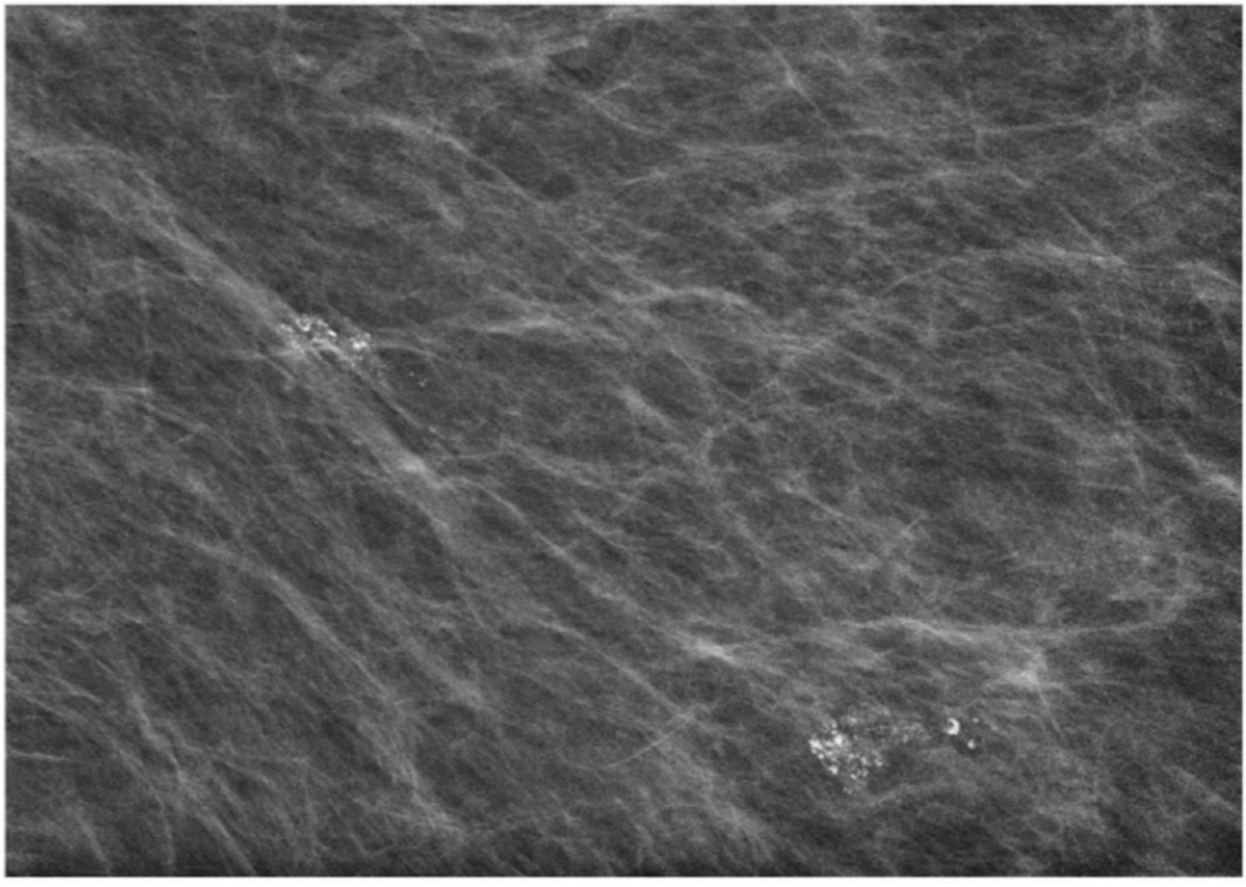

Figure 4 – Grouped FINE PLEOMORPHIC calcifications (DM). Two distinct groups are present. A few coarse heterogeneous calcifications are present in each group as well. However, the overall group morphology should be described based on the most suspicious forms present. Pathology: DCIS, both groups.



Figure 5 – Grouped FINE PLEOMORPHIC calcifications (DM). Pathology: DCIS and ADH.

B. CALCIFICATIONS

2. SUSPICIOUS MORPHOLOGY

d. Fine Linear or Fine Linear-Branching

Fine linear or fine linear-branching calcifications are thin, linear, irregular calcifications, which may be discontinuous, and are typically < 0.5 mm in caliber. Occasionally, branching forms may be seen. Their appearance suggests filling of the lumen of a duct or ducts by breast cancer, especially ductal carcinoma in situ (DCIS). Among the suspicious calcifications, fine linear and fine linear-branching calcifications have the highest likelihood of being malignant [24].

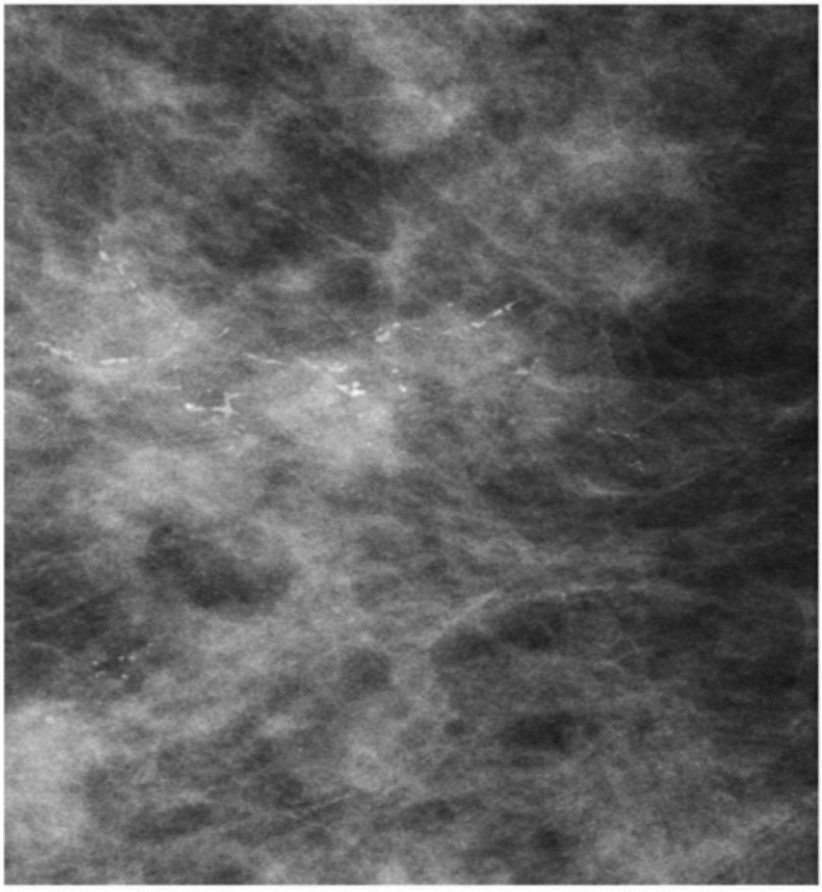

Figure 1 – FINE LINEAR calcifications in a segmental distribution (DM). Although the area involved is not large, fine linear calcifications are seen to conform to adjacent bifurcating ducts, making them segmental in distribution. Pathology: DCIS, high nuclear grade.



Figure 2 – Segmental FINE LINEAR-BRANCHING calcifications (DM). Branching forms are seen in this example. *Note*: Some of these suspicious calcifications are thick rather than fine, but they are irregular and do not taper (as would be seen in large rod-like calcifications). This appearance is highly characteristic of at least DCIS and benign biopsy results would be considered discordant. Pathology: DCIS.



Figure 3 – Segmental FINE LINEAR calcifications (DM). Pathology: DCIS.

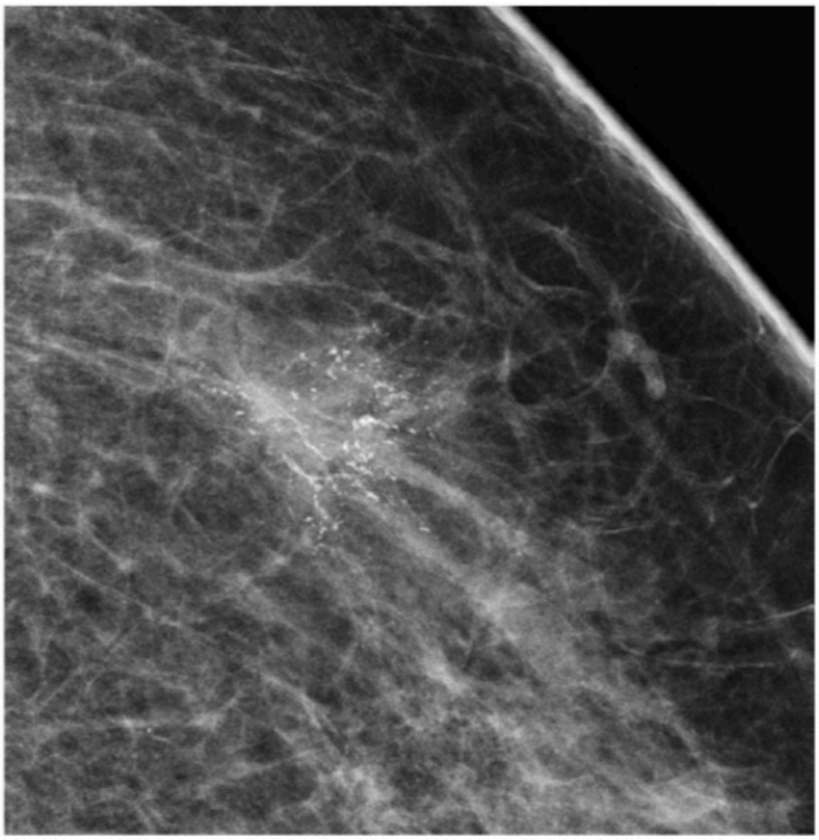

Figure 4 – Grouped FINE LINEAR calcifications. Also present are fine pleomorphic and amorphous calcifications (DM). Pathology: DCIS.

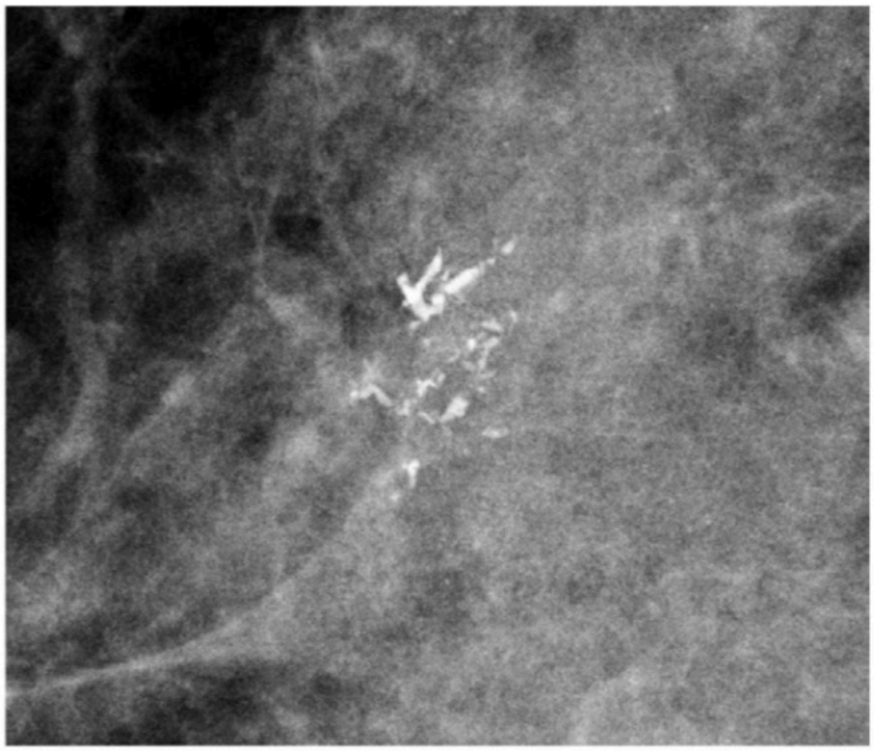

Figure 5 – Grouped FINE LINEAR calcifications (DM). Also present are some fine pleomorphic forms. Pathology: DCIS (comedocarcinoma).

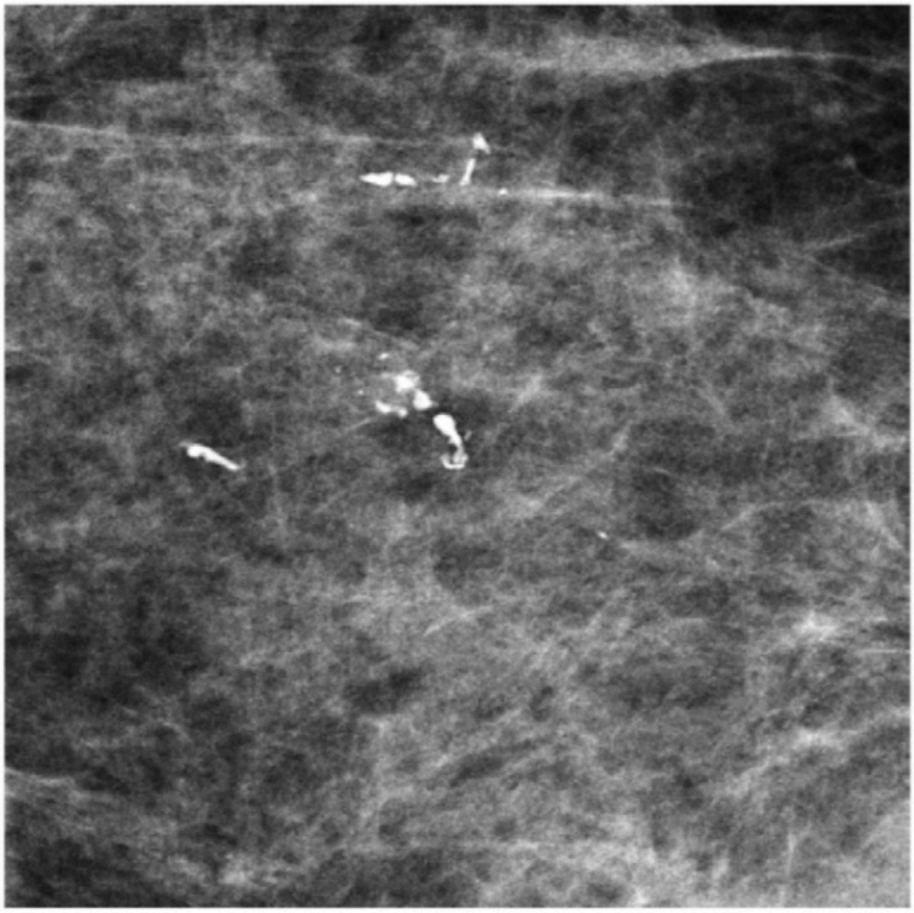

Figure 6 – FINE LINEAR calcifications in a linear distribution (DM). Some of these malignant calcifications are thicker than is usually seen in fine linear forms, but their irregular contours and linear distribution contribute to their suspicious nature. Pathology: DCIS, high nuclear grade.

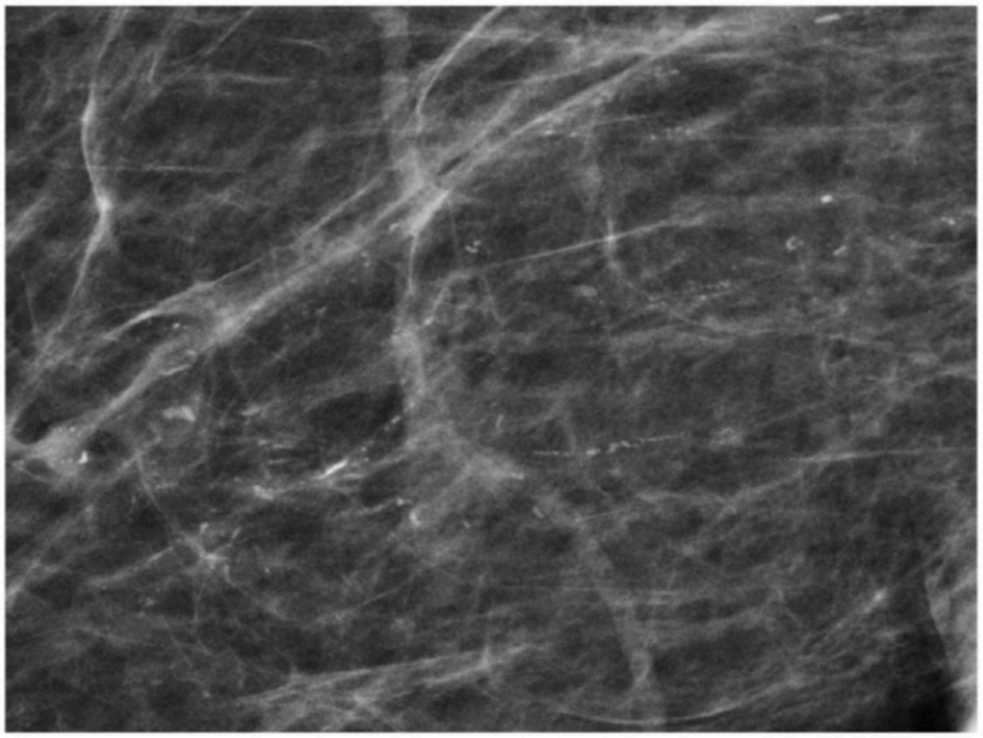

Figure 7 – Segmental FINE LINEAR calcifications (SM). Pathology: DCIS.

B. CALCIFICATIONS

3. DISTRIBUTION

Distribution descriptors are used to indicate the arrangement of calcifications in the breast. In evaluating the likelihood of malignancy for calcifications, distribution is at least as important as morphology.

a. Diffuse

Diffuse calcifications are distributed randomly throughout the breast. When bilateral, round and amorphous calcifications in this distribution are almost always benign. Unilateral diffuse calcifications are uncommon and may be due to diffuse DCIS, especially if the calcifications are coarse heterogeneous, fine pleomorphic or fine linear-branching in morphology.

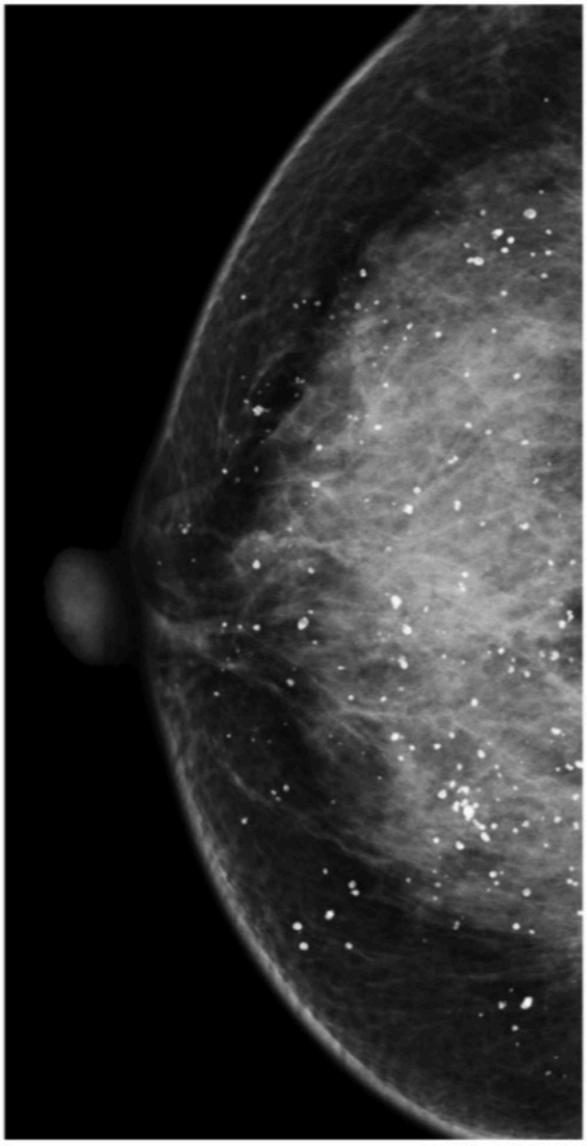

Figure 1 – DIFFUSE, primarily round calcifications (DM). Although many of these numerous calcifications have radiolucent centers, not even one calcific particle projects over the skin surface, making it unlikely that these are skin calcifications. Similar diffuse calcifications were present in the contralateral breast. Multiplicity, bilaterality, diffuse distribution, and absence of suspicious morphology should prompt a benign assessment (category 2).

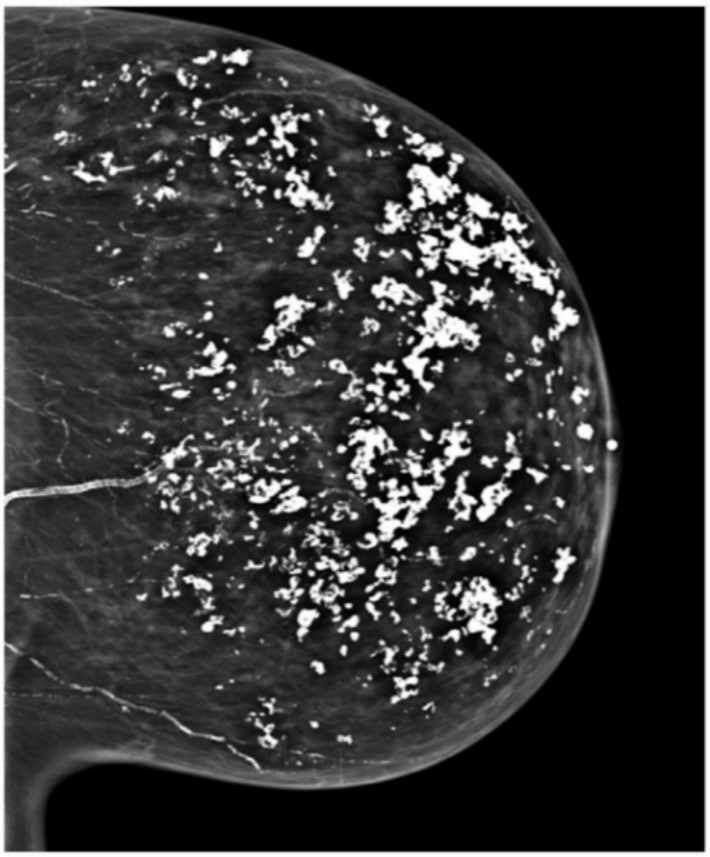

Figure 2 – DIFFUSE coarse calcifications (DM). Innumerable fibroadenomas.

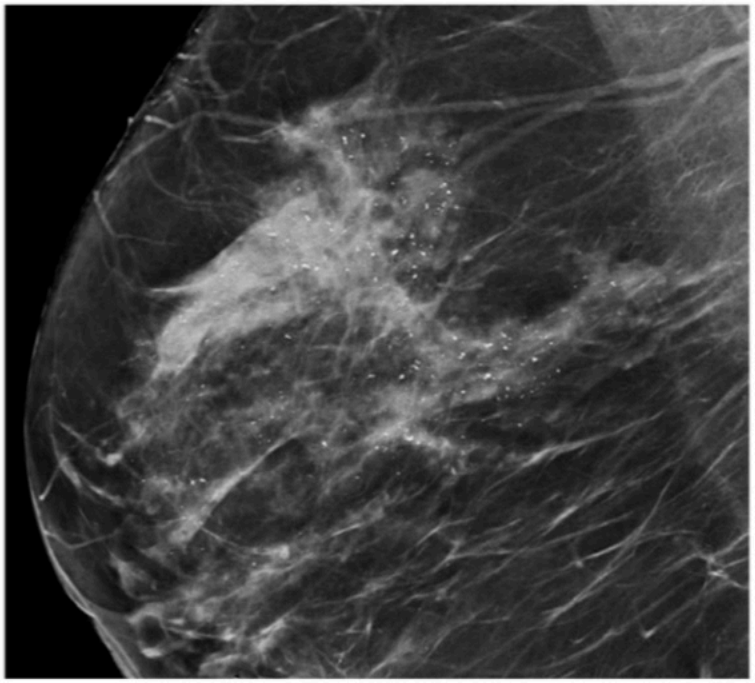

Figure 3 – DIFFUSE round and layering calcifications (ML view, SM). Although the calcifications lie mainly within fibroglandular tissue in superior and, to a lesser degree, inferior breast, they are randomly distributed amidst that tissue. Stable, benign.

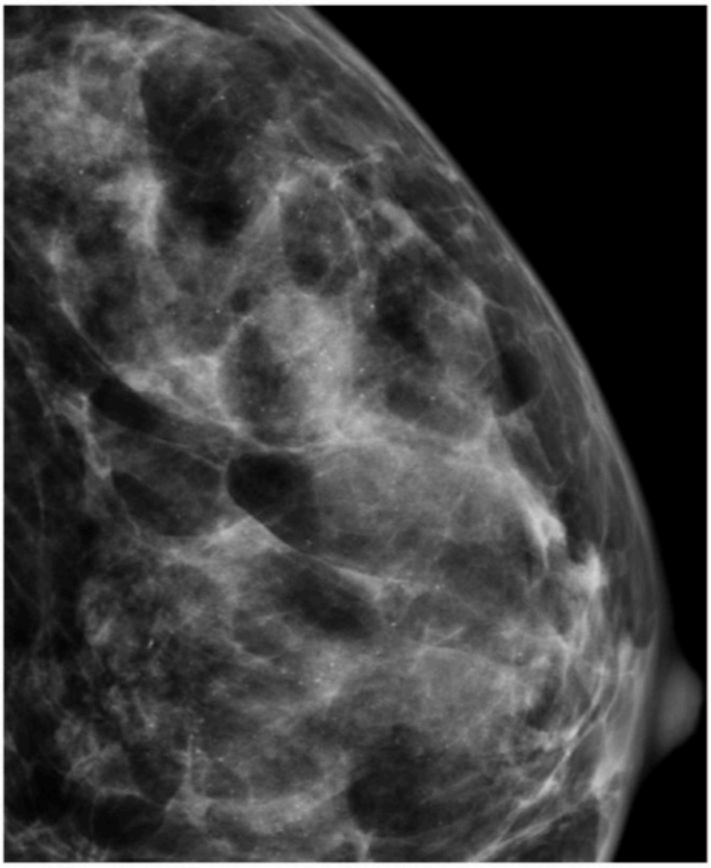

A

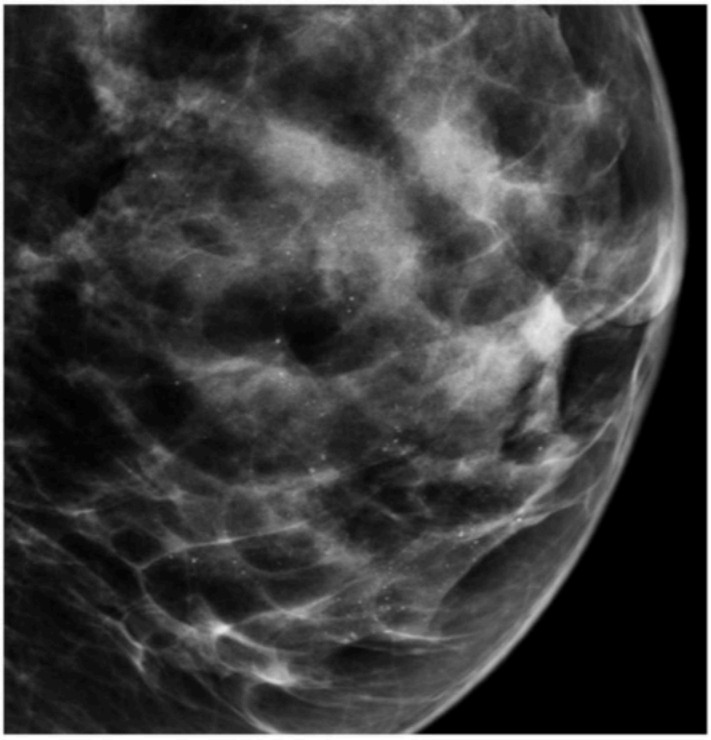

B

Figure 4 – DIFFUSE round calcifications (DM). (A) CC (B) MLO.

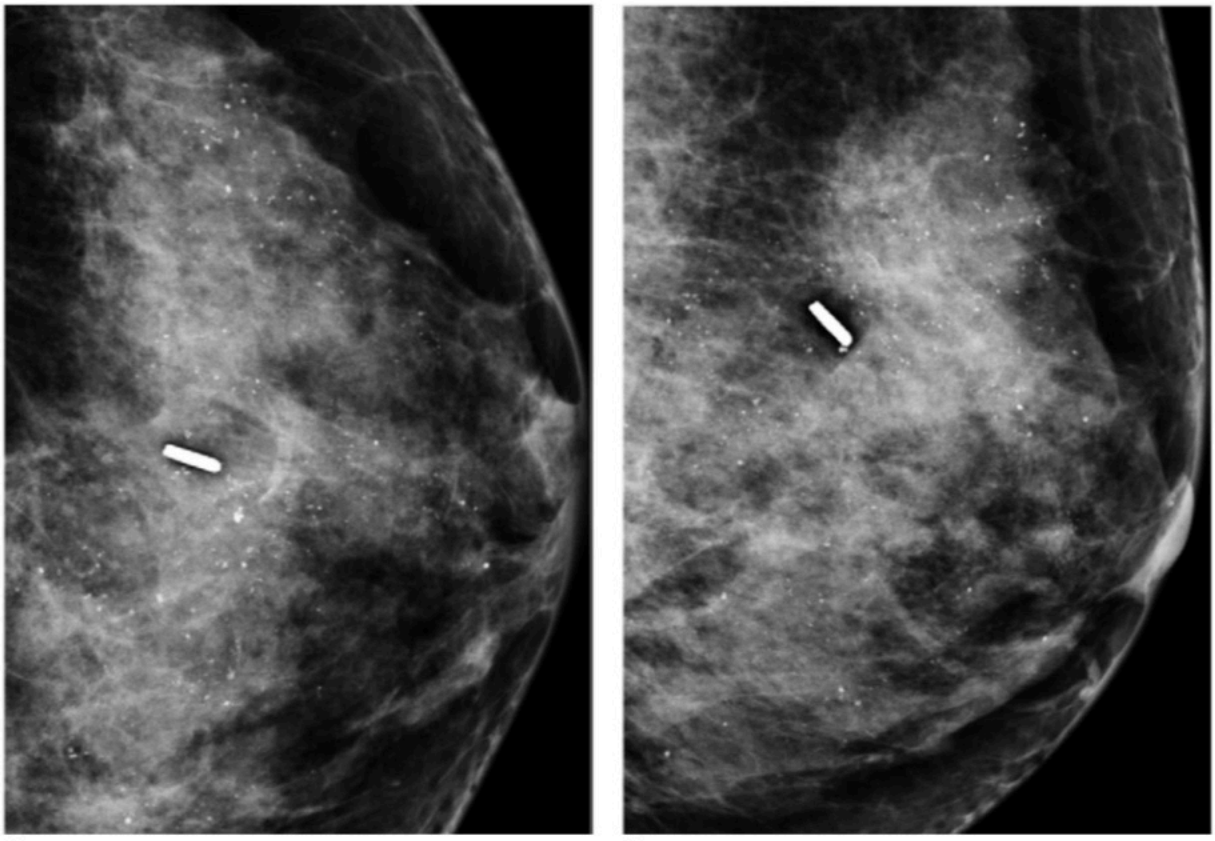

A B

Figure 5 – Round, DIFFUSE (A) CC and (B) MLO (DM).

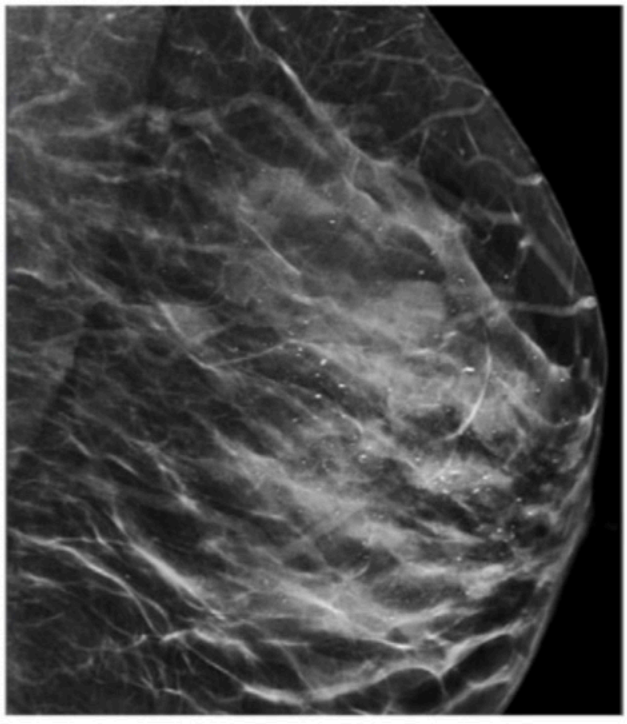

Figure 6 – DIFFUSE round and layering calcifications (SM MLO).

B. CALCIFICATIONS

3. DISTRIBUTION

b. Regional

Regional calcifications occupy a large portion of the breast, often spanning > 2 cm, but not the entire breast as seen with diffuse calcifications. Calcifications are scattered randomly throughout the region, and do not conform to a ductal or segmental distribution. Because this distribution may involve most of a quadrant or even more than a single quadrant, malignancy is less likely. However, the calcification morphology will influence the level of suspicion, as will unilaterality vs bilaterality.

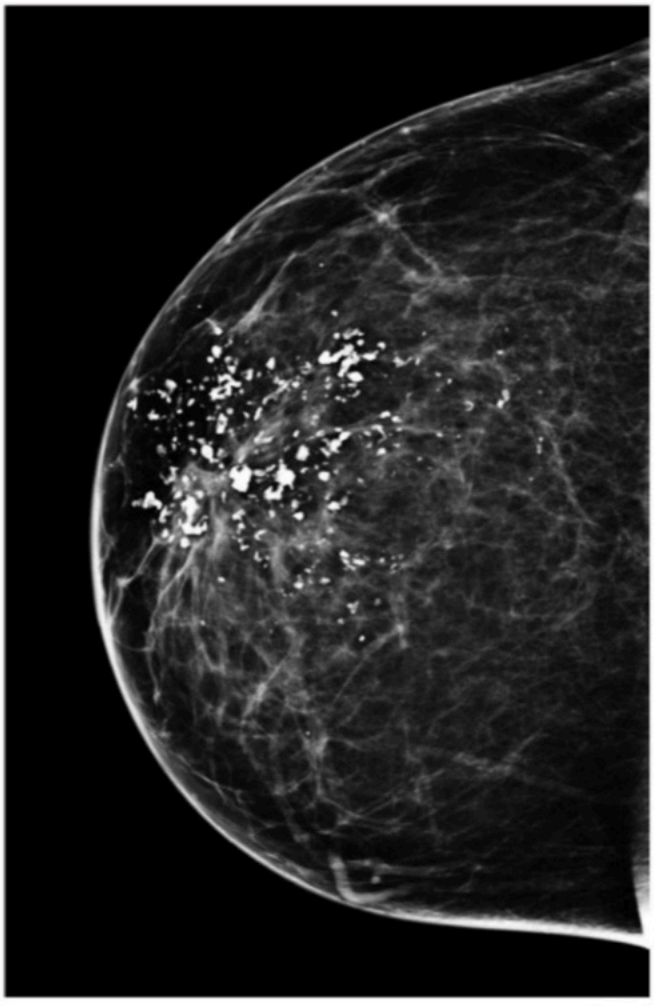

Figure 1 – REGIONAL coarse calcifications (DM). This patient had a prior seat belt injury to this breast. The calcifications are randomly distributed in the central breast. Fat necrosis.

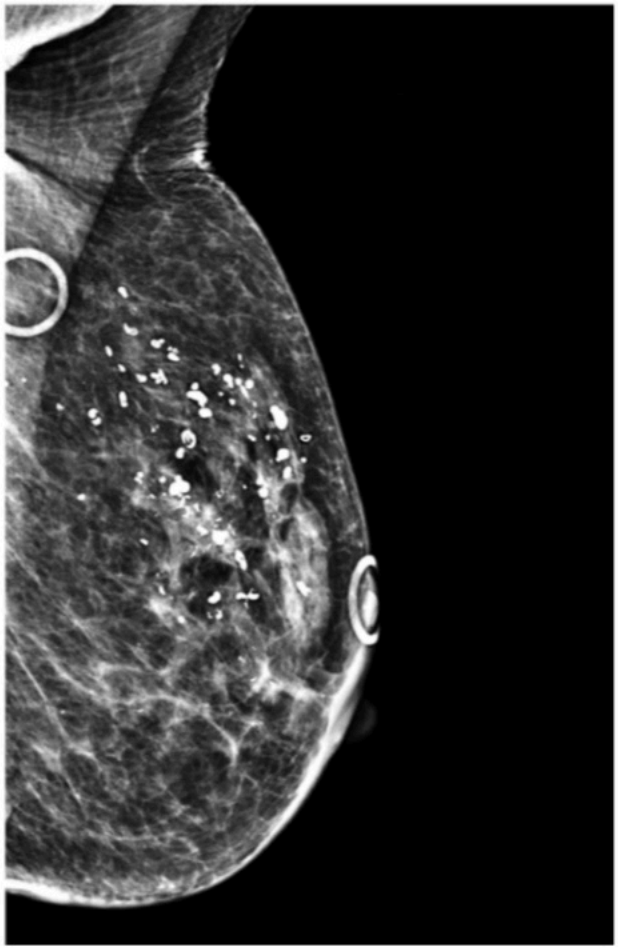

Figure 2 – REGIONAL coarse calcifications (DM). The radio-opaque skin markers outline moles. Stable, benign.

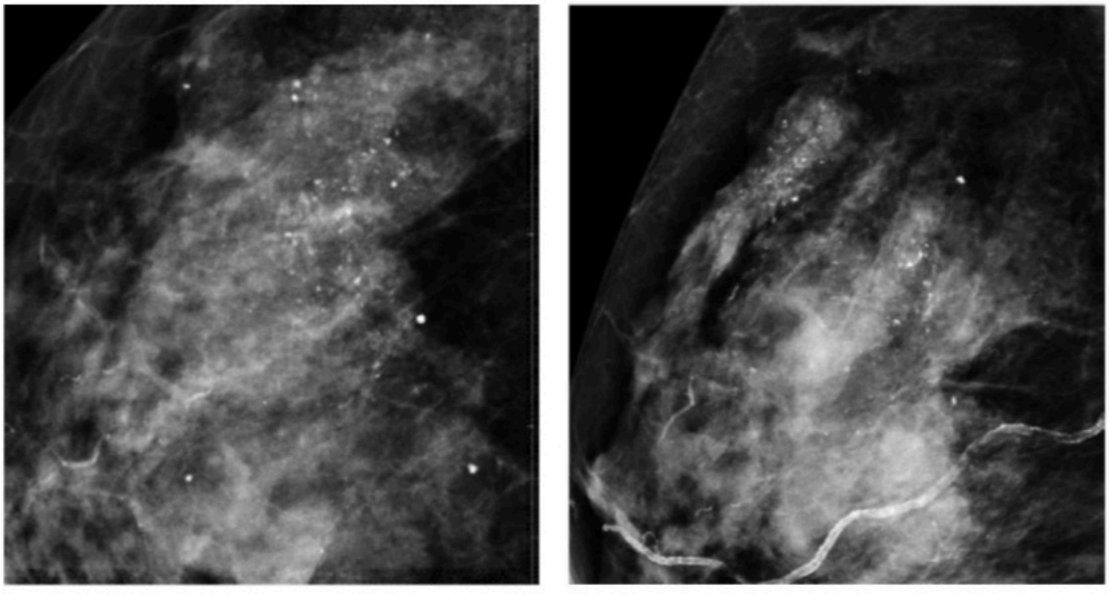

A **B**

Figure 3 – Amorphous, coarse heterogeneous and vascular calcifications, REGIONAL (DM). (A) CC and (B) MLO. Benign, confirmed by long-term stability.

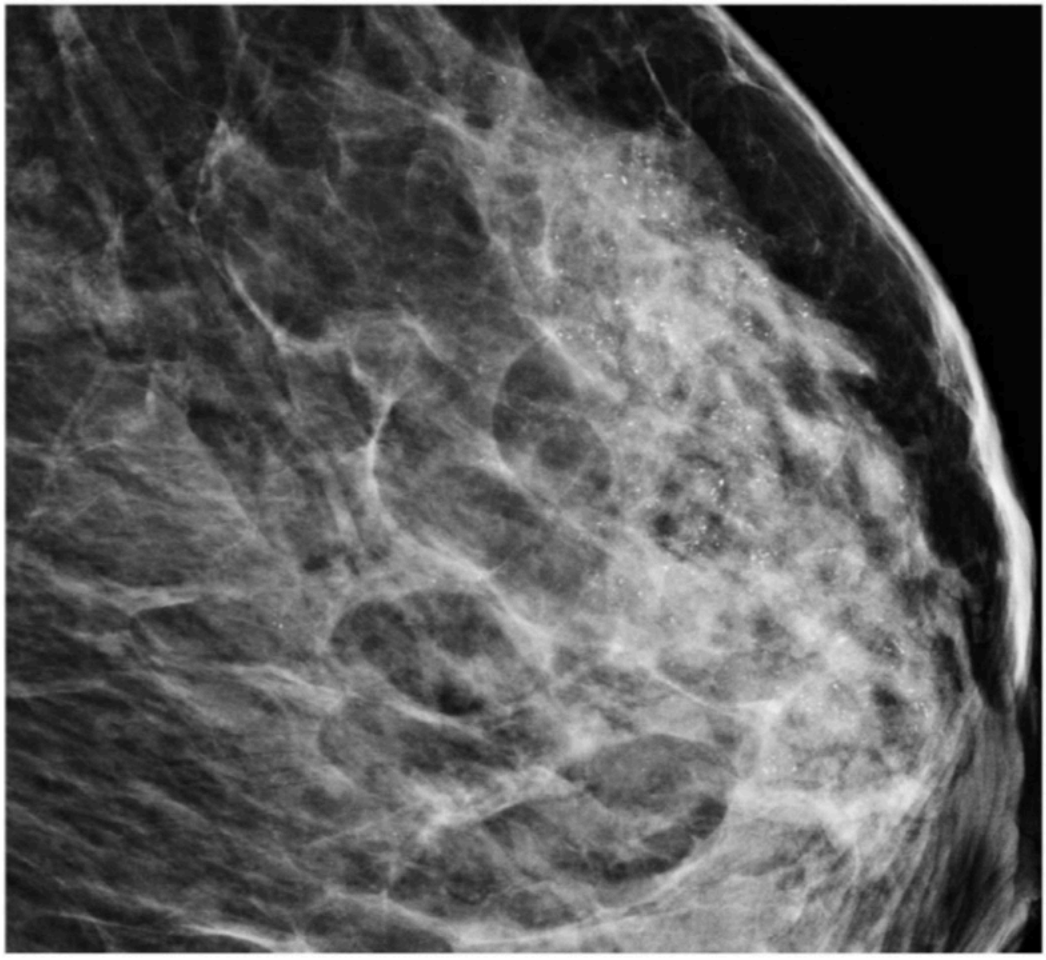

Figure 4 – REGIONAL fine pleomorphic and fine linear calcifications (DM). Although the calcifications appear to be distributed randomly within the upper portion of the breast, they show suspicious morphology, requiring biopsy. Pathology: DCIS.

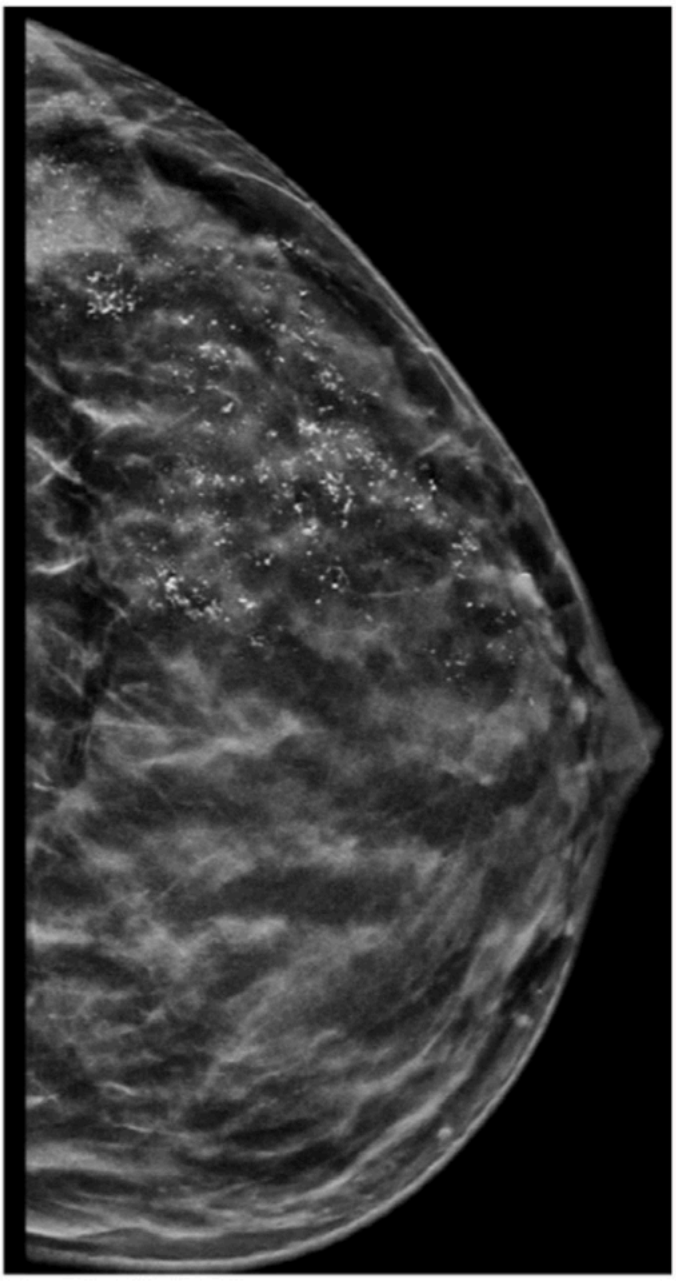

Figure 5 – REGIONAL coarse heterogeneous, fine pleomorphic and fine linear calcifications (SM). Although the morphology of these calcifications is highly suspicious and biopsy is indicated, the calcifications do appear to be largely random, rather than clearly segmental, in their distribution. This case outlines the importance of closely examining both the morphology and distribution of breast calcifications and using the more suspicious feature to inform management decisions. Pathology: DCIS.

B. CALCIFICATIONS

3. DISTRIBUTION

c. Grouped

Grouped calcifications occupy a small portion of the breast. This generally means at least five calcifications within a 1 cm area or a greater number within a 2 cm span, implying a discrete, non-random collection, as opposed to regional or diffuse distributions. Note that morphology of individual calcifications is more important than absolute number, so if suspicious, biopsy should be performed even if the calcifications number is fewer than five.

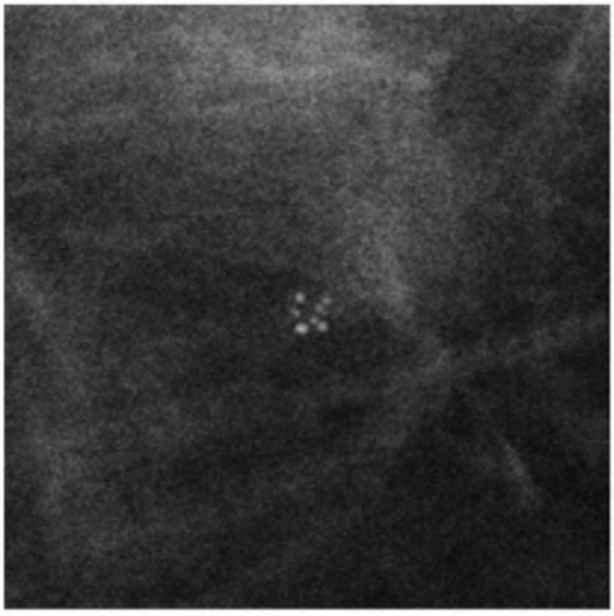

Figure 1 – GROUPED, round calcifications (DM). Stable, presumed benign.

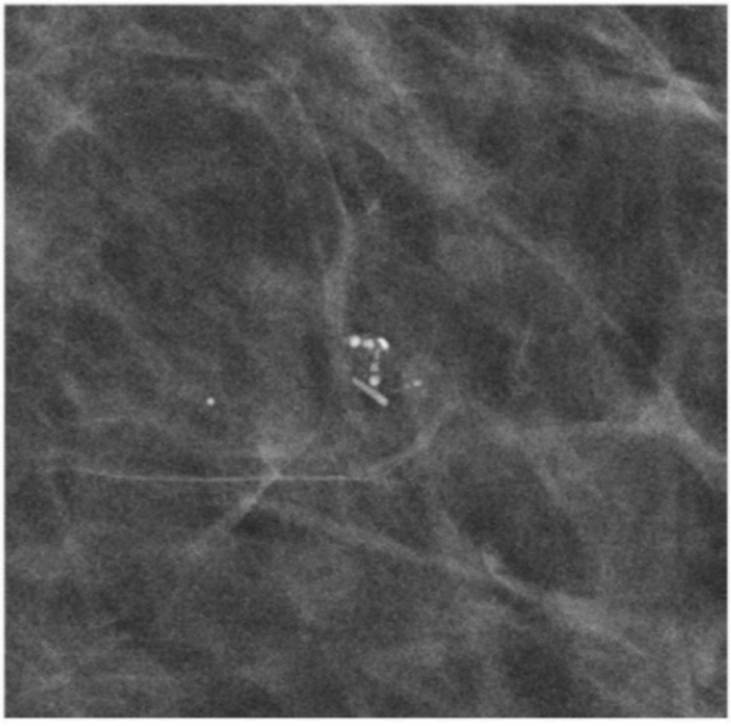

Figure 2 – GROUPED round, coarse heterogeneous and (single) linear calcifications (DM). Pathology: Fibroadenomatoid change.

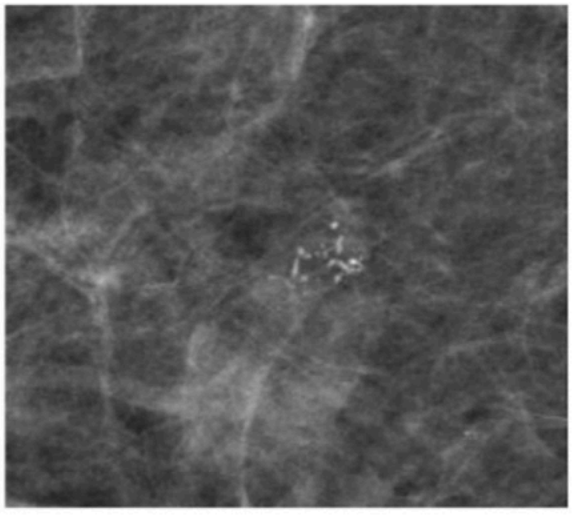

Figure 3 – GROUPED fine pleomorphic and fine linear calcifications (DM CC magnification). Pathology: DCIS.

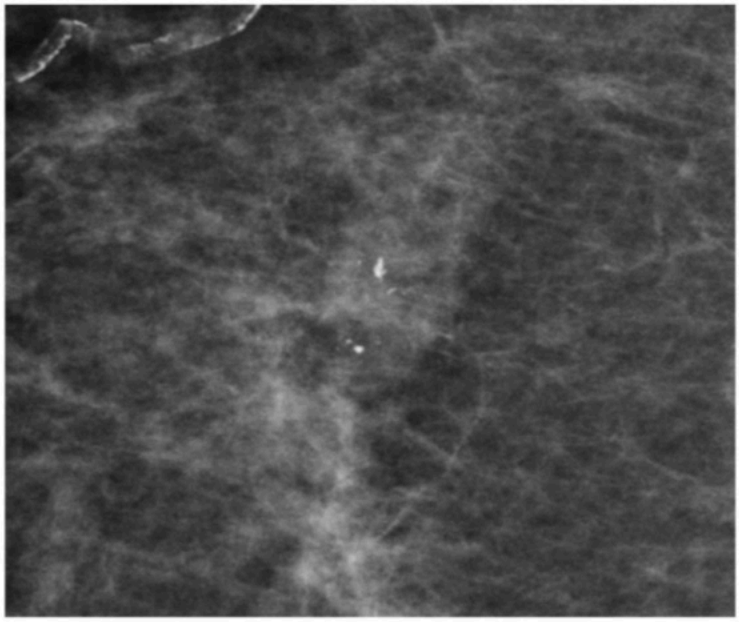

Figure 4 – GROUPED coarse heterogeneous and fine pleomorphic calcifications (DM). A surrounding soft tissue component is also present. Pathology: Fibroadenoma.

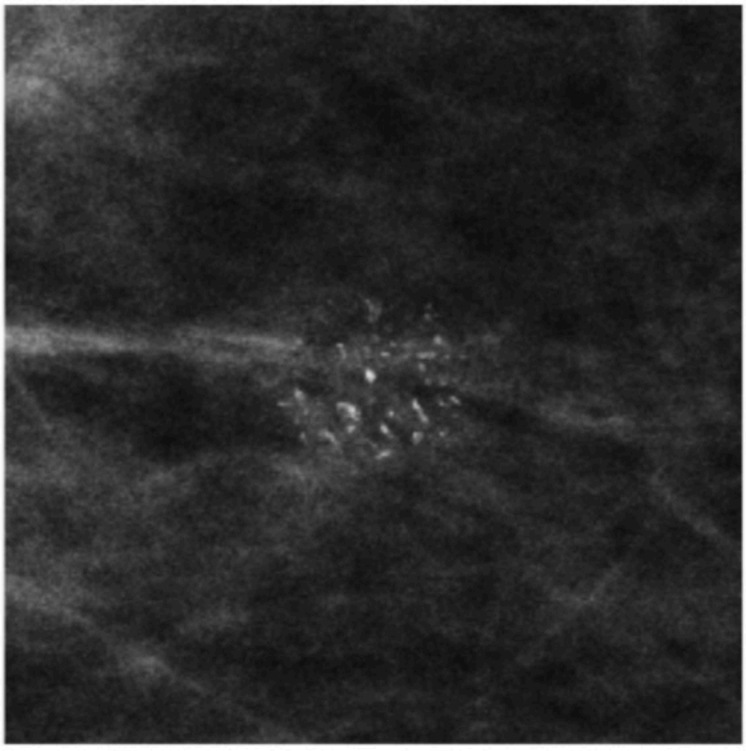

Figure 5 – GROUPED fine pleomorphic and fine linear calcifications (DM). Pathology: DCIS.

B. CALCIFICATIONS

3. DISTRIBUTION

d. Linear

Linear calcifications are arrayed in a line. This distribution has a higher suspicion for malignancy, as it suggests deposits within a duct. Although both vascular and large rod-like calcifications may be found in a linear distribution, their characteristically benign morphologies facilitate a benign diagnosis.

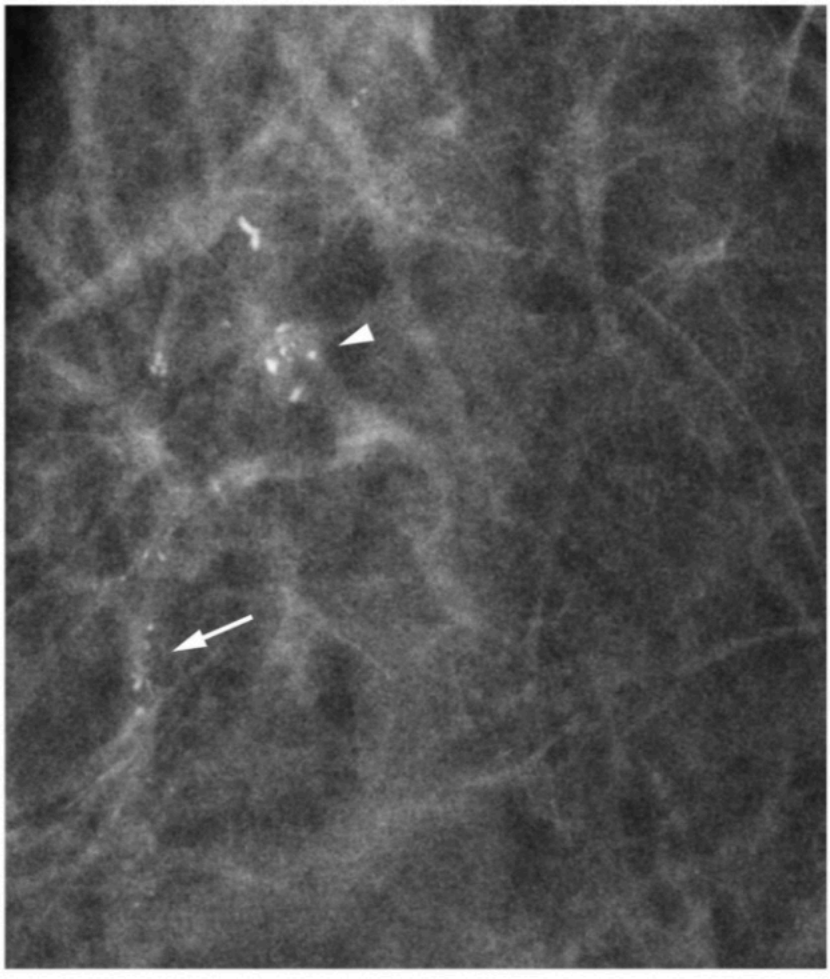

Figure 1 – LINEAR distribution of fine pleomorphic calcifications (arrow), with adjacent grouped coarse heterogeneous (arrowhead) (DM). Pathology: DCIS (arrow), stable fibroadenoma (arrowhead).

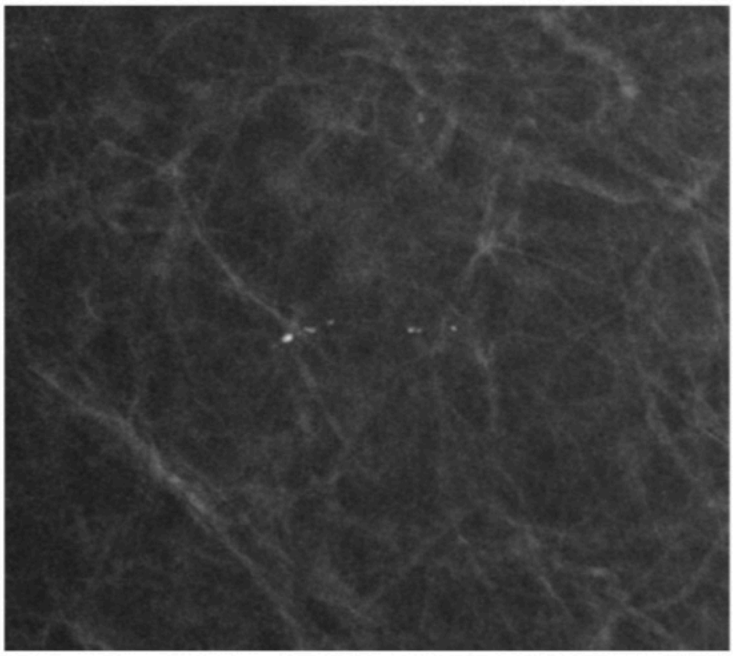

Figure 2 – LINEAR distribution of fine pleomorphic and round calcifications (DM). Pathology: Benign stromal fibrosis.

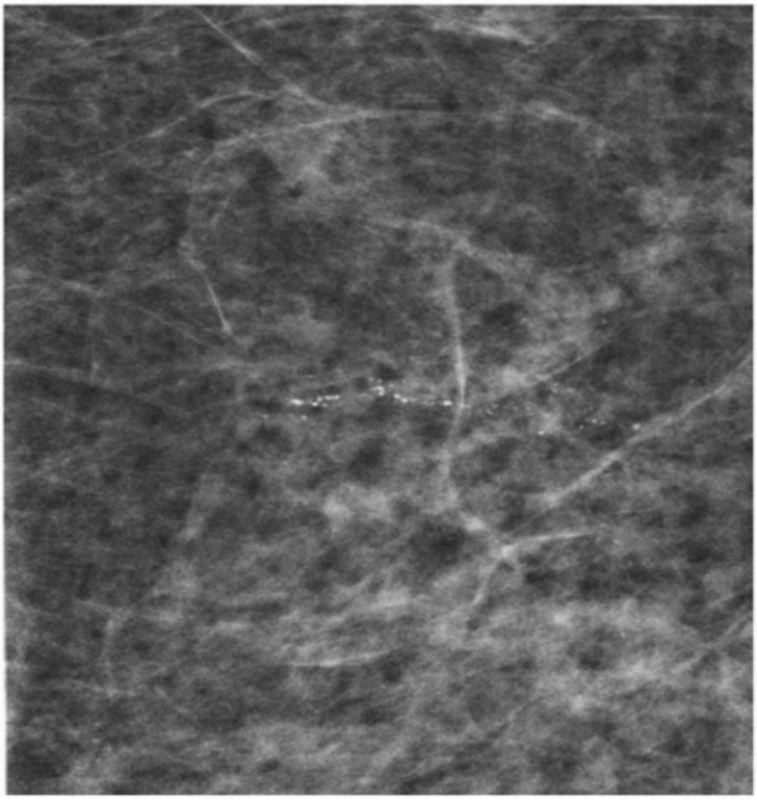

Figure 3 – LINEAR distribution of fine pleomorphic and fine linear calcifications (DM). Pathology: DCIS, intermediate grade.

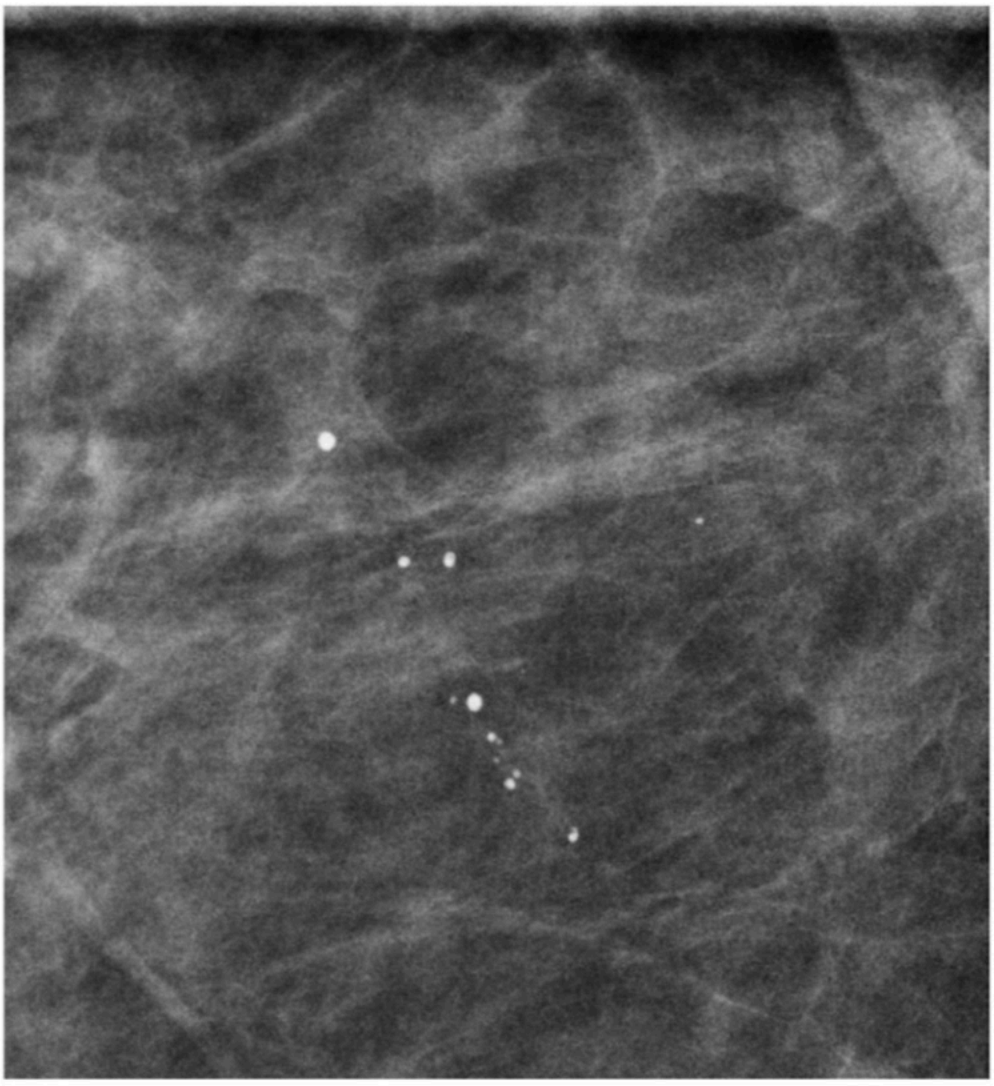

Figure 4 – LINEAR distribution of round calcifications (DM). Although the morphology appears benign, the linear distribution may prompt the need for biopsy. Pathology: Benign.



Figure 5 – LINEAR distribution of fine linear calcifications (oval) (DM). Also present are coarse and coarse heterogeneous calcifications (arrows). Pathology of circled calcifications: DCIS.

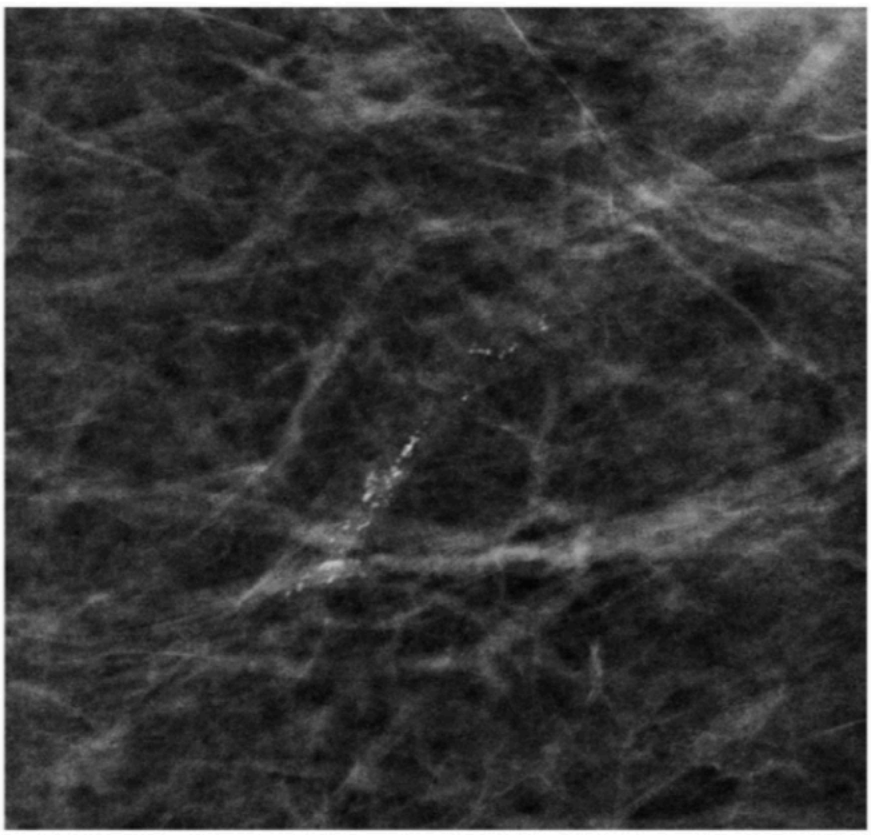

Figure 6 – LINEAR distribution of fine pleomorphic calcifications (DM magnification). Pathology: DCIS.

B. CALCIFICATIONS

3. DISTRIBUTION

e. Segmental

Segmental calcifications are generally arranged in a triangular distribution with the apex typically oriented towards the nipple in at least one projection. The triangular arrangement may be composed of multiple merging lines of intraductal calcium which converge toward the nipple, as expected in a ductal system. Segmental calcifications have a higher level of suspicion as they are likely deposits within multiple ducts or ductal branches. This distribution suggests extensive or multifocal breast cancer. Although benign causes of segmental calcifications exist (e.g., large rod-like), this distribution is of concern when the morphology is not typically benign.

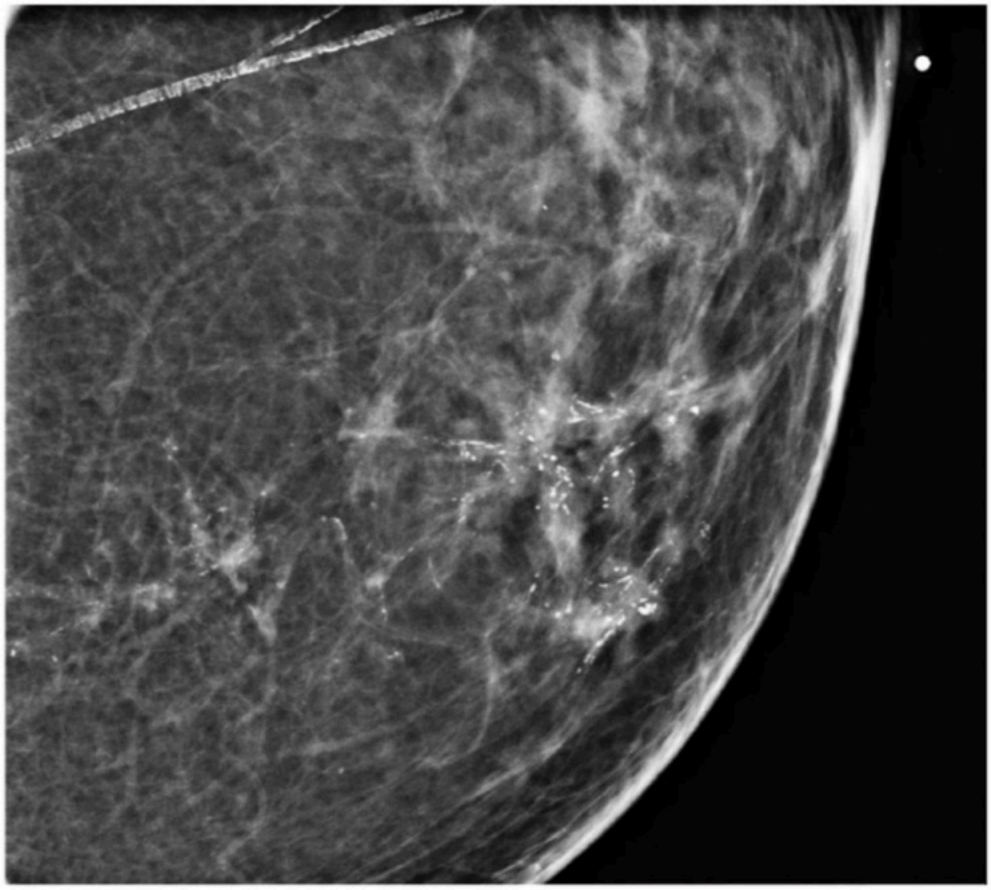

Figure 1 – SEGMENTAL distribution of fine linear and fine pleomorphic calcifications (DM). Pathology: DCIS, high grade.

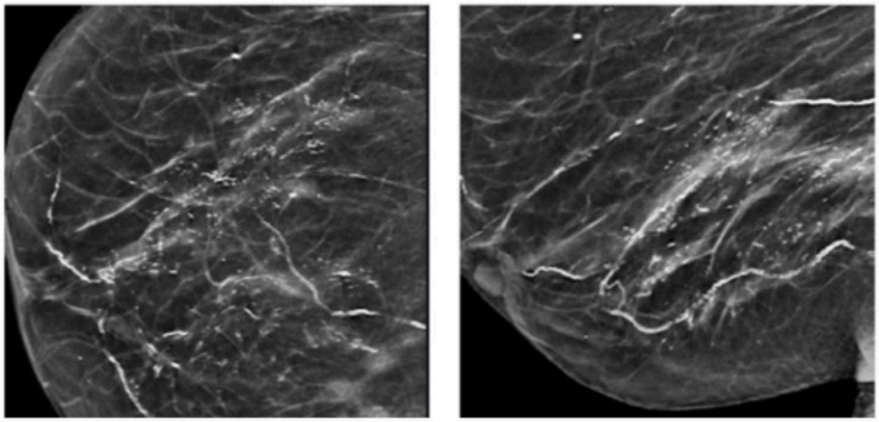

A B

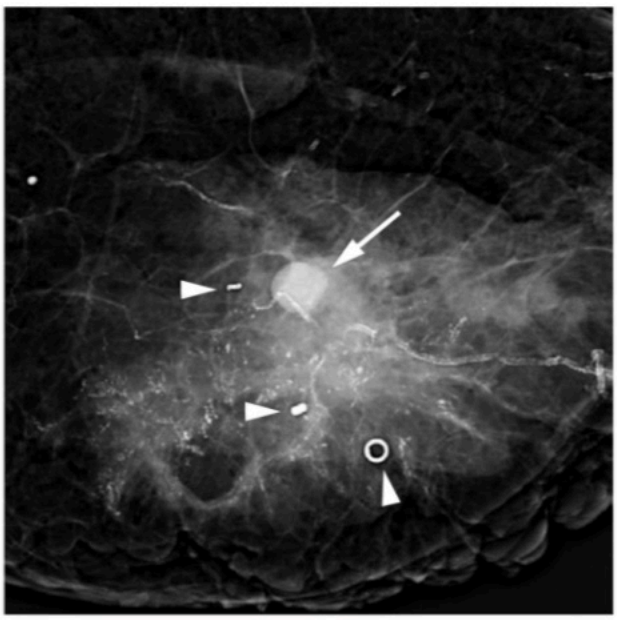

C

Figure 2 – SEGMENTAL distribution of fine linear-branching calcifications, extensive. (A) CC and (B) MLO (SM); (C) mastectomy specimen radiograph in coronal orientation (DM). Arrowheads outline core biopsy markers; white arrow shows the nipple projecting *en face* over mastectomy specimen. Pathology: IDC and DCIS.

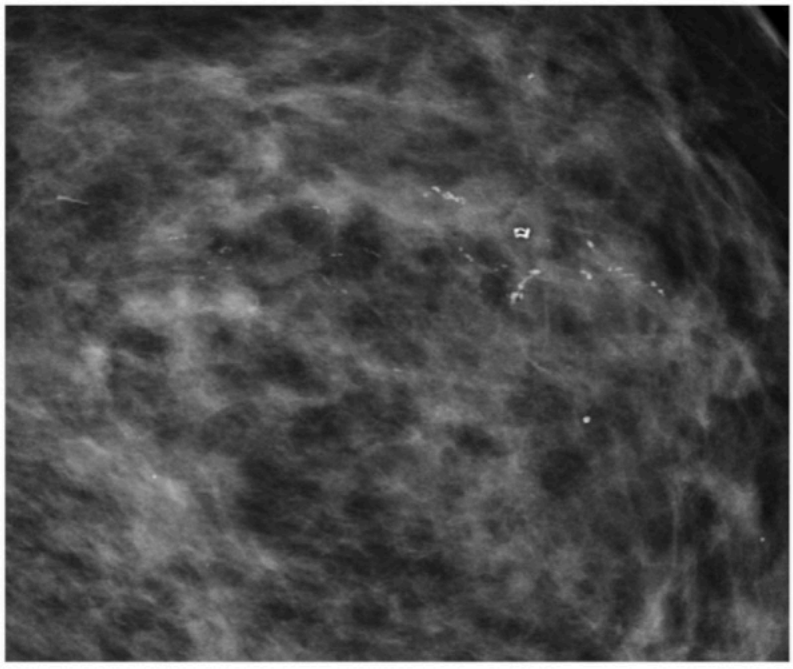

Figure 3 – SEGMENTAL distribution of fine pleomorphic, fine linear and coarse heterogeneous calcifications (DM). Pathology: DCIS, intermediate grade.

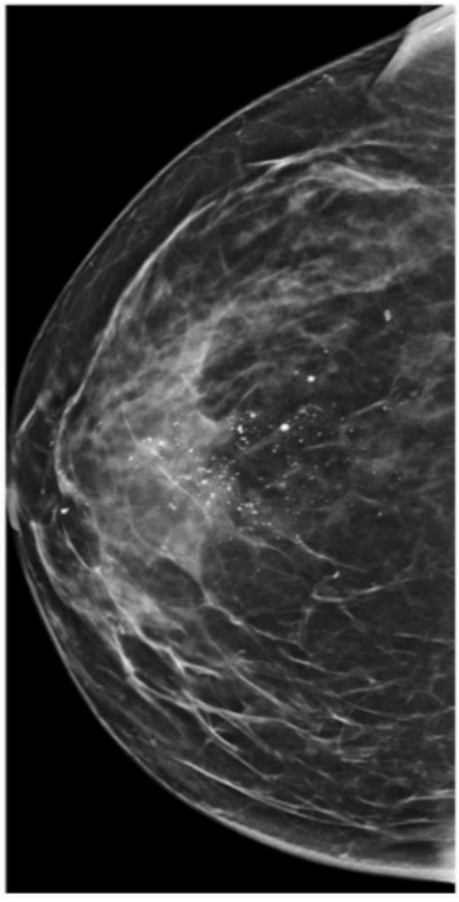

Figure 4 – SEGMENTAL round, amorphous and coarse heterogeneous calcifications (SM). Stable, benign.

C. ARCHITECTURAL DISTORTION

Architectural distortion is characterized by thin, straight, dense and/or lucent lines radiating from a point, and/or focal retraction or straightening along the edge of the breast parenchyma with no definite mass visible. Architectural distortion may be a primary finding or be secondarily associated with an asymmetry, focal asymmetry or calcifications. Architectural distortion may be more conspicuous on DBT or SM compared to DM, and may present subtly, visible only on DBT slices or only on one view. While architectural distortion is seen more frequently on DBT than DM, the positive predictive value is lower on DBT [27–29]. Nevertheless, architectural distortion that is evident only on DBT remains moderately predictive of malignancy [28–30]. In the absence of a history of trauma or surgery, a recommendation for tissue diagnosis is appropriate, even if no ultrasound correlate is identified. If the architectural distortion is questionable or seen only on one DM or SM view, careful inspection of DBT slices may facilitate identification of superimposed linear structures at different depths as the cause of pseudo-distortion.

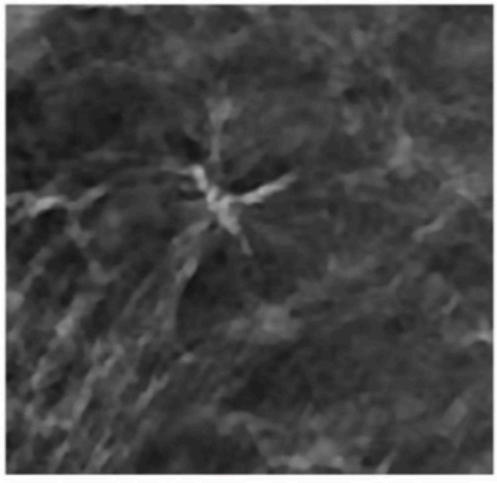

Figure 1 – ARCHITECTURAL DISTORTION (DBT). Pathology: Invasive ductal carcinoma.

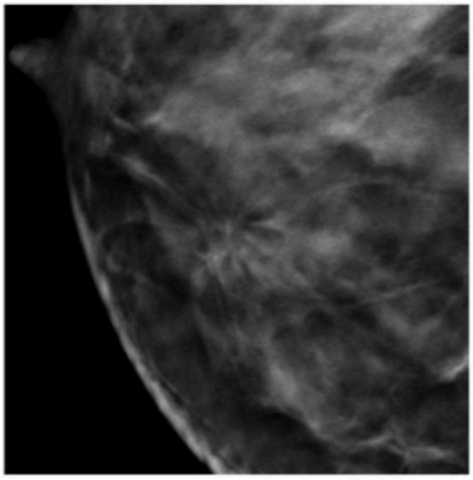

Figure 2 – ARCHITECTURAL DISTORTION (DBT). Pathology: Sclerosing adenosis.

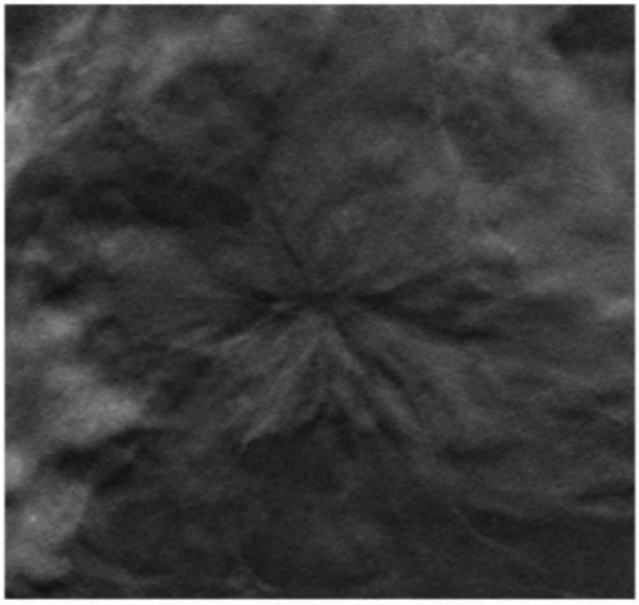

Figure 3 – ARCHITECTURAL DISTORTION (DBT). Pathology: Invasive ductal carcinoma.

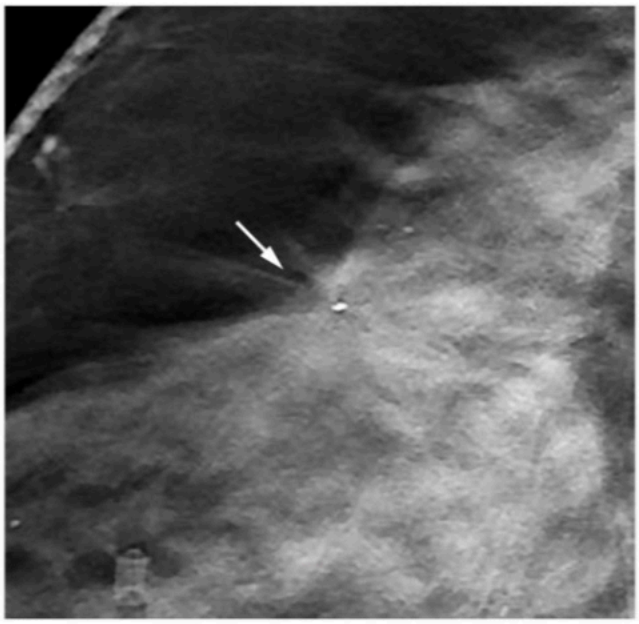

Figure 4 – ARCHITECTURAL DISTORTION (DBT). A subtle architectural distortion is demonstrated within very dense tissue (arrow), outlining the effectiveness of DBT in their detection. Pathology: Invasive ductal carcinoma.

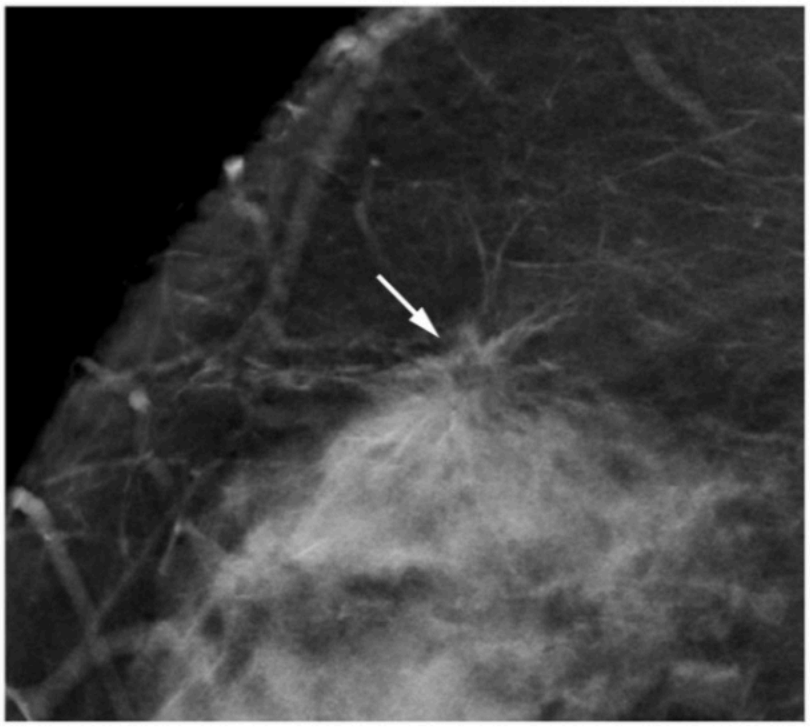

Figure 5 – ARCHITECTURAL DISTORTION (arrow) (SM). Pathology: Invasive ductal carcinoma.

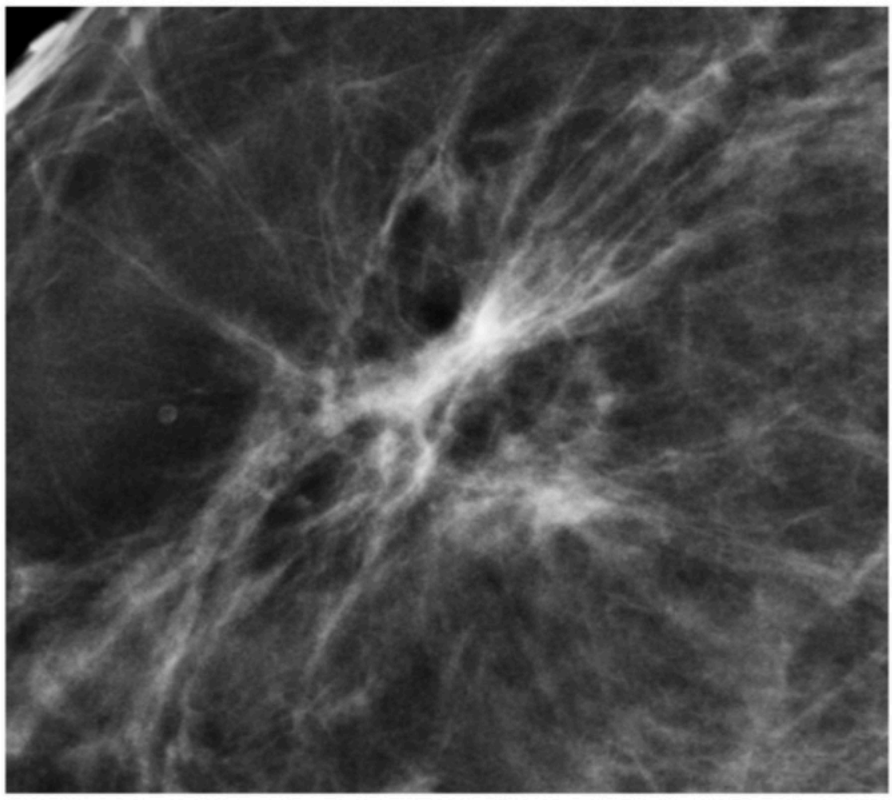

Figure 6 – ARCHITECTURAL DISTORTION (DBT). Pathology: Postsurgical changes.

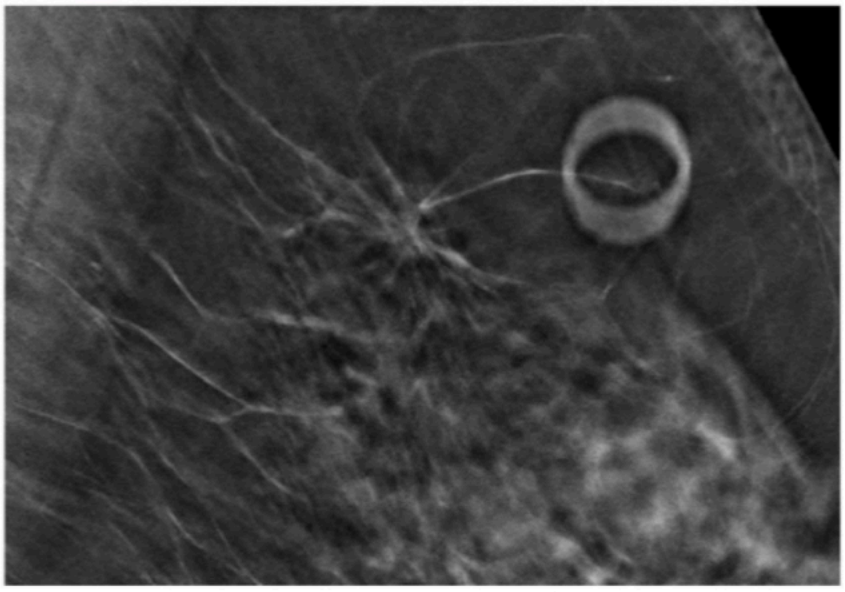

Figure 7 – ARCHITECTURAL DISTORTION (DBT). Although the appearance is suspicious, thorough percutaneous sampling and careful radiologic-pathologic correlation allowed confirmation of its benign nature. Pathology: Radial scar.

D. ASYMMETRIES

Asymmetries are unilateral focal areas of tissue that are detectable because they are unmatched in a mirror image location in the contralateral breast. They have concave contours and are usually interspersed with fat. Asymmetries do not conform to the definition of a mass, which has a radiodense center and at least partially convex contour. There are three types of asymmetries. In this version of BI-RADS, the developing asymmetry descriptor has been removed to be consistent with the remaining lexicon, where delineation of change over time is not embedded in the descriptor terminology. However, as described later, the clinical importance of a focal asymmetry that is enlarging, becoming denser or more conspicuous must be recognized.

D. ASYMMETRIES

1. GLOBAL ASYMMETRY

A global asymmetry is tissue that extends over a substantial portion of the breast (at least one quadrant) and is asymmetric to the corresponding area in the contralateral breast. There is no associated mass, architectural distortion or suspicious calcifications. Global asymmetries usually represent a normal but asymmetric distribution of fibroglandular breast tissue, often first described on a baseline mammogram. When enlarging or associated with a clinical finding, global asymmetries cannot be dismissed as benign, as some malignancies may present as large areas of asymmetric tissue.

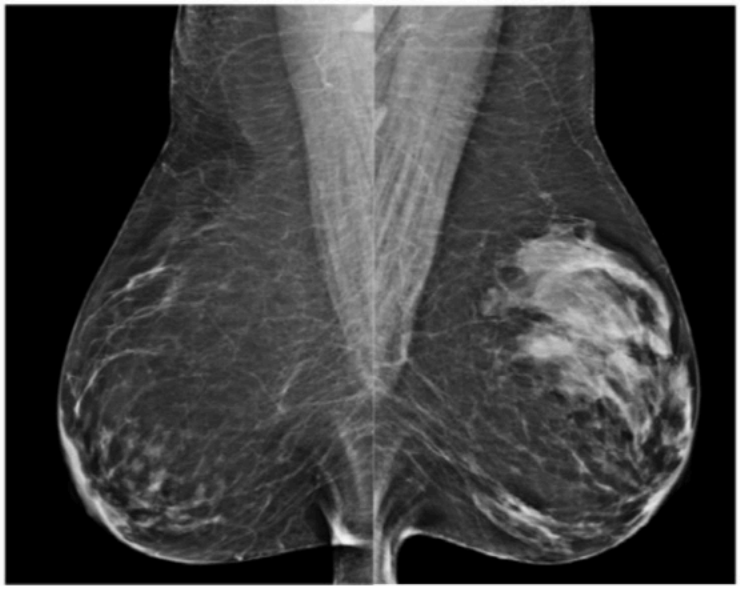

A

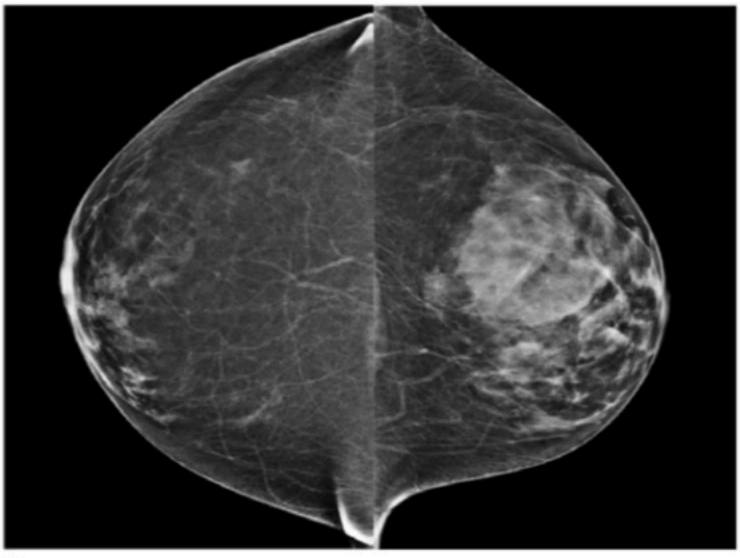

B

Figure 1 – GLOBAL ASYMMETRY (A) MLO and (B) CC (SM).
Benign - years of stability.

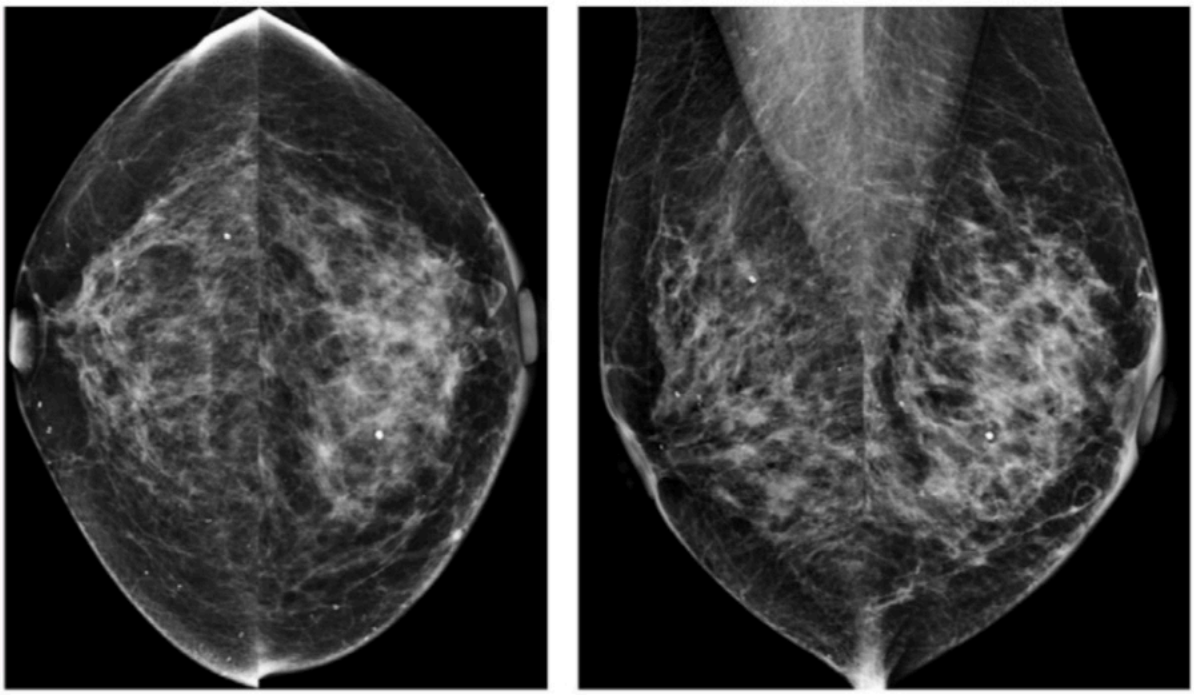

Figure 2 – GLOBAL ASYMMETRY – left breast (DM). Note left skin thickening. This finding was palpable (see triangular skin marker). Although most global asymmetries are benign and developmental, they should be approached with caution if associated with clinical or any suspicious imaging findings. Pathology: Locally advanced invasive ductal carcinoma.

D. ASYMMETRIES

2. ASYMMETRY

An asymmetry is tissue unmatched in the other breast that is visible on only one mammographic projection. If a radiologist, especially using information from DBT, can reliably and confidently recognize that a questioned asymmetry is due to normal but superimposed breast structures, no further imaging evaluation will be needed. If, on the other hand, a true lesion cannot be excluded with confidence, especially if the finding is seen on multiple consecutive DBT slices (implying that it has intrinsic volume and actually represents a focal asymmetry simply not visible on the orthogonal view) the patient should be recalled for diagnostic imaging evaluation. Most asymmetries represent the superimposition of normal breast structures. However, on subsequent diagnostic views, an asymmetry confirmed to be a real finding may be determined to represent a mass or focal asymmetry.

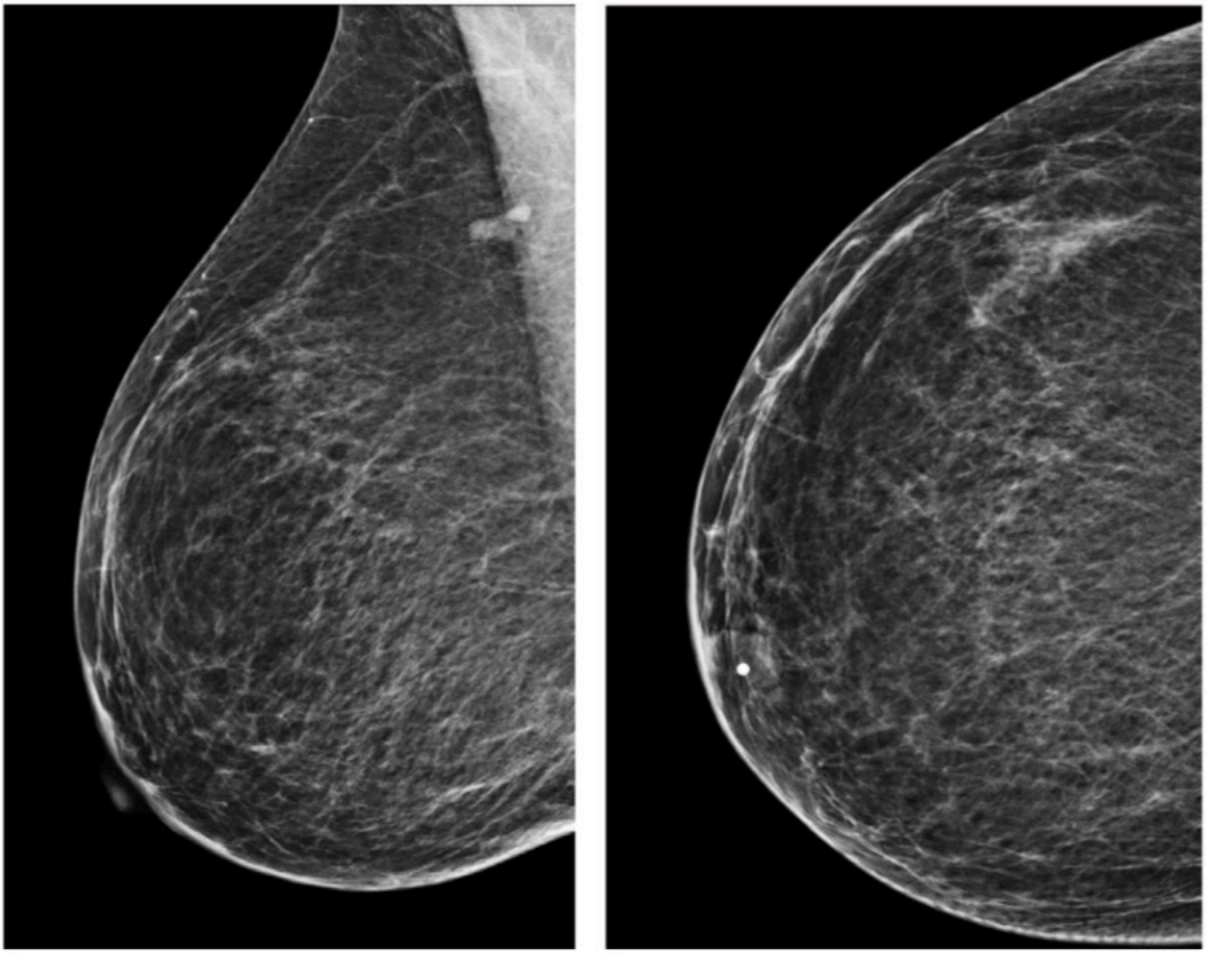

A B

Figure 1 – ASYMMETRY (A) MLO and (B) CC (SM). Tissue seen only on CC view. No matching tissue was seen in the contralateral breast. Stable over many years, benign.

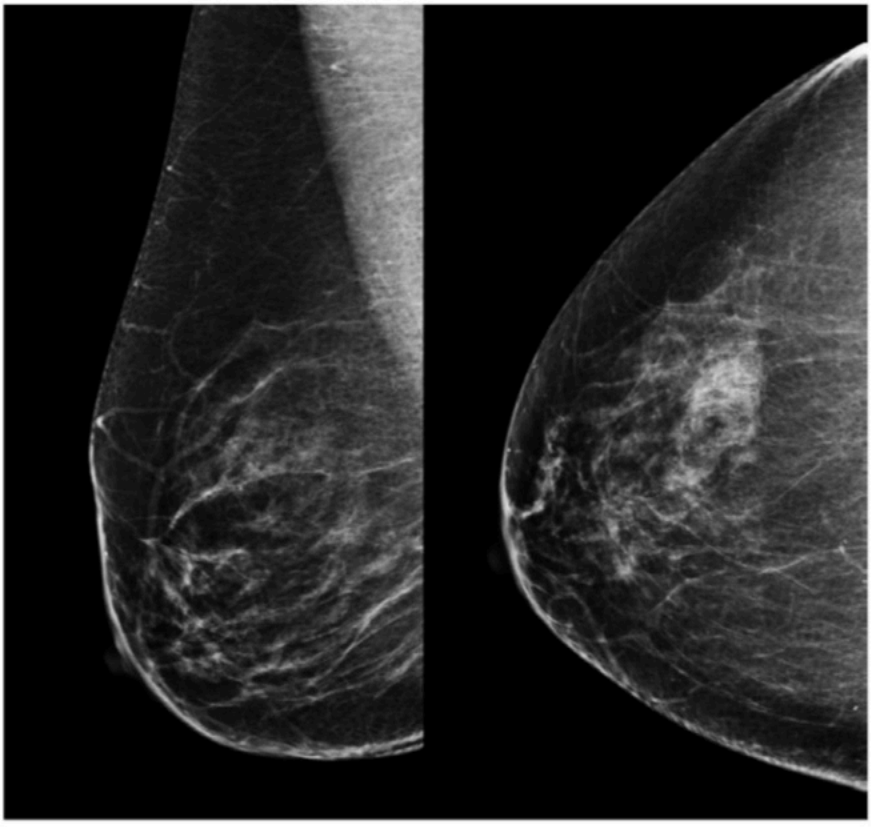

Figure 2 – ASYMMETRY (DM). Note the area of dense tissue in the lateral aspect of the right breast seen only on the CC view (right image). Presumed to represent summation artifact. No asymmetry was visible at subsequent screening examination 1 year later.

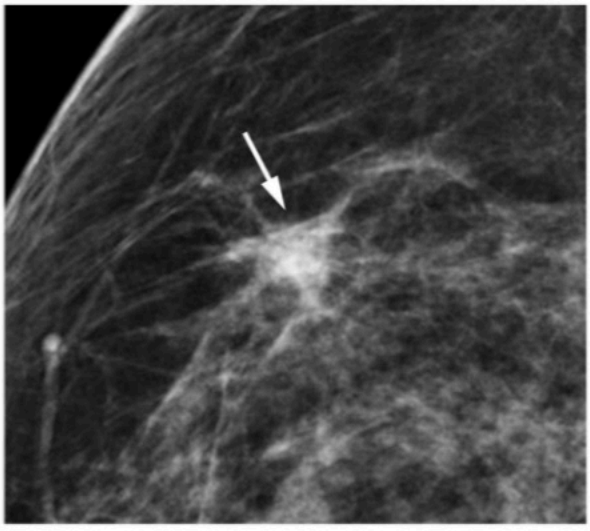

Figure 3 – ASYMMETRY (SM). This triangular area of tissue (arrow), although conspicuous, does not meet the criteria for a mass (it was seen only on one view, has a concave contour and interspersed fat). There was no matching finding the contralateral breast. It therefore is characterized as an asymmetry. Diagnostic work-up confirmed that it represented superimposed tissue.

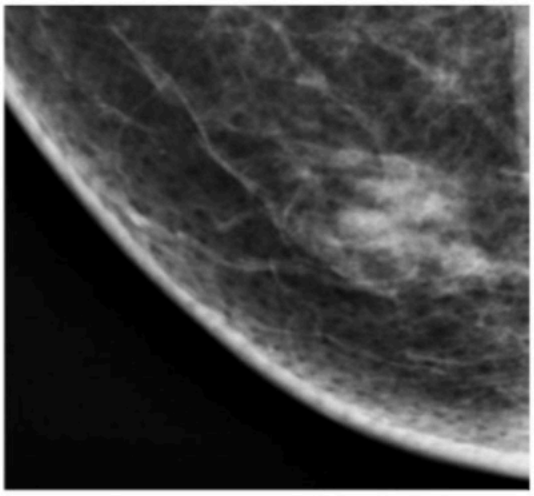

Figure 4 – ASYMMETRY (SM). Pathology: PASH.

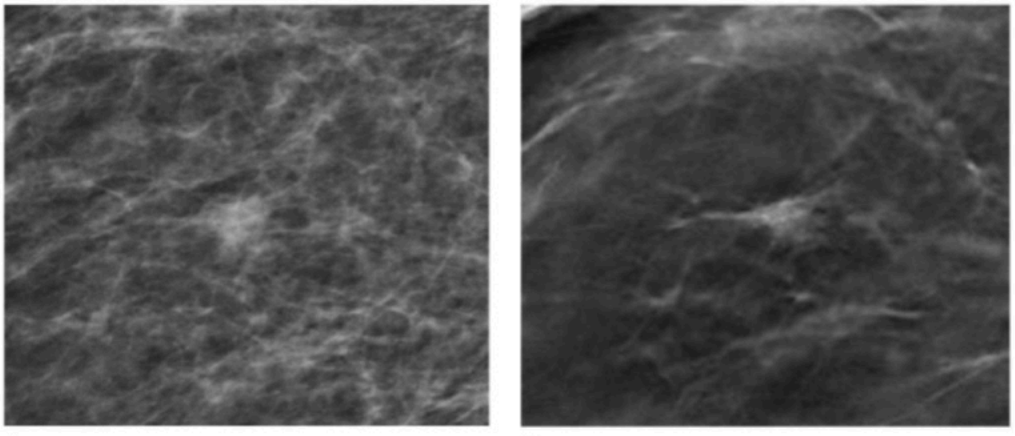

A B

Figure 5 – ASYMMETRY (A) DM and (B) DBT slice. There was no corresponding finding on other screening views, so this finding was characterized as an asymmetry. However, due to the density of the finding and its persistence on subsequent diagnostic work-up, biopsy was recommended. Pathology: Invasive ductal carcinoma.

D. ASYMMETRIES

3. FOCAL ASYMMETRY

A focal asymmetry is an area of tissue that is confined to less than one quadrant and asymmetric to the corresponding location in the contralateral breast. It is visible and may appear similar on multiple mammographic projections (hence, a real finding rather than superimposition of normal breast structures) but lacks the convex contour, central density and the conspicuity of a mass. The contour of a focal asymmetry is concave and there is usually interspersed fat.

Note that occasionally what is properly described as a focal asymmetry at screening (i.e., a finding visible on standard MLO and CC views) is determined at diagnostic mammography to be two different findings, (i.e., two separate asymmetries, each representing superimposed normal tissue) or, alternatively, an actual mass. A focal asymmetry that is new or increasing in size or conspicuity compared to prior mammograms is more suspicious than a focal asymmetry seen on a baseline mammogram and these two entities should be managed differently (i.e., biopsy of a new or increasing focal asymmetry; short-term follow-up of a focal asymmetry seen on baseline exam assuming no additional mammographic or sonographic findings are present at diagnostic evaluation).

Although the term "developing asymmetry" as a descriptor has been discontinued in this version, the clinical importance of a new or increasingly conspicuous focal asymmetry should be strongly stressed. If confirmed to be a real finding on diagnostic evaluation, biopsy should be recommended even in the absence of an ultrasound correlate, as the positive predictive value for such a finding is in the range of 7.4–12.8% when detected on screening and 19.7–26.7% in the diagnostic setting [31, 32].

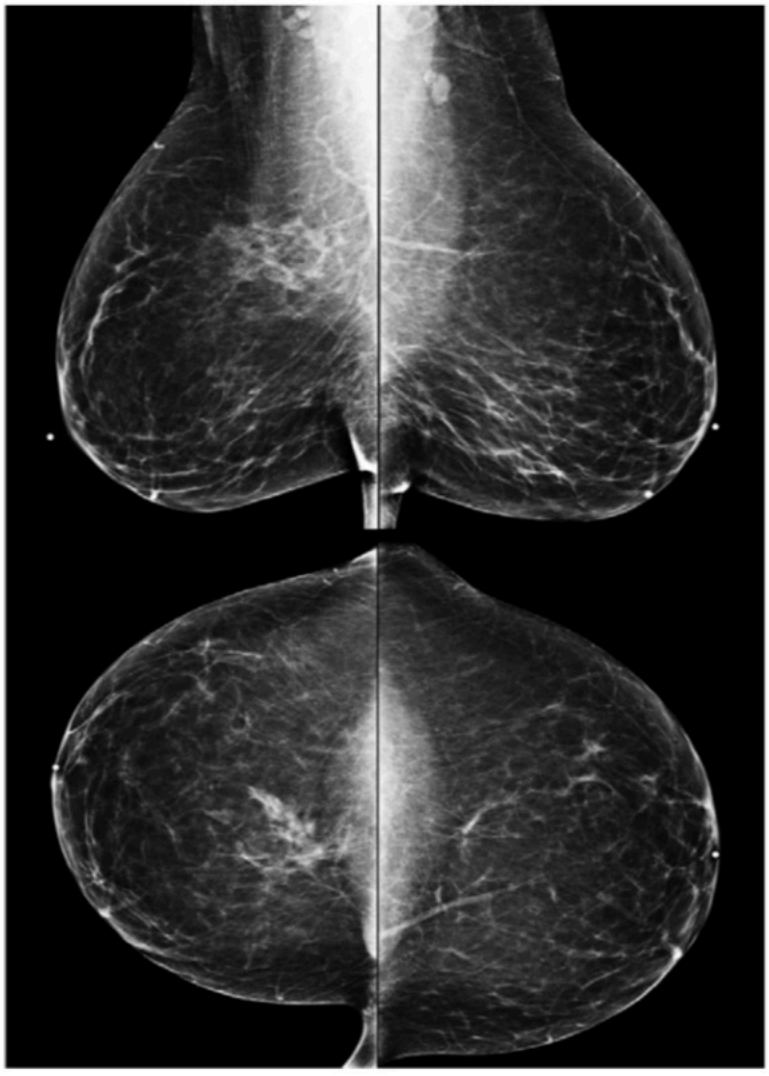

Figure 1 – FOCAL ASYMMETRY (DM). The asymmetric dense tissue occupies less than the entire upper inner quadrant of the right breast. Presumed benign. Long-term stability was observed by comparison with previous examinations.

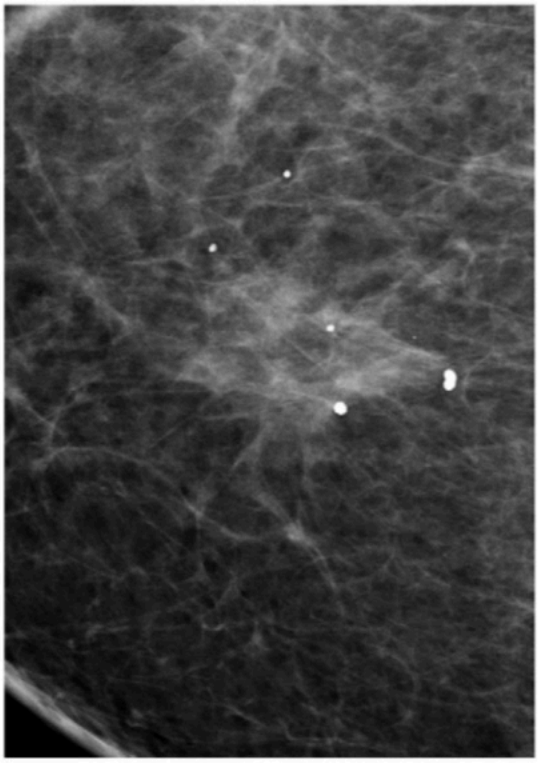

Figure 2 – FOCAL ASYMMETRY (DM). This finding was seen on CC and MLO screening views and appeared similar on both views (only one detailed view shown here). The tissue has a concave contour, is interspersed with fat, and has no associated mass, architectural distortion, or abnormal calcifications. There was no correlate at targeted US examination. This finding was assessed as probably benign after full diagnostic imaging work-up, but slight interval enlargement at 6-month follow-up examination then prompted a suspicious assessment. Pathology (stereotactic core biopsy): Invasive ductal carcinoma.

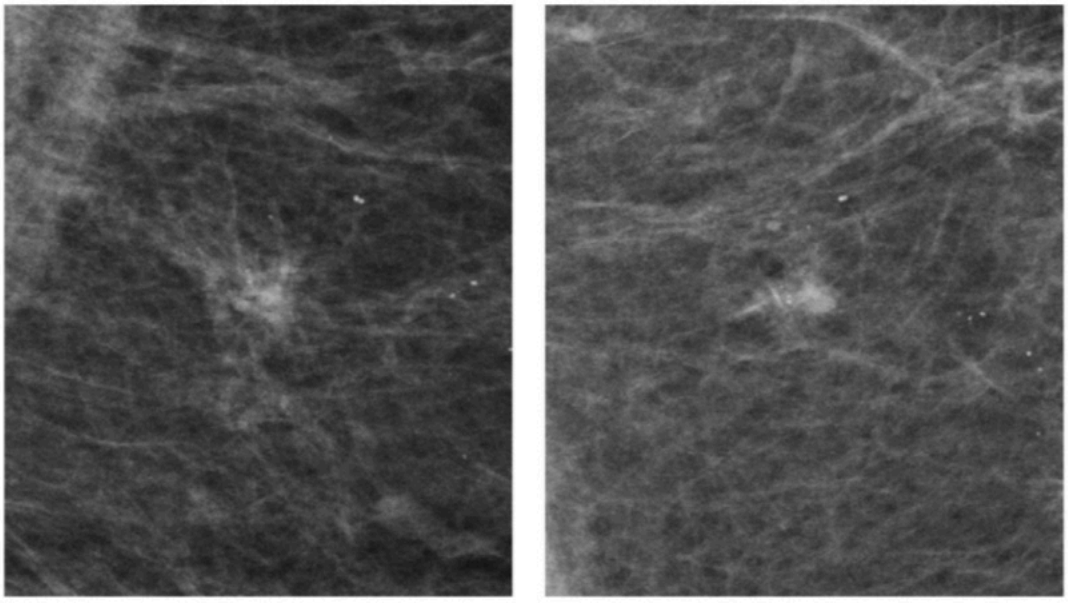

A B

Figure 3 – FOCAL ASYMMETRY (DM). (A) MLO and (B) CC. This finding was unmatched in the contralateral breast and was new compared to prior exams. While discernable in two views, it does not fulfill the criteria for a mass. Diagnostic evaluation is indicated for focal asymmetries that are new or increasing in conspicuity. Pathology: Invasive ductal carcinoma.

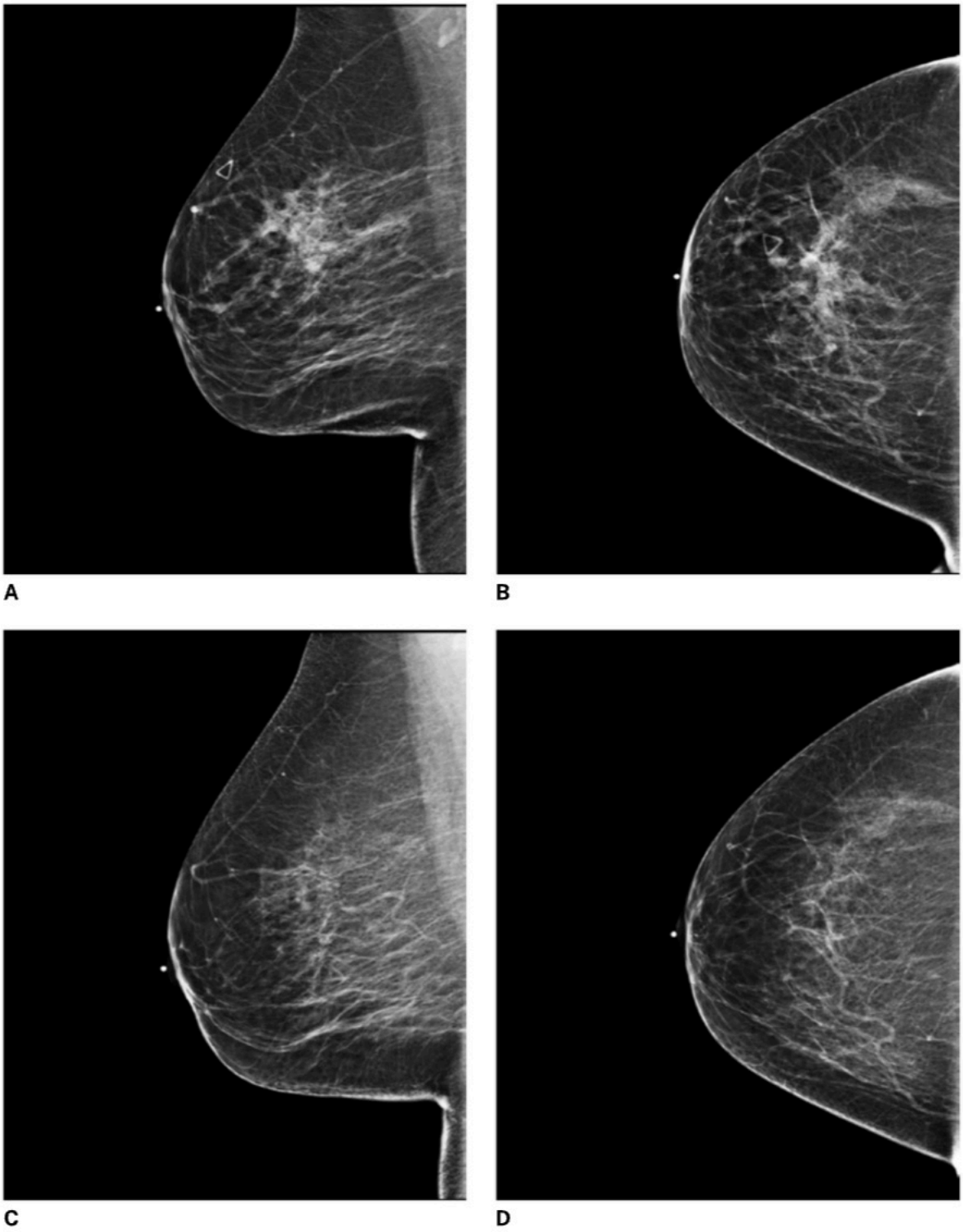

Figure 4 – FOCAL ASYMMETRY. A palpable focal asymmetry (location indicated by triangular skin marker) is noted in superior right breast (DM) on (A) MLO and (B) CC views. It is new compared to the prior exam (C, D). Pathology: Invasive lobular carcinoma.



E

Figure 4 – *(Continued)* FOCAL ASYMMETRY. Targeted US (E) shows a corresponding hypoechoic shadowing non-mass lesion. Core biopsy was performed under US-guidance. Pathology: Invasive lobular carcinoma.

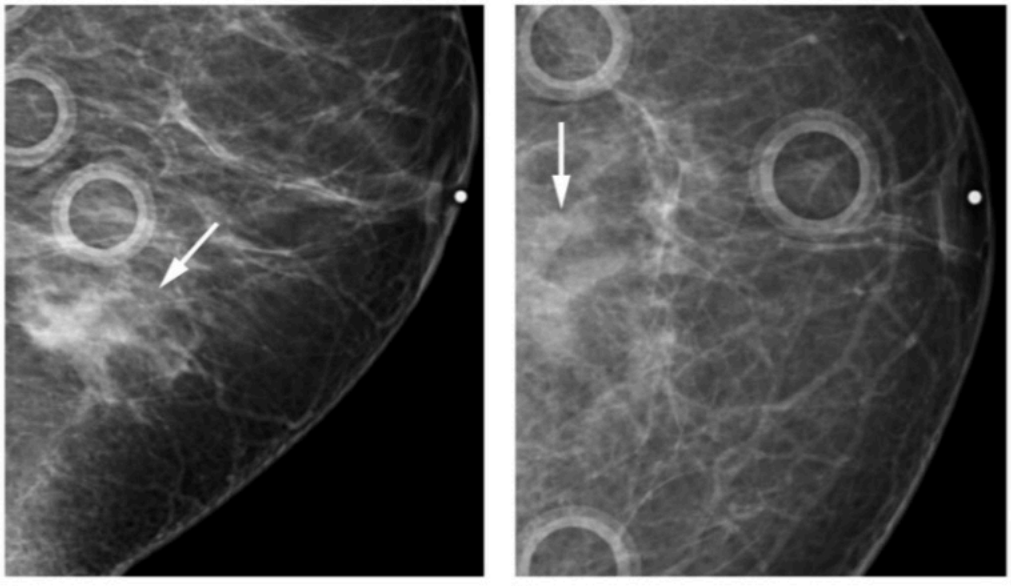

A B

Figure 5 – FOCAL ASYMMETRY (arrows). (A) MLO and (B) CC (DM). This focal asymmetry (arrows) is more apparent on the MLO than the CC view but was new, confirming the need for further evaluation. Note incidental circular mole markers and metallic nipple marker. Pathology: DCIS.

E. LYMPH NODES

1. INTRAMAMMARY LYMPH NODES (IMLN)

Normal intramammary lymph nodes are circumscribed masses that are reniform in shape and have hilar fat. Rigorous, peer-reviewed data providing clear morphologic standards to differentiate benign and suspicious intramammary lymph nodes on mammography are currently absent. Morphology is the most important factor to consider in the assessment of lymph nodes.

a. Normal intramammary lymph nodes typically display reniform shape and a fatty hilum. Intramammary lymph nodes most commonly occur in the upper outer quadrant of the breast, approaching the axilla, although they may occur elsewhere in the breast. New oval circumscribed masses should not be assumed to be lymph nodes unless they fulfill morphologic criteria, especially when they are not located laterally. They often are seen adjacent to an artery or vein because the lymphatic drainage of the breast often parallels the vascular drainage. The presence of hilar fat and the relationship to an adjacent vessel is often more apparent on DBT than DM.

b. Abnormal lymph nodes may show rounded morphology and or loss of fatty hila and/or subjectively thickened cortices. Changes in lymph node size or shape from prior imaging or asymmetry compared to contralateral intramammary nodes, may raise suspicion in the appropriate clinical context [33, 34].

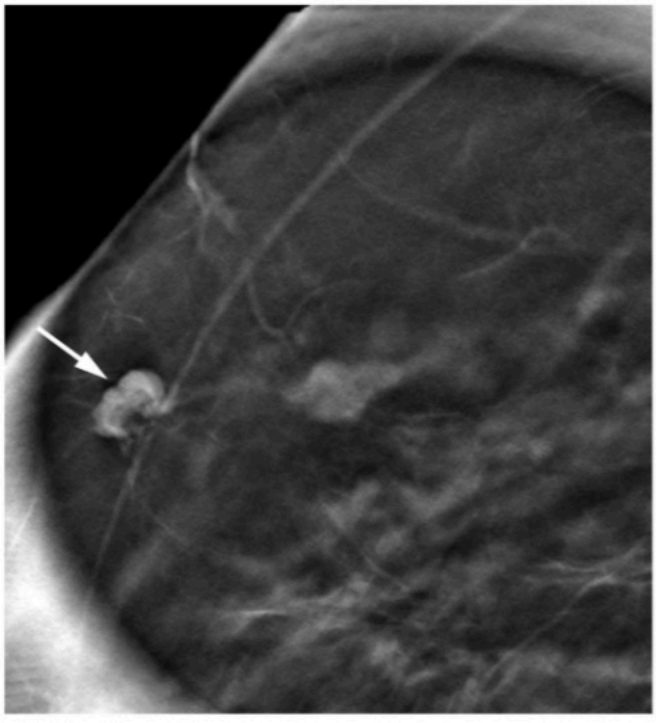

Figure 1 – NORMAL INTRAMAMMARY LYMPH NODE (arrow) with fatty hilum depicted tangentially (DBT).

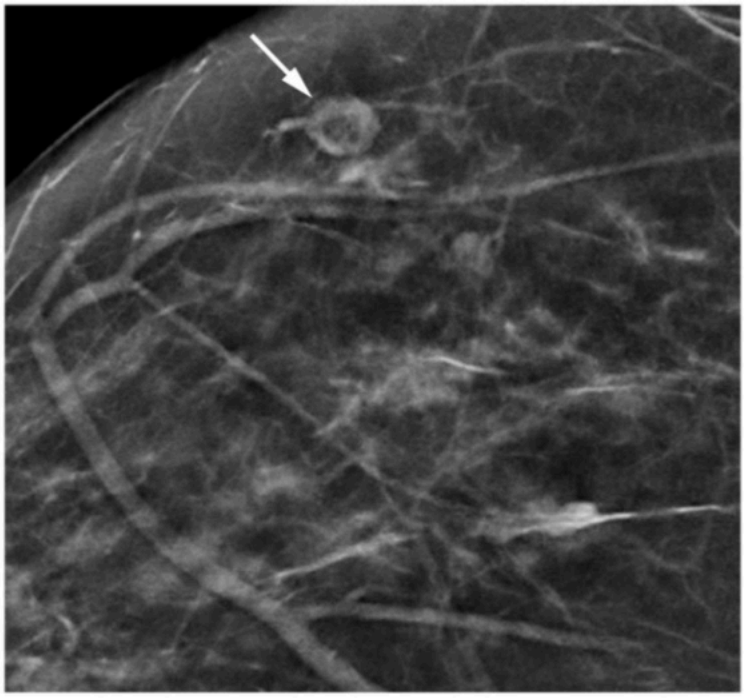

Figure 2 – NORMAL INTRAMAMMARY LYMPH NODE with fatty hilum depicted *en face* (arrow) (SM).

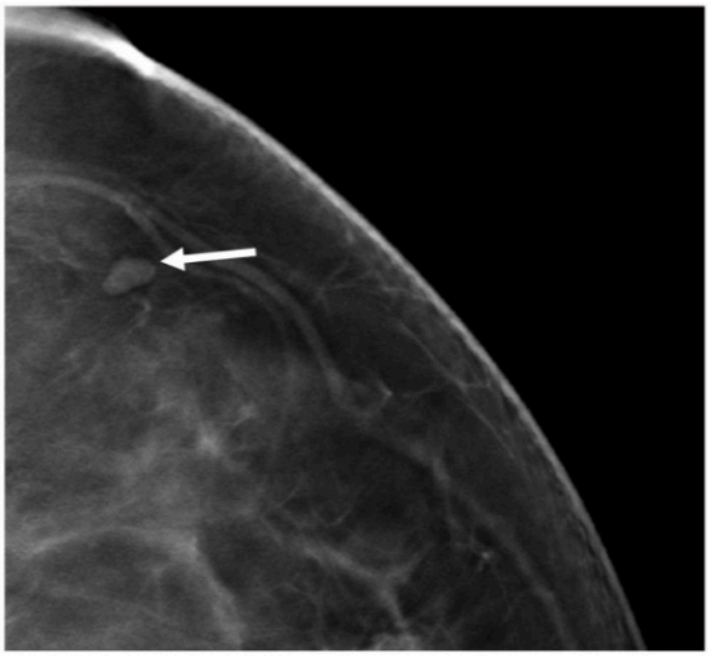

Figure 3 – NORMAL INTRAMAMMARY LYMPH NODE (arrow) (SM).

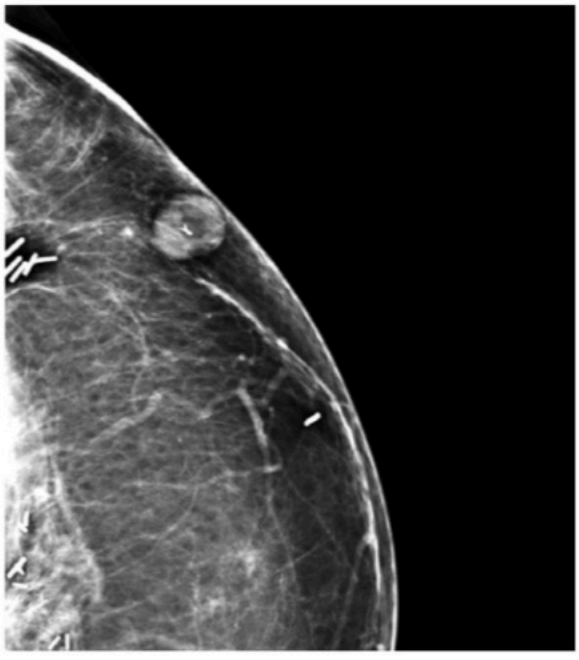

Figure 4 – ABNORMAL INTRAMAMMARY LYMPH NODE (DM). The lymph node in lateral left breast in a patient with prior breast conserving therapy was larger than on prior exams and has lost its reniform shape. Because of these changes, it underwent US-guided core biopsy. A tissue maker lies in the lymph node. Pathology: Recurrent invasive ductal carcinoma in an intramammary lymph node.

E. LYMPH NODES

2. AXILLARY LYMPH NODES

Axillary lymph nodes are usually visible on the MLO view and typically drain the lateral breast and upper extremity.

a. Normal axillary lymph nodes show circumscribed margins and fatty hila. While a specific cortical thickness threshold has not been defined for mammography, normal axillary nodes generally show uniformly thin (albeit subjectively assessed) cortices. Lymph node length is not an independent determinant of suspicion. Further evaluation with ultrasound is warranted for indeterminate findings.

b. Abnormal axillary lymph node morphology includes high radiodensity, non-reniform shape, loss of fatty hilum, increased cortical thickness that may be focal, the presence of calcifications, interval enlargement over baseline, or, uncommonly, indistinct margins. They can occur with a variety of benign and malignant etiologies. The 3 mm cortical thickness that may be used with ultrasound as a threshold for suspicion is not validated for mammography.

There has been an increase in visualization of enlarged axillary lymph nodes on mammography related to the COVID-19 or other vaccinations. Auto-immune disorders and infections can also be associated with abnormal lymph nodes. Review of the patient's medical record may reveal a benign cause for adenopathy. Assessing symmetry in relation to the contralateral axilla is an important part of the evaluation, as bilateral adenopathy is more likely to be reactive or inflammatory. However, if an appropriate history to account for adenopathy is not confirmed, diagnostic evaluation may be warranted to rule out underlying malignancy, including non-breast malignancies.

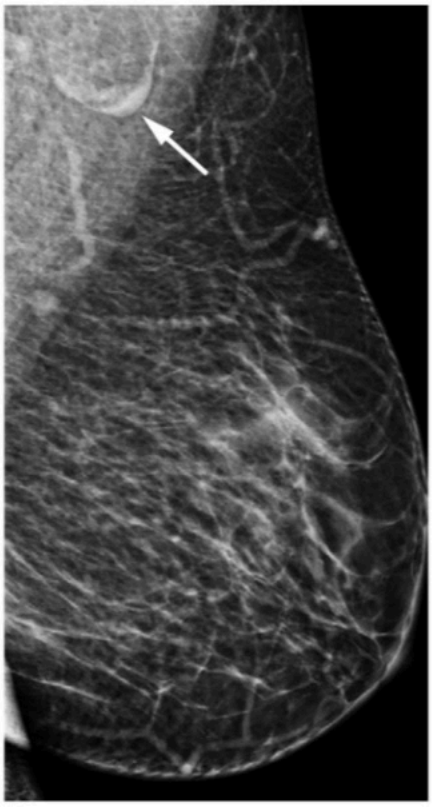

Figure 1 – NORMAL AXILLARY LYMPH NODE (SM) (arrow). While the node is large in overall size, it displays a thin cortex and fatty hilum.

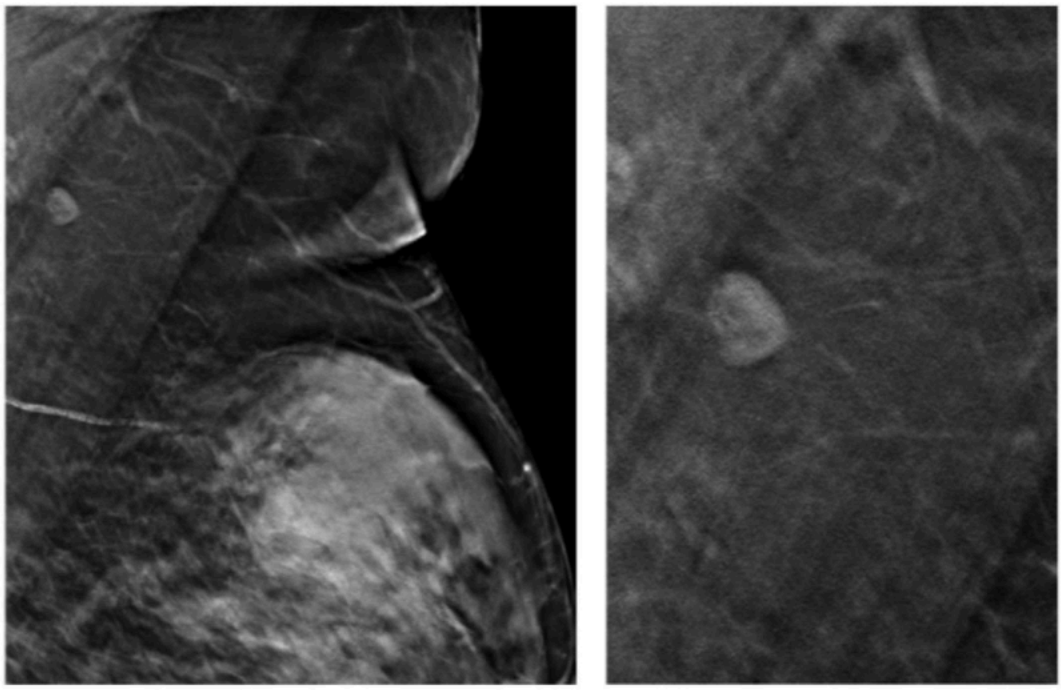

A B

Figure 2 – NORMAL AXILLARY LYMPH NODE (A) SM and (B) DBT (detail image).

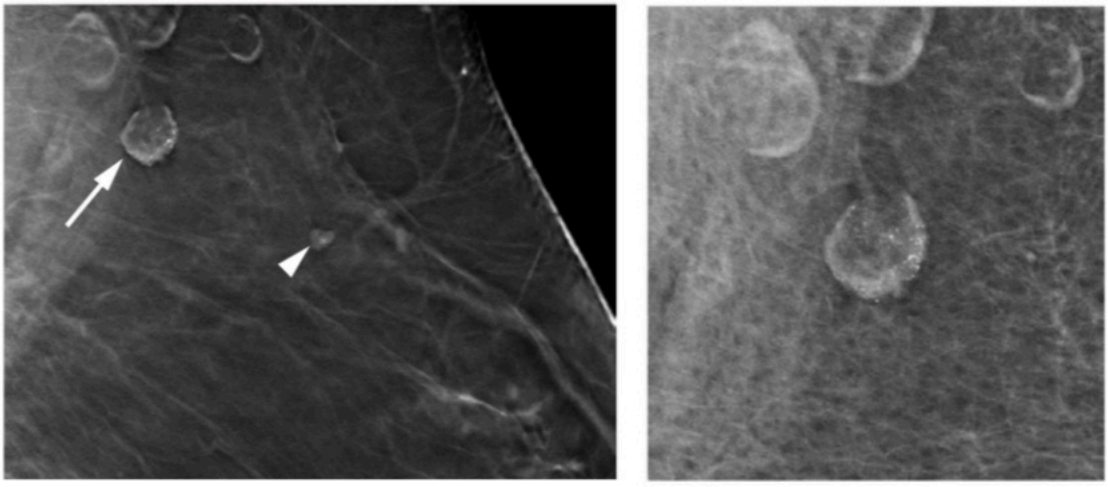

A B

Figure 3 – AXILLARY LYMPH NODES, one containing calcifications (arrow). (A) DBT and (B) DM (detail image). Although the visualized axillary lymph nodes show normal cortical thickness and preservation of the fatty hila, the presence of calcifications, especially if non-coarse, may signal pathology. Note the incidental normal intramammary lymph node lying in axillary tail region (arrowhead). Pathology: Metastatic serous papillary ovarian carcinoma.

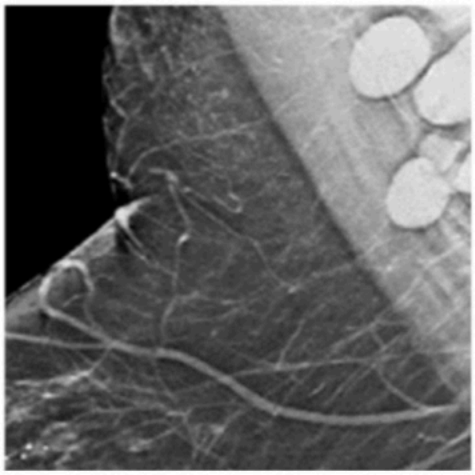

Figure 4 – ABNORMAL AXILLARY LYMPH NODES (SM). Pathology: Reactive follicular hyperplasia.

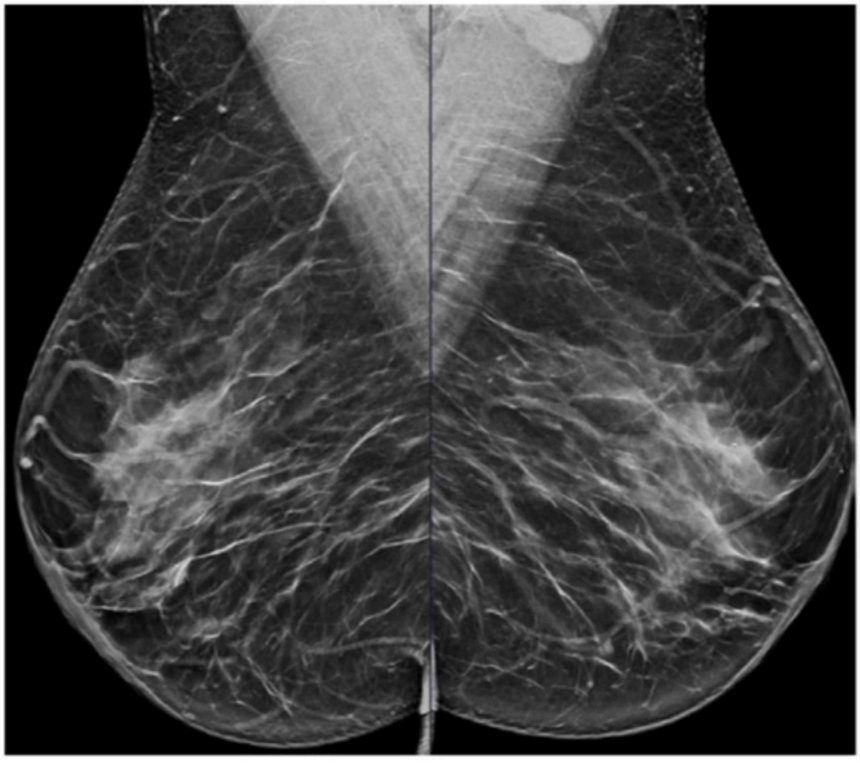

Figure 5 – ABNORMAL LEFT AXILLARY NODES (right image) after COVID vaccination (SM).

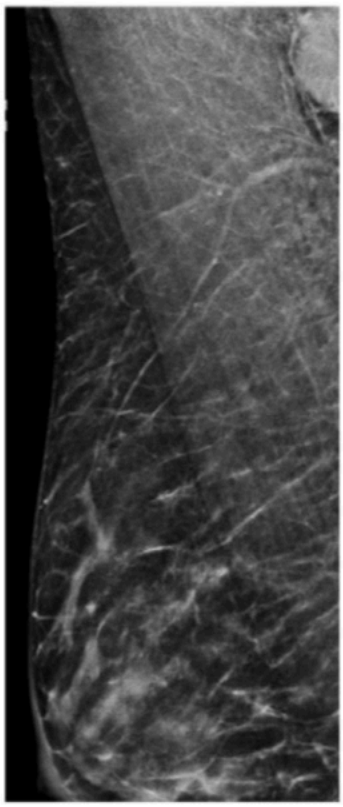

Figure 6 – ABNORMAL AXILLARY LYMPH NODES (SM). Pathology: Follicular lymphoma.

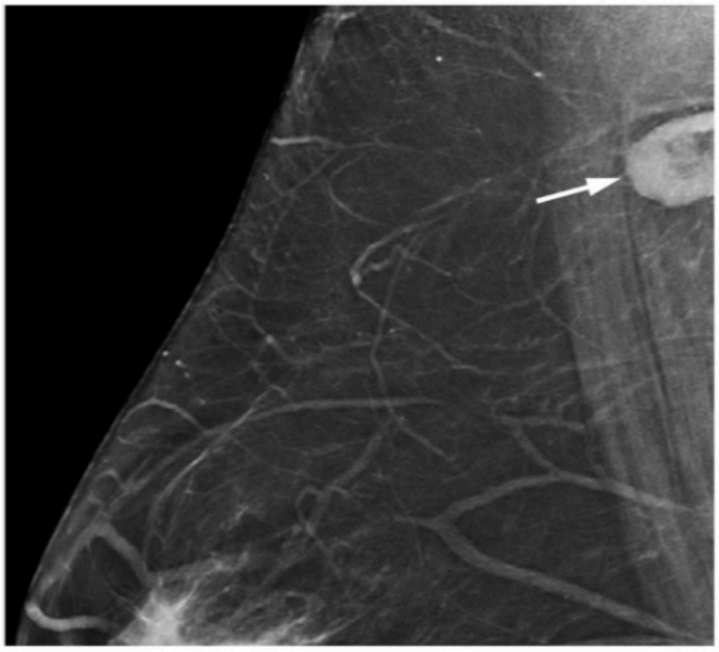

Figure 7 – ABNORMAL AXILLARY LYMPH NODE (SM). This node's cortex shows subtle focal cortical thickening (arrow). Detection of this subtle finding could be facilitated by noting a change from prior studies or its unique appearance compared to other ipsilateral or contralateral nodes. Pathology: Metastatic breast carcinoma.

F. SKIN LESIONS

Skin lesions, including moles, keloids and epidermal inclusion cysts, may be detected on mammography. When visible on the skin surface, they are often marked with a radio-opaque marker by the technologist to avoid confusion with an intramammary mass. Frequently, skin lesions present with a radiolucent halo due to air surrounding the base of the lesion. A skin lesion may be more easily characterizable on DBT due to its location on the first few or last few slices of the imaged breast. Metallic skin markers may cause artifact on DBT. Therefore, some institutions prefer not to mark skin lesions, or non-metallic markers can be used.



Figure 1 – SKIN LESION (SM) (arrow). Note the characteristic radiolucent halo, which represents air at the margin of this raised skin lesion. Mole.

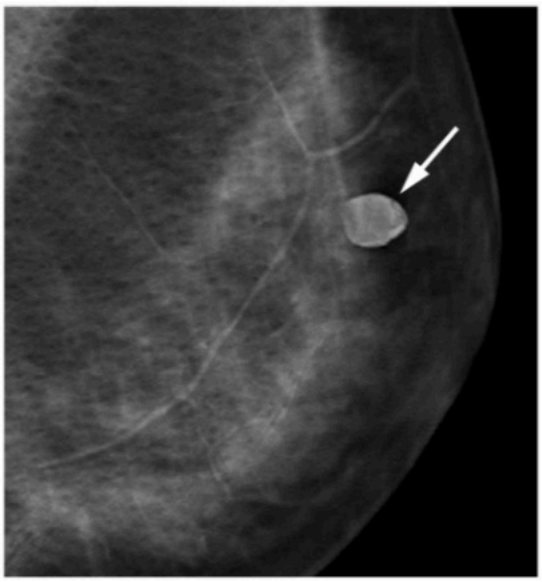

Figure 2 – SKIN LESION (DBT) (arrow). Mole.

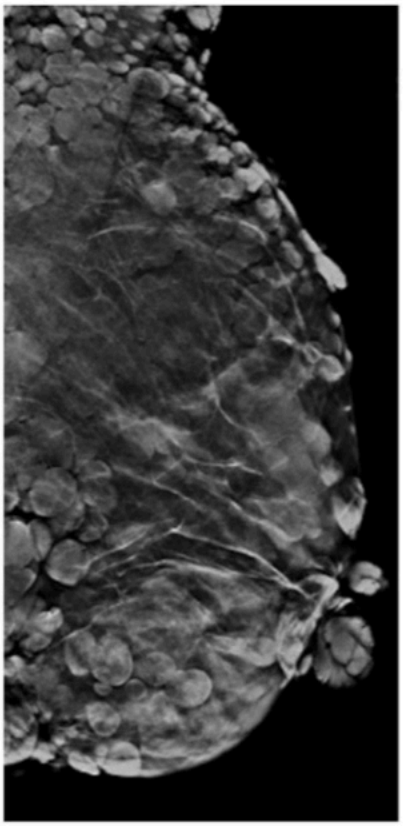

Figure 3 – Innumerable raised SKIN LESIONS (SM). Neurofibromatosis.

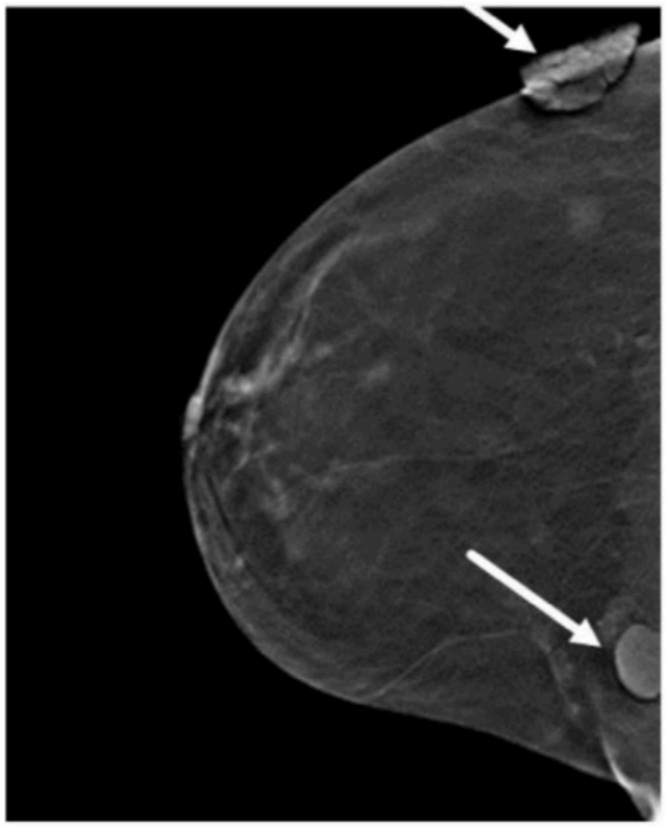

Figure 4 – SKIN LESION (SM) (arrows). Moles.

G. DILATED DUCTS

1. MULTIPLE DILATED DUCTS

Multiple dilated ducts are tubular structures often greater than 5 mm in diameter originating from the nipple that may be unilateral or bilateral. They are typically a benign finding and are commonly seen in patients who are pregnant or lactating. When new, asymmetric, or associated with clinical symptoms or other mammographic abnormalities, further evaluation with diagnostic imaging may be warranted to exclude malignancy [35].

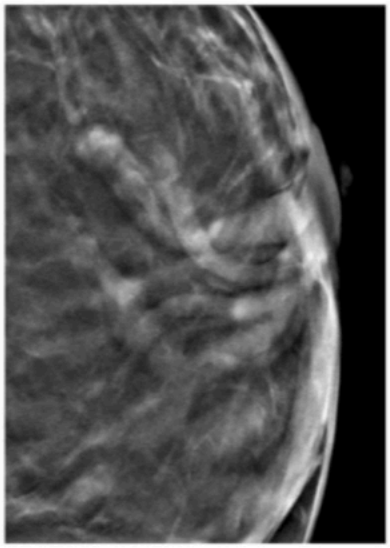

Figure 1 – MULTIPLE DILATED DUCTS converging at the nipple (DBT). Pathology: Duct ectasia.

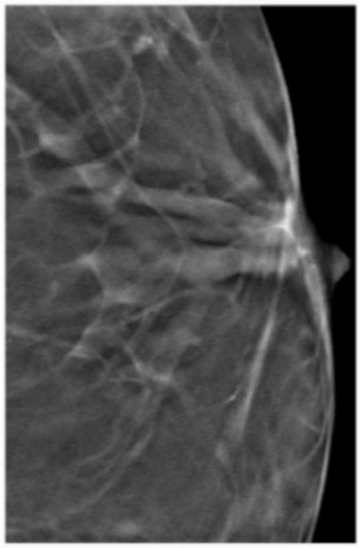

Figure 2 – MULTIPLE DILATED DUCTS (DBT). Pathology: Benign papilloma.

G. DILATED DUCTS

2. SOLITARY DILATED DUCT

A solitary dilated duct (SDD) is a unilateral single or branching tubular structure often greater than 5 mm in diameter that is typically oriented towards the nipple. Solitary dilated ducts are a rare finding at both screening and diagnostic mammography. A solitary dilated duct may be the mammographic presentation for a patient with nipple discharge.

Limited data report that malignancy rates of a solitary dilated duct without other associated clinical or imaging findings are low [36–38]. While the 5th Edition indicated that this finding should be considered a BI-RADS 4A finding, more recent publications suggest that the malignancy rate is sufficiently low to consider a benign assessment if there are no associated clinical or additional imaging findings or change over time. At baseline, or when new or associated with clinical or other mammographic abnormalities, further evaluation with diagnostic imaging may be warranted to exclude malignancy [35, 39].

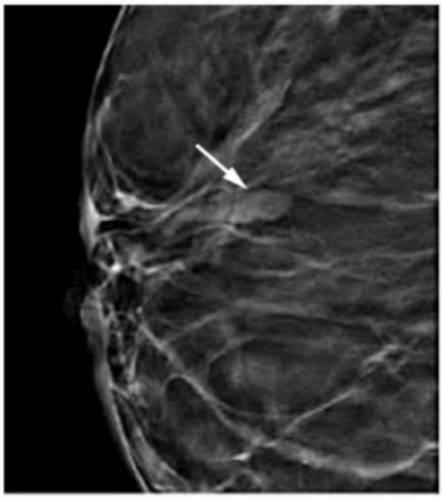

Figure 1 – SOLITARY DILATED DUCT (arrow) (DBT). Stable finding in asymptomatic patient, benign.

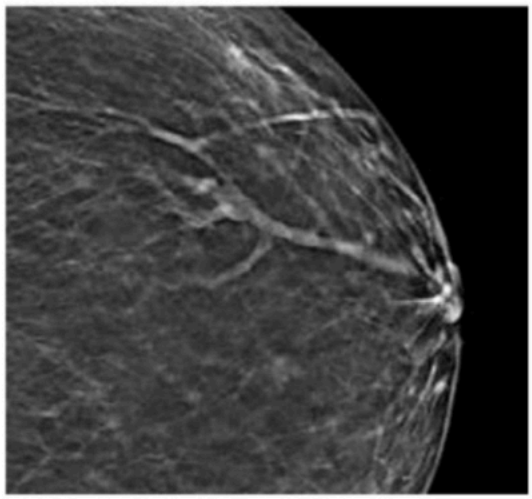

Figure 2 – SOLITARY DILATED DUCT (DBT). Stable finding in asymptomatic patient, benign.

H. ASSOCIATED FEATURES

Associated features are related findings described in the context of a primary breast abnormality. They may also be the presenting finding(s) that prompt(s) work-up for a primary abnormality.

1. SKIN RETRACTION

   In skin retraction, the skin is pulled into the breast in the direction of the primary abnormality. This may manifest as mild skin dimpling or deeper skin indentation on physical examination of the breast. Skin retraction may be normal in the setting of prior surgery.

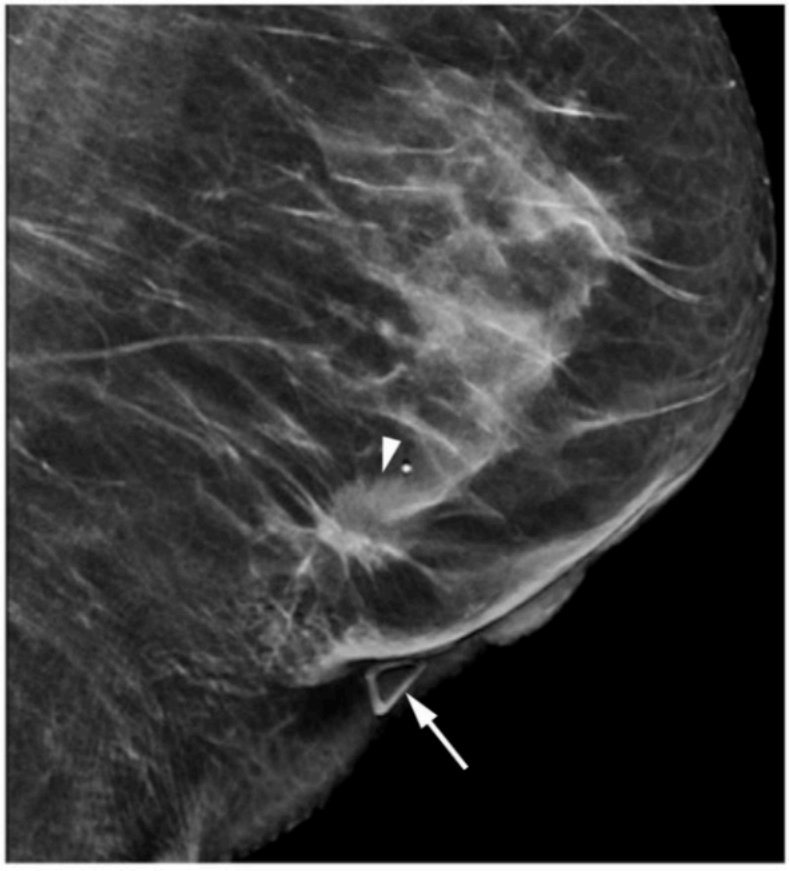

Figure 1 – SKIN RETRACTION (arrow) (SM). Also present is an underlying round spiculated equal-density mass (arrowhead). The mass was palpable, as indicated by the triangular skin marker. Pathology: Invasive ductal carcinoma.

H. ASSOCIATED FEATURES

2. NIPPLE RETRACTION

In nipple retraction, the nipple is pulled inwards even when the patient is appropriately positioned with the nipple in profile. There is increased suspicion for malignancy if nipple retraction is new, unilateral or irreversible. This should be clinically differentiated from nipple inversion, which is inconstant/reversible, often bilateral, demonstrates long term stability, and is usually benign. As with skin retraction, nipple retraction may be normal in the setting of underlying surgical scar.

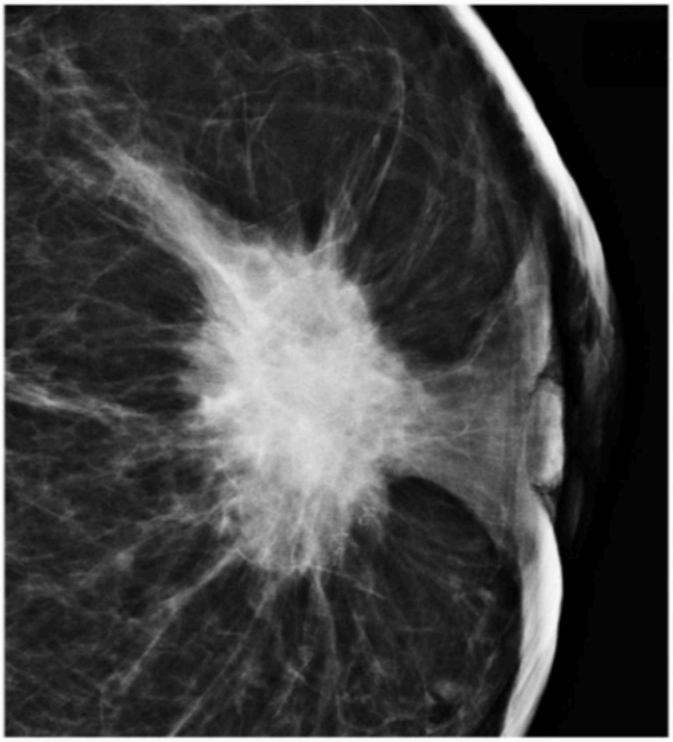

Figure 1 – NIPPLE RETRACTION (SM). Note the underlying high density irregular spiculated mass and associated skin thickening. Pathology: Invasive ductal carcinoma.

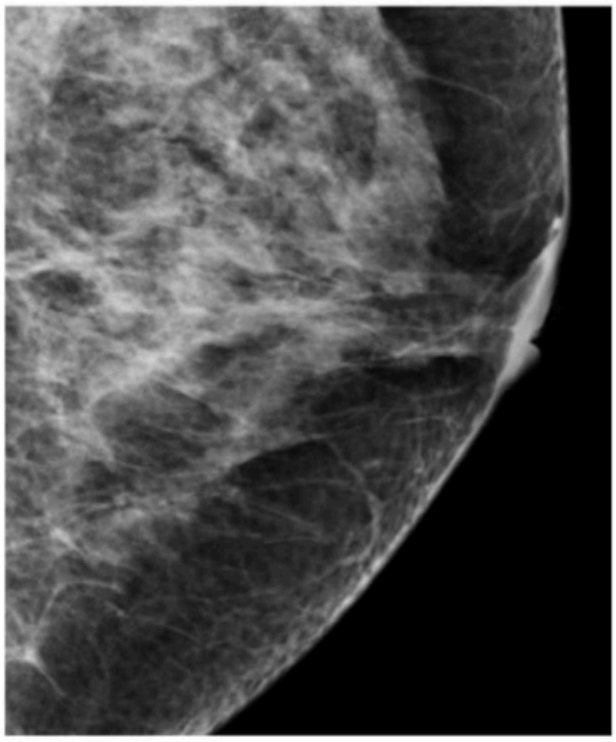

Figure 2 – NIPPLE INVERSION (SM). The nipple is not fully visible, even in this well-positioned MLO view. In this case, the finding was bilateral and stable, in keeping with nipple inversion rather than nipple retraction. Benign etiology.

H. ASSOCIATED FEATURES

3. SKIN THICKENING

Skin thickening (> 2 mm in thickness [40]) may be focal or diffuse. Skin in the nipple areolar complex is normally thicker than the rest of the breast but should be symmetric. Unilateral skin thickening is an expected finding after radiation therapy and generally decreases over time. Bilateral skin thickening is usually benign and due to edema from underlying systemic disease (e.g., renal, hepatic, or cardiac failure). New skin thickening, especially if unilateral and focal, is concerning for malignancy in the absence of a known infectious or benign inflammatory etiology.

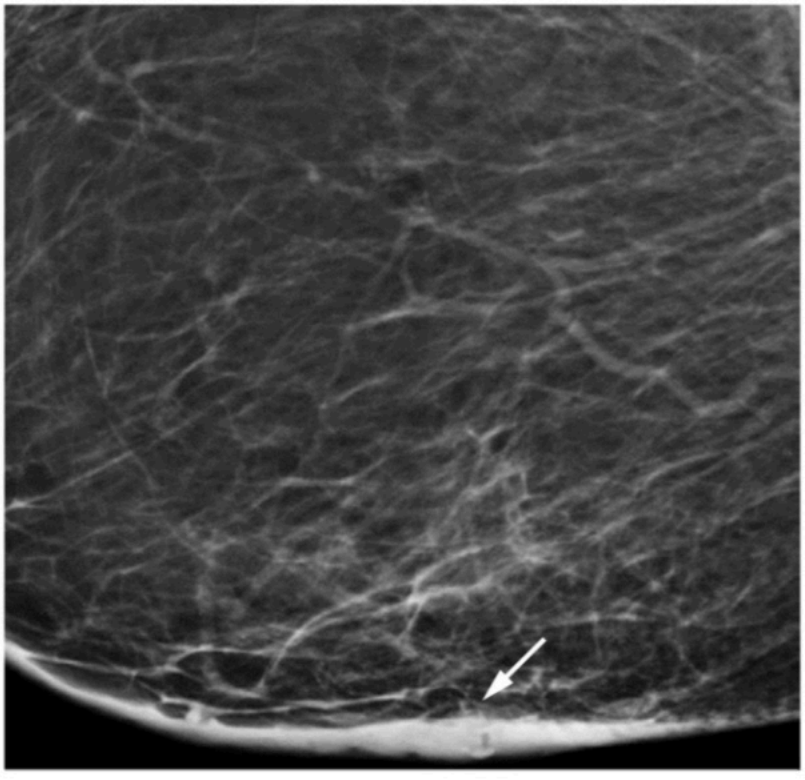

Figure 1 – Focal SKIN THICKENING (arrow) (DM). There is associated underlying trabecular thickening. Pathology: Ruptured epidermal inclusion cyst.

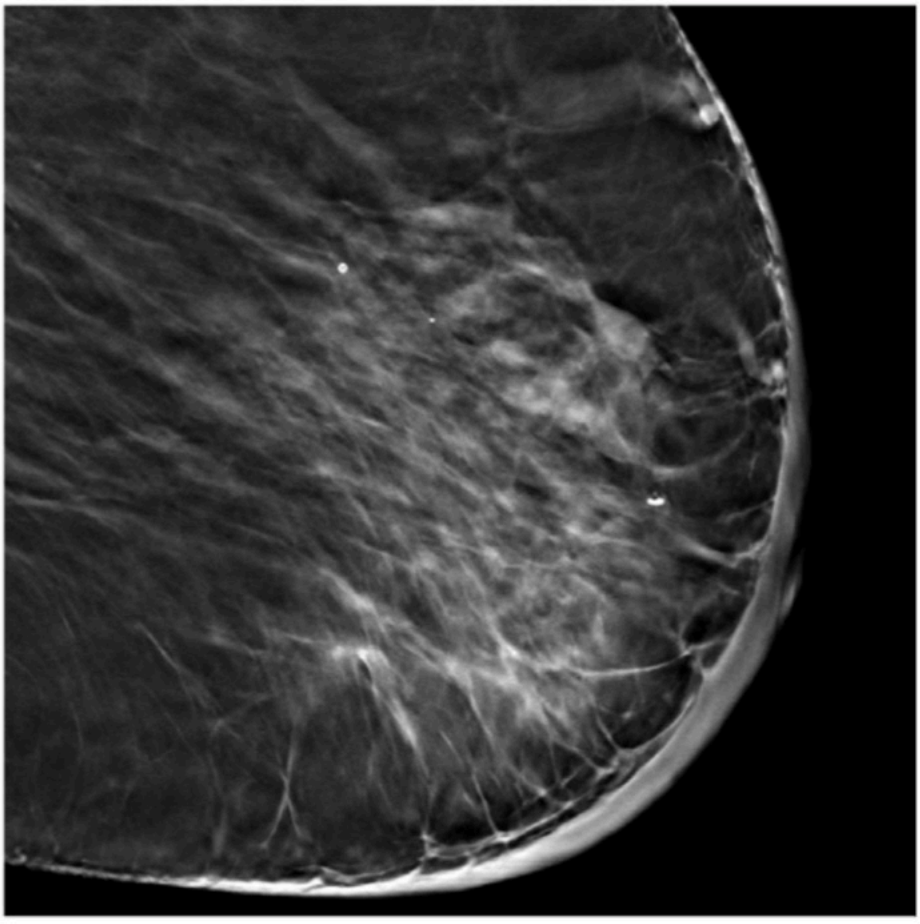

Figure 2 – SKIN THICKENING (DBT). Associated trabecular thickening. This constellation of findings suggests the possibility of inflammatory breast cancer but is non-specific. Pathology: Invasive ductal carcinoma.

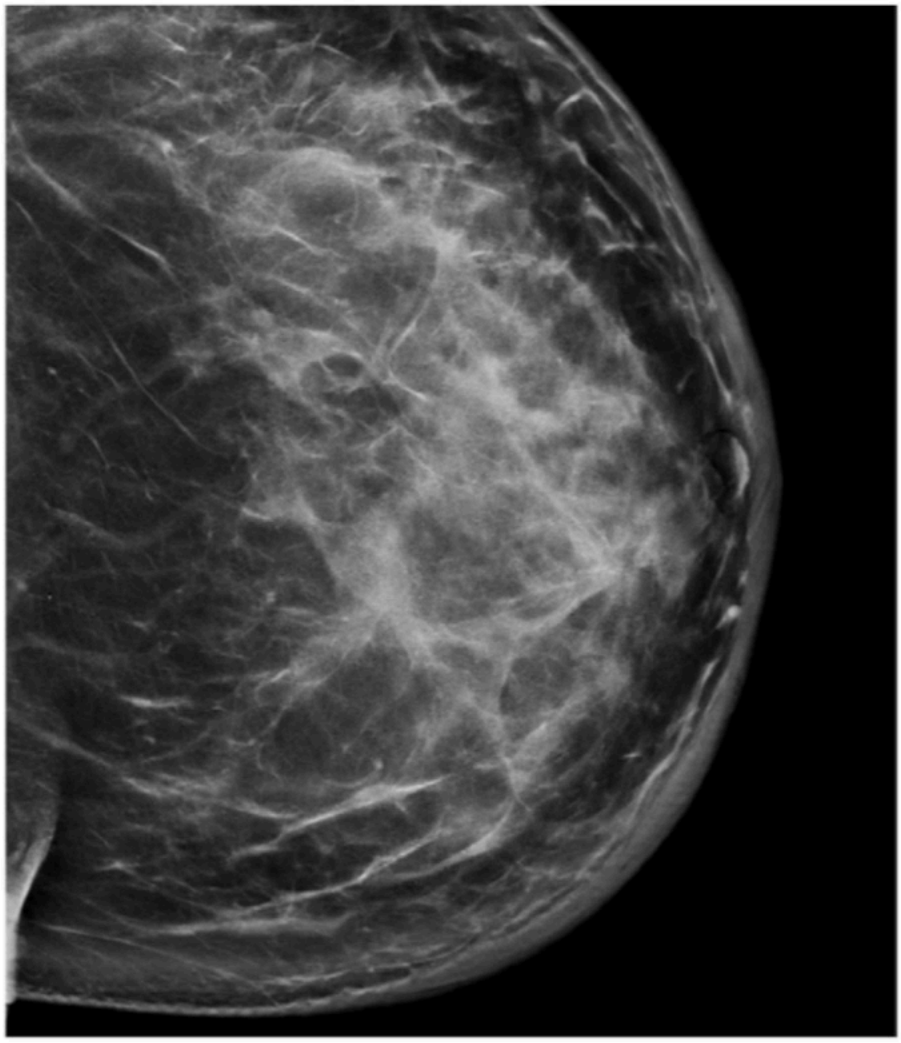

Figure 3 – SKIN THICKENING (SM). Diffuse, with associated trabecular thickening. Mastitis.

H. ASSOCIATED FEATURES

4. TRABECULAR THICKENING

Thickening of the fibrous septa of the breasts may be found in patients with edema due to systemic disease (e.g., congestive heart failure, renal disease) or impaired drainage of the lymphatic system, such as following axillary lymph node dissection. Trabecular thickening can also be seen in patients with extensive axillary metastases or inflammatory breast carcinoma due to tumoral obstruction of the lymphatics.

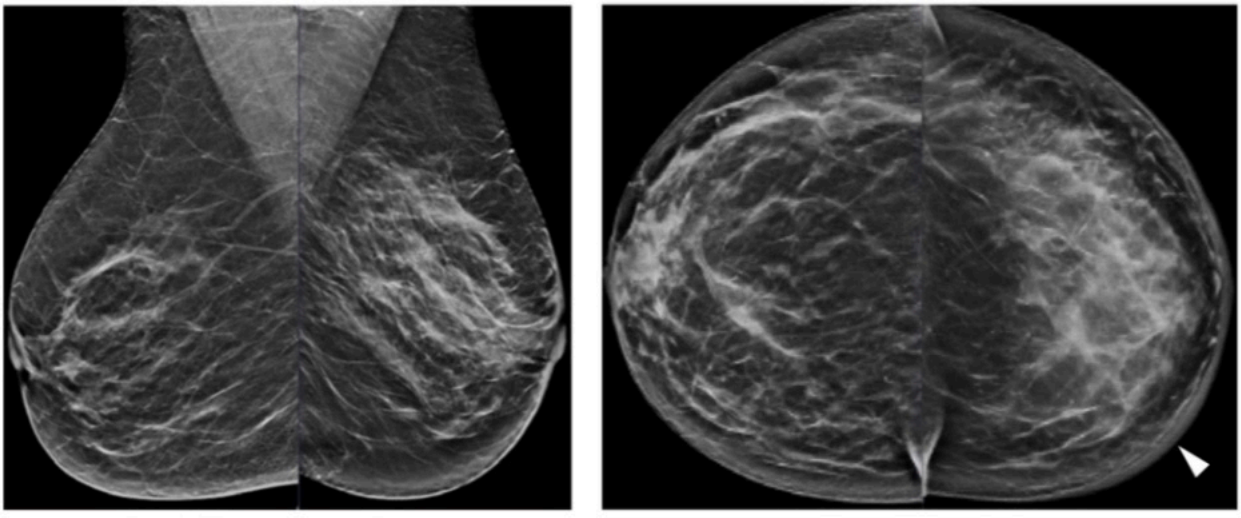

Figure 1 – Left breast diffuse TRABECULAR THICKENING (SM). Skin thickening is noted on the left CC view as well (arrowhead). Mastitis.

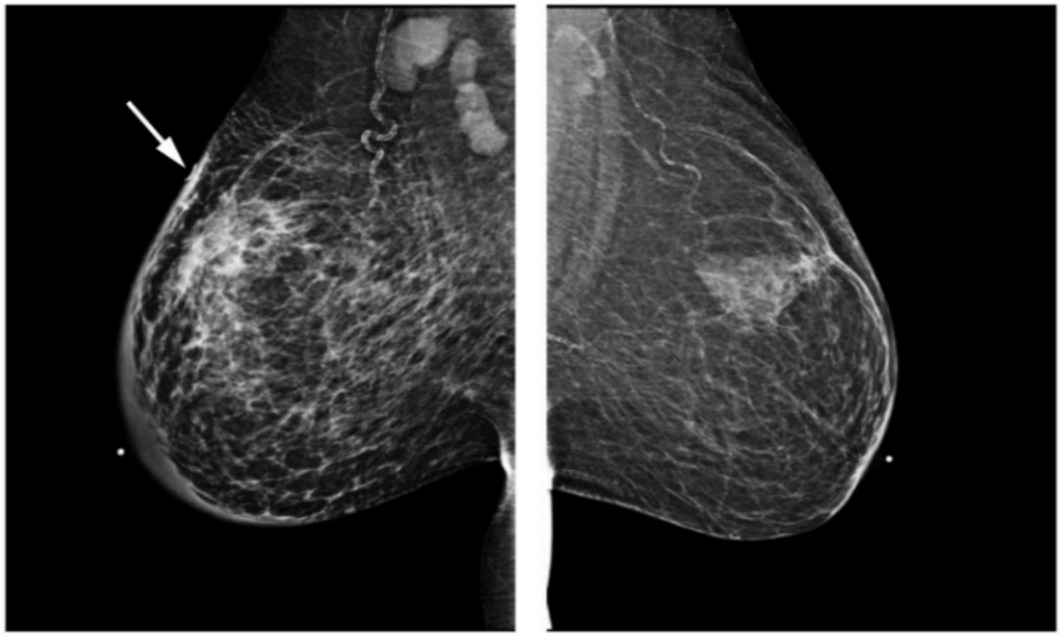

A **B**

Figure 2 – (A) Diffuse right breast TRABECULAR THICKENING with associated skin thickening and axillary adenopathy, as well as a palpable finding in superior breast (triangular marker seen on skin surface (arrow). Left breast (B) appears normal. The imaging findings were consistent with the clinical diagnosis of inflammatory breast cancer (DM). Pathology: Invasive ductal carcinoma.

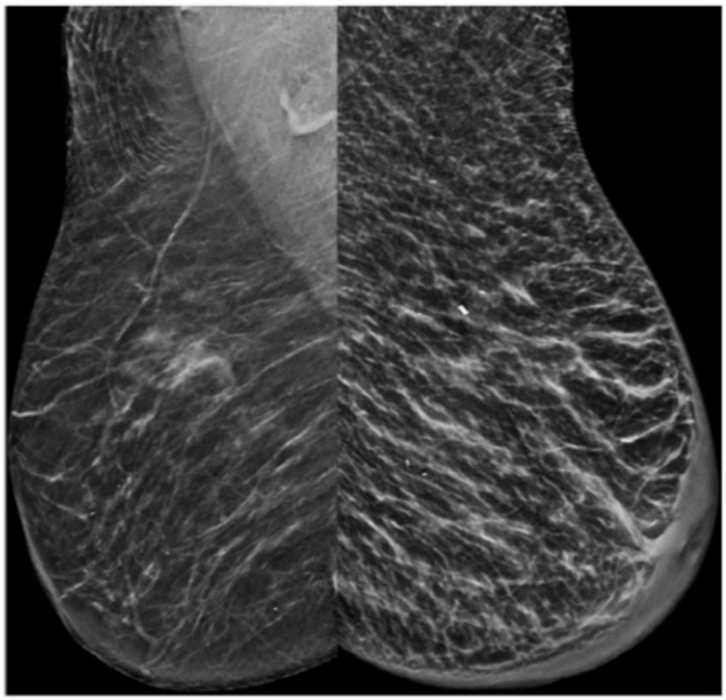

Figure 3 – Left breast TRABECULAR THICKENING and skin thickening (SM). While often bilateral, systemic causes of skin and trabecular thickening may be unilateral. Congestive heart failure.

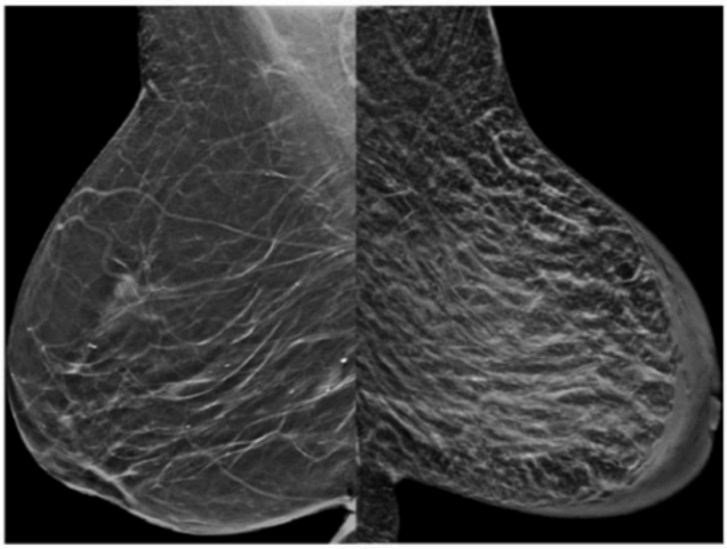

Figure 4 – Left breast TRABECULAR THICKENING and skin thickening (SM). Etiology: Congestive heart failure and renal disease (forearm hemodialysis shunt on the left).

I. SPECIAL CASES

1. GYNECOMASTIA

Gynecomastia is the benign development of breast tissue either unilaterally or bilaterally in the cisgender male patient. There are numerous potential causes of gynecomastia. Gynecomastia is commonly the result of alterations in hormone levels due to physiologic status in adolescents or older patients. Anti-depressants, prostate cancer medications, steroids, antibiotics, chemotherapy, or certain types of cardiovascular medicines may contribute to gynecomastia, as can marijuana, methamphetamines, alcohol, and heroin. Alternatively, systemic disease processes such as liver failure, kidney disease, lung cancer, testicular cancer, thyroid disorders and tumors of the adrenal and pituitary glands can also stimulate the development of breast tissue [41]. Patients may present with a tender palpable abnormality in the subareolar region of one or both breasts. In men with clinical findings consistent with gynecomastia or pseudogynecomastia (i.e., breast enlargement in men primarily due to fatty tissue but with no associated glandular or stromal tissue) no imaging is routinely recommended. Hormone-induced breast tissue occurring in transfeminine patients should not be characterized as gynecomastia.

On mammography, breast density should be documented in male patients similar to female patients. Breast density is assigned based on the densest portion of the breast tissue, indicating the potential of obscuring a malignancy, using accepted BI-RADS terminology. There are no well-established or validated descriptors of the extent of gynecomastia. Radiologists may report a qualitative assessment of the pattern of gynecomastia (e.g., nodular, dendritic, diffuse; see examples in Figure 1) although data on patient outcomes are currently lacking. Other findings such as calcifications, masses, asymmetries or distortions should be described if present as these entities are not typically associated with gynecomastia and will likely require further evaluation.

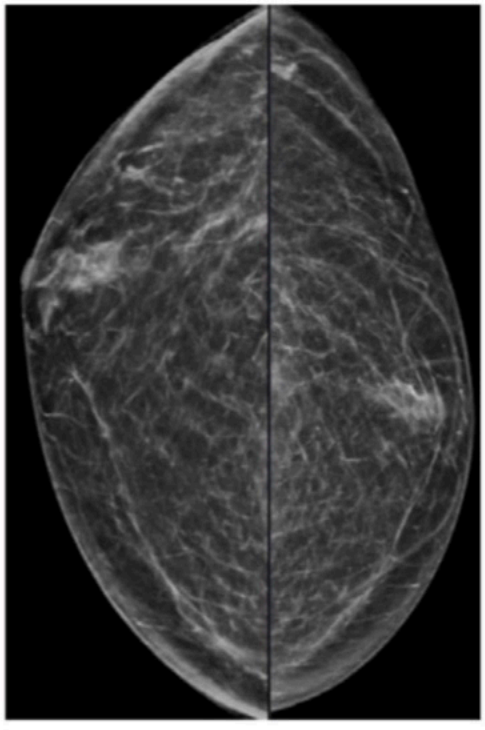

Figure 1 – Nodular GYNECOMASTIA (SM).



Figure 2 – Dendritic GYNECOMASTIA (SM).

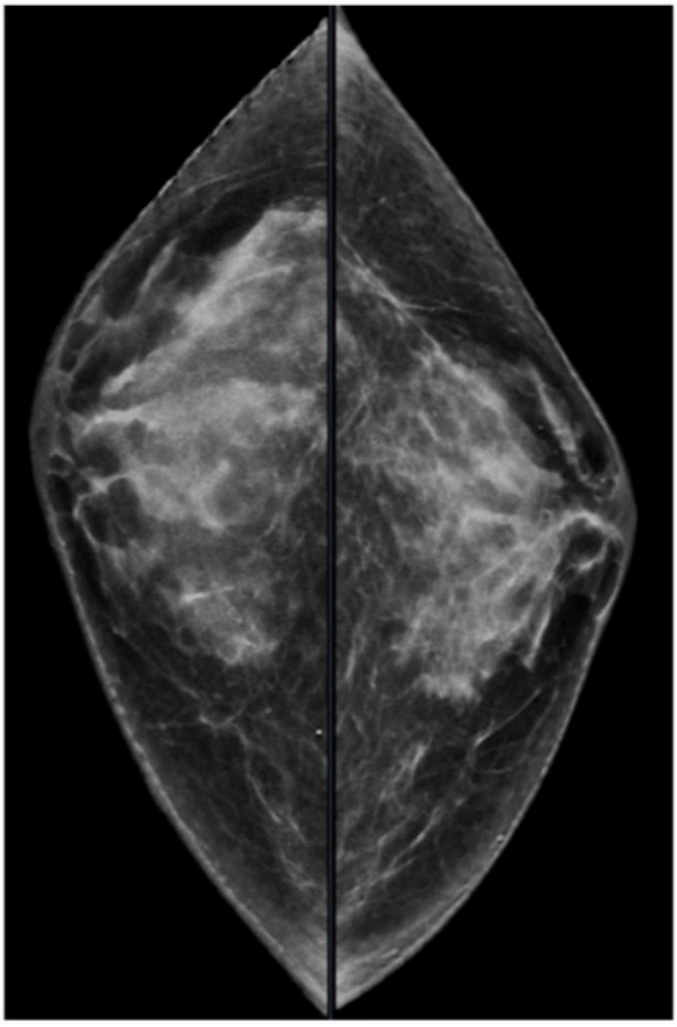

Figure 3 – Diffuse GYNECOMASTIA (SM).

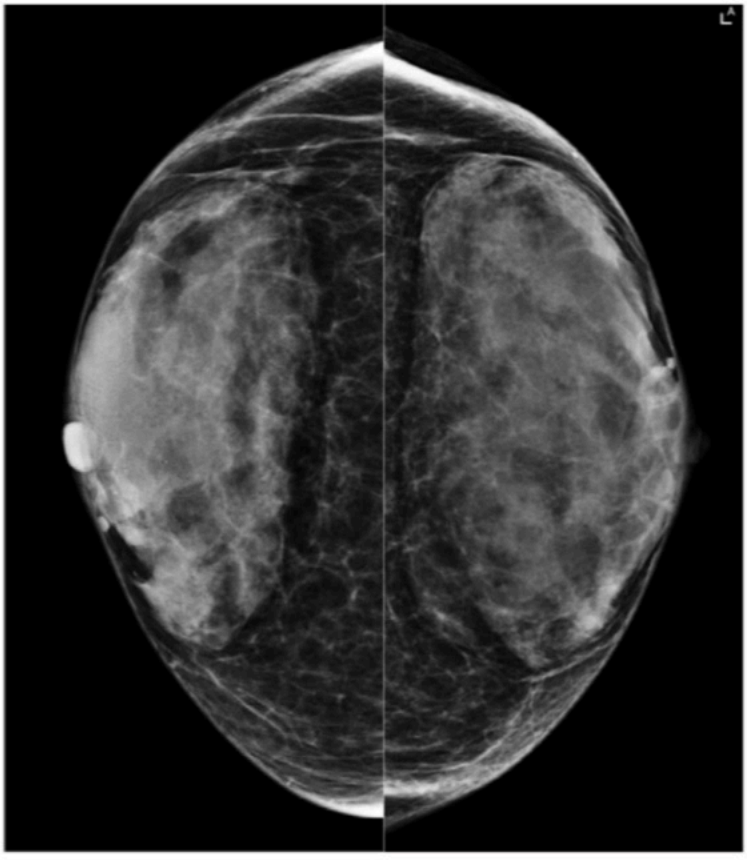

Figure 4 – Diffuse GYNECOMASTIA (SM).



Figure 5 – Asymmetric GYNECOMASTIA (SM).

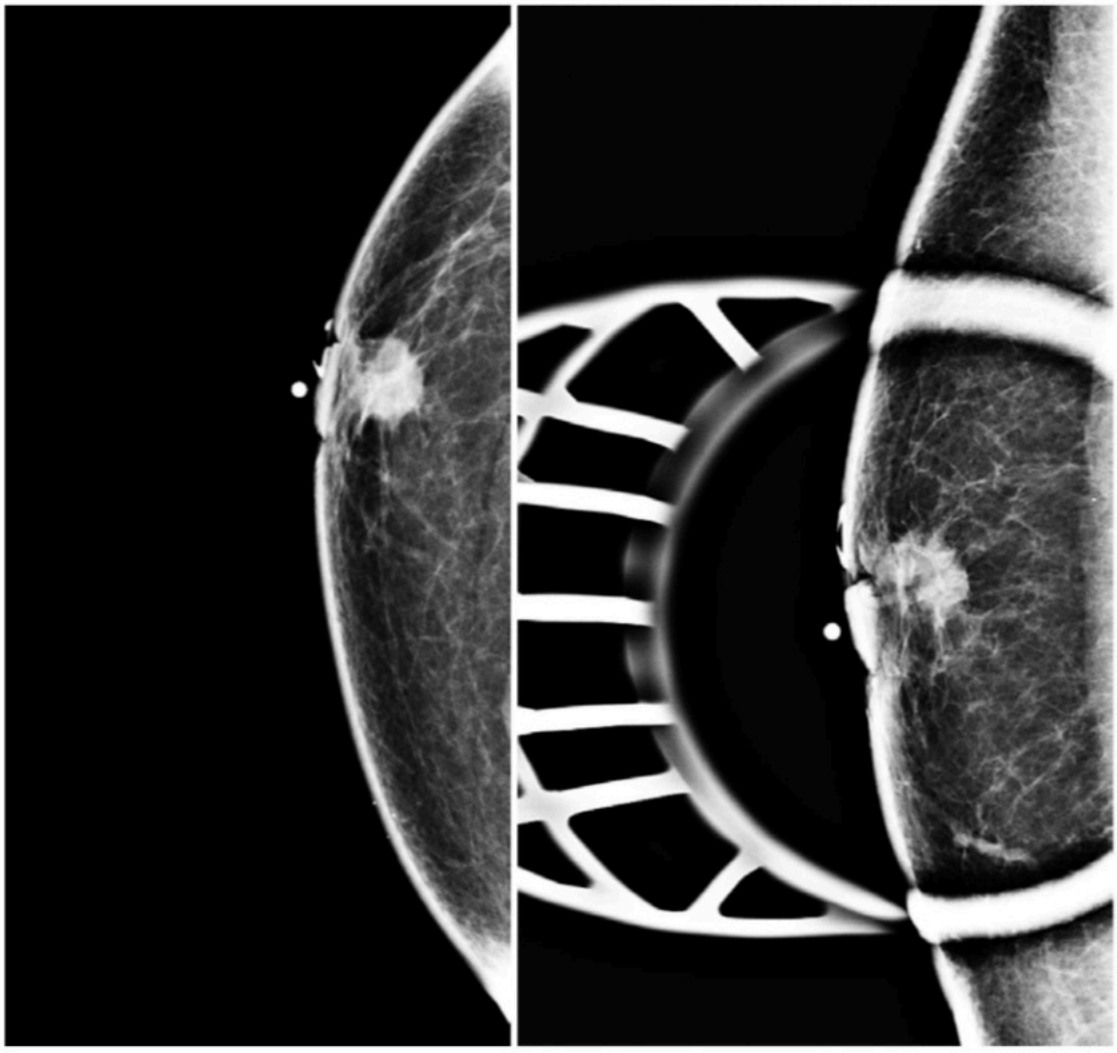

Figure 6 – Example of male breast cancer, NOT gynecomastia (DM). Upon diagnostic imaging evaluation of this palpable finding, it was determined to be an irregular spiculated mass. There is associated nipple retraction. Close inspection of all imaging features can help prevent inadvertent dismissal of a suspicious finding as gynecomastia. Pathology: Invasive ductal carcinoma.

I. SPECIAL CASES

2. IMPLANTS AND OTHER FORMS OF AUGMENTATION

Breast implants are routinely encountered in mammography. The type (e.g., saline, silicone, or dual lumen) and location (e.g., retropectoral or pre-pectoral [historically retroglandular]) should be included in the report as well as a description of the views obtained (e.g., routine and implant-displaced views). Additionally, in the case of silicone breast implants, commenting on evidence of extracapsular rupture is recommended along with a description of the location of the extracapsular silicone deposits. Occasionally, free silicone, paraffin and other materials may be directly injected into the breast and create a characteristic mammographic appearance of fatty round deposits (paraffin) or dense deposits (silicone), with or without rim calcification.

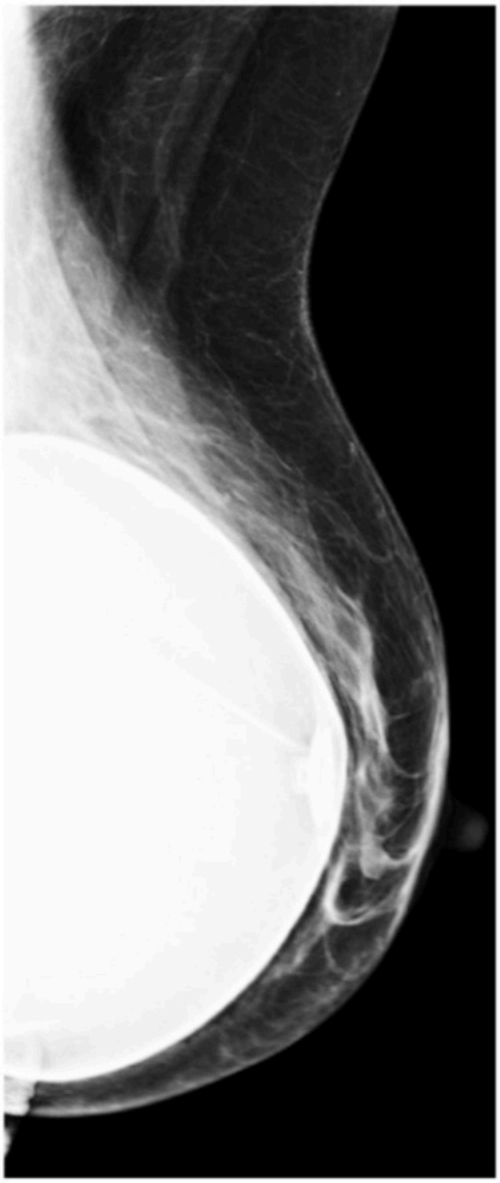

Figure 1 – Saline IMPLANT, RETROPECTORAL (SM). This saline implant is less dense than a silicone implant would be.



Figure 2 – Silicone IMPLANT, PRE-PECTORAL (DM).

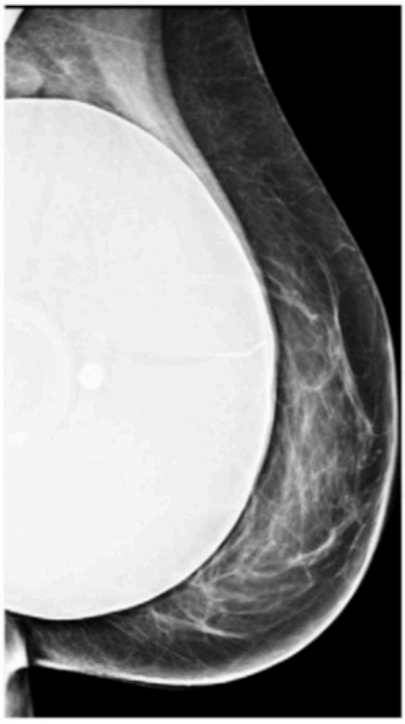

Figure 3 – Saline IMPLANT, RETROPECTORAL (SM).

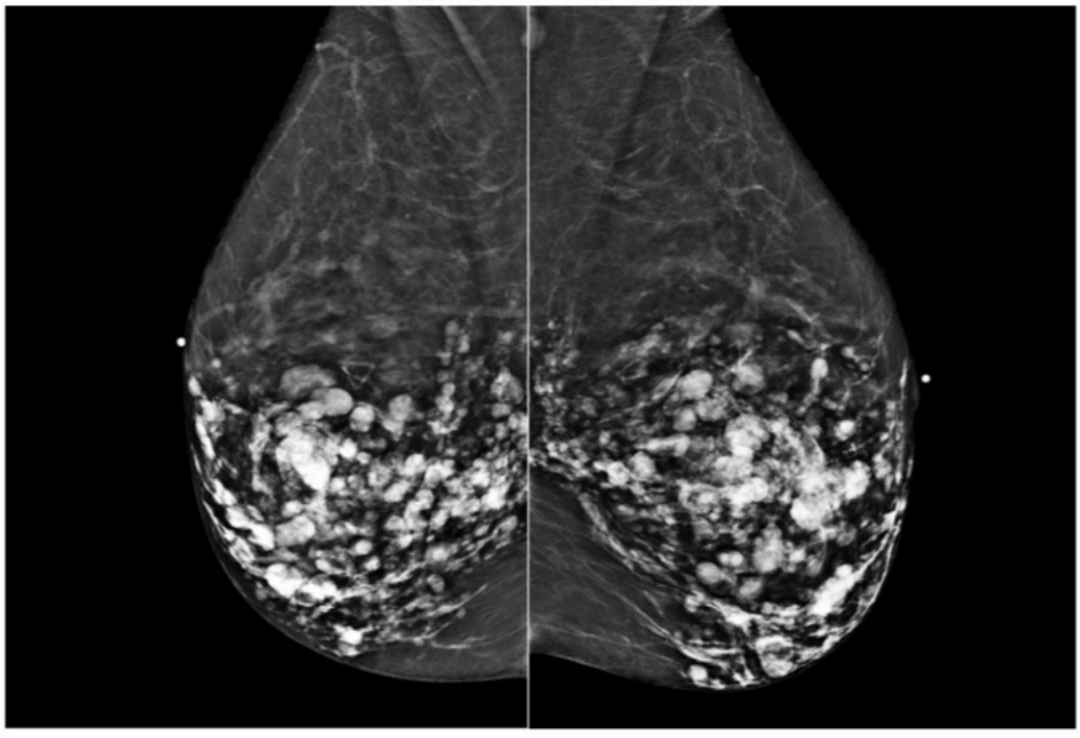

Figure 4 – Free injection of silicone (DM).

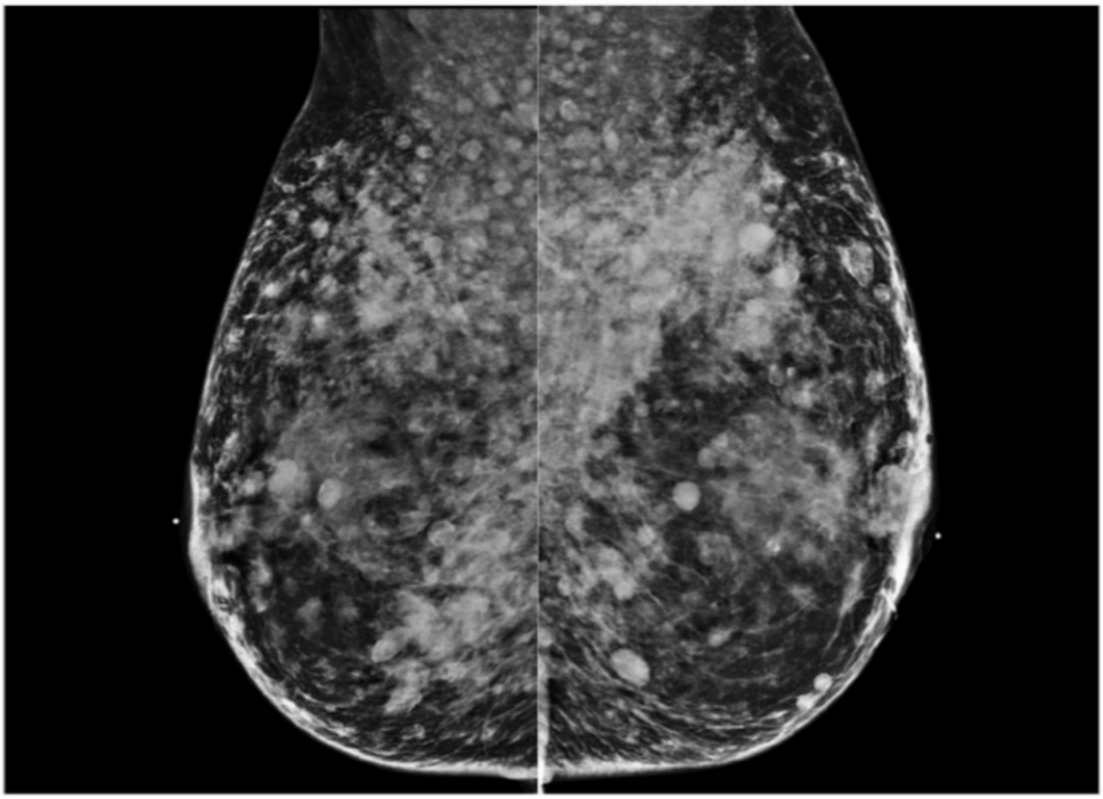

Figure 5 – Free injection of silicone (DM).

I. SPECIAL CASES

3. MASTECTOMY

Although ipsilateral mammography after mastectomy is usually not indicated, imaging of the reconstructed breast or mastectomy site may be required to evaluate a clinical finding (i.e., a palpable finding). As with any mammographic report, breast density should be recorded in the mastectomy patient. When only the mastectomy side is imaged, breast density should be assigned based on the tissue present. Usually, the tissue is almost entirely fatty and therefore BI-RADS breast composition category A is appropriate. However, occasionally some breast tissue remains (e.g., skin-sparing mastectomies and subtotal mastectomies) and therefore denser breast composition categories may be appropriate. It is often difficult to image a mastectomy patient due to the minimal amount of residual tissue, especially in patients without reconstruction. Therefore, only limited views of the area of concern (e.g., spot tangential) may be obtained. These mammographic views can be critical as benign fat necrosis is a common finding in mastectomy patients. On ultrasound, fat necrosis may appear as an irregular, shadowing, suspicious mass and result in an unnecessary biopsy if the mammographic view is not obtained.



Figure 1 – MASTECTOMY pre-pectoral silicone implant (SM). Breast Density: Almost entirely fatty.

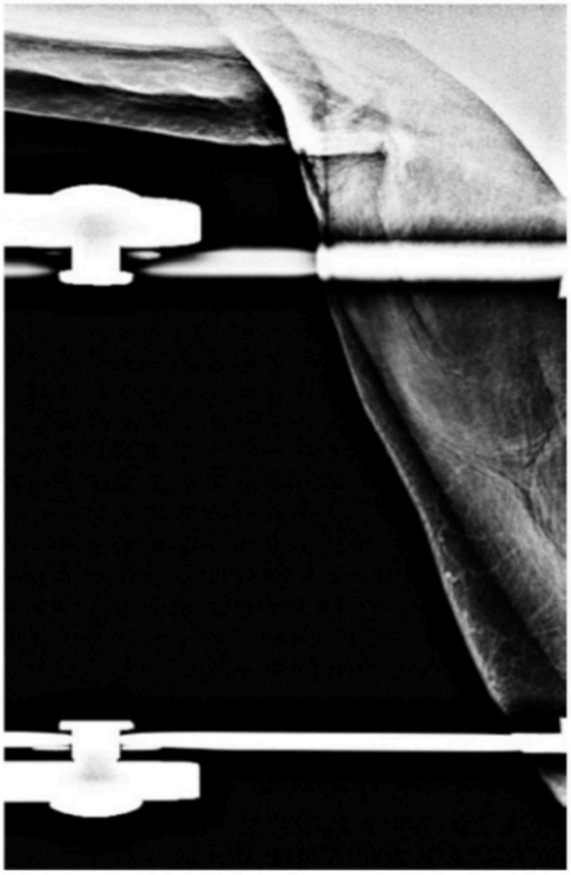

Figure 2 – MASTECTOMY (DM). Spot tangential view of area of pain. Breast Density: Almost entirely fatty.

J. LOCATION OF FINDING

The location of a salient finding should be described to facilitate easy identification in the future and correlation with clinical findings. The laterality of the finding as left or right should always be reported. The position of the finding within the breast should be described by quadrant and/or clock face. For findings seen on only one view, it may not be possible to provide this level of precision. For findings seen predominantly on DBT, the slice number should be provided for all views to ensure that the finding can be accurately reidentified prior to further imaging. Depth or distance from the nipple to the center of the finding should be reported. If the finding is large, distance to its anterior and posterior extents can be included. Also, it may be helpful to describe the anatomic zone where the finding lies to facilitate lesion identification when correlating among modalities. For example, noting that a mass lies at the subcutaneous fat-fibroglandular zone junction may allow easier search and more confident identification when ultrasound evaluation is undertaken.

Finding location should be described by laterality first, followed by clock face and/or quadrant, and then depth or distance from the nipple. The following are examples of a finding location description:

Right breast, upper outer quadrant, anterior depth
Left breast, 3:00, 5 cm from the nipple

Slice #20, MLO

LOCATION OF FINDING

1. LATERALITY

   Laterality indicates the right or left breast.

2. LOCATION IN BREAST AS QUADRANT OR CLOCK FACE

   Quadrant and/or clock face should be reported. Quadrants refer to smaller sub-divisions of the breast, including upper outer, upper inner, lower outer, and lower inner portions of the breast. Some additional location descriptors that do not conform to a quadrant include central (deep to the nipple on all views, middle to posterior depth), retroareolar (deep to the nipple on all views, anterior depth), axillary tail (upper outer quadrant adjacent to axilla), and axilla. Clock face is oriented based on the patient facing the observer and should be specified using a whole number. For example, 3:00 is in the lateral left breast and the medial right breast. For some large one-view findings, it may not be possible to specify a quadrant or clock face. In these situations, a hemisphere descriptor should be used: upper, lower, inner, or outer.

3. DEPTH or DISTANCE FROM THE NIPPLE

   Describe the location based on depth (anterior, middle, posterior) or distance from the nipple in whole centimeters (e.g., 2 cm from the nipple, not 2.3 cm from the nipple). Using smaller distance increments implies a higher level of precision than is possible across readers and modalities. If findings are between whole cm locations, the closest whole cm location should be selected and used.

   Measure the distance from the nipple from the base of the nipple to the center of the finding, on the same image if both are visible. If the finding is close to the nipple, it is important to describe how far the anterior extent of the imaging finding is from the nipple to assist with surgical planning. If the finding is large, distance to its anterior and posterior extents can also be included, to assist with surgical planning. If the findings are close to the skin, pectoralis muscle or chest wall, describe the distance of the findings to these structures.

Due to differences in patient positioning and other technique factors, distance from the nipple, skin, pectoralis muscle and chest wall may vary across modalities.

It may be helpful to describe the anatomic zone where the finding lies to facilitate lesion identification when correlating among modalities. For example, noting that a mass lies at the subcutaneous fat-fibroglandular zone junction may allow for more efficient search and more confident identification when ultrasound evaluation is undertaken.

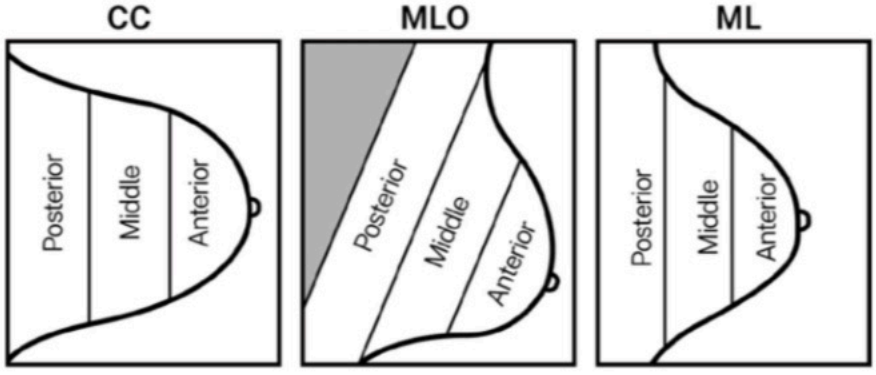

Figure 1 – Depth diagrams.

V. REPORTING SYSTEM

A. ASSESSMENT CATEGORIES

Table 4. Concordance Between BI-RADS® Assessment Categories and Management Recommendations

Assessment	Management	Likelihood of Cancer
Category 0: Incomplete: Need Additional Imaging Evaluation OR Category 0: Incomplete: Need Prior Mammograms for Comparison	Recall for additional imaging Need comparison to prior examination(s)	N/A
Category 1: Negative	Routine mammography screening	Essentially 0% likelihood of malignancy
Category 2: Benign	Routine mammography screening	Essentially 0% likelihood of malignancy
Category 3: Probably Benign	Short-interval (0 to 6-month) follow-up or continued surveillance (12-month)	> 0% but ≤ 2% likelihood of malignancy
Category 4: Suspicious Category 4A: *Low suspicion* for malignancy Category 4B: *Intermediate suspicion* for malignancy Category 4C: *High suspicion* for malignancy	Tissue diagnosis	> 2% but < 95% likelihood of malignancy > 2% to ≤ 10% likelihood of malignancy > 10% to ≤ 50% likelihood of malignancy > 50% to < 95% likelihood of malignancy
Category 5: Highly Suggestive of Malignancy	Tissue diagnosis	≥ 95% likelihood of malignancy
Category 6: Known Biopsy-Proven Malignancy	Clinical follow-up with surgeon and/or oncologist, and definitive local therapy (usually surgery) when clinically appropriate	N/A

a. Mammographic Assessment is Incomplete

Amendments to the MQSA regulations, which took effect on Sept. 10, 2024, resulted in the creation of two new assessment categories under category 0 (replacing the previous combined descriptive verbiage of "Category 0: Incomplete: Need additional imaging evaluation and/or prior imaging for comparison"). The two new categories are: **Category 0: Incomplete: Need additional imaging evaluation**, used to indicate that the examination is incompletely evaluated, and the recommendation is for additional imaging evaluation (i.e., supplementary mammographic views and/or US); and **Category 0: Incomplete: Need prior mammograms for comparison**, to be used if retrieval of previous examinations for comparison is indicated before a final assessment can be rendered.

A category 0 "Incomplete: Need additional imaging evaluation" assessment is almost always used in a screening situation to indicate an abnormal screening examination that is not definitively negative (category 1) or benign (category 2). This reflects the binary nature of screening assessments (positive versus negative) and management recommendations (routine screening versus prompt action). Even when a suspicious abnormality is clearly demonstrated on a screening examination, a category 0 assessment should be used, indicating the need for a complete diagnostic examination to more accurately evaluate the extent of potential disease prior to biopsy. The use of category 0 assessments for all abnormal screening examinations emphasizes that the abnormal interpretation rate should reflect even those screening examinations with findings sufficiently abnormal to justify tissue diagnosis. Once the diagnostic imaging is completed, a final assessment is rendered for the diagnostic examination, but the screening mammography examination remains assessed as category 0.

When feasible, especially if a mammography examination is not assessed as negative or benign, it is recommended that the current examination be compared with prior examination(s), which decreases the frequency of recall [42, 43]. Therefore, assessment category 0 "Incomplete: Need prior mammograms for comparison" should be used for previous image comparison only when such comparison is required to make a final assessment. Most frequently, this involves examinations on which a probably benign finding could be dismissed as benign by the demonstration of stability.

Mammography facilities utilizing a category 0 "Incomplete: Need prior mammograms for comparison" assessment when awaiting prior mammograms should have a tracking procedure in place guaranteeing with 100% reliability that a final assessment will be made within 30 days (preferably sooner), even if prior examinations do not become available. Some mammography practices may reasonably choose never to use category 0 in the context of awaiting prior examinations if they do not have a 100% reliable tracking procedure and rather elect to hold the case for reporting until it is determined if prior exams can be made available. If an "Incomplete: Need prior mammograms for comparison" report is issued while awaiting prior examinations, an addendum to the initial mammography report should be released once prior examinations become available, and the incomplete assessment replaced by a final assessment once the comparison is made. Proper procedures for the auditing of category 0 assessments are described in detail in the Auditing and Outcomes Monitoring section of the Manual. Under rare circumstances, this assessment category may be used in a diagnostic mammography report if the diagnostic evaluation was not fully completed (e.g., a patient electively leaves a facility prior to completing the mammographic views or diagnostic ultrasound). A recommendation for additional imaging evaluation may include the use of spot compression or magnification or other special mammographic views, and/or ultrasound. Category 0 should generally not be used for diagnostic breast imaging findings that warrant further evaluation with MRI. Rather, the interpreting physician should issue a final assessment in a report that is made before the MRI examination is performed. Specifically, category 0 should not be used in cases of a negative or benign mammogram where the interpreting physician

desires the physiologic information afforded by breast MRI due to breast density (e.g., supplemental screening) or clinical symptomology (e.g., suspicious nipple discharge). In these cases, a category 1 or 2 should be given as the mammography assessment, with the discordant management recommendation for breast MRI. Additionally, a category 0 assessment recommending MRI should not be given for further evaluation of findings already deemed suspicious on mammography as a way to potentially defer biopsy. These cases should be assessed as suspicious and given category 4 or 5.

B. Mammographic Assessment is Complete — Final Assessment Categories

Category 1: Negative

This is a normal examination.

Category 2: Benign

Similar to category 1, this is a normal assessment, but the interpreting radiologist chooses to describe a benign finding in the mammography report. Involuting calcified fibroadenomas, skin calcifications, metallic foreign bodies (e.g., core biopsy and surgical clips), and fat-containing masses (e.g., oil cysts, lipomas, galactoceles, and hamartomas) all have characteristically benign appearances and may be described with confidence. The interpreting radiologist may also choose to describe intramammary lymph nodes, vascular calcifications, implants, or architectural distortion clearly related to prior surgery while still concluding that there is no mammographic evidence of malignancy. However, the interpreter may choose not to describe such findings, in which case the examination should be assessed as negative (category 1).

Category 3: Probably Benign

A finding assessed using this category should have a ≤ 2% likelihood of malignancy, but greater than the essentially 0% likelihood of malignancy of a characteristically benign finding. A category 3 assessment should not be given on a screening examination but only after complete diagnostic imaging evaluation. Rendering category 3 assessments directly from screening examination has been shown to result in adverse outcomes: 1) unnecessary follow-up of many findings that could have been promptly assessed as benign, and 2) delayed diagnosis of a small number of cancers that otherwise may have been smaller in size and less likely to be advanced in stage if confirmed on diagnostic evaluation of an equivocal screening finding [44]. A probably benign finding is not expected to change over the suggested period of imaging surveillance, but the interpreting physician needs to establish stability of the finding before recommending routine mammography screening, as there is a small possibility of malignancy. A BI-RADS category 3 assessment is not an indeterminate category used when the radiologist is simply unsure whether to render a benign (BI-RADS category 2) or suspicious (BI-RADS category 4) assessment, nor should this category be used "to wait and see what happens."

There is robust literature describing three findings seen on **baseline** mammography followed by diagnostic work-up that have likelihoods of malignancy in the category 3 assessment range [45–47]. These are a (1) solitary noncalcified circumscribed solid mass, (2) focal asymmetry without an ultrasound correlate, and (3) solitary group of round calcifications. Assessment category 3 for mammographic findings other than these three should be considered only in situations where the radiologist has knowledge and personal experience with a sufficient number of cases to suggest that watchful waiting may be justified (e.g. equivocal calcifications developing at the site of prior surgery felt to be evolving fat necrosis, focal asymmetry at the site of recent trauma) [44].

The use of a probably benign assessment for a palpable lesion with probably benign features is supported by several small, retrospective, single-institution studies that report successful

outcomes for palpable lesions with probably benign imaging features [48–52]. Finally, because evidence from previously cited studies indicates the need for biopsy rather than continued surveillance when a probably benign finding increases in size or extent [45–47], it is generally not recommended to render a category 3 assessment when a finding that otherwise meets "probably benign" imaging criteria is either new or has substantially increased in size or extent.

For category 3 assessments, the initial short-term follow-up interval is usually 6 months, involving the breast(s) containing the probably benign finding(s). A follow-up interval of less than 6 months is typically reserved for cases of infection, inflammation, or trauma, where changes on imaging are expected and often a definitive BI-RADS 2 assessment could be rendered. Assuming stability at this 6-month examination, a category 3 assessment again will be rendered with a management recommendation for a second short-interval follow-up examination in 6 months but now involving both breasts if the opposite breast is due for routine annual screening. Again, assuming stability at this second short-interval follow-up, the examination is once more assessed as category 3, but now the recommended follow-up interval is generally lengthened to 1-year due to the already observed 12-month stability. Note that although the 1-year follow-up coincides with the routine screening interval in the United States, a category 3 assessment still should be rendered to indicate that the period of continued mammographic surveillance is still underway, and that diagnostic rather than screening mammography is indicated. After 2 years of stability, the final assessment category should be changed to benign (BI-RADS category 2) [50].

If during the course of surveillance the probably benign finding decreases in size or disappears, or now displays definitively benign characteristics, then the appropriate assessment would become benign (BI-RADS category 2) or negative (BI-RADS category 1), with return to a routine screening schedule. Alternatively, if the finding becomes more suspicious during the surveillance cycle, it should be assessed as a BI-RADS category 4 or 5, and biopsy should be pursued immediately.

One may encounter the scenario in which the patient or referring clinician requests that a probably benign finding be biopsied. In this scenario, the correct approach is to render a probably benign (BI-RADS category 3) assessment with a concordant management recommendation for short-interval or surveillance mammography, but to follow this with a sentence indicating that tissue diagnosis will be performed instead, due to patient or referring clinician preference.

Category 4: Suspicious

A category 4 assessment is used for findings that are sufficiently suspicious to warrant tissue diagnosis but not pathognomonic for cancer. According to BI-RADS definitions expressed in terms of likelihood of malignancy, category 4 findings have a > 2 but $< 95\%$ chance of malignancy. As established in the BI-RADS 5th Edition, the management recommendation "biopsy should be performed in the absence of clinical contraindication" unequivocally specifies tissue diagnosis as the interpreting physician's management recommendation and allows the referring provider and patient to discuss any medical concerns or contraindications to biopsy.

Many institutions have subdivided category 4 into low suspicion (4A), moderate suspicion (4B), and high suspicion (4C) to account for the wide range of findings subjected to interventional procedures and corresponding broad range of likelihood of malignancy. This allows a more meaningful practice audit, is useful in research involving receiver operating characteristic (ROC) curve analysis, and is an aid for patients, clinicians, and pathologists to more readily make informed decisions on the ultimate course of action. The subdivisions of category 4 are discussed in more detail in the Guidance section.

Category 5: Highly Suggestive of Malignancy

A category 5 assessment is given when the likelihood of malignancy is estimated to be ≥ 95%. This assessment was established at a time when surgical excision was used as the primary means of tissue diagnosis. Category 5 assessments were used for those findings that had such characteristic features of cancer (such as an irregular, spiculated, high density mass with associated microcalcifications or new fine linear and branching calcifications in a segmental distribution) that one-stage surgical treatment might be performed immediately following frozen-section histological confirmation of malignancy. Today, breast cancer diagnosis for imaging-detected findings almost always involves percutaneous tissue sampling, so the current rationale for using a category 5 assessment is to identify findings for which any nonmalignant percutaneous tissue diagnosis is typically considered discordant, resulting in the recommendation for repeat (usually surgical) biopsy. Note that there is no single mammographic feature that is associated with a likelihood of malignancy of ≥ 95%. Just as for breast US and MRI examinations, a combination of suspicious imaging features is required to justify a category 5 assessment.

As for category 4, the management recommendation for category 5 assessments ("biopsy should be performed in the absence of clinical contraindication") unequivocally specifies tissue diagnosis as the interpreting physician's management recommendation.

Category 6: Known Biopsy-Proven Malignancy

A category 6 assessment category is used when breast imaging is performed after a tissue diagnosis of malignancy but prior to definitive local therapy (usually surgery, but this could include other local treatments considered definitive by the multidisciplinary team), and there are no additional or new mammographic abnormalities other than the known cancer that need evaluation. Category 6 is the appropriate assessment prior to definitive local therapy, when providing second opinion review of previously biopsied findings already shown to be malignant, after attempted complete removal of the target lesion by percutaneous core biopsy (but before definitive local therapy), and for the monitoring of response to neoadjuvant chemotherapy.

Category 6 should also be used for breast imaging examinations performed after attempted complete surgical excision when the pathology report indicates positive resection margins **and** there is at least one mammographic feature suggestive of residual tumor. The purpose of breast imaging in this situation is not to determine whether re-excision is needed but to indicate the specific location of any area(s) suspicious for a residual tumor that should be included in planned re-excision. If there are no mammographic findings other than those indicating postsurgical change, a benign (BI-RADS category 2) assessment should be rendered, supplemented by a sentence stating that the pathology report indicates positive margins suggesting residual tumor despite the absence of a mammographic correlate.

The use of category 6 is not appropriate for breast imaging examinations performed in surveillance follow-up of prior surgical excision of a malignancy (lumpectomy) when the pathology report indicated no tumor at the margins of resection. If a post-lumpectomy examination demonstrates surgical scarring but no visible malignancy, the appropriate assessment is benign (BI-RADS category 2). If a suspicious finding warranting tissue diagnosis is seen, a BI-RADS category 4 assessment should be given.

Breast imaging is often performed following completion of neoadjuvant systemic treatment prior to definitive local therapy. In this case, a category 6 assessment should be given, even if all mammographic findings of the cancer have resolved, because definitive local therapy (typically surgery) has not been performed. If the post-neoadjuvant therapy imaging study demonstrates a suspicious finding besides the known cancer, then a category 4 or 5

assessment should be rendered. The use of a category 3 (probably benign) assessment is not recommended in individuals with known cancer, as stability cannot be assessed due to ongoing treatment. To allow for complete determination of disease extent prior to treatment and given the higher PPV of additional findings in the situation of a known index cancer, ipsilateral or contralateral findings that might otherwise be assigned a BI-RADS 3 category can be assessed as BI-RADS 4 with a recommendation for biopsy.

For category 6 assessments, the management recommendation "appropriate clinical follow-up with surgeon and/or oncologist" implies surgical excision as eventual management while considering the clinical reality that the timing of excision (when clinically appropriate) will be determined by someone other than the interpreting radiologist. This recommendation does not take into account novel alternative management strategies, like non-surgical treatment or active surveillance of low-risk DCIS [51–53], because these management strategies have not yet been validated.

Note that, as described in the Auditing and Outcomes Monitoring chapter, examinations with a category 6 assessment should not be included in breast imaging audits. Because the diagnosis of malignancy already has been established, inclusion of these cases would skew the data for many performance parameters, confounding the interpretation of audit results.

Post-Procedure Mammogram for Marker Placement

The 2023 Amendments to the MQSA Regulations added another assessment category: "Post-Procedure Mammogram for Marker Placement." This assessment was derived from the prior 2003 alternate standard and is to be used on mammograms whose specific purpose is to delineate the presence of a tissue marker, exempting it from requirements for auditing, as with the "Known Biopsy-Proven Malignancy" category. An accompanying numerical code has not been assigned by ACR to this assessment category.

B. REPORT ORGANIZATION

The reporting system should be concise and organized using the following structure:

Table 5. Report Organization

1.	Indication for examination
2.	Comparison to previous examination(s)
3.	Technique
4.	Breast density
5.	Clear description of any important findings
6.	Assessment
7.	Management recommendations

1. INDICATION FOR EXAMINATION

New to this version of BI-RADS are structured categories for the major clinical indications for breast imaging, with associated optional subcategories and relevant clinical histories. These structured categories should be used when creating reports for all modalities. Use of structured indications (outlined below) is recommended to aid in achieving report clarity and outcomes monitoring, including method of cancer detection.

A brief but specific description of the indication for examination is provided. This may be screening for an asymptomatic woman undergoing a screening exam. For diagnostic exams,

indications may include recall of a screening-detected finding, evaluation of a clinical finding (specify the finding and its location), or follow-up of a probably benign finding, using the "Diagnostic Work-up" category. If the patient has a current breast cancer not yet definitively treated, the "Diagnostic: Current Cancer" indication can be used. Additional use of the optional sub-categories can provide more information and nuance to the report.

Table 6. Structured Exam Indications

Major Indication	Optional Subcategory Indication	Relevant History to Report, if known
Asymptomatic Screening	• Elevated risk • Dense breasts • Prior breast cancer, treatment completed • Other	• Gene mutation • Estimated cancer risk • Prior breast cancer history
Diagnostic Work-up	• Clinical findings • Imaging findings • Follow-up category 3 • Follow-up after biopsy • Implant assessment • Other	• Clinical finding type • Imaging finding type
Diagnostic: Current Breast Cancer	• Extent of disease before treatment/therapy • Response during or after neoadjuvant therapy • Other	• Location and size of cancer on prior imaging evaluation

2. COMPARISON TO PREVIOUS EXAMINATION(S)

   A statement indicating that the current examination has been compared to previous examination(s) and the dates of previous exams reviewed is recommended. "Baseline exam" can be specified when it is the patient's first mammogram. If the patient has undergone prior imaging but the images are not available for comparison, it is recommended to indicate that in the report.

3. TECHNIQUE

   For screening, a statement indicating that standard digital mammography (DM) views and/or digital breast tomosynthesis (DBT) views were obtained should be included. If diagnostic imaging was performed, then the type of mammogram and the specific mammographic views performed can be included. Practices may wish to include a statement indicating any supplemental tools used, such as computer-aided detection (CAD) or Artificial Intelligence (AI).

4. BREAST DENSITY

   A breast density assessment is required in every mammography report, screening or diagnostic, including post-procedure mammogram for clip placement, and even in mastectomy patients and male patients. It is acceptable to put the breast density under its own heading or in the findings section. Wording of breast density is mandated by FDA regulation and must be explicitly followed. Note that in July 2025, the FDA approved an alternative standard that would allow the interpreting physician to provide an overall assessment of

breast density that is phrased in the singular phrasing. The singular phrasing is intended to be used in reports of unilateral mammograms. Please see the Guidance section for more information.

5. CLEAR DESCRIPTION OF ANY IMPORTANT FINDINGS

   a. **Mass**
      Size
      Morphology – shape, margin
      Density
      Secondary findings (e.g., calcifications or architectural distortion)
      Associated features
      Location

   b. **Calcifications**
      Size/extent
      Morphology – describe typically benign type (if reporting) or describe shape of calcifications
      Distribution – may not be appropriate for typically benign calcifications
      Secondary findings
      Associated features
      Location

   c. **Architectural Distortion**
      Size
      Secondary findings
      Associated features
      Location

   d. **Asymmetries**
      Size
      Secondary findings
      Associated features
      Location

   e. **Intramammary lymph node**
      Location
      Morphology

   f. **Axillary Lymph node**
      Location
      Morphology

   g. **Skin lesion**
      Location

   h. **Solitary dilated duct**
      Location

6. ASSESSMENT

   An assessment category in the overall summary of the mammography report is mandated by the Food and Drug Administration, Mammography Quality Standards; Final Rule [54]. The assessment section should explicitly state the overall final assessment using BI-RADS categories 1–6 and the phrases associated with them (See FAQ 1 on page 166 for FDA approved language link and table).

7. MANAGEMENT RECOMMENDATIONS

Whereas FDA-mandated assessments are not linked to management recommendations, BI-RADS assessment categories are designed to be paired with concordant specific management recommendations. The linking of assessment categories with concordant management recommendations further enhances sound medical practice. In some settings, a discordant management recommendation may be appropriate, related to unique clinical circumstances. An explanation of the discordant recommendation added to the report can provide nuanced guidance in these situations.

An incomplete (category 0) assessment is given for screening examinations when additional imaging evaluation is recommended before it is appropriate to render a final assessment. It is good practice for a recall (category 0) assessment to include suggestions for the next course of action (e.g., additional evaluation with diagnostic imaging). Category 0 may also be used in the setting of an incomplete diagnostic examination due to the patient leaving before the diagnostic examination is complete.

If the exam is negative or benign, a recommendation can be made to continue or resume screening at the appropriate interval. If a BI-RADS 3 is rendered, the recommended follow-up interval can be specifically outlined. If a suspicious abnormality is identified, the report should indicate that biopsy is recommended. This is an assessment for which the interpreting physician has sufficient concern for malignancy that tissue diagnosis is warranted based on imaging findings. It is good practice to include the recommended method of tissue diagnosis (e.g., stereotactic biopsy, ultrasound-guided biopsy, etc.).

C. WORDING OF REPORT

The type of examination, such as screening or diagnostic, and the indication should be stated, preferably using structured indication terminology. The current examination should be compared to prior examination(s) when available. The report should be organized with a brief description of the composition of the breast and any pertinent findings, followed by the assessment and management recommendations.

The report should be succinct, using terminology from the latest approved lexicon without embellishment. Following the impression section and the management recommendation section of the report, both the FDA-approved terminology for the assessment category (see FAQ #1) and the assessment category number should be stated [54]. Note that FDA regulations require that FDA-approved terminology for the assessment category must precede the assessment category number, and that use of an assessment category number is optional. Any discussions between the interpreting physician and the referring clinician or patient should be documented in the original report or in an addendum to the report. Other aspects of the report should comply with the ACR Practice Parameter for Communication of Diagnostic Imaging Findings [55].

Table 7. BI-RADS Assessment Categories and FDA-Approved Equivalent Wording

BI-RADS Assessment Category	BI-RADS Numeric Code	FDA-Approved Equivalent Wording
Incomplete - Need Additional Imaging Evaluation OR Incomplete - Need Prior Mammograms for Comparison	0 0	• Incomplete: Need Additional Imaging Evaluation • Incomplete: Additional Imaging Evaluation Needed • Need Additional Imaging Evaluation (the term "Incomplete can be inferred in this example) • Incomplete Mammogram: Need Additional Imaging Evaluation • Incomplete: Need Prior Mammograms for Comparison • Incomplete: Comparison with Prior Mammograms Needed • Need Prior Mammograms for Comparison (the term "Incomplete" can be inferred in this example) • Incomplete Mammogram: Need Prior Mammogram for Comparison
Negative	1	• Negative Mammogram
Benign	2	• Benign Finding • Benign Findings • Benign Abnormality • Benign Abnormalities • Benign Mammogram
Probably Benign	3	• Probably Benign Finding • Probably Benign Findings • Probably Benign Abnormality • Probably Benign Abnormalities • Probably Benign – Short Interval Follow-up Suggested • Probably Benign Finding – Short Interval Follow-up Suggested • Probably Benign Mammogram
Suspicious	4	• Suspicious Finding • Suspicious Findings • Suspicious Abnormality • Suspicious Abnormalities • Suspicious for Malignancy • Suspicious of Malignancy • Suspicious Finding – Biopsy Should be Considered • Suspicious Abnormality – Biopsy Should be Considered • Suspicious Mammogram
Highly Suggestive of Malignancy	5	• Highly Suggestive for Malignancy • Highly Suggestive of Malignancy – Appropriate Action Should be Taken
Known Biopsy-Proven Malignancy	6	• Known Biopsy – Proven Cancer • Known Malignancy • Known Cancer

VI. GUIDANCE

Many substantive changes were incorporated into the current version to reflect new data, improve the clinical utility of the BI-RADS Manual and supply a unified base for research involving breast imaging. This chapter expands on these changes as they appear in each section of the BI-RADS Manual and provides more complete explanations for the changes. What follows is intended for guidance and is not meant to imply required standards of practice.

A. MAMMOGRAPHY LEXICON

For several findings in the lexicon for which more than one descriptor was used in past editions, only one descriptor remains in the current version. These changes were made to simplify reporting. To ease the transition, the eliminated descriptor is reviewed along with the reasoning behind the change.

1. MASS VS. ASYMMETRY

   All types of asymmetries have different contours than true masses and often lack the conspicuity of masses. Indeed, asymmetries appear similar to other discrete areas of benign fibroglandular tissue except that they are unilateral, with no mirror-image correlate in the opposite breast. An asymmetry demonstrates a concave contour and is usually interspersed with fat, whereas a mass demonstrates a completely or partially convex contour and (when radiodense) appears denser in the center than at the periphery.

   Historically, a mass (by definition) had to be visualized on two orthogonal mammographic projections, and, if visualized only in one projection, was classified as an asymmetry. New to this version, if a one-view finding demonstrates the characteristic features of a mass (e.g., convex contour and central radiodensity), it may be appropriate to classify it as a mass. True masses may be seen on only one view due to masking by overlapping fibroglandular tissue or exclusion from the image field. One-view only masses may be more apparent on DBT.

2. MASS: LOBULATED SHAPE AND MICROLOBULATED MARGIN

   The shape descriptor “lobulated” (one or more shallow undulations) has been reinstated (although the verbiage slightly changed from the prior term descriptor “lobular” to avoid overlap with the cancer cell type descriptor in lobular carcinoma). The margin descriptor “microlobulated” (many small undulations) has been removed from the mammography lexicon. Lobulated shape was felt, based on some data as well as expert consensus, to convey a more suspicious appearance compared to a strictly oval shape and was therefore returned to the lexicon to allow a more nuanced shape description. Microlobulated margin was removed to avoid overlapping terminology between shape and margin. A microlobulated margin should now be described as indistinct.

3. TYPICALLY BENIGN CALCIFICATIONS

   In the current version, among the descriptors of typically benign calcifications, the term “popcorn like” has been eliminated by incorporating it into the remaining term “coarse” to simplify reporting, and in keeping with the radiology-wide move away from using food-related descriptors. This category also now includes dystrophic calcifications as well, which has been eliminated as a separate category.

   The term “milk of calcium” has been replaced by “layering” to emphasize the morphologic appearance of underlying process (i.e., layering or sedimentation of calcium within micro- or macro-cysts) rather than the physiologic make-up of the sediment.

The term "punctate" has also been removed, since both "round" and "punctate" referred to particles that are round in shape. Historically, round calcifications were termed punctate when < 0.5 mm and round when > 0.5 mm. In the 5th Edition, punctate became a subcategory of round calcifications. However, given the impracticality of measuring the size of individual calcifications, "punctate" has been removed as a descriptor. Any calcification with a round shape should be characterized as "round," regardless of size.

4. SOLITARY DILATED DUCT

In the BI-RADS 5th Edition, a tissue diagnosis was recommended for a solitary dilated duct unless a benign etiology was demonstrated. Newer literature confirms prior research that a solitary dilated duct is a rare finding and, when not associated with suspicious imaging features (e.g., associated mass, architectural distortion, or microcalcifications) and occurring in asymptomatic individuals, has essentially 0% likelihood of malignancy and can be considered benign. If a solitary dilated duct is present on a baseline exam, in a symptomatic woman or is associated with other suspicious imaging features, then additional imaging evaluation leading to possible tissue diagnosis should be considered.

5. FOCAL ASYMMETRY VS. DEVELOPING ASYMMETRY

A focal asymmetry is an area of tissue that is confined to less than one quadrant and asymmetric to the corresponding location in the contralateral breast. It is visible and may appear similar on multiple mammographic projections (hence, a real finding rather than superimposition of normal breast structures) but lacks the convex contour, central density and the conspicuity of a mass. The contour of a focal asymmetry is concave and there is usually interspersed fat.

New to this version, the term "developing asymmetry" as a descriptor has been discontinued, to be consistent with the remaining lexicon, where delineation of change over time is not embedded in the descriptor terminology. Additionally, the term was on occasion not fully descriptive, as it was intended to describe a new, larger or more conspicuous *focal* asymmetry, but only contained the term "asymmetry." Now such findings can be described as focal asymmetries and, if desired, change in appearance over time can be commented upon.

Although terminology has changed, the clinical importance of a new or increasingly conspicuous asymmetry or focal asymmetry should be strongly stressed. If confirmed to be a real finding on diagnostic evaluation, biopsy should be recommended even in the absence of an ultrasound correlate, as the positive predictive value for such a finding is in the range of 7.4–12.8% when detected on screening and 19.7–26.7% in the diagnostic setting [31, 32].

6. DESCRIPTORS FOR LOCATION OF FINDING

In the current version, more flexibility is permitted in lesion location description. Delineation of quadrant and/or clock face is acceptable, as is either depth (anterior, mid or posterior) or distance from the nipple. Note that in this version, depth on MLO view is determined by using imaginary divisions that parallel the angle of the pectoralis major muscle. This method is felt to be more anatomically logical. In this way, findings that project over axilla will always be considered at posterior depth, rather than occasionally at middle depth, as could occur using the prior system of depth assignment. This facilitates correlation between mammography and other breast imaging modalities, given differences in patient positioning.

7. COMPARISON TO PREVIOUS EXAMINATIONS

Comparison to prior exams should occur when the patient has images within the system; retrieval of outside images for comparison is encouraged when logistically feasible. When suspicious findings are present, comparison with previous examination(s) can be useful, but biopsy should not be delayed awaiting arrival of prior exams. For findings that clearly require

prompt action, comments about the presence or absence of interval change may be omitted. Comparison to prior exams remains essential before assigning a BI-RADS 3 assessment. This will allow stable findings to be appropriately dismissed as benign and prompt biopsy rather than surveillance for findings whose change over time confirms suspicion.

8. USE OF RADIOPAQUE MARKERS

   A raised skin lesion sufficiently large to be seen at mammography may be marked by the technologist with a radiopaque device designed for this use. Because this marker is placed directly on top of or surrounding the skin lesion, both the marker and the skin lesion will be seen in the same location on mammographic images obtained in any projection. This approach enables the interpreting physician to discount the importance of the demarcated mammographic finding, which is definitively confirmed to represent a benign skin lesion.

   Similarly, the technologist may use a radiopaque marker to indicate the location of a palpable abnormality in the breast. The technologist should place the marker at the location on the skin that is expected to overlie the palpable lesion when the breast is compressed in a given mammographic projection [56]. Visibility of the marker on the mammogram may serve as an indicator that the palpable lesion has been included in the image field. This approach assists the interpreting physician in correlating the presence or absence of any visible mammographic finding(s) with the palpable lesion.

   Finally, facilities should establish protocols for the shape of markers to be used for skin findings versus other clinical findings such as palpable or painful areas.

9. SECONDARY FINDINGS VS. ASSOCIATED FEATURES

   The primary finding is the abnormality that drives the BI-RADS recommendation and management. Secondary findings are those additional abnormalities present in association with the primary finding. For example, there is a suspicious mass (primary finding) for which an ultrasound-guided biopsy is recommended, but there are also calcifications (secondary finding) within the mass. Alternatively, there are suspicious calcifications (primary finding) for which a stereotactic biopsy is recommended, but there is also a subtle asymmetry (secondary finding) overlapping the calcifications. In contrast, associated features are those changes to the breast that occur as a result of the primary and secondary findings, such as skin retraction or trabecular thickening. The use of primary and secondary findings as well as associated features, when appropriate, allows for a more nuanced description of the imaging presentation of abnormalities.

10. USE OF FDA ALTERATIVE STANDARD #26-ISSUING A REPORT WITH A BREAST DENSITY ASSESSMENT THAT IS PHRASED IN THE SINGULAR, OR IS NEITHER SINGULAR NOR PLURAL

    In July 2025, the FDA approved Alternative Standard #26 to amend the original MQSA standard *21 CFR 900.12(c)(1)(vi)* which allows the interpreting physician to provide an overall assessment of breast density that is phrased in the singular phrasing. The singular phrasing is intended to be used in reports of unilateral mammograms. The new approved terminology, outlined in *21 CFR 900.12(c) Medical records and mammography reports – (1) Contents and terminology . . . (https://www.fda.gov/radiation-emitting-products/regulations-mqsa/mqsa-alternative-standard-26-issuing-report-breast-density-assessment-phrased-singular-or-neither)*, is as follows:

    (vi) Overall assessment of breast density, classified in one of the following categories:

    (A) "The breast is almost entirely fatty."

    (B) "There are scattered areas of fibroglandular density."

    (C) "The breast is heterogeneously dense, which may obscure small masses."

(D) "The breast is extremely dense, which lowers the sensitivity of mammography."

(E) "Breast Density: Almost entirely fatty"

(F) "Breast Density: Scattered areas of fibroglandular density"

(G) "Breast Density: Heterogeneously dense, which may obscure small masses"

(H) "Breast Density: Extremely dense, which lowers the sensitivity of mammography"

In communicating mammography results to patients, similar singular terminology may be used, outlined in detail on the FDA website.

B. REPORT ORGANIZATION

1. ASSESSMENT-MANAGEMENT CONCORDANCE

Assessment-management concordance is a hallmark of appropriate interpretation. Concordance ensures that referring clinicians and/or patients understand the report recommendations, which helps to reduce confusion and incorrect treatment. Appropriate management recommendations for BI-RADS assessment categories are outlined in Table 4.

In earlier editions of the BI-RADS Manual, management recommendations were linked to assessment categories. Starting with the 5th Edition, management recommendations were unlinked from assessment categories to provide more flexibility when describing special case scenarios or when clinical factors necessitate alternative management recommendations. Discordant management recommendations should be used only in appropriate clinical scenarios and should be clearly documented in the report to inform the referring provider and the patient.

A common clinical scenario in which the appropriate management recommendation may appear to be discordant with the proper BI-RADS assessment category occurs when there are no imaging findings in a patient who has a palpable breast abnormality. Typically, the breast imaging report should indicate a negative (BI-RADS category 1) assessment, because there are no imaging findings to describe. However, if there is sufficient concern that a palpable cancer is not visible at breast imaging, the interpreting physician may suggest surgical consultation or tissue diagnosis. These management recommendations would be discordant with a negative assessment. The correct approach to reporting in this scenario is to provide a negative (BI-RADS category 1) assessment with a concordant management recommendation for routine mammography screening. This should be followed with a sentence recommending clinical management to include surgical consultation or tissue diagnosis if clinically indicated.

Another discordant clinical scenario involves a patient with a painful simple (characteristically benign) cyst for which therapeutic aspiration is offered for symptomatic relief. The correct reporting approach is to provide a benign (BI-RADS category 2) assessment with a concordant management recommendation for routine mammography screening, but to follow this with a sentence recommending aspiration to relieve the discomfort produced by the cyst.

One more example of a discordant clinical scenario occurs in a patient who has a ruptured implant but no imaging findings suggestive of malignancy. The correct approach to reporting in this scenario is to provide a benign (BI-RADS category 2) assessment with a concordant management recommendation for routine mammography screening, but to follow this with a sentence recommending surgical consultation to address proper management of the ruptured implant.

The correct approach to reporting discordant interpretive scenarios is that a) the assessment category should reflect the imaging findings of the case, b) a concordant management recommendation should be provided for this assessment, but c) an additional sentence should recommend the additional (apparently discordant) management appropriate for the

scenario. This approach provides flexibility in reporting to allow for both concordant and discordant components of management to be associated with the imaging-appropriate assessment. The one exception to this rule is non-visualization of a biopsy-proven cancer in the setting of preoperative systemic therapy, which should be assessed as BI-RADS category 6 despite the lack of a residual imaging abnormality.

2. ASSESSMENT WHEN MORE THAN ONE BREAST IMAGING EXAMINATION IS REPORTED TOGETHER

The terms used for assessment categories and management recommendations are the same for all imaging modalities. When more than one type of diagnostic examination is performed on the same day, it is preferable that the examinations be reported together. The findings for each examination are described in separate paragraphs, with an overall assessment and management recommendations for the combined examinations. In general, when the assessments for two examinations differ, the overall assessment and management recommendations should be the final assessment in highest order actionable. The following hierarchy of decreasing abnormality is used: categories 5, 4, 0, 6, 3, 2, 1 (Table 5). For example, a diagnostic mammogram is performed to evaluate a palpable concern which is interpreted as normal with a BI-RADS category 1 assessment, but subsequent same-day ultrasound reveals a suspicious mass. The final report, which includes both modalities, should provide an overall assessment of BI-RADS category 4 with a management recommendation for tissue diagnosis. If a BI-RADS category 0 assessment is resolved by subsequent same-day imaging, it would not be considered the highest actionable assessment. For example, if a mammographic mass requires ultrasound evaluation and is shown to be a simple cyst, the overall assessment would be a BI-RADS category 2, not a BI-RADS category 0, even though the category 0 assigned to the mammogram finding is higher in the assessment hierarchy.

Table 8. Abnormality Hierarchy

BI-RADS Assessment Category	Degree of Abnormality
5	Highest
4	
0	
6	
3	
2	
1	Lowest

3. REPORTING SINGLE VS. SEPARATE ASSESSMENTS FOR EACH BREAST

The FDA regulations require that a single overall assessment [32] or a separate assessment for each breast [54, 57] be rendered for every mammographic examination. If a single overall assessment is provided, the assessment is rendered for the more abnormal of the two breasts, based on the same hierarchy of decreasing abnormality described previously (categories 5, 4, 0, 6, 3, 2, 1). For example, if there is a probably benign assessment for one breast and a suspicious assessment for the opposite breast, the overall assessment should be suspicious (BI-RADS category 4).

If an assessment is rendered for each breast, FDA regulations specifically require that:

- a single medical report for both breasts will be sent to the referring clinician;
- a single lay report will be sent to the patient, containing information based on what would have been the overall assessment for both breasts; and

- even though separate assessments are made for each breast, the interpretation will count as only one examination towards meeting the MQSA experience requirements and will be billed as a single examination.

Category 1 vs. Category 2

Note that both category 1 and category 2 assessments indicate that there is no mammographic evidence of malignancy, and both have the same management recommendation for routine mammography screening. The difference is that category 1 should be used when no specific benign finding is described in the report, whereas category 2 should be used when at least one benign finding is described. Note that this difference relates to whether benign findings are described in the report, not whether such findings are visible at examination. It is recommended that all radiologists who work at a given mammography facility collectively agree on whether and when to describe benign findings in the report; hence, when to use category 1 versus category 2.

Category 3: Short term follow-up and continued surveillance.

For category 3 assessments, the initial short-term follow-up interval is usually 6 months, followed by a second 6-month interval (12 months after the initial study), followed by continued surveillance at 12-month intervals, so that long term stability of 2 years is established. If at any short-interval or surveillance mammography examination, the probably benign finding decreases or resolves, the appropriate assessment is benign (BI-RADS category 2) or negative (BI-RADS category 1). One may encounter the scenario in which the patient or referring clinician requests that a probably benign finding be biopsied. In this scenario, the correct approach is to render a probably benign (BI-RADS category 3) assessment with a concordant management recommendation for short-interval or surveillance mammography, but to follow this with a sentence indicating that tissue diagnosis will be performed instead, due to patient or referring clinician preference.

Category 4: Subdivisions 4A, 4B, and 4C

Category 4 findings are those with between > 2% – < 95% likelihood of malignancy and encompasses most findings prompting breast interventional procedures. Category 4 is frequently subdivided to better indicate the relative likelihood of malignancy within this broad category. In a retrospective review of diagnostic mammography data submitted to the National Mammography Database, 33% (41,841 of 125,447) of exams with category 4 Assessments were subcategorized into 4A, 4B and 4C assessments with PPV3 of 7.6% (4A), 22% (4B), and 69.3% (4C) respectively [58]. Subcategory designation cannot replace the overall category 4 designation per FDA regulations but may be used in addition to it.

Category 4A

Category 4A may be used for a finding needing intervention but with a low suspicion for malignancy. A malignant finding is not expected. The range of likelihood of malignancy for category 4A assessments is > 2% to ≤ 10%. Some particularly risk-tolerant patients may even choose to decline a recommended biopsy for category 4A lesions, if they are willing to accept the risk that up to 10% of such lesions are malignant.

Category 4B

Category 4B includes lesions with a moderate suspicion for malignancy. Findings in this category warrant careful radiologic and pathologic correlation after percutaneous tissue diagnosis if benign results are returned. The range of likelihood of malignancy for category 4B assessments is > 10% to ≤ 50%. Examples of findings placed in this category may include a group of fine pleomorphic calcifications and an otherwise nondescript solid mass with indistinct margin.

Category 4C

Category 4C includes findings that have a high suspicion for malignancy but are not highly suggestive of malignancy (category 5). The range of likelihood of malignancy for category 4C assessments is > 50% to < 95%, more likely malignant than benign and therefore properly termed "high suspicion." Examples of findings placed in this category are a new indistinct, irregular solid mass and a new group of fine linear calcifications.

Consistent use of the subdivisions of category 4 may inform nuanced management of benign results. For example, pathologists may initiate further histological evaluation of benign results for 4C findings. Additionally, referring clinicians may be better able to understand the radiology follow-up recommendations for findings placed in each subdivision of category 4.

Category 5

Category 5 assessments are used for those findings that have characteristic features of cancer for which almost all nonmalignant percutaneous tissue diagnosis is likely to be considered discordant, resulting in the recommendation for repeat (usually surgical) biopsy.

Category 6

A category 6 assessment is given when breast imaging is performed in an individual with a known malignancy during neoadjuvant treatment and prior to definitive local treatment, typically surgical excision.

When further breast imaging is performed prior to definitive treatment of a biopsy-proven malignancy and additional suspicious findings other than the known cancer are demonstrated, a category 6 assessment is not appropriate. It must be clearly communicated that besides the known malignancy, there are one or more findings requiring specific prompt action. The single overall assessment should be based on the most immediate action needed. If, at additional imaging, no other suspicious finding is identified, then a category 6 assessment should be rendered accompanied by the recommendation that subsequent management should be directed to the known cancer. As for any examination in which there is more than one finding, the management section of the report may include a second sentence that describes the appropriate management for the finding(s) not covered by the overall assessment.

VII. FREQUENTLY ASKED QUESTIONS

1. What is the difference between MQSA and ACR requirements for mammography reporting?

The Mammography Quality Standards Act (MQSA) is legislation that was developed to establish minimum standards that would ensure all patients have access to quality mammography services. MQSA required the Department of Health and Human Services (HHS) to develop standards that would be enforced through strict accreditation, certification and inspection of equipment and personnel at mammography facilities. The Food and Drug Administration (FDA) was tasked with implementing the federal regulations. The American College of Radiology (ACR) is one of three FDA-approved accreditation bodies.

Mammography reports are required to be compliant with FDA-approved wording. The FDA-approved wording uses overall assessment categories (e.g., negative, benign), but not a numeric code. The ACR provides more nuance in reporting and utilizes numeric codes and subcategories within BI-RADS (e.g., 4A, 4B), which may be helpful for practice auditing. For audit purposes, practices must comply with the FDA-approved wording.

Table 7. BI-RADS Assessment Categories and FDA-Approved Equivalent Wording

BI-RADS Assessment Category	BI-RADS Numeric Code	FDA-Approved Equivalent Wording
Incomplete - Need Additional Imaging Evaluation OR Incomplete - Need Prior Mammograms for Comparison	0 0	• Incomplete: Need Additional Imaging Evaluation • Incomplete: Additional Imaging Evaluation Needed • Need Additional Imaging Evaluation (the term "Incomplete can be inferred in this example) • Incomplete Mammogram: Need Additional Imaging Evaluation • Incomplete: Need Prior Mammograms for Comparison • Incomplete: Comparison with Prior Mammograms Needed • Need Prior Mammograms for Comparison (the term "Incomplete" can be inferred in this example) • Incomplete Mammogram: Need Prior Mammogram for Comparison
Negative	1	• Negative Mammogram
Benign	2	• Benign Finding • Benign Findings • Benign Abnormality • Benign Abnormalities • Benign Mammogram
Probably Benign	3	• Probably Benign Finding • Probably Benign Findings • Probably Benign Abnormality • Probably Benign Abnormalities • Probably Benign – Short Interval Follow-up Suggested • Probably Benign Finding – Short Interval Follow-up Suggested • Probably Benign Mammogram

Suspicious	4	• Suspicious Finding • Suspicious Findings • Suspicious Abnormality • Suspicious Abnormalities • Suspicious for Malignancy • Suspicious of Malignancy • Suspicious Finding – Biopsy Should be Considered • Suspicious Abnormality – Biopsy Should be Considered • Suspicious Mammogram
Highly Suggestive of Malignancy	5	• Highly Suggestive for Malignancy • Highly Suggestive of Malignancy – Appropriate Action Should be Taken
Known Biopsy-Proven Malignancy	6	• Known Biopsy – Proven Cancer • Known Malignancy • Known Cancer

2. ***Is there a numeric code in BI-RADS for "Post-Procedure Mammograms for Marker Placement?"***

   No, there is no numeric code for the FDA-approved alternative standard for "Post-Procedure Mammograms for Marker Placement." This assessment may only be used for post-procedure mammograms obtained for the purpose of confirming the deployment and position of breast tissue markers, which typically have been placed at the time of core biopsy. Comparison with pre-biopsy imaging is important to ensure accurate biopsy targeting and sampling. This assessment should be excluded from auditing. Note that there is no FDA-approved equivalent wording for this assessment category other than "Post-Procedure Mammograms for Marker Placement."

   Per FDA requirements, mammographic density must be included in the report when marker placement is performed on a different day.

3. ***In my practice we commonly issue addenda and/or comparison reports after initial mammography reports have been issued. What are the FDA requirements for assigning assessment categories?***

   Following comparison with prior mammograms, a final assessment category for the addendum must be assigned. The report must be communicated to the referring provider. A lay summary of the addendum must be provided to the patient, even if there is no change in the final assessment category or recommended course of action. Amended reports and lay summaries must also include breast density assessment.

4. ***My practice uses the BI-RADS category 4 subdivisions (4A - low suspicion for malignancy, 4B - moderate suspicion for malignancy, 4C - high suspicion for malignancy). May our reports use these subdivisions as assessment categories instead of the category 4 assessment (suspicious)?***

   No. While you have the option of using one of the three subdivisions of category 4 *in addition to* a final assessment of Suspicious, the FDA will not allow you to use the subcategories instead of the Suspicious assessment category in the mammography report.

5. ***Can screening and diagnostic examinations performed on the same day be combined into one report or must there be two separate reports?***

   Mammography facilities have the option to issue either separate or combined reports. If two reports are issued (recommended by the ACR), each must contain its own overall final

assessment. If facilities decide to issue a single combined report, they need to be aware of the following:

- A single combined report must contain a single overall final assessment.
- The report should clearly state that it represents the combined results of a screening and diagnostic study.
- It is critical to understand that issuing a single report with a single final assessment will skew the facility's audit results ***if the overall assessment category is used for both the screening and diagnostic audit calculations***. Therefore, it is recommended that separate BI-RADS assessments are generated and recorded for audit purposes. ***If a breast imaging facility declines this recommendation and continues to generate a combined report with a single overall final assessment, then unique and accurate assessments for the screening and diagnostic examinations should be recorded within the audit data to allow for accurate audit calculations***.
- Although some computerized reporting systems may consider this a single examination (rather than two), FDA would still allow the facility to count both examinations toward meeting the continuing experience requirement of the interpreting physician.

6. ***Axillary adenopathy is seen at screening mammography with no suspicious findings in the breasts. What should the BI-RADS final assessment be?***

   In the absence of a known infectious, reactive, or inflammatory cause, isolated unilateral axillary adenopathy should receive a category 0, with the recommendation for further work-up with ultrasound. At that time, further clinical information may be obtained. Final management would depend on the appearance on diagnostic imaging and the clinical history if available. Of note, unilateral enlarged axillary lymph nodes can be associated with a recent COVID-19 and/or other vaccination when administered in the ipsilateral arm. Review of the patient's medical record may mitigate the need for diagnostic imaging evaluation, in which case the axillary adenopathy can be deemed benign (BI-RADS category 2) if described in the report or negative (BI-RADS category 1) if the radiologist decides not to describe the finding.

   Bilateral axillary adenopathy can occur with benign systemic conditions such as autoimmune disease, infection, inflammatory conditions as well as non-breast malignancies such as lymphoma/leukemia. When those histories can be confirmed, axillary adenopathy may be assessed as benign (BI-RADS category 2) if described in the report or negative (BI-RADS category 1) if the radiologist elects not to describe the findings. If no salient clinical history can be identified to account for the adenopathy, recall (BI-RADS 0) for ultrasound imaging and possible biopsy may be indicated, even if adenopathy is bilateral and symmetric. Note that even though lymphoma and leukemia are malignancies, a "known malignancy" assessment (BI-RADS category 6) is not appropriate, since that category is reserved for cancers of breast origin only.

   In the case where either unilateral or bilateral axillary adenopathy is determined to be of no clinical significance, a benign rather than negative final assessment may be preferable, so that the etiology of the adenopathy can be communicated in the report to future interpreters.

7. ***For comparison examinations, is it required to include in the report actual dates of the examinations used for comparison or is it acceptable to make a more generalized statement such as "prior breast examinations were compared?"***

   While not required, it is recommended to include the dates of prior examinations that are used for comparison with the current study in your report, especially if there are findings the radiologist is evaluating for stability or in cases assessing treatment response.

8. ***Do I need to assign a breast density descriptor to all mammographic exams, even a diagnostic exam with limited views?***

BI-RADS requires classification of breast density on every mammography examination that leads to rendering an assessment (0 through 6), as well as when a post-procedure mammogram for clip placement is performed on a day removed from the day of biopsy. In the scenario where only a portion of the tissue is imaged, the best solution may be to repeat the previous breast density (of the bilateral mammogram) in classifying the follow-up examination, to avoid confusion. Additionally, breast density must be included in the lay summary communicated to patients for each of these exam types.

A breast density assessment is required for mammographic evaluation of the male breast and for the ipsilateral post-mastectomy breast even when only that side has been imaged. Additionally, breast density assessment is required for post-procedural examinations performed strictly for marker position verification.

9. ***Is it acceptable to only use a BI-RADS breast composition category letter (A-D) or is the written description required in the report?***

   No, at minimum the FDA-approved written descriptors of breast density must be used in the report. The BI-RADS density letter designation can be included to improve communication.

10. ***If the referring provider orders a screening mammogram and indicates that an ultrasound should be performed if needed, which BI-RADS final assessment category is appropriate for the screening examination? Should I assign a category 0 since an ultrasound may be appropriate such as for supplemental screening in patients with dense breasts?***

    If the screening mammogram is normal or benign, then the BI-RADS final assessment should be category 1 or 2, as appropriate. It is not appropriate to assess a normal screening mammography examination as category 0 even if supplemental screening is recommended. Instead, an additional statement can be included, such as "because of the patient's dense breasts, supplemental screening should be considered."

11. ***In a patient with silicone breast implants, if the mammogram is negative for malignancy but there is question of implant rupture, is it acceptable to give a BI-RADS category 0 and recommend MRI evaluation to assess implant integrity?***

    If the mammogram is negative but there is questionable implant rupture, the correct BI-RADS final assessment would be benign category 2: benign, with an additional sentence that recommends a breast MRI to assess implant integrity.

12. ***What is wrong with assigning a probably benign (category 3) assessment to a group of calcifications I see on a screening exam?***

    It is only appropriate to assign a probably benign (BI-RADS category 3) assessment following appropriate diagnostic work-up. Immediate diagnostic evaluation may confirm a benign finding (such as layering calcifications) obviating the need for short term follow-up or might identify suspicious features (such as fine pleomorphic calcifications only appreciated with magnification views) that warrant prompt biopsy.

13. ***Should a post-lumpectomy patient who had the tumor completely excised automatically be assigned a category 3?***

    A probably benign (BI-RADS category 3) assessment should not be automatically assigned when the patient is undergoing routine surveillance following lumpectomy, even if the facility elects to image at intervals less than one year. Postsurgical changes are expected on mammography and in the absence of suspicious new findings, a benign (category 2) assessment is correct. A category 3 assessment in the post-lumpectomy setting should only be utilized if there are imaging

findings that individually warrant a probably benign designation, such as coarse calcifications at the lumpectomy site that suggest developing fat necrosis.

14. ***If you see a finding on a mammogram that has convex margins and can be seen on multiple DBT slices but is only seen on one view (e.g., CC or MLO view), can you still call this a mass?***

    Yes. Because DBT displays findings on multiple consecutive slices, characterization of a mass can be performed even if only identified on one view. Examples of this include low axillary lymph nodes that are only included on the MLO view, or masses that are obscured by surrounding breast tissue on one view but characterized well on the other view.

APPENDIX A — MAMMOGRAPHIC VIEWS

Terminology and abbreviations for mammographic views are displayed in Table 9.

Table 9. Standardized Terminology and Abbreviations for Mammography Views

Projection/View	Labeling Code
Mediolateral oblique	MLO
Mediolateral	ML
Lateromedial	LM
Lateromedial oblique	LMO
Craniocaudal	CC
Craniocaudal exaggerated laterally	XCCL
Craniocaudal exaggerated medially	XCCM
Caudocranial (from below)	FB
Superolateral-to-inferomedial oblique	SIO
Inferomedial-to-superolateral oblique	ISO
Cleavage	CV
Axillary tail	AT
Tangential	TAN
Step-oblique view - 15 degree	MLO15
Step-oblique view - 30 degree	MLO30
Step-oblique view - 45 degree	MLO45
Step-oblique view - 60 degree	MLO60
Step-oblique view - 75 degree	MLO75
Spot compression	S.
Magnification	M.
Rolled lateral	.RL
Rolled medial	.RM
Rolled superior	.RS
Rolled inferior	.RI
Implant displaced	.ID
Nipple in profile	.NP
Anterior compression	.AC
Inframammary fold	.IMF
Axillary tissue	.AX
Stereo scout	.SC
Stereo-	.ST-
Stereo+	.ST+
Prefire-	.PRF-

Prefire+	.PRF+
Postfire-	.POF-
Postfire+	.POF+
Postbiopsy-	.POB-
Postbiopsy+	.POB+
Postbiopsy	.POB

Note: XX. — used as a prefix before the projection (e.g., LSMML) .
XX — used as a suffix after the projection (e.g., LCCRL)

APPENDIX B — MAMMOGRAPHY LEXICON SUMMARY FORM

ACR BI-RADS® — MAMMOGRAPHY LEXICON SUMMARY FORM

For each of the following categories, select the term that best describes the dominant lesion feature.

BREAST TISSUE		
Breast Composition *(select one)*		
(A) The breasts are almost entirely fatty		
(B) There are scattered areas of fibroglandular density		
(C) The breasts are heterogeneously dense, which may obscure small masses		
(D) The breasts are extremely dense, which lowers the sensitivity of mammography		
FINDINGS		
A. Masses: A mass is 3D and occupies space (either seen in two different mammographic projections or on consecutive DBT slice). It has a completely or partially convex-outward contour and (if radiodense) is denser in the center than at the periphery.		
1. Shape *(select one)*	a. Oval	Elliptical with one axis longer than the other two
	b. Lobulated	Displays one or more indentations resulting in an undulating contour
	c. Round	Spherical, ball-shaped, circular
	d. Irregular	Neither oval, lobulated nor round; shows acute-angle protrusions
2. Margin *(select one)*	a. Circumscribed	At least 75% of the margin is sharply demarcated, with an abrupt transition between the lesion and surrounding tissue
	b. Obscured	25% or more of the margin is hidden by superimposed or adjacent fibroglandular tissue (but the visible margin is circumscribed)
	c. Indistinct	No clear demarcation of the entire margin or any portion of it from the surrounding tissue
	d. Spiculated	Margin is characterized by lines radiating from the mass
3. Density *(select one)*	a. Fat-containing	Includes all masses containing fat, such as oil cyst, lipoma, or galactocele as well as mixed-density lesions such as hamartoma
	b. Low density	X-ray attenuation of the mass is less than the expected attenuation of an equal volume of fibroglandular breast tissue
	c. Equal density	X-ray attenuation of the mass is the same as the expected attenuation of an equal volume of fibroglandular breast tissue
	d. High density	X-ray attenuation of the mass is greater than the expected attenuation of an equal volume of fibroglandular breast tissue
B. Calcifications *(select one)*		
1. Typically benign *(select all that apply)*	a. Skin	Usually lucent-centered and pathognomonic in appearance
	b. Vascular	Parallel tracks or linear, tubular calcifications that are usually clearly associated with blood vessels

	c. Coarse	These calcifications are classic, large (> 2 to 3 mm in greatest diameter), dense and confluent
	d. Large rod-like	Associated with ductal ectasia, may form solid or discontinuous, smooth linear rods often with tapering ends
	e. Round	Usually small and smooth but may vary in size and, therefore, also in opacity
	f. Rim	Appear as calcium deposited on the surface of a sphere (usually < 1 mm in thickness when viewed on edge)
	g. Layering	A manifestation of sedimented calcifications in macro- or microcysts, usually but not always grouped. On the CC image — often less evident and appear as round, smudgy deposits, while occasionally on MLO and especially on 90° lateral (LM/ML) views — more clearly defined and often semilunar, crescent shaped, curvilinear (concave up) or linear, defining the dependent portion of cysts. The most important feature of these calcifications is the apparent change in shape of the calcific particles on different mammographic projections (CC versus occasionally the MLO view and especially LM/ML views)
	h. Suture	Typically linear or tubular in appearance; when present, knots are frequently visible
2. Suspicious morphology *(select one)*	a. Amorphous	So small and/or hazy/formless in appearance that a more specific particle shape cannot be determined
	b. Coarse heterogeneous	Irregular, conspicuous calcifications that are generally between 0.5 mm and 1 mm and tend to coalesce but are smaller than coarse calcifications
	c. Fine pleomorphic	Usually more conspicuous than amorphous forms and are seen to have discrete shapes — these irregular calcifications are distinguished from fine linear and fine linear-branching forms by the absence of fine-linear particles — they vary in size and shape and are usually < 0.5 mm in diameter
	d. Fine linear or fine linear-branching	Thin, linear, irregular calcifications, which may be discontinuous and < 0.5 mm in caliber — occasionally, branching forms may be seen
3. Distribution *(select one)*	a. Diffuse	Distributed randomly throughout the breast
	b. Regional	Used for numerous calcifications that occupy a large portion of breast tissue (> 2 cm in greatest dimension) but not the entire breast, not conforming to a duct distribution — may involve most of a quadrant or even more than a single quadrant
	c. Grouped	Used when relatively few calcifications occupy a small portion of breast tissue — generally at least 5 calcifications grouped within 1 cm of each other or a greater number within 2 cm of each other
	d. Linear	Calcifications arrayed in a line
	e. Segmental	Used when the distribution of calcifications suggests deposits in a duct or ducts and their branches, generally arranged in a triangular arrangement with apex point toward the nipple
C. Architectural distortion: The parenchyma is distorted with no definite mass visible.		

D. Asymmetries: Involve a spectrum of mammographic findings that represent unilateral deposits of fibroglandular tissue not conforming to the definition of a radiodense mass. *(select one)*		
1. Global asymmetry		Judged relative to the corresponding area in the contralateral breast and represents a large amount of fibroglandular-density tissue over a substantial portion of the breast (at least one quadrant) — there is no mass, distorted architecture, or associated suspicious calcifications
2. Asymmetry		An area of fibroglandular-density tissue that is visible on only one mammographic projection, frequently representing superimposition of normal breast structures (summation artifact)
3. Focal asymmetry		Seen on more than one view. Judged relative to the corresponding location in the contralateral breast and represents a relatively small amount of fibroglandular-density tissue over a confined portion of the breast (less than one quadrant) — having similar shape on different mammographic projections, with concave-outward contour, usually interspersed with fat. When new or more conspicuous, must be viewed with suspicion
E. Lymph nodes		
Intramammary	a. Normal	Circumscribed masses that are reniform and have hilar fat. They are generally 1 cm or smaller in size (but may be larger than 1 cm and still characterized as normal)
	b. Abnormal	May show rounded morphology and loss of fatty hila
Axillary	a. Normal	Circumscribed masses that are reniform and have hilar fat, thin cortex. Degree of suspicion is independent of length
	b. Abnormal	May show rounded morphology, cortical thickening and loss of fatty hila
F. Skin lesion: This finding may be described in the mammography report or annotated on the mammographic image when it projects over the breast (especially on two different projections) and may be mistaken for an intramammary lesion.		
G. Dilated ducts		
1. Multiple dilated ducts		Tubular structures often > 5 mm in diameter originating from the nipple; may be unilateral or bilateral and are typically a benign finding
2. Solitary dilated duct		Unilateral single or branching dilated duct often > 5 mm in diameter. May be a benign or suspicious finding
H. Associated features: Used with masses, architectural distortions, asymmetries, or calcifications, or may stand alone as findings when no other abnormality is present. *(select all that apply)*		
1. Skin retraction		The skin is pulled in abnormally
2. Nipple retraction		The nipple is pulled in (should not be confused with nipple inversion, which is often bilateral)
3. Skin thickening		May be focal or diffuse, and is defined as being > 2 mm in thickness
4. Trabecular thickening		A thickening of the fibrous septa of the breast
I. Special cases		
1. Gynecomastia		Benign development of breast tissue in one or both breasts in cisgender males
2. Implants and other forms of augmentation	Saline	
	Silicone	
	Other forms of augmentation	
3. Mastectomy		

J. Location of finding — The side is given first followed by the quadrant and clock-face position, then the depth of the lesion, and its distance from the nipple.	
1. Laterality	Right, left or bilateral
2. Location in breast	Use clock-face position (preferred), or quadrant location (upper outer, upper inner, lower outer, lower inner). Use: retroareolar, central, and axillary tail preceded by right, left, or both breasts, when applicable
3. Depth **and/or** **Distance from the nipple**	Indicate depth in the breast (anterior, middle, posterior third) Distance from base of nipple to center of finding in whole cm; include centimeters from the skin, or chest wall as appropriate

ASSESSMENT CATEGORIES (select one)		
Incomplete Assessment	**Management**	**Likelihood of Cancer**
Incomplete: Need Additional Imaging Evaluation OR Incomplete: Need Prior Mammograms for Comparison	Recall for additional imaging Need comparison to prior examination(s)	N/A
Final Assessment	**Management**	**Likelihood of Cancer**
Category 1: Negative	Routine mammography screening	Essentially 0% likelihood of malignancy
Category 2: Benign	Routine mammography screening	Essentially 0% likelihood of malignancy
Category 3: Probably Benign	Short-interval (6-month) follow-up or continued surveillance mammography	> 0% but ≤ 2% likelihood of malignancy
Category 4: Suspicious – Category 4A: *Low suspicion for malignancy* – Category 4B: *Moderate suspicion for malignancy* – Category 4C: *High suspicion for malignancy*	Tissue diagnosis	2% but < 95% likelihood of malignancy >2% to ≤ 10% likelihood of malignancy > 10% to ≤ 50% likelihood of malignancy 50% to < 95% likelihood of malignancy
Category 5: Highly Suggestive of Malignancy	Tissue diagnosis	≥ 95% likelihood of malignancy
Category 6: Known Biopsy-Proven Malignancy	Clinical follow-up with surgeon and/or oncologist, and definitive local therapy (usually surgery) when clinically appropriate	N/A

REFERENCES

1. Duffy S, Tabar L, Smith RA. The mammographic screening trials: commentary on the recent work by Olsen and Gotzsche. J Surg Oncol 2002;81:159–62; discussion 62-6.
2. Nickson C, Mason KE, English DR, Kavanagh AM. Mammographic screening and breast cancer mortality: a case-control study and meta-analysis. Cancer Epidemiol Biomarkers Prev 2012;21: 1479–88.
3. Hendrick RE, Baker JA, Helvie MA. Breast cancer deaths averted over 3 decades. Cancer 2019; 125:1482–88.
4. Durand MA, Haas BM, Yao X, et al. Early clinical experience with digital breast tomosynthesis for screening mammography. Radiology 2015;274:85–92.
5. Friedewald SM, Rafferty EA, Rose SL, et al. Breast cancer screening using tomosynthesis in combination with digital mammography. JAMA 2014;311:2499–507.
6. McCarthy AM, Kontos D, Synnestvedt M, et al. Screening outcomes following implementation of digital breast tomosynthesis in a general-population screening program. J Natl Cancer Inst 2014;106.
7. Ni Mhuircheartaigh N, Coffey L, Fleming H, O'Doherty A, McNally S. With the advent of tomosynthesis in the workup of mammographic abnormality, is spot compression mammography now obsolete? An initial clinical experience. The Breast Journal 2017;23:509–18.
8. Peppard HR, Nicholson BE, Rochman CM, Merchant JK, Mayo RC, 3rd, Harvey JA. Digital Breast Tomosynthesis in the Diagnostic Setting: Indications and Clinical Applications. Radiographics 2015;35:975–90.
9. Carney PA, Miglioretti DL, Yankaskas BC, et al. Individual and combined effects of age, breast density, and hormone replacement therapy use on the accuracy of screening mammography. Ann Intern Med 2003;138:168–75.
10. Pisano ED, Gatsonis C, Hendrick E, et al. Diagnostic performance of digital versus film mammography for breast-cancer screening. N Engl J Med 2005;353:1773–83.
11. Rafferty EA, Durand MA, Conant EF, et al. Breast Cancer Screening Using Tomosynthesis and Digital Mammography in Dense and Nondense Breasts. JAMA 2016;315:1784–6.
12. Engmann NJ, Golmakani MK, Miglioretti DL, Sprague BL, Kerlikowske K, Breast Cancer Surveillance C. Population-Attributable Risk Proportion of Clinical Risk Factors for Breast Cancer. JAMA Oncol 2017;3:1228–36.
13. Hong AS, Rosen EL, Soo MS, Baker JA. BI-RADS for sonography: positive and negative predictive values of sonographic features. AJR Am J Roentgenol 2005;184:1260–5.
14. Burrell HC, Pinder SE, Wilson AR, et al. The positive predictive value of mammographic signs: a review of 425 non-palpable breast lesions. Clin Radiol 1996;51:277–81.
15. Liberman L, Abramson AF, Squires FB, Glassman JR, Morris EA, Dershaw DD. The breast imaging reporting and data system: positive predictive value of mammographic features and final assessment categories. AJR Am J Roentgenol 1998;171:35–40.
16. Woods RW, Sisney GS, Salkowski LR, Shinki K, Lin Y, Burnside ES. The mammographic density of a mass is a significant predictor of breast cancer. Radiology 2011;258:417.

17. Osman M, Regner S, Osman K, et al. Association Between Breast Arterial Calcification on Mammography and Coronary Artery Disease: A Systematic Review and Meta-Analysis. J Womens Health (Larchmt) 2022;31:1719–26.

18. Allen TS, Bui QM, Petersen GM, et al. Automated Breast Arterial Calcification Score Is Associated With Cardiovascular Outcomes and Mortality. JACC Adv 2024;3:101283.

19. Graf O, Berg WA, Sickles EA. Large rodlike calcifications at mammography: analysis of morphologic features. AJR Am J Roentgenol 2013;200:299–303.

20. Lai KC, Slanetz PJ, Eisenberg RL. Linear breast calcifications. AJR Am J Roentgenol 2012;199:W151–7.

21. Choi WJ, Han K, Shin HJ, Lee J, Kim EK, Yoon JH. Calcifications with suspicious morphology at mammography: should they all be considered with the same clinical significance? Eur Radiol 2021;31:2529–38.

22. Park GE, Kim SH, Lee JM, Kang BJ, Chae BJ. Comparison of Positive Predictive Values of Categorization of Suspicious Calcifications Using the 4th and 5th Editions of BI-RADS. AJR Am J Roentgenol 2019;213:710–15.

23. Kim SY, Kim HY, Kim EK, Kim MJ, Moon HJ, Yoon JH. Evaluation of malignancy risk stratification of microcalcifications detected on mammography: a study based on the 5th Edition of BI-RADS. Ann Surg Oncol 2015;22:2895–901.

24. Bent CK, Bassett LW, D'Orsi CJ, Sayre JW. The positive predictive value of BI-RADS microcalcification descriptors and final assessment categories. AJR Am J Roentgenol 2010;194:1378–83.

25. Burnside ES, Ochsner JE, Fowler KJ, et al. Use of microcalcification descriptors in BI-RADS 4th Edition to stratify risk of malignancy. Radiology 2007;242:388–95.

26. Oligane HC, Berg WA, Bandos AI, et al. Grouped Amorphous Calcifications at Mammography: Frequently Atypical but Rarely Associated with Aggressive Malignancy. Radiology 2018;288:671–79.

27. Lourenco AP, Barry-Brooks M, Baird GL, Tuttle A, Mainiero MB. Changes in recall type and patient treatment following implementation of screening digital breast tomosynthesis. Radiology 2015; 274:337–42.

28. Alshafeiy TI, Nguyen JV, Rochman CM, Nicholson BT, Patrie JT, Harvey JA. Outcome of architectural distortion detected only at breast tomosynthesis versus 2D mammography. Radiology 2018;288:38–46.

29. Bahl M, Lamb LR, Lehman CD. Pathologic Outcomes of Architectural Distortion on Digital 2D Versus Tomosynthesis Mammography. AJR Am J Roentgenol 2017;209:1162–67.

30. Patel BK, Covington M, Pizzitola VJ, et al. Initial Experience of Tomosynthesis-Guided Vacuum-Assisted Biopsies of Tomosynthesis-Detected (2D Mammography and Ultrasound Occult) Architectural Distortions. AJR Am J Roentgenol 2018;210:1395–400.

31. Venkatesan A, Chu P, Kerlikowske K, Sickles EA, Smith-Bindman R. Positive predictive value of specific mammographic findings according to reader and patient variables. Radiology 2009; 250:648–57.

32. Leung JW, Sickles EA. Developing asymmetry identified on mammography: correlation with imaging outcome and pathologic findings. AJR Am J Roentgenol 2007;188:667–75.

33. Bitencourt AG, Ferreira EV, Bastos DC, et al. Intramammary lymph nodes: normal and abnormal multimodality imaging features. Br J Radiol 2019;92:20190517.

34. Troupis T, Michalinos A, Skandalakis P. Intramammary lymph nodes: a question seeking for an answer or an answer seeking for a question? Breast 2012;21:615–20.

35. Lee S-J, Sobel LD, Shamis M, Mahoney MC. Asymmetric ductal ectasia: an often overlooked sign of malignancy. American Journal of Roentgenology 2019;213:473–81.

36. Ayres VJ, Ramalho LC, Fernandes CE, Fleury EFC, Pompei LM. Solitary dilated duct visualised by mammography: ultrasound and anatomopathological correlation. Clin Radiol 2020;75: 962 e9–62 e15.

37. Chang CB, Lvoff NM, Leung JW, et al. Solitary dilated duct identified at mammography: outcomes analysis. American Journal of Roentgenology 2010;194:378-82.

38. Choudhery S, Simmons C, Woodard GA, Bhatt AA, Anderson TL, Lee CU. Outcomes of solitary dilated breast ducts in symptomatic and asymptomatic patients. Br J Radiol 2020;93:20191039.

39. Panigrahi B, Fernandes K, Mullen LA, et al. Solitary Dilated Ducts Revisited: Malignancy Rate and Implications for Management. Acad Radiol 2023;30:807–13.

40. Freer PE. Skin and Trabecular Thickening. Breast Imaging 2018;377.

41. Robeva R, Elenkova A, Zacharieva S. Causes and Metabolic Consequences of Gynecomastia in Adult Patients. Int J Endocrinol 2019;2019:6718761.

42. Roelofs AA, Karssemeijer N, Wedekind N, et al. Importance of comparison of current and prior mammograms in breast cancer screening. Radiology 2007;242:70–7.

43. Hayward JH, Ray KM, Wisner DJ, et al. Improving screening mammography outcomes through comparison with multiple prior mammograms. AJR. American journal of roentgenology 2016;207:918.

44. Kerlikowske K, Smith-Bindman R, Abraham LA, et al. Breast cancer yield for screening mammographic examinations with recommendation for short-interval follow-up. Radiology 2005;234:684–92.

45. Sickles EA. Periodic mammographic follow-up of probably benign lesions: results in 3,184 consecutive cases. Radiology 1991;179:463–8.

46. Varas X, Leborgne JH, Leborgne F, Mezzera J, Jaumandreu S, Leborgne F. Revisiting the mammographic follow-up of BI-RADS category 3 lesions. AJR Am J Roentgenol 2002;179:691–5.

47. Vizcaíno I, Gadea L, Andreo L, et al. Short-term follow-up results in 795 nonpalpable probably benign lesions detected at screening mammography. Radiology 2001;219:475–83.

48. Graf O, Helbich TH, Fuchsjaeger MH, et al. Follow-up of palpable circumscribed noncalcified solid breast masses at mammography and US: can biopsy be averted? Radiology 2004;233:850–56.

49. Harvey JA, Nicholson BT, Lorusso AP, Cohen MA, Bovbjerg VE. Short-term follow-up of palpable breast lesions with benign imaging features: evaluation of 375 lesions in 320 women. AJR Am J Roentgenol 2009;193:1723–30.

50. Berg WA, Berg JM, Sickles EA, et al. Cancer Yield and Patterns of Follow-up for BI-RADS Category 3 after Screening Mammography Recall in the National Mammography Database. Radiology 2020;296:32–41.

51. Elshof LE, Tryfonidis K, Slaets L, et al. Feasibility of a prospective, randomised, open-label, international multicentre, phase III, non-inferiority trial to assess the safety of active surveillance for low risk ductal carcinoma in situ - The LORD study. Eur J Cancer 2015;51:1497–510.

52. Francis A, Thomas J, Fallowfield L, et al. Addressing overtreatment of screen detected DCIS; the LORIS trial. Eur J Cancer 2015;51:2296–303.

53. Hwang ES, Hyslop T, Lynch T, et al. The COMET (Comparison of Operative versus Monitoring and Endocrine Therapy) trial: a phase III randomised controlled clinical trial for low-risk ductal carcinoma in situ (DCIS). BMJ Open 2019;9:e026797.

54. 21CFR Part 16 and 900: Mammography Quality Standards; Quality Mammography Standards; Correction, Final Rule. Federal Register 1997.

55. American College of Radiology. ACR practice parameter for communication of diagnostic imaging findings. Available at: https://gravitas.acr.org/PPTS/GetDocumentView?docId=74.

56. Homer MJ. Proper placement of a metallic marker on an area of concern in the breast. AJR Am J Roentgenol 1996;167:390–1.

57. Department of Health and Human Services FaDA. MQSA Alternative Standard #8: Separate Assessment of Findings For Each Breast. 2022.

58. Elezaby M, Li G, Bhargavan-Chatfield M, Burnside ES, DeMartini WB. ACR BI-RADS Assessment Category 4 Subdivisions in Diagnostic Mammography: Utilization and Outcomes in the National Mammography Database. Radiology 2018;287:416–22.



ACR BI-RADS® v2025

Ultrasound

Jessica W. T. Leung, MD, Chair

Jay A. Baker, MD
Regina J. Hooley, MD
Vilert A. Loving, MD, MMM
Jocelyn A. Rapelyea, MD



American College of Radiology™

TABLE OF CONTENTS

PREFACE 186

INTRODUCTION 188

I. GENERAL CONSIDERATIONS 190

A. BREAST ANATOMY 190

B. IMAGE QUALITY 201

C. LABELING AND MEASUREMENT 220

D. DOCUMENTATION 223

E. HANDHELD VS. AUTOMATED AND PHYSICIAN- VS. TECHNOLOGIST-PERFORMED 225

II. BREAST IMAGING LEXICON — ULTRASOUND 227

A. TISSUE COMPOSITION 229

B. MASSES 242

C. NON-MASS LESIONS 350

D. CALCIFICATIONS 374

E. ASSOCIATED FEATURES 383

F. SPECIAL CASES 418

G. LYMPH NODES 452

H. LOCATION OF FINDING 471

III. REPORTING SYSTEM 472

A. ASSESSMENT CATEGORIES 472

B. REPORT ORGANIZATION 476

C. WORDING OF REPORT 480

IV. GUIDANCE 481

A. TISSUE COMPOSITION 481

B. BREAST ULTRASOUND LEXICON 481

C. LYMPH NODES 483

V. FREQUENTLY ASKED QUESTIONS 484

APPENDIX A — ULTRASOUND LEXICON SUMMARY FORM 488

PREFACE

The BI-RADS v2025 Manual on Ultrasound is an extension of the prior editions. Since the publication of the 5th Edition of BI-RADS (second version for the ultrasound section) in 2013, much has taken place that has solidified the role of ultrasound as indispensable in breast imaging. Breast density reporting laws have now been enacted in most states. The U.S. Congress has passed a federal law mandating the reporting of breast density, and the U.S. Food and Drug Administration has updated its regulations to require patient notification of breast density. This requirement became effective on September 10, 2024 in all 50 states. With the increasing reporting of breast density (based on mammography), supplemental screening with ultrasound is increasingly practiced. Supplemental ultrasound takes place in different forms around the world – handheld performed by technologist versus physician, or automated breast ultrasound. We took into account both methods when discussing screening ultrasound in this version.

A new element in this version of BI-RADS is the assessment of breast composition at ultrasound. Increasingly, studies are revealing that ultrasound assessment of breast tissues not only may influence detection but also indicate risk. This is particularly significant in practices around the world where ultrasound is being performed as a screening modality (and perhaps even the sole screening modality). Like MRI where there is assessment of degree of enhancement in addition to tissue composition, we are proposing in ultrasound that the both the echotexture pattern and the glandular tissue content may play a clinical role in assessment of risk and in the detection and characterization of breast lesions.

BI-RADS is at its heart a lexicon, and its role as a language remains very much at play. Hence, assessment and fine-tuning of the lesion descriptors is always an important task in updating BI-RADS. In this version, we are introducing (or re-introducing) the term mixed solid and cystic mass, the mass shape of lobulated, and echogenic rind as an associated feature. "Mixed solid and cystic" emphasizes the relative importance of the solid component. In ultrasound, we know that shape is an important consideration in communication, and we feel that having lobulated as a shape in addition to oval, round, and irregular allows for more precise and meaningful communication. Echogenic rind is being used to connote the reaction in the surrounding tissues that may accompany some cancers. The word rind is meant to invoke a sense of import and weight.

Significantly, a new finding category termed non-mass lesion is introduced. With the advances in imaging technology, increasingly nuanced findings are detected, some of which may represent subtle malignancy. We recognize that the non-mass lesion may be a challenging lesion to detect; this is not simply heterogeneous breast tissue but a discrete finding. By creating this category, we hope to expand the utility of ultrasound in diagnosing infiltrative pathologies including lobular and in-situ breast cancers, which may currently elude ultrasound detection. Furthermore, this category may support the clinical implementation of newer modalities such as digital breast tomosynthesis (DBT), molecular breast imaging (MBI), or CEM, by recognizing non-mass sonographic correlates to imaging findings initially detected on other modalities and thus facilitating biopsy using ultrasound as imaging guidance.

In this Manual, the discussion of lymph nodes has expanded in depth and scope. Nearly all breast cancers spread via the lymphatic system, so the importance of evaluating lymph nodes cannot be over-emphasized. Ultrasound is arguably the most important modality in the evaluation of nodes, especially given its accessibility and utility as a means of biopsy guidance. We describe the spectrum of morphological changes when a node is involved by tumor, along with the anatomy of the various regional nodal basins that constitute nodal staging in the TNM (tumor/node/metastasis) system.

As in prior editions, each image legend describes several features of the imaging finding, with those capitalized signifying the dominant feature being illustrated. Additional descriptors in the legend will be included in lower case (e.g., "ROUND, circumscribed, hypoechoic mass"). Where possible, the biopsy-proven pathology of the finding will be included. Occasionally, multiple descriptors might apply to a finding in the illustration and will be additionally described in the legend. For example, a mass may include both circumscribed and indistinct margination. While more than one descriptor may be included for the purpose of illustration, a single management recommendation should be made based on the most suspicious finding(s) present. As with the mammography and MRI sections, the ultrasound lexicon descriptors within a given category in this BI-RADS Manual are arranged from least to most suspicious, where appropriate.

Committee on BI-RADS®
American College of Radiology
RADS@acr.org

Jessica W. T. Leung, MD, FACR, FSBI
Chair, Subcommittee on BI-RADS® Ultrasound

INTRODUCTION

As ultrasound equipment improves and as the evidence-based approach to managing sonographic findings expands, the terminology used to describe breast US findings evolves. The importance of ultrasound as a modality for correlation with imaging findings identified at mammography, contrast-enhanced mammography (CEM), breast MRI, and other cross-sectional modalities is well-established, along with the use of ultrasound as a guidance method for percutaneous biopsy. It is crucial that an established, standardized lexicon is used for clear, concise, and meaningful reports and to achieve optimal patient care. The descriptive terms and definitions contained in the lexicon have been approved by the ACR Subcommittee on BI-RADS® Ultrasound. The subcommittee based its recommendations on published evidence whenever possible, with the understanding that clinical practices may differ depending on local factors. Additionally, it is certain that the field of breast ultrasound will continue to evolve. Modifications in existing terminology and/or new terminology will be considered as indication arises. If you would like to propose a substantive change, please submit it to the ACR for review by the Committee on BI-RADS, using the contact information mentioned in the preface.

The ACR BI-RADS® — Ultrasound is divided into five sections with an appendix at the end.

SECTION I: General Considerations

SECTION II: Breast Imaging Lexicon — Ultrasound

SECTION III: Reporting System

SECTION IV: Guidance

SECTION V: Frequently Asked Questions

APPENDIX A — Ultrasound Lexicon Summary Form

The following are brief summaries of each section.

I. General Considerations

This section discusses the anatomy of the breast, imaging quality issues and techniques, labeling of the images and measuring of the findings, and documenting results of the examination.

II. Breast Imaging Lexicon — Ultrasound

Ultrasound is indispensable in breast imaging. The lexicon offers a set of standardized terms along with numerous examples of how and when to use these terms. In this version, nearly all the ultrasound images are new. The Subcommittee on BI-RADS Ultrasound believes that uniform and widespread use of these descriptors will facilitate radiologists around the world in communicating results clearly and efficiently to their colleagues, other physicians, and their patients.

III. Reporting System

Breast ultrasound examinations may be reported as a stand-alone entity or in combination with mammography. As data become increasingly available for both the screening and diagnostic outcomes of breast ultrasound, regular audits including ultrasound are encouraged to ensure quality and optimize patient care.

Utilizing an organized approach to reporting breast ultrasound facilitates image interpretation and patient management, and it forms the basis for the audit downstream. Software-based

reporting systems are now widely available, many of which are incorporated in the electronic medical records of health systems.

Report Organization

Appropriate and consistent use of the standardized terminology is fundamental in achieving quality reports. The BI-RADS approach to reporting breast imaging examinations categorizes the overall composition of the breast and then describes masses by their shape, orientation, margin, echo patterns, and posterior features. In this version, the non-mass lesion is introduced, and such lesions may be described by their distribution, echo pattern, and any associated features. The findings are then evaluated and an assessment determined that includes the degree of suspicion for malignancy. Finally, the report indicates the pertinent management recommendation(s). Thus, the breast US report should be divided into:

1. **INDICATION FOR EXAMINATION**
2. **COMPARISON TO PREVIOUS EXAMINATION(S), IF ANY**
3. **STATEMENT OF SCOPE AND TECHNIQUE OF BREAST US EXAMINATION**
4. **SUCCINCT DESCRIPTION OF THE OVERALL BREAST COMPOSITION** (whole-breast ultrasound only)
5. **CLEAR DESCRIPTION OF ANY IMPORTANT FINDINGS**
6. **COMPOSITE REPORTS, IF APPLICABLE**
7. **ASSESSMENT**
8. **MANAGEMENT RECOMMENDATIONS**

Note: Assessment and management may be uncoupled from each other.

Note: Breast ultrasound examination may be reported in combination with mammography as a combined report, or it may be reported as a stand-alone examination. Whether in combination with mammography or not, the structure of the report should follow the general guidelines to ensure clarity and effectiveness.

IV. Guidance

The guidance section explains changes made in this version pertaining to BI-RADS Ultrasound. This chapter is intended to clarify through examples some of the confusing or controversial situations that are encountered in clinical practice.

V. Frequently Asked Questions

Frequently asked questions are addressed.

APPENDIX A — Ultrasound Lexicon Summary Form

The appendix contains a form for recording the findings of an US examination with the appropriate BI-RADS terminology in a simple checklist. The BI-RADS ultrasound terms are presented in an organized manner with definitions for each term. This form also contains the BI-RADS assessment categories.

I. GENERAL CONSIDERATIONS

A. BREAST ANATOMY

The breast is located on the chest wall between the second and sixth ribs within layers of the superficial pectoral fascia. The fat and fibroglandular tissues of the breast lie between the superficial layer of this fascia just beneath the skin and the deep layer of the fascia just anterior to the pectoral major muscle (Figure 1).

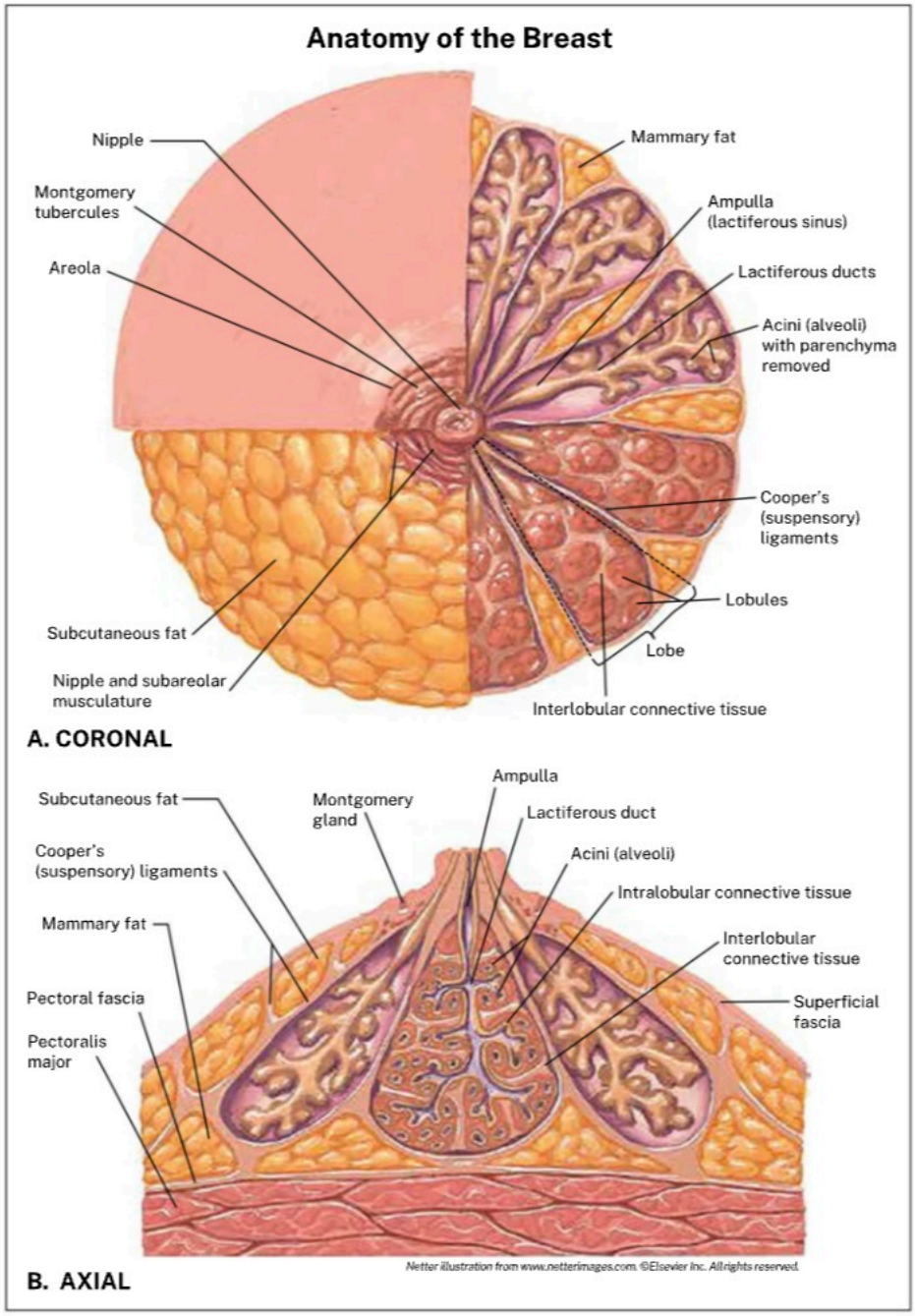

Figure 1 – NORMAL BREAST ANATOMY. Diagram of breast anatomy in coronal plane (A) and axial plane (B).

The breast is comprised of approximately 12 to 20 sections or lobes. Each lobe consists of multiple smaller lobules (i.e., the fibroglandular tissue that if properly stimulated by hormones produces milk). The lobules start with small peripheral branches and end in a large collecting duct, its punctum visible on the nipple (Figure 2). The most peripheral ducts, the intra-lobular terminal ducts, end in terminal duct lobular units (TDLUs) that give rise to common malignant and benign pathologies.

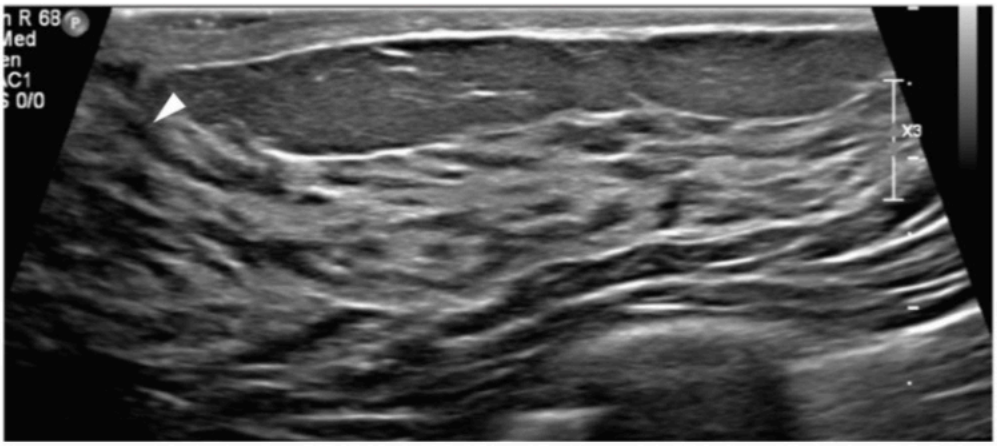

Figure 2 – NORMAL BREAST ANATOMY. Radial view shows the normal anatomy of a lactiferous duct from its lobules at the periphery, arching anteriorly (arrowhead) towards the nipple. The duct is within the fibroglandular zone of tissue beneath a layer of fat.

Breast development (thelarche) often marks the beginning of female puberty (Figure 3). The female breast at puberty resembles gynecomastia in a male with hypoechoic tissue immediately posterior to the nipple. Because these young patients ordinarily do not undergo mammography, it is important not to misinterpret the hypoechoic retroareolar breast bud as an abnormality requiring biopsy. This area should be recognized as normal for this age group; if it is removed surgically, the breast will not develop.



Figure 3 – NORMAL BREAST ANATOMY – PUBERTAL. Expected hypoechoic tissue immediately posterior to the nipple (arrow).

The arterial supply to the breast is provided by the subclavian and axillary arteries and their lateral thoracic, thoracoacromial, superior thoracic, and internal mammary branches. The venous vasculature lies predominantly just deep to the skin. Over 90% of the lymphatics of the breast drain into the ipsilateral axilla, with a small percentage draining into the internal mammary chain. In patients who have had axillary dissections or mastectomies extending into the axilla, lymphatic drainage may cross to the contralateral axilla.

The axilla contains lymph nodes, the brachial plexus, and the axillary artery and vein. The number and size of normal axillary lymph nodes vary widely from individual to individual. There is no upper limit of size for a normal axillary lymph node if the cortex remains appropriately thin. Cortical thickness is an imperfect measure of lymph node benignity, but most normal nodes have a cortex no thicker than 3 mm [1]. Side-to-side symmetry of size, shape, and number of nodes may help distinguish normal from abnormal. Nodes may be depicted in the axillae on mammograms; commonly two, three, or more can be identified as circumscribed oval, often reniform, masses with hilar fat and cortices of soft tissue density. With US, normal axillary or intramammary lymph nodes have echogenic fatty hila and cortices that are typically hypoechoic (Figure 4).



A

Figure 4 – NORMAL AXILLARY LYMPH NODE. Transverse plane (A) of a lymph node of normal size, cortical thickness, and echogenic hilus, resembling a miniature kidney.

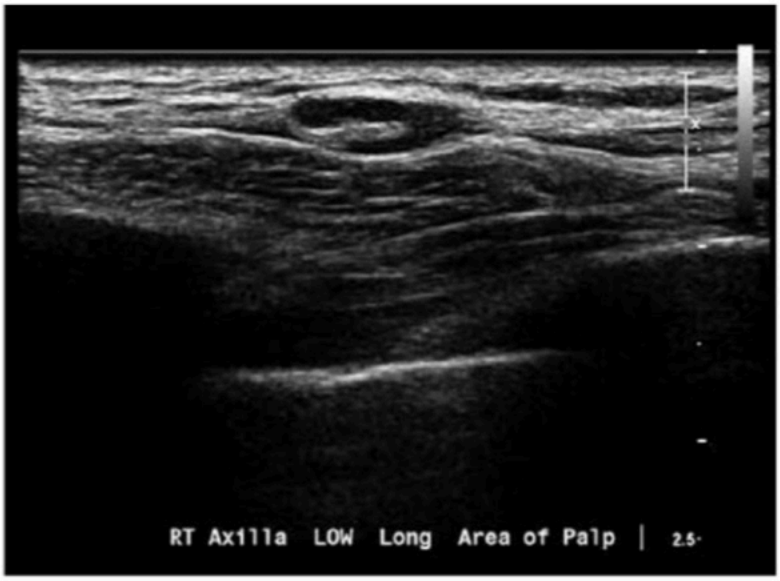

B

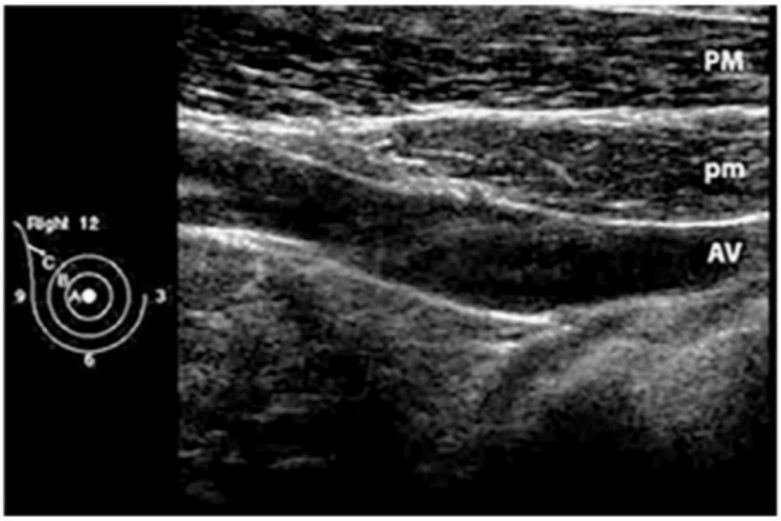

C

Figure 4 – *(Continued)* NORMAL AXILLARY LYMPH NODE.
(B) Longitudinal plane of a lymph node of normal size, cortical thickness, and echogenic hilus, resembling a miniature kidney.
(C) Pectoralis major (PM) muscle is shown anterior to pectoralis minor (pm) muscle with axillary vein (AV) deep to both.

A. BREAST ANATOMY

1. NIPPLE AND AREOLA

The nipple-areolar complex is quite variable with areola diameter differing widely among patients based in part on patient age and breast size, making the nipple a more reliable landmark than the areola [2]. Normal nipples can be prominent, flat, or inverted. If an abnormality of the nipple is suspected, comparison can be made to the contralateral breast. The nipple's crevices and irregular surface may cause posterior shadowing during ultrasound scanning. A thick layer of gel may provide a medium for clear depiction (Figure 5), but often the tissue behind the nipple and areola are best imaged at an obliquity so as not to image directly through the nipple. The skin of the areola tapers as the areola radiates out from the nipple. The thickness of normal skin over the breast is up to 2 mm except for the region of the areola and inframammary fold, where the skin is normally a little thicker [3].

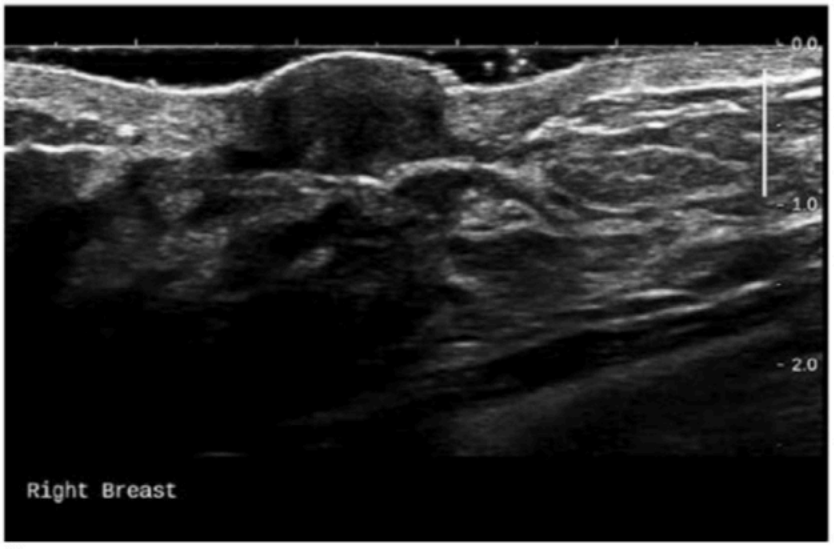

A

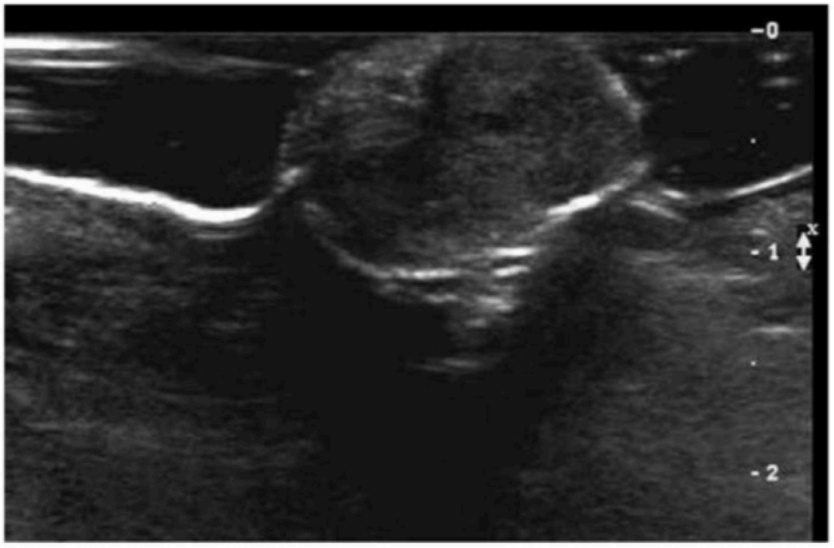

B

Figure 5 – ANATOMY: NIPPLE AND UNDERLYING BREAST TISSUE. The size and appearance of the nipple are variable, from inverted to flat to protuberant. A gel offset (A and B) enables the skin and superficial tissue to be seen. The nipple is normal (A). If there is concern for abnormality, comparison with the contralateral side is helpful in decision making. Nipple is enlarged due to mucinous carcinoma contained within it (B).

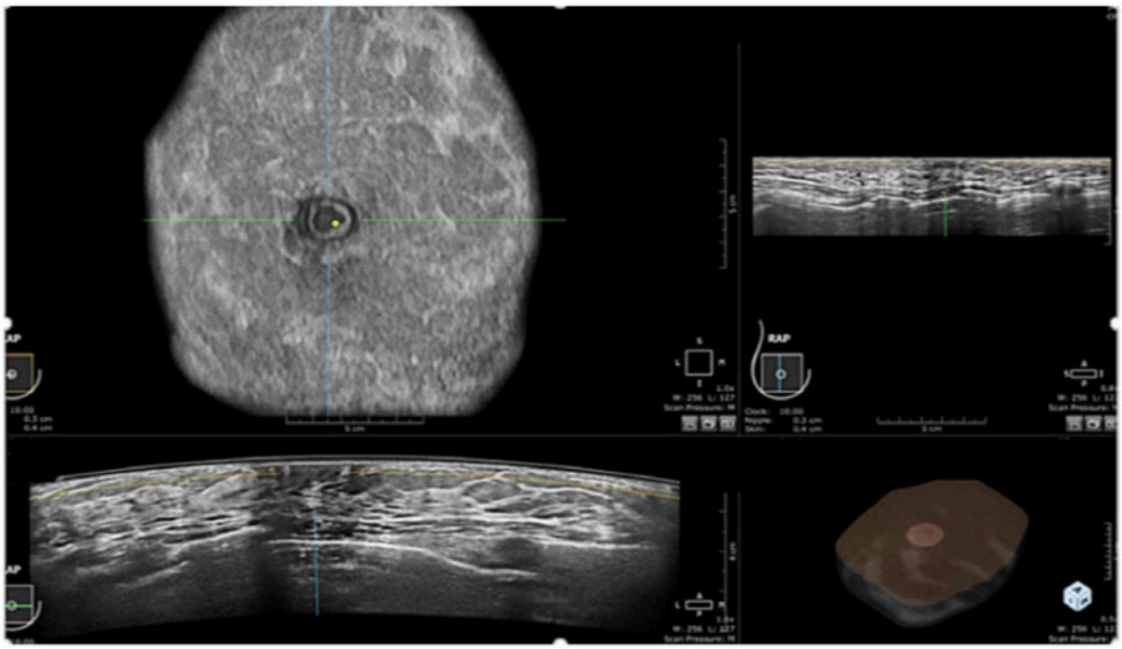

Figure 6 – ANATOMY: NIPPLE AND UNDERLYING BREAST. Automated supine whole-breast scan. Upper left image: coronal reconstruction (z-plane); upper right image: sagittal reconstruction (Y-plane). 3D reconstruction of the full thickness of the breast is in the bottom right. B-mode acquisition (X-plane or transverse) centered over normal nipple is on bottom left. The tissue beneath the nipple is not obscured by shadowing as is often the case with handheld US.



Figure 7 – ANATOMY. Ultrasound image of the breast demonstrates the layered appearance of normal breast anatomy. From superficial to deep, the image demonstrates the skin, subcutaneous fat (subQ), fibroglandular zone (fgz) with breast lobules, retroglandular fat (retro), and pectoralis muscle (pec).

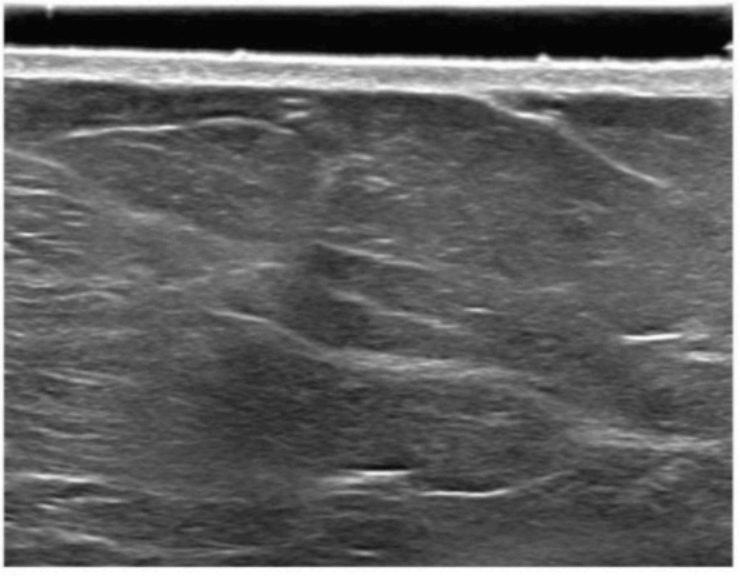

A

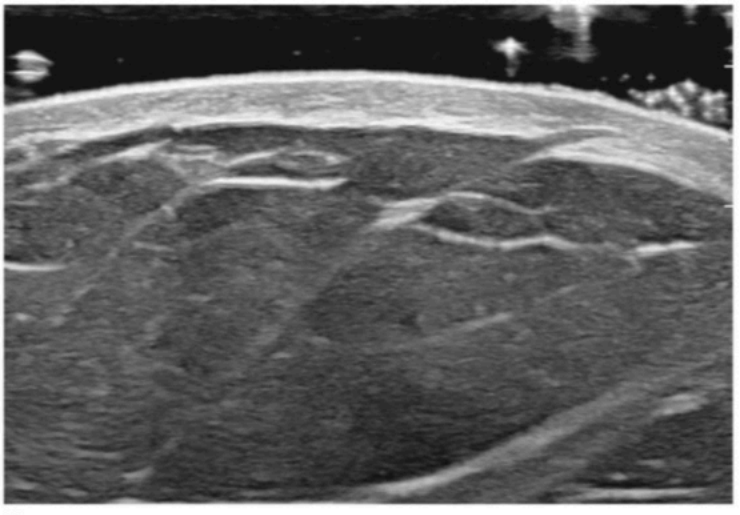

B

Figure 8 – ANATOMY: NORMAL SKIN COMPLEX. Imaging performed at 18 MHz (A) and 26 MHz (B). Two echogenic lines define a less hyperechoic layer whose total thickness is ≤ 2 mm, except in the periareolar region or inframammary fold where it may be thicker. A gel offset enables the upper layer of skin to be seen. The focal zone should be set superficially when evaluating the skin.

A. BREAST ANATOMY

2. LOCATION OF FINDINGS

The layered appearance of normal breast anatomy provides landmarks that assist in finding a mass initially identified on other imaging modalities or physical examination. In order from superficial to deep, the layers of the breast include: echogenic skin, isoechoic subcutaneous fat which includes Cooper's ligaments, the echogenic fibroglandular zone, and isoechoic retroglandular fat. All this tissue overlies the isoechoic pectoralis major muscle. When describing the location of a suspected mass, asymmetry or distortion identified on mammography, noting the tissue layer in which the finding is located can be more useful than reporting its apparent depth or precise distance from the nipple estimated on mammographic views while the breast is under compression (Figures 1–4 below). Distance from the nipple may be estimated as anterior, middle, or posterior third of the breast.

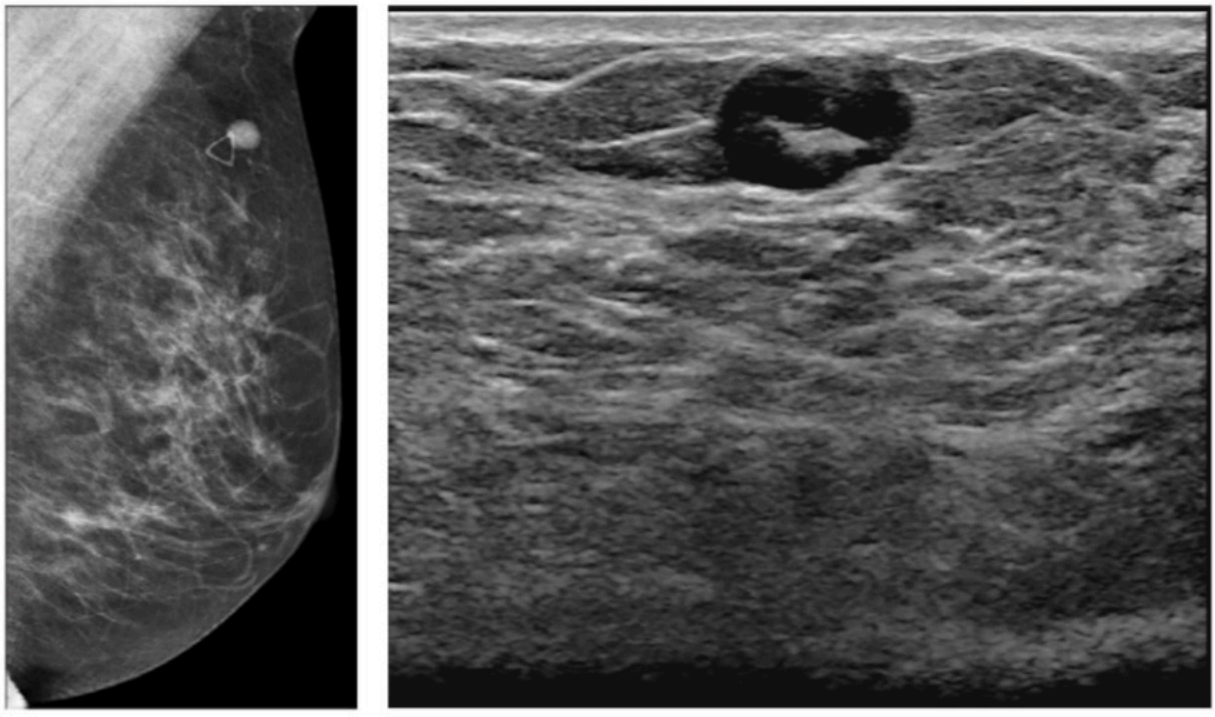

A B

Figure 1 – LOCATION. When reporting the location of a finding identified on mammography or MRI, a radiologist can help the sonographer identify the corresponding structure on ultrasound by describing not only the clock position but also the layer of tissue in which the lesion is located. MLO mammogram (A) shows an oval circumscribed mass in the subcutaneous fat (triangle marker). This location is confirmed on ultrasound (B). Pathology: Reactive intramammary lymph node.

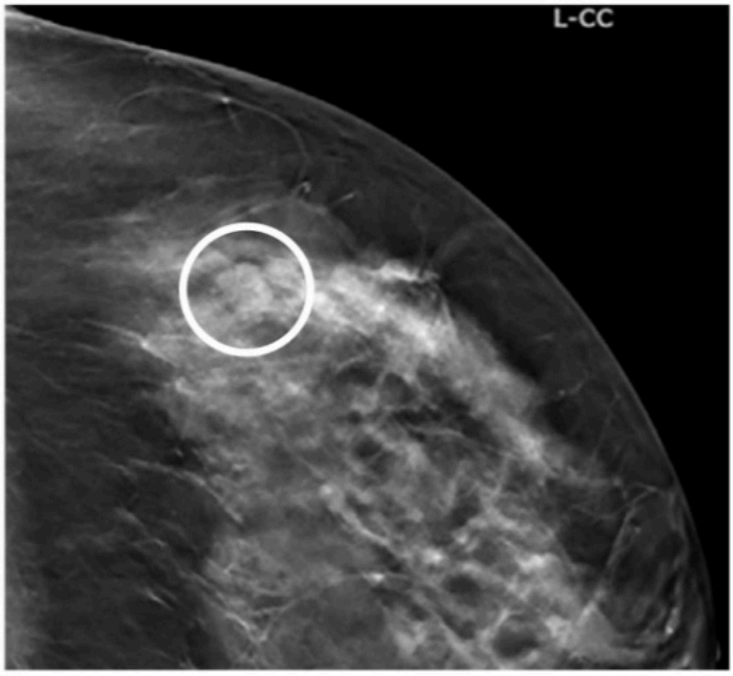

A

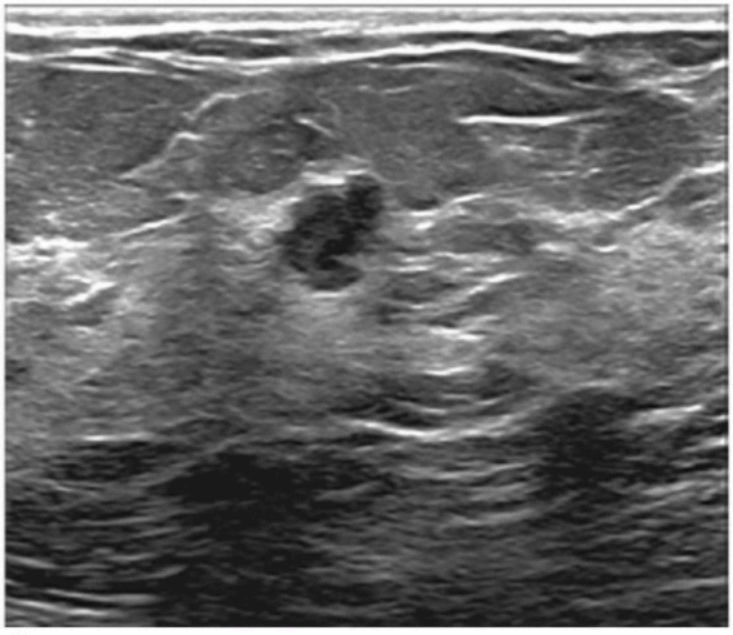

B

Figure 2 – LOCATION. Mass identified in the left breast on this DBT slice (A) is within the fibroglandular tissue (circled). Corresponding ultrasound image (B) demonstrates an irregular indistinct mass within the fibroglandular zone. Knowledge of the precise tissue layer provides additional confirmation that the mammographic and sonographic finding are, in fact, the same mass. Pathology: Fibroadenoma.

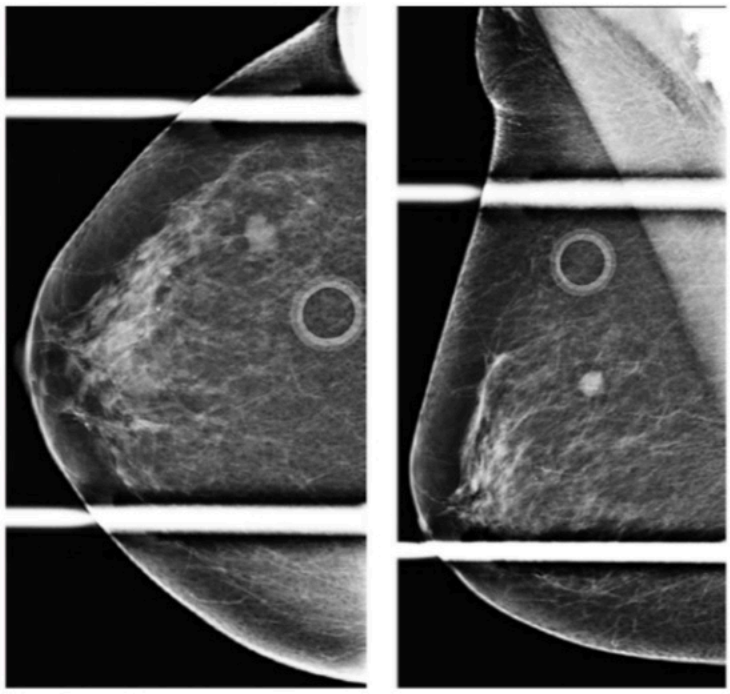

A B

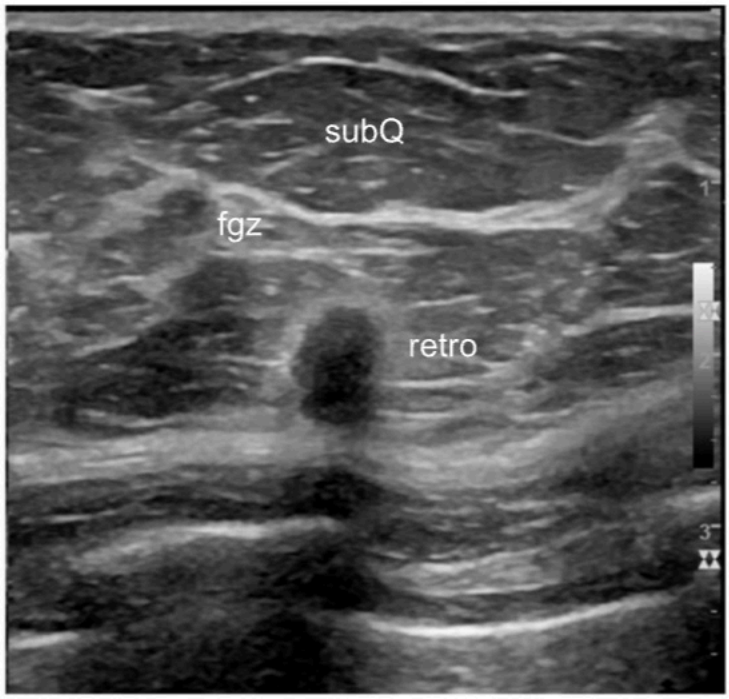

C

Figure 3 – LOCATION. Mass identified in the right breast on CC (A) and MLO (B) spot compression views is in the retroglandular fat. (Circle present in both (A) and (B) is a marker on the skin denoting the presence of a mole.) Corresponding ultrasound image (C) demonstrates a non-parallel mass with an echogenic rind in the retroglandular fat (retro). Pathology: Invasive ductal carcinoma.

In addition to the layers themselves, the boundary or interface between layers makes a useful landmark to localize a breast mass (Figure 4).

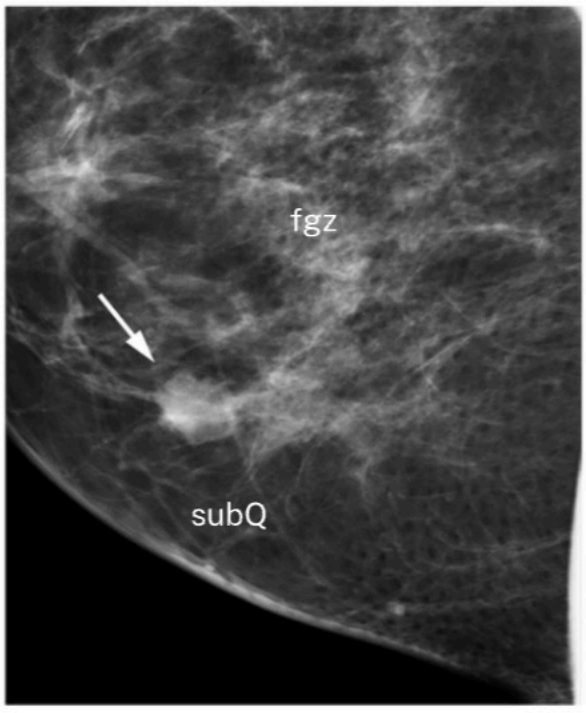

A

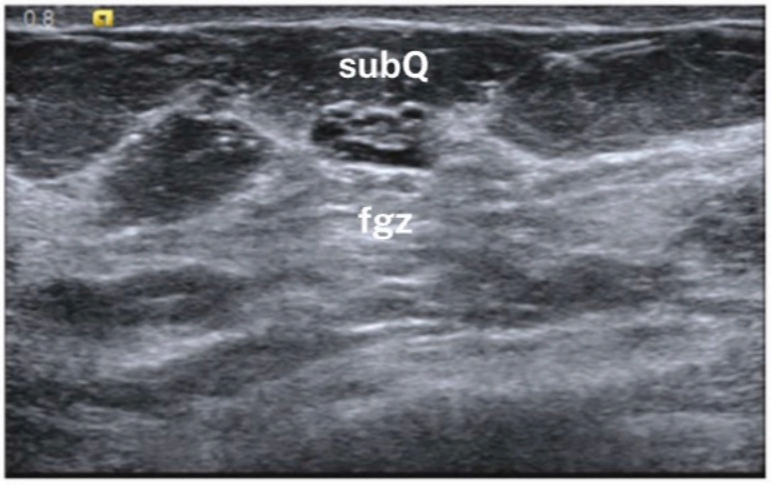

B

Figure 4 – LOCATION. Mass (arrow) in the right breast on ML mammogram (A) is located at the interface between the subcutaneous fat and fibroglandular tissue. On the corresponding ultrasound image, the mass is a cluster of microcysts also at the interface between the subcutaneous fat (subQ) and the fibroglandular zone (fgz). Recognizing interfaces between tissue layers can help localize and confirm the location of a mass identified at mammography or MRI.

B. IMAGE QUALITY

The value of ultrasound relies on creating the highest quality images.

Handheld, high-frequency breast ultrasound exams largely depend on operator skill, equipment quality, and optimal configuration of the ultrasound system's image parameters. Poor US image quality can lead to serious misinterpretations such as mistaking a cancer for a cyst.

Optimizing the transducer frequency, field of view (FOV), dynamic range, gain, and focal zone settings can correctly differentiate benign from suspicious findings and improve diagnostic accuracy. Doppler settings are also useful to determine the presence of blood flow; any mass within which blood flow can be demonstrated is not a cyst. However, care must be taken to scan without too much compression that may reduce or prevent detection of slow vascular flow in the breast. Compression may even make vascular masses appear avascular.

1. TRANSDUCER FREQUENCY AND PRESSURE

   The ACR Practice Parameter for the Performance of a Diagnostic Breast Ultrasound Examination recommends a transducer with a broad bandwidth operating at a center frequency of at least 12 MHz and preferably higher [4]. A high-frequency ultrasound transducer provides superior contrast and spatial resolution but has less penetration. Typically, breast ultrasound is performed with the highest frequency linear transducer available. In contrast, lower frequency transducers provide greater tissue penetration but have a lower resolution. Therefore, when evaluating deep tissue in patients with large breasts, it may be helpful to select lower frequency settings for the beam to penetrate tissue and provide better characterization.

   Higher frequency sound waves are more strongly attenuated by breast tissue than lower frequency waves. With proper positioning, most breasts in the supine or supine-oblique position are only a few centimeters thick, and high frequencies can provide optimal image quality for all the breast tissue.

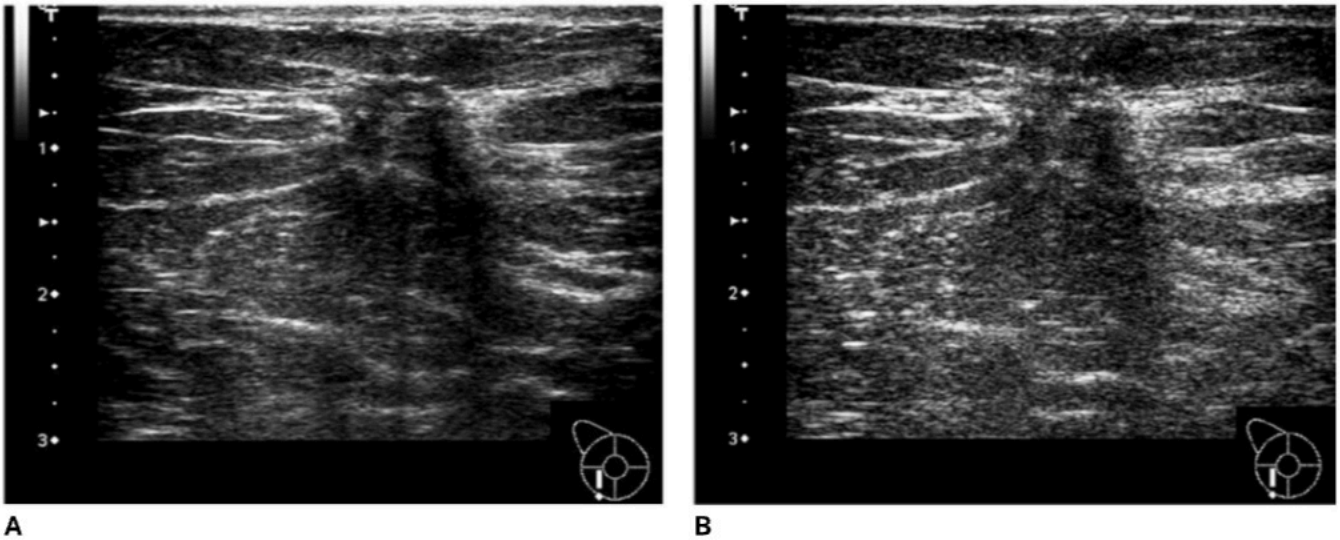

A B

Figure 1 – IMAGE QUALITY: TRANSDUCER FREQUENCY. Margin and surrounding architectural distortion of this irregular mass (longitudinal view) with transducer operating at 7.2 MHz (A) is less well characterized than same mass (B) imaged at 14 MHz. Cicatrization the Cooper's ligaments is more conspicuous and the indistinct margin of the mass more confidently characterizable due to improved resolution of the higher frequency transducer. Pathology: Invasive ductal carcinoma.

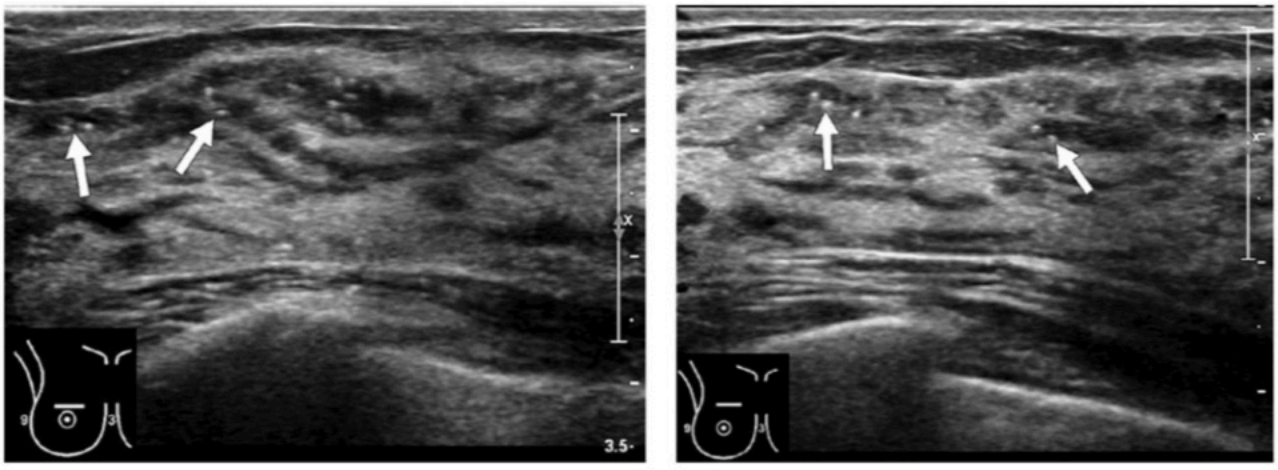

A B

Figure 2 – IMAGE QUALITY: TRANSDUCER FREQUENCY. The image obtained with a linear transducer with frequency range of 12–5 MHz is diagnostic (A) but greatly improved with a transducer whose frequency range is 17–5 MHz (B). In both images, the microcalcifications present within ducts (arrows) in the echogenic fibroglandular zone of tissue can be seen, but resolution of these particles and the ductal anatomy is better with the higher frequency probe.

Alternatively, a greater degree of compression can improve ultrasound wave penetration and reduce attenuation of the ultrasound beam. Compression with the ultrasound probe will reduce refractive shadowing and enhance image quality.

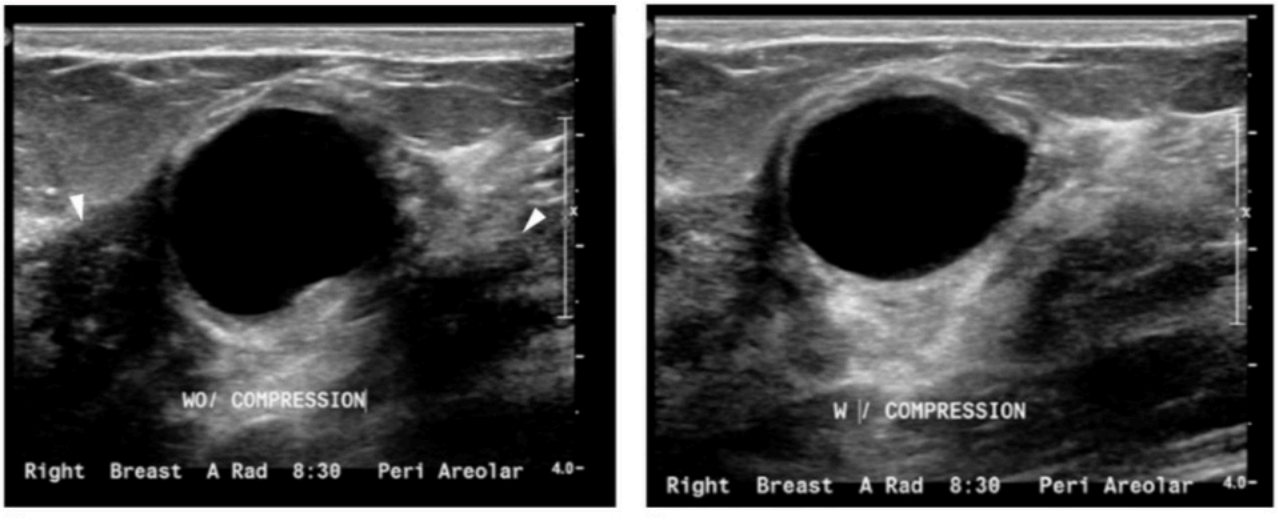

A B

Figure 3 – IMAGE QUALITY: TRANSDUCER PRESSURE. Antiradial images of an anechoic cyst with improved visualization of the margin characteristics in image (B) due to compression. The focal zone is properly located at the level of the cyst in (A), but artifactual acoustic shadowing in the adjacent fibrous tissue (arrowheads) is seen, resulting from insufficient compression while scanning. An increase in compression (B) improves visualization of the cyst margin as well as reducing artifactual acoustic shadowing in the surrounding fibrous tissue.

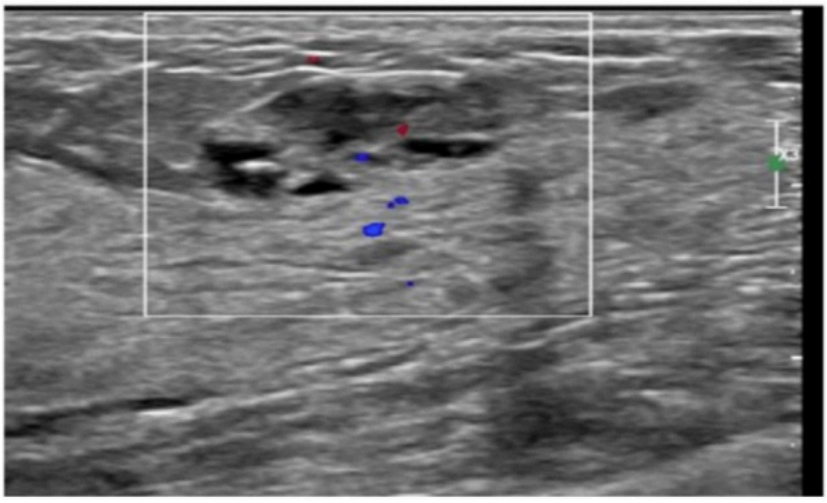

A

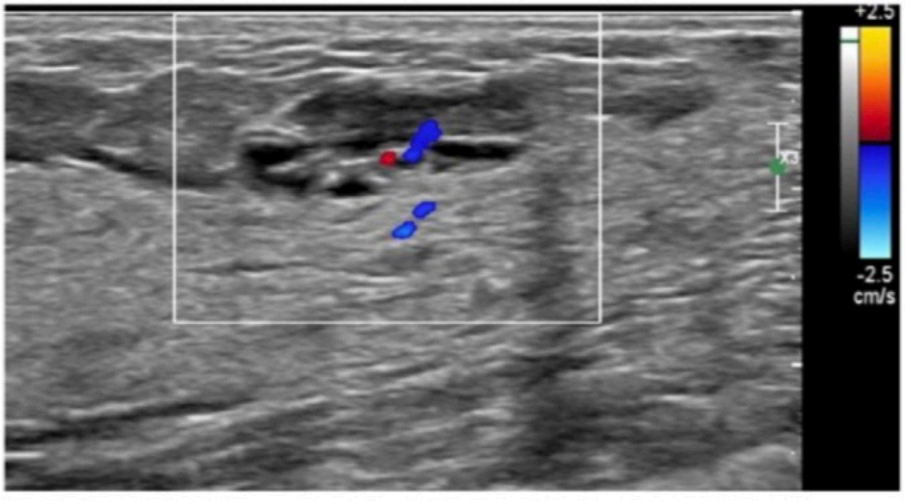

B

Figure 4 – IMAGE QUALITY: TRANSDUCER PRESSURE. Color flow images of a mixed solid and cystic mass. In image (A) compression results in a decrease in the depiction of vascularity of this lesion. With the same doppler frequency but less compression (B), there is more accurate depiction of slow flow vascular characteristics of the mass. Pathology: Fibroadenoma.

B. IMAGE QUALITY

2. FIELD OF VIEW (FOV)

Although a high-frequency transducer can improve resolution, technical parameters such as field of view (FOV) can enhance identification and extent of a lesion. FOV refers to the extent of tissue displayed on the monitor. The optimal setting will allow visualization of the skin to the pectoralis major muscle and does not include the pleura or the lung.

The depth displayed should be optimized to allow for the correct characterization of a lesion. Complete tissue inclusion and optimum resolution are needed for accurate interpretation. Excessive zoom and shallow depths can make the margin of the mass appear indistinct. Deep lesions may be missed because they are not included in the tissue image. If the FOV extends too deep, then the ability to detect and characterize superficial or small lesions is significantly reduced. Smaller findings appear significantly reduced in size and cannot be accurately portrayed.

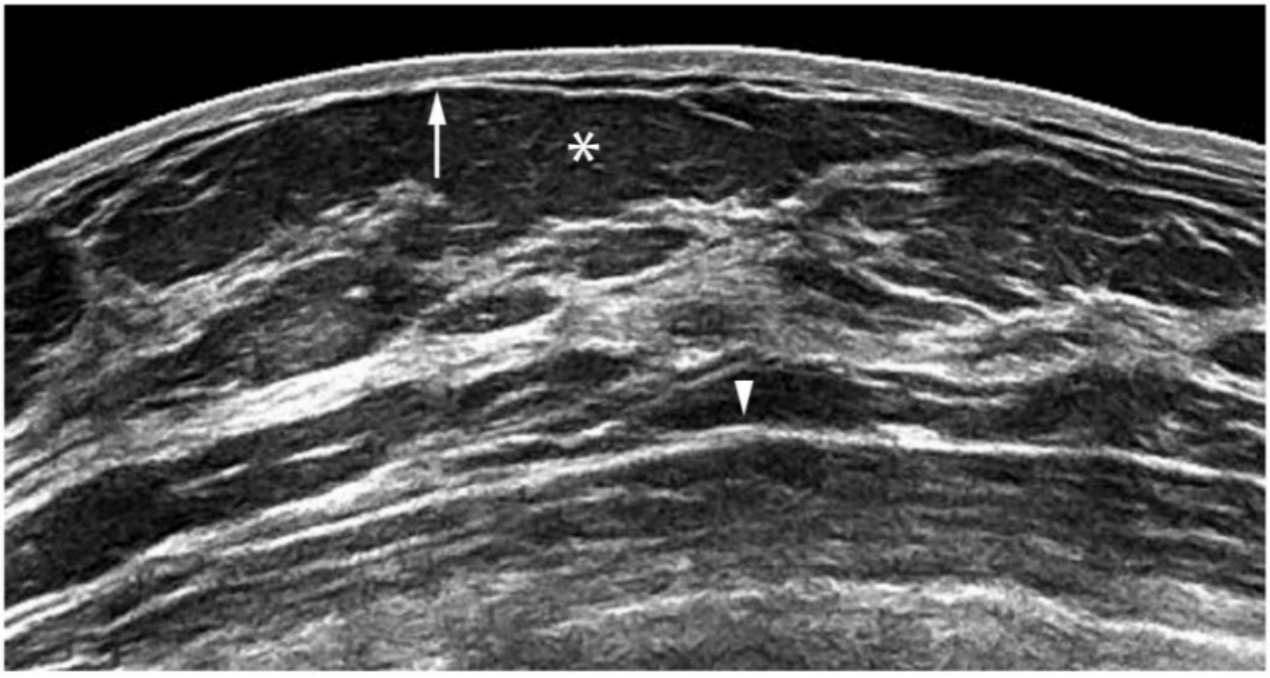

Figure 1 – IMAGE QUALITY: FIELD OF VIEW (FOV). Gray scale transverse extended FOV image of the breast demonstrates appropriate FOV with the skin (arrow) in the near field and the pectoralis major muscle (arrowhead) in the far field. The SubQ zone (*) demonstrates a medium gray appearance of the fat lobules, while the FGZ (located posterior to the SubQ zone) may have varying echogenicity depending on the amount of fibroglandular composition.

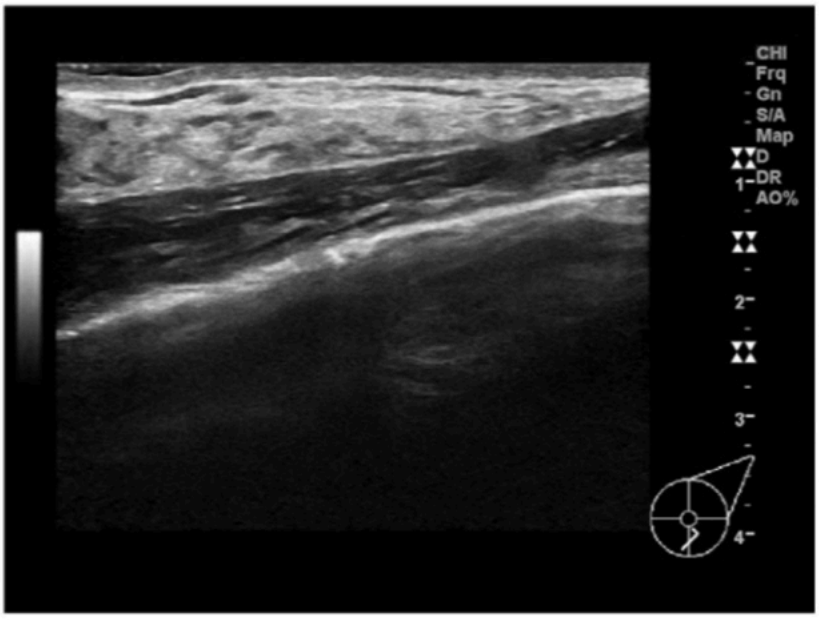

Figure 2 – IMAGE QUALITY: FIELD OF VIEW (FOV) too deep. Single suboptimal view of the left breast at 6:00 with tissue of interest (from the skin to the pectoralis muscle) occupying only 50% of the depth of the FOV. From a depth of 2–4 cm, there is no information related to the breast. The focal zones (marked by ⌘ icons) are also set too deep.



Figure 3 – IMAGE QUALITY: FIELD OF VIEW (FOV). Oval parallel complicated cyst with posterior acoustic enhancement. The focal zone is set at the cyst; however, the depth of FOV is suboptimal and too deep, including the ribs and pleura, which may cause mischaracterization and misinterpretation of this cyst.

Linear array transducers for breast imaging are typically between 4-5.5 cm in length allowing visualization of that length of breast tissue. Switching the display from rectangular to trapezoidal can improve visualization of larger findings, particularly deeper in the breast.

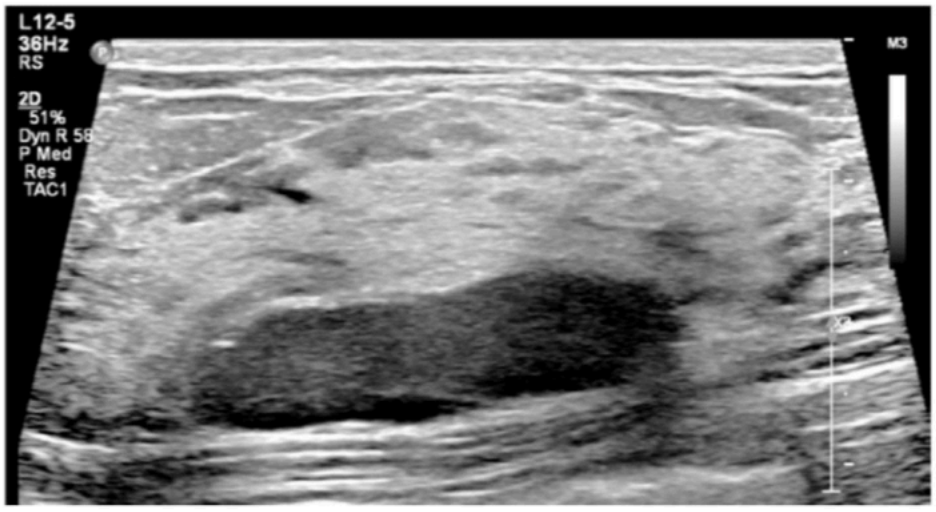

Figure 4 – IMAGE QUALITY: FIELD OF VIEW (FOV). Trapezoidal FOV is used to evaluate a 3 cm lobulated parallel hypoechoic circumscribed mass with posterior acoustic enhancement. FOV is set correctly to include pectoralis muscle but not lung. The focal zone is positioned at the level of the hypoechoic mass in the far posterior breast with adequate depiction of the mass and posterior features. Pathology: Fibroadenoma.



A



B



C

Figure 5 – IMAGE QUALITY: FIELD OF VIEW (FOV). (A) 5 cm isoechoic oval parallel mass corresponding to a palpable lump. The trapezoidal image in (B) allows for entire visualization of the mass compared to the rectangular image noted in (A). The extended field of view (EFOV) (C) gives improved characterization of the adjacent tissue along with the corresponding palpable mass.

For larger lesions, there are several methods that can be used to show the entire lesion in one image. Using split screen settings allows visualization of the right and left portions of a large mass or non-mass lesion, thus permitting an approximation of size of the region of interest. Activating split-screen format allows the capture of half of a large lesion or region, followed by activation of the second screen, and image capture of the other half of the lesion. An additional method termed extended field-of-view (EFOV), also known as panoramic view, is more comprehensive and displays the entire length of a lesion in one image and defines the lesion and its relationship with the surrounding tissue. EFOV imaging ensures visualization of far greater tissue than can be imaged with the length of a typical linear array transducer.

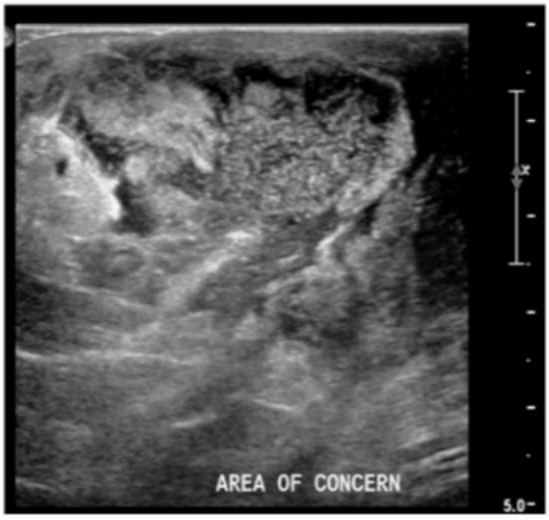

A

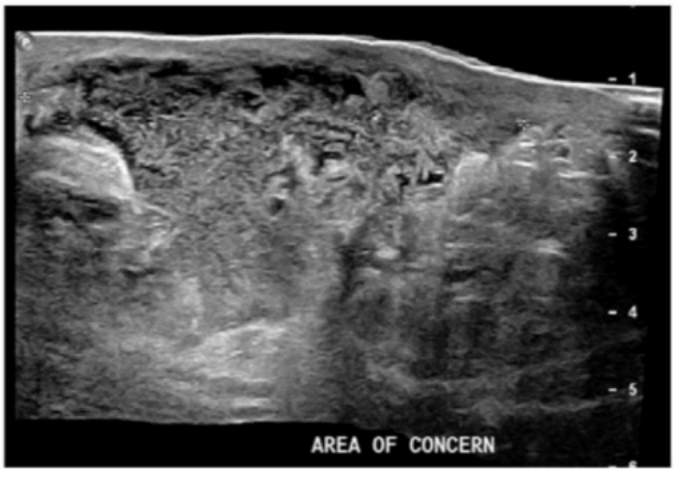

B

Figure 6 – IMAGE QUALITY: FIELD OF VIEW (FOV). Rectangular image (A) demonstrates a mixed solid and cystic mass with mobile debris noted on real time scanning. The EFOV (B) demonstrates the full extent of the fluid collection later proven to represent an abscess in a post-partum patient with recurrent mastitis. Pathology: Abscess.

A large EFOV can be obtained and is helpful to demonstrate the geographic relationship among multiple lesions or between a lesion and a structure such as the nipple. As with wide FOV automated US, freehand EFOV is also useful for imaging multiple masses as well as large lesions [5]. Such imaging improves global understanding of abnormal findings, particularly in the setting of multiple lesions.

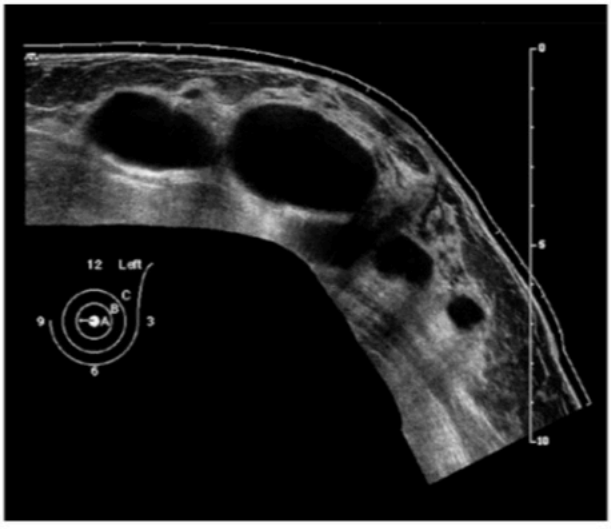

Figure 7 – IMAGE QUALITY: FIELD OF VIEW. The extended FOV (EFOV) sweep shows numerous simple cysts within the fibroglandular tissue.

In addition, volumetric acquisitions using 14–15 cm linear or curved transducers enable a broad sweep of tissue to be displayed in the axial plane with the capability of 3D reconstruction and visualization in the coronal and sagittal planes.

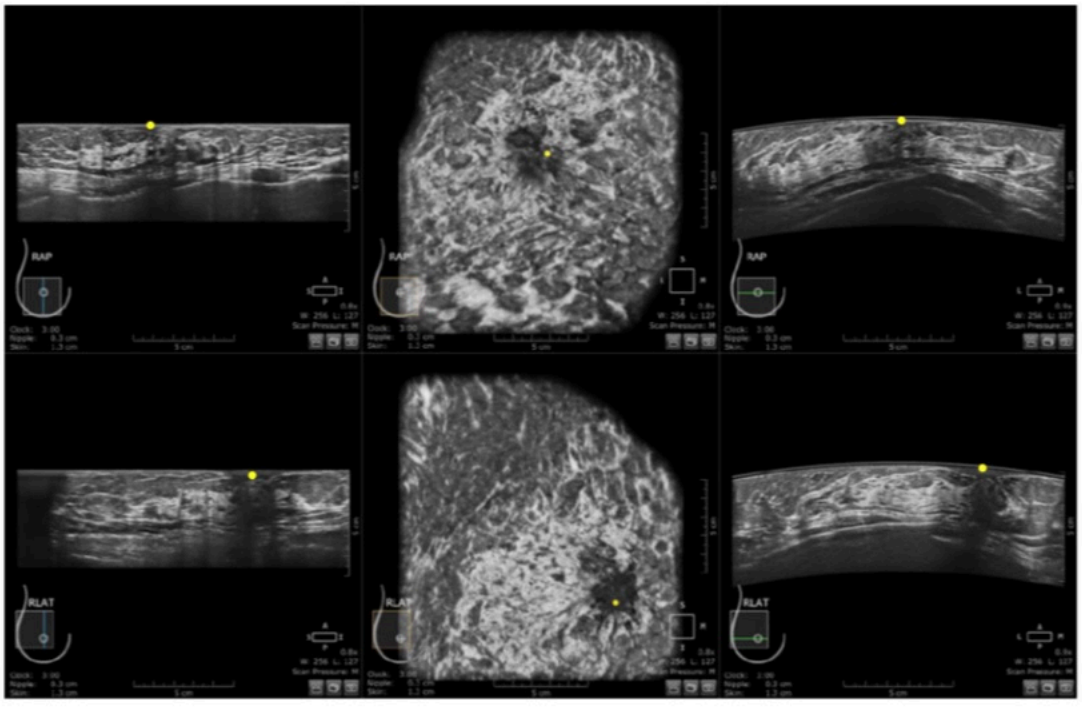

Figure 8 – IMAGE QUALITY: FIELD OF VIEW (FOV), volumetric acquisition. Planar visualization of breast anatomy using a 3D automated system demonstrates a reconstructed sagittal (left), reconstructed coronal volume (center) and acquired large FOV transverse images (right) using a 14–15cm transducer. Multiplanar visualization improves characterization of a lesion. The nipple areolar region is annotated with a yellow dot on all planes.

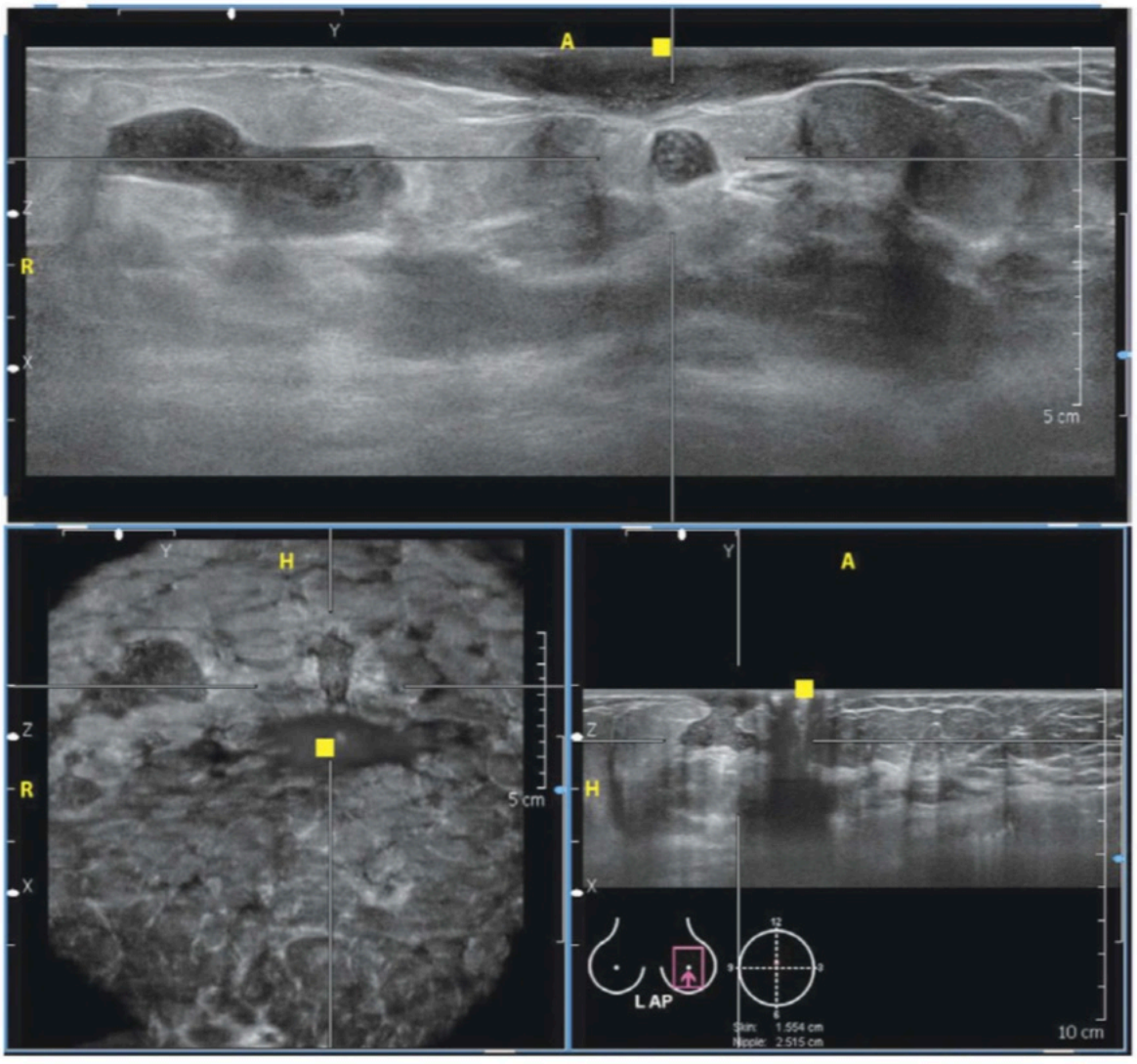

Figure 9 – IMAGE QUALITY: FIELD OF VIEW (FOV), volumetric acquisition. Patient with chronic, sterile abscesses. Large FOV B-mode transverse acquisition is illustrated (top) with coronal (lower left) and sagittal (lower right) reconstructed images. The yellow square indicates the location of the nipple, and the crosshairs are placed over a purulent collection shown in three orthogonal planes. Pathology: Granulomatous mastitis.

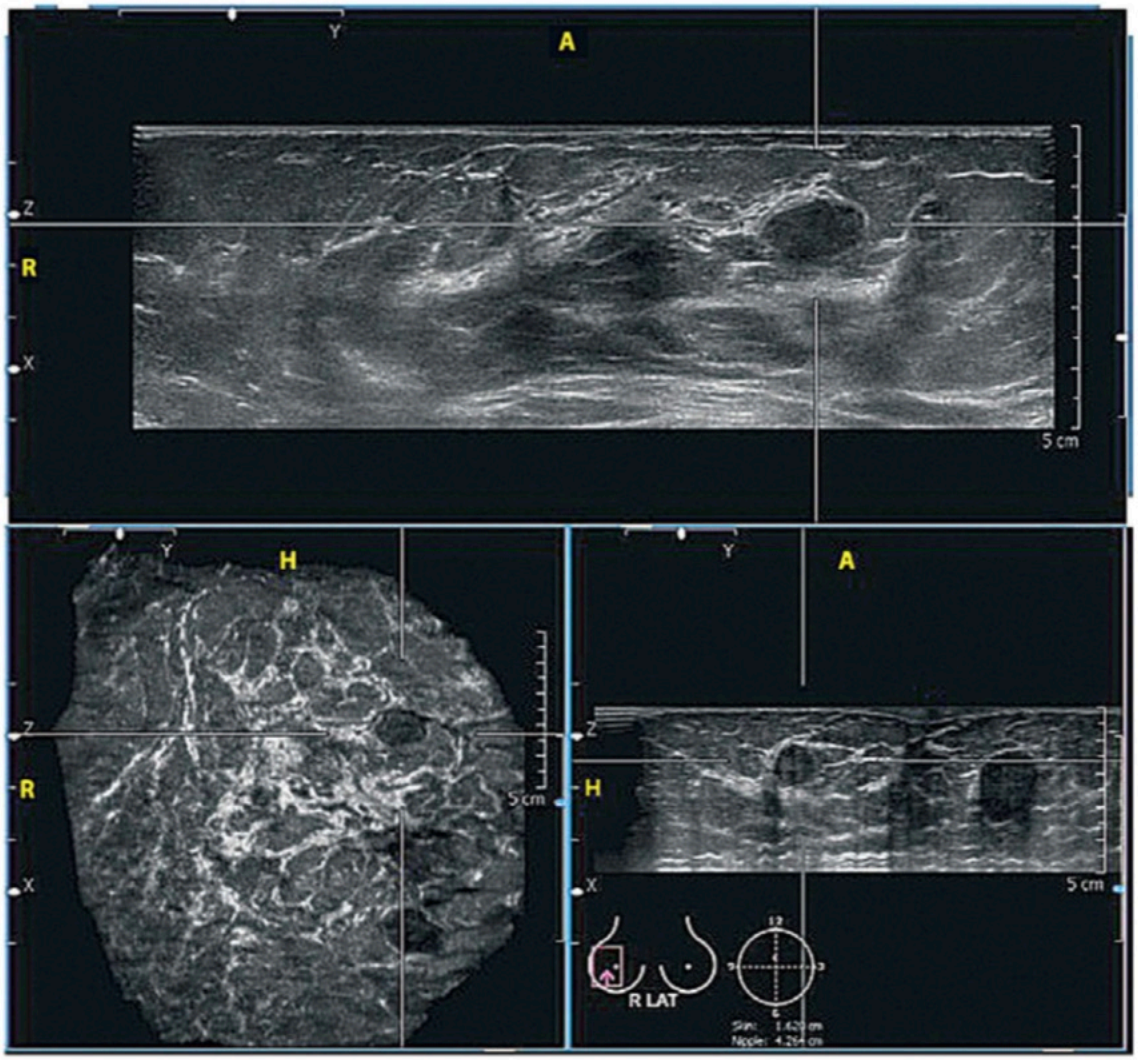

Figure 10 – IMAGE QUALITY: FIELD OF VIEW (large FOV volumetric acquisition). Supine automated US examination. Crosshairs intersect on a circumscribed, oval, parallel mass at 12:00. Top image is transverse, B-mode acquisition; lower left is coronal reconstruction with fibroglandular tissue being white and fat darker gray; lower right, sagittal reconstruction. Wider acquisition fields allow more of the local anatomy to be depicted along with effect, if any, on the surrounding tissue (none in this case). The volumetric acquisition also depicts the lesion in three orthogonal planes and can show distances between and relationships among multiple masses.

B. IMAGE QUALITY

3. FOCAL ZONE

To obtain an accurate characterization of normal and abnormal findings, the placement of the focal zone(s) in the anterior-to-middle third of the region of interest between the skin and chest wall improves the depiction and resolution of adjacent objects at similar depth. The discrimination of a lesion is best when the focal zone is positioned at the center of the lesion. Two to three focal zones or a single focal zone that has variable range will increase the resolution of the tissue imaged within that zone. However, in many systems, if more than three focal zones are used, the frame rate will be slowed significantly, making real-time scanning prohibitive. Modern systems have transducers that can be used with broad focal zone ranges that facilitate the rapidity of scanning large areas of the breast. If a targeted scan (focused on one specific finding) is being done, a single zone or narrow range can be set at the midlevel of the mass or area of interest. Artifacts and blur caused by poor placement of the focal zones can cause misinterpretation of breast lesions.

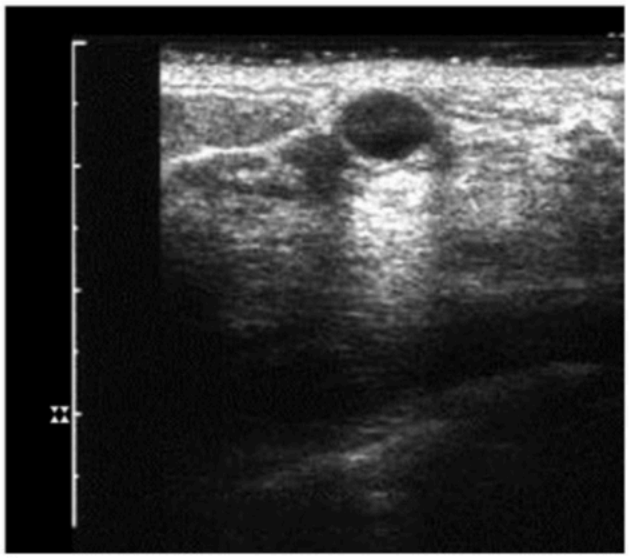

A

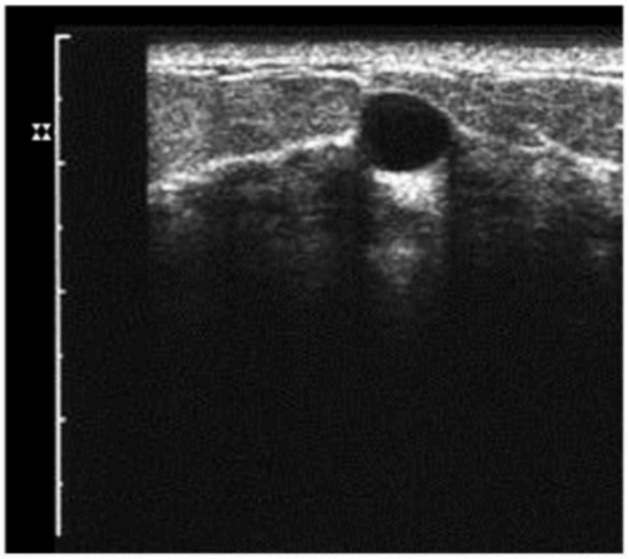

B

Figure 1 – IMAGE QUALITY: FOCAL ZONE. Focal zone (marked ⧗ icons) inappropriately positioned below the mass causing echoes to appear within its anterior half (A); with focal zone set properly in the midportion of the mass (B), its anechogenicity is unquestioned. The internal echoes seen in (A) are confirmed as artifactual.



A

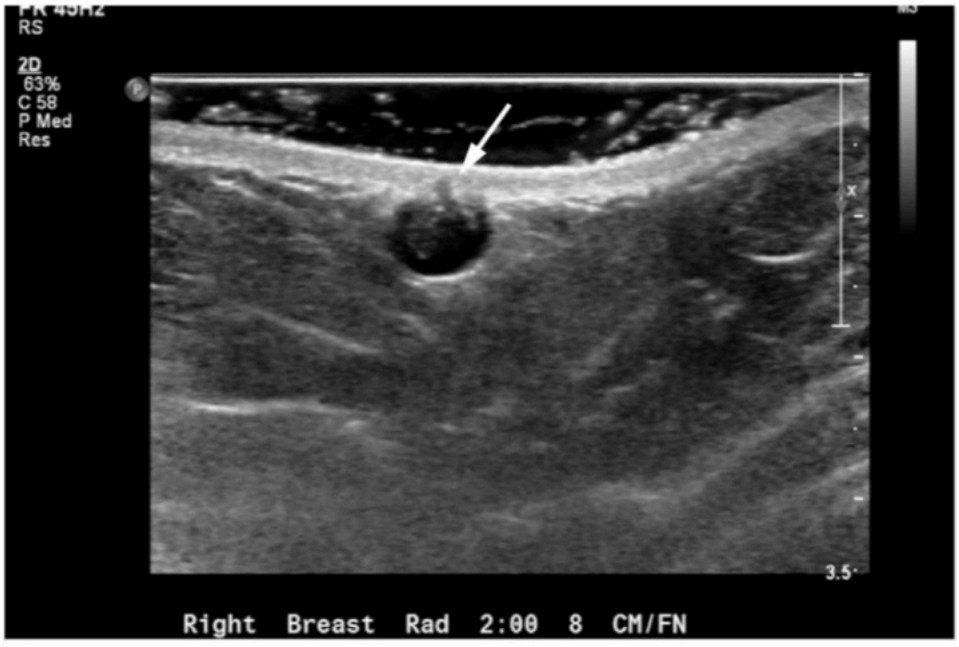

B

Figure 2 – IMAGE QUALITY: FOCAL ZONE. Focal zone position is posterior to the superficial mass in (A) and at the anterior aspect of the lesion in (B). The image obtained with standoff gel (B) allows for improved visualization and identification of the punctum extending from the superficial hypoechoic mass (arrow) to the surface of the skin indicative of an epidermal inclusion cyst.

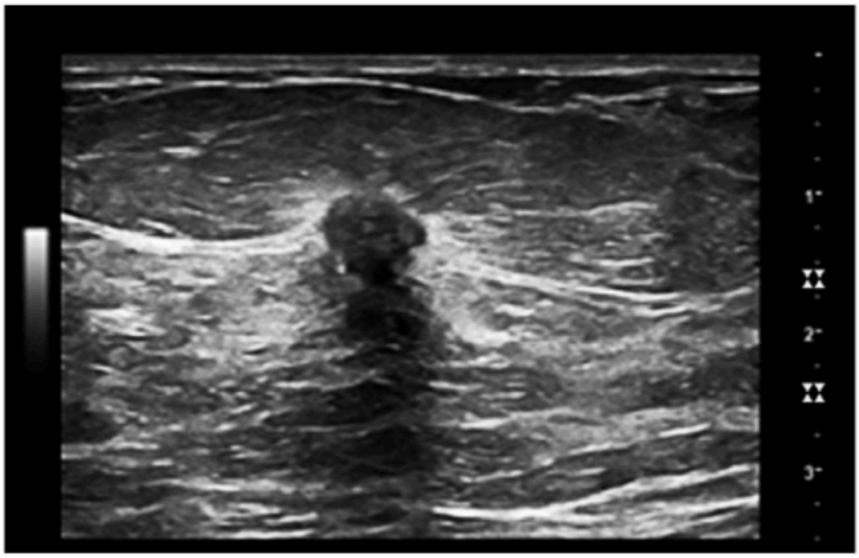

A

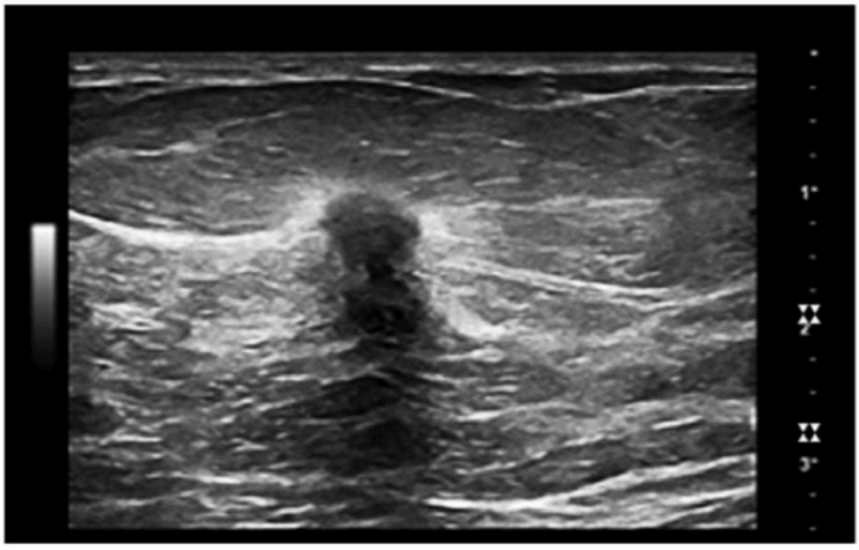

B

Figure 3 – IMAGE QUALITY: FOCAL ZONE. Focal zone placement can affect conspicuity and clarity of lesion depiction. Two US images of a carcinoma that was readily visible at mammography (not shown) were obtained with focal zone settings (marked by a pair of ⧗ icons) at different levels. Although the small invasive ductal carcinoma is clearly identifiable on both images, marginal features are best depicted when the focal zones are set at the depth of the lesion (A). When the focal zones are set at the posterior aspect of the lesion (B) marginal features are less distinct.



A



B

Figure 4 – IMAGE QUALITY: FOCAL ZONE. Patient presents with increasing skin redness and a retroareolar lump. Gray scale trapezoidal images demonstrate a 3.8 cm mixed solid and cystic mass at the left 3:00 periareolar region. The same mass is depicted in both images; however, the focal zone is positioned correctly in the center of the lesion in (A) and inappropriately focused 10 cm deep in the tissue in (B). The reduced resolution in (B) decreases the confidence to accurately characterize this abscess. Pathology: Abscess.

B. IMAGE QUALITY

4. GRAY SCALE GAIN

Grayscale gain is used to compensate for beam attenuation in deeper tissue. US waves are absorbed by tissue; the deeper the tissue, the greater the absorption that has occurred, with less of the beam available to create an image. Increasing the gain may help compensate for this by increasing the brightness of the image, but penetration of tissue for adequate depiction also depends on transducer frequency (greater penetration inversely proportional to frequency), focal zone settings, power increase, and the appropriate selection of FOV. Gray scale gain should be set so normal breast parenchyma varies in echogenicity using much of the gray scale range. The gain may be set too high if the tissue appears as varying shades of white, which can obscure some lesions and make some cysts appear solid. The gain may be set too low if the fat appears dark gray to black, causing some very hypoechoic solid lesions to appear anechoic and be mistaken for simple cysts. As a reference setting for the gray scale, subcutaneous fat lobules should appear medium gray, never black.



Figure 1 – IMAGE QUALITY: GRAY SCALE GAIN. A simple cyst is optimally imaged with appropriate gain and focal zone setting. The center of the cyst appears anechoic, and distinct from the surrounding fat and parenchyma recognized due to the different shades of gray in this well-modulated image. The focal zone is positioned in the middle one third of the anechoic cyst allowing proper interpretation. Reverberation artifact (arrow) is identified along the anterior wall of the anechoic cyst.

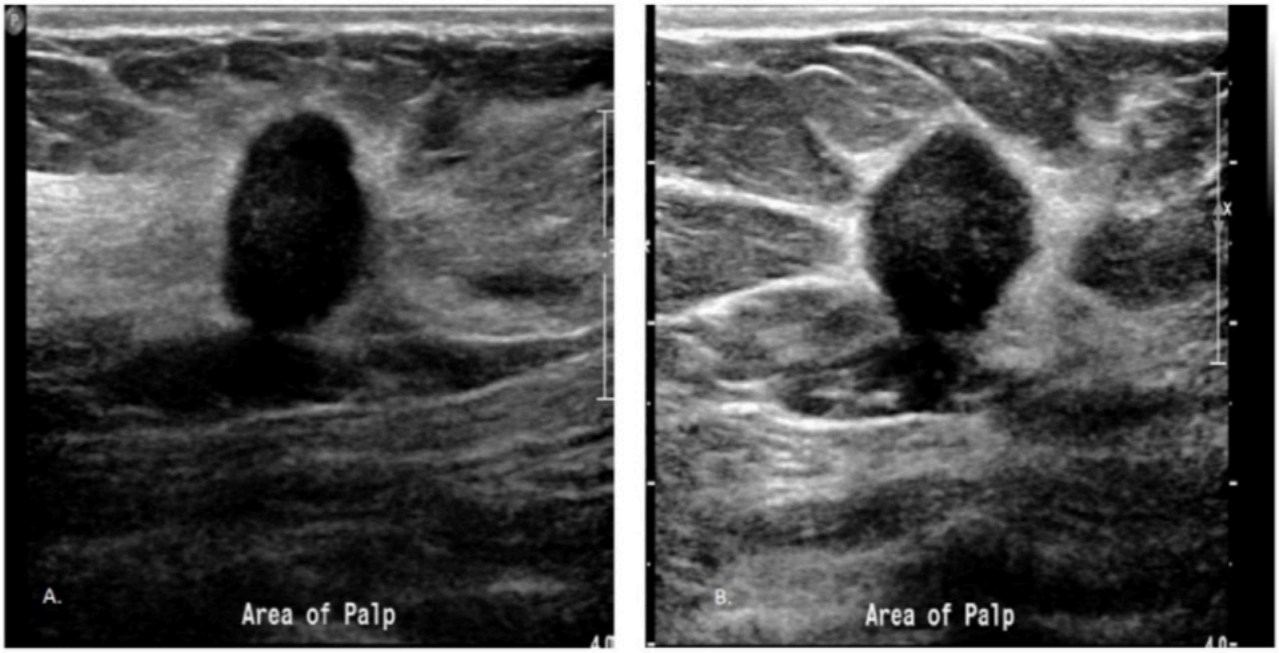

Figure 2 – IMAGE QUALITY: GRAY SCALE GAIN. Two patients diagnosed with triple negative breast cancer. In (A) there is an inappropriately low setting of the gain making this triple negative breast cancer appear more anechoic than in image (B). Fat should appear gray as in image (B).

B. IMAGE QUALITY

5. COMPOUND IMAGING

Compound imaging reduces noise (speckle) by averaging ultrasound information obtained from numerous angles into one composite image. Electronic steering of the ultrasound beam along many angles improves visualization of a mass margin and its relationship with the adjacent surrounding tissue. The process can be repeated so rapidly that imaging occurs in real time, but the frame rate will slow as an increasing number of overlapping images is selected [6]. Given the improvement in image quality with compound imaging, architectural alterations may be easier to appreciate.

When masses are centered in an image obtained with spatial compounding, the margin is more confidently interpreted [7]. However, posterior acoustic features such as shadowing and enhancement may be suppressed with spatial compounding, and enhancement may appear conical, reflecting the pattern of intersecting beam angles.

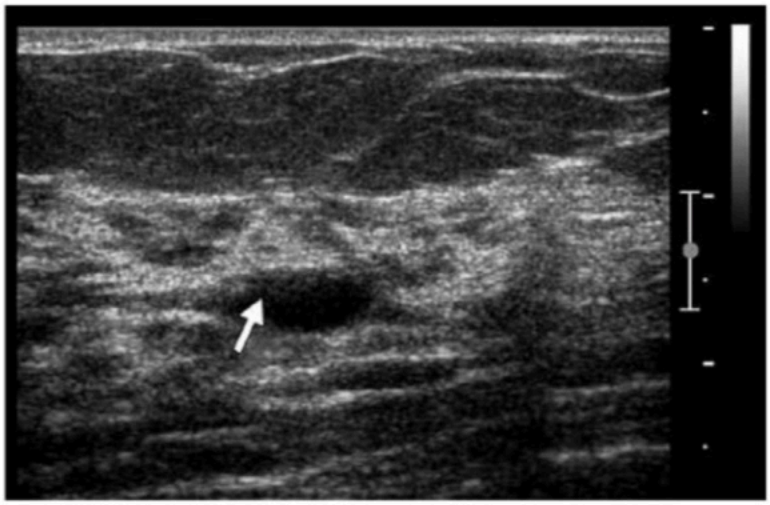

A

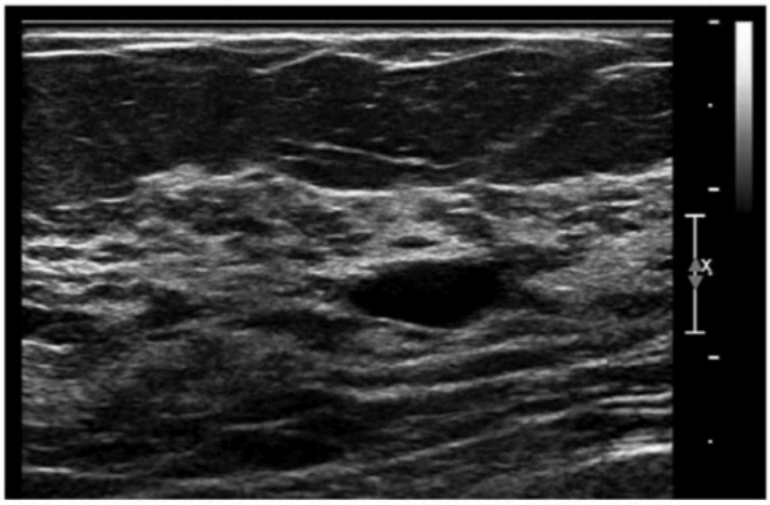

B

Figure 1 – IMAGE QUALITY: COMPOUND IMAGING. US image in native mode (A) demonstrates reverberation artifact in anterior, nondependent wall of cyst (arrow). Spatial compounding technique (B) eliminates artifacts, making the cyst appear anechoic. In both images, the focal zone is set correctly.

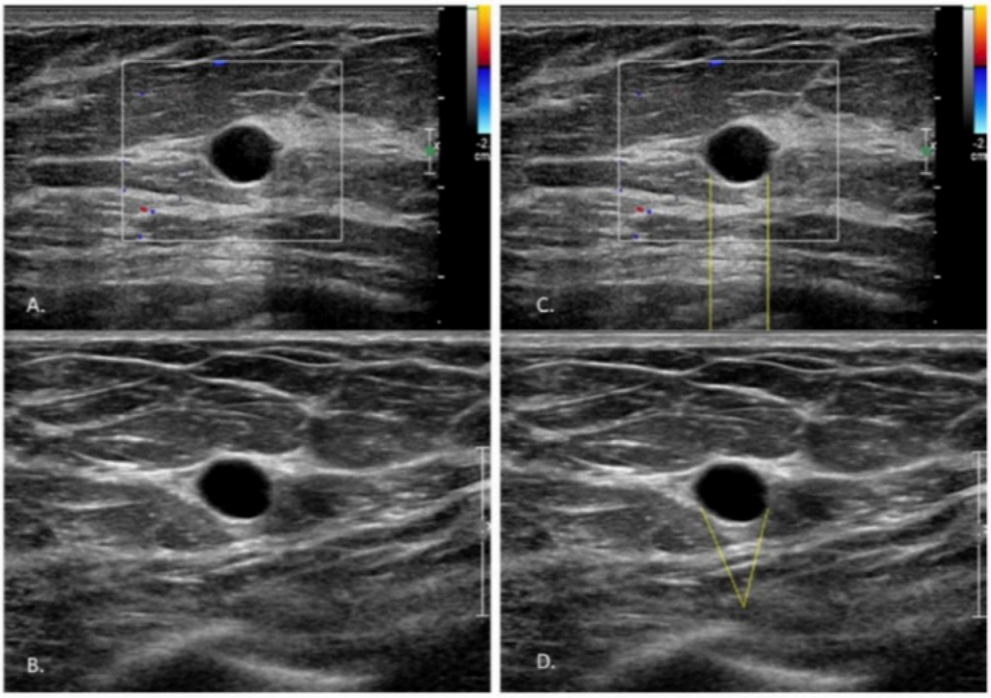

Figure 2 – IMAGE QUALITY: COMPOUND IMAGING. Simple benign cyst without (A, C) and with (B, D) compound imaging exhibit posterior acoustic enhancement (echogenic area directly posterior to mass). When compound imaging is utilized (B and D) posterior enhancement is more conical in shape versus rectangular when compound imaging is not in use (A and C). Note that (C) is an annotated version of (A) and (D) is an annotated version of (B).

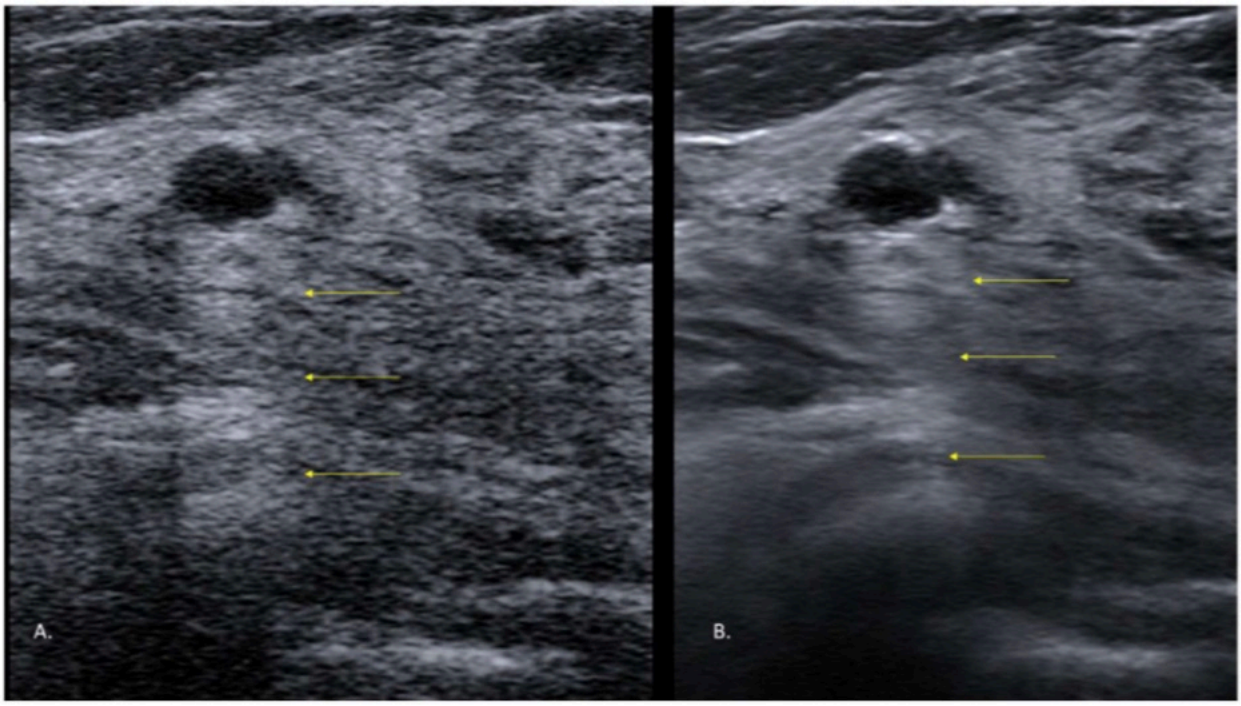

Figure 3 – IMAGE QUALITY: COMPOUND IMAGING (AND SPECKLE REDUCTION). A hypoechoic mass with posterior enhancement that appears as a column in image A, without compound imaging. Posterior enhancement is triangular or conical in image (B), with compound imaging. Since compound imaging produces an image from several overlapping ultrasound images each obtained with the beam angled differently, artifacts due to inherent noise (i.e., speckle artifact) seen in image (A) are reduced and real reflectors are clarified with its use, as seen in image (B).

C. LABELING AND MEASUREMENT

1. LABELING

   Breast US images should include the following label as described in the ACR Practice Parameter for the Performance of a Diagnostic Breast Ultrasound Examination [4] and the ACR Practice Parameter for the Performance of Ultrasound-guided Percutaneous Breast Interventional Procedure [8].

   a. Facility name and location

   b. Examination date

   c. Patient's first and last name

   d. Identifying number and/or date of birth

   e. Designation of right or left breast

   f. Anatomic location using clock-face notation (to the nearest hour) or a labeled diagram of the breast

   g. Transducer orientation (e.g., radial, antiradial, oblique, transverse, sagittal)

   h. Distance from the nipple to the center of the abnormality or the area being scanned in centimeters (measure from the nipple as a standard reference point, not the edge of the very variable areola). Round up or down to nearest whole centimeter to avoid misleading sense of precision.

   i. Sonographer's and/or physician's identification number, initials, or other identifying symbol

2. MEASUREMENT OF FINDING SIZE

   a. Round and record measurements to no greater than one decimal place when using cm and to whole numbers when using mm. For example, 0.45 cm–0.49 cm should be rounded up to 0.5 cm, 2.43 cm should be rounded down to 2.4 cm, and 12.4 mm should be rounded to 12 mm. Be consistent in usage of units throughout the report.

   b. When possible, three measurements of a lesion should be given. The largest measurement should represent the longest axis of the lesion. The next measurement should be oriented perpendicular to the first. The third measurement should be taken in a view orthogonal to that of the first two measurements and should represent the plane not yet measured. For an example, see diagram below.

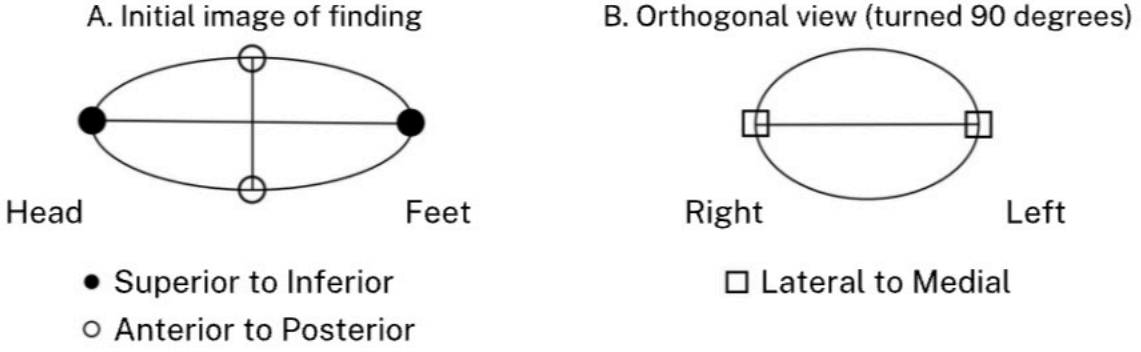

If necessary, the volume of a mass can be computed and reported by using a 3D transducer (for 2D US, two perpendicular images will allow three measurements to be made). If posterior shadowing is intense, the posterior margin of the mass may be obscured, and the anterior-posterior dimension may not be measurable.

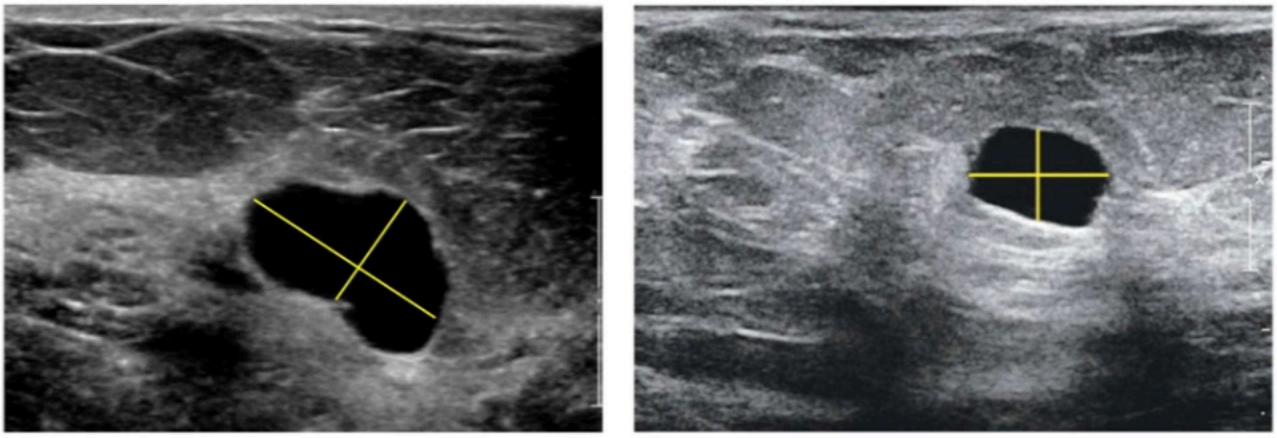

A B

Figure 1 – LABELING AND MEASUREMENT. When opting to provide multi-dimensional measurements of a cyst rather than the largest diameter, this simple cyst and other obliquely situated masses should be measured as in (A), first finding the longest axis of the mass and then a measurement perpendicular to it. The measurements shown in (B) are incorrect; the rectangular image frame should not be the reference for measuring.

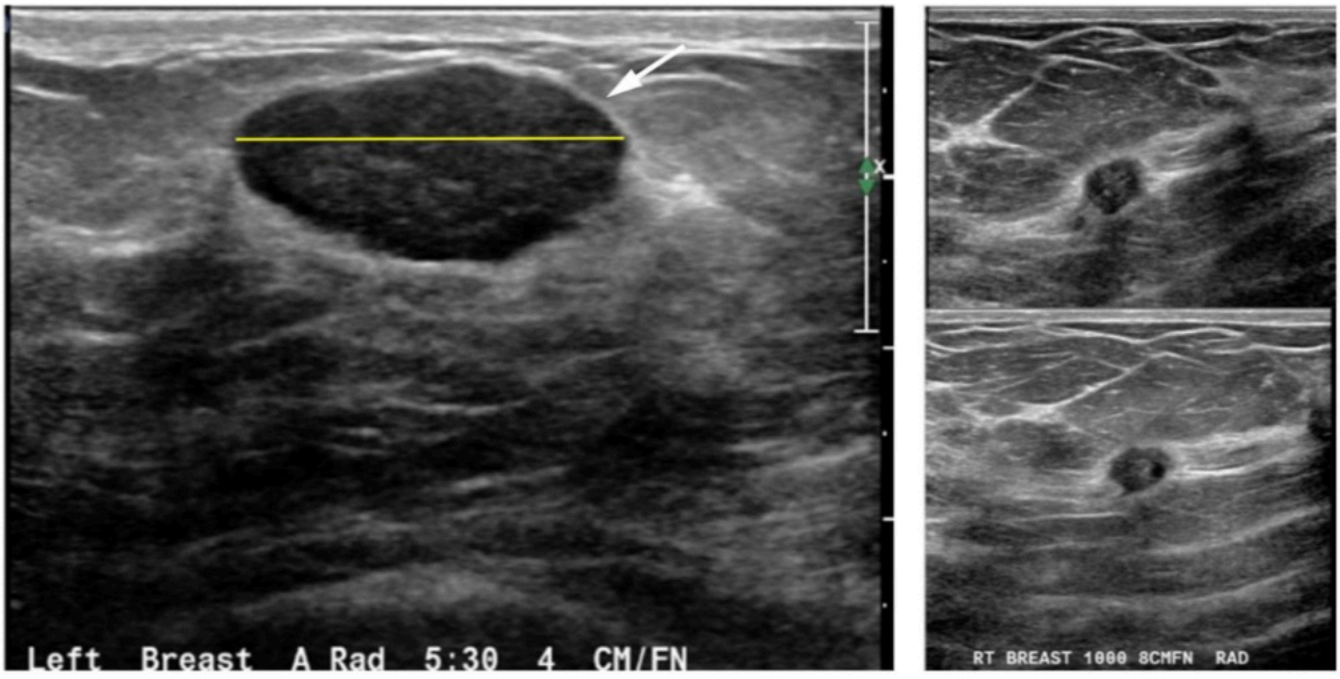

Figure 2 – LABELING AND MEASUREMENT. Pseudocapsule versus echogenic rind. Measurement of a circumscribed mass with abrupt transition such as the fibroadenoma in left image should include the hypoechoic portion and not the surrounding thin hyperechoic rim/pseudocapsule (arrow) that represents normal adjacent compressed tissue. In the right images, the irregular hypoechoic mass with blurry transition from the adjacent tissue is associated with an echogenic rind containing spicules radiating from the mass. Measuring the mass on the right should include the hypoechoic portion and echogenic rind to be more predictive of the size at pathologic evaluation.

When measuring a mass with an indistinct margin and disruption of the surrounding breast architecture and an associated echogenic rind, measurements of the hypoechoic portion should be obtained in three dimensions as described above with inclusion of the central mass and the echogenic rind. Studies have suggested that inclusion of the echogenic rind is more predictive of the actual size at pathologic evaluation [9, 10].

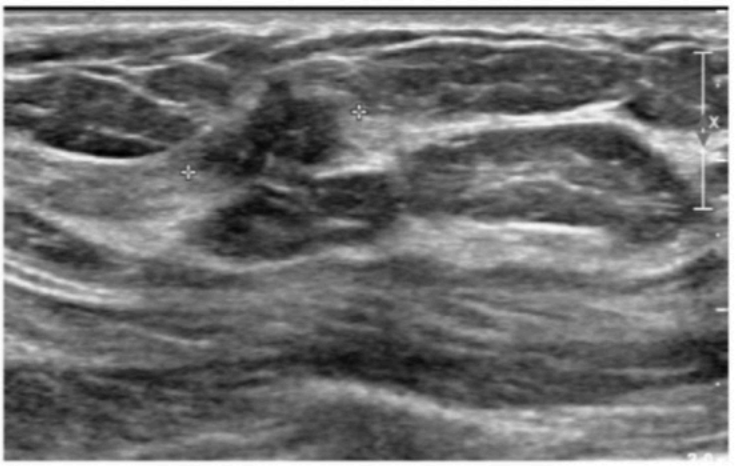

A

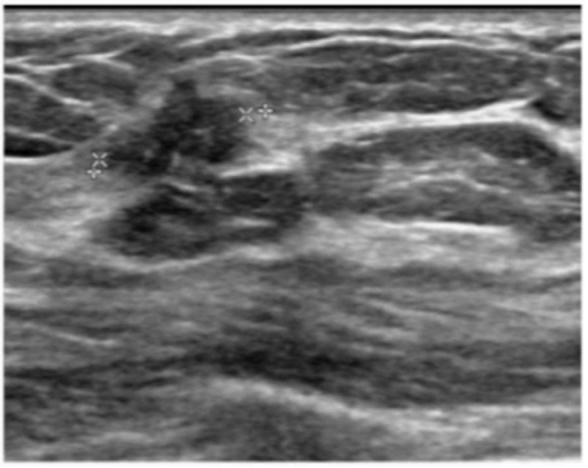

B

Figure 3 – LABELING AND MEASUREMENT. Hypoechoic irregular mass with echogenic rind. (A) displays a measurement inclusive of both the hypoechoic mass and hyperechoic rim or "echogenic rind" surrounding the cancer, which correlates best with the pathological final measurement. (B) demonstrates the difference between the recordings of the hypoechoic portion only vs the mass inclusive of the hyperechoic rim. If measuring only the hypoechoic portion of this mass, the measurement is foreshortened by approximately 2 mm.

D. DOCUMENTATION

Cysts, Intramammary Lymph Nodes, and Multiple Benign Masses

When there are multiple cysts, representative images suffice. When several cysts are present, it is not necessary to document every cyst in two views; measuring the largest in each breast along only its longest axis is sufficient. If the US examination is directed to a specific mammographic abnormality or if the cyst corresponds to an area of clinical concern to the patient, physician, or other health care provider, its measurements should be recorded in three dimensions. However, if a solitary asymptomatic simple cyst is identified at screening US, then documentation depends on whether or not the radiologist chooses to include it as a finding in the report. One image along the longest axis of the cyst is sufficient if the cyst is described in the report (benign assessment). No imaging documentation is required if the cyst is not described in the report (negative assessment).

Although cysts can occur high in the axillary tail location or in accessory breast tissue within the axilla, such a location should suggest other etiologies, such as metastatic lymph nodes. Color or power Doppler and some elastography methods can offer confirmation of the circumscribed, anechoic mass as a simple cyst.

Similar guidance is pertinent for the documentation of intramammary lymph node(s). If the US examination is directed to a mammographic abnormality or if the node corresponds to an area of clinical concern to the patient, physician, or other health care provider, full documentation of the lymph node is appropriate. However, an asymptomatic, characteristically benign, intramammary lymph node, fully evaluated at real-time scanning or observed incidentally, does not require documentation.

For US, as for mammography, benign (category 2) is the appropriate assessment for multiple bilateral solid circumscribed masses, as long as all the masses are similar and typically benign in appearance [11, 12]. If the interpreting physician prefers to document all masses rather than just the largest in each quadrant or in each breast, reporting should be in the form of a list including clock-face locations of the masses, distance from the nipple, and three orthogonal measurements. When there are numerous masses in the same area, reporting the depth from the skin to the center of a lesion also helps to differentiate it from others, assuming such detailed documentation is indicated and desired. (Please refer to Audit and Outcomes Monitoring section regarding the effect of permanent archival of nonstandard images on the audit of screening examinations.)

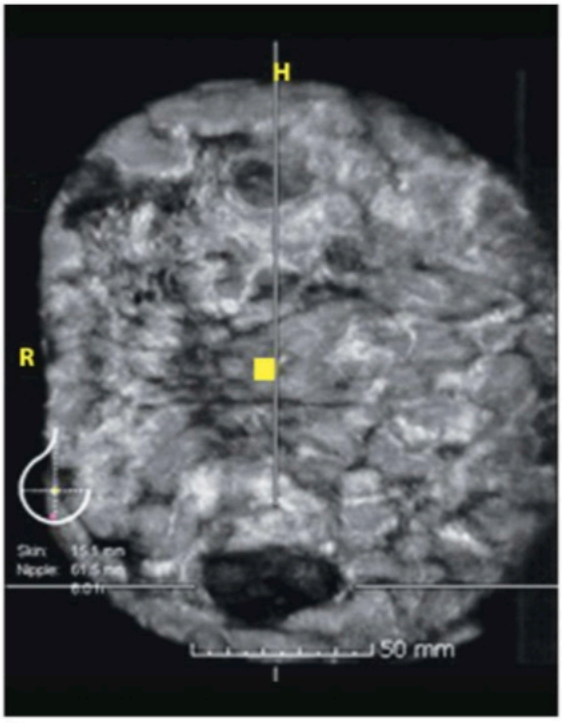

A

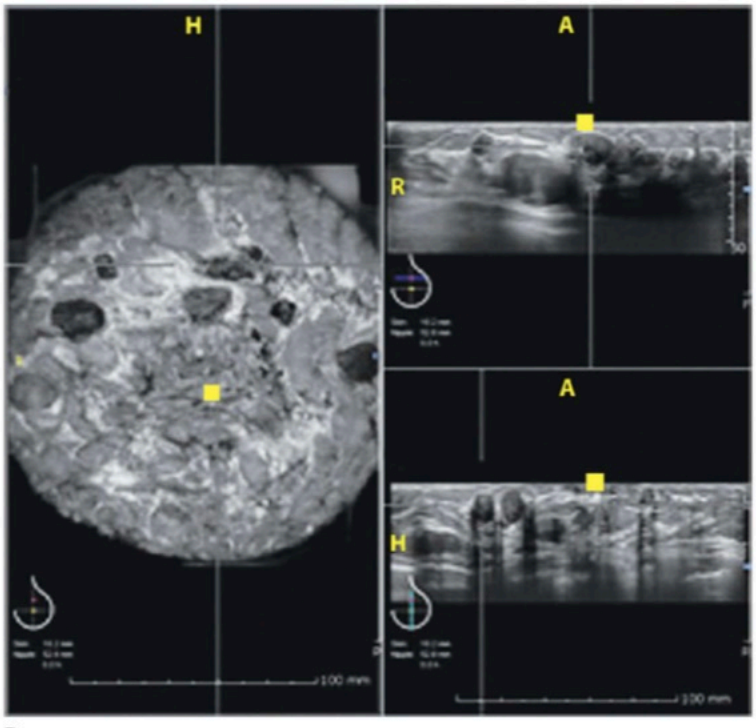

B

Figure 1 – DOCUMENTATION: MULTIPLE MASSES. Coronal views of the right (A) and left (B) breasts obtained with automated US show numerous circumscribed masses bilaterally. The transverse or axial acquisition is shown at the top right of (B) with the sagittal reconstruction at the lower right. Crosshairs correlate with lesion location on the three views. Diagrams and annotation at the lower corners of the coronal views indicate distance from the nipple, clock-face notation, and depth from the skin to the center of the crosshairs. Documentation in a list is efficient and clear.

E. HANDHELD VS. AUTOMATED AND PHYSICIAN- VS. TECHNOLOGIST-PERFORMED

The limitations of mammography in patients with dense breast tissue have led to a dramatic increase in the use of ultrasound in the last decade. In the 2024 the use of whole-breast ultrasound as an adjunct screening tool can be considered for women with heterogeneously or extremely dense breast tissue, women with a high lifetime breast cancer risk (20% or greater) who are not candidates for breast MRI or those women at high risk who cannot easily access breast MRI [13]. Several multi-institutional and prospective trials such as the ACRIN 6666, J-START and ASTOUND study conclude the use of supplemental ultrasound screening improves the detection of small, node negative invasive breast cancers compared to mammography alone in women with dense breast tissue, albeit associated with an increase in the number of false-positives [14–16].

The implementation of a screening ultrasound program is dependent on the dedicated resources and availability of extra space and personnel (trained technologist and interpreting physician) at each institution. Supplemental screening with handheld ultrasound allows for continued use of existing equipment, as opposed to fully or semi-automated screening ultrasound systems that require specialized transducers (15 cm linear/curved array or ring-shaped) with or without the use of a water bath.

According to the ACR Practice Parameter for the Performance of Whole-Breast Ultrasound for Screening and Staging [13] documentation of a standard HHUS screening exam requires a minimum recording of one image from each quadrant and one image behind the nipple. Automated systems record the images during the acquisition process for later interpretation by the physician. The storage of the entire exam facilitates the decoupling of exam interpretation and image acquisition.

Handheld ultrasound can be performed by either the interpreting physician or the technologist. In a review published in 2019 [17], there were similar outcomes between screening ultrasound exams performed by a technologist, and those conducted by a physician. The average incremental cancer detection rate (CDR) across 361,502 physician performed screening ultrasound exams was 2.0 per 1000 women screened, comparable to the 2.7 cancers diagnosed per 1000 women screened in 64,018 technologists performed screening ultrasound exams. In the same review, the CDR was 2.5 per 1000 screens performed across 27,163 automated or semi-automated exams.

Some PACS and automated ultrasound systems can reconstruct the data in multiple planes to improve lesion characterization. The 3D automated ultrasound platform can generate a coronal image which has the potential to enhance a pattern of architectural distortion associated with malignancy. This finding, when seen on the reconstructed coronal view, is unique and highly predictive of malignancy [18]. The pattern appears as radiating hypoechoic lines perpendicular to and converging on a central hypoechoic mass and is thought to represent tumor infiltration (hypoechoic lines) into the adjacent tissue. Accompanying this finding is a surrounding echogenic rind which represents the adjacent desmoplastic reaction. The rind can be quite variable in its conspicuity.

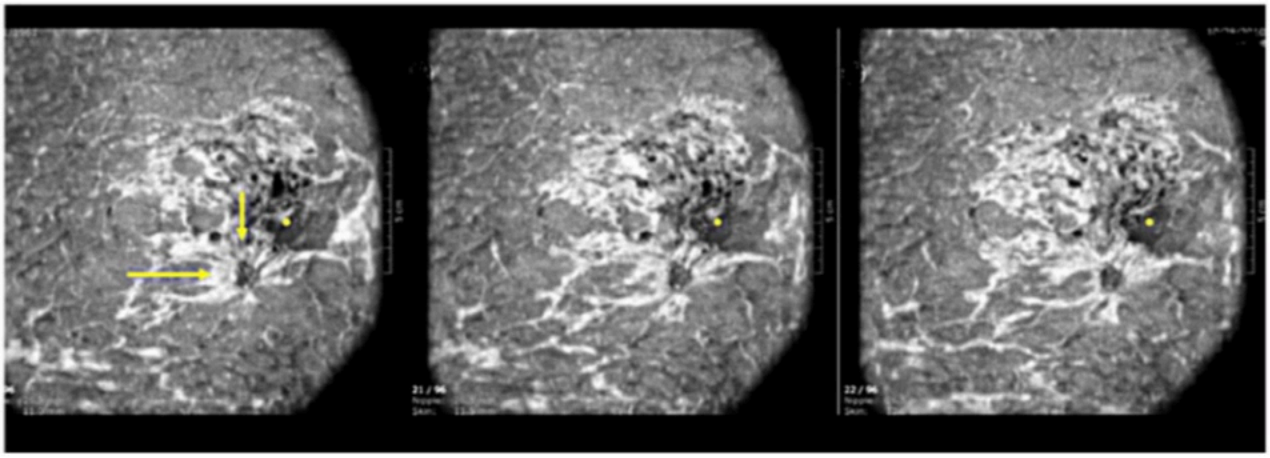

Figure 1 – AUTOMATED SCREENING ULTRASOUND. Retraction phenomenon. Patient with dense breast tissue had supplemental screening with ultrasound. The consecutive 3D reconstructed coronal images demonstrate a hypoechoic irregular mass with surrounding echogenic rind and architectural distortion. The retraction associated with the echogenic rind (arrows) is highly predictive for malignancy.

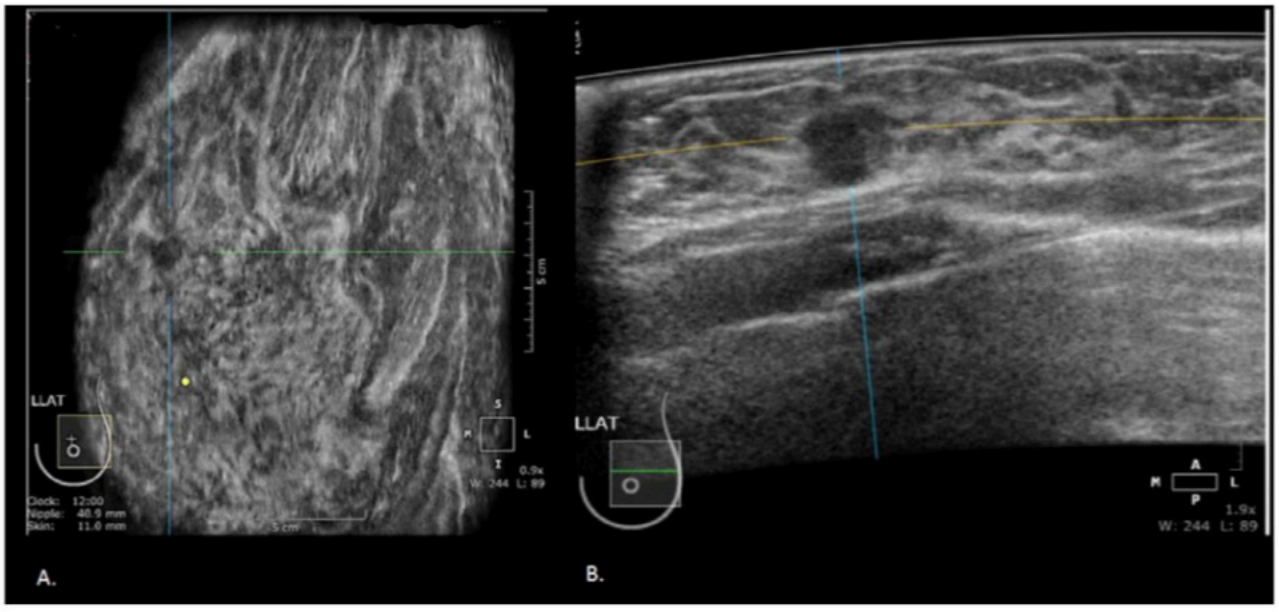

Figure 2 – AUTOMATED SCREENING ULTRASOUND: 3D reconstructed coronal image (A) demonstrates a hypoechoic mass identified in the middle of the crosshairs. The corresponding axial transverse EFOV image (B) demonstrates a microlobulated hypoechoic mass with no posterior acoustic features. Pathology: Intermediate grade invasive ductal carcinoma.

A BI-RADS assessment category 0 is recommended for any suspicious or indeterminate finding identified on an automated or HHUS screening study that requires further diagnostic workup. A patient may undergo further workup with focused handheld ultrasound on the same day; however, the latter is considered to be a diagnostic exam and both exams require separate final assessment codes for the purpose of the audit. The interpreting physician may choose to dictate each exam under one report and give an overall final recommendation. Separate BI-RADS assessment categories for the screening and diagnostic ultrasound evaluation help with outcomes monitoring and auditing. Only BI-RADS assessment codes 0, 1, or 2 should be assigned to screening ultrasound examinations, and only after a diagnostic evaluation should a BI-RADS assessment code of 3, 4, or 5 be given.

II. BREAST IMAGING LEXICON — ULTRASOUND

Table 1. BI-RADS® Ultrasound Lexicon Overview

Breast Tissue		Terms	
A. Tissue composition	1. Tissue pattern	a. Homogeneous background echotexture - fat	
		b. Homogeneous background echotexture - fibroglandular	
		c. Heterogeneous background echotexture	
	2. Glandular tissue component	a. Minimal	
		b. Mild	
		c. Moderate	
		d. Marked	
Findings		**Terms**	
B. Masses	1. Shape	a. Oval	
		b. Lobulated	
		c. Round	
		d. Irregular	
	2. Orientation	a. Parallel	
		b. Non-parallel	
	3. Margin	a. Circumscribed	
		b. Non-circumscribed	i. Indistinct
			ii. Microlobulated
			iii. Angular
			iv. Spiculated
	4. Echo pattern	a. Anechoic	
		b. Hyperechoic	
		c. Isoechoic	
		d. Hypoechoic	
		e. Heterogeneous	
		f. Mixed solid and cystic	
	5. Posterior features	a. No posterior features	
		b. Enhancement	
		c. Shadowing	
C. Non-mass lesions	1. Distribution	a. Regional	
		b. Focal	
		c. Linear	
		d. Segmental	
	2. Echo pattern	a. Hyperechoic	
		b. Heterogeneous	
		c. Hypoechoic	
	3. Posterior features	a. No posterior features	
		b. Enhancement	
		c. Shadowing	

D. Calcifications	1. Macrocalcifications	
	2. Microcalcifications	
	3. Calcifications in a mass or non-mass lesion	
	4. Calcifications outside of a mass or non-mass lesion	
	5. Intraductal calcifications	
E. Associated features	1. Echogenic pseudocapsule	
	2. Echogenic rind	
	3. Architectural distortion	
	4. Duct changes	
	5. Skin changes	a. Skin thickening
		b. Skin retraction
	6. Edema	
	7. Vascularity	a. Avascular
		b. Internal vascularity
		c. Peripheral hypervascularity
	8. Elasticity assessment	a. Soft
		b. Intermediate
		c. Hard
F. Special cases	1. Simple cyst	
	2. Clustered microcysts	
	3. Complicated cyst	
	4. Mass in or on skin	
	5. Foreign body	
	6. Implants	
	7. Postsurgical changes, including fluid collections	
	8. Fat necrosis	
	9. Post-traumatic (non-surgical) changes	
	10. Abscess	
	11. Vascular abnormalities	a. AVMs (arteriovenous malformations/pseudoaneurysms)
		b. Superficial thrombophlebitis (Mondor's disease)
G. Lymph nodes	1. Intramammary	
	2. Axilla	a. Level I
		b. Level II
		c. Level III
	3. Internal mammary	
	4. Supraclavicular	
H. Location of finding	1. Laterality	
	2. Location in breast	
	3. Depth and/or distance from the nipple	

A. TISSUE COMPOSITION

The wide normal variability in tissue composition seen on mammograms can also be observed on US images. The sonographic echo pattern of the breast depends on the distinct composition of the breast elements within the fibroglandular zone. The fibroglandular zone is located between the subcutaneous and retromammary fat and is comprised of various glandular elements (the milk ducts, the terminal duct lobular units) and stromal fibrous tissue. Unlike mammography, where the density of stromal and glandular elements is similar, ultrasound can differentiate the hypoechoic glandular elements from the hyperechoic stromal background. Based on the tissue composition, there are three basic tissue patterns: Homogeneous background echotexture-fat, homogeneous background echotexture-fibroglandular, and heterogeneous background echotexture.

1. TISSUE PATTERN

    a. Homogeneous Background Echotexture — Fat

    Fat lobules and uniformly echogenic bands of supporting structures comprise the bulk of breast tissue.

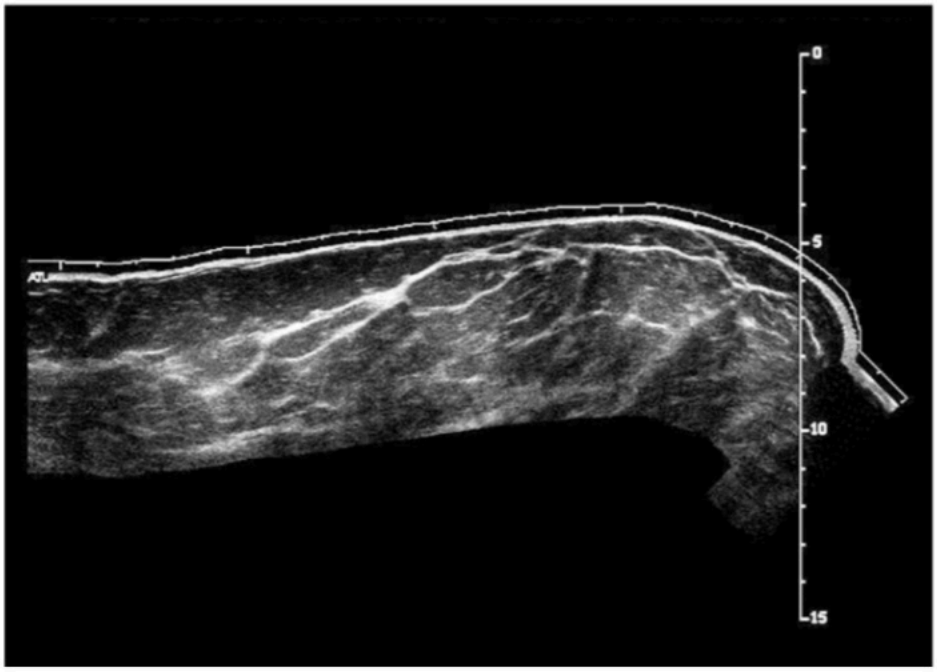

Figure 1 – TISSUE COMPOSITION: HOMOGENEOUS BACKGROUND ECHOTEXTURE-FAT. Homogeneously fatty tissue is easily characterized and compared with mammography using extended FOV or other US techniques that widen the field. The patient's head would be at the left and feet at the right.

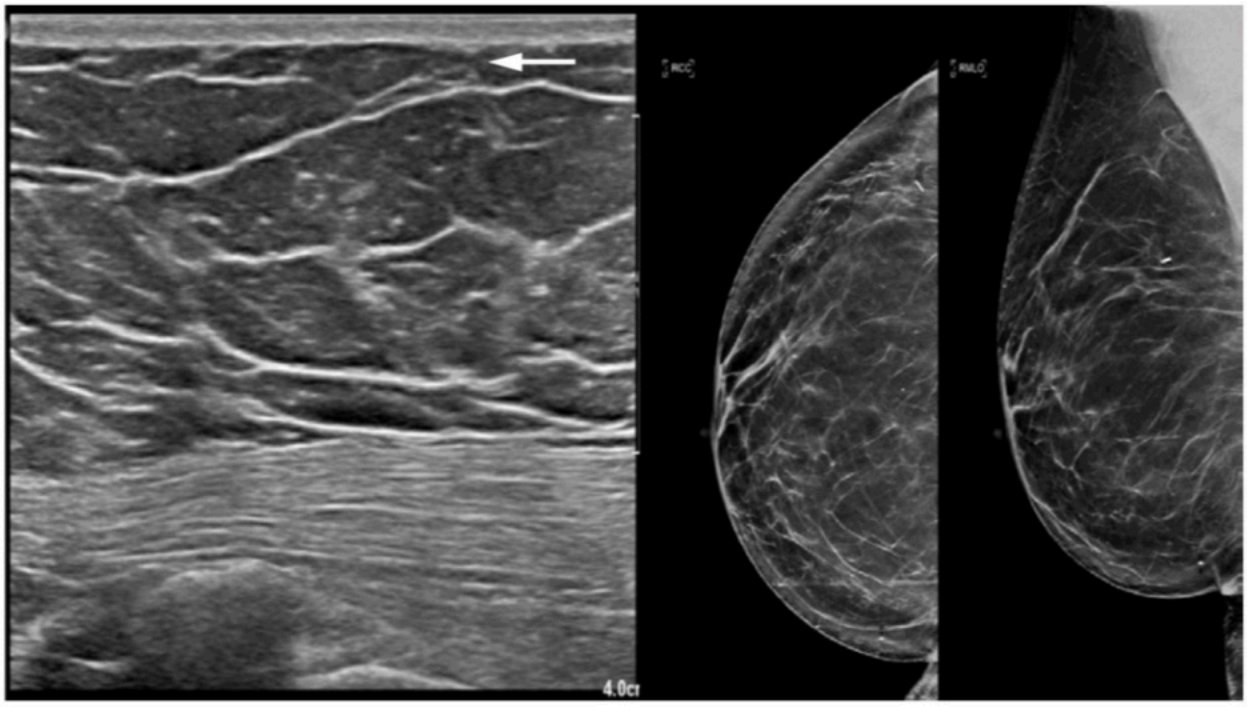

Figure 2 – TISSUE COMPOSITION: HOMOGENEOUS BACKGROUND ECHOTEXTURE-FAT. Gray scale image of the right breast with accompanying unilateral right mammogram demonstrates that the fibroglandular zone is comprised of fat lobules and thick bands of supporting structures. The subcutaneous fat (arrow) is horizontally oriented under the echogenic dermis.

A. TISSUE COMPOSITION

1. TISSUE PATTERN

   b. Homogeneous Background Echotexture — Fibroglandular

   A thick zone of homogeneously echogenic fibroglandular parenchyma is present beneath the isoechoic layer of subcutaneous fat lobules. Many lesions, including cancers and fibroadenomas, are found within the fibroglandular zone or at its junction with the layer of fat.

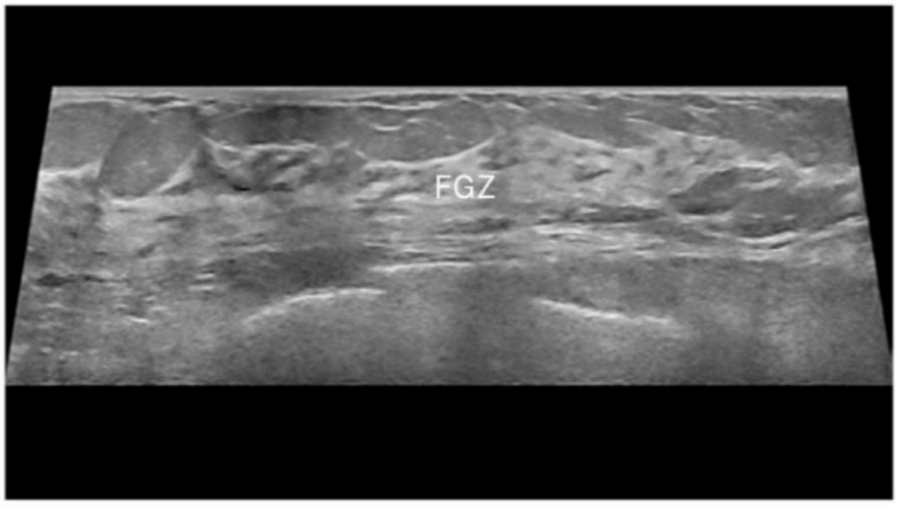

Figure 1 – TISSUE COMPOSITION: HOMOGENEOUS BACKGROUND ECHOTEXTURE-FIBROGLANDULAR. The subcutaneous layer of fat is distinct from the more echogenic fibroglandular zone (FGZ) that lies between it and the pectoralis fascia and muscle beneath it.

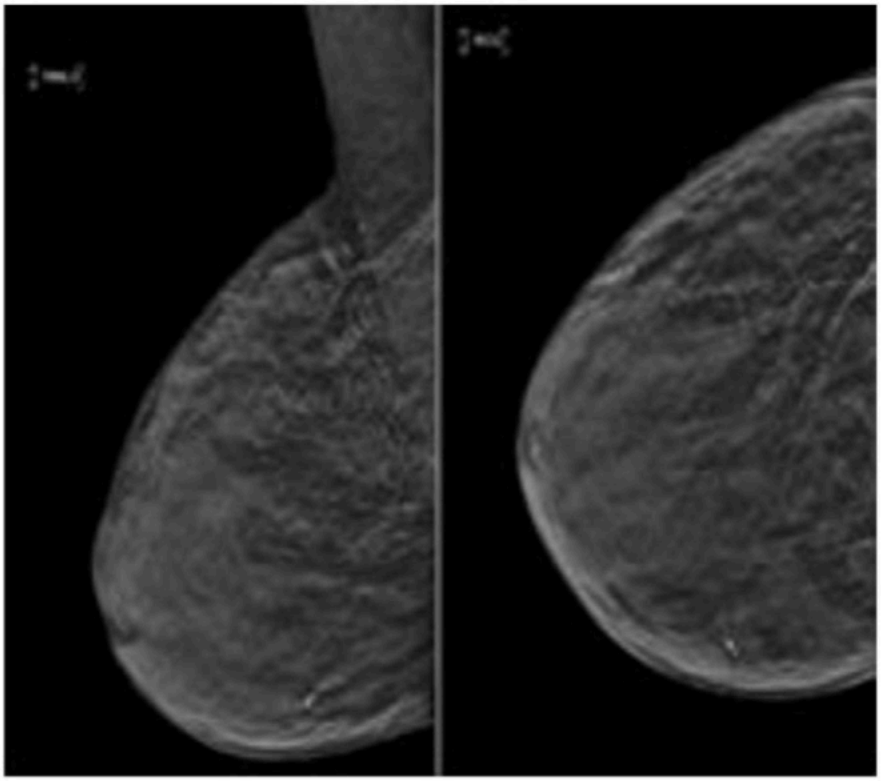

A

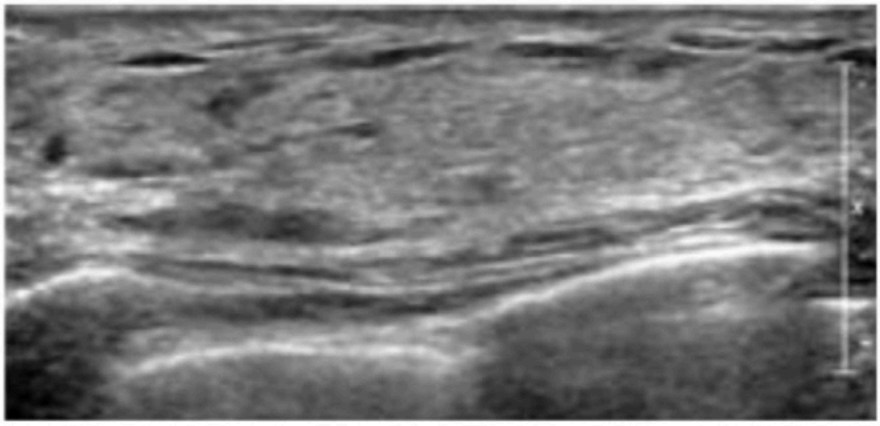

B

Figure 2 – TISSUE COMPOSITION: HOMOGENEOUS BACKGROUND ECHOTEXTURE-FIBROGLANDULAR. Mammogram (A) and ultrasound (B) demonstrate a thick zone of fibroglandular tissue beneath a thin layer of subcutaneous fat. Ultrasound allows for improved visualization of the dense fibroglandular tissue identified on the mammogram.

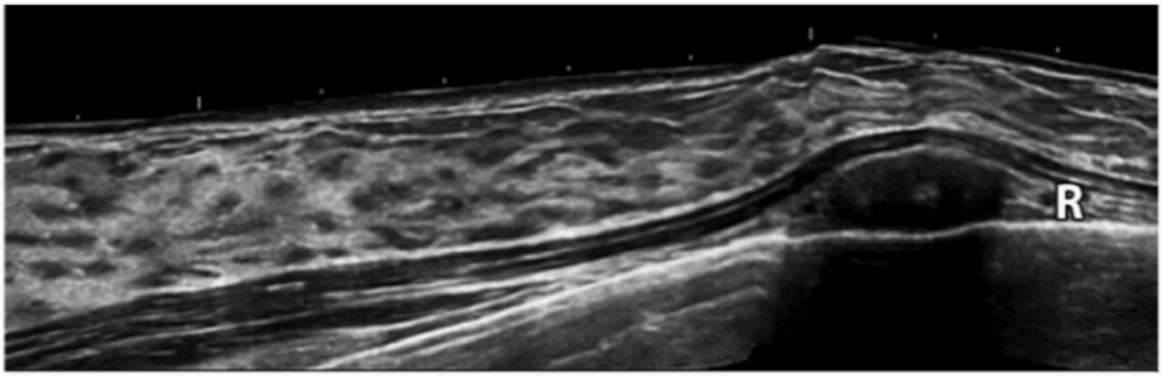

Figure 3 – TISSUE COMPOSITION: HOMOGENEOUS BACKGROUND ECHOTEXTURE-FIBROGLANDULAR. Echogenic fibroglandular tissue with hypoechoic ducts beneath a layer of subcutaneous fat that is extremely thin. R = Rib.

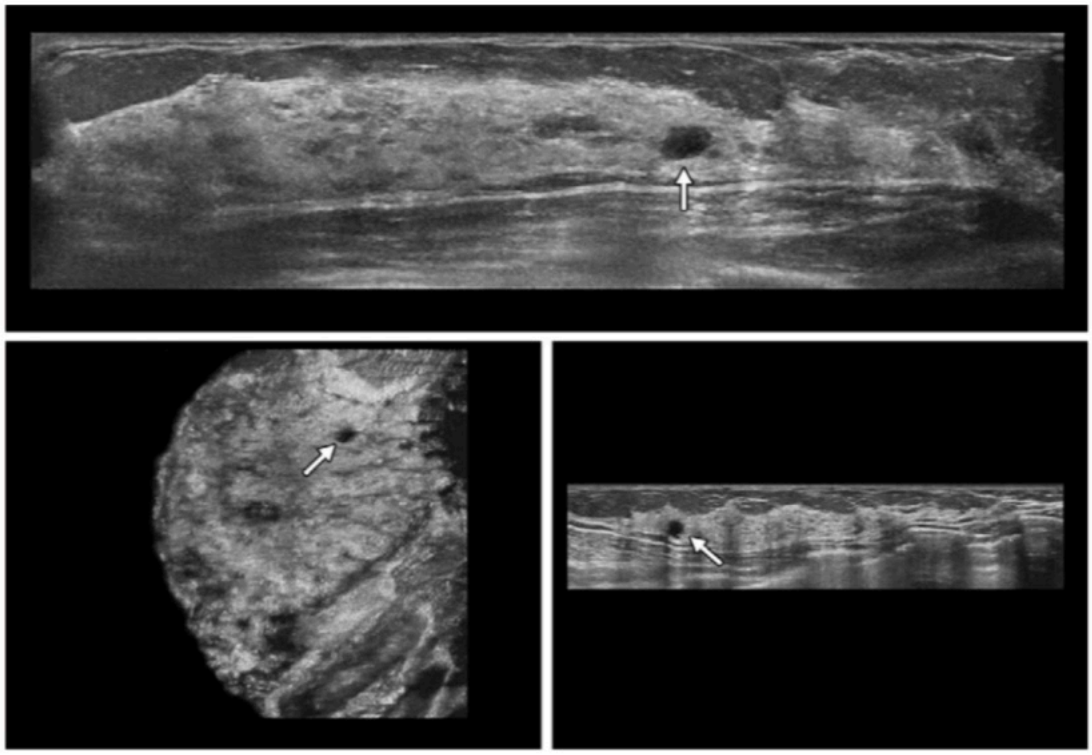

Figure 4 – TISSUE COMPOSITION: HOMOGENEOUS BACKGROUND ECHOTEXTURE-FIBROGLANDULAR. Automated US images showing a small cyst (arrow) within the homogeneous echogenic fibroglandular zone on each view (lateral view: top; coronal reconstruction: bottom left; vertical reconstruction: bottom right). A thin layer of subcutaneous fat overlies the fibroglandular zone.

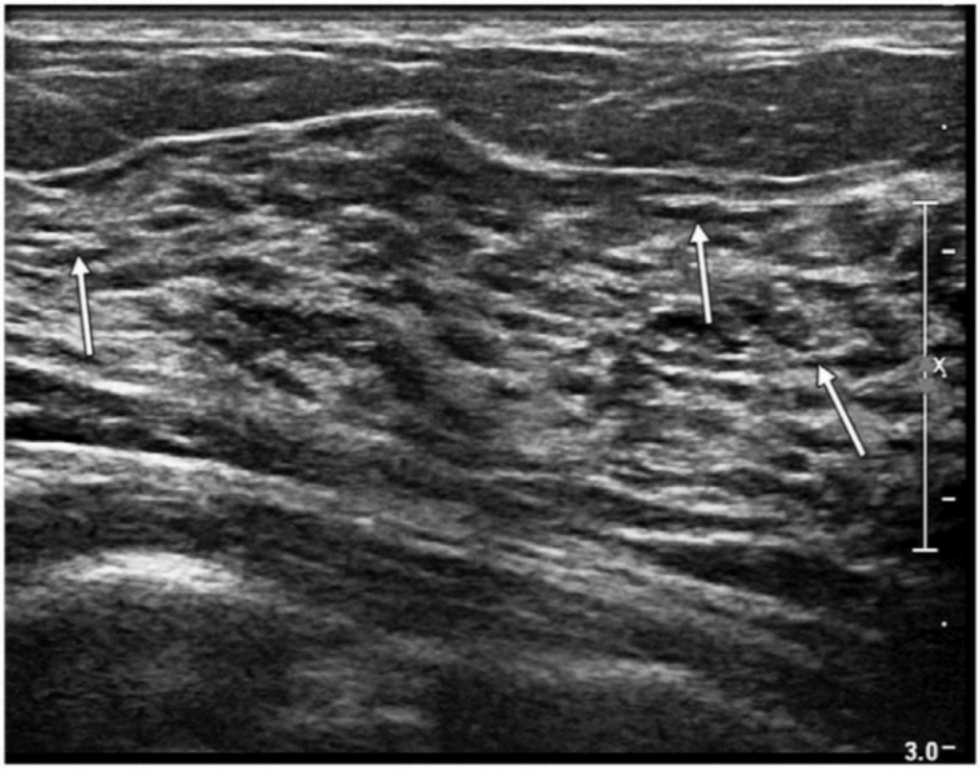

Figure 5 – TISSUE COMPOSITION: HOMOGENEOUS BACKGROUND ECHOTEXTURE-FIBROGLANDULAR. Handheld image (linear transducer 17–5 MHz) with similar findings, but in greater detail, than the automated image above. The linear hypoechoic threadlike ducts are seen throughout the fibroglandular tissue in the axillary tail of the right breast (arrows).

A. TISSUE COMPOSITION

1. TISSUE PATTERN

c. Heterogeneous Background Echotexture

Heterogeneity can be either focal or diffuse. The breast echotexture is characterized by multiple small areas of relative increased and decreased echogenicity. Shadowing may occur at the interfaces of fat lobules and parenchyma. This pattern occurs in younger patients and those with heterogeneously dense parenchyma depicted mammographically. Whether and how this pattern affects the sensitivity of sonography merits additional study, but clinical experience suggests that the detection of small and subtle lesions may be confounded by heterogeneous background echotexture. Technical maneuvers may help resolve interpretive dilemmas that occasionally result in unnecessary biopsy. Different techniques, including appropriate placement of the focal zone(s), modifying the angle of insonation, and implementing compound imaging, can notably enhance characterization at diverse interfaces. To decrease the impact of shadowing caused by refraction, placing a single focal zone at the preferred depth or multiple focal zones can improve contrast resolution at varying depths. Additionally, adjusting the angle of insonation or using compound imaging can improve tissue differentiation by gathering data from multiple angles.

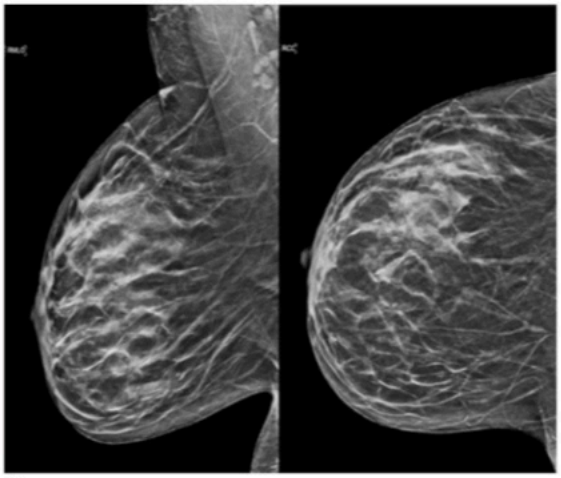

A

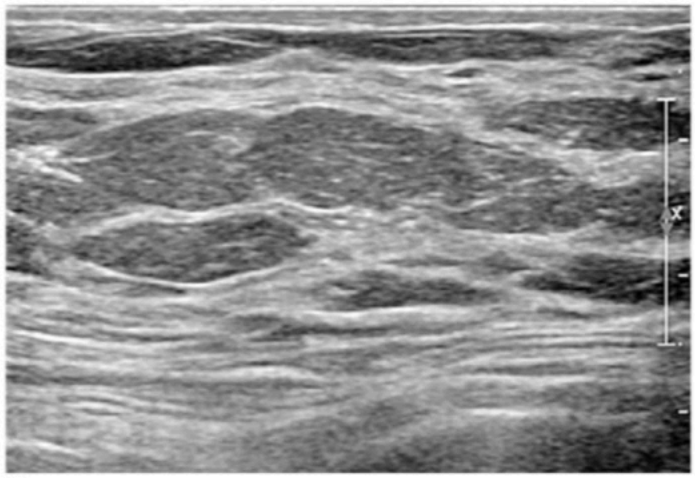

B

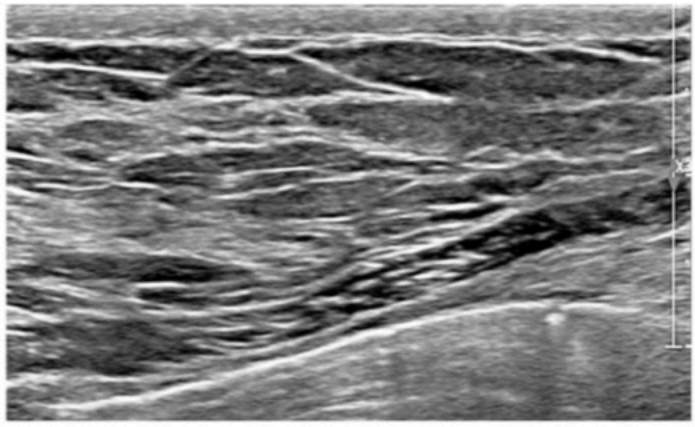

C

Figure 1 – TISSUE COMPOSITION: HETEROGENEOUS BACKGROUND ECHOTEXTURE. Mammogram (A) and ultrasound (B). The mammogram (A) demonstrates heterogeneous dense tissue. The corresponding ultrasound exam (B) depicts heterogeneous background echotexture with intervening areas of increased and decreased echogenicity. (C) depicts a single grayscale image of a different premenopausal patient with heterogeneous background echotexture.

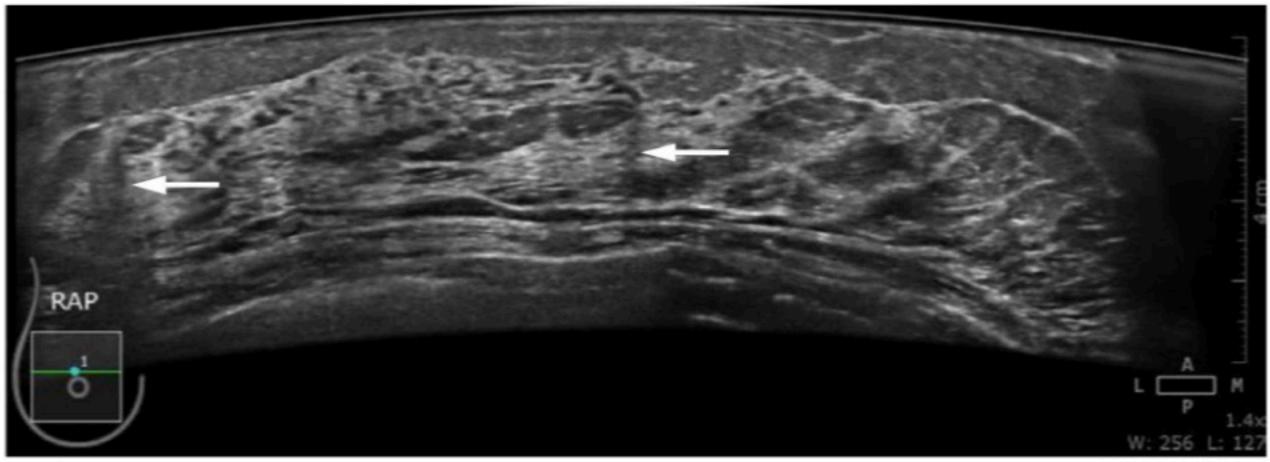

Figure 2 – TISSUE COMPOSITION: HETEROGENEOUS BACKGROUND ECHOTEXTURE. Transverse gray scale image of the right 12:00 axis using a large 15 cm transducer demonstrates intervening areas of increased and decreased echogenicity consistent with heterogeneous background echotexture. There is minimal shadowing at the interface of parenchyma and fat lobules (arrows).

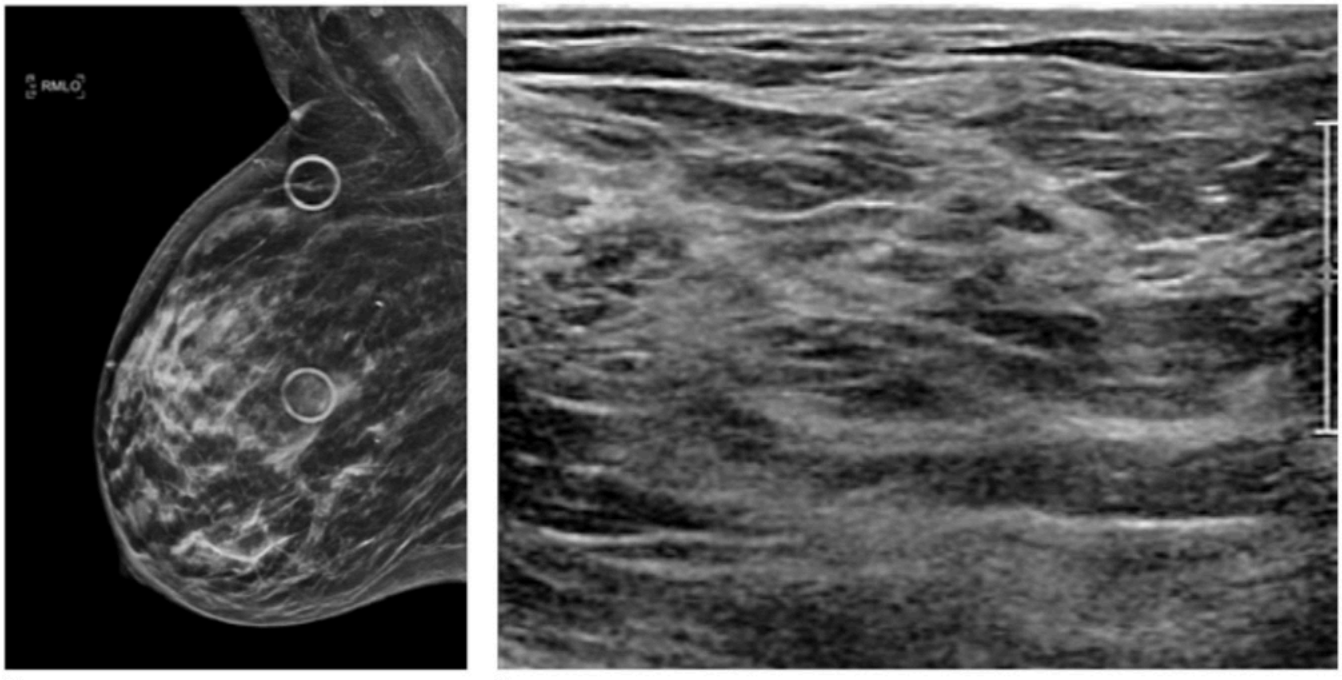

A B

Figure 3 – TISSUE COMPOSITION: HETEROGENEOUS BACKGROUND ECHOTEXTURE. Heterogeneously dense mammographic density on the right MLO image (A). Right breast ultrasound transverse image (B) demonstrates heterogeneous background echotexture with fatty (isoechoic) lobules interspersed with areas of fibroglandular (hyperechoic) tissue.

A. TISSUE COMPOSITION

2. GLANDULAR TISSUE COMPONENT

Ultrasound, which can differentiate between the glandular (relatively hypoechoic TDLUs) and stromal (hyperechoic interlobular fibrous tissue) components of the breast, provides a unique set of information regarding breast composition compared to other imaging modalities. In one large-scale longitudinal study, an increase in the observed proportion of glandular tissue (GT) was associated with an inherent future risk of breast cancer comparable to dense breasts on mammography or increased background parenchymal enhancement on contrast-enhanced breast MRI. Lee and colleagues prospectively reviewed 14,767 screening breast ultrasound examinations and stratified the exams based on the percent volume of ductal lobular units in the fibroglandular zone [19, 20]. A qualitatively appraised percent volume of glandular tissue (referred to as the glandular tissue component, or GTC) of < 25% of the overall fibroglandular tissue (FGT) was considered minimal, 25% to 49% as mild, 50% to 74% as moderate, and ≥ 75% as marked glandular tissue component. Patients with a moderate to marked GTC had a higher future risk of developing breast cancer with a hazard ratio of 1.5; p = .03. Additional studies [21, 22] that used this standardized measure and evaluated lobular involution in pathological breast specimens have also demonstrated an increased inherent risk in women with less glandular involution and a moderate to marked degree of glandular tissue component. Breast parenchymal echotexture pattern as well as a qualitative assessment of glandular elements can be reported on screening ultrasound to recognize the potential impact of tissue composition on interpretation and breast cancer risk. This descriptor can be included as a qualifier of fibroglandular background echotexture. See examples below.

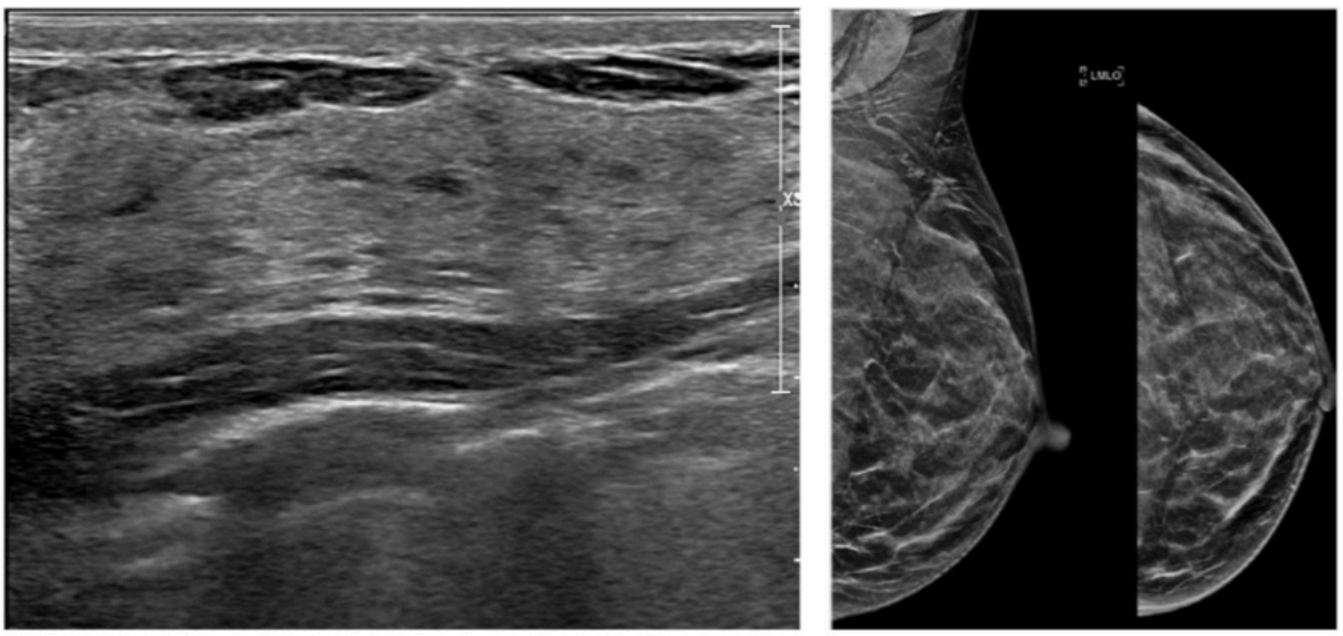

A B

Figure 1 – GLANDULAR TISSUE COMPONENT: MINIMAL. Ultrasound and mammogram demonstrating homogeneously dense fibroglandular tissue with a minimal amount of glandular tissue component. Less than 25% of the tissue in the fibroglandular zone is comprised of TDLUs.

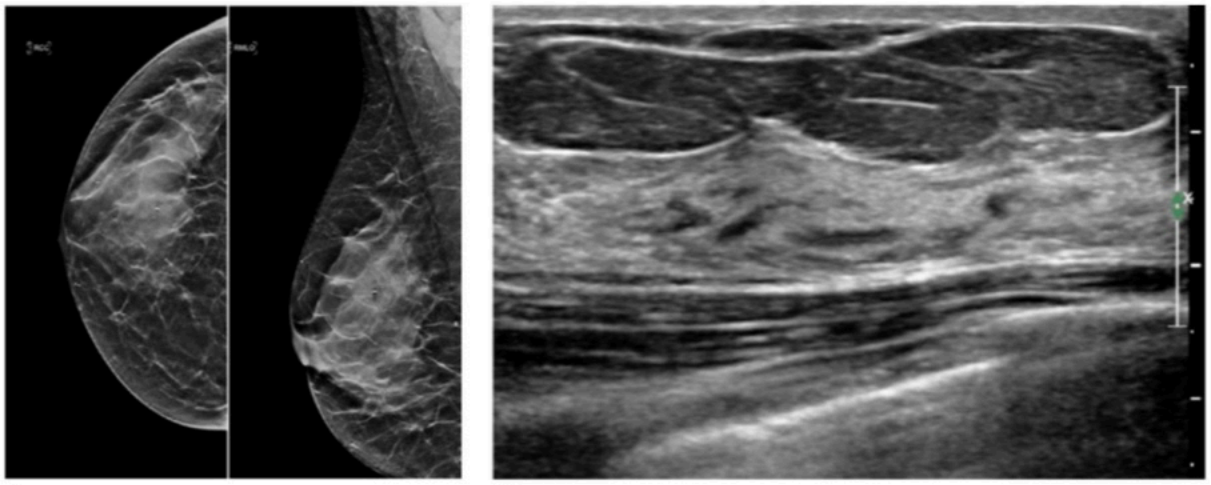

A B

Figure 2 – GLANDULAR TISSUE COMPONENT: MILD. Mammogram (A) and ultrasound (B). The ultrasound demonstrates mild glandular tissue component. Approximately 25% of glandular elements are scattered among the fibrous tissue. This qualitative assessment is not obtainable on the mammogram since the glandular and fibrous tissue are both dense.

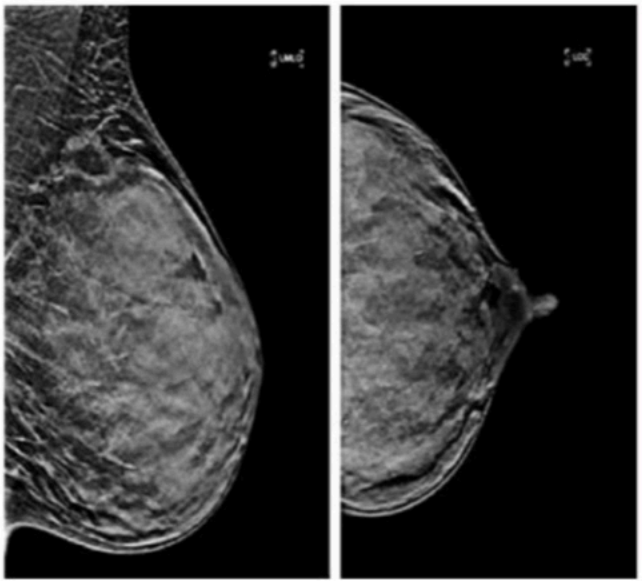

A

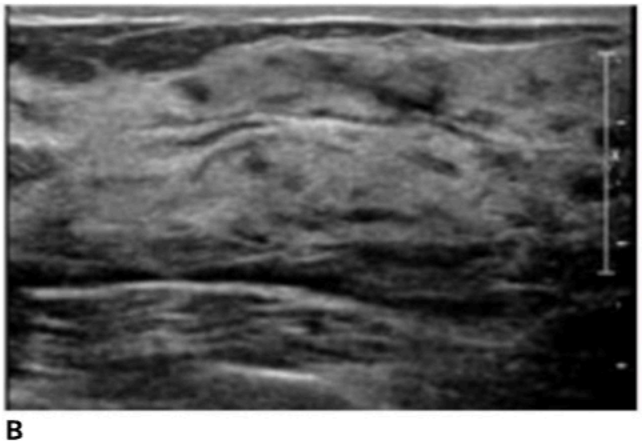

B

Figure 3 – GLANDULAR TISSUE COMPONENT: MILD. The unilateral mammogram (A) demonstrates extremely dense breast tissue. Differentiation between glandular and fibrous tissue is not possible on mammography since both are dense. Ultrasound (B) demonstrates mild glandular tissue component with scattered areas of glandular elements comprising between 25 and < 50% of the fibroglandular tissue.

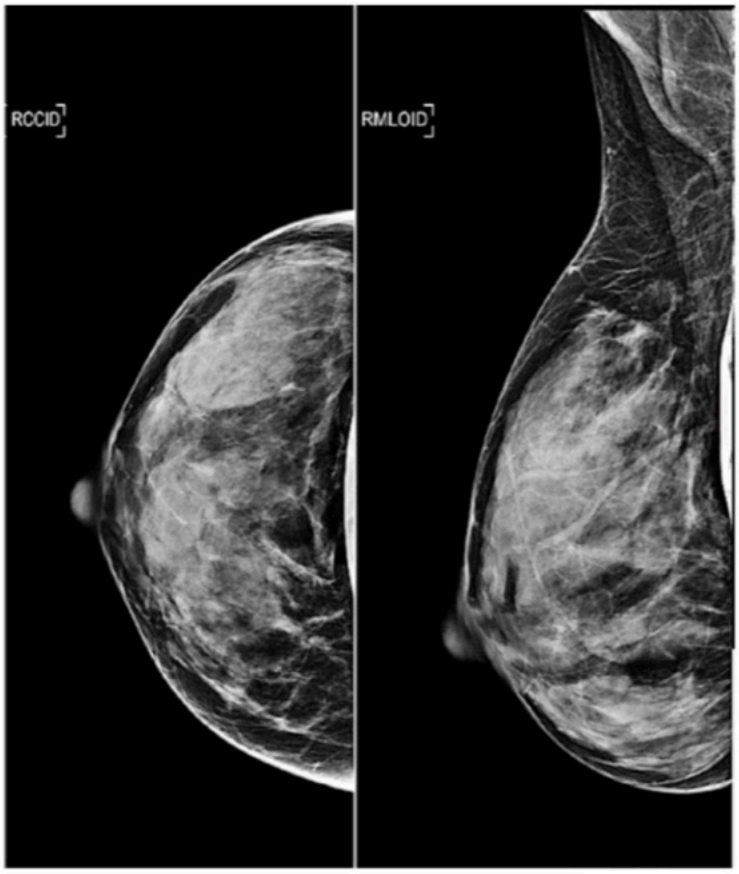

A

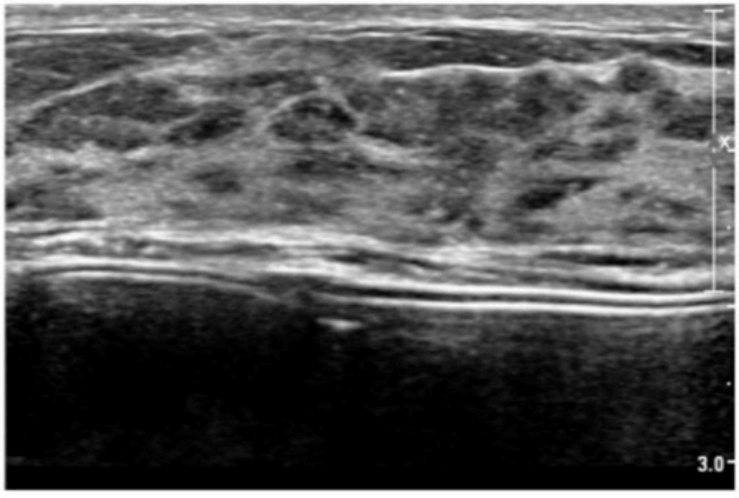

B

Figure 4 – GLANDULAR TISSUE COMPONENT: MODERATE. Mammogram (A) and ultrasound (B) of a patient with subpectoral implants and dense fibroglandular tissue. The ultrasound demonstrates a moderate degree (50% to < 75%) of TDLUs visualized within the fibroglandular zone.

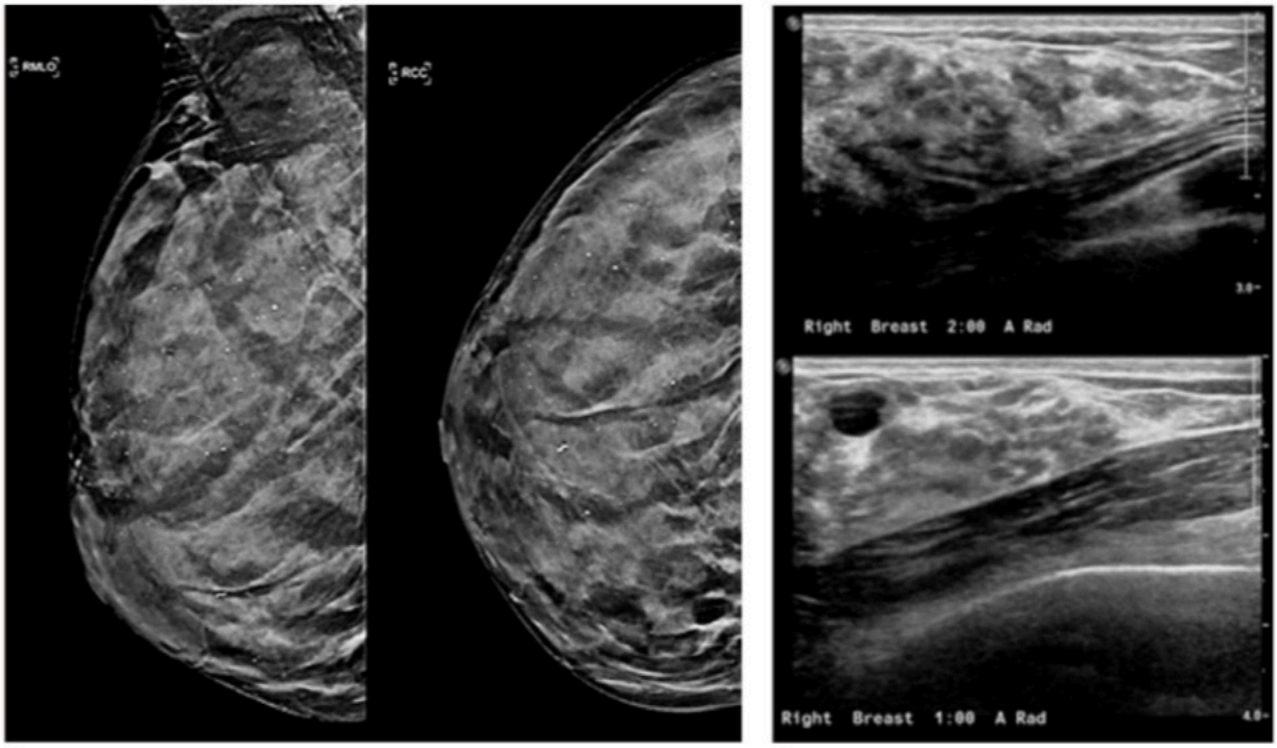

A B

Figure 5 – GLANDULAR TISSUE COMPONENT: MODERATE. Mammogram (A) demonstrates extremely dense breast tissue with scattered benign calcifications. There is a previous biopsy marker at the 6:00 axis. Corresponding right breast ultrasound (B) demonstrates a moderate amount of glandular tissue component with a simple cyst noted at the 1:00 axis.

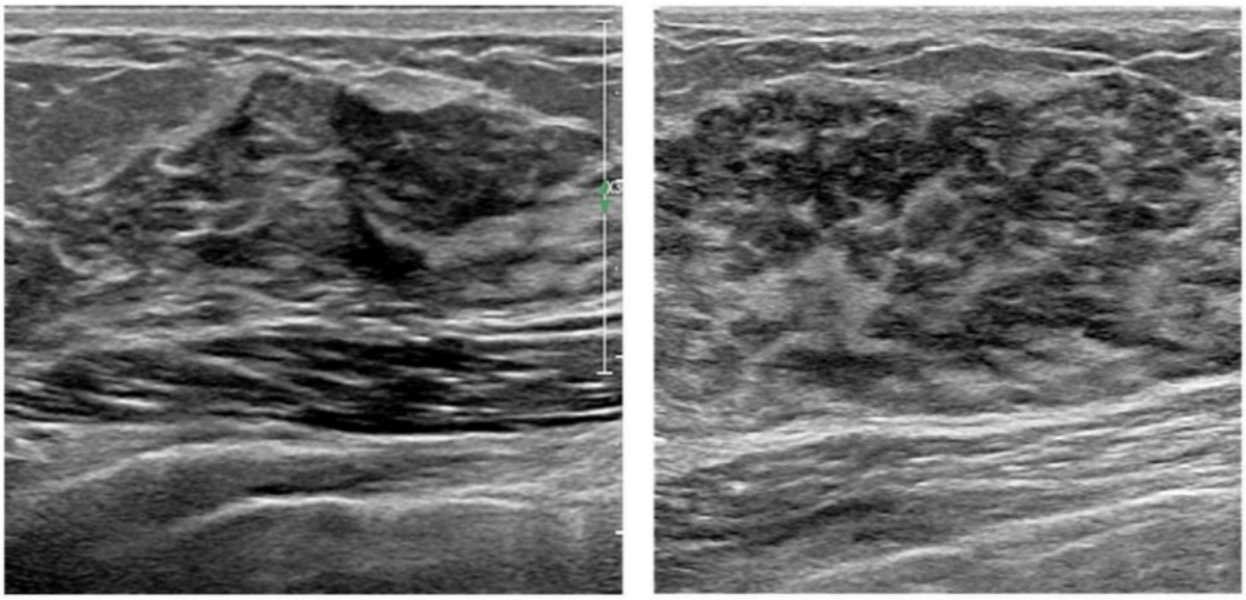

Figure 6 – GLANDULAR TISSUE COMPONENT: MARKED. Two different pre-menopausal patients with extremely dense tissue identified on mammogram (not shown). Both patients have a strong family history of breast cancer. The ultrasound demonstrates a marked degree of glandular tissue component with > 75% of the fibroglandular zone made up of TDLUs.

B. MASSES

A mass is a three-dimensional space-occupying lesion that is visible in two different planes; with volumetric acquisitions it should be seen in three planes. Masses may be benign or malignant.

1. SHAPE

   a. Oval

      A mass that is elliptical or egg-shaped. See Guidance section. The previous edition of the BI-RADS Atlas included gently lobulated masses under the descriptor OVAL. In this 2025 version, masses with gentle indentations are assigned the shape descriptor LOBULATED.

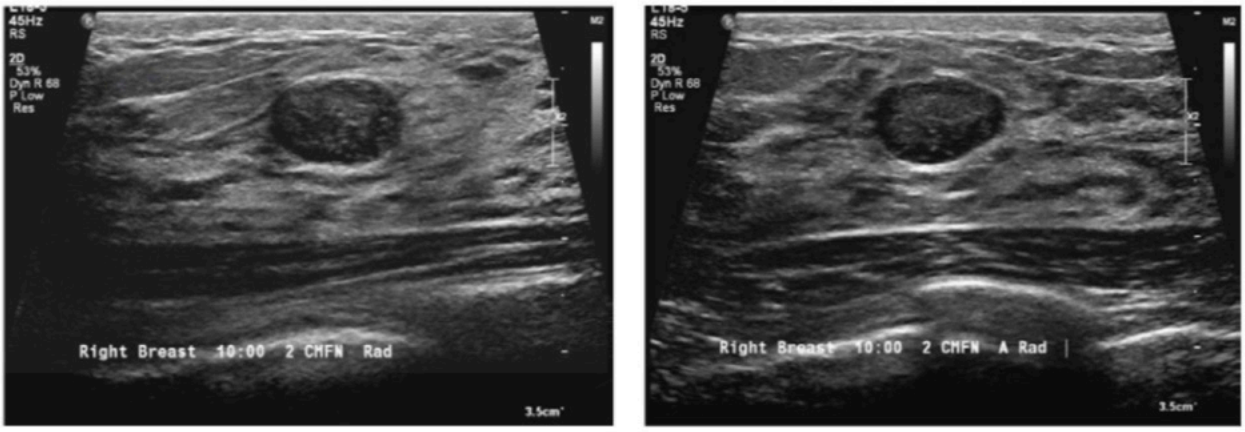

A B

Figure 1 – SHAPE: OVAL. Radial (A) and antiradial (B) images of an OVAL, circumscribed mass with parallel orientation and no posterior acoustic features. This combination of imaging features suggests a benign etiology, and the mass was assigned BI-RADS assessment category 3, probably benign. The patient requested biopsy. Pathology: Fibroadenoma.

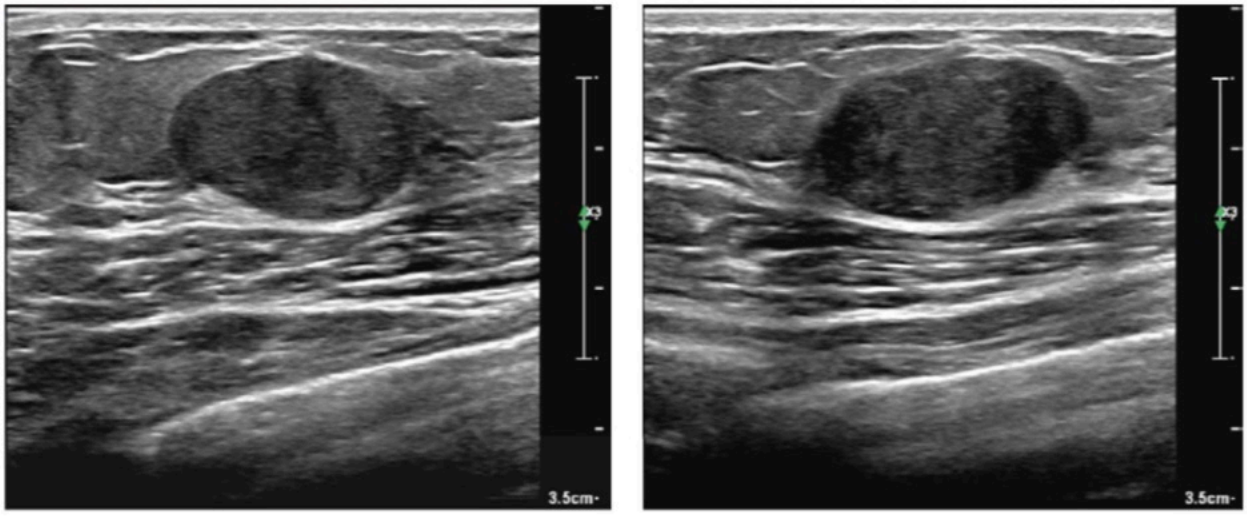

A B

Figure 2 – SHAPE: OVAL. Radial (A) and antiradial (B) images of an OVAL, hypoechoic, circumscribed mass with parallel orientation. This mass was assigned BI-RADS assessment category 3, probably benign. Biopsy was ultimately performed due to subsequent growth of the mass. Pathology: Fibroadenoma.

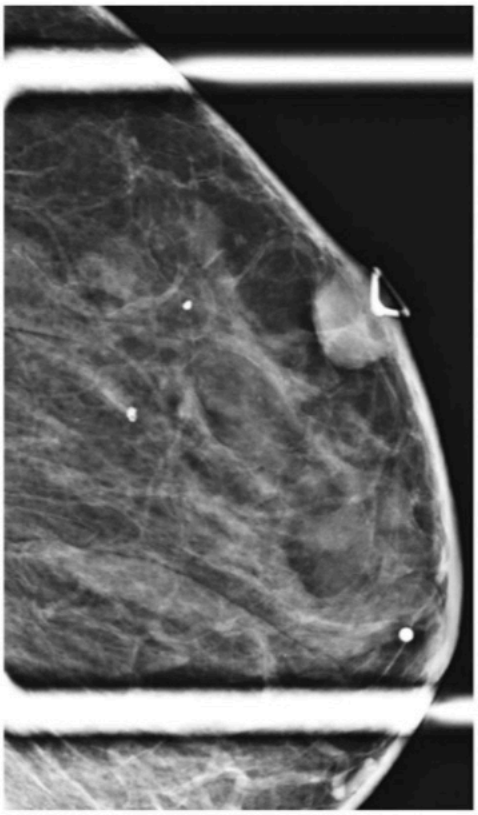

A



B

Figure 3 – SHAPE: OVAL. Spot compression mammographic view of the left breast (A) demonstrates a palpable mass in the subcutaneous fat abutting the skin. Ultrasound image (B) shows an OVAL, hypoechoic mass with circumscribed margin, parallel orientation and posterior enhancement. Pathology: Solid-cystic hidradenoma, which is a benign tumor of the apical sweat gland.

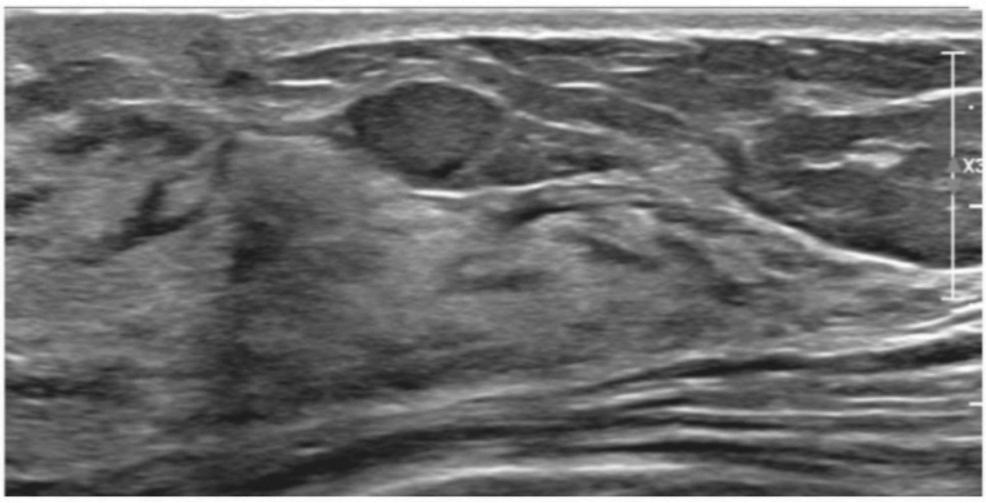

A

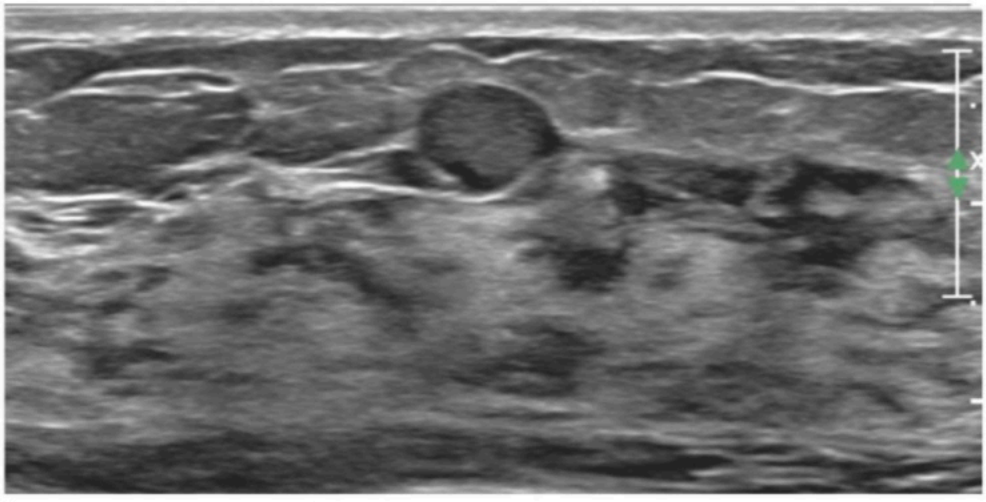

B

Figure 4 – SHAPE: OVAL. Radial (A) and antiradial (B) images of an OVAL, isoechoic, parallel mass with no posterior features. Pathology: DCIS on surgical excision.

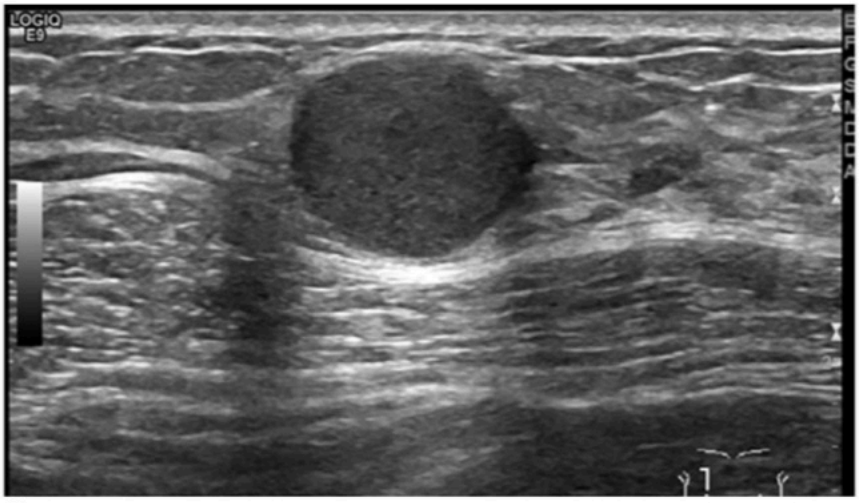

A



B

Figure 5 – SHAPE: OVAL. Radial (A) and antiradial (B) images of an OVAL, hypoechoic mass with posterior enhancement. Posterior enhancement of a solid mass is not a reassuring feature. Although the margin appears circumscribed in the radial view, it is indistinct along one margin on the antiradial view (arrow) and spiculated along another (arrowhead). Pathology: Invasive ductal carcinoma.

B. MASSES

1. SHAPE

   b. Lobulated

   A lobulated mass displays a generally oval shape but exhibits one or more indentations resulting in an undulating contour.

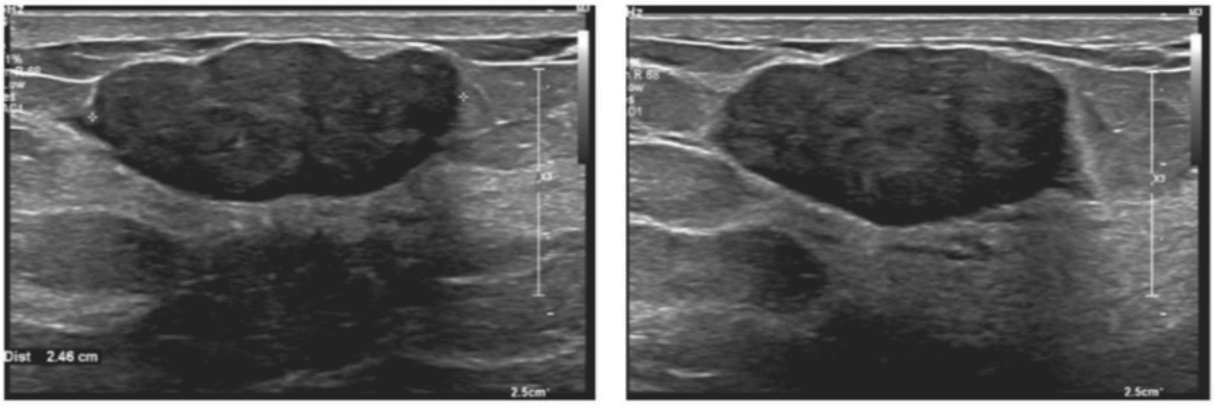

A B

Figure 1 – SHAPE: LOBULATED. Radial (A) and antiradial (B) images of a LOBULATED mass. The mass is hypoechoic, circumscribed, parallel to the skin and demonstrates mild posterior shadowing. The mass was assigned BI-RADS assessment category 3, probably benign, but the patient opted for core needle biopsy and subsequent excision. Pathology: Fibroadenoma.

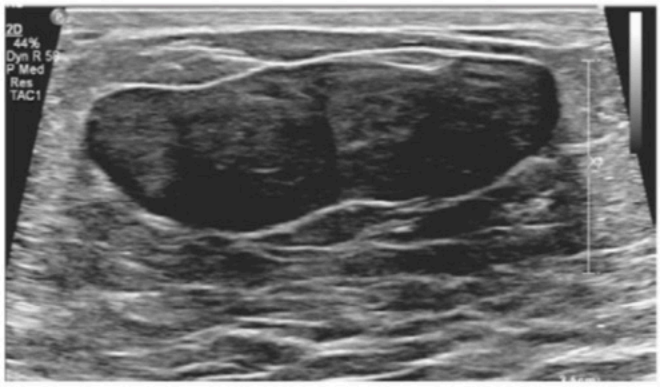

Figure 2 – SHAPE: LOBULATED. Radial image of a LOBULATED mass. The mass is circumscribed, parallel, and has an echogenic pseudocapsule. Because the mass was stable over two years, it was assigned to the BI-RADS assessment category 2, benign. Presumptive diagnosis: Fibroadenoma.



Figure 3 – SHAPE: LOBULATED. Hypoechoic parallel LOBULATED mass with posterior enhancement. Pathology: Benign phyllodes tumor.

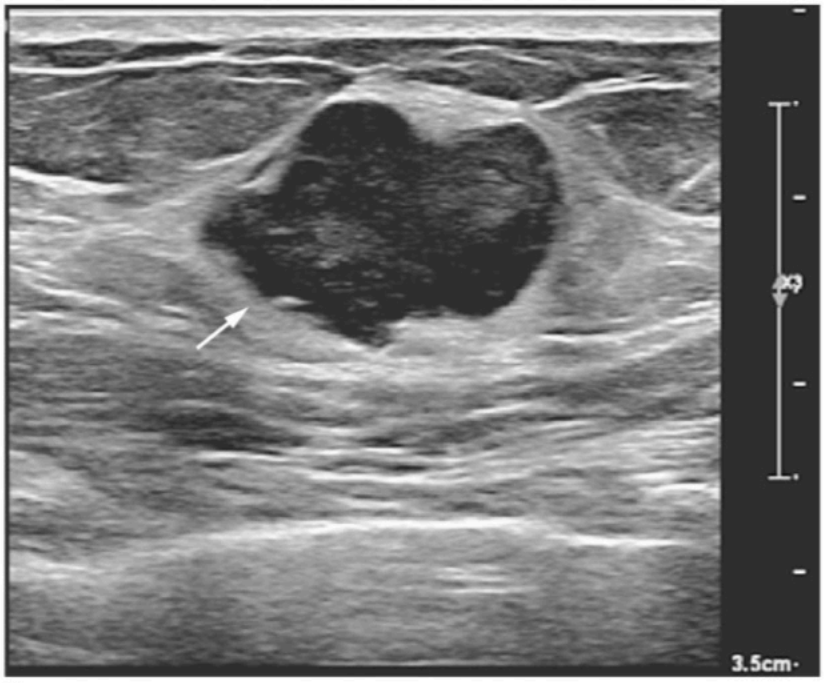

A



B

Figure 4 – SHAPE: LOBULATED. Radial (A) and antiradial (B) images of a LOBULATED, parallel, hypoechoic mass. Although part of the margin is circumscribed, portions are indistinct (arrows). Pathology: Grade 3 invasive ductal carcinoma.

B. MASSES

1. SHAPE

   c. Round

   A round mass is one that is spherical. It has an antero-posterior diameter roughly equal to its transverse and longitudinal diameters. To qualify as round, a mass must be circular in perpendicular projections. Note that, by definition, the orientation of a round mass is non-parallel.

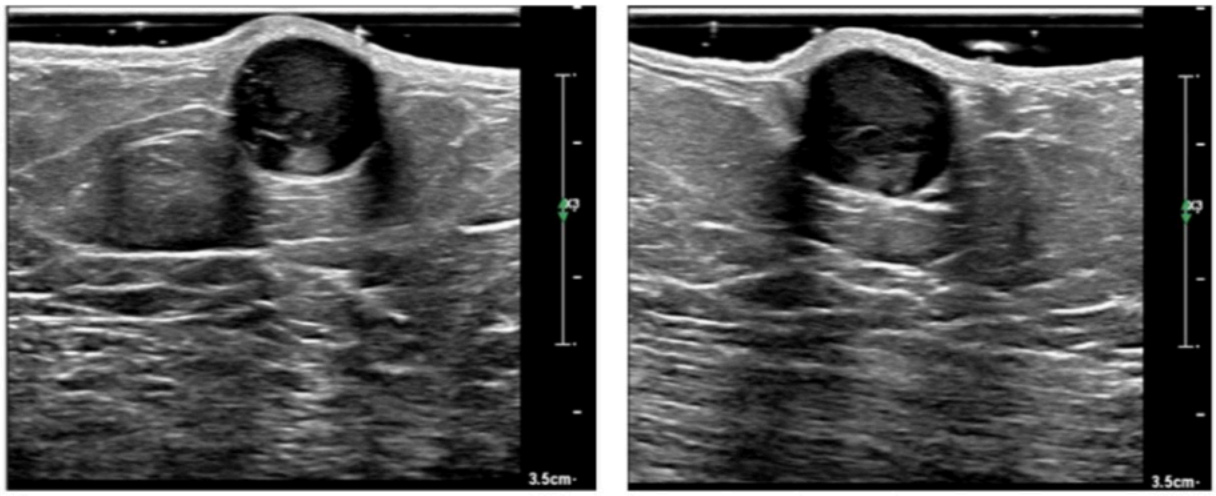

A B

Figure 1 – SHAPE: ROUND. Radial (A) and antiradial (B) images of a ROUND, hypoechoic, non-parallel mass with posterior enhancement. Epidermal inclusion cyst was suspected, but a definitive tract to the skin could not be identified. Biopsy was therefore performed. Pathology: Epidermal inclusion cyst.

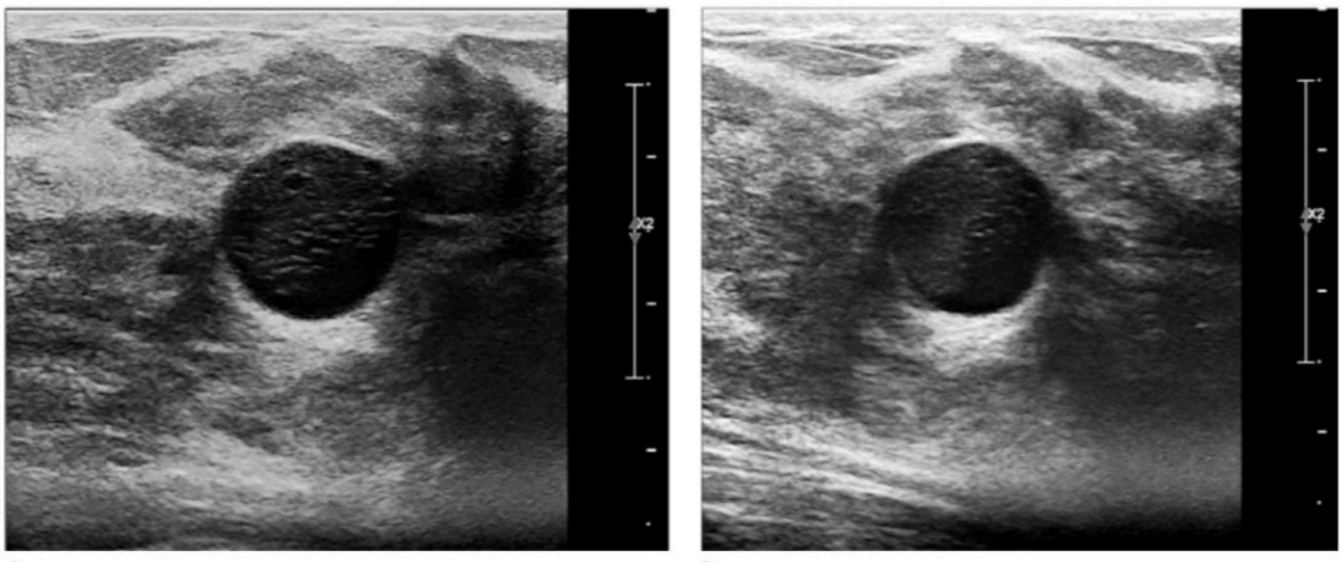

A B

Figure 2 – SHAPE: ROUND. Radial (A) and antiradial (B) images of a ROUND, circumscribed, non-parallel mass with posterior enhancement. Pathology: Adenomyoepithelioma.

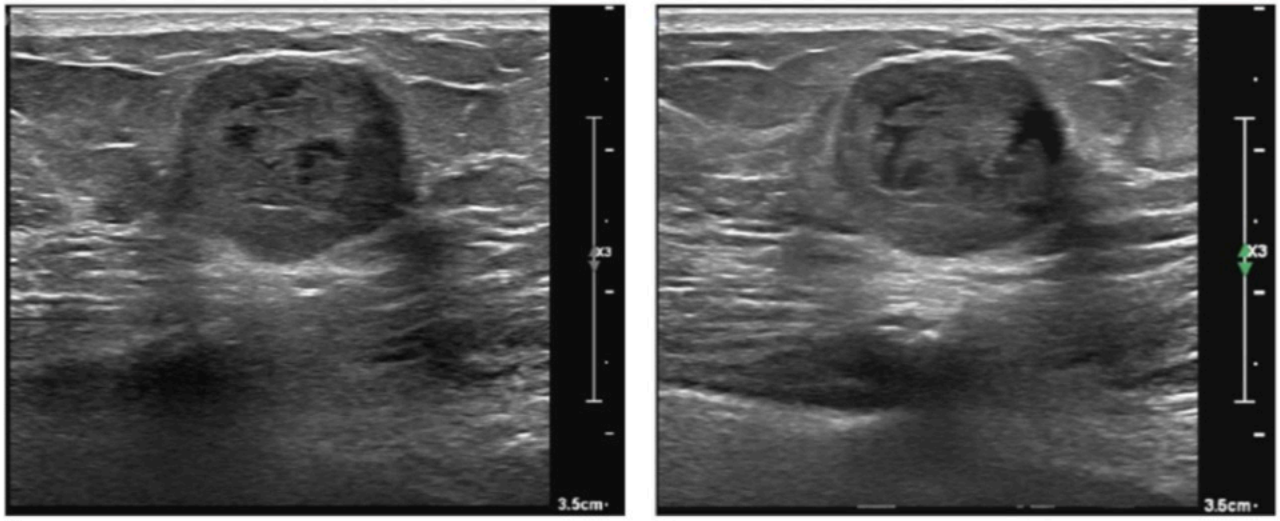

A B

Figure 3 – SHAPE: ROUND. Radial (A) and antiradial (B) images of a ROUND mass with heterogeneous echo pattern and posterior enhancement. Pathology: Mucinous carcinoma.

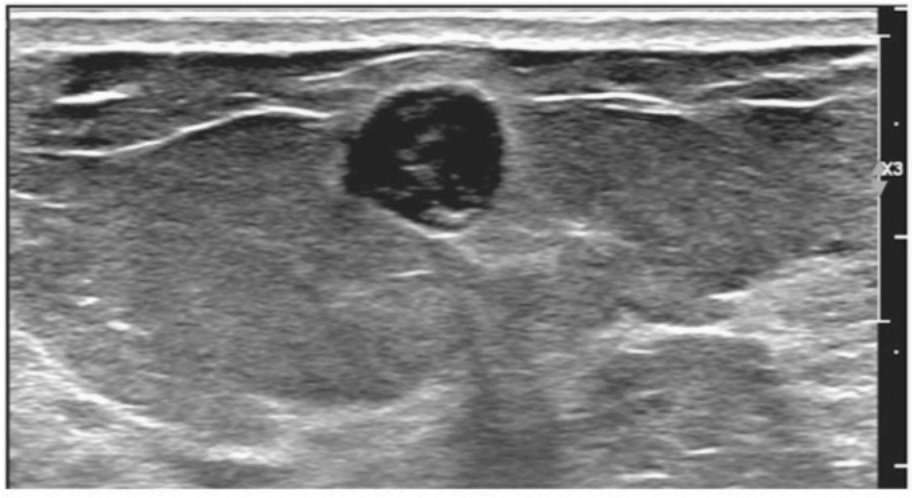

A

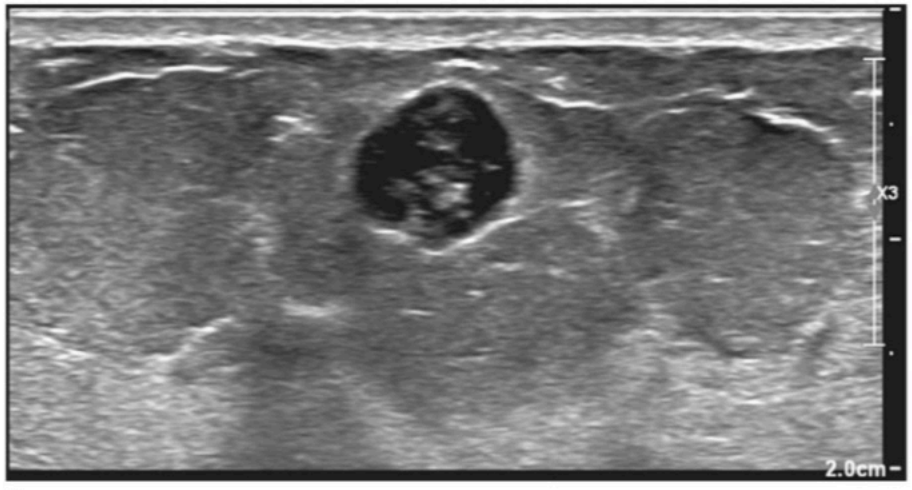

B

Figure 4 – SHAPE: ROUND. Radial (A) and antiradial (B) images of a ROUND heterogeneous mass with no posterior features. Because the mass is round, the mass orientation is defined as non-parallel. Pathology: Metastatic melanoma.

B. MASSES

1. SHAPE

   d. Irregular

      Any mass that is not round, oval, or lobulated with acute angle protrusions is defined as irregular in shape.

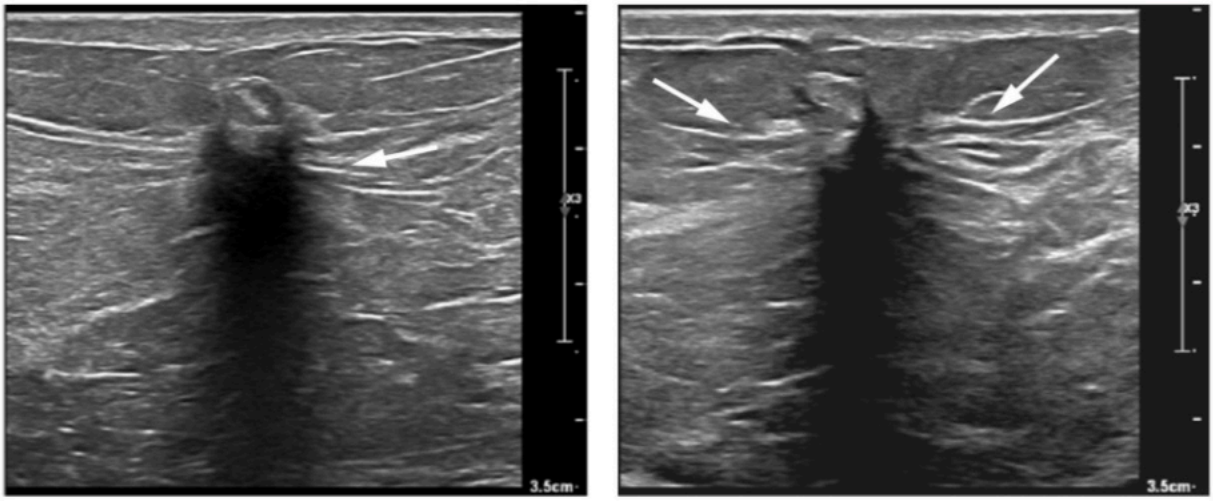

A B

Figure 1 – SHAPE: IRREGULAR. Radial (A) and antiradial (B) images of an IRREGULAR mass in a patient who had previously undergone lumpectomy and radiation therapy. The mass is hypoechoic, demonstrates substantial posterior shadowing, and has associated straightening and thickening of Cooper's ligaments (arrows). Pathology: Dense fibrosis suggestive of postsurgical site.

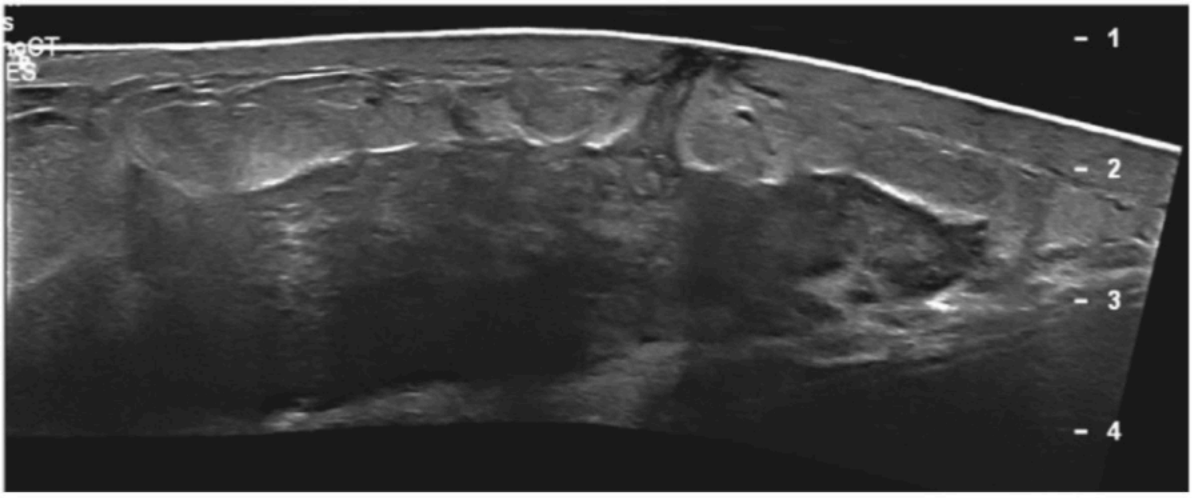

A

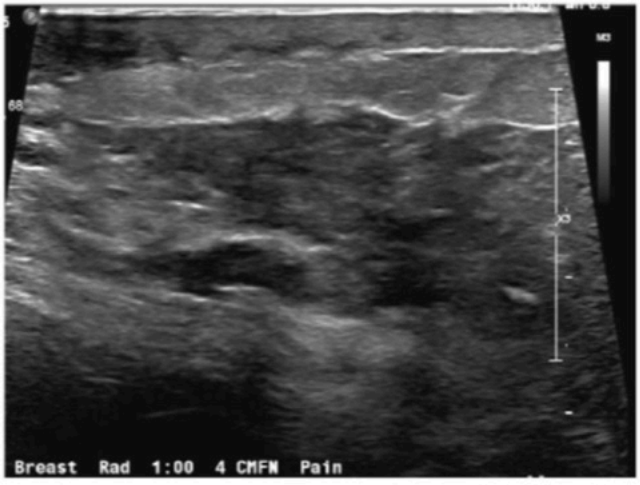

B

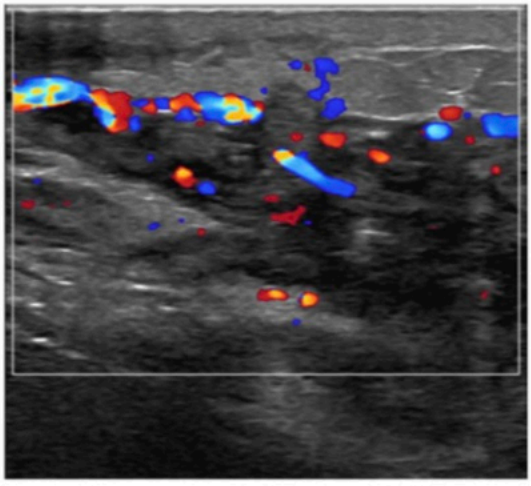

C

Figure 2 – SHAPE: IRREGULAR. Extended field-of-view (EFOV) (A) and radial (B) images of a large IRREGULAR hypoechoic mass in a patient who presented with severe breast pain. Doppler ultrasound image (C) demonstrates hypervascularity of the mass. Attempt at aspiration yielded no fluid, and subsequent core needle biopsy demonstrated noncaseating granulomas, giant cells, and chronic inflammation. Pathology: Granulomatous mastitis.

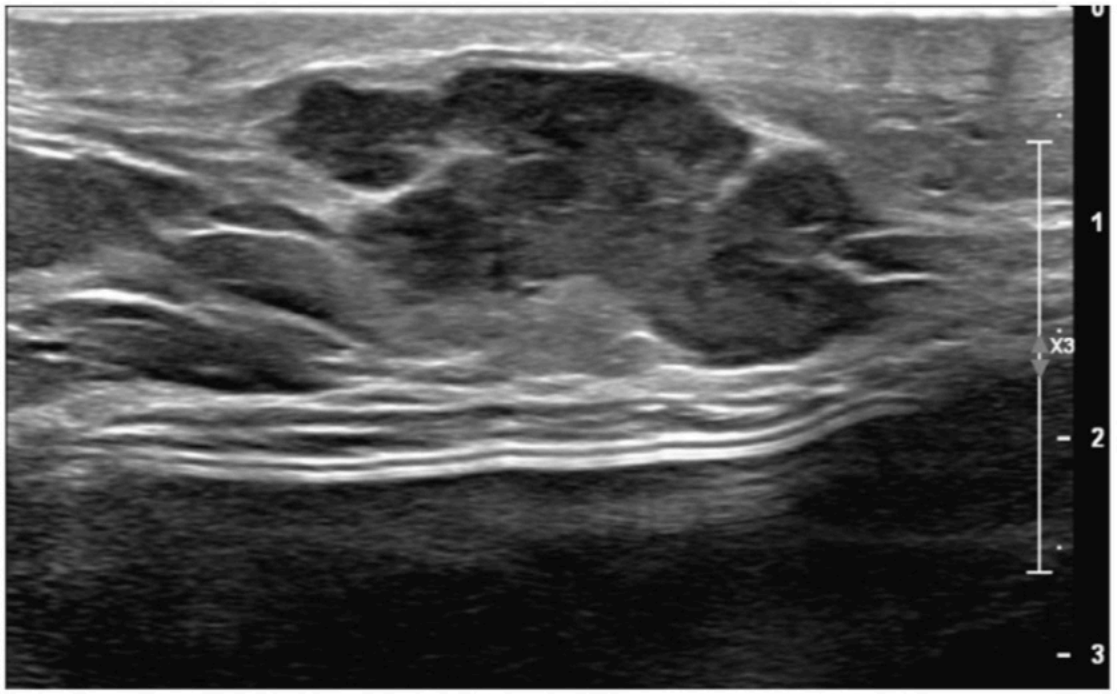

A

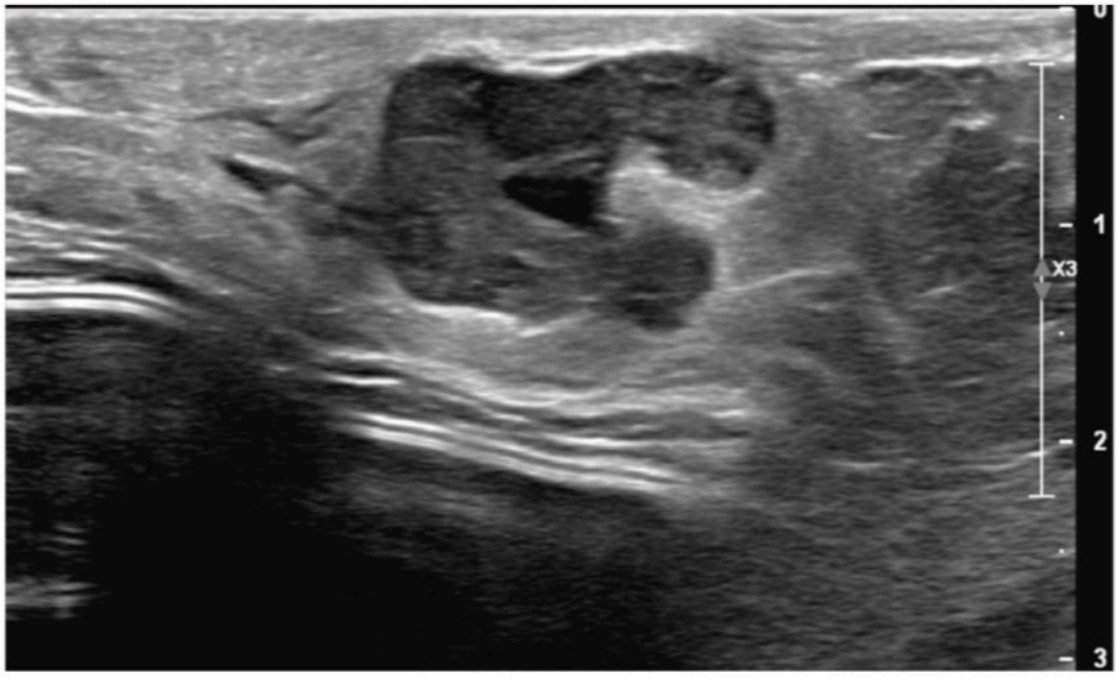

B

Figure 3 – SHAPE: IRREGULAR. Radial (A) and antiradial (B) images of an IRREGULAR mass with parallel orientation and posterior enhancement overlying a silicone breast implant. Pathology: Invasive ductal carcinoma.

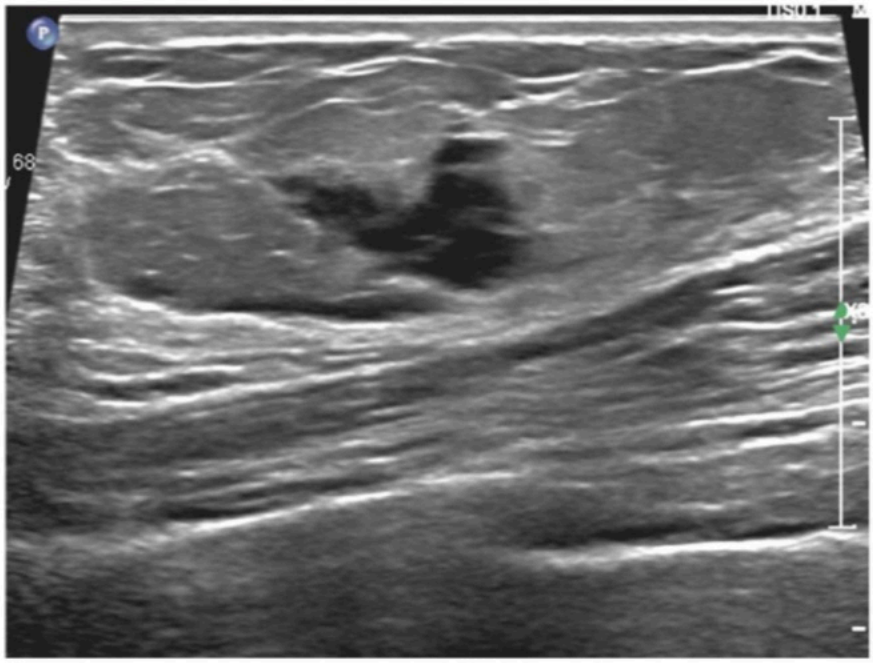

A

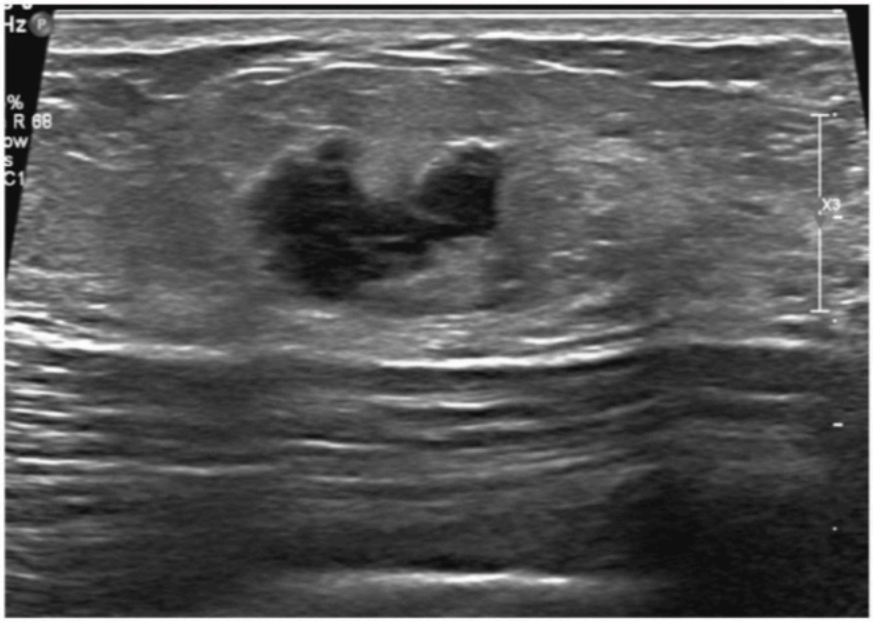

B

Figure 4 – SHAPE: IRREGULAR. Radial (A) and antiradial (B) images of an IRREGULAR mass. Margin is indistinct, and orientation is parallel. Pathology: Grade 3 invasive ductal carcinoma.

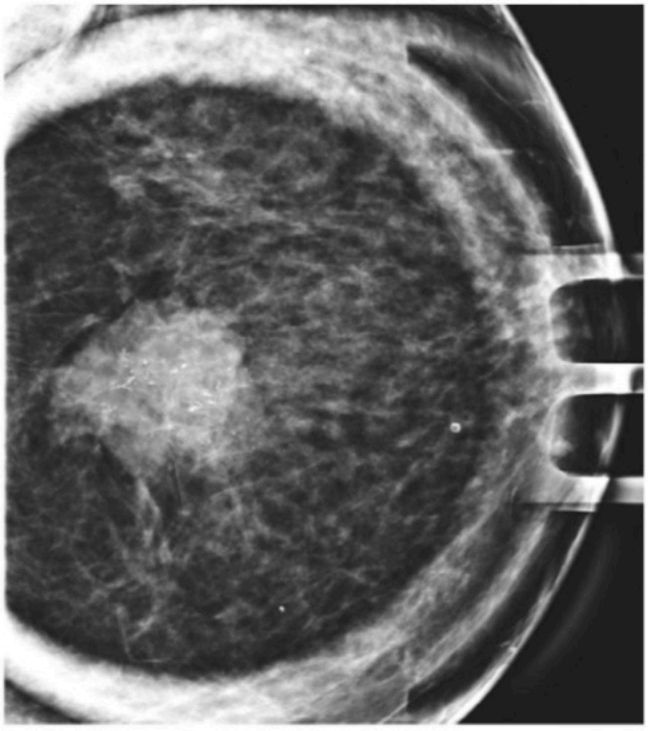

A

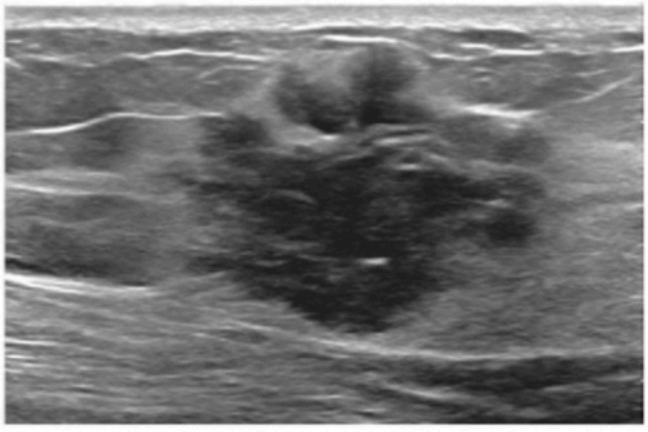

B

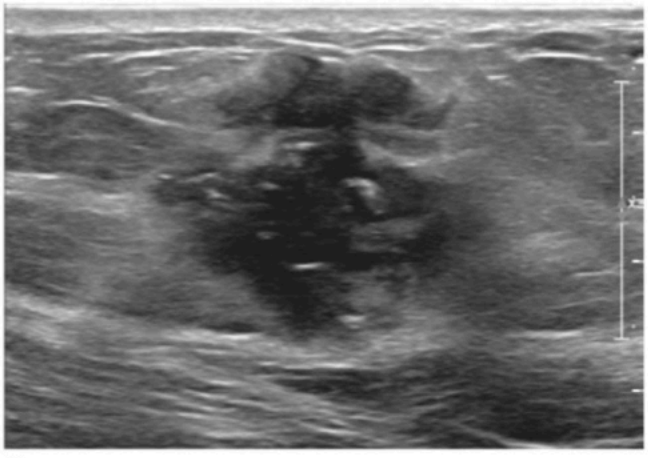

C

Figure 5 – SHAPE: IRREGULAR. Spot compression magnification view (A) of an irregular indistinct mass with fine pleomorphic calcifications. Radial (B) and antiradial (C) ultrasound images demonstrate an IRREGULAR mass with indistinct margin, non-parallel orientation, no posterior features, and an echogenic rind. Echogenic foci within the mass correspond to calcifications seen on mammography. Pathology: Grade 3 invasive ductal carcinoma.

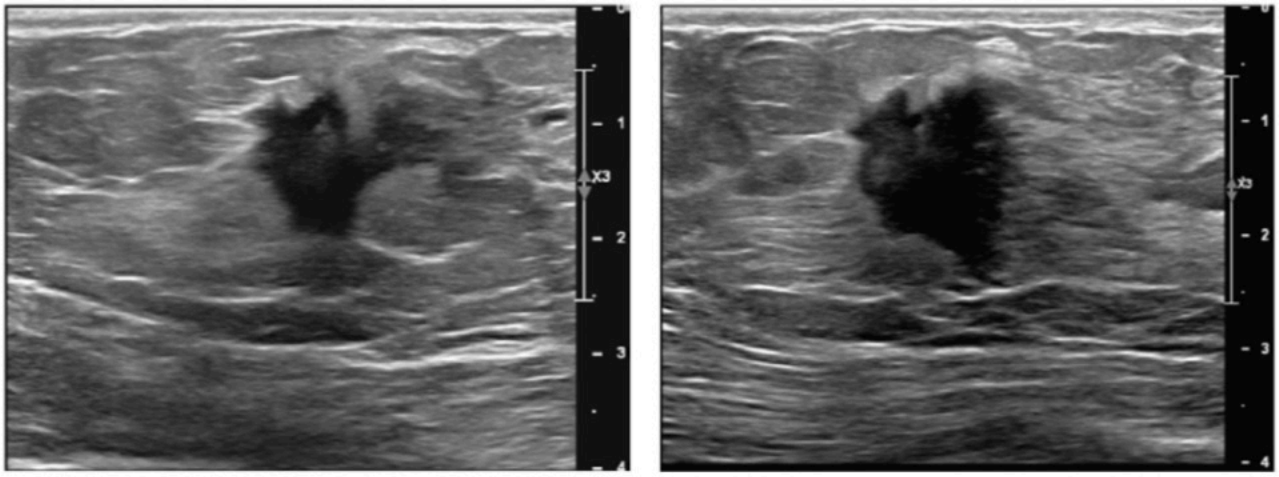

A B

Figure 6 – SHAPE: IRREGULAR. Radial (A) and antiradial (B) images of an IRREGULAR non-parallel mass. The margin is indistinct, angular, and spiculated (though only the most suspicious margin, spiculated, should be reported) with mild shadowing. Pathology: Invasive ductal carcinoma.

B. MASSES

2. ORIENTATION

Orientation of a mass is defined with reference to the skin line.

a. Parallel

The horizontal dimension of the mass is greater than the anteroposterior dimension in all US orientations. Parallel orientation is a property of most benign masses. However, many carcinomas may have parallel orientation as well.

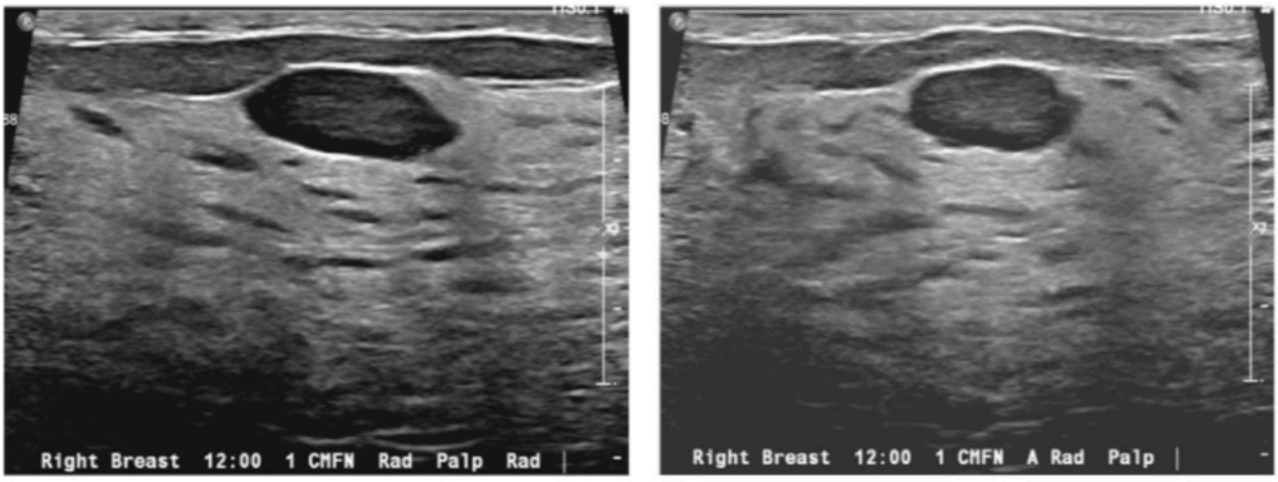

A B

Figure 1 – ORIENTATION: PARALLEL. Radial (A) and antiradial (B) images of a circumscribed mass with posterior enhancement and PARALLEL orientation. The mass remained stable by imaging for 2 years, presumed fibroadenoma.

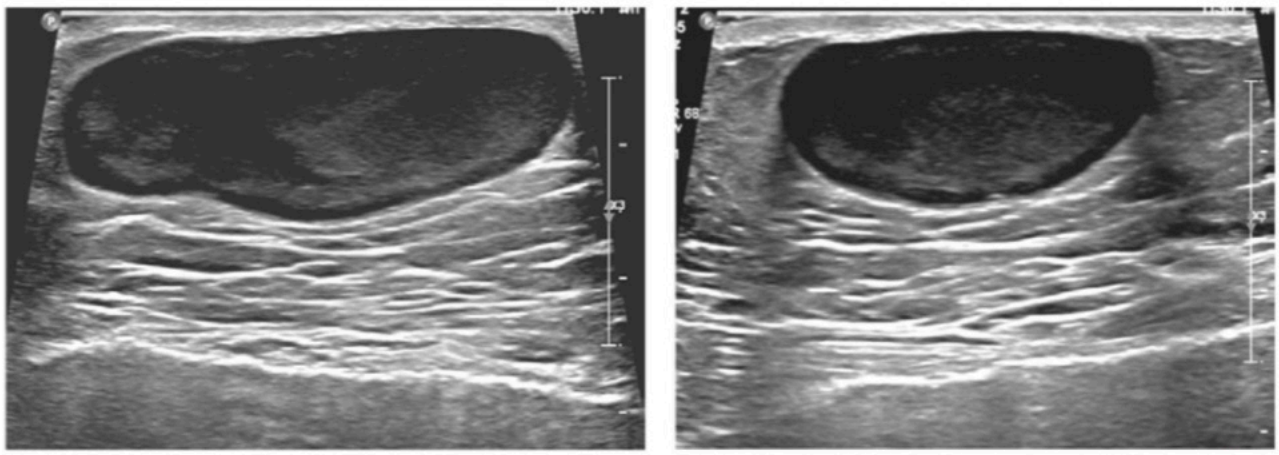

A B

Figure 2 – ORIENTATION: PARALLEL. Radial (A) and antiradial (B) images of a hypoechoic oval circumscribed mass. Orientation is PARALLEL. Pathology: Fibroadenoma.

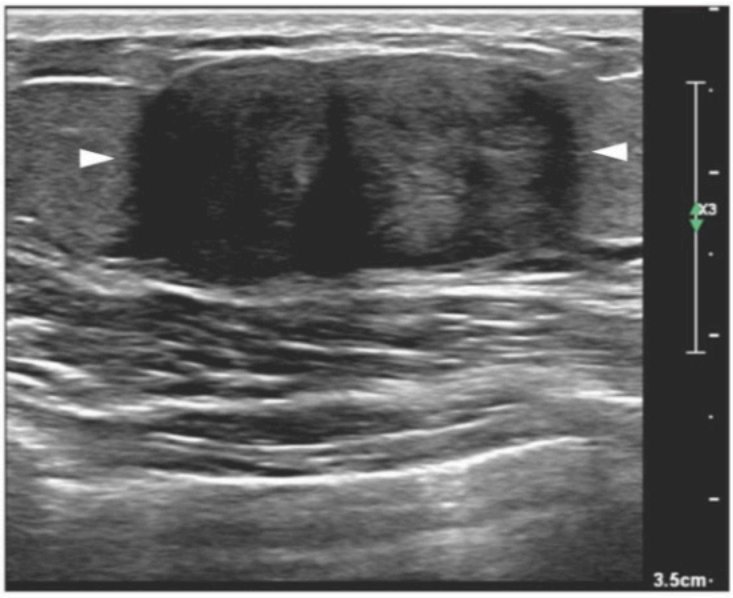

A

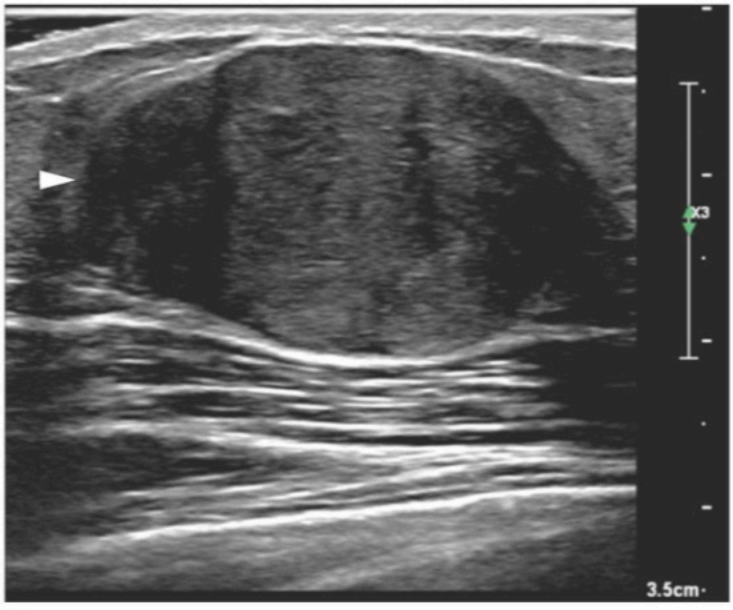

B

Figure 3 – ORIENTATION: PARALLEL. Radial (A) and antiradial (B) images of an oval mass with indistinct margin along the sides of the mass (arrowheads). Orientation is PARALLEL. Pathology: Fibroadenoma.



A

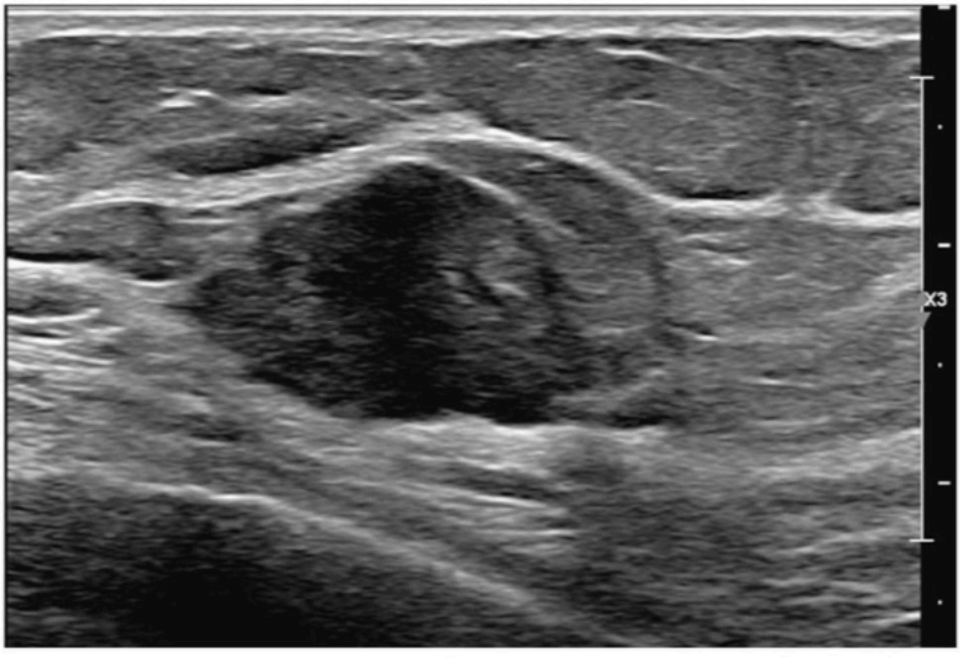

B

Figure 4 – ORIENTATION: PARALLEL. Radial (A) and antiradial (B) images of an oval mass with indistinct margin. Orientation is PARALLEL. Pathology: Invasive ductal carcinoma.



A



B

Figure 5 – ORIENTATION: PARALLEL. Radial (A) and antiradial (B) images of an oval, predominantly isoechoic mass with indistinct margin and no posterior features. Caliper measurements confirm the horizontal dimensions of the mass are greater than the anteroposterior dimensions in all ultrasound views; hence, the orientation of the mass is PARALLEL. Pathology: Invasive ductal carcinoma.

B. MASSES

2. ORIENTATION

b. Non-parallel (historically “not parallel”)

The anteroposterior dimension of the mass is equal to or greater than the horizontal dimension in any ultrasound orientation. If any part of the mass is non-parallel, the entire mass is defined as non-parallel. Round masses are defined as non-parallel. Non-parallel is typically a suspicious feature.

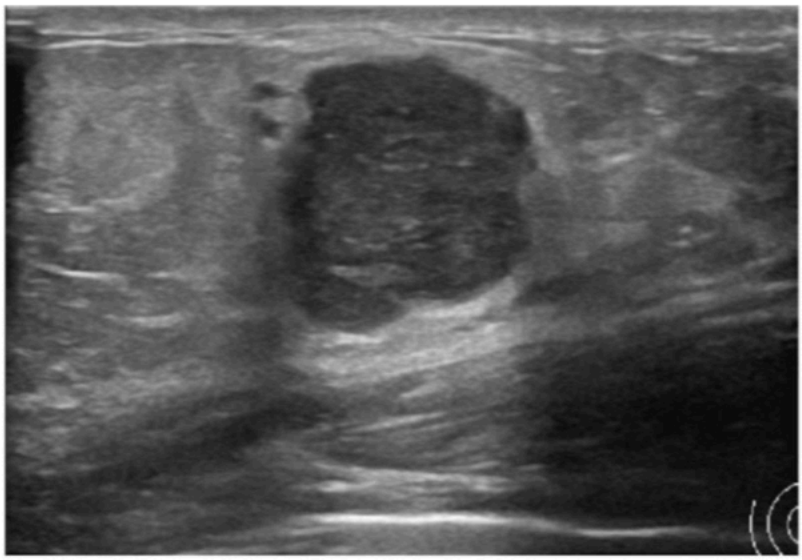

A

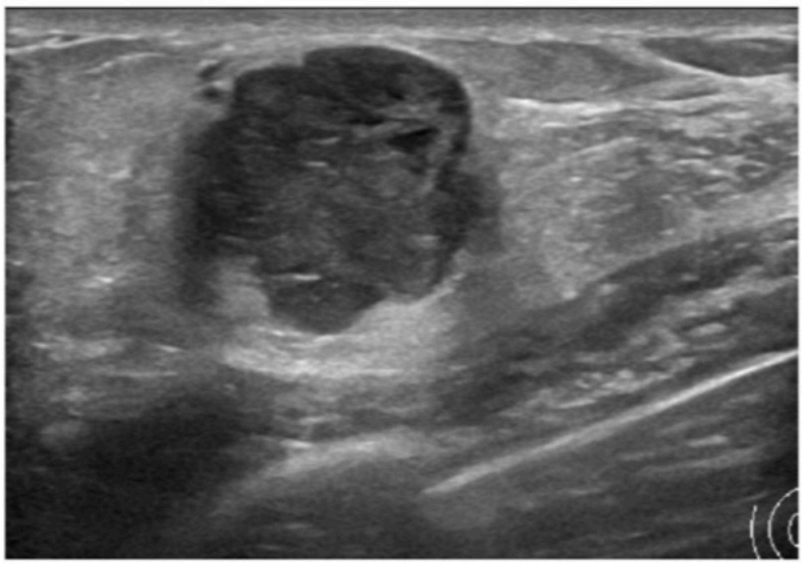

B

Figure 1 – ORIENTATION: NON-PARALLEL. Radial (A) and antiradial (B) images of a hypoechoic, lobulated mass with posterior enhancement and NON-PARALLEL orientation. Although largely circumscribed, the side margins are indistinct. Pathology: Invasive ductal carcinoma.



A

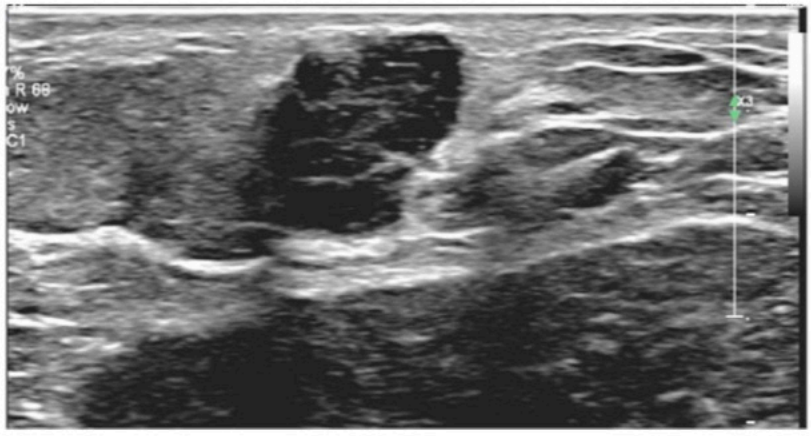

B

Figure 2 – ORIENTATION: NON-PARALLEL. Radial (A) and antiradial (B) images of a lobulated mass with indistinct margin and posterior enhancement. Orientation is NON-PARALLEL. Pathology: Invasive ductal carcinoma.

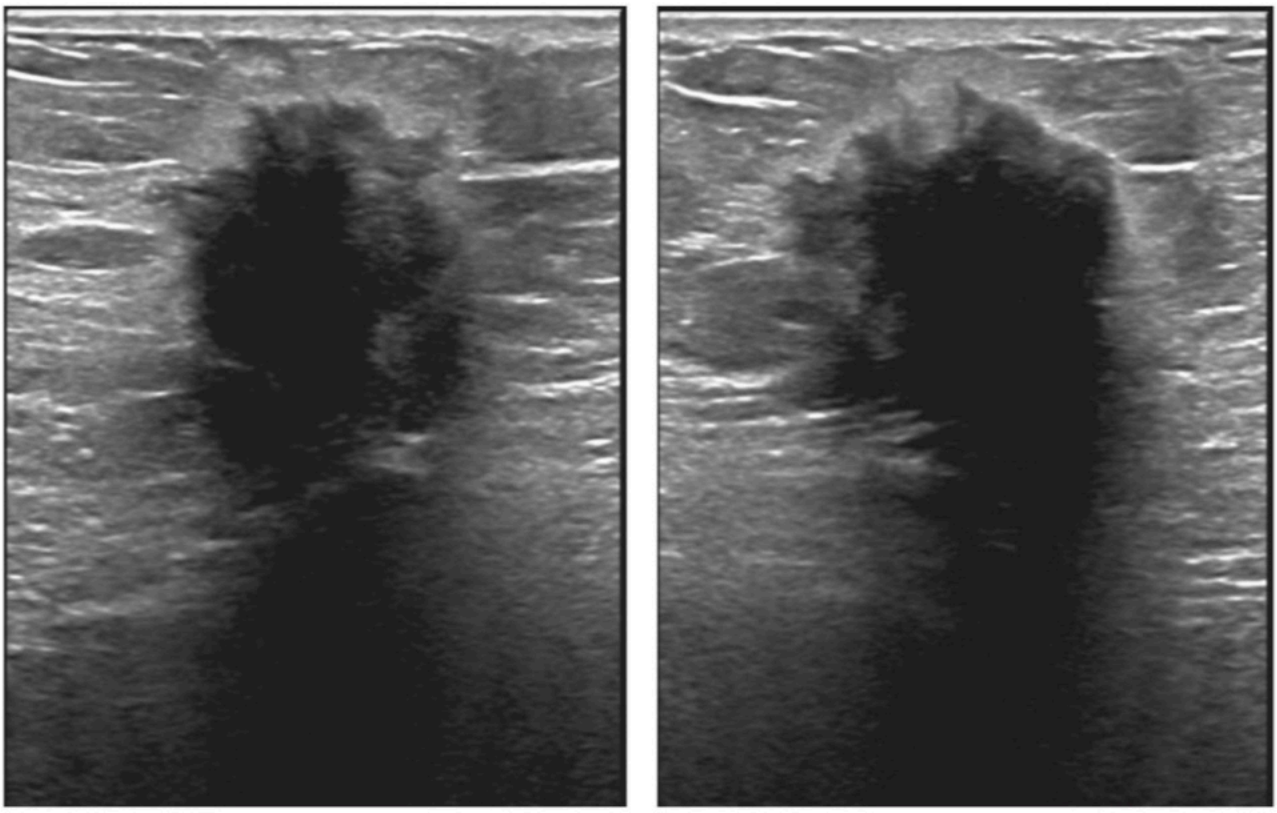

A B

Figure 3 – ORIENTATION: NON-PARALLEL. Radial (A) and antiradial (B) images of mass with irregular shape, spiculated margin, posterior shadowing and an echogenic rind. Orientation is NON-PARALLEL. Pathology: Invasive ductal carcinoma.

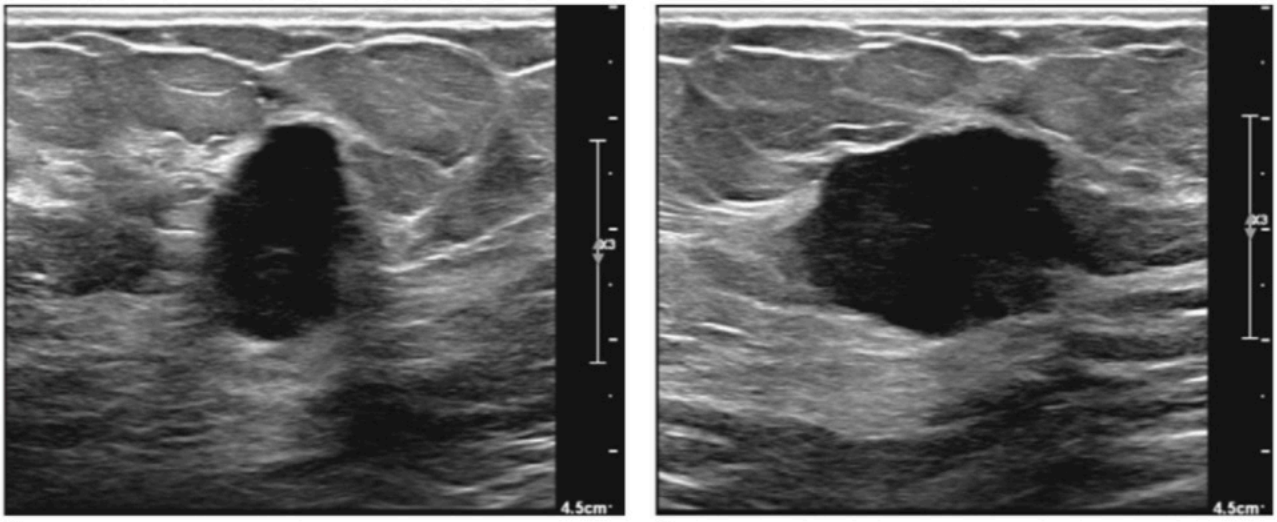

A B

Figure 4 – ORIENTATION: NON-PARALLEL. Radial (A) and antiradial (B) images of an oval mass with indistinct and spiculated margin. Orientation is NON-PARALLEL in the radial image (A) which therefore defines the entire mass as NON-PARALLEL. Pathology: Grade 3 invasive ductal carcinoma.

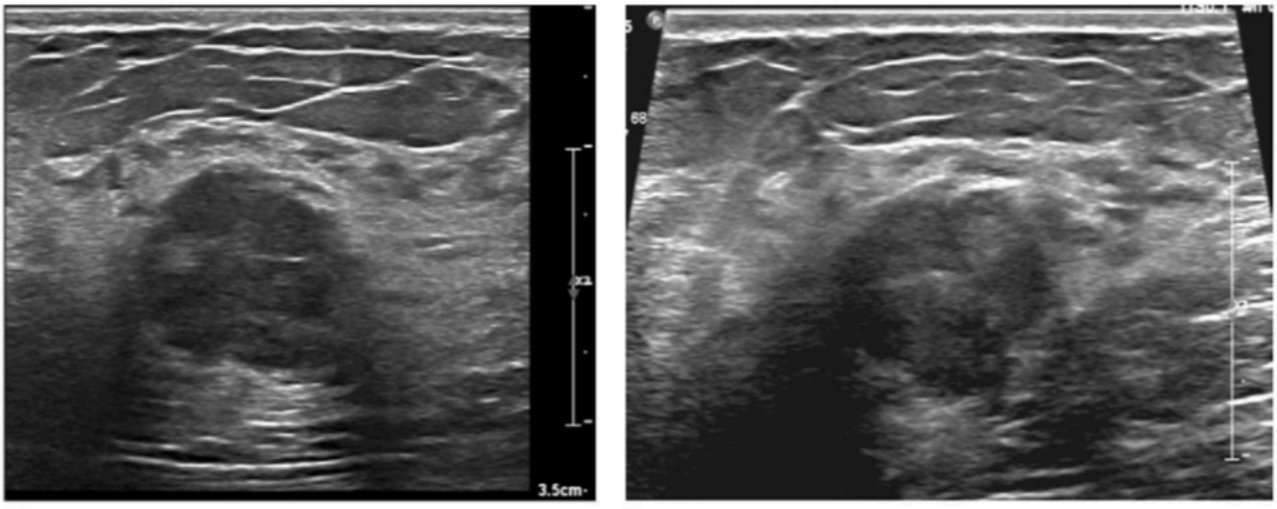

A B

Figure 5 – ORIENTATION: NON-PARALLEL. Radial (A) and antiradial (B) images of a round mass with indistinct margin and posterior enhancement. Orientation of round masses is defined as NON-PARALLEL. Pathology: Invasive ductal carcinoma.

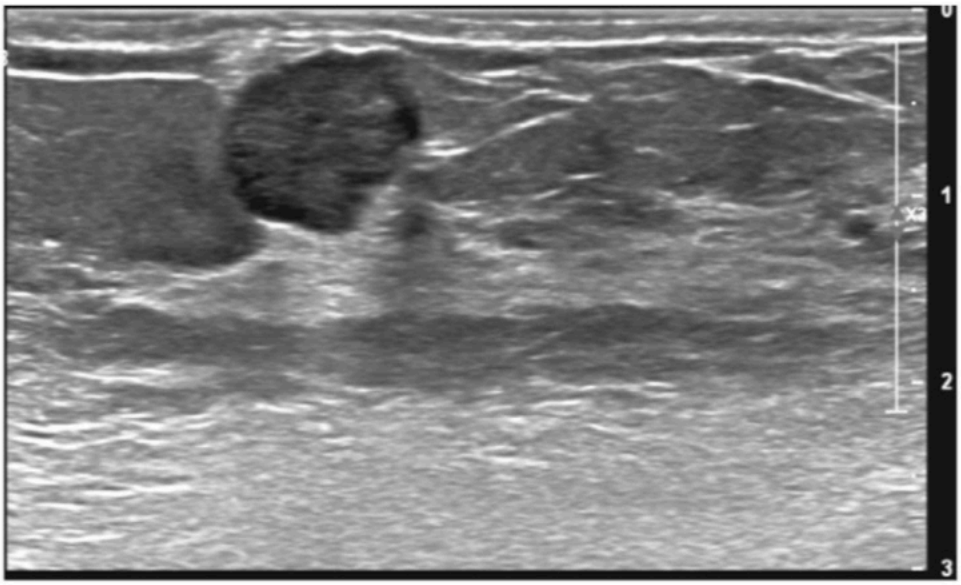

A

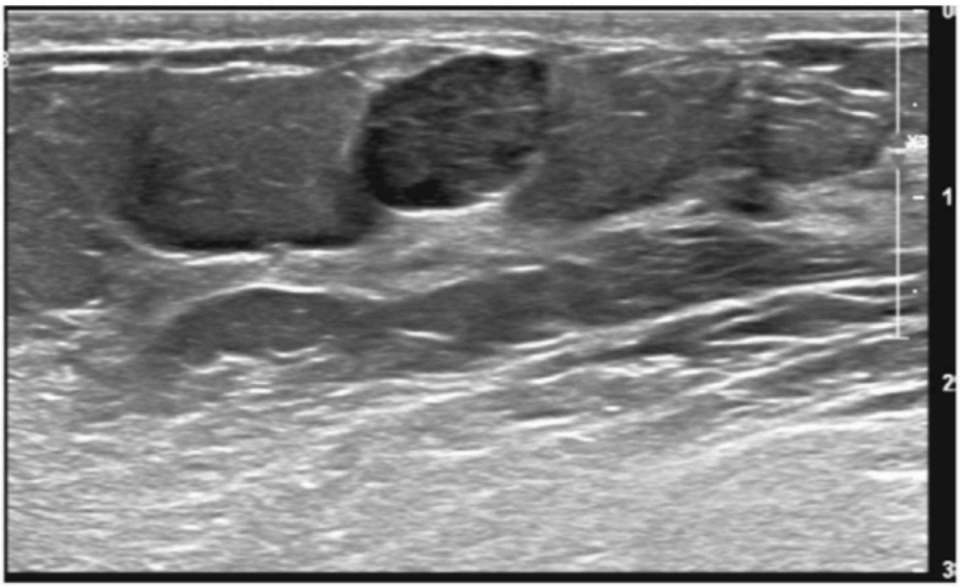

B

Figure 6 – ORIENTATION: NON-PARALLEL. Radial (A) and antiradial (B) images of an indistinct mass with NON-PARALLEL orientation. The horizontal dimension is the same as the anteroposterior in the radial projection (A) which defines the orientation as NON-PARALLEL. Despite the apparent parallel orientation in the antiradial view (B), the NON-PARALLEL orientation in one view is sufficient to make this a suspicious mass. Pathology: Invasive ductal carcinoma.

B. MASSES

3. MARGIN

The margin is the edge or border of a mass. The descriptors of margin, like the descriptors of shape, are important predictors of whether a mass is benign or malignant.

a. Circumscribed

A circumscribed margin is one that is very well defined, with a sharp transition between the mass and the surrounding tissue. For a mass to be described as circumscribed at ultrasound, the entire margin must be sharply defined. Care must be taken to fully evaluate the side margins by tipping or rocking the transducer as needed. Circumscribed margin often indicates a benign mass, but other factors including stability and shape must be considered. Most circumscribed masses have oval, lobulated, or round shapes, but irregularly shaped masses may, on occasion, be circumscribed. In that case, the irregular shape usually defines the mass as suspicious.

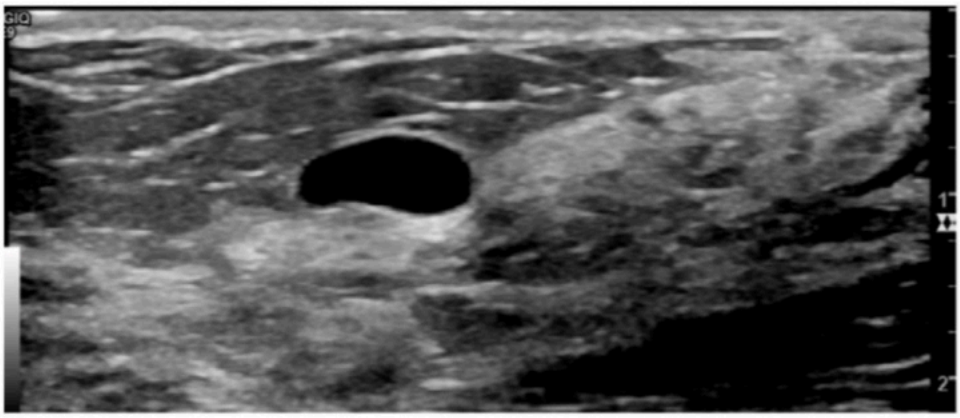

A



B

Figure 1 – MARGIN: CIRCUMSCRIBED. Radial (A) and antiradial (B) images of an oval, anechoic mass with CIRCUMSCRIBED margin. Diagnosis: Simple cyst.

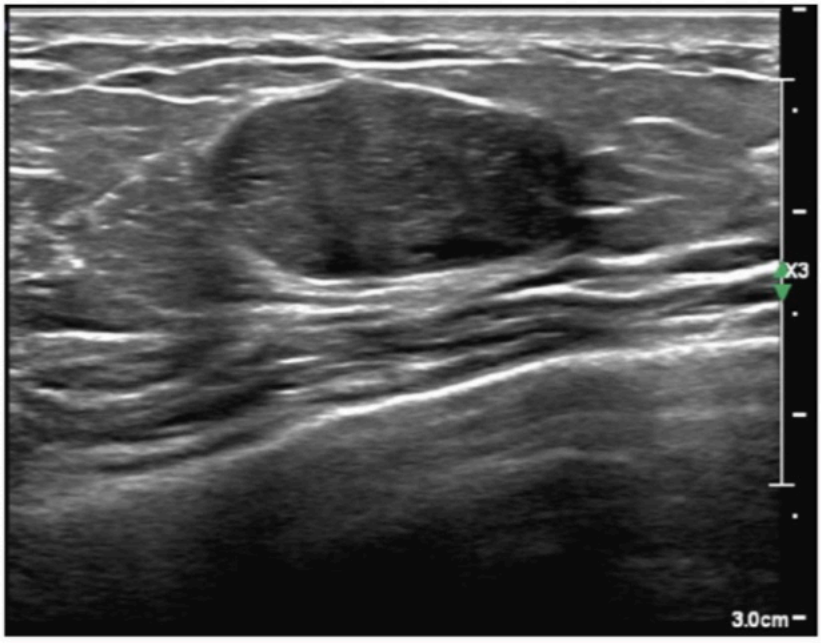

A



B

Figure 2 – MARGIN: CIRCUMSCRIBED. Radial (A) and antiradial (B) images of a hypoechoic lobulated mass with CIRCUMSCRIBED margin and parallel orientation. The mass was assigned BI-RADS assessment category 3, probably benign, but was larger in size at follow-up, prompting biopsy. Pathology: Fibroadenoma.

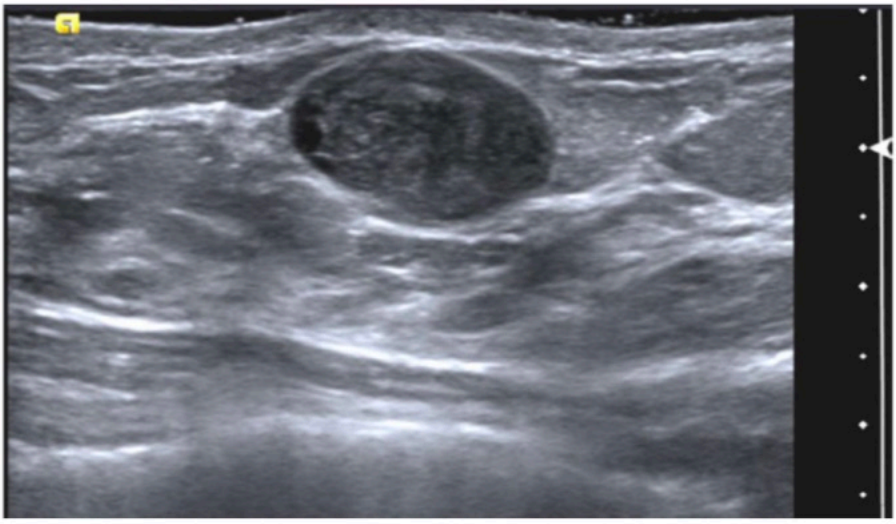

A

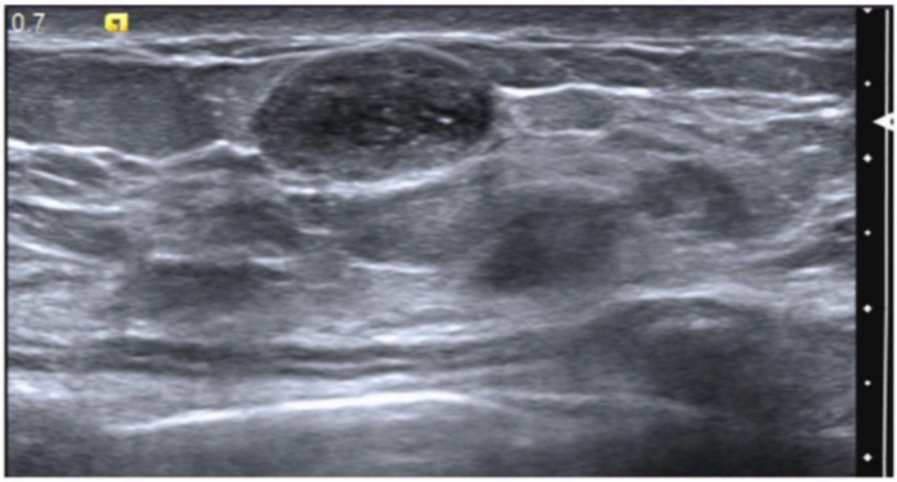

B

Figure 3 – MARGIN: CIRCUMSCRIBED. Radial (A) and antiradial (B) images of an oval, hypoechoic mass. Margin is CIRCUMSCRIBED, and orientation is parallel. The mass was assigned BI-RADS assessment category 3, probably benign. The mass grew substantially in size at follow-up, prompting core biopsy. Pathology: Complex fibroadenoma.

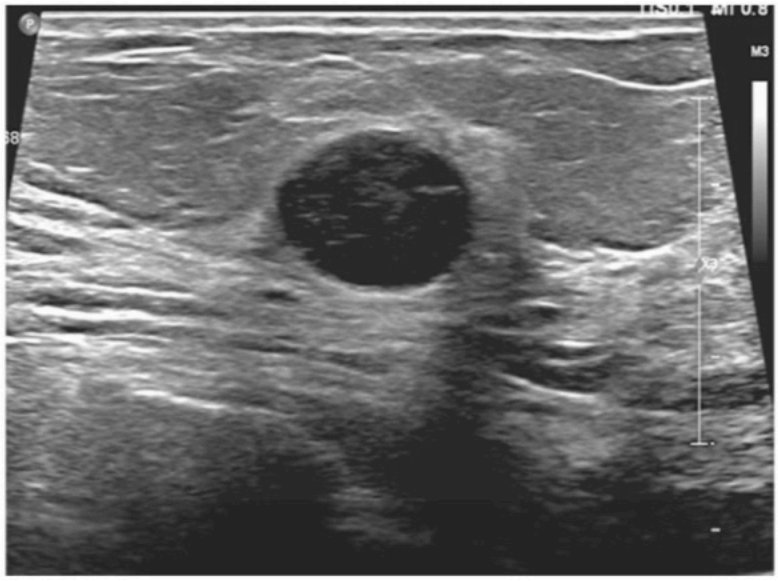

A

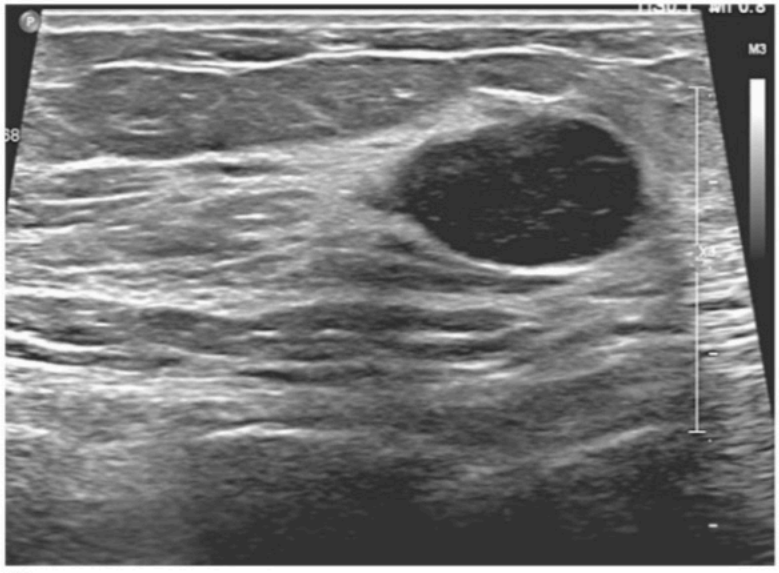

B

Figure 4 – MARGIN: CIRCUMSCRIBED. Radial (A) and antiradial (B) images of an oval, hypoechoic mass. Margin is CIRCUMSCRIBED, and orientation is parallel. Although this combination of features typically suggests a benign etiology, the mass was new by imaging. Therefore, biopsy was performed. Circumscribed margin often indicates a benign mass, but other factors including shape and stability versus change over time must be considered as well. Pathology: Grade 1 invasive ductal carcinoma.

B. MASSES

3. MARGIN

b. Non-circumscribed

Malignant masses most commonly have a margin that is non-circumscribed and often have more than one type of non-circumscribed margin. A mass is characterized by its most suspicious margin.

Benign masses may occasionally have margins that are non-circumscribed, but the diagnosis should be confirmed either by an otherwise characteristically benign appearance on imaging (e.g., fat in fat necrosis confirmed on mammography) or by biopsy.

i. Indistinct

All or some portion of the margin is poorly defined or fuzzy with no sharp demarcation from the surrounding tissue. The significant feature is that the mass is non-circumscribed.

The margin of any mass with an echogenic rind is considered NON-CIRCUMSCRIBED and is often INDISTINCT.

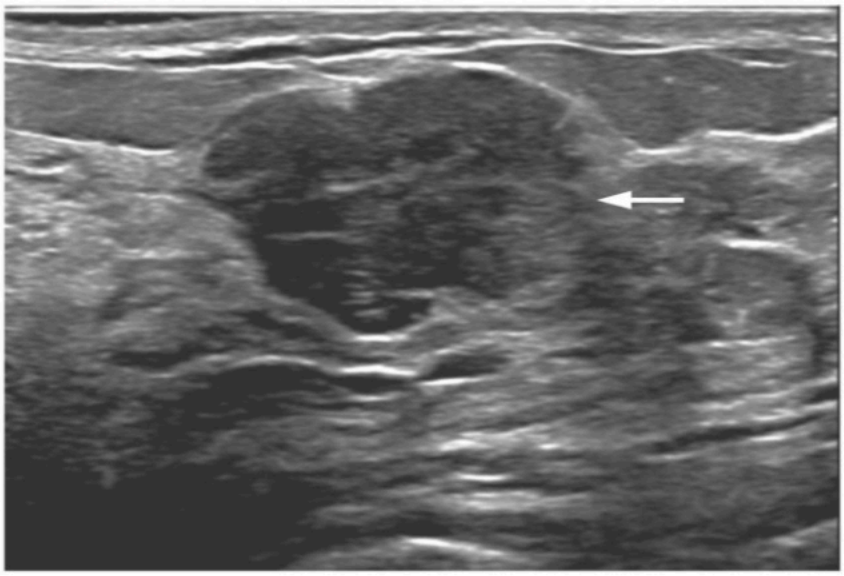

Figure 1 – MARGIN: INDISTINCT. Lobulated, heterogeneous mass with parallel orientation and an INDISTINCT margin (arrow). Due to the suspicious margin, biopsy was performed. Pathology: Fibroadenoma.



A

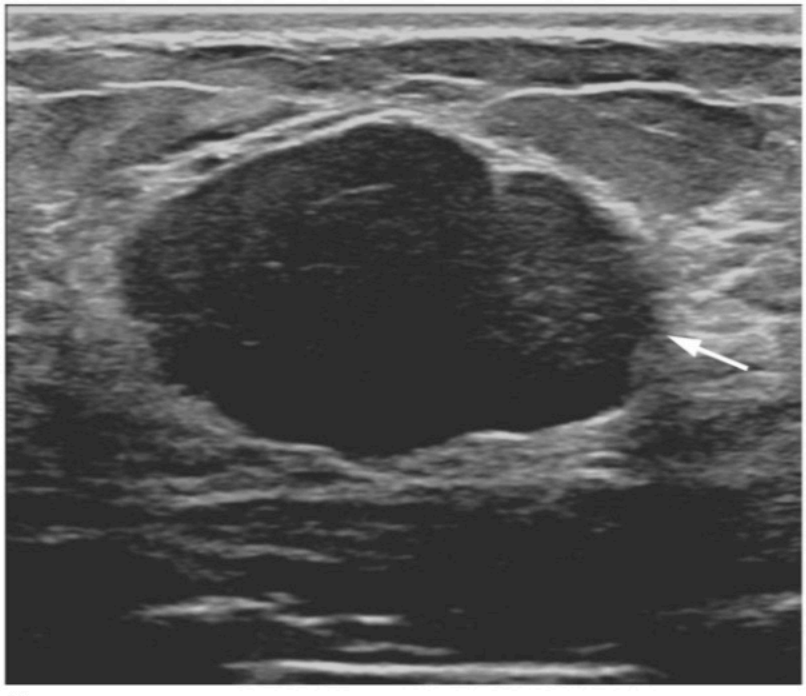

B

Figure 2 – MARGIN: INDISTINCT. Radial (A) and antiradial (B) images of a hypoechoic mass with parallel orientation and INDISTINCT margin (arrows). Pathology: Tubular adenoma.



A

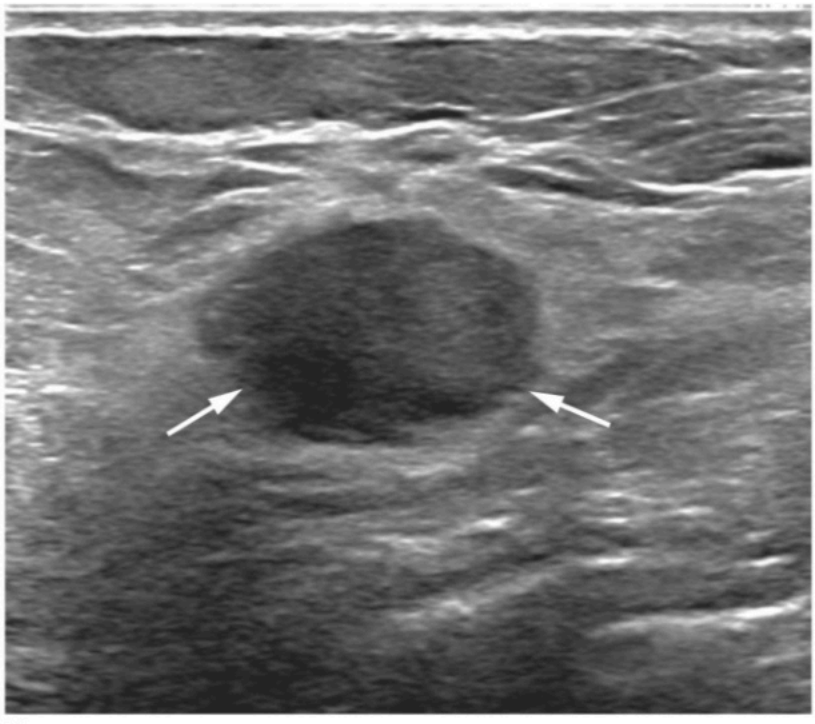

B

Figure 3 – MARGIN: INDISTINCT. Radial (A) and antiradial (B) images of an oval mass with INDISTINCT margin (arrows). Although the mass may appear at first glance to have benign features, the INDISTINCT margin is suspicious and prompted biopsy. Pathology: Invasive ductal carcinoma.

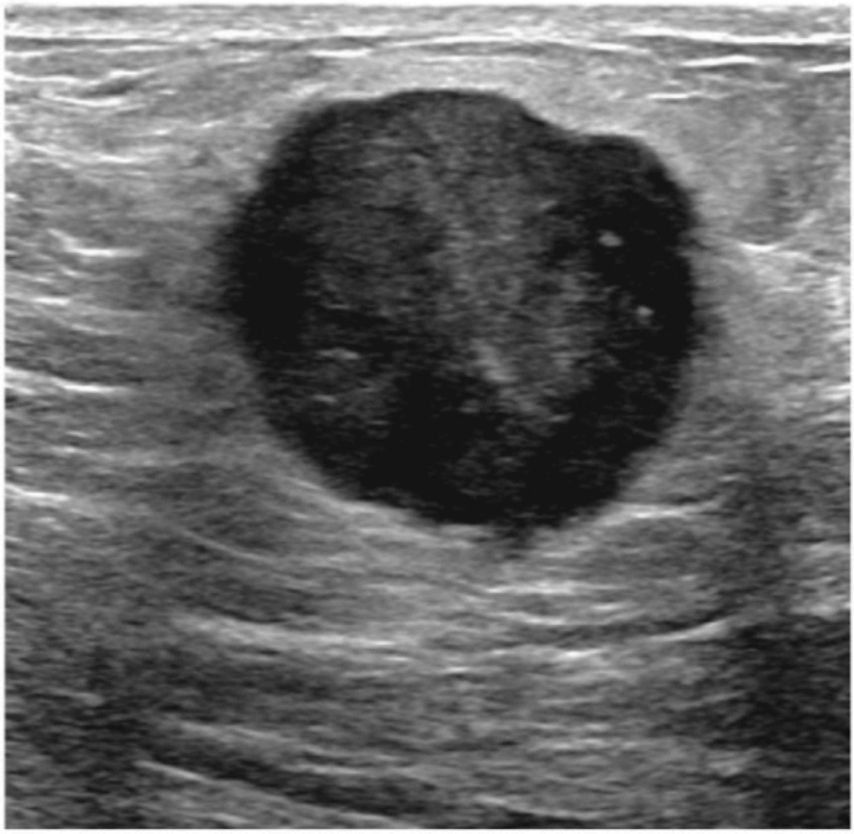

Figure 4 – MARGIN: INDISTINCT. Round, heterogeneous mass with INDISTINCT margin and posterior enhancement. Pathology: Invasive ductal carcinoma.

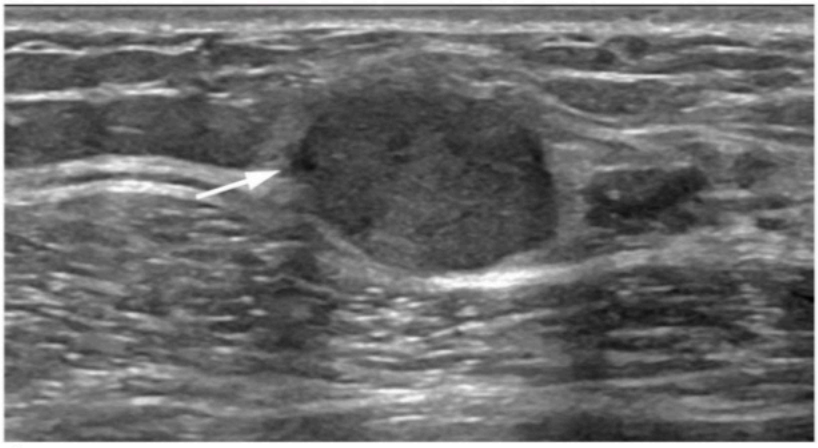

A

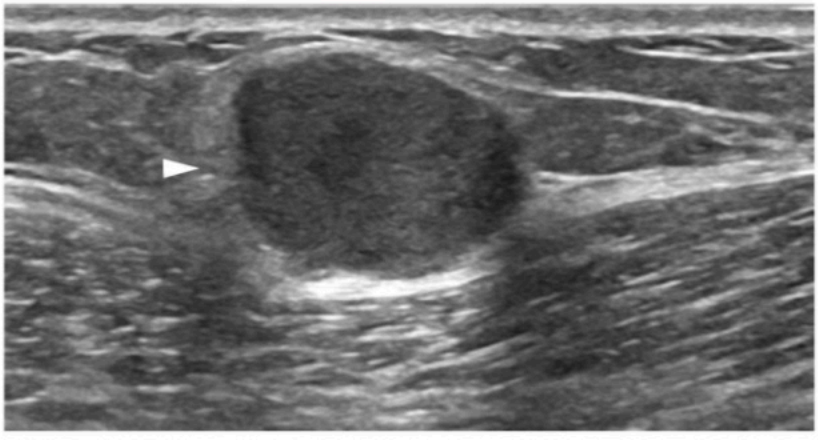

B

Figure 5 – MARGIN: INDISTINCT. Radial (A) and antiradial (B) images of a hypoechoic, oval mass with parallel orientation and posterior enhancement. Although portions of the margin appear circumscribed, some of the margin is INDISTINCT (arrow), so the mass is defined as INDISTINCT. The presence of an echogenic rind (arrowhead) also defines the mass as non-circumscribed. Posterior enhancement in a solid mass is not a reassuring sign. Pathology: Invasive mucinous carcinoma.

B. MASSES

3. MARGIN

b. Non-circumscribed

ii. Microlobulated

The margin is characterized by short-cycle 2–3 mm undulations or ripples. Microlobulated describes the margin while lobulated describes the shape of a mass. Microlobulations are typically more numerous but are less deep than the lobulations that define a lobulated shape. This term was purposefully retained in the ultrasound section (but discontinued in the Mammography section) because the feature is easily discernable with current ultrasound equipment and technique as a mass undergoes real-time interrogation of its surface features and provides an added descriptor that can assist in differentiating benign from suspicious masses. The significant feature is that the mass is non-circumscribed.

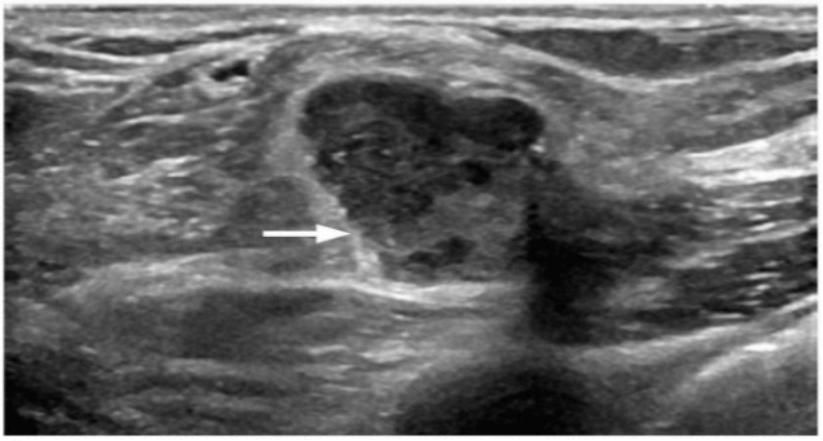

A

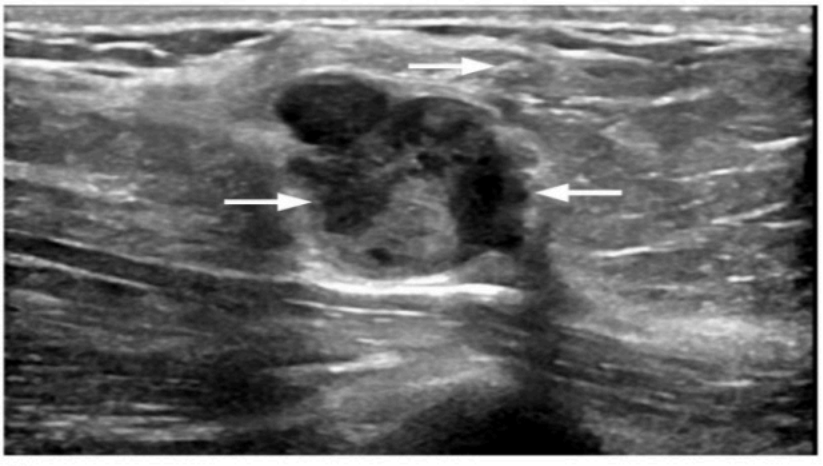

B

Figure 1 – MARGIN: MICROLOBULATED. Radial (A) and antiradial (B) images of a lobulated heterogeneous mass with posterior enhancement and MICROLOBULATED margin (arrows). Pathology: Invasive ductal carcinoma.

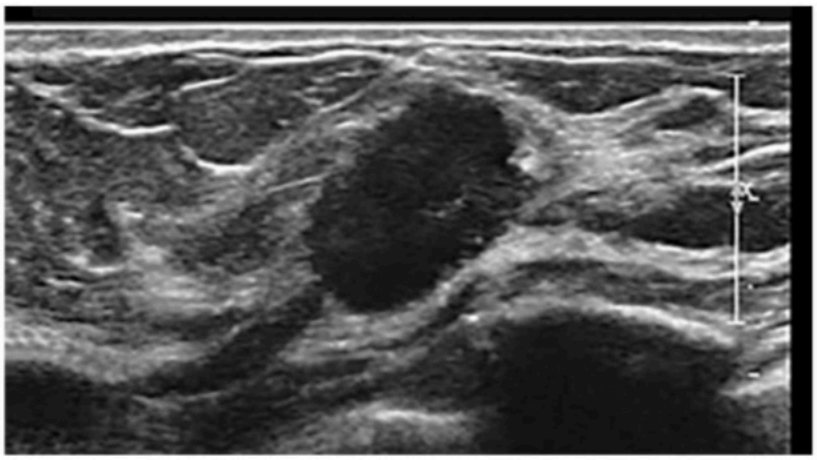

A

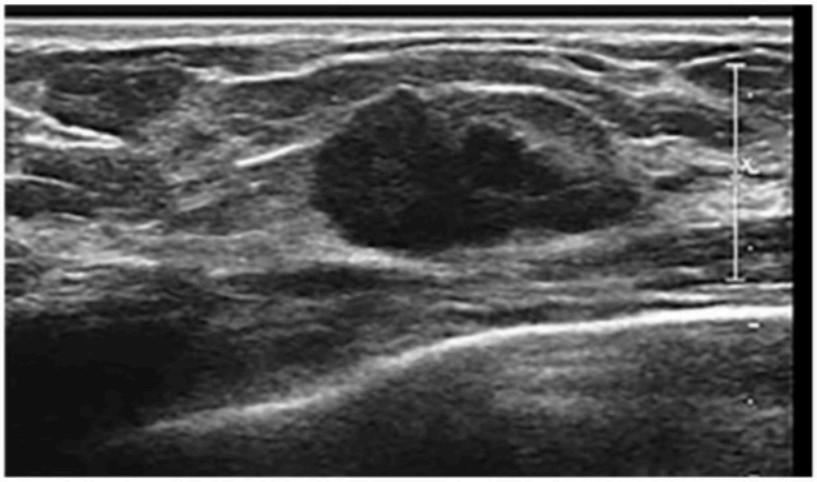

B

Figure 2 – MARGIN: MICROLOBULATED. Oval, hypoechoic, non-parallel mass with MICROLOBULATED margin. Pathology: Invasive ductal carcinoma.

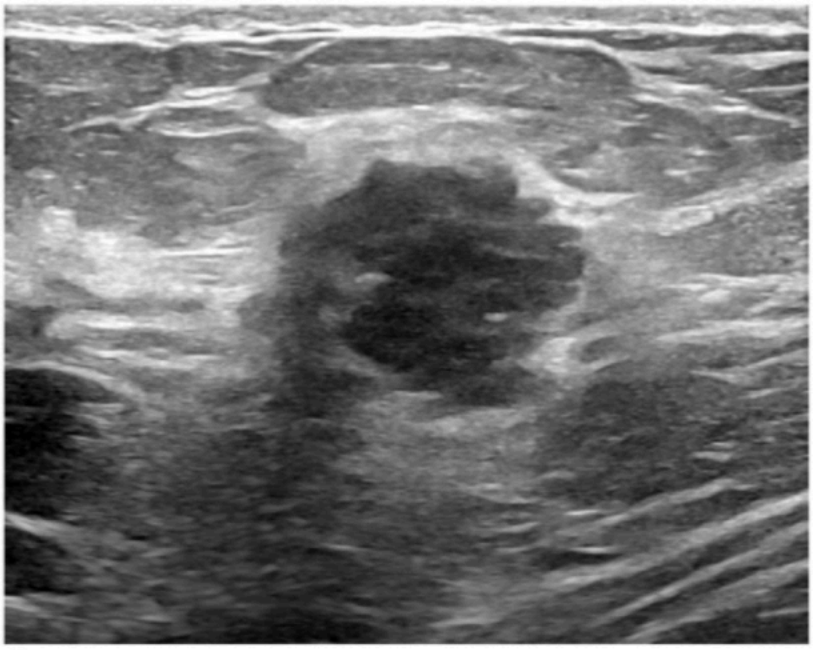

A



B

Figure 3 – MARGIN: MICROLOBULATED. Radial (A) and antiradial (B) images of an irregular heterogeneous non-parallel mass with posterior enhancement and MICROLOBULATED margin (margin best demonstrated in the radial view). Pathology: Invasive ductal carcinoma.

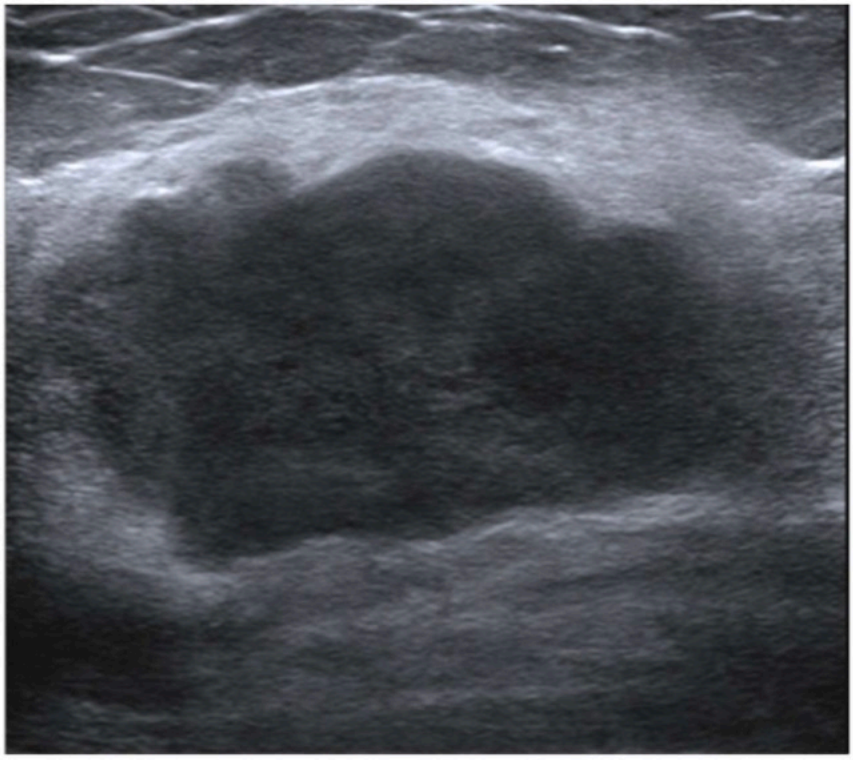

Figure 4 – MARGIN: MICROLOBULATED. Lobulated, hypoechoic mass with MICROLOBULATED margin. Pathology: Invasive ductal carcinoma.

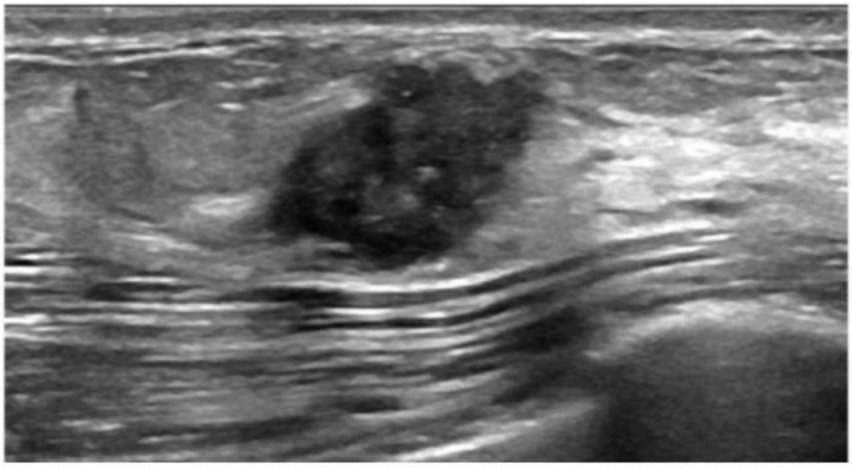

Figure 5 – MARGIN: MICROLOBULATED. Irregular heterogeneous mass with MICROLOBULATED margin. Pathology: Invasive ductal carcinoma.

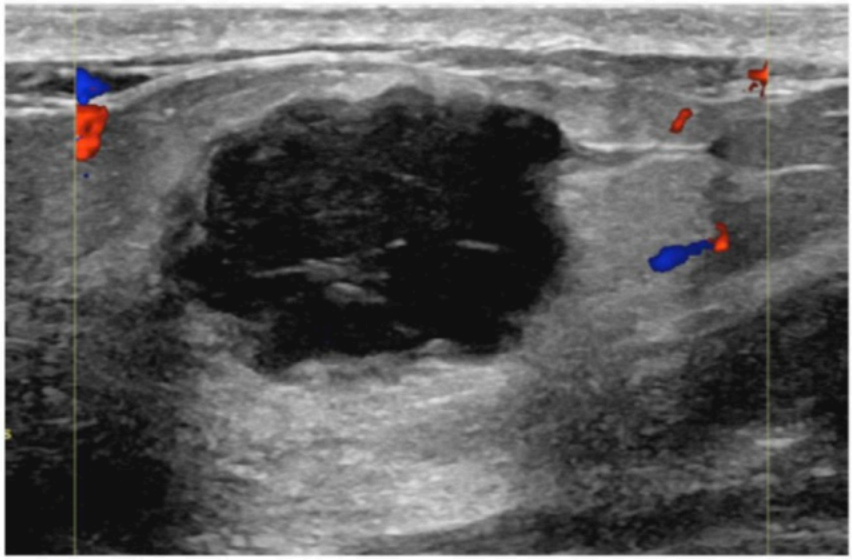

Figure 6 – MARGIN: MICROLOBULATED. Oval, parallel, mixed solid and cystic mass with MICROLOBULATED margin and posterior enhancement. Pathology: Invasive ductal carcinoma.

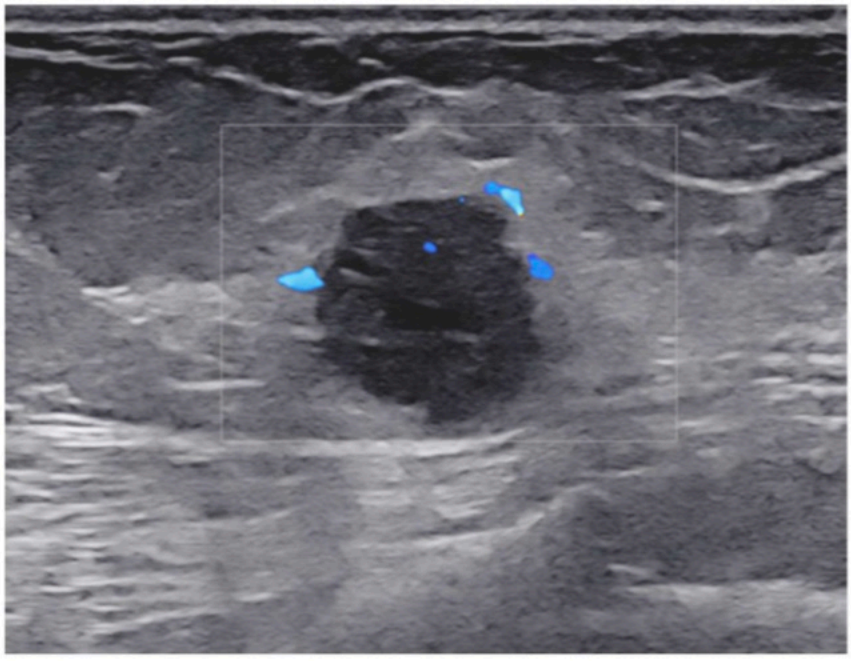

Figure 7 – MARGIN: MICROLOBULATED. Round, non-parallel, hypoechoic mass with MICROLOBULATED margin and posterior enhancement. Pathology: Invasive ductal carcinoma.

B. MASSES

3. MARGIN

b. Non-circumscribed

iii. Angular

Some or all aspects of the margin have sharp corners, often forming acute angles. The significant feature is that the mass is non-circumscribed.

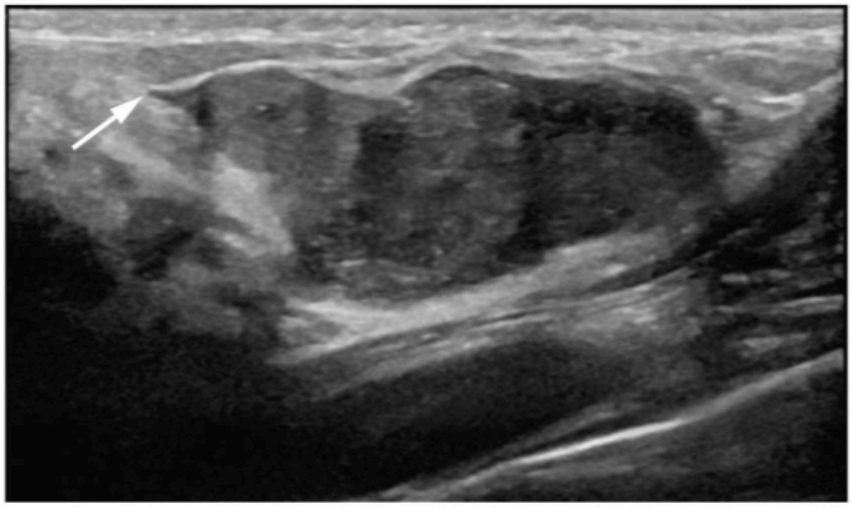

Figure 1 – MARGIN: ANGULAR. Ultrasound image of a lobulated mass in an 18-year-old woman. Despite some portions of the mass showing circumscribed margin, the single ANGULAR margin (arrow) is suspicious. The mass was assigned a BI-RADS final assessment category 4A, low suspicion for malignancy. Pathology: Fibroadenoma.

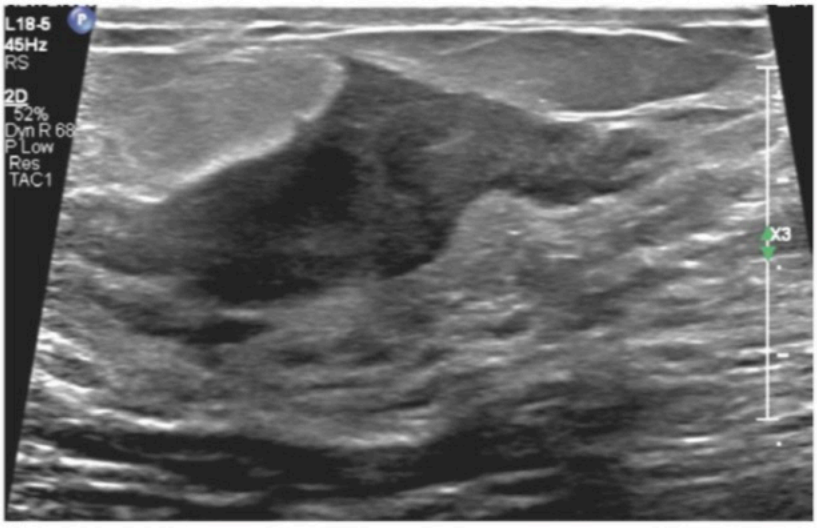

A

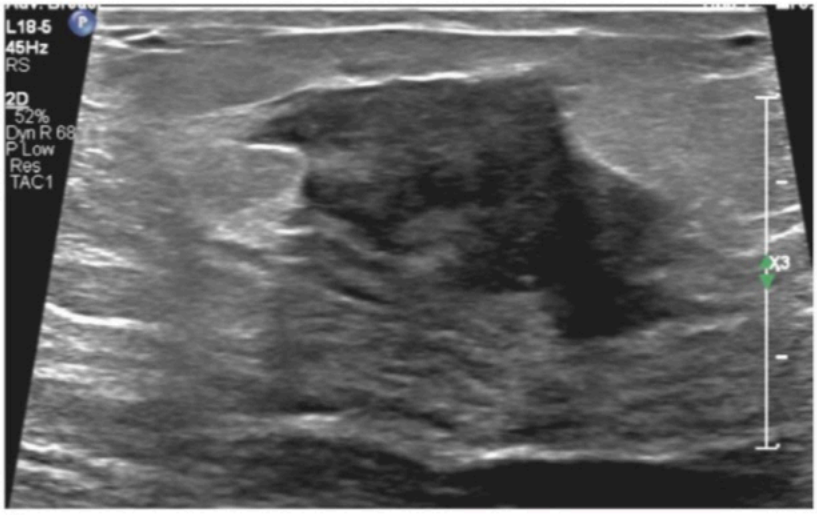

B

Figure 2 – MARGIN: ANGULAR. 78-year-old woman with uncontrolled type II diabetes presented with a painful palpable lump in her breast. Radial (A) and antiradial (B) images demonstrate an irregular, hypoechoic, parallel mass with ANGULAR margin. Pathology: Diabetic mastopathy.

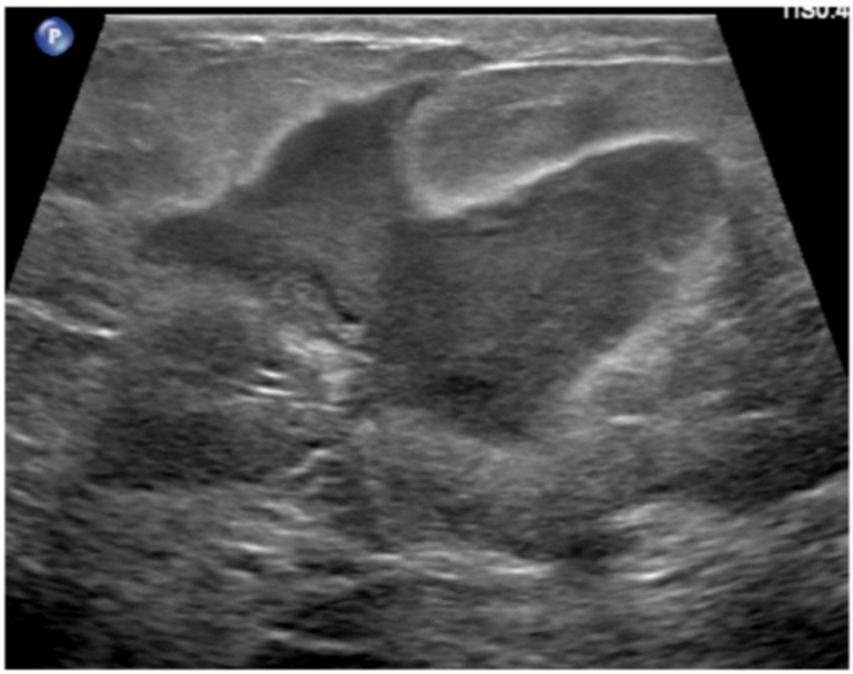

Figure 3 – MARGIN: ANGULAR. 25-year-old woman presented to the Emergency Department with right breast swelling and pain increasing over two months. Imaging demonstrates an irregular, hypoechoic, parallel mass with an echogenic rind and no posterior features. The margin is ANGULAR. Pathology: Breast abscess.

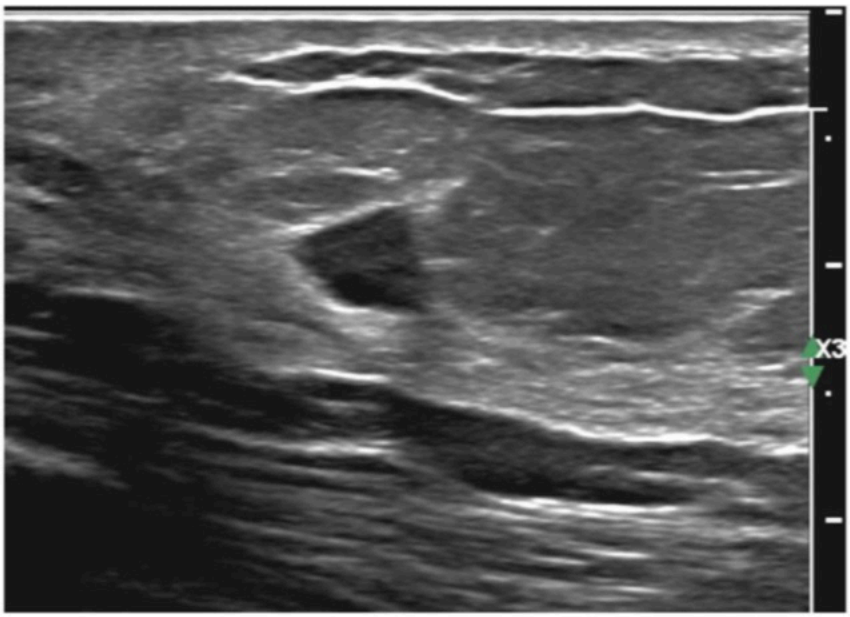

Figure 4 – MARGIN: ANGULAR. Hypoechoic irregular mass with ANGULAR margin and posterior enhancement. Pathology: Intraductal papilloma.

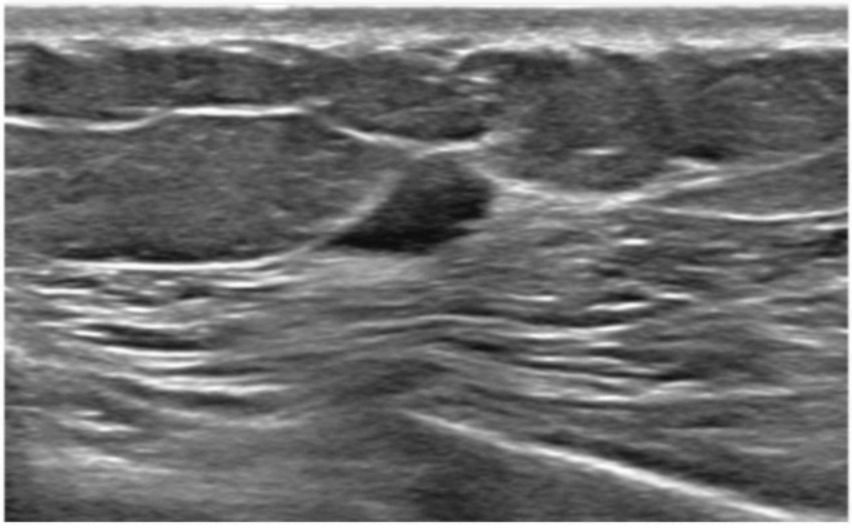

Figure 5 – MARGIN: ANGULAR. Hypoechoic, parallel mass with ANGULAR margin and no posterior features. Pathology: Invasive ductal carcinoma with micropapillary features.

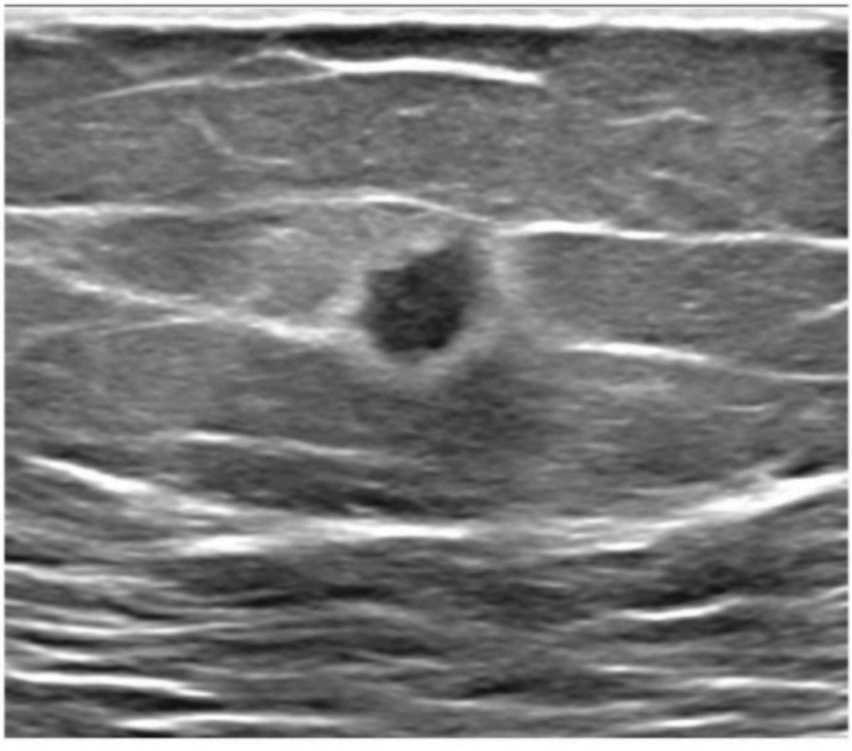

Figure 6 – MARGIN: ANGULAR. Oval, hypoechoic, non-parallel mass with ANGULAR margin and echogenic rind. Pathology: Invasive ductal carcinoma.



Figure 7 – MARGIN: ANGULAR. Hypoechoic lobulated mass with parallel orientation and ANGULAR margin. Pathology: Mucinous carcinoma.

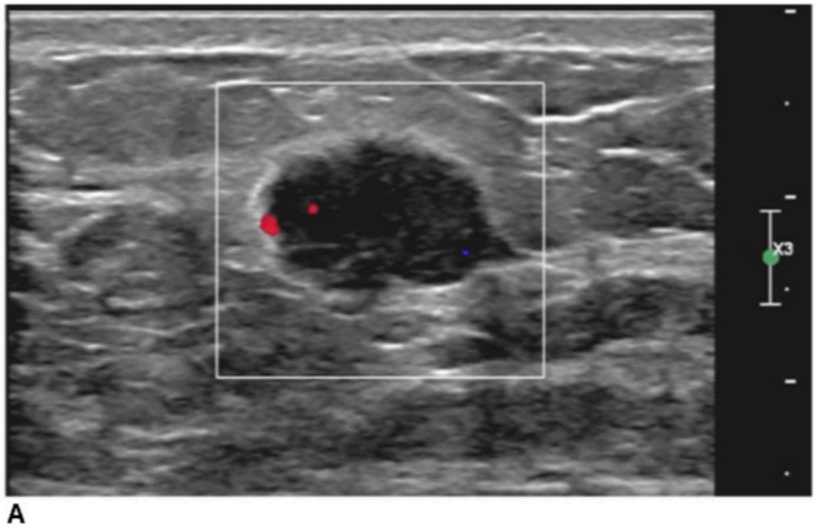

A

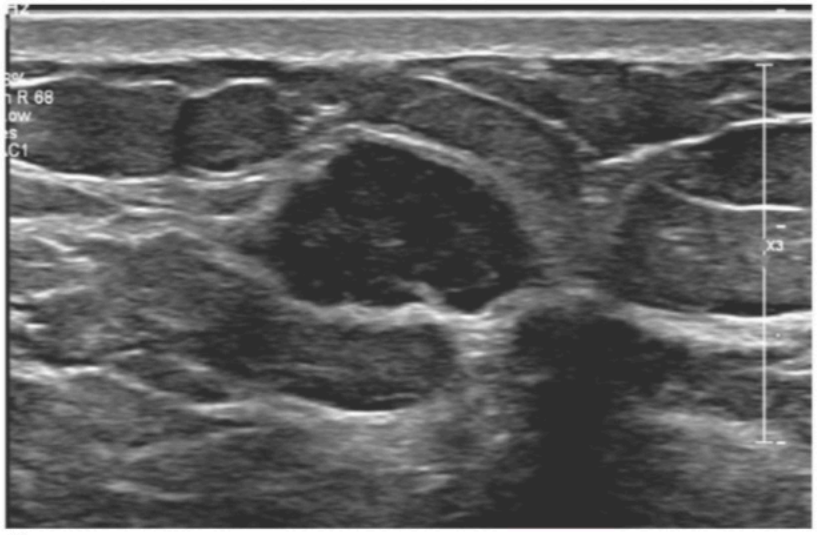

B

Figure 8 – MARGIN: ANGULAR. Radial (A) and antiradial (B) images of an oval, parallel, hypoechoic mass. In addition to the indistinct margin and echogenic rind best seen in the anterior margin of the radial view (A), each view also demonstrates an ANGULAR margin. Pathology: Invasive ductal carcinoma.

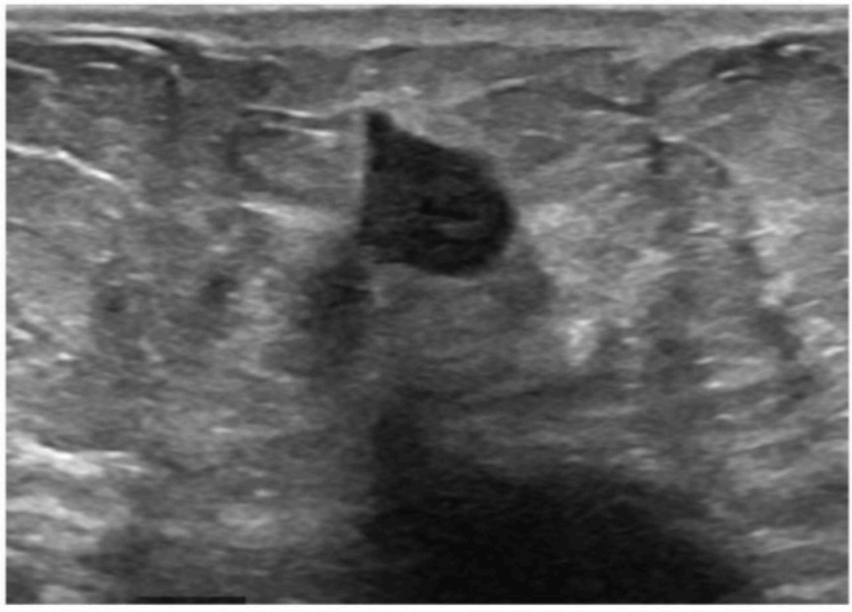

Figure 9 – MARGIN: ANGULAR. Oval, hypoechoic, non-parallel mass with ANGULAR margin and posterior shadowing. Pathology: Invasive ductal carcinoma.

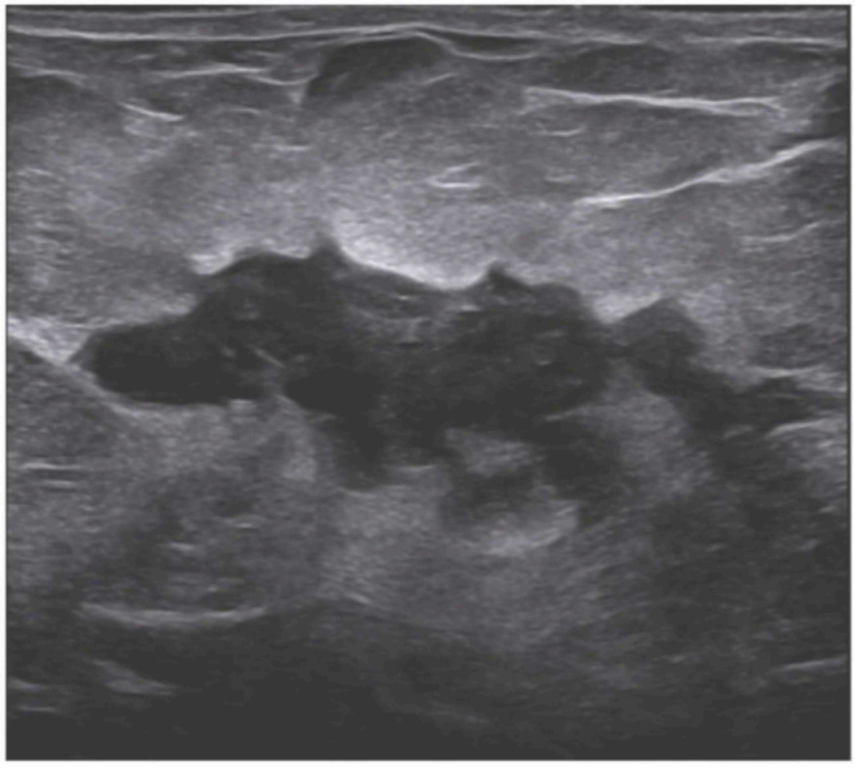

Figure 10 – MARGIN: ANGULAR. Irregular, hypoechoic, parallel mass with an ANGULAR margin and echogenic rind. Pathology: Invasive ductal carcinoma.

B. MASSES

3. MARGIN

b. Non-circumscribed

iv. Spiculated

The margin is characterized by sharp lines radiating from the mass, often a sign of malignancy.

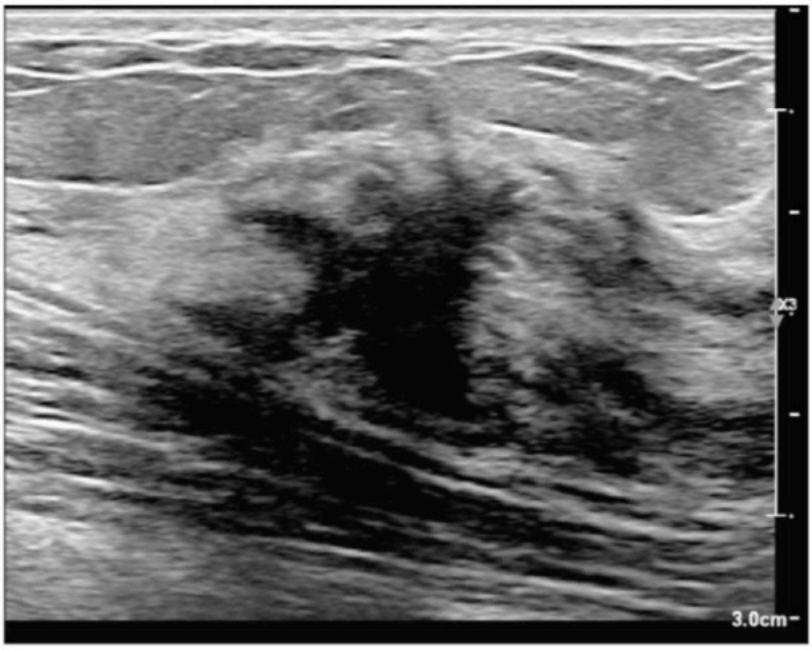

A

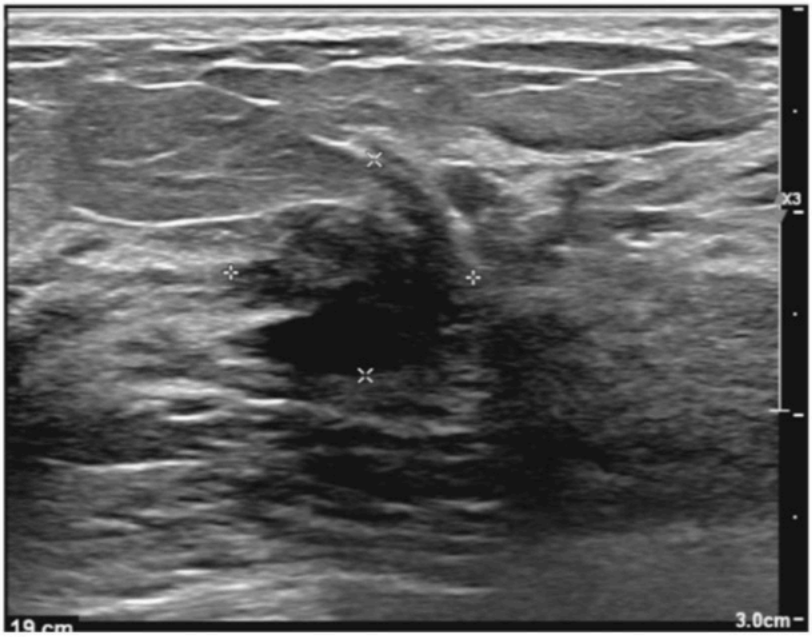

B

Figure 1 – MARGIN: SPICULATED. Radial (A) and antiradial (B) images of an irregular hypoechoic mass with SPICULATED margin in a 22-year-old woman who presented with a palpable lump. Despite the patient's young age, these imaging features are suspicious for malignancy. Pathology on needle biopsy and subsequent excision: Breast tissue with marked stromal fibrosis, suspicious for fibromatosis.

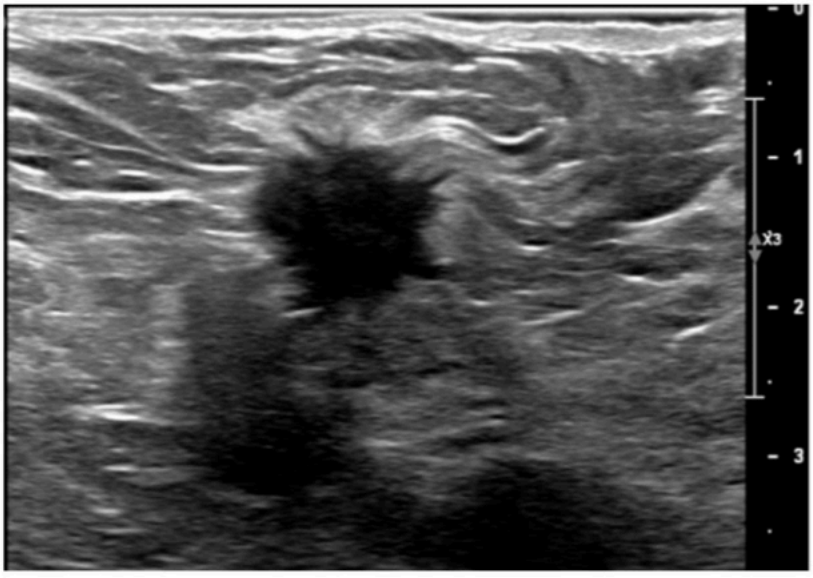

A

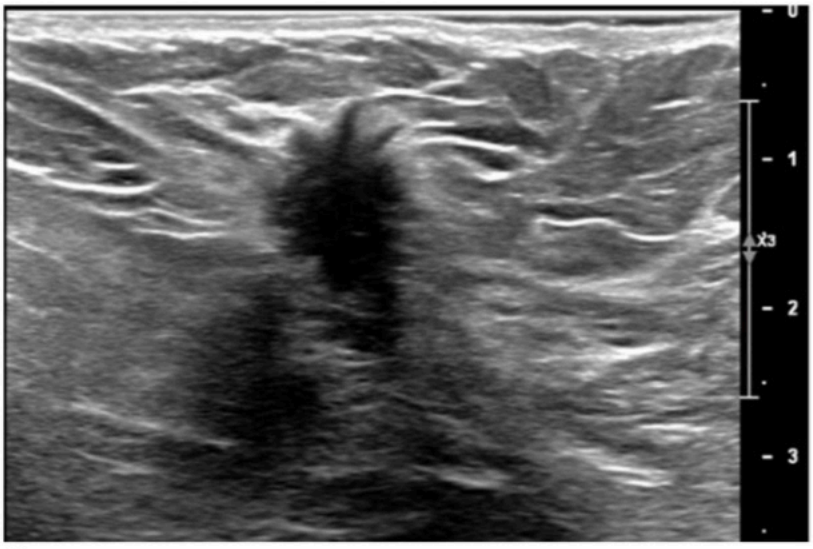

B

Figure 2 – MARGIN: SPICULATED. Radial (A) and antiradial (B) images of an irregular, hypoechoic, shadowing mass with non-parallel orientation, echogenic rind and SPICULATED margin. Pathology: Invasive ductal carcinoma.

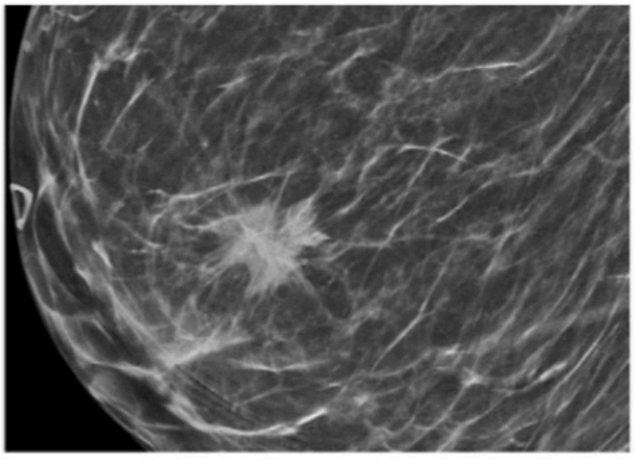

A

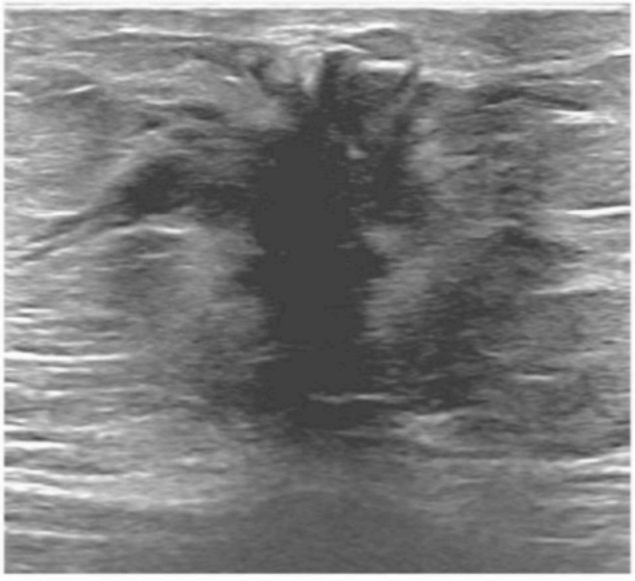

B

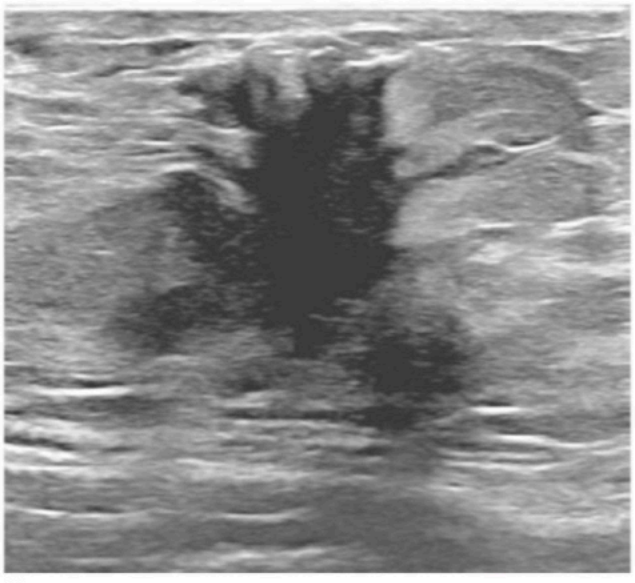

C

Figure 3 – MARGIN: SPICULATED. Synthetic mammogram (A) of a patient who presented with a palpable lump demonstrates an irregular mass with a spiculated margin. Radial (B) and antiradial (C) ultrasound images show corresponding hypoechoic mass with irregular shape, non-parallel orientation, SPICULATED margin, and echogenic rind. Pathology: Invasive ductal carcinoma.



A



B

Figure 4 – MARGIN: SPICULATED. Radial (A) and antiradial (B) images of a lobulated mass with heterogeneous echo pattern, non-parallel orientation and associated echogenic rind. Although some aspects of the margin are indistinct (arrowheads), much of the margin in the radial view (A) is SPICULATED (arrows), the descriptor with the highest likelihood of malignancy. Pathology: Invasive ductal carcinoma.



A

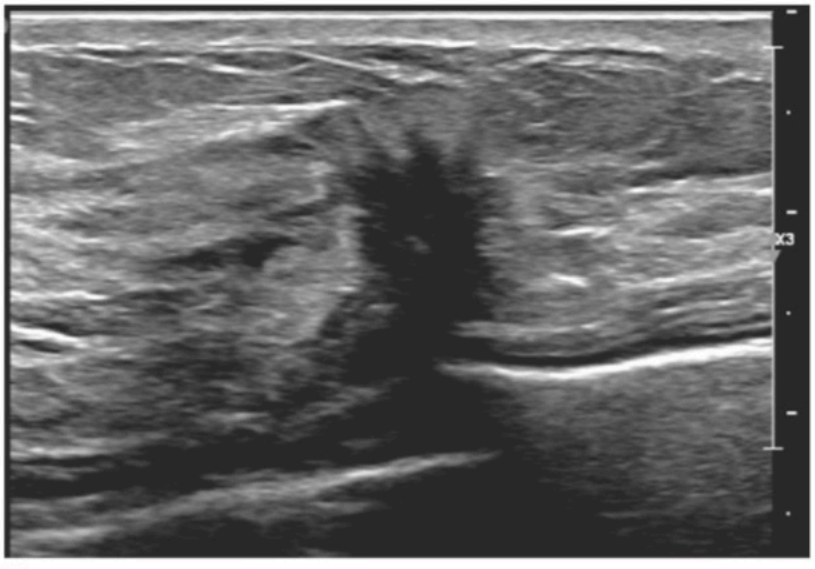

B

Figure 5 – MARGIN: SPICULATED. Radial (A) and antiradial (B) images of an irregular mass with a SPICULATED margin, an echogenic rind, and posterior shadowing. The mass is non-parallel based on the antiradial view (B). This mass was assigned a BI-RADS assessment category 5, highly suggestive of malignancy. Pathology: Invasive lobular carcinoma.

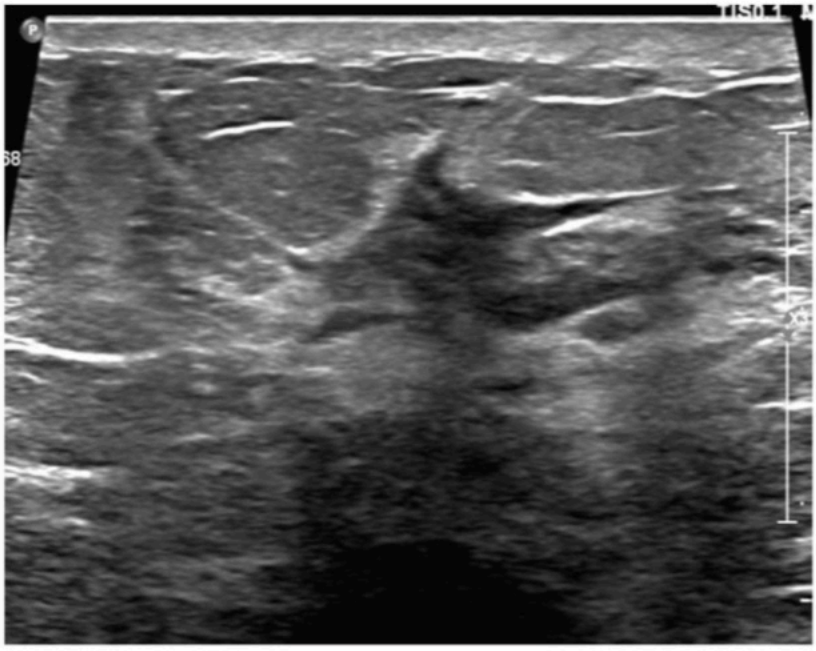

A



B

Figure 6 – MARGIN: SPICULATED. Radial (A) and antiradial (B) images of an irregular mass with parallel orientation, SPICULATED margin and echogenic rind. Pathology: Invasive ductal carcinoma.

B. MASSES

4. ECHO PATTERN

The echo pattern of a mass refers to the echogenicity of the mass relative to the echogenicity of adjacent or nearby fat lobules.

a. Anechoic

Without internal echoes. The mass appears entirely black. Simple cysts are anechoic and benign. However, on rare occasions, some solid masses may also appear anechoic, notably necrotic and/or triple negative breast cancers. Unlike simple cysts, the margin of anechoic malignancies is almost never circumscribed. Anechogenicity should not be confused with the marked hypoechogenicity that may be seen in some solid masses.

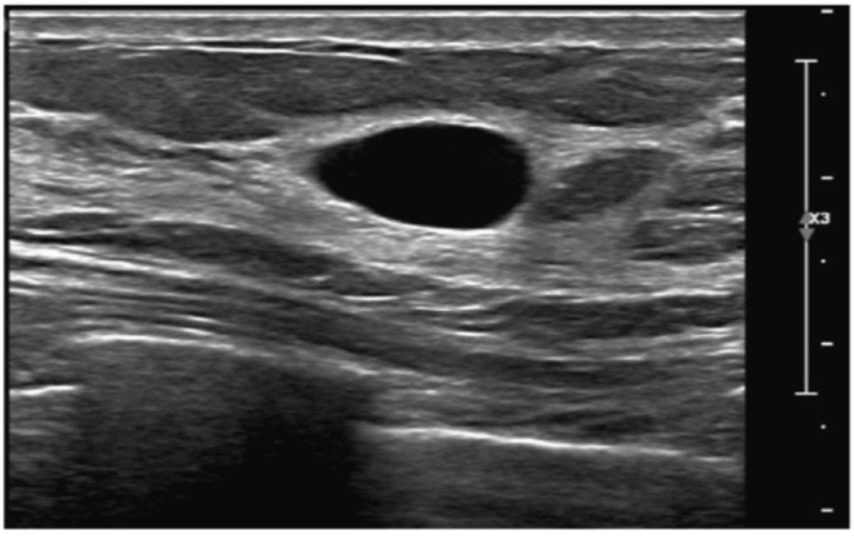

A

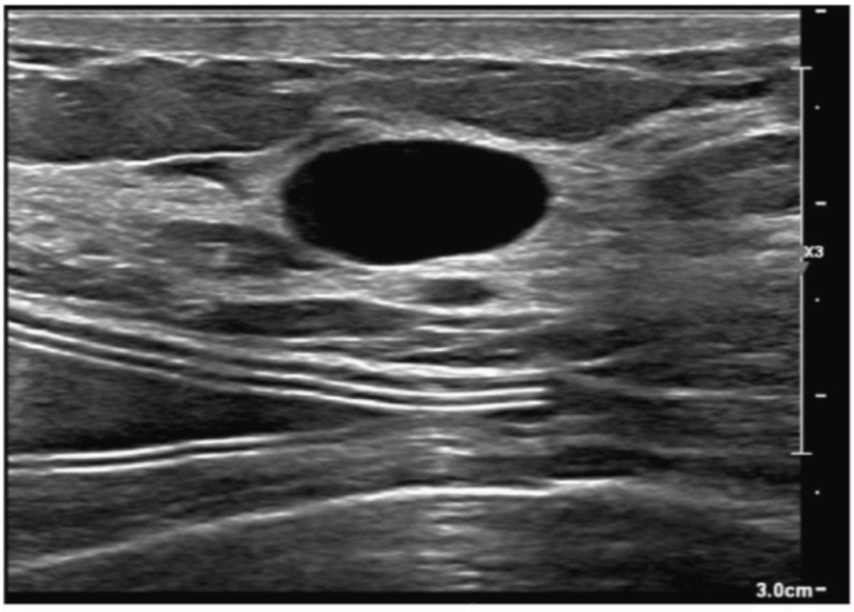

B

Figure 1 – ECHO PATTERN: ANECHOIC. Radial (A) and antiradial (B) images of an oval, circumscribed, ANECHOIC mass, with posterior enhancement. This combination of features is diagnostic of a benign simple cyst.

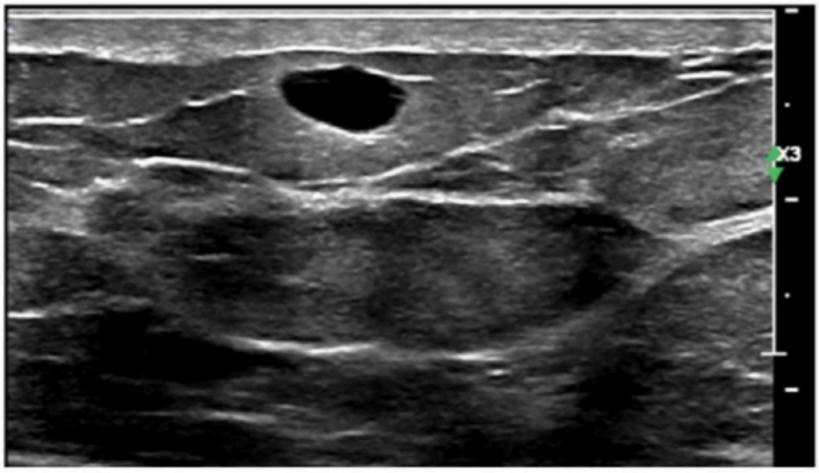

Figure 2 – ECHO PATTERN: ANECHOIC. Oval, circumscribed, ANECHOIC mass, with posterior enhancement. Etiology: Simple cyst.

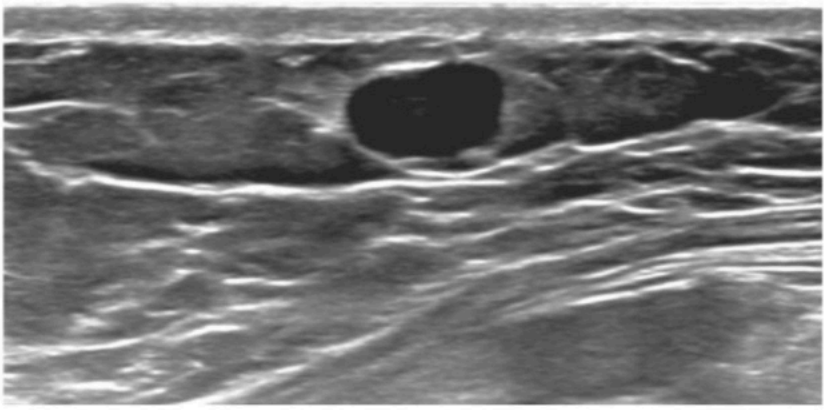

A

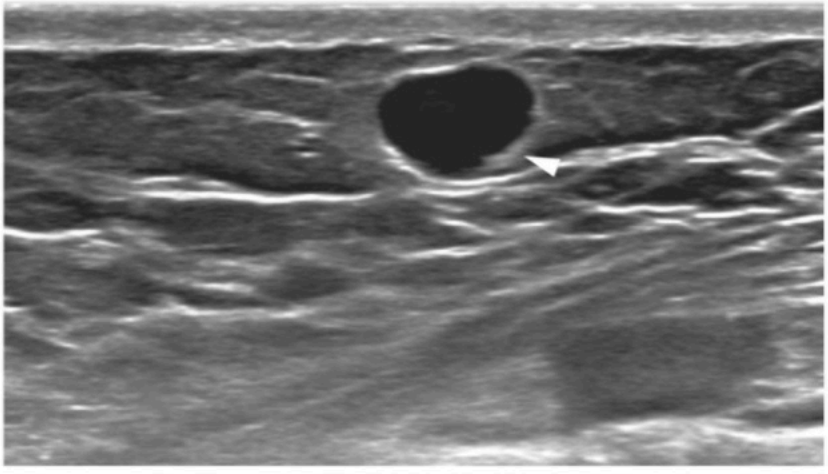

B

Figure 3 – ECHO PATTERN: ANECHOIC. Patient presented with a painful palpable lump. Radial (A) and antiradial (B) images of an oval, circumscribed, ANECHOIC mass, with no posterior features. The mass was believed to represent a simple cyst, though an echogenic rind (arrowhead) is not typically seen with a benign cyst. Aspiration performed to address the patient's pain did not yield fluid. Needle biopsy ultimately confirmed the diagnosis: Reactive intramammary lymph node.

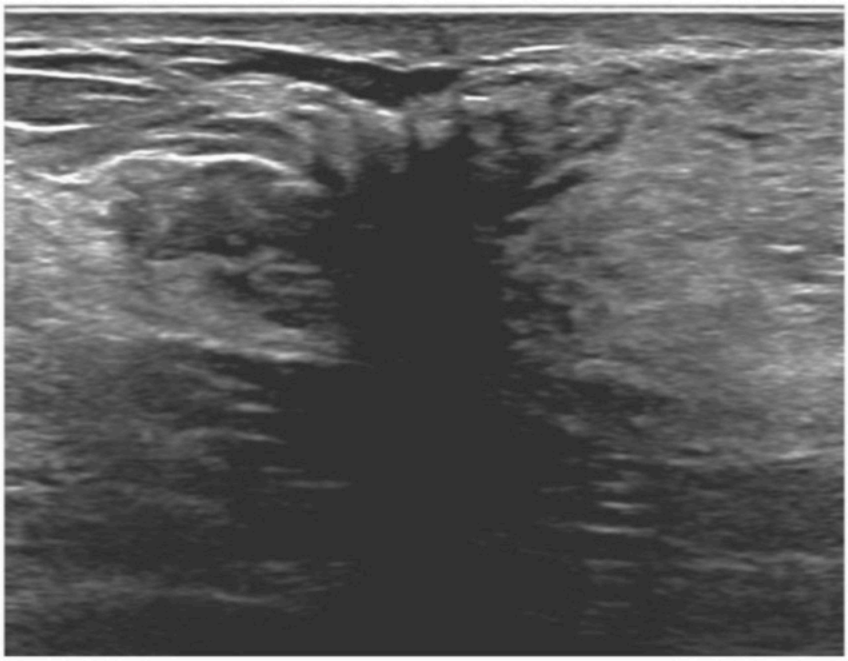

A

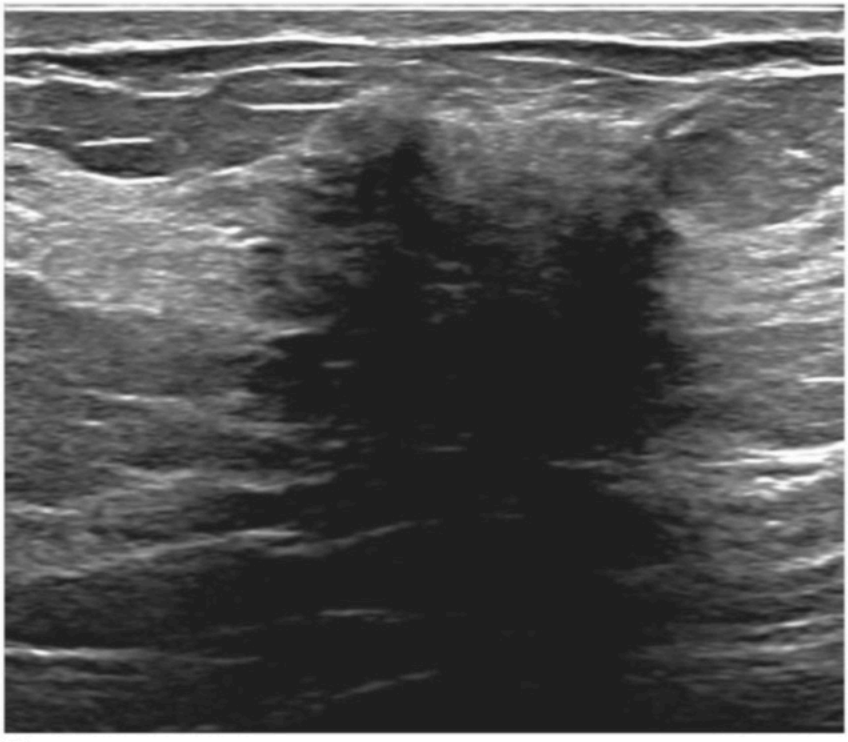

B

Figure 4 – ECHO PATTERN: HYPOECHOIC (not anechoic). 74-year-old diabetic patient presented with a new palpable lump. Radial (A) and antiradial (B) images of an irregular, spiculated, markedly HYPOECHOIC mass with posterior shadowing. There is an absence of echoes in the mass centrally. However, echoes do emanate from the periphery of the mass, indicating that the mass does not fit into the anechoic category. Pathology: Diabetic mastopathy.

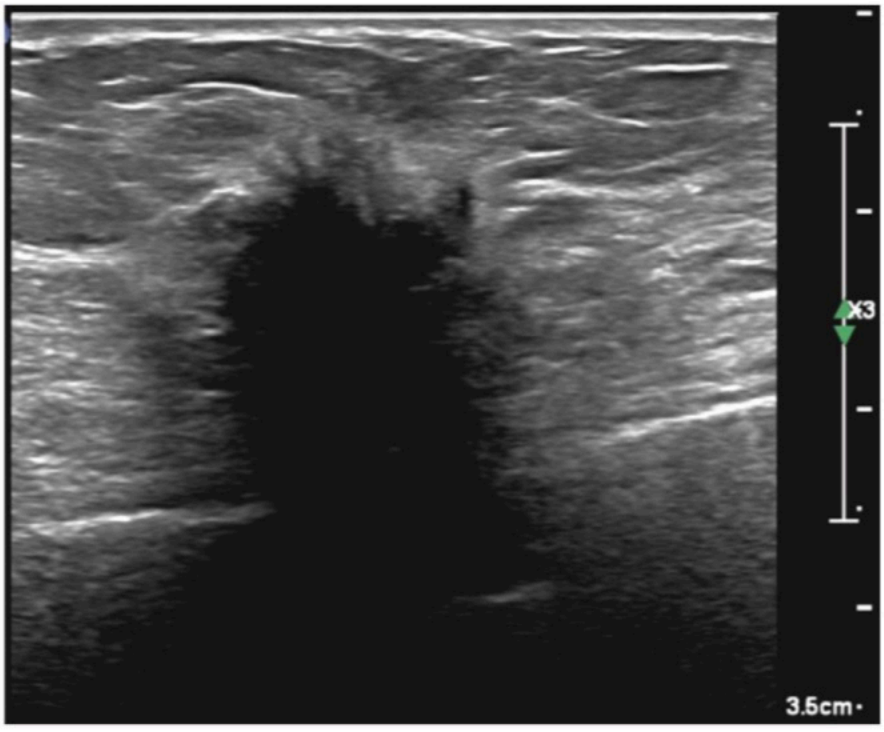

Figure 5 – While this mass appears largely anechoic, it should not be considered to display benign features. The anechogenicity likely stems from profound shadowing emanating from the anterior part of the mass (and extending behind the mass, rendering the posterior mass margin invisible). This irregular, spiculated, non-parallel mass was assigned an assessment category BI-RADS 5, highly suggestive of malignancy. Pathology: Invasive lobular carcinoma.

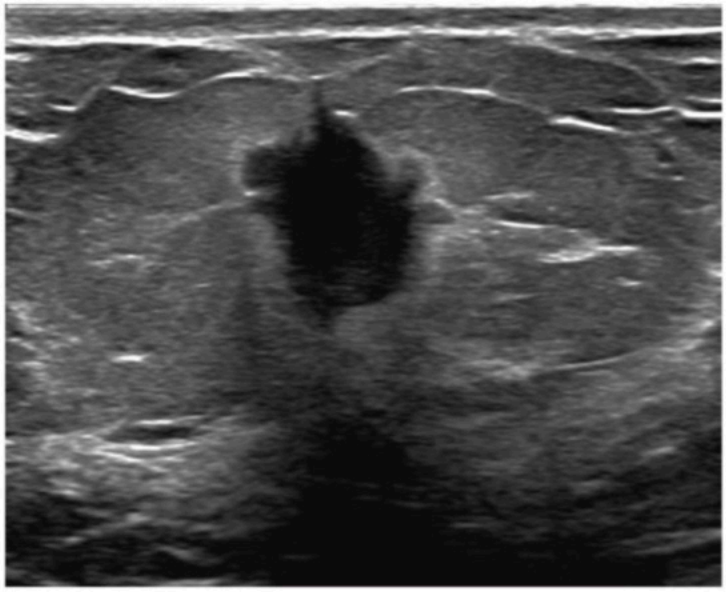

A

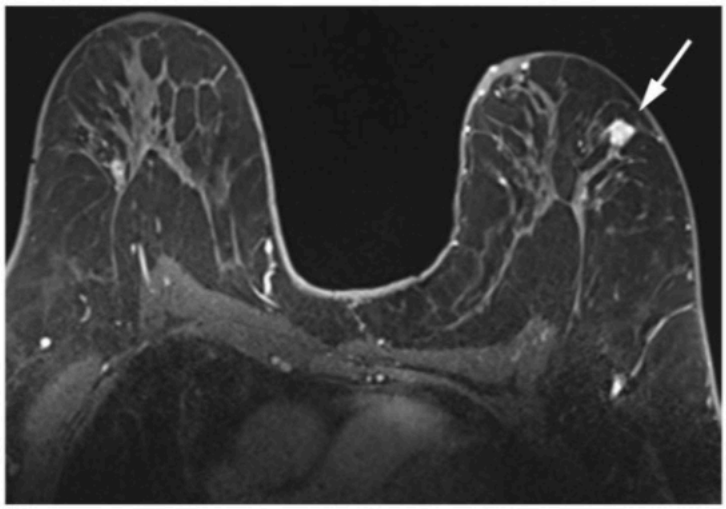

B

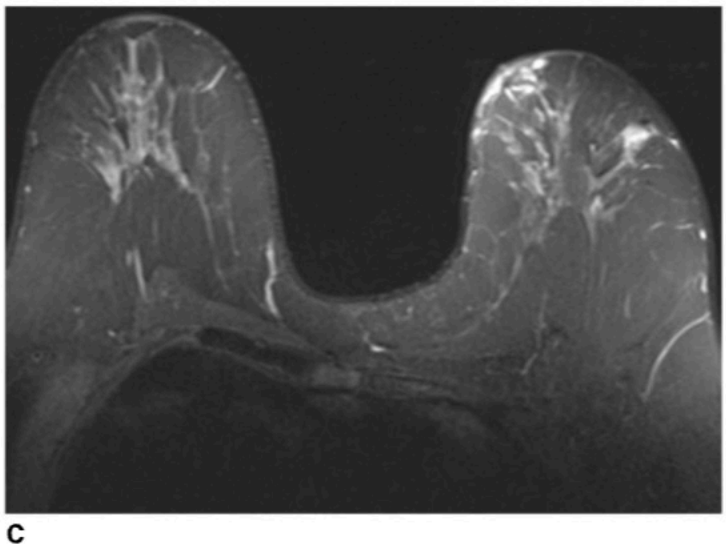

C

Figure 6 – ECHO PATTERN: ANECHOIC. US image (A) of an ANECHOIC, irregular, non-parallel mass with an angular margin and echogenic rind. Although the anechoic echo pattern may suggest this mass is necrotic, MRI images confirm it is solid. Post-contrast T1-weighted image (B) demonstrates enhancement of the mass in the lateral left breast (arrow), and corresponding T2-weighted image (C) of the mass shows isointense signal, rather than the hyperintense signal that would be expected of a necrotic, fluid-filled mass. Pathology: Invasive ductal carcinoma.

B. MASSES

4. ECHO PATTERN

b. Hyperechoic

Hyperechoic masses have increased echogenicity relative to fat, often equal to fibroglandular tissue. Although many hyperechoic masses such as fat necrosis, hemangiomas, and some lipomas are benign, hyperechoic echo pattern alone is not sufficient to assign a benign assessment. To be assessed as BI-RADS 2, benign based on its hyperechoic echo pattern, a mass must also be located in the subcutaneous fat, must be uniformly hyperechoic with no hypoechoic or anechoic portion, and must be oval in shape with circumscribed margin, parallel orientation, and no posterior shadowing. A hyperechoic mass that is clearly associated with a fat-containing mass at mammography can also be presumed benign; however, a hyperechoic mass on ultrasound associated with a soft tissue density mass on mammogram is suspicious [23–26].

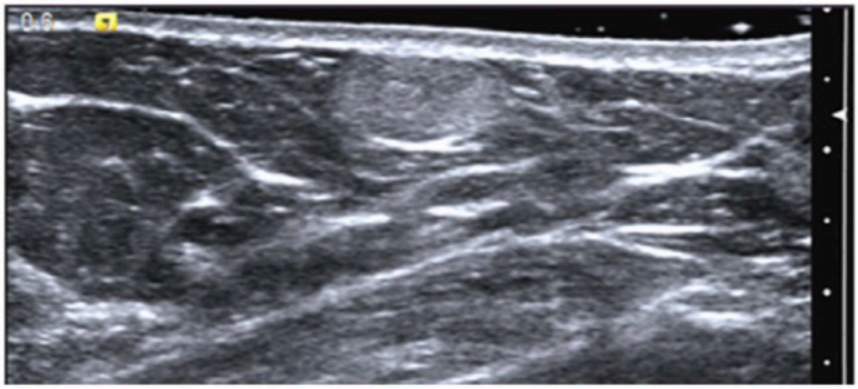

A

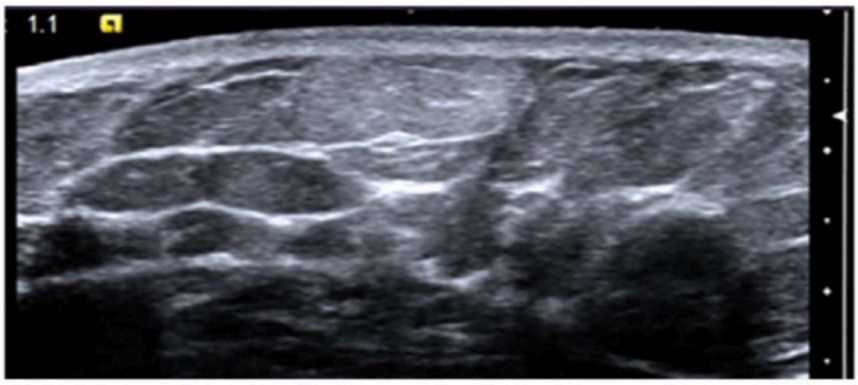

B

Figure 1 – ECHO PATTERN: HYPERECHOIC. Radial (A) and antiradial (B) images of an oval, parallel, homogeneously HYPERECHOIC mass with circumscribed margin and no posterior features. The mass was soft and compressible to palpation. This combination of features is diagnostic of evolving fat necrosis or a benign lipoma.

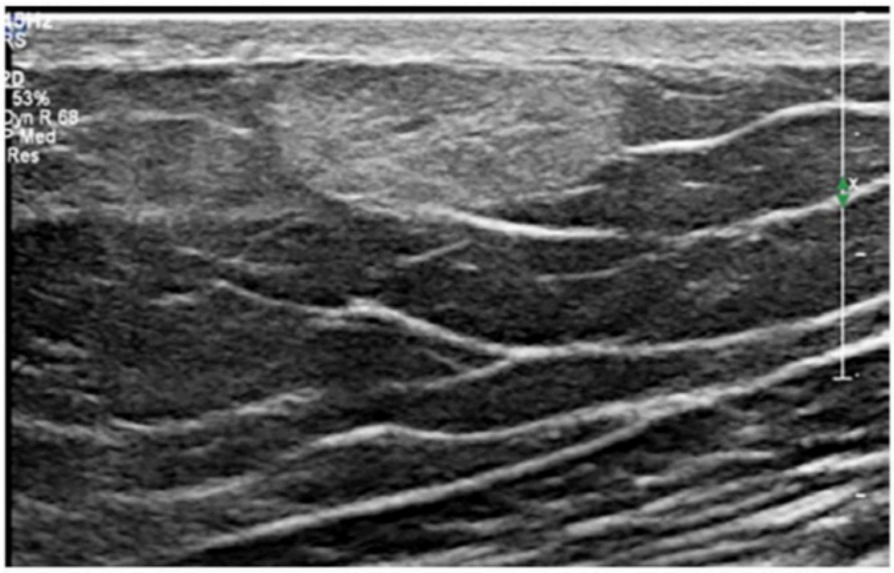

Figure 2 – ECHO PATTERN: HYPERECHOIC. Oval HYPERECHOIC mass in a male patient. The mass has a circumscribed margin and no posterior acoustic features and was soft and pliable to palpation. Three other similar appearing masses were also identified in the same region which is common for fat necrosis and would be highly unusual for a malignant hyperechoic mass. Final assessment, BI-RADS 2, benign.

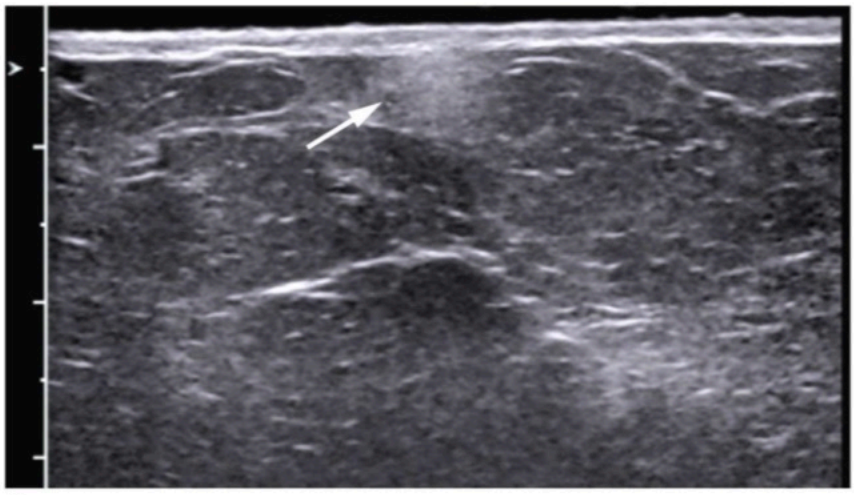

A

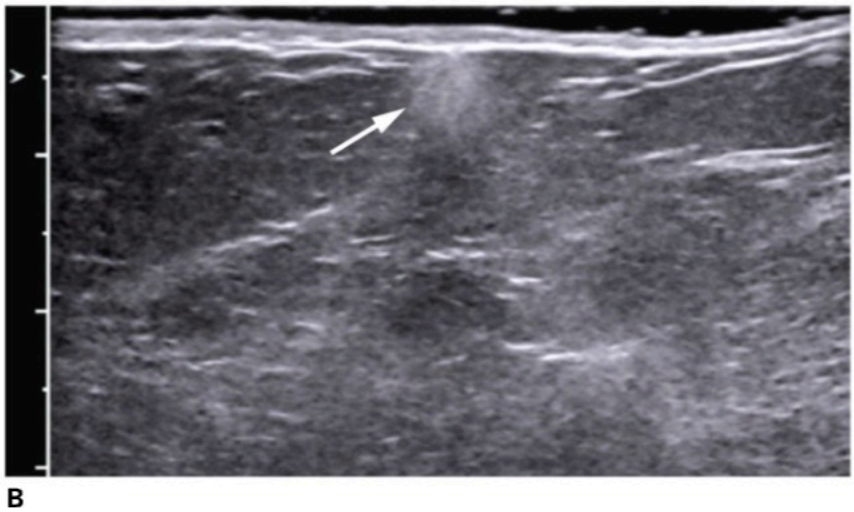

B

Figure 3 – ECHO PATTERN: HYPERECHOIC. Radial (A) and antiradial (B) images of a HYPERECHOIC mass (arrows). Although fat necrosis can have this appearance, there was no mammographic correlate to confirm a fat-containing mass. Because the mass has an indistinct margin, non-parallel orientation and subtle posterior shadowing, biopsy was performed. Pathology: Fat necrosis.

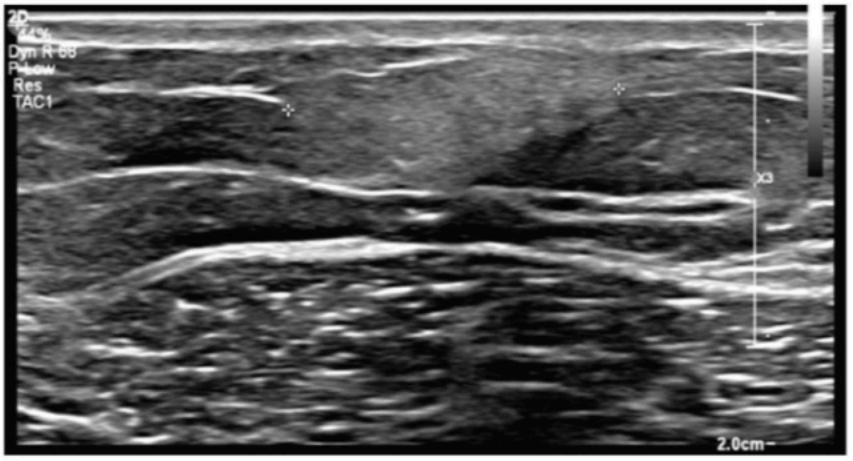

A

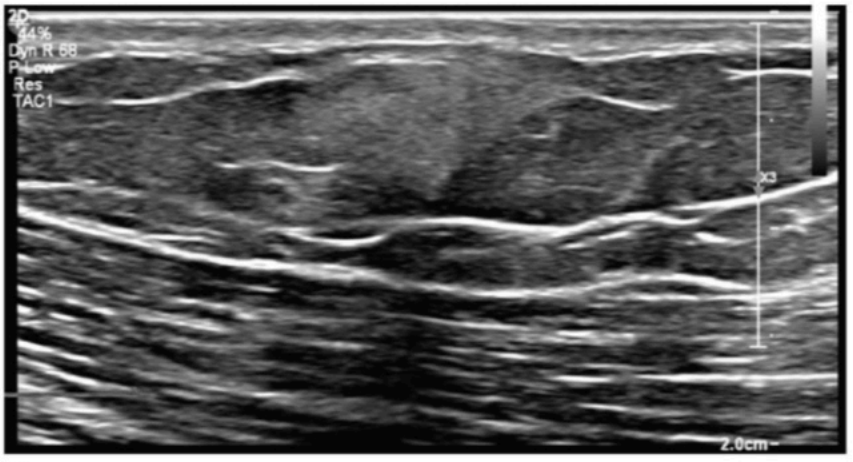

B

Figure 4 – ECHO PATTERN: HYPERECHOIC. Radial (A) and antiradial (B) images of a palpable HYPERECHOIC mass. The mass is irregular, parallel in orientation, with indistinct and angular margins. Although the mass was visible on tomosynthesis, fat was not evident in the mass mammographically. Because of the suspicious shape and margin at ultrasound, biopsy was performed. Pathology: Fat necrosis.

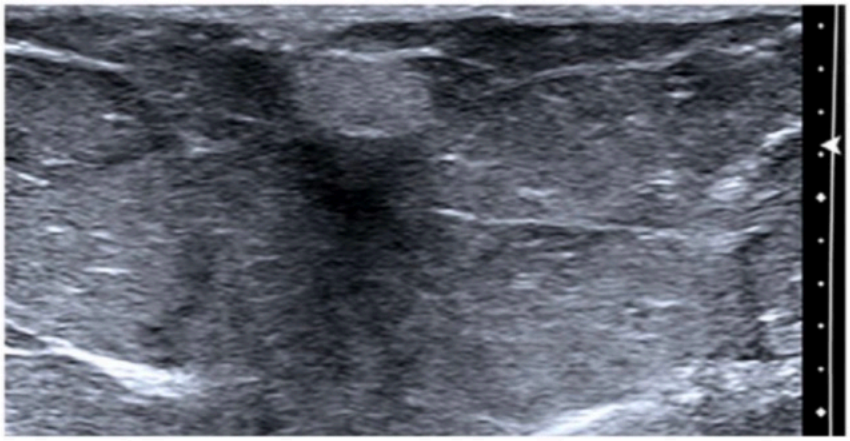

A

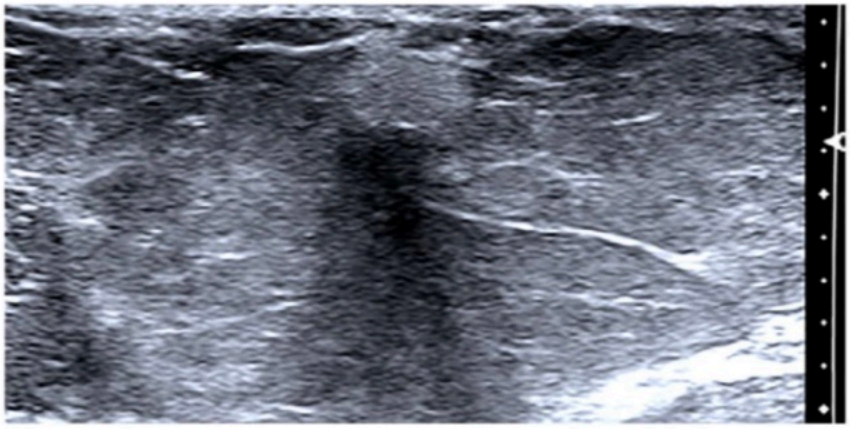

B

Figure 5 – ECHO PATTERN: HYPERECHOIC. Radial (A) and antiradial (B) images of an oval, homogeneously HYPERECHOIC mass. Because the mass has an indistinct margin and posterior shadowing and no characteristically benign mammographic appearance, it was deemed suspicious, and needle biopsy was performed. Pathology: Angiolipoma.

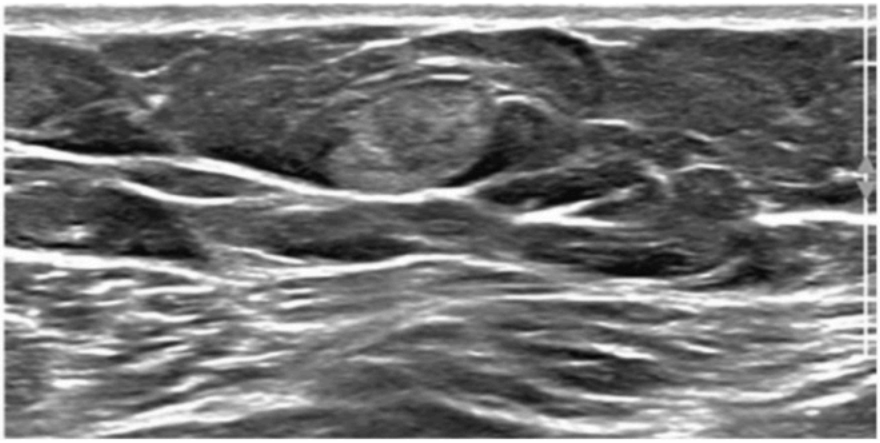

Figure 6 – ECHO PATTERN: HYPERECHOIC. Oval, circumscribed, HYPERECHOIC, parallel mass with no characteristically benign mammographic correlate. Pathology: Cavernous hemangioma.

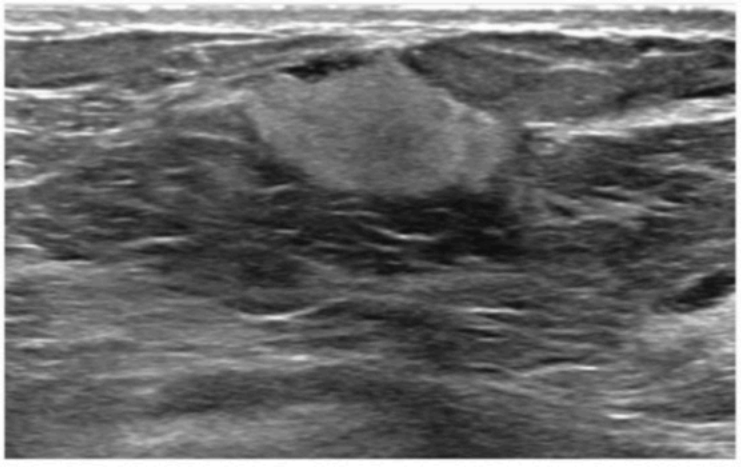

A

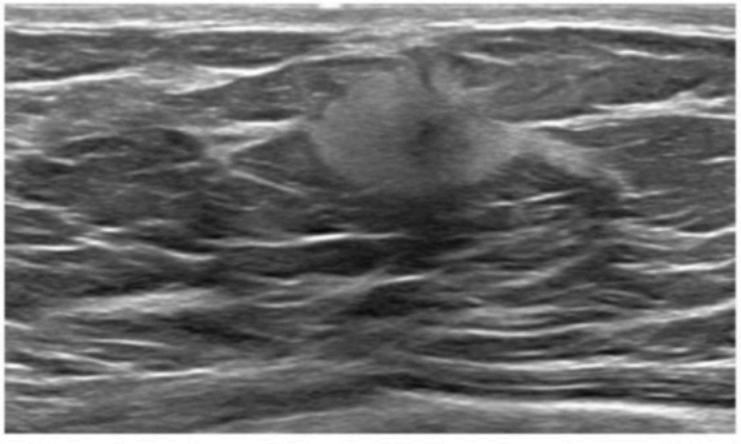

B

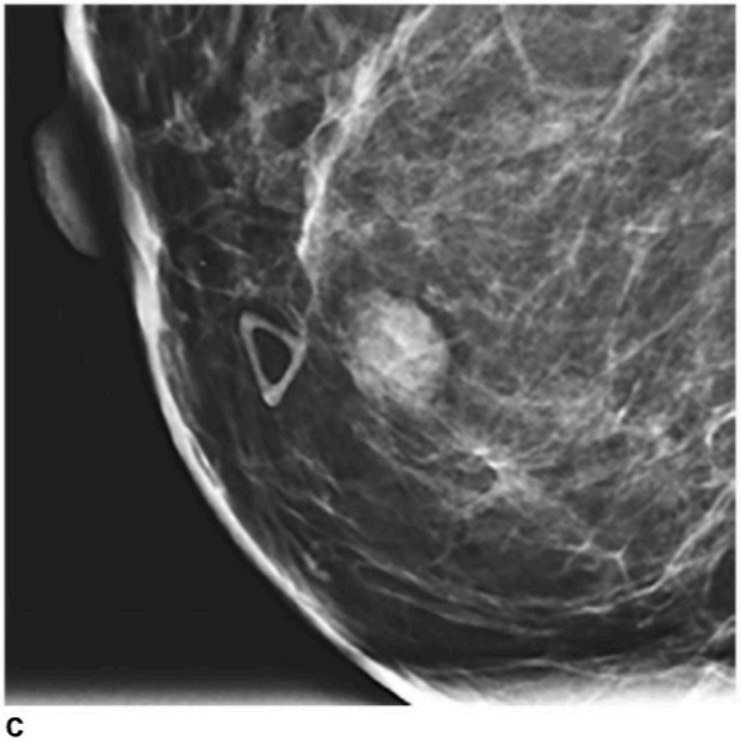

C

Figure 7 – ECHO PATTERN: HYPERECHOIC. Radial (A) and antiradial (B) images of an oval, parallel, HYPERECHOIC mass. At mammography (C), a mass is seen corresponding to the sonographic mass, which presented as a palpable lump. The indistinct margin and lack of fat in the corresponding mass at mammography are suspicious features. Pathology: Invasive carcinoma with mixed ductal and lobular features.

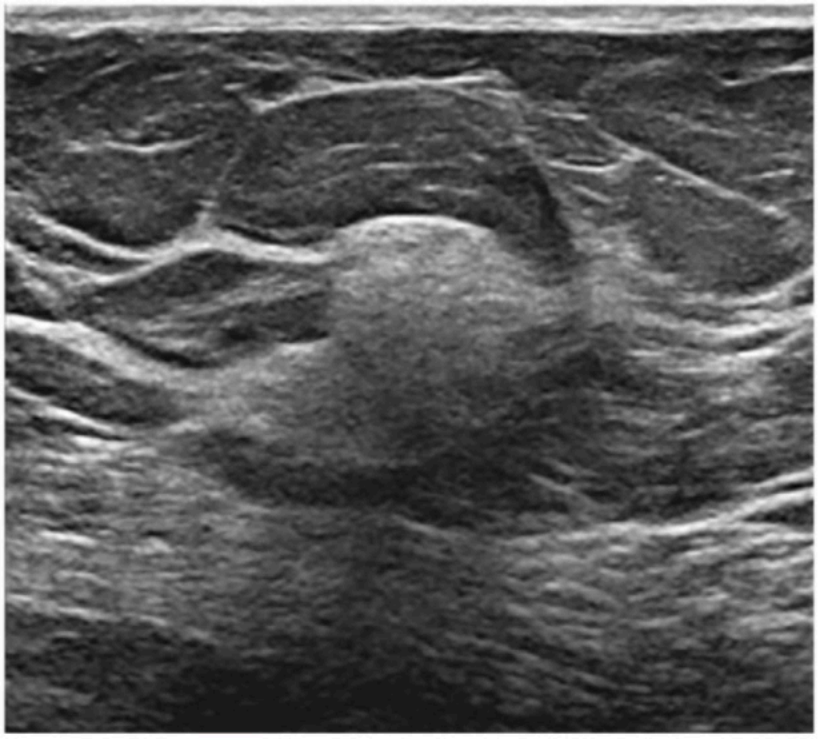

A

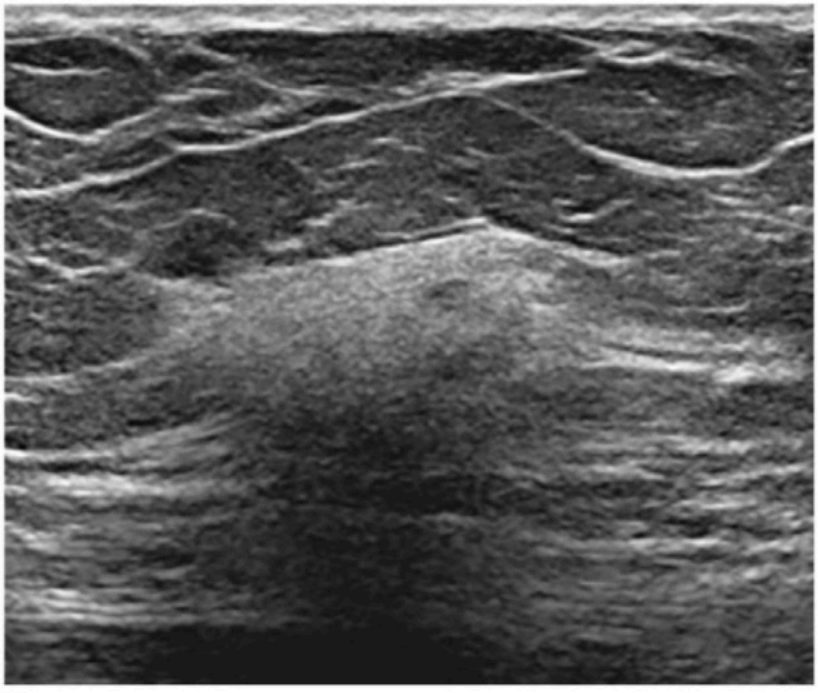

B

Figure 8 – ECHO PATTERN: HYPERECHOIC. Radial (A) and antiradial (B) images of a HYPERECHOIC irregular mass with indistinct margin and posterior shadowing. Despite the HYPERECHOIC echo pattern, other features including shape, margin, and posterior features must be considered. For this mass, several of these additional features are suspicious for malignancy. Pathology: Invasive ductal carcinoma.

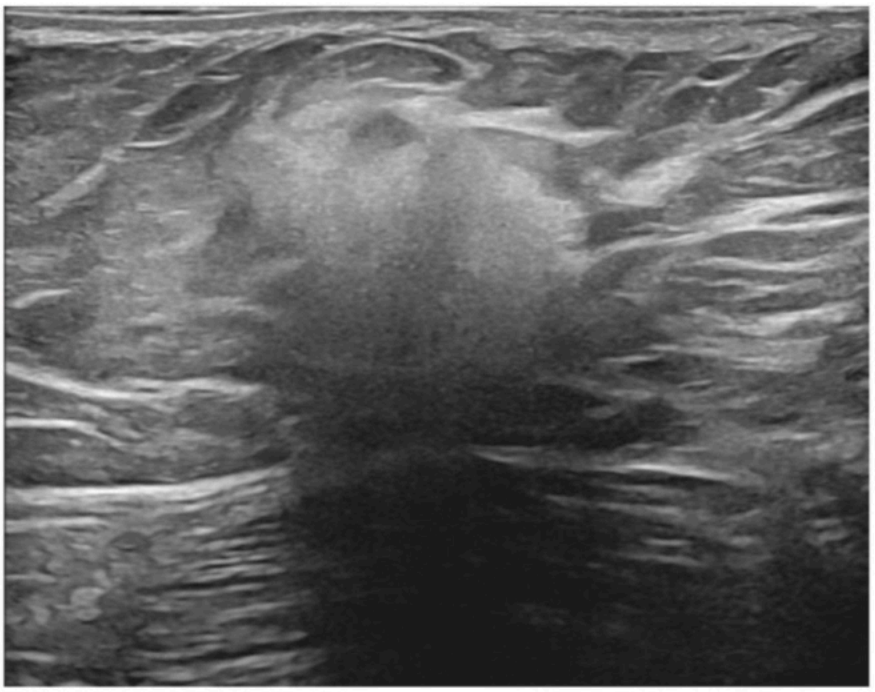

A



B

Figure 9 – ECHO PATTERN: HYPERECHOIC. Radial (A) and antiradial (B) ultrasound images of a HYPERECHOIC, oval, non-parallel mass with an indistinct margin and posterior shadowing. Despite the HYPERECHOIC echo pattern, the other features of the mass are suspicious for malignancy. Pathology: Invasive ductal carcinoma.

B. MASSES

4. ECHO PATTERN

   c. Isoechoic

   Isoechoic masses have the same echogenicity as subcutaneous fat and may be relatively inconspicuous, particularly when they are situated within an area of fat lobules.

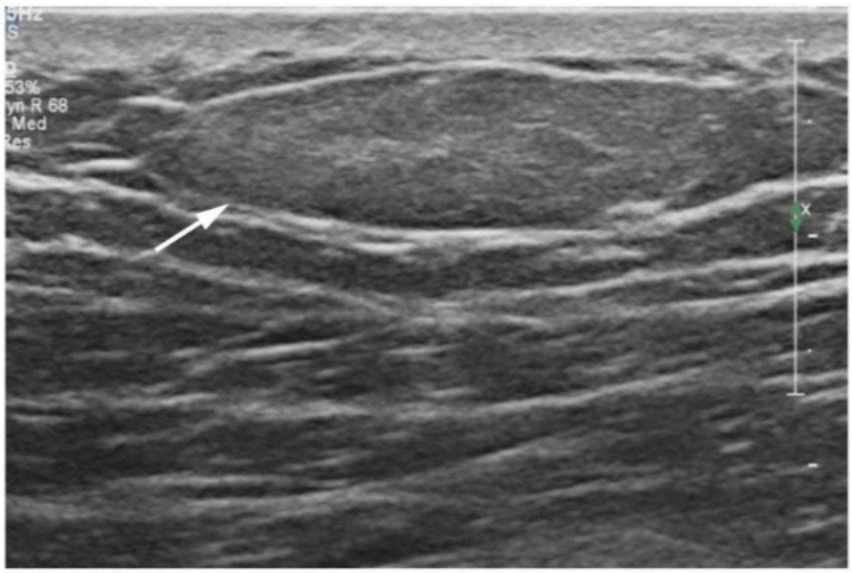

A

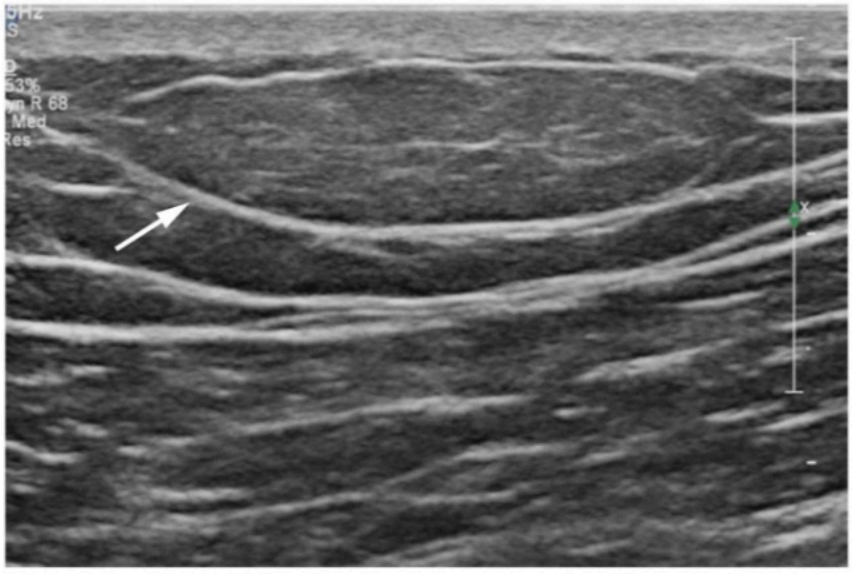

B

Figure 1 – ECHO PATTERN: ISOECHOIC. Patient presented with a soft, easily compressible mass that was not visible on mammography despite the entirely fatty tissue composition of the breast. Radial (A) and antiradial (B) ultrasound images demonstrate an oval, circumscribed, ISOECHOIC, parallel mass (arrows). The mass is the same echogenicity as the adjacent fat and can only be distinguished by the thin echogenic pseudocapsule surrounding the mass. These images and the physical exam are characteristic of a benign lipoma, and the study was assigned BI-RADS assessment 2, benign.

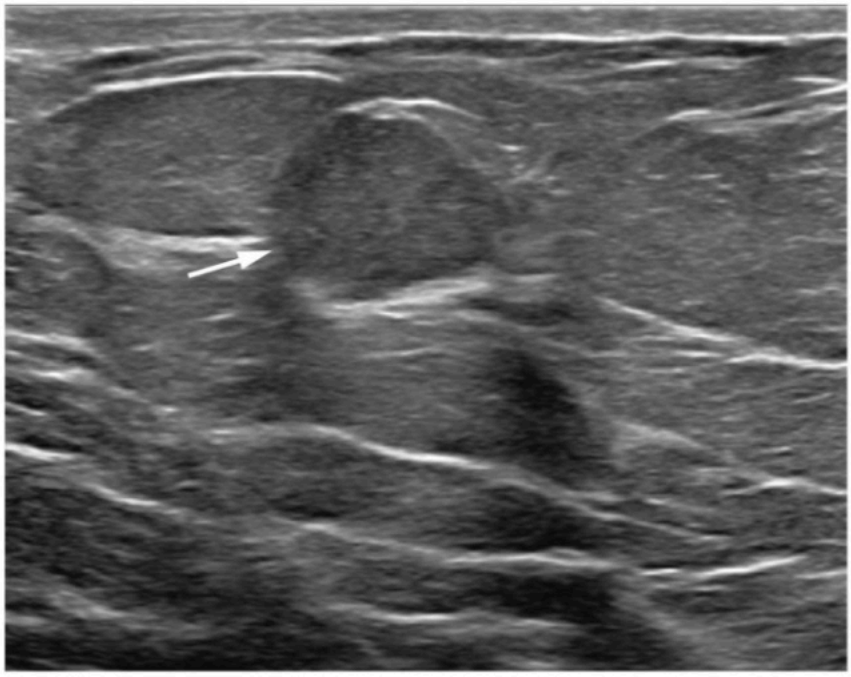

A

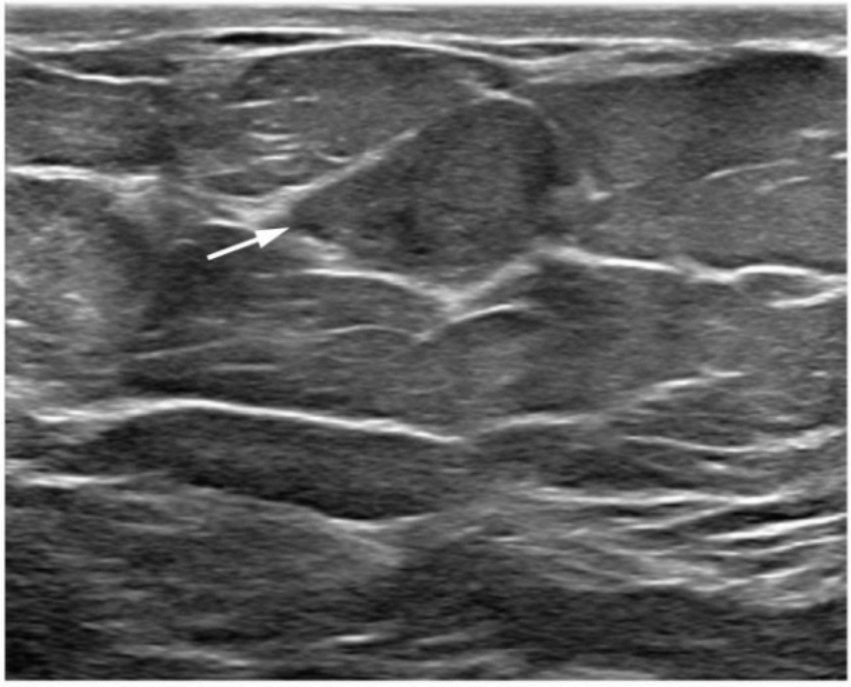

B

Figure 2 – ECHO PATTERN: ISOECHOIC. Radial (A) and antiradial (B) images of an oval, circumscribed, parallel ISOECHOIC mass (arrows) with no posterior features. Pathology: Complex fibroadenoma.

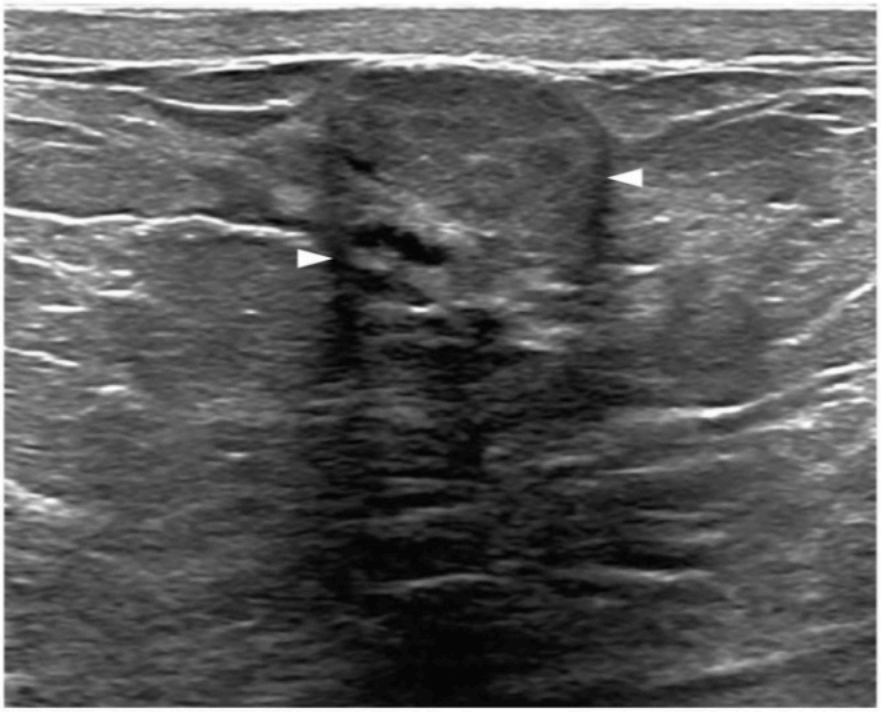

Figure 3 – ECHO PATTERN: ISOECHOIC. Ultrasound image of an oval, ISOECHOIC, circumscribed parallel mass in a patient with a new palpable lump. Note refractive edge shadowing (arrowheads) which does not contribute to the assessment of the mass. Pathology: Fat necrosis and fibrosis.

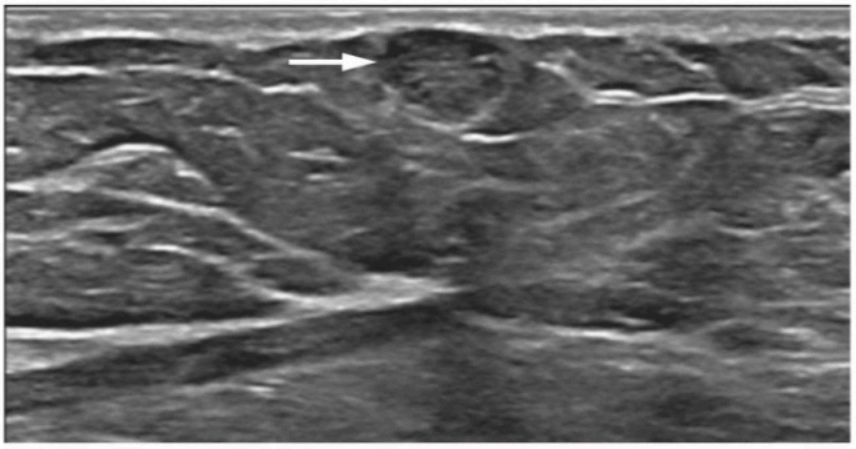

A

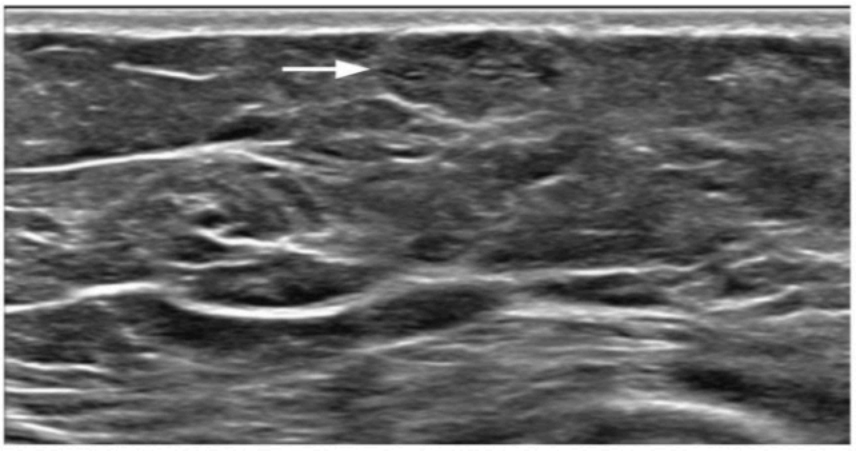

B

Figure 4 – ECHO PATTERN: ISOECHOIC. Radial (A) and antiradial (B) images of an oval, parallel, ISOECHOIC mass (arrows) with no posterior features. This mass was newly palpable and underwent needle biopsy. Pathology: Hemangioma.

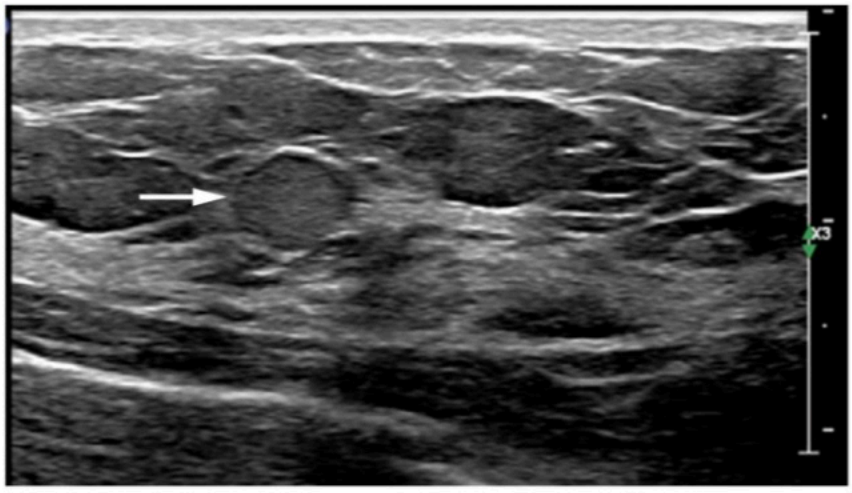

A

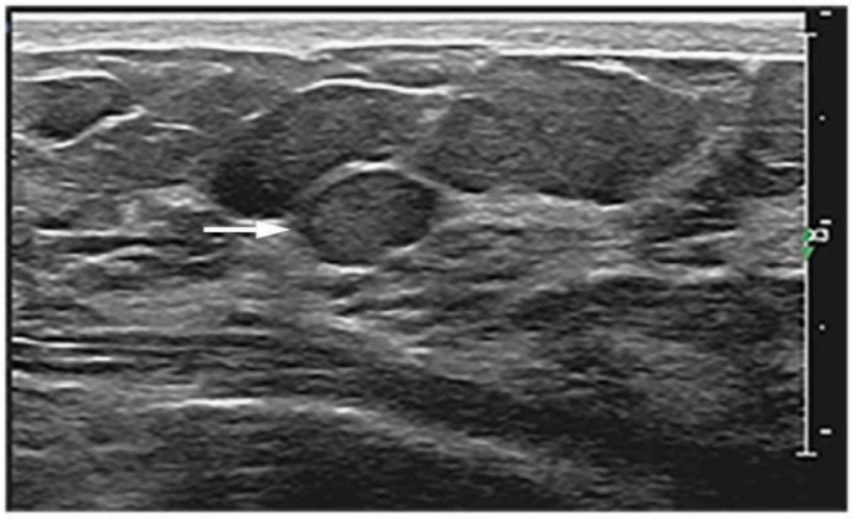

B

Figure 5 – ECHO PATTERN: ISOECHOIC. Radial (A) and antiradial (B) images of an oval, circumscribed ISOECHOIC mass (arrows) with no posterior features. Despite these benign features, the mass was new on mammography and therefore suspicious. Pathology: DCIS.

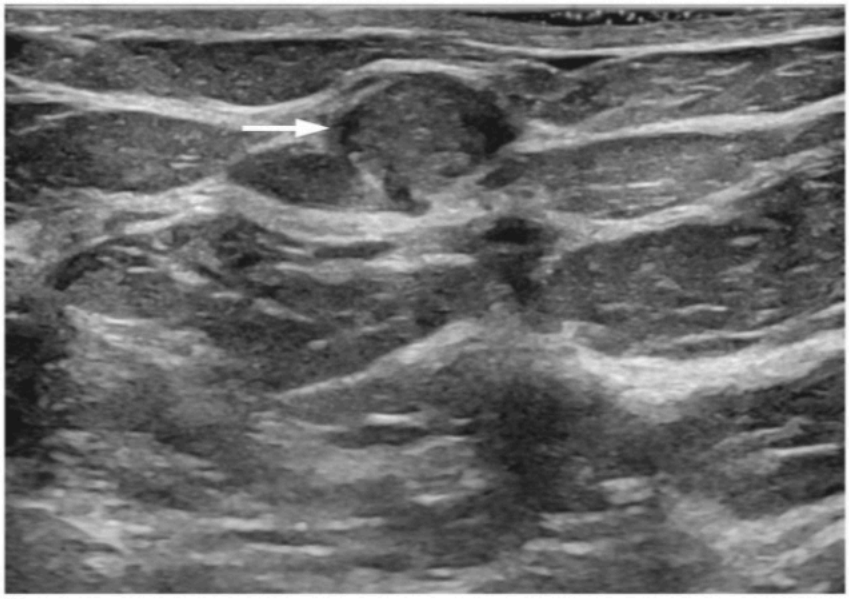

A

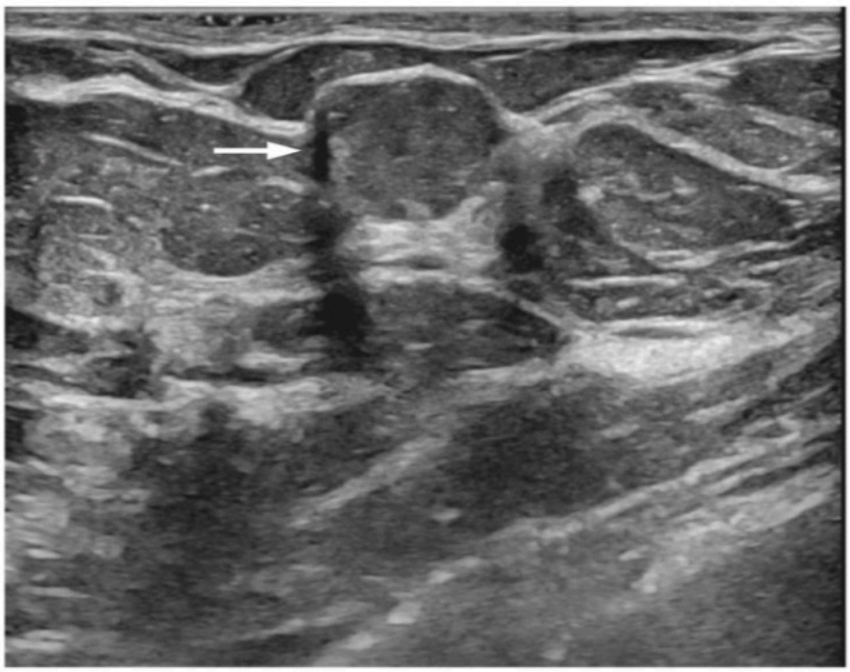

B

Figure 6 – ECHO PATTERN: ISOECHOIC. Radial (A) and antiradial (B) images of an oval, parallel, ISOECHOIC mass (arrows) with no posterior features. Pathology: Invasive ductal carcinoma.

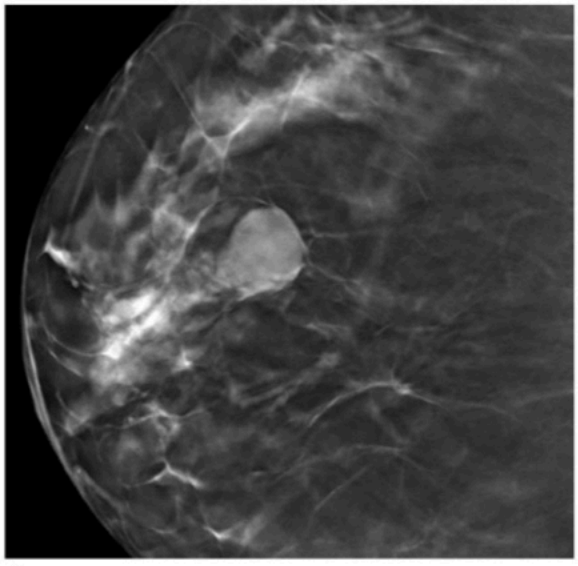

A

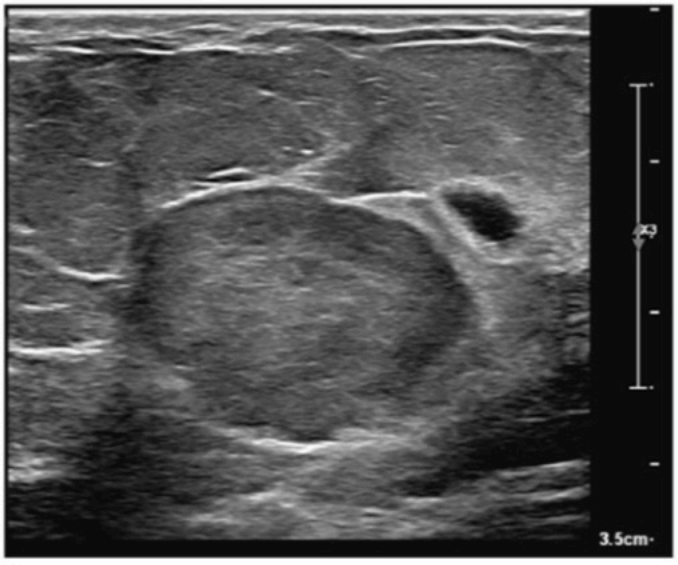

B

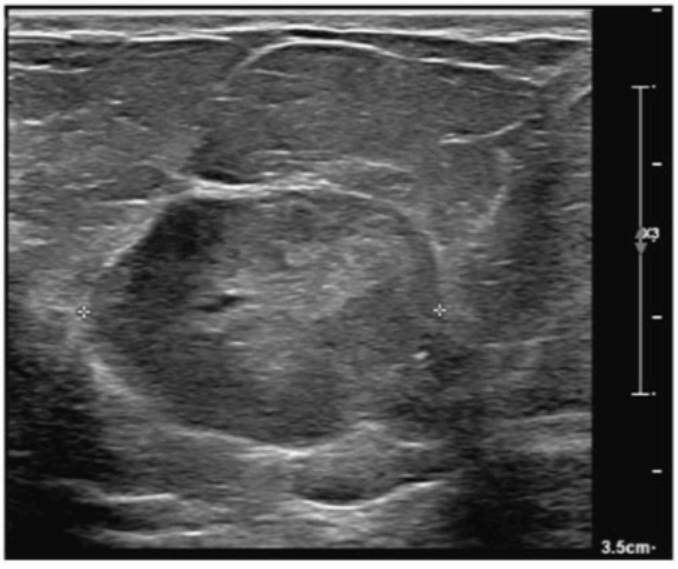

C

Figure 7 – ECHO PATTERN: ISOECHOIC. Right CC tomosynthesis image of an oval mass (A). Radial (B) and antiradial (C) ultrasound images of the corresponding oval, ISOECHOIC mass with partially circumscribed and partially indistinct margin (therefore reported as indistinct). The adjacent cyst was incidental. Pathology: Mucinous carcinoma.

B. MASSES

4. ECHO PATTERN

   d. Hypoechoic

   Echogenicity is defined relative to subcutaneous fat. Hypoechoic masses are less echogenic than fat but not anechoic (i.e., darker gray than fat but not black). The echo pattern of most benign and malignant masses is hypoechoic.

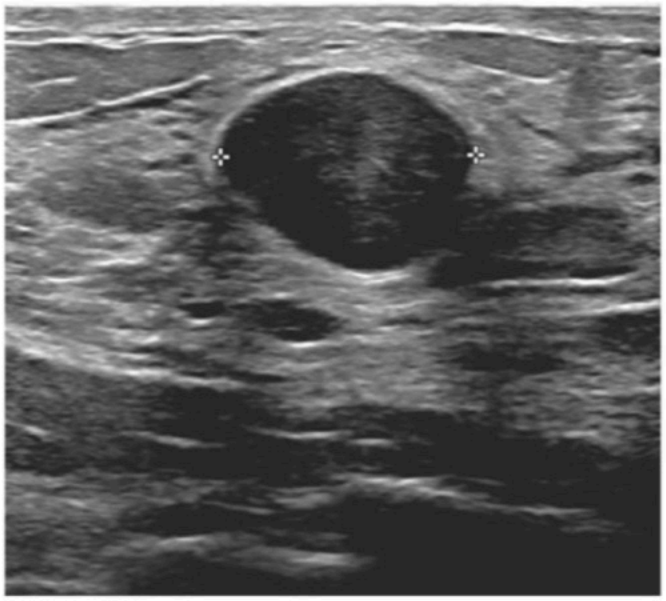

A

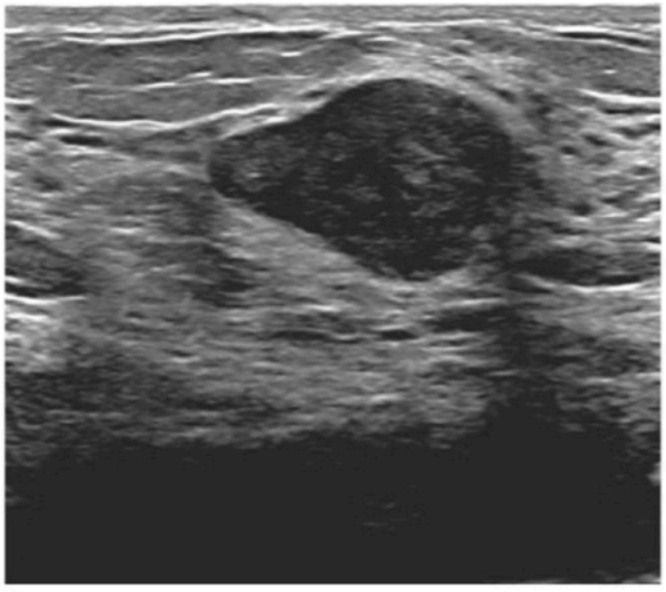

B

Figure 1 – ECHO PATTERN: HYPOECHOIC. Oval, circumscribed, parallel, HYPOECHOIC mass with posterior enhancement on a baseline exam. Given the morphology, the mass was assigned BI-RADS assessment category 3, probably benign. The mass remained stable in size for two years and was ultimately dismissed as benign, most likely a fibroadenoma.

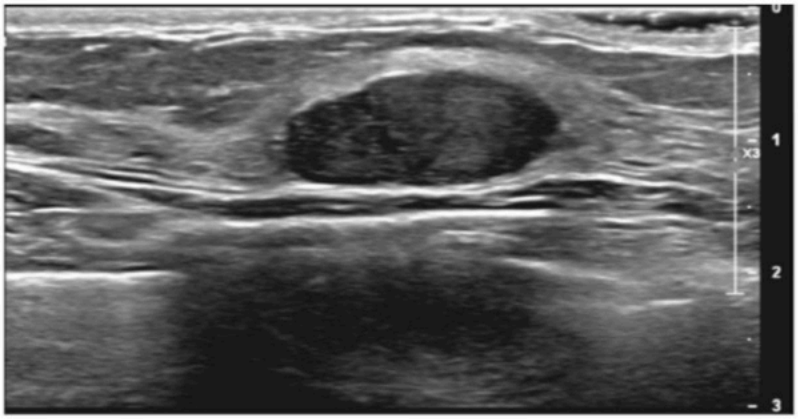

Figure 2 – ECHO PATTERN: HYPOECHOIC. Oval, parallel, circumscribed, HYPOECHOIC mass with no posterior features. Pathology: Fibroadenoma.



A



B

Figure 3 – ECHO PATTERN: HYPOECHOIC. Radial (A) and antiradial (B) images of an irregular HYPOECHOIC mass with angular margin in a patient with type 2 diabetes. Pathology: Diabetic mastopathy.



Figure 4 – ECHO PATTERN: HYPOECHOIC. Oval, parallel, HYPOECHOIC mass with indistinct margin. Pathology: Invasive ductal carcinoma.

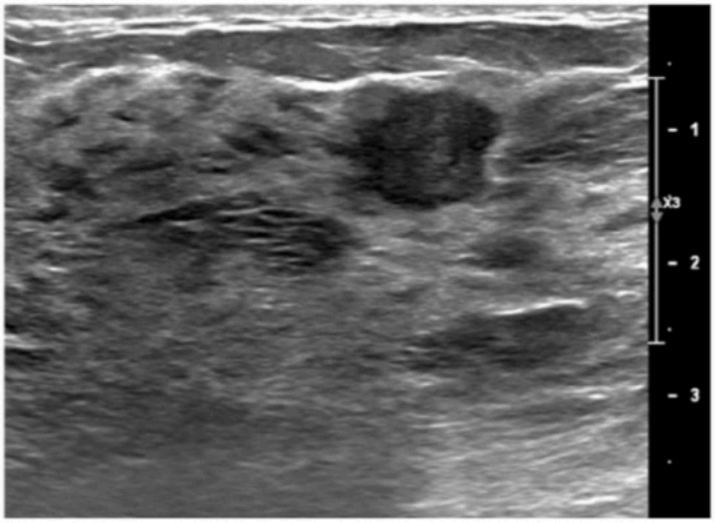

A

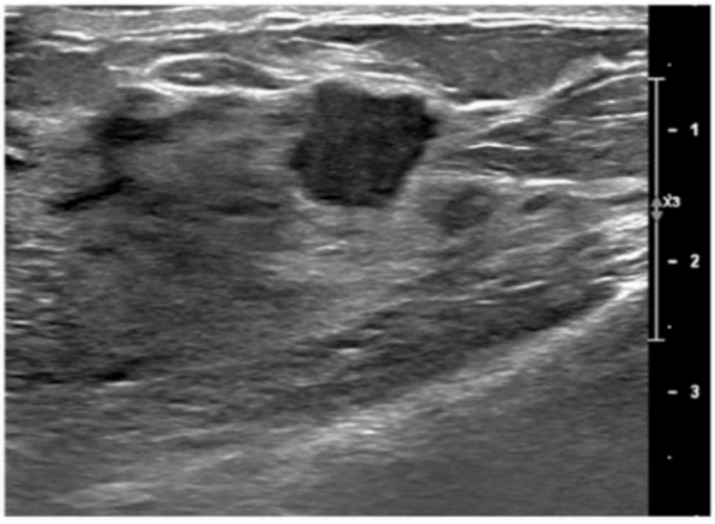

B

Figure 5 – ECHO PATTERN: HYPOECHOIC. Radial (A) and antiradial (B) images of an irregular HYPOECHOIC mass with non-parallel orientation and indistinct, angular, and spiculated margination. Pathology: Invasive ductal carcinoma.

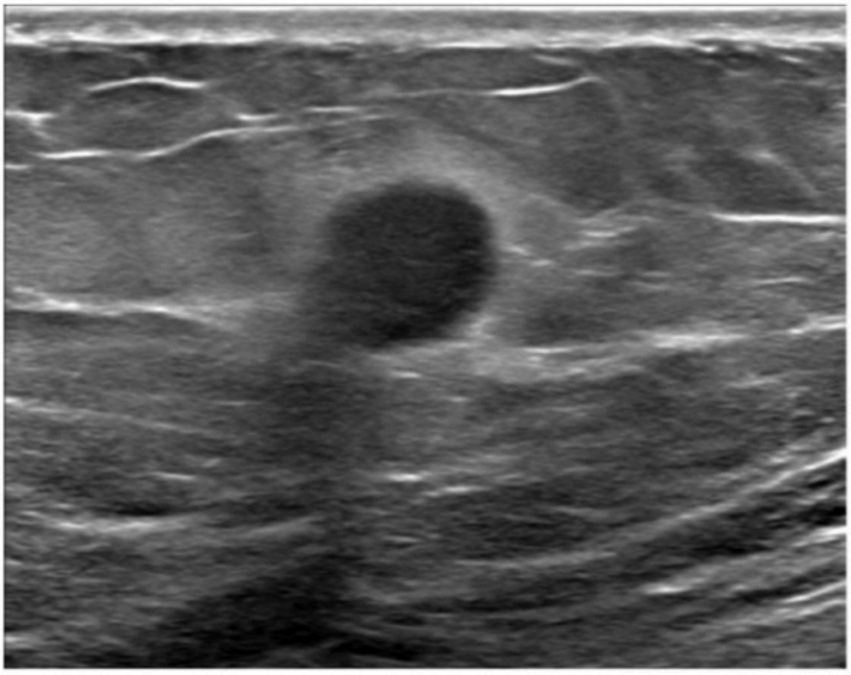

A

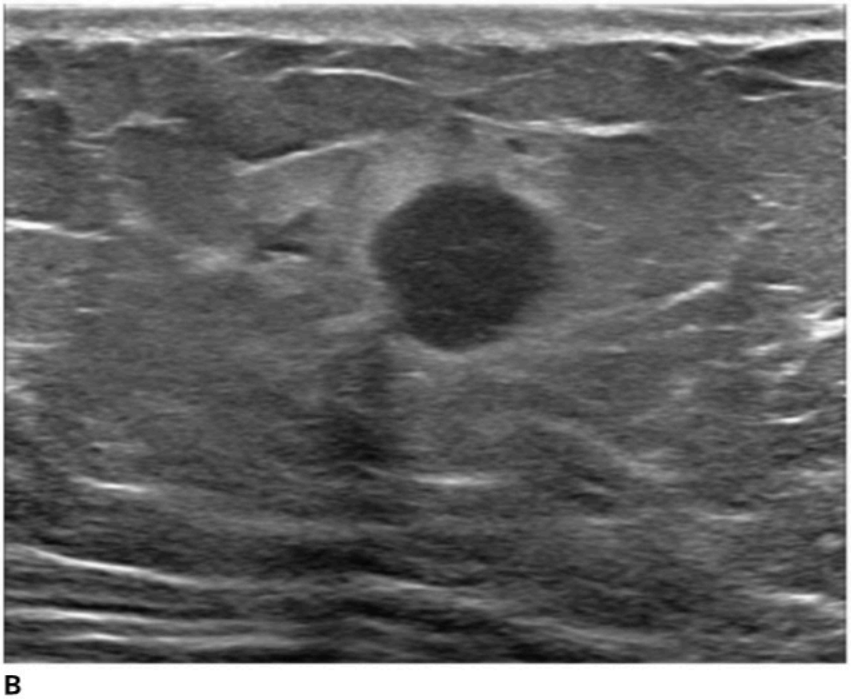

B

Figure 6 – ECHO PATTERN: HYPOECHOIC. Radial (A) and antiradial (B) images of a round, HYPOECHOIC mass with indistinct margin, no posterior features, and an echogenic rind. Pathology: Invasive ductal carcinoma.

B. MASSES

4. ECHO PATTERN

e. Heterogeneous

Heterogeneous masses display a mix of echo patterns. Heterogeneity has little prognostic value in differentiating benign from malignant masses, and it is common to observe heterogeneity in fibroadenomas as well as cancers.

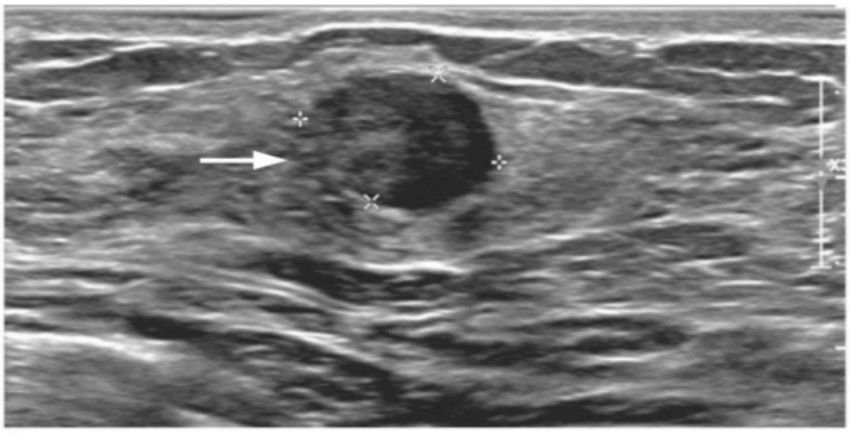

A

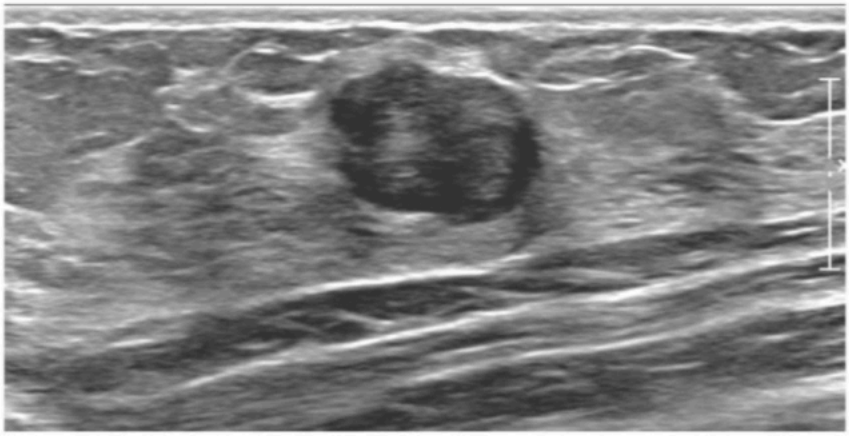

B

Figure 1 – ECHO PATTERN: HETEROGENEOUS. Radial (A) and antiradial (B) images of an oval, indistinct (arrow), parallel mass with HETEROGENEOUS echo pattern and no posterior features. Pathology: Fibroadenoma.

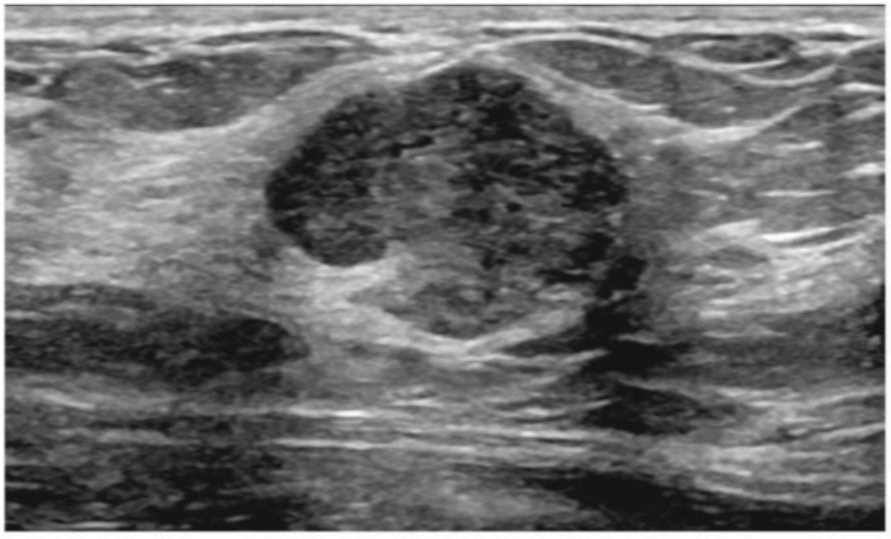

Figure 2 – ECHO PATTERN: HETEROGENEOUS. Oval, parallel, lobulated mass with posterior enhancement and HETEROGENEOUS echo pattern. There are hypoechoic and isoechoic portions of the mass. Pathology: Fibroadenoma.

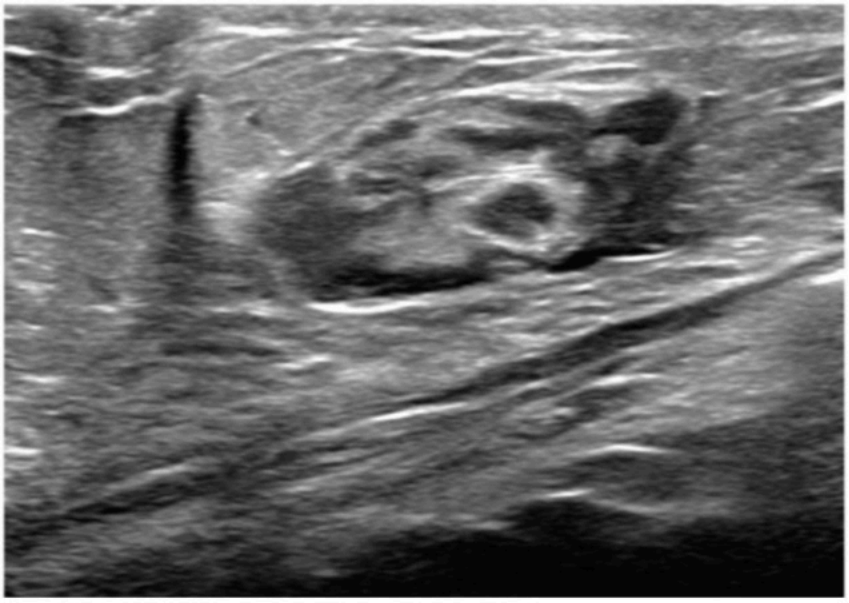

A

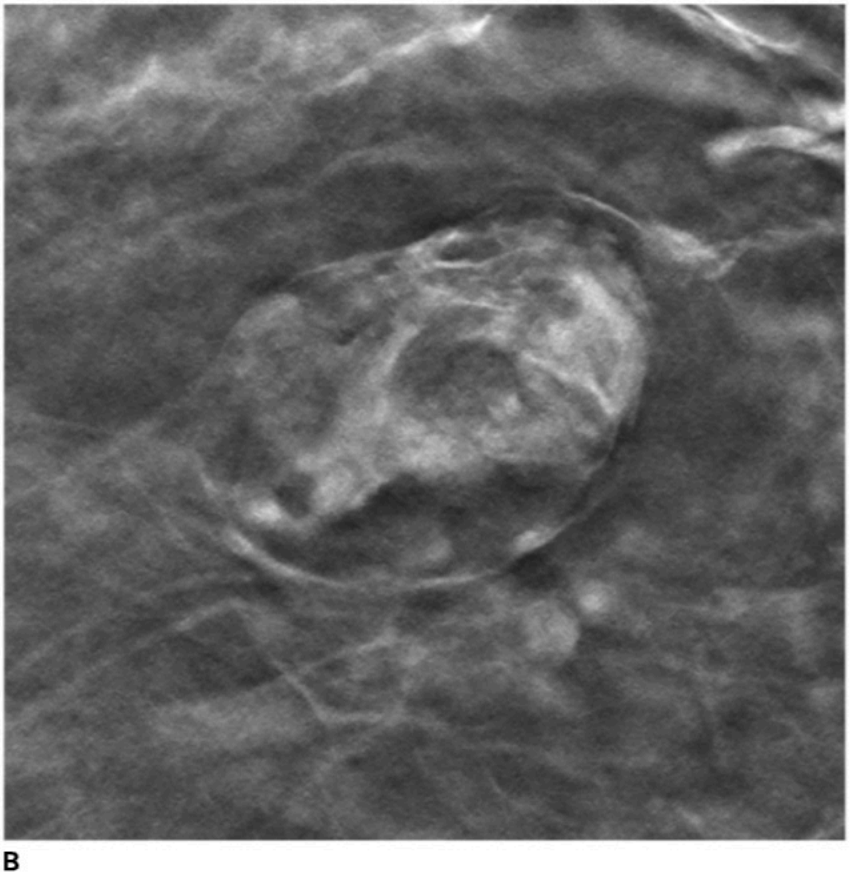

B

Figure 3 – ECHO PATTERN: HETEROGENEOUS. Ultrasound image (A) of a HETEROGENEOUS mass with hyperechoic and hypoechoic elements. The echo pattern, oval or slightly lobulated shape and circumscribed margin are all typical (though not diagnostic) of a hamartoma. Mammographic image of the mass (B) confirms a mixed fat and soft-tissue density circumscribed mass diagnostic of a benign hamartoma.



Figure 4 – ECHO PATTERN: HETEROGENEOUS. A patient presents with a painful, palpable mass and erythematous breast. Ultrasound imaging demonstrates an oval, parallel, HETEROGENEOUS mass with indistinct margin and posterior enhancement. Overlying skin thickening and surrounding edema are all consistent with the diagnosis of breast abscess, confirmed by aspiration. Pathology: Abscess.

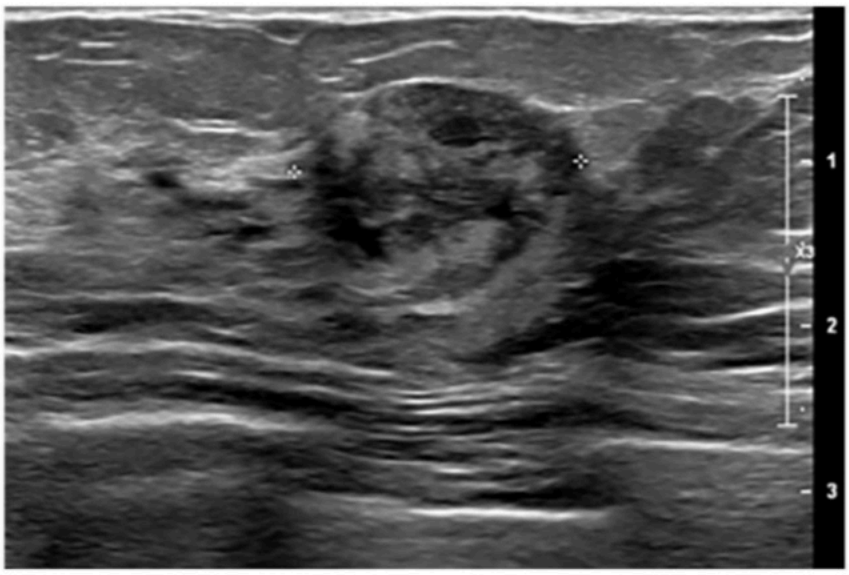

A

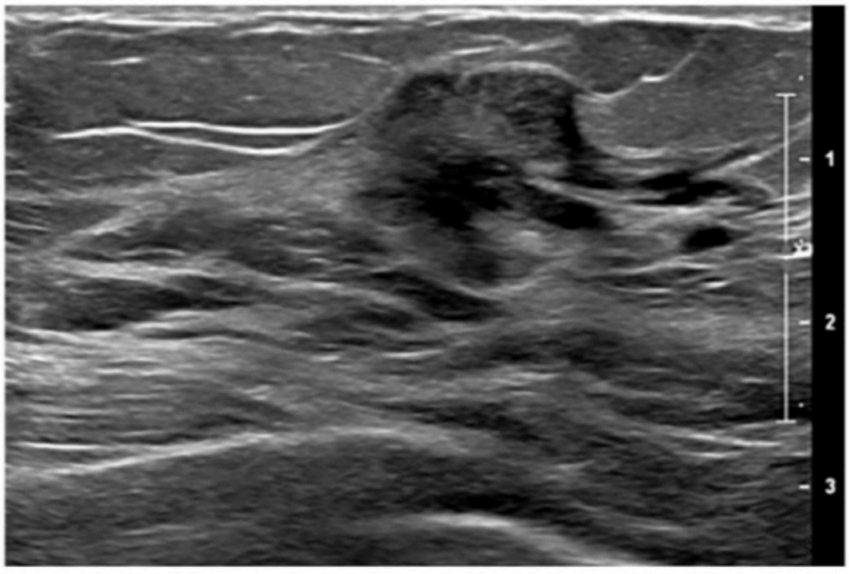

B

Figure 5 – ECHO PATTERN: HETEROGENEOUS. Radial (A) and antiradial (B) images of a HETEROGENEOUS, non-parallel, irregular mass with indistinct margin. Pathology: Invasive ductal carcinoma with lobular features.

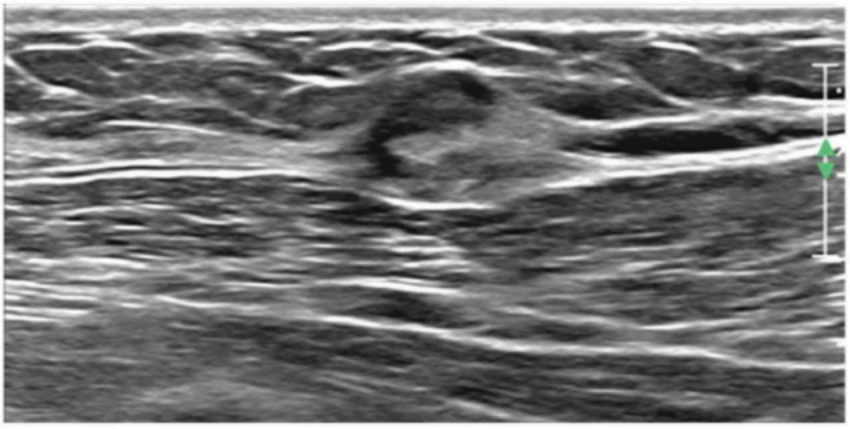

A

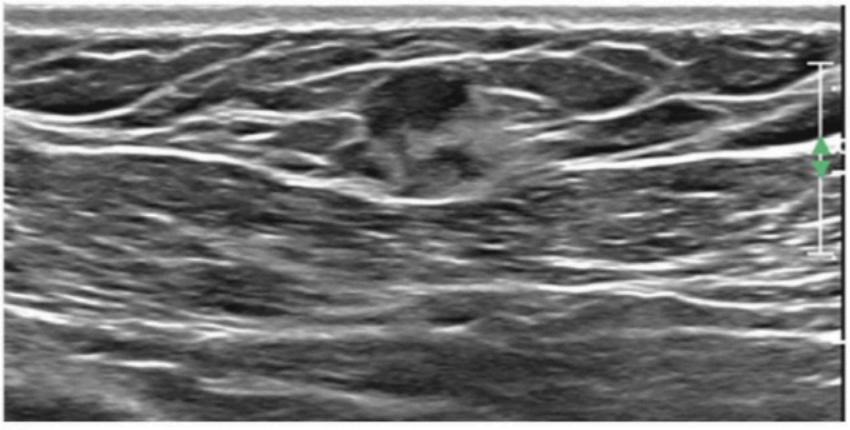

B

Figure 6 – ECHO PATTERN: HETEROGENEOUS. HETEROGENEOUS oval mass with indistinct margin and no posterior features. Pathology: Invasive ductal carcinoma.

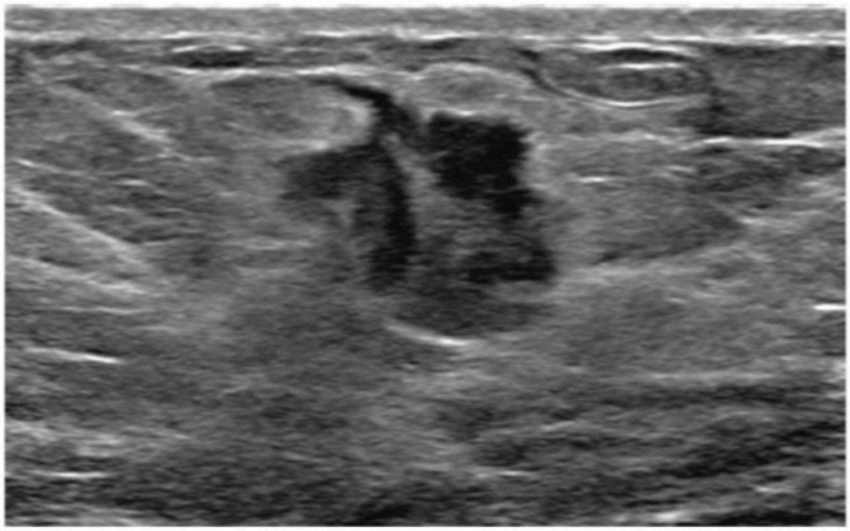

A

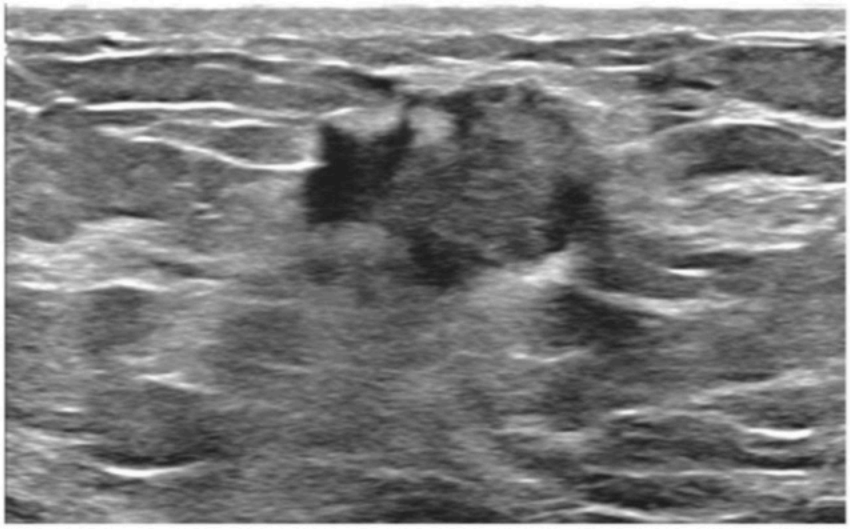

B

Figure 7 – ECHO PATTERN: HETEROGENEOUS. Radial (A) and antiradial (B) images of a HETEROGENEOUS, irregular, non-parallel mass with indistinct, angular, and spiculated margins (reported as spiculated to match the most suspicious feature) and an echogenic rind. This mass was assigned BI-RADS assessment 5, highly suggestive of malignancy. Pathology: Invasive ductal carcinoma.

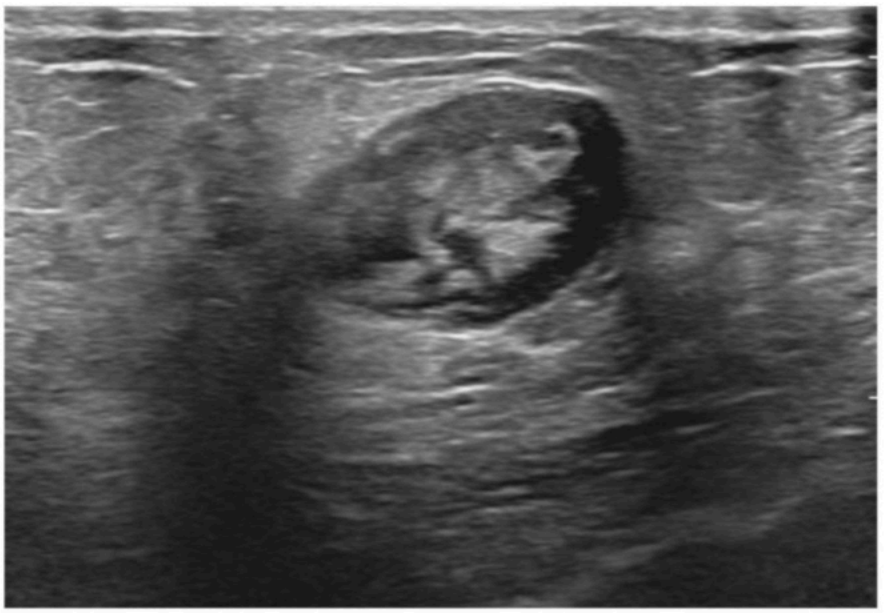

Figure 8 – ECHO PATTERN: HETEROGENEOUS. Oval, parallel, HETEROGENEOUS mass with posterior enhancement. Although a fibroadenoma could have this appearance, the mass was new, and the adjacent posterior shadowing was not artifactual refractive edge shadowing. This combination of features is not typical of a fibroadenoma, and the mass was assigned BI-RADS assessment category 4, suspicious. Note that in contrast to a benign cyst, the posterior enhancement behind this solid mass is not a reassuring sign. Pathology: Invasive ductal carcinoma.

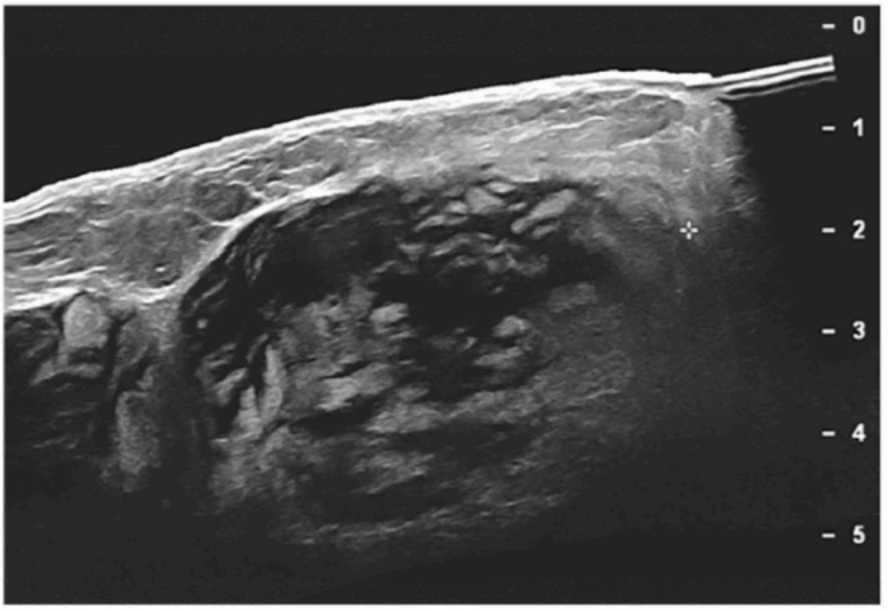

Figure 9 – ECHO PATTERN: HETEROGENEOUS. Large, HETEROGENEOUS mass with associated edema in the axilla. Although mastitis or abscess could have a similar appearance, the patient's age and the location of the mass in the axilla make this mass highly suggestive of malignancy. Pathology: Poorly differentiated invasive ductal carcinoma.

B. MASSES

4. ECHO PATTERN

f. Mixed Solid and Cystic (historically "complex cystic and solid")

A mixed solid and cystic mass contains both solid (iso-, hypo-, or hyperechoic) and cystic or fluid (anechoic) components. The important feature is the solid component, and biopsy targeting the solid component is usually required to determine the etiology of the mass. Aspiration of the cystic component may yield a false negative result and is rarely useful when assessing a mixed solid and cystic mass. The lexicon change from the prior edition emphasizes that the solid component of the mass is the most significant feature and prevents potential terminology confusion with complicated cysts.

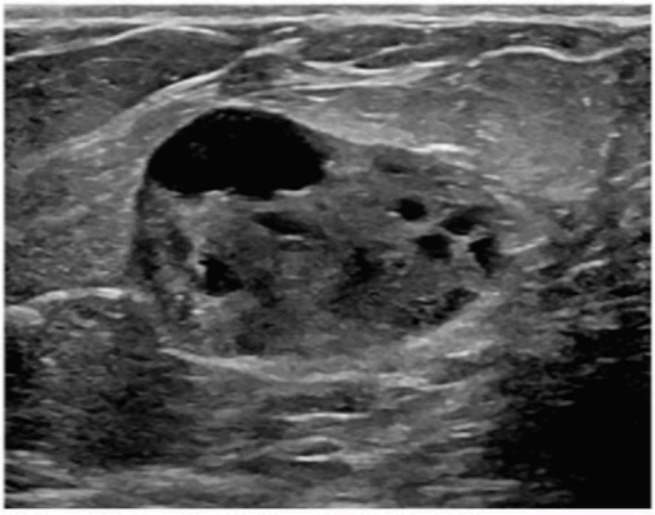

A



B

Figure 1 – ECHO PATTERN: MIXED SOLID AND CYSTIC. Radial (A) and antiradial (B) images of a MIXED SOLID AND CYSTIC, oval, parallel mass with circumscribed margin, and no posterior features. In this case, the mass is predominantly solid with a few cystic spaces. MIXED SOLID AND CYSTIC masses are usually not appropriate for follow-up; unless the clinical presentation suggests an abscess, these masses typically require biopsy to establish the diagnosis. Pathology: Complex fibroadenoma.

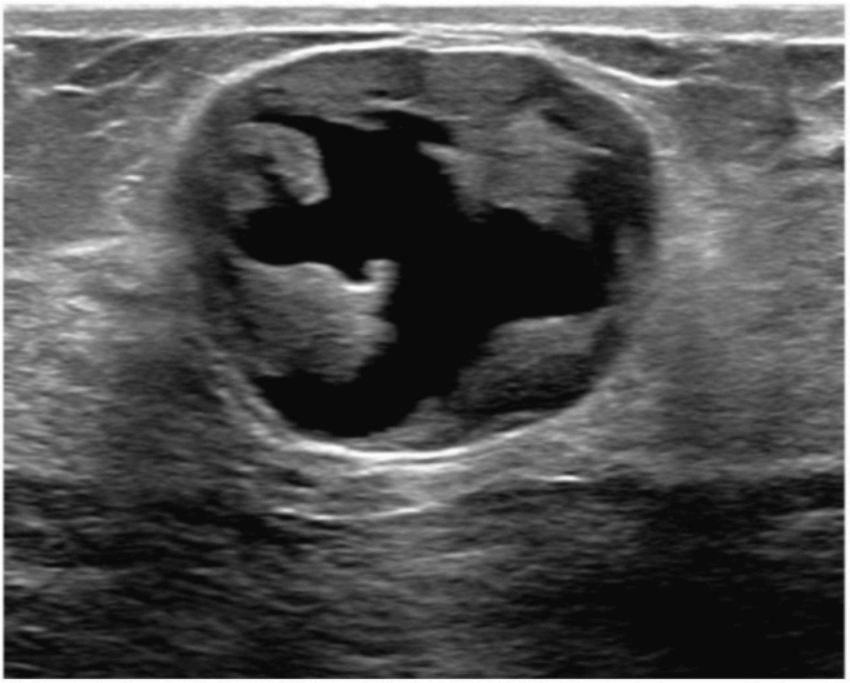

A

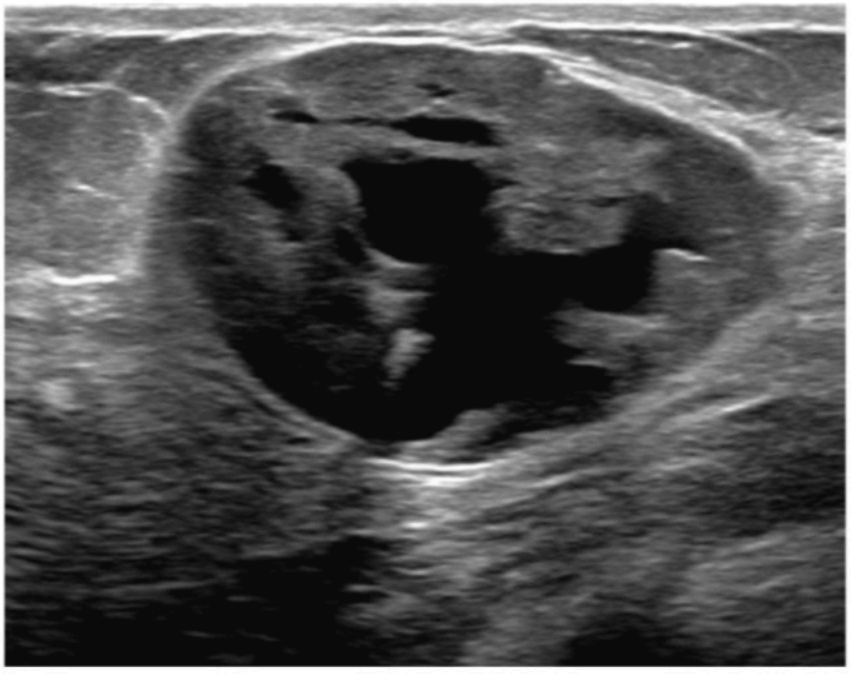

B

Figure 2 – ECHO PATTERN: MIXED SOLID AND CYSTIC. Radial (A) and antiradial (B) images of a MIXED SOLID AND CYSTIC, oval, parallel mass with circumscribed margin. Pathology: Fibroadenoma.

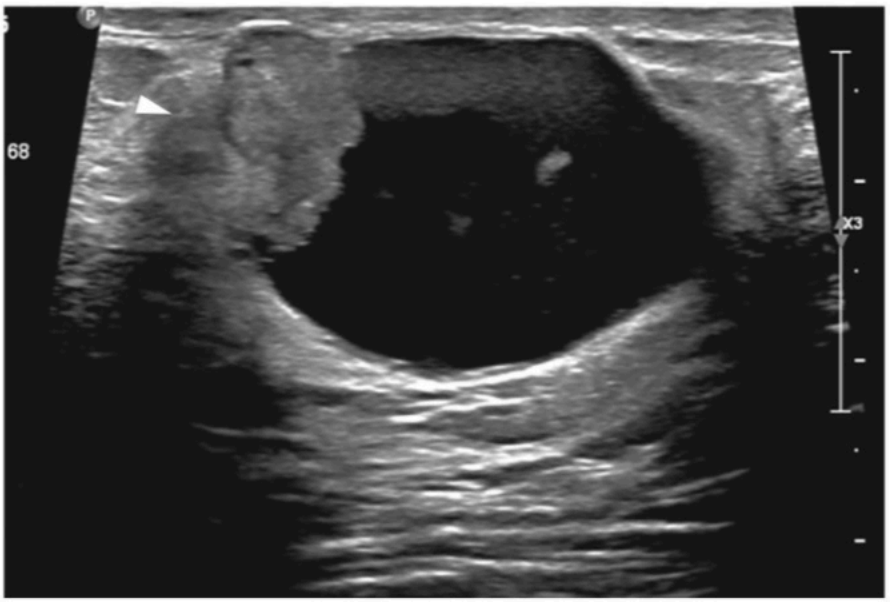

Figure 3 – ECHO PATTERN: MIXED SOLID AND CYSTIC. Oval, parallel, MIXED SOLID AND CYSTIC mass. The solid component extends into the surrounding tissue (arrowhead). Biopsy targeting the solid component and subsequent excision were performed. Pathology: Intraductal papilloma.

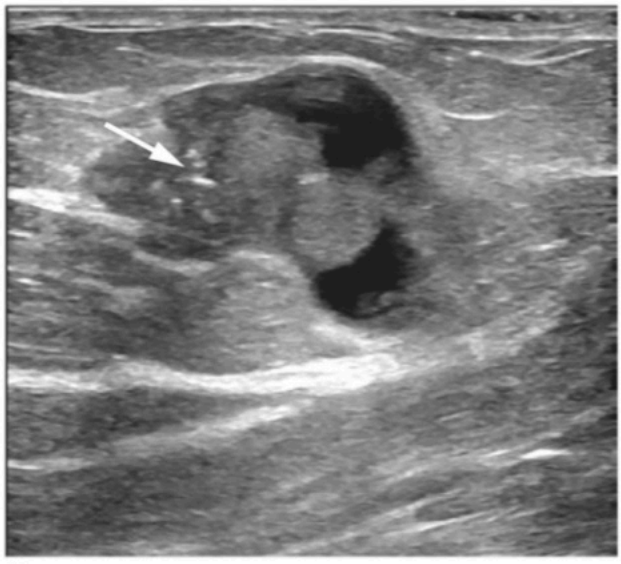

A

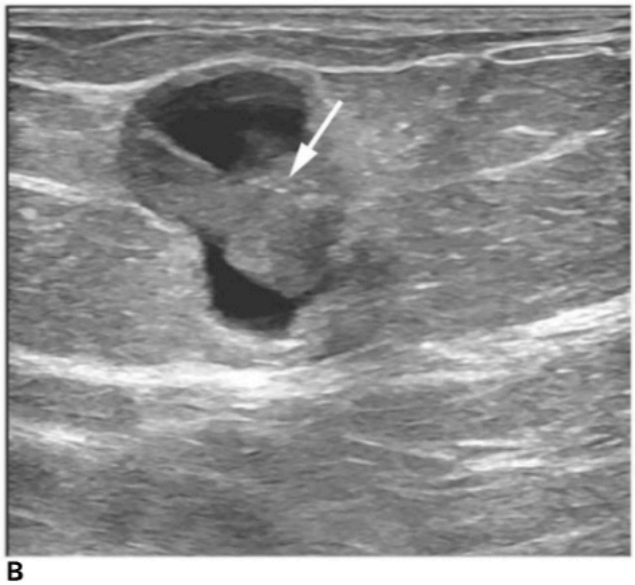

B

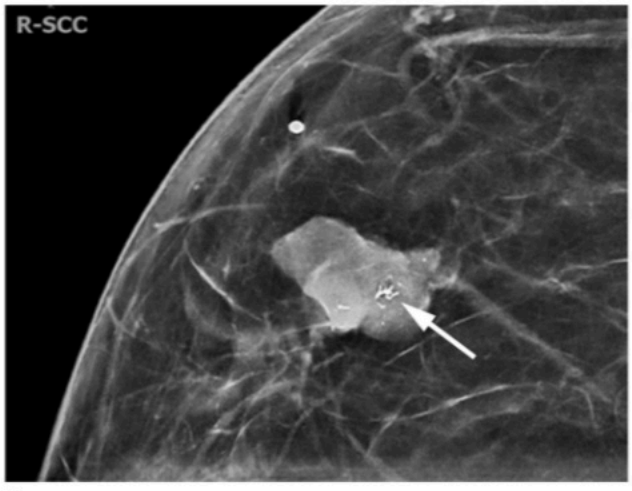

C

Figure 4 – ECHO PATTERN: MIXED SOLID AND CYSTIC. Radial (A) and antiradial (B) images of an irregular non-parallel, MIXED SOLID AND CYSTIC mass with indistinct margin. Calcifications are evident in both the ultrasound and mammographic (C) images (arrows) of the mass. Pathology: Sclerosed intraductal papilloma.

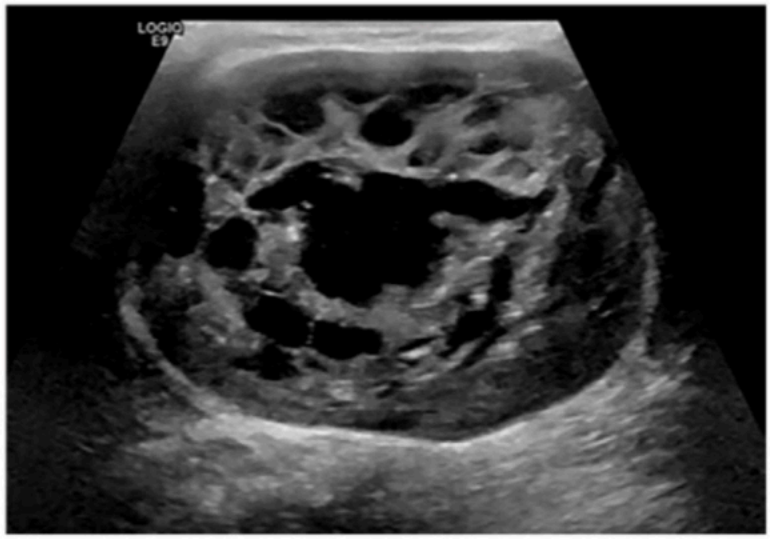

Figure 5 – ECHO PATTERN: MIXED SOLID AND CYSTIC. A patient with a remote history of extracapsular rupture of a silicone breast implant presented with this oval, parallel, circumscribed mass with MIXED SOLID AND CYSTIC echo pattern. Pathology: Silicone granuloma (biopsy-proven).

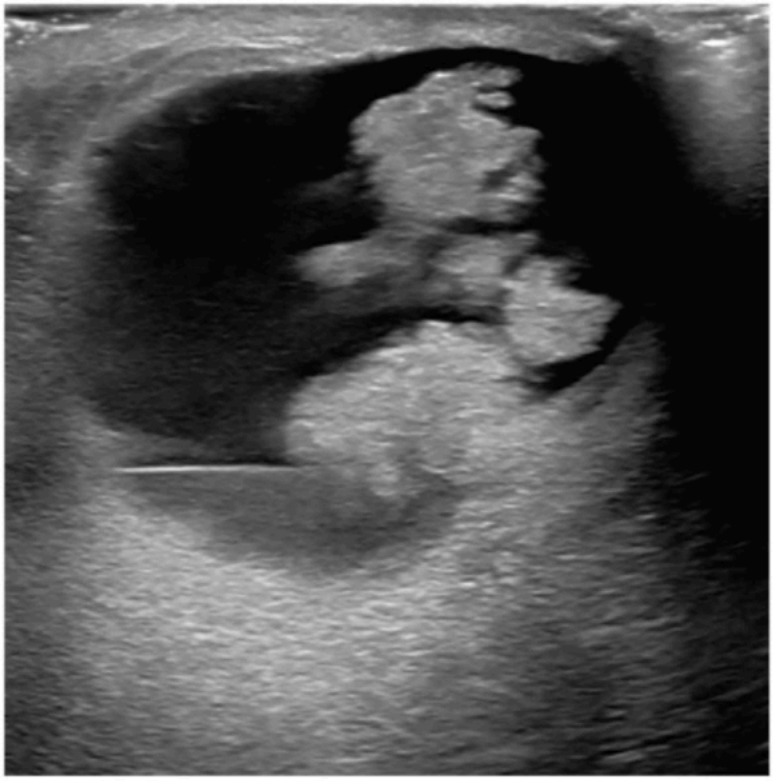

Figure 6 – ECHO PATTERN: MIXED SOLID AND CYSTIC. Oval MIXED SOLID AND CYSTIC mass with an indistinct margin and posterior enhancement. Although this mass is typical of papillary lesions, there are no imaging features that differentiate benign from malignant papillary lesions. The important feature is the solid component which should be specifically targeted during needle biopsy. Pathology: Invasive papillary carcinoma.

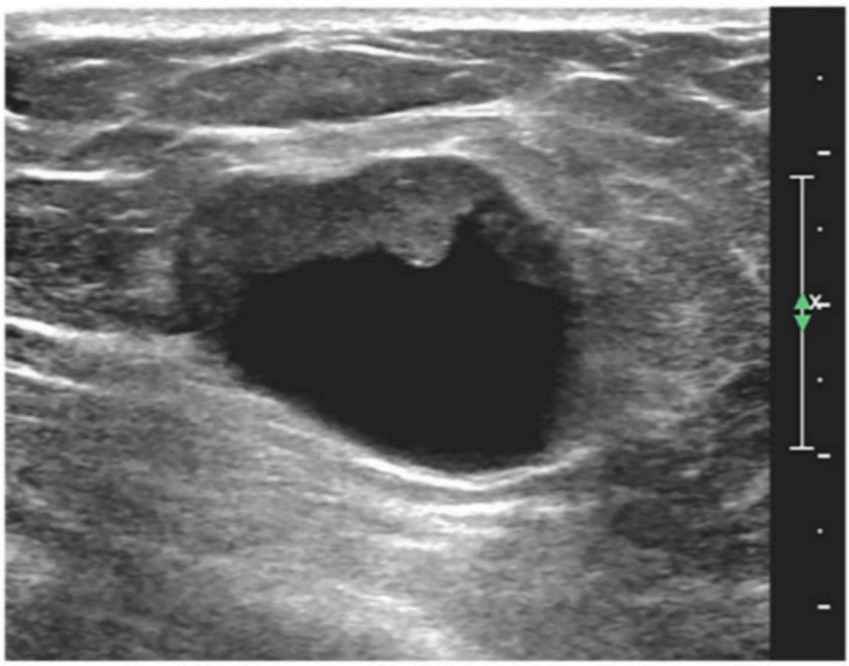

A

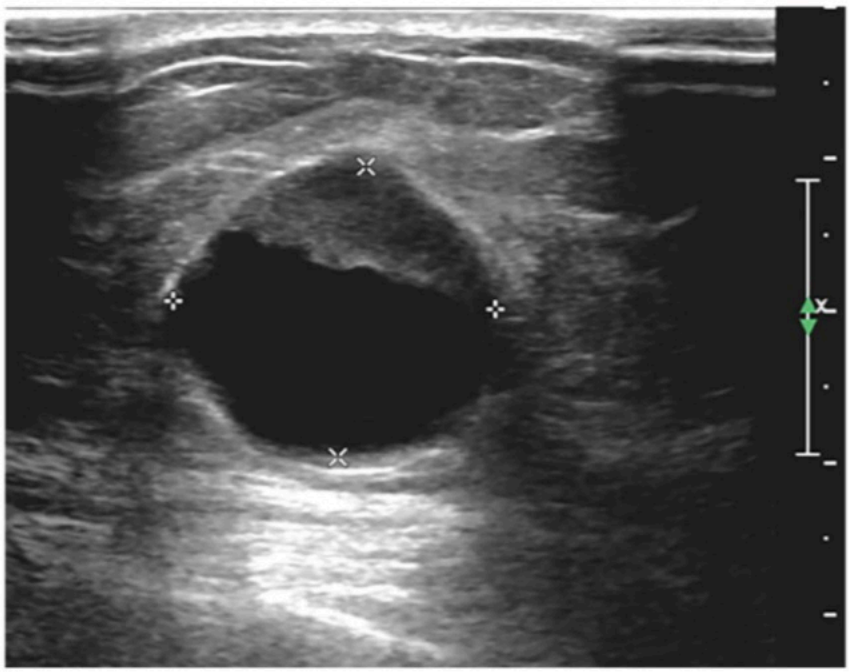

B

Figure 7 – ECHO PATTERN: MIXED SOLID AND CYSTIC. Radial (A) and antiradial (B) images of a MIXED SOLID AND CYSTIC oval, non-parallel mass with a circumscribed margin and posterior enhancement. Although the mass is predominantly cystic, it has an isoechoic solid mural mass component which is the important feature of this mass. This case demonstrates the considerable overlap in appearance of benign and malignant MIXED SOLID AND CYSTIC masses. Biopsy is necessary in almost all such cases. Pathology: Papillary carcinoma.



A

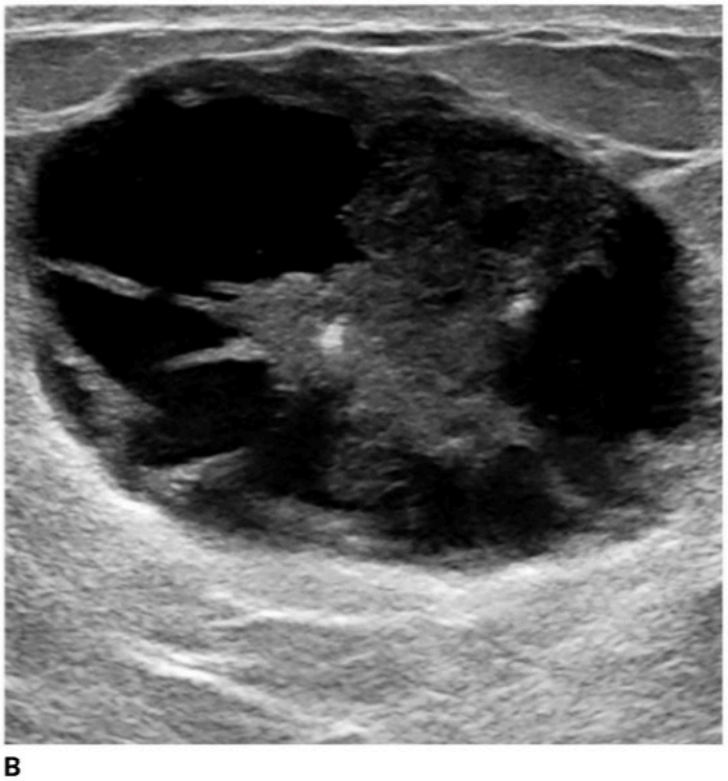

B

Figure 8 – ECHO PATTERN: MIXED SOLID AND CYSTIC. Radial (A) and antiradial (B) images of an oval, parallel MIXED SOLID AND CYSTIC mass with indistinct margin. The solid component was targeted at needle biopsy. Pathology: Grade 3 invasive ductal carcinoma.

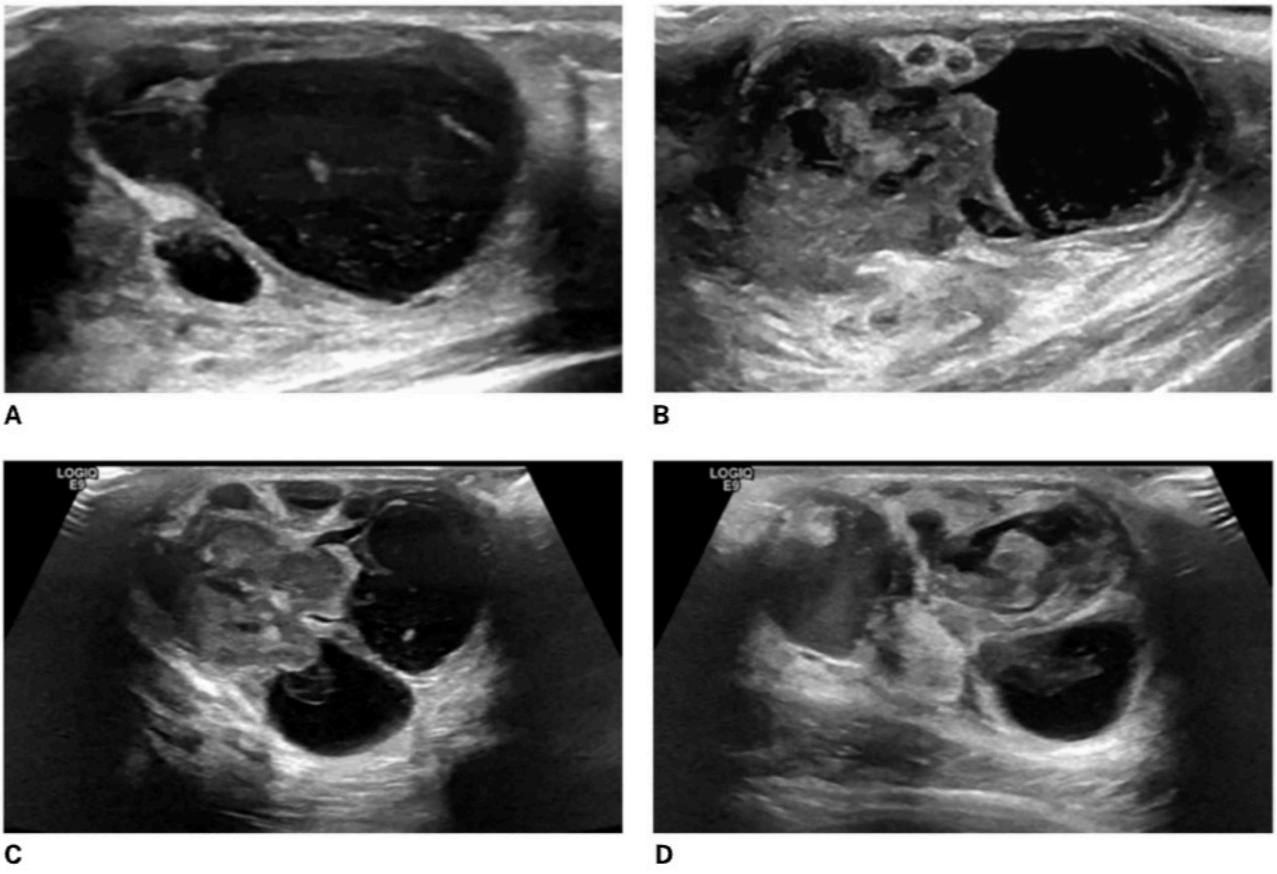

Figure 9 – ECHO PATTERN: MIXED SOLID AND CYSTIC. Radial (A, B) and antiradial (C, D) images of an oval, indistinct, MIXED SOLID AND CYSTIC mass in a 19-year-old woman. Despite the patient's young age, this mass is suspicious. Pathology: Malignant phyllodes.

B. MASSES

5. POSTERIOR FEATURES

Posterior features describe the echogenicity of the tissue immediately deep to a mass and are judged relative to the echogenicity of the adjacent tissue at the same depth. Posterior features reflect the attenuation characteristics of a mass with respect to its acoustic transmission. Because both benign and malignant solid masses can demonstrate either attenuation (shadowing) or enhancement, posterior features are mostly of secondary rather than primary predictive value.

Note that compound imaging on modern ultrasound machines tends to reduce the conspicuity of posterior features.

a. No Posterior Features

No shadowing or enhancement is present deep to the mass; the echogenicity of the area immediately behind the mass is the same as that of the adjacent tissue at the same depth.

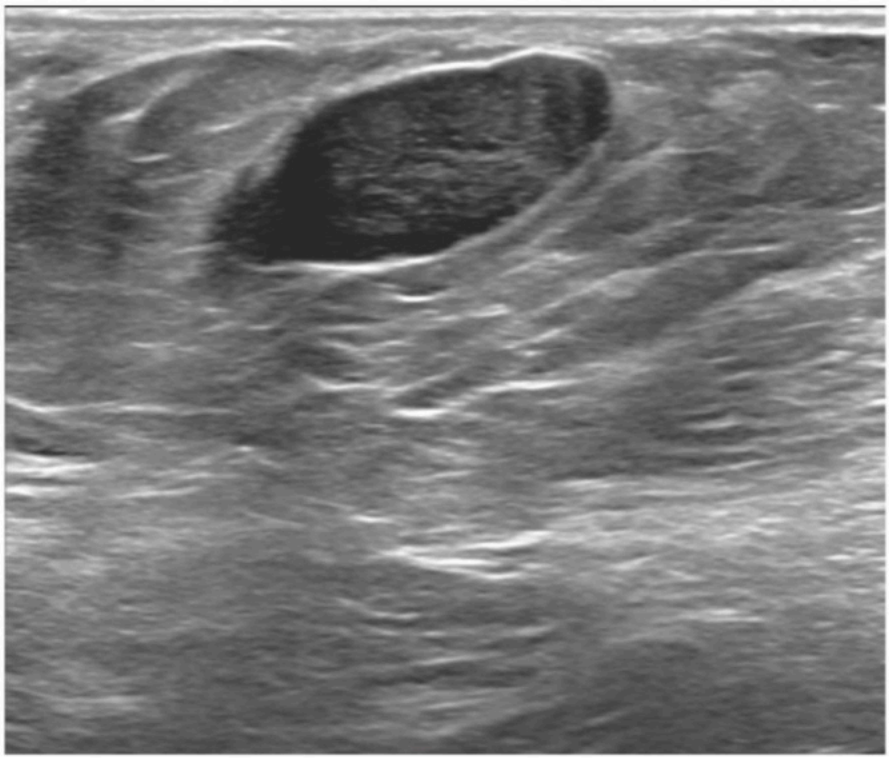

Figure 1 – POSTERIOR FEATURES: NO POSTERIOR FEATURES. Lobulated, circumscribed, hypoechoic, parallel mass, with NO POSTERIOR FEATURES. The mass was assigned a BI-RADS assessment category 3, probably benign. It remained stable in size and morphology over two years and was subsequently declared benign, BI-RADS assessment category 2. Presumptive diagnosis is fibroadenoma.

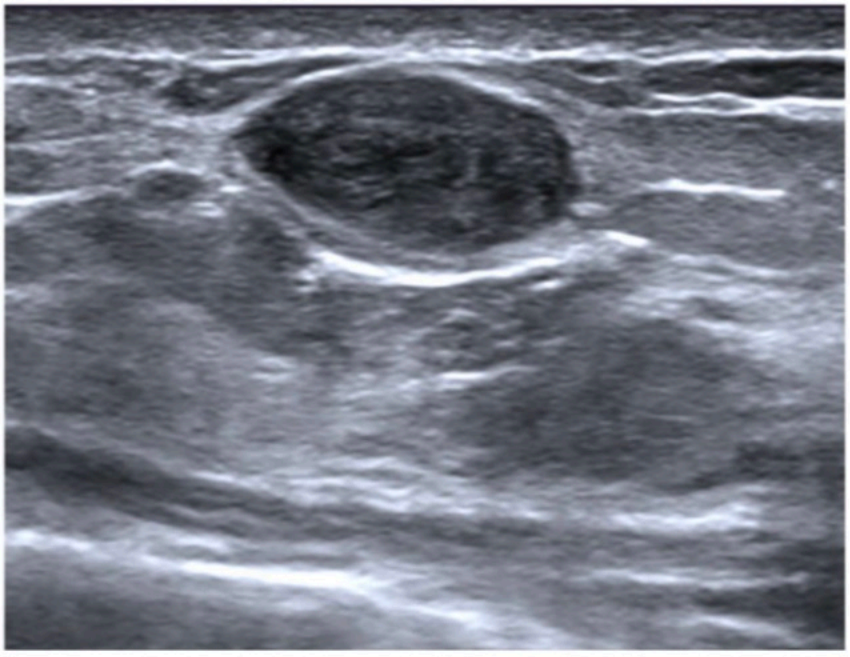

A

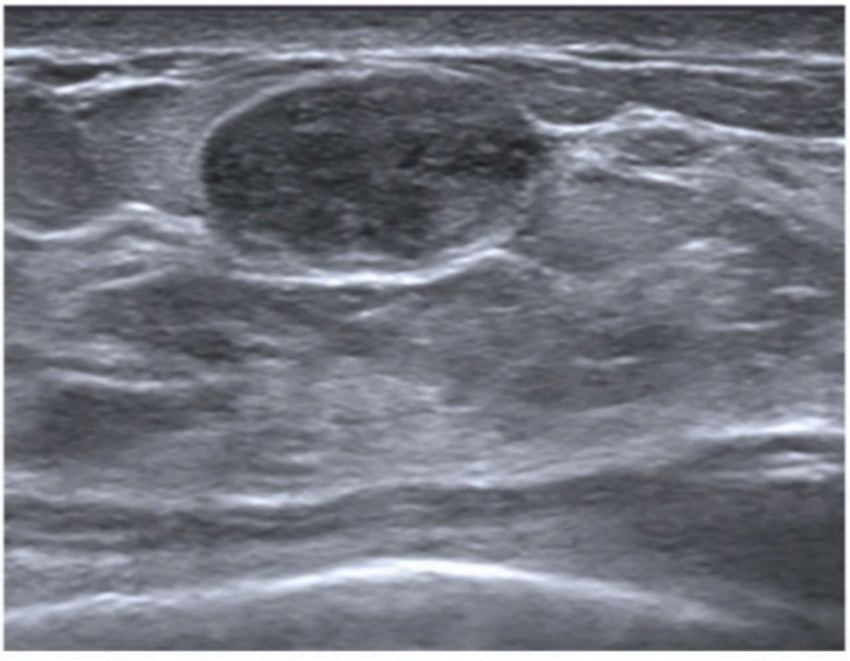

B

Figure 2 – POSTERIOR FEATURES: NO POSTERIOR FEATURES. Radial (A) and antiradial (B) images of an oval, circumscribed, parallel, hypoechoic mass, with NO POSTERIOR FEATURES. The mass was assigned a BI-RADS assessment category 3, probably benign, but it enlarged during the follow-up period, so biopsy was performed. Pathology: Fibroadenoma.

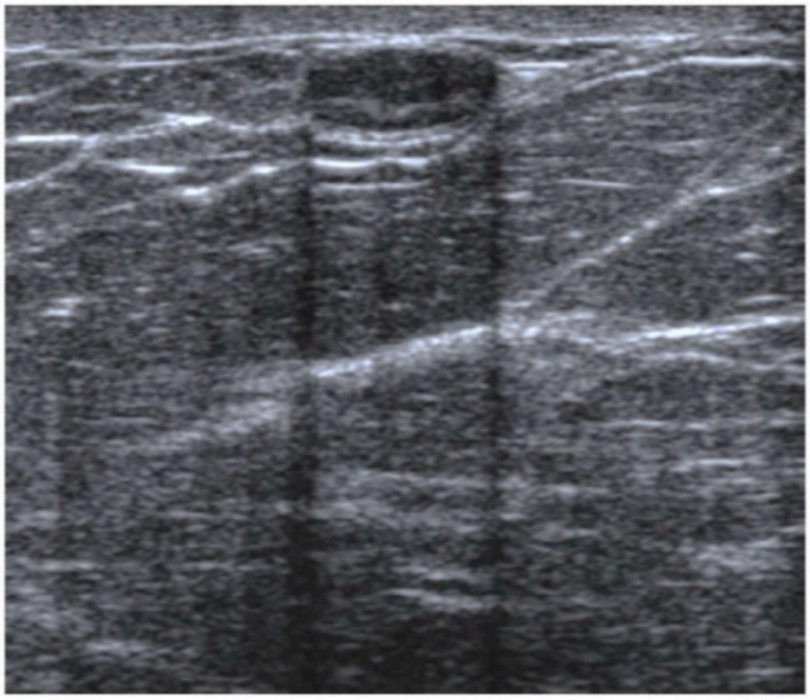

A

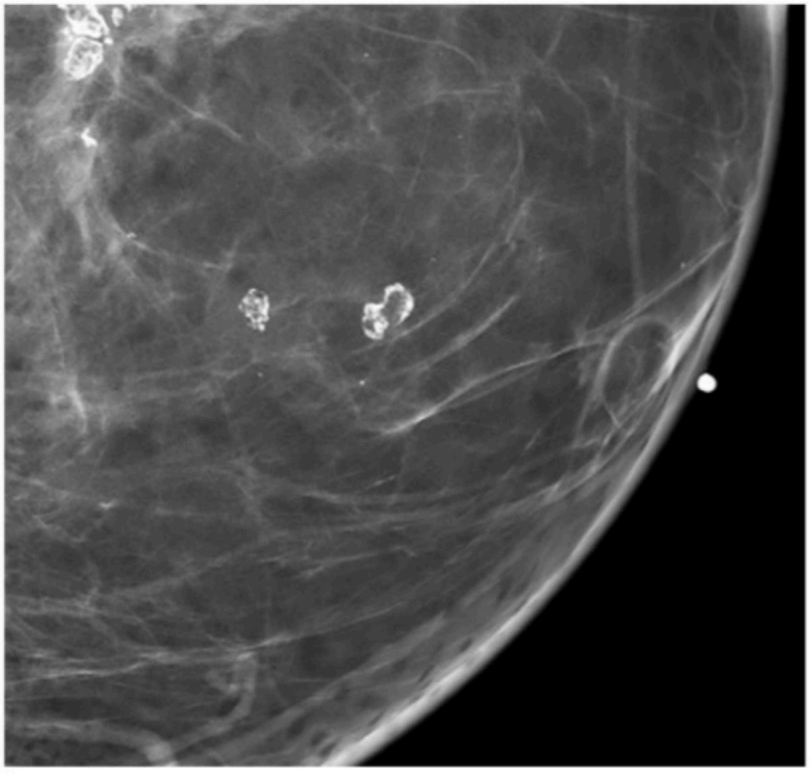

B

Figure 3 – POSTERIOR FEATURES: NO POSTERIOR FEATURES. Ultrasound image (A) of a palpable mass demonstrates an oval, circumscribed, hypoechoic mass in the subcutaneous fat with NO POSTERIOR FEATURES. The thin dark lines extending from the edges of the mass represent refractive edge shadowing and can be ignored. The tissue posterior to the mass is isoechoic to the adjacent tissue at the same depth; therefore, this mass is defined as having NO POSTERIOR FEATURES. Tangential view mammogram after placement of a radiopaque marker at the site of the mass confirms an oval fat-containing mass. Etiology: Oil cyst.



A

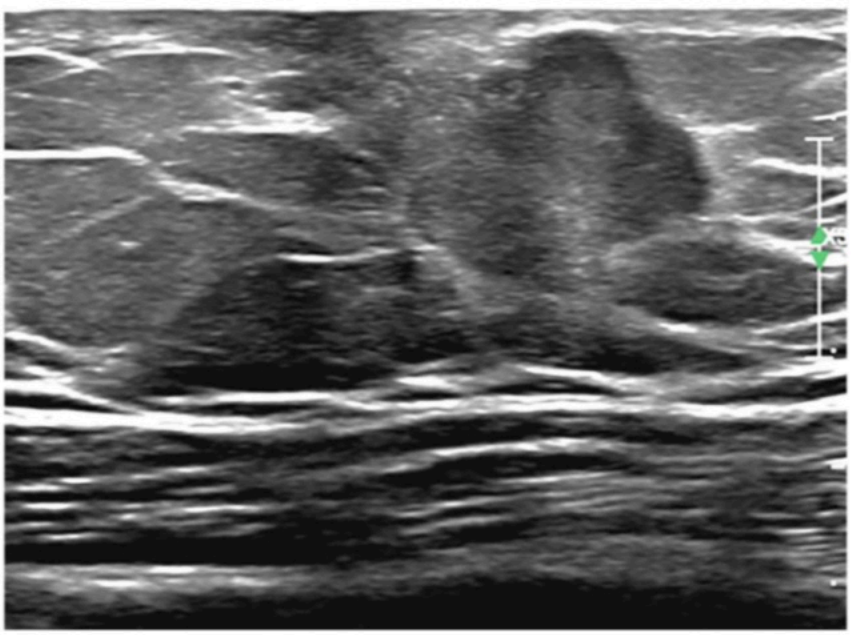

B

Figure 4 – POSTERIOR FEATURES: NO POSTERIOR FEATURES. Radial (A) and antiradial (B) images of a lobulated mass that is non-parallel in orientation with indistinct margin and NO POSTERIOR FEATURES. The mass has an echogenic rind that is most evident in the antiradial plane. This combination of features, in either male or female patient, is suggestive of malignancy. Pathology: Grade 3 invasive ductal carcinoma.

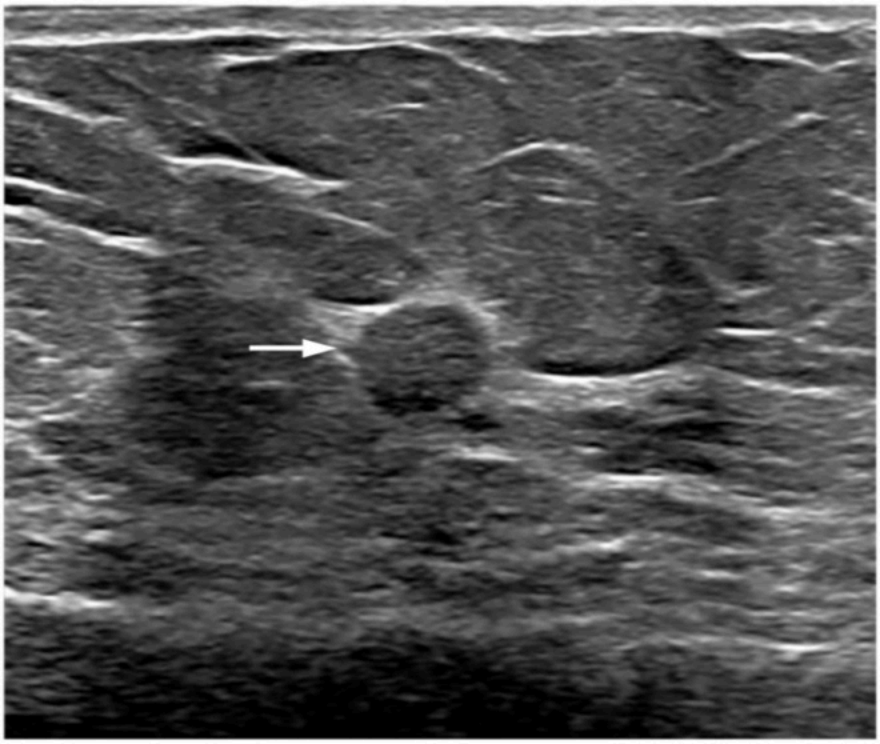

Figure 5 – POSTERIOR FEATURES: NO POSTERIOR FEATURES. Isoechoic oval mass with NO POSTERIOR FEATURES. Mass margin is indistinct but also demonstrates a single spiculation (arrow). Pathology: Grade 1 invasive ductal carcinoma and DCIS.

B. MASSES

5. POSTERIOR FEATURES

b. Enhancement

Posterior enhancement is demonstrated by an echogenic column deep to the mass, brighter than that seen in the adjacent tissue at a similar depth. Sound transmission is less attenuated passing through the mass than it is passing through the same thickness of normal tissue on either side of the mass.

Although posterior enhancement is one criterion for diagnosing a simple cyst, importantly, posterior enhancement is not a favorable predictive feature for solid masses [27]. Although some benign masses may demonstrate posterior enhancement, other solid masses, including high-grade carcinomas, may also show enhancement. Therefore, posterior enhancement is not a reassuring feature in solid masses.

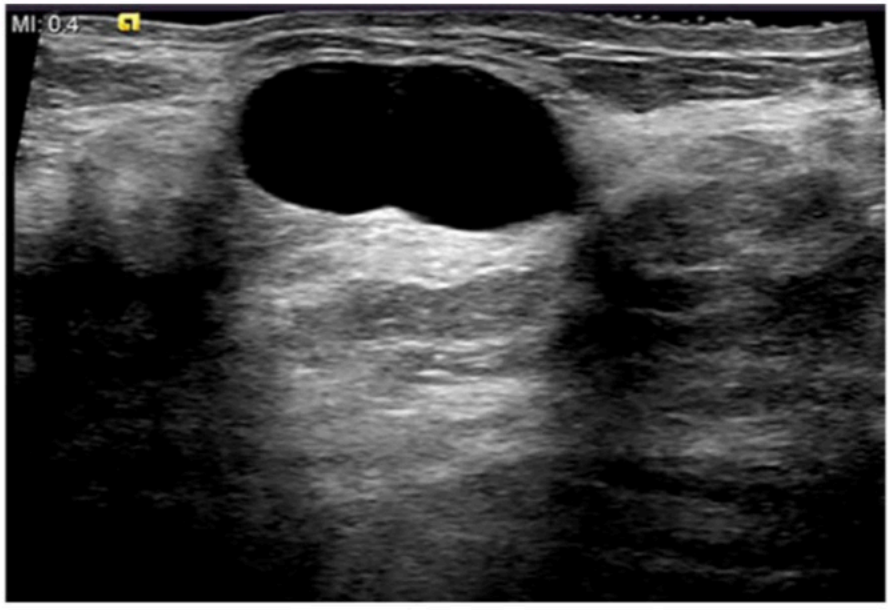

Figure 1 – POSTERIOR FEATURES: ENHANCEMENT. Anechoic circumscribed parallel mass with posterior ENHANCEMENT. This combination of features is diagnostic of a simple cyst.

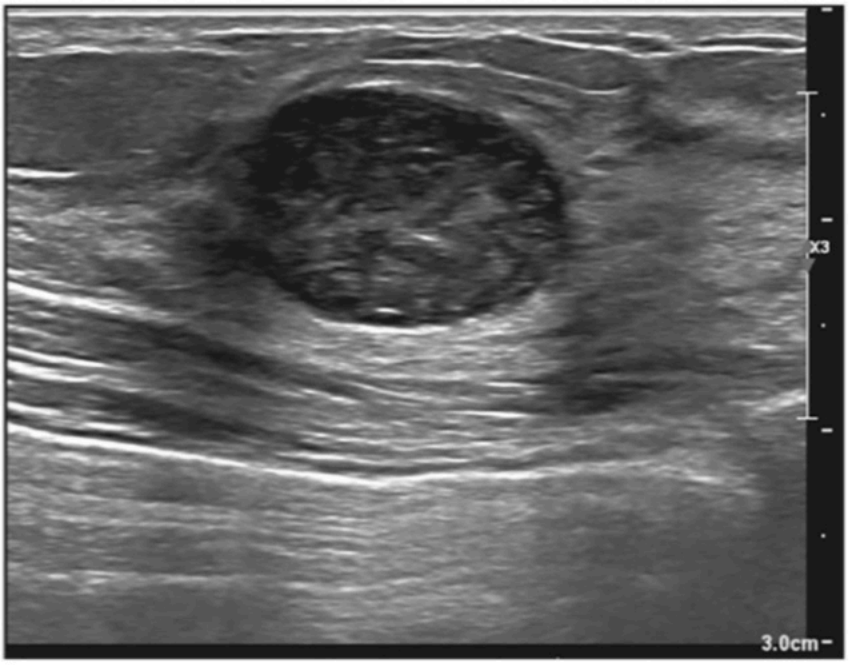

A

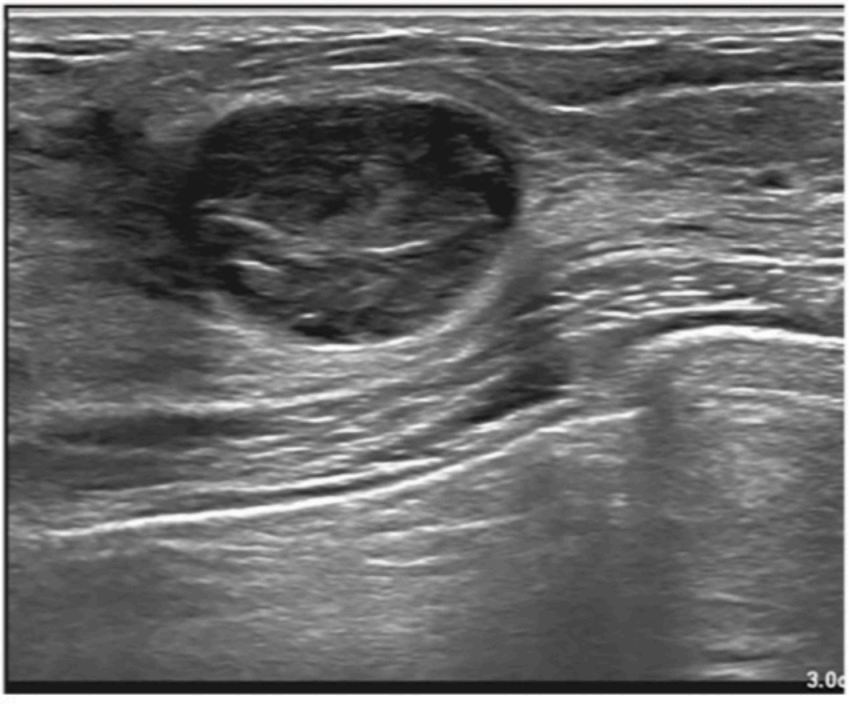

B

Figure 2 – POSTERIOR FEATURES: ENHANCEMENT. Radial (A) and antiradial (B) images of an oval, parallel, circumscribed, heterogeneous mass with posterior ENHANCEMENT. The shape, margin, and orientation of the mass suggest a benign diagnosis, and the mass was assigned a BI-RADS assessment category 3, probably benign. The patient requested biopsy due to her strong family history of breast cancer. Pathology: Fibroadenoma.

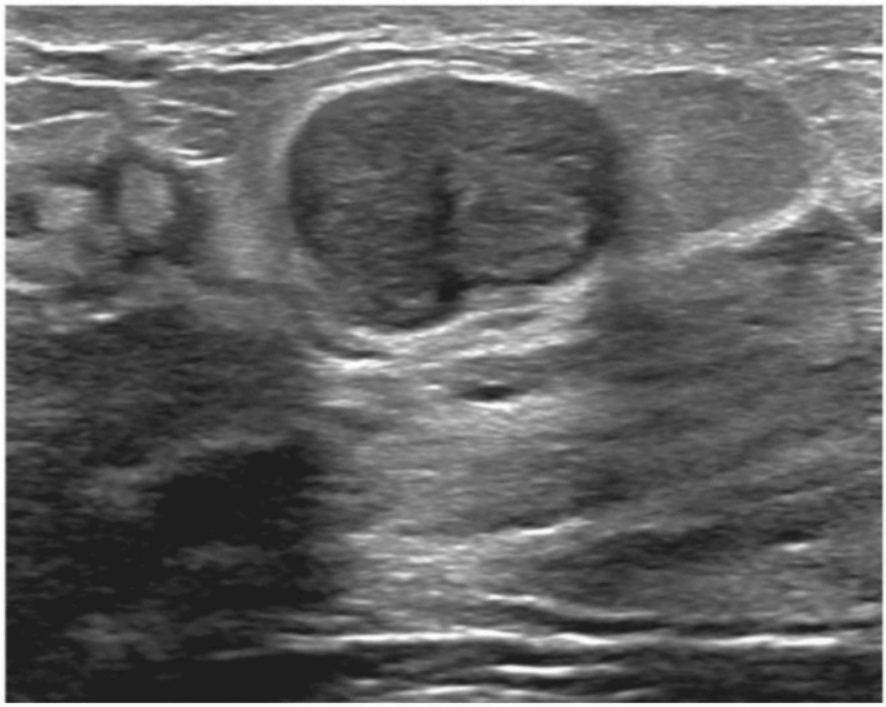

Figure 3 – POSTERIOR FEATURES: ENHANCEMENT. Lobulated, circumscribed, hypoechoic mass with posterior ENHANCEMENT. Pathology: Fibroadenoma.

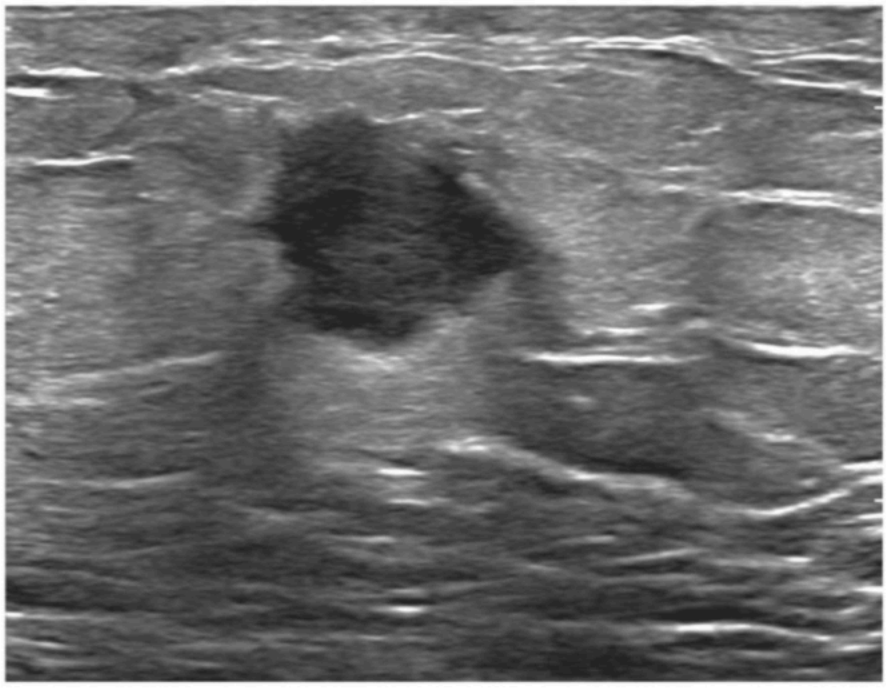

Figure 4 – POSTERIOR FEATURES: ENHANCEMENT. Male patient presents with a painful palpable lump. Ultrasound imaging demonstrates a hypoechoic mass with angular margin and posterior ENHANCEMENT. This combination of features is suspicious for malignancy, and biopsy was performed. Pathology: Abscess. The diagnosis was surprising given the lack of erythema, skin thickening or edema adjacent to the mass.

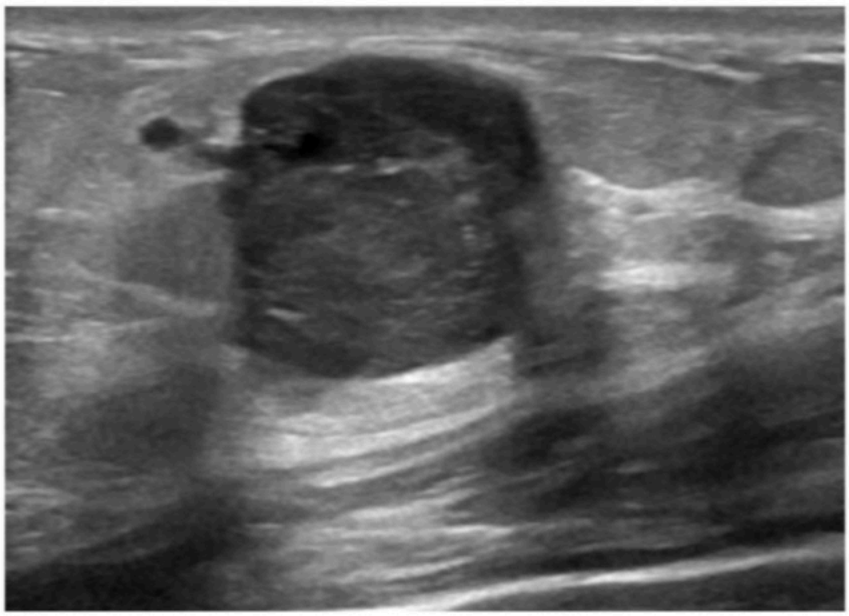

A

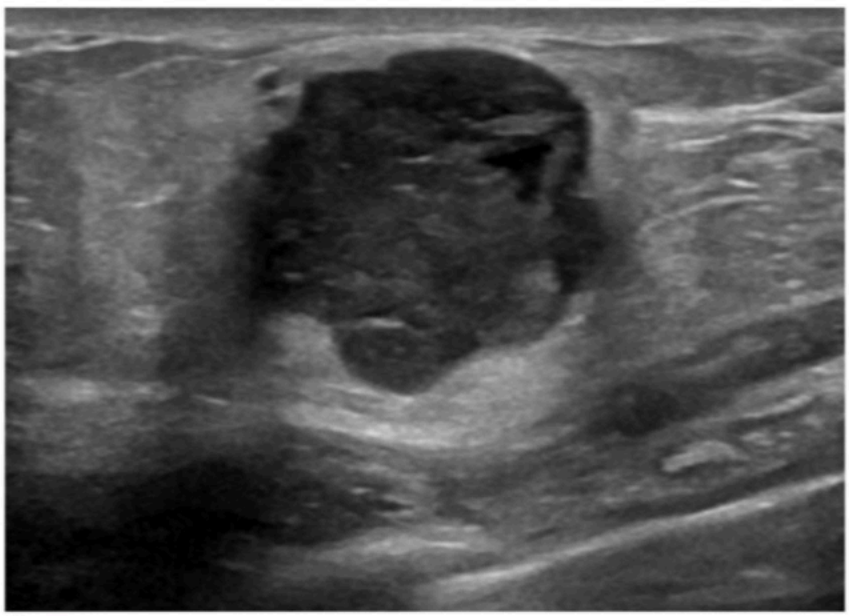

B

Figure 5 – POSTERIOR FEATURES: ENHANCEMENT. Radial (A) and antiradial (B) images of a lobulated, hypoechoic mass with indistinct margin most notably along the sides of the mass. Mass orientation is non-parallel, and the posterior feature is ENHANCEMENT. Pathology: Poorly differentiated invasive ductal carcinoma.

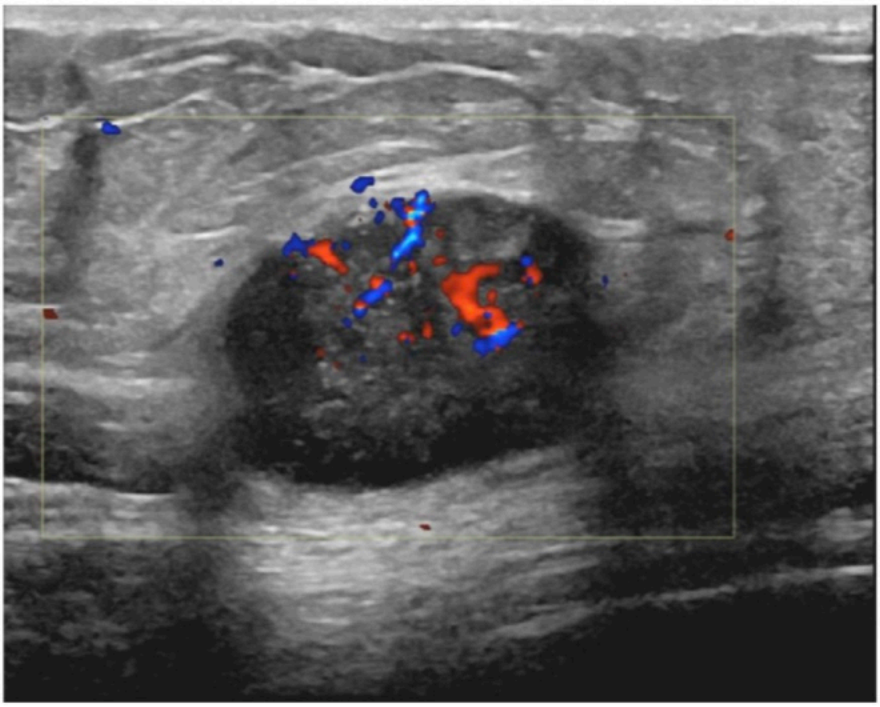

Figure 6 – POSTERIOR FEATURES: ENHANCEMENT. Oval, parallel, hypoechoic mass with an indistinct margin, internal vascularity and posterior ENHANCEMENT. Pathology: Invasive ductal carcinoma.

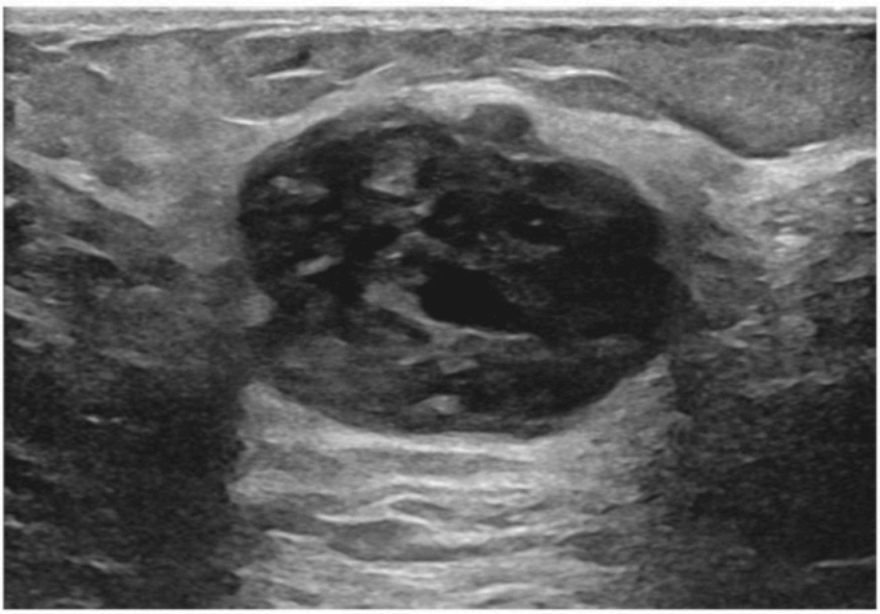

Figure 7 – POSTERIOR FEATURES: ENHANCEMENT. Lobulated, parallel, angular, heterogeneous mass demonstrates POSTERIOR ENHANCEMENT. Pathology: Invasive ductal carcinoma.

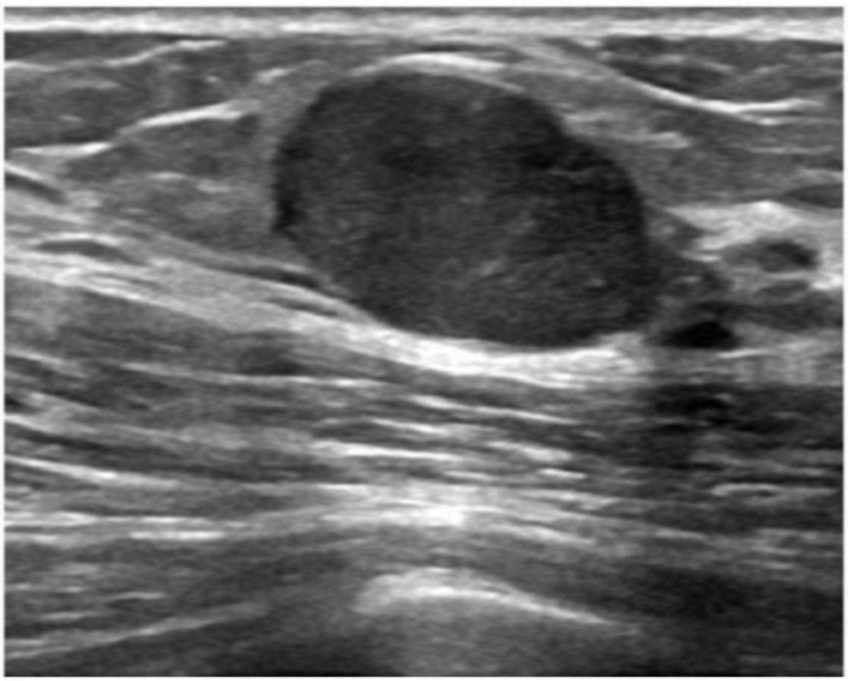

A

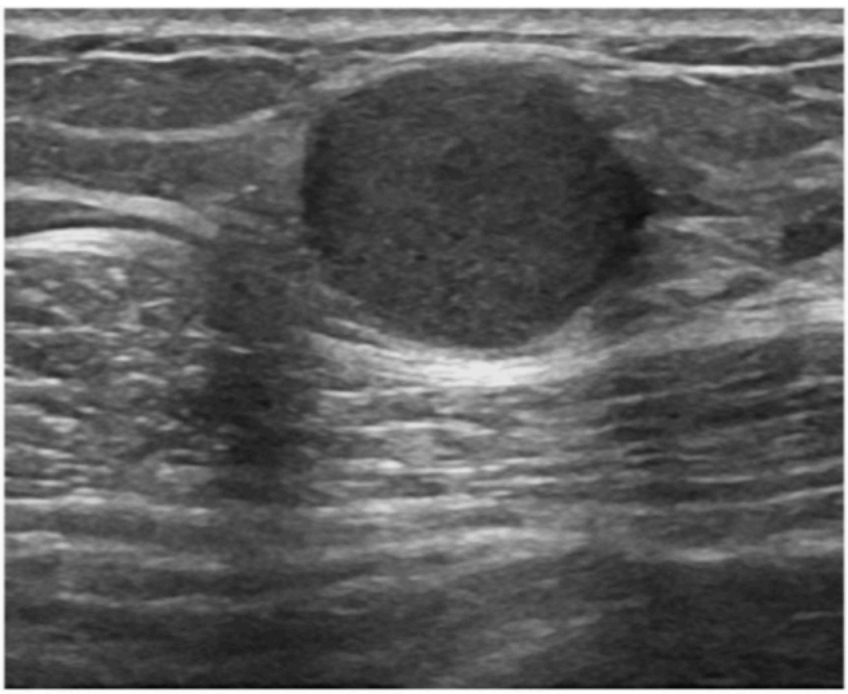

B

Figure 8 – POSTERIOR FEATURES: ENHANCEMENT. Radial (A) and antiradial (B) images of an oval, hypoechoic, circumscribed mass that demonstrates posterior ENHANCEMENT. Given the biopsy-proven diagnosis of invasive ductal carcinoma, this mass is a good example that ENHANCEMENT is not a reassuring or predictive sign when associated with a solid mass. Pathology: Invasive ductal carcinoma, high grade.

B. MASSES

5. POSTERIOR FEATURES

c. Shadowing

Shadowing is caused by attenuation of the ultrasound beam as it passes through the mass, producing a dark column deep to the mass. The shadowing column is darker than the tissue at the same depth to either side of the mass.

Although commonly considered a suspicious feature, shadowing may be associated with both benign and malignant masses. Some malignancies will present as only a band of shadowing with no evident mass.

Previous versions of the BI-RADS Atlas included the posterior feature COMBINED to describe shadowing behind part of a mass and either enhancement or no posterior feature behind the remainder of the mass. The term COMBINED has now been removed because any posterior shadowing, even shadowing behind only part of a mass, is a significant finding that supersedes any other posterior feature. If any part of the mass shadows (other than refractive edge shadowing), then the posterior feature is described as SHADOWING.

A thin line of shadowing may be visible only behind the lateral edges of a curved mass due to a combination of absorption and refraction of the sound beam. This thin refractive edge shadowing is of no significance and should be distinguished from shadowing deep to the body of the mass [28, 29].

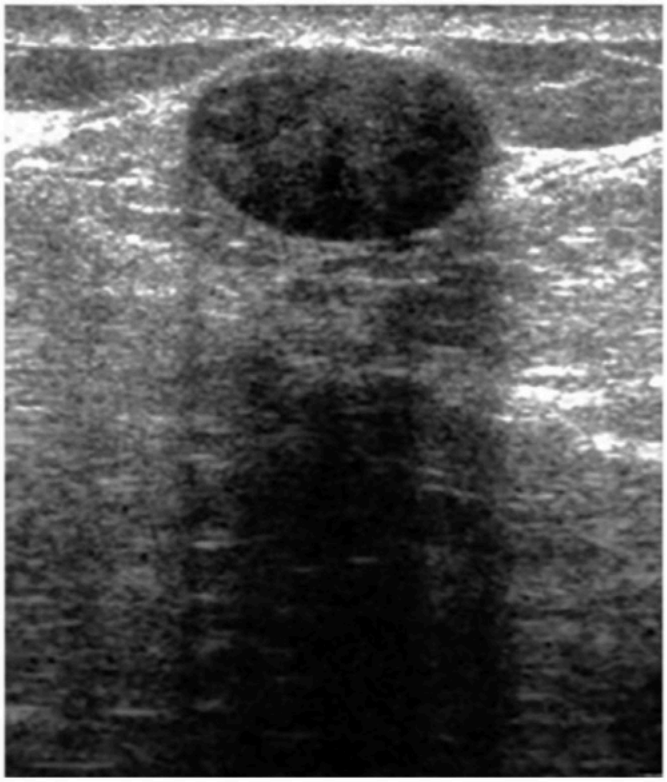

Figure 1 – POSTERIOR FEATURES: SHADOWING. Radial ultrasound image of an oval, circumscribed, hypoechoic mass with parallel orientation and posterior SHADOWING. Pathology: Fibroadenoma.

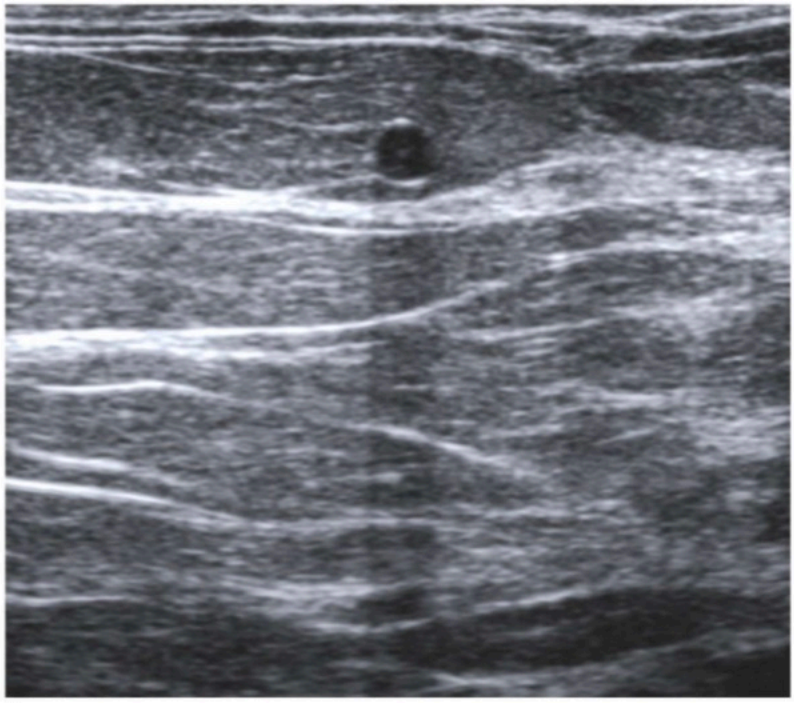

A

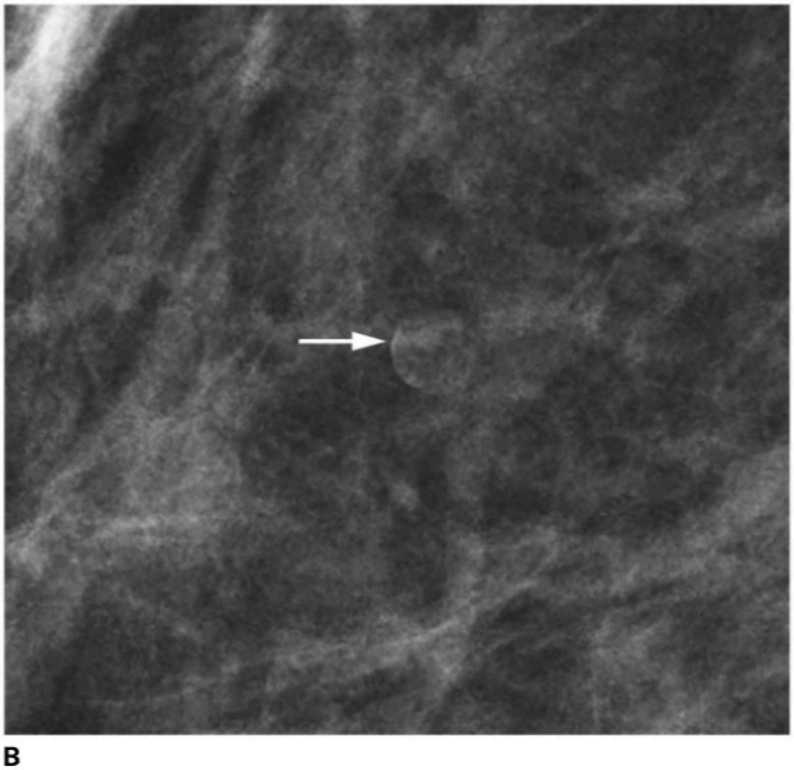

B

Figure 2 – POSTERIOR FEATURES: SHADOWING. Ultrasound image (A) of a round, circumscribed, anechoic mass with posterior SHADOWING. The shadowing is remarkably sharply delineated which is a common feature of some oil cysts. Close inspection of the mammogram (B) confirms a small, round, circumscribed fat-containing mass with rim calcifications diagnostic of an oil cyst (arrow). Simple and complicated cysts will almost never produce posterior shadowing. If shadowing is seen in association with an apparent cyst, and the cyst cannot be confirmed as an oil cyst on mammography, aspiration or tissue sampling is commonly indicated.

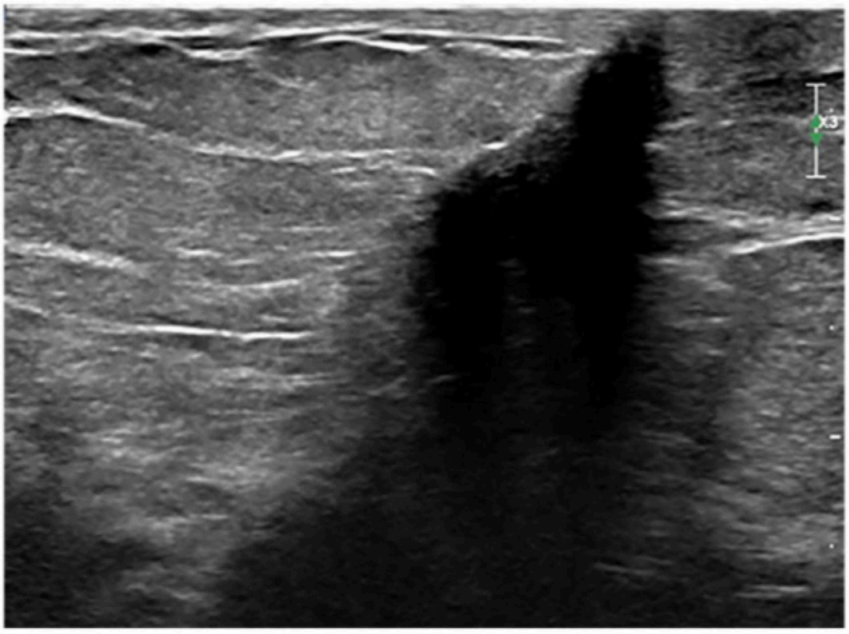

A

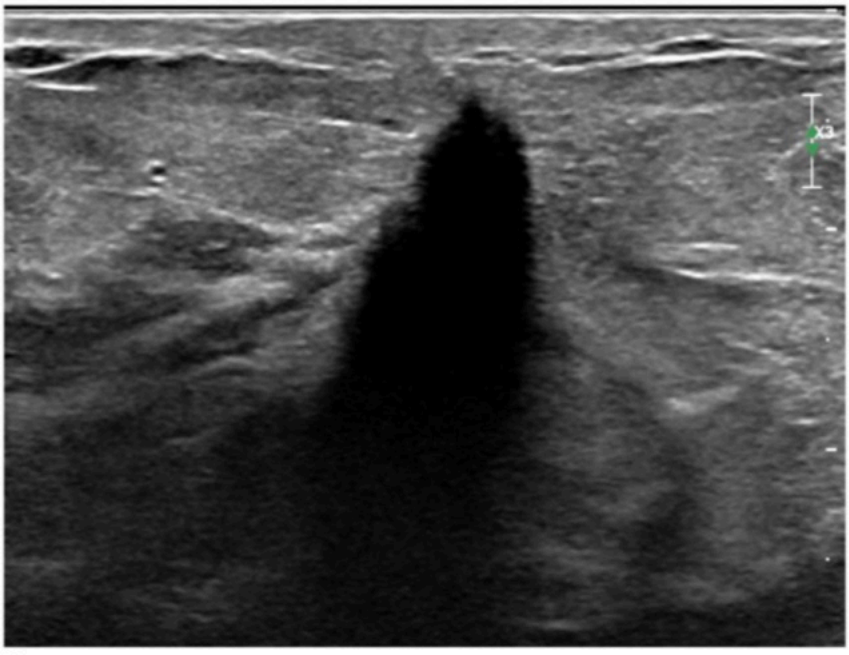

B

Figure 3 – POSTERIOR FEATURES: SHADOWING. Radial (A) and antiradial (B) images of an irregular, non-parallel, anechoic mass with posterior SHADOWING. In this case, the anechogenicity is the result of complete attenuation of the acoustic beam by the mass, rendering any internal echoes within the mass undetectable. This mass was at the site of prior lumpectomy. Although biopsy is typically not necessary to confidently diagnose a surgical scar, this mass enlarged substantially over a short period of time, so biopsy was performed. Pathology: Dense fibrosis with minimal chronic inflammation, consistent with scar.



Figure 4 – POSTERIOR FEATURES: SHADOWING. Irregular, hypoechoic mass with spiculated margin and posterior SHADOWING. Pathology: Fibromatosis.

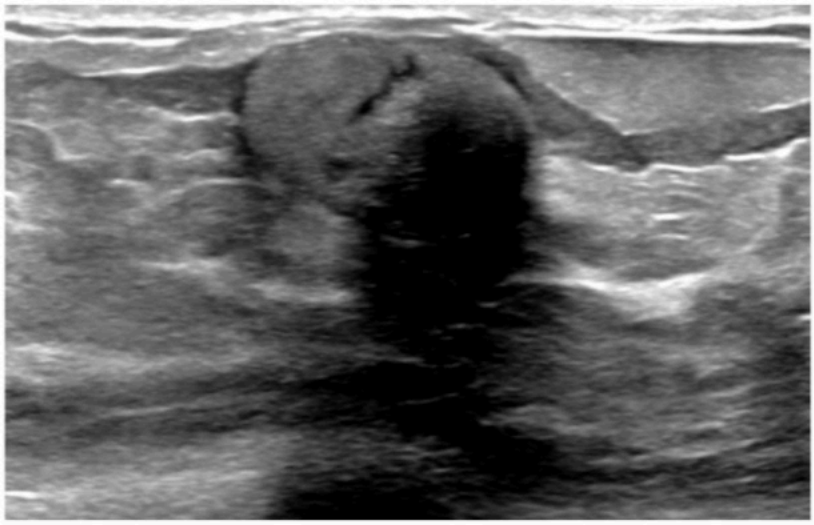

A

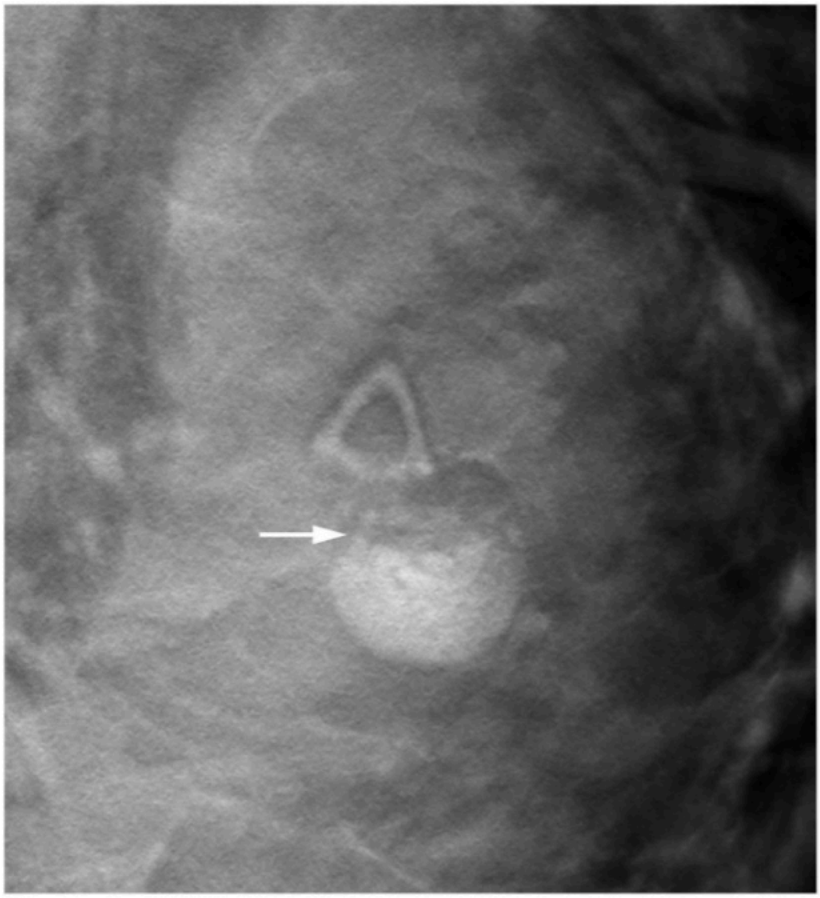

B

Figure 5 – POSTERIOR FEATURES: SHADOWING. Lactating patient presented with a palpable lump. Ultrasound image (A) demonstrates an oval, circumscribed, parallel mass. Posterior features are a combination of no posterior features and SHADOWING. Therefore, the mass is reported as SHADOWING. Given the appearance and patient history, a single ML view mammogram (B) was performed which confirmed a fat-fluid level (arrow). This combination of features and history is diagnostic of a galactocele.

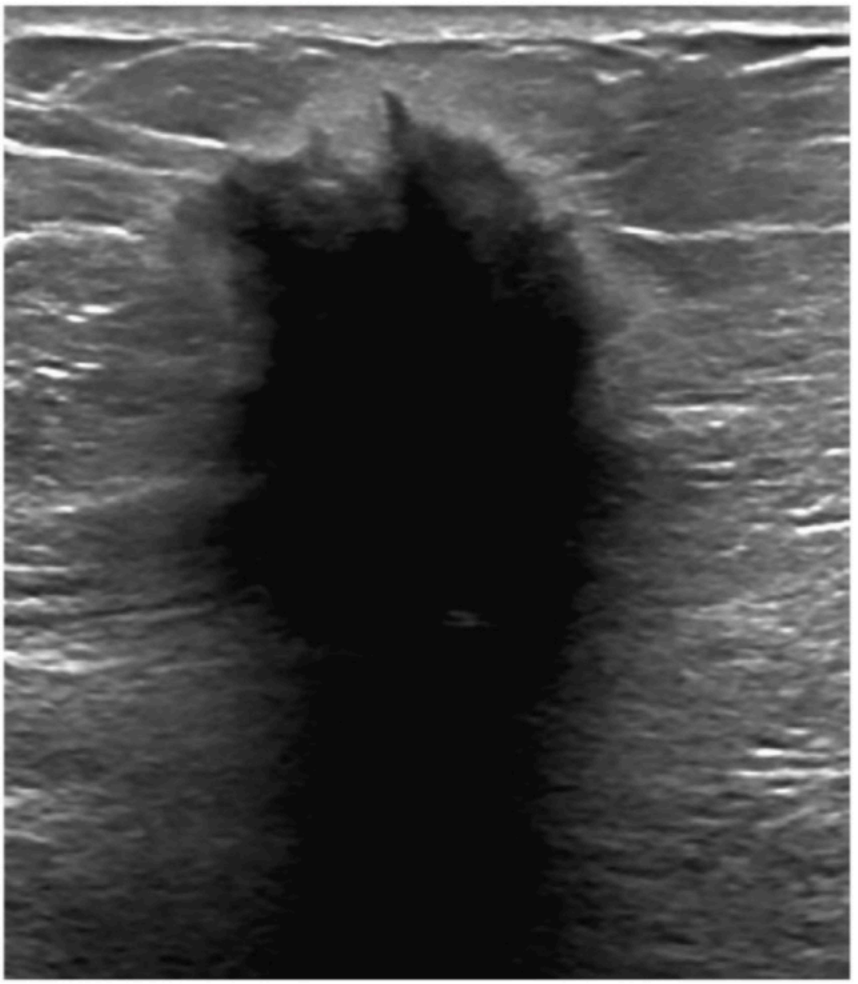

Figure 6 – POSTERIOR FEATURES: SHADOWING. Hypoechoic, irregular mass with spiculated margins, echogenic rind, and SHADOWING. This mass was assigned BI-RADS assessment category 5, highly suggestive of malignancy. Pathology: Invasive ductal carcinoma.

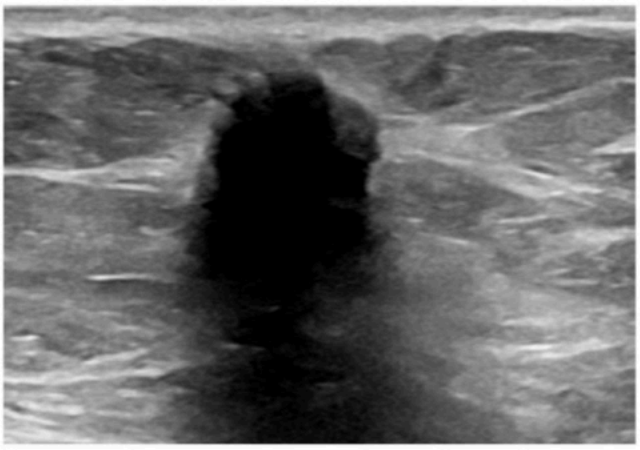

A

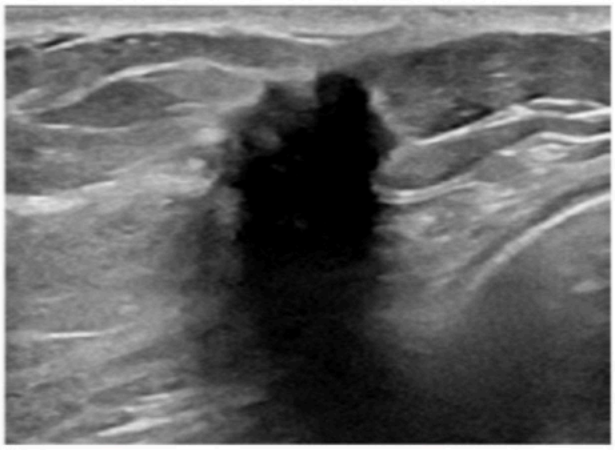

B

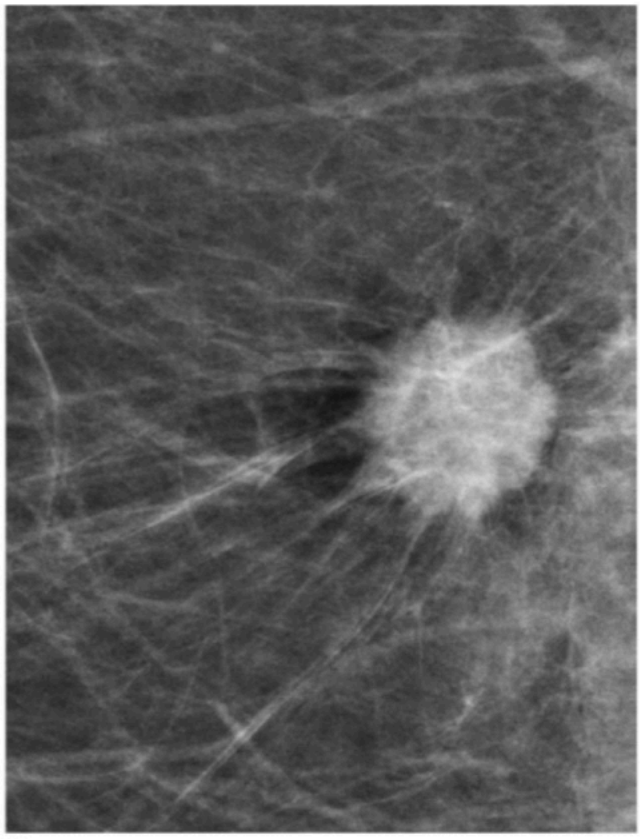

C

Figure 7 – POSTERIOR FEATURES: SHADOWING. Radial (A) and antiradial (B) ultrasound images of a hypoechoic, spiculated, irregular mass with an echogenic rind, and SHADOWING. These images correspond to the mammographic image (C) of an irregular spiculated mass. This mass was assigned BIRADS assessment category 5, highly suggestive of malignancy. Pathology: Invasive ductal carcinoma.

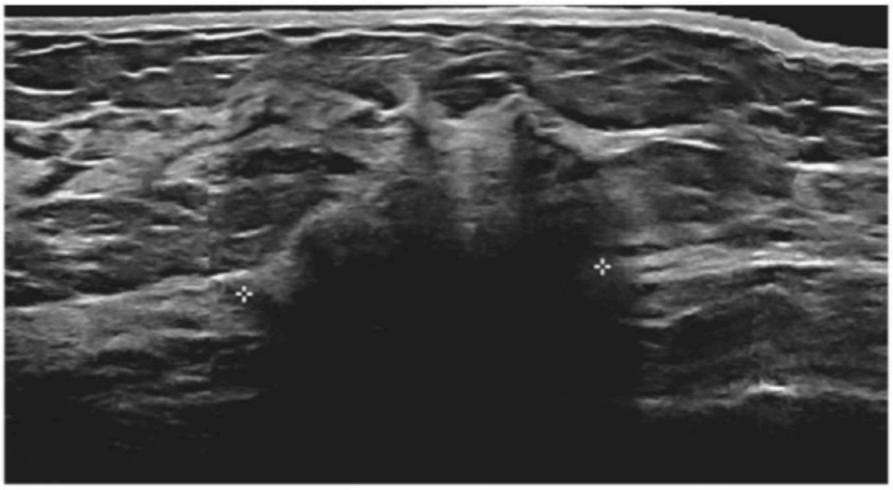

Figure 8 – POSTERIOR FEATURES: SHADOWING. Irregular, parallel mass with indistinct margin and posterior SHADOWING. Diagnosis: Invasive lobular carcinoma.

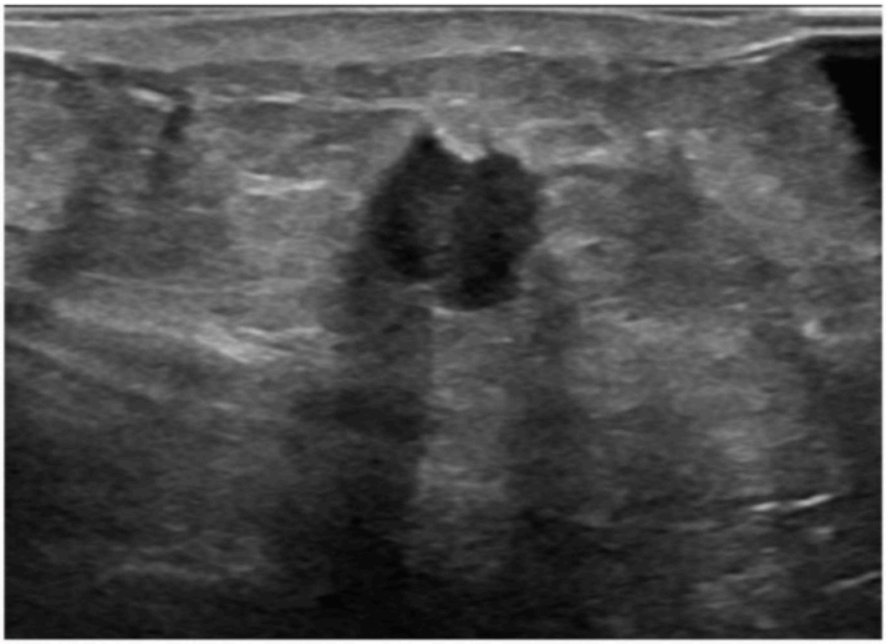

Figure 9 – POSTERIOR FEATURES: SHADOWING. Irregular, hypoechoic, non-parallel mass with angular margination. Although half of the mass has no posterior features, the other half demonstrates SHADOWING. Therefore, the posterior feature of the mass is reported as SHADOWING. Diagnosis: Invasive ductal carcinoma.

C. NON-MASS LESIONS

Definition

With advances in equipment capabilities and knowledge of breast ultrasonography, there is increasing awareness and identification of sonographic findings and abnormalities that do not meet the criteria of a mass. A mass is a space-occupying lesion seen in at least 2 different planes. It is important to recognize that some important sonographic findings do not meet the criteria for, and may lack conspicuity of, a mass but may still represent malignancy.

The concept of such a sonographic lesion was introduced by Uematsu et al in 2012 [30], and they classified such findings as either ductal hypoechoic areas or non-ductal hypoechoic areas. Since that time, various terminologies have been used, including non-mass like lesion, non-mass lesion, non-mass image-forming lesion, ductal changes, duct-like structures, and focal shadowing [31].

New to this version, we incorporate this concept and use the term non-mass lesion. A non-mass lesion is a discrete finding that can be identified as distinctly different from normal tissue, is seen in 3 dimensions but lacks the discrete margination of a mass and cannot be assigned a specific shape. It is often subtle and may be detected only because the background tissue is disrupted. It may appear very different in different planes, and it may be visualized primarily in one plane only. Because it lacks a definitive shape or margin, coupled with the fact that it is often seen primarily in one plane only, size may be difficult to determine. It is important to note that a non-mass lesion is a distinct finding and that heterogeneous breast tissue alone does not constitute a non-mass lesion.

Similar to a mass, a non-mass lesion may have associated features that contribute to accurate detection and differentiate a real finding from normal heterogeneous breast tissue. An echogenic rind may accompany a non-mass lesion. Hypervascularity at Doppler imaging may also be seen. While neither secondary finding is specific for malignancy, their presence may help distinguish normal tissue (i.e., heterogeneous background tissue mimicking a non-mass lesion) from a non-mass lesion. Of the various sonographic features of a non-mass lesion, the single most predictive of malignancy is segmental distribution [31].

Classification/Lexicon

1. Distribution
    a. Regional: large geographic area that does not conform to a linear or segmental distribution
    b. Focal: small, confined area
    c. Linear: longitudinal area arrayed in a line that may conform to a ductal distribution
    d. Segmental: triangular area with base toward the pectoralis muscle and apex toward that nipple that conforms to a segment of the breast
2. Echo pattern
    a. Hyperechoic: echogenicity is increased relative to fat, often equal to fibroglandular tissue — this presentation of a non-mass lesion is expected to be unusual
    b. Heterogeneous: echogenicity that is a mixture of echogenic patterns
    c. Hypoechoic: echogenicity that is decreased relative to fat; darker gray than fat but not black

3. Posterior features

    a. No posterior features: no shadowing or enhancement posterior to the lesion

    b. Enhancement: tissue posterior to the lesion appears brighter and hyperechoic compared to the tissue at the same depth on either side of the lesion — this presentation of a non-mass lesion is expected to be unusual

    c. Shadowing: tissue posterior to the lesion appears darker and hypoechoic compared to the tissue at the same depth on either side of the lesion

Note that shape/margin are not applicable as shape/margin are not characterizable in a non-mass lesion

Associated Findings (imaging variables)

Studies have reported the following associated sonographic features of a non-mass lesion as being predictive of malignancy:

Architectural distortion

Posterior shadowing

Hypervascularity

Duct extension or abnormal ductal changes

Calcifications

One single study of 715 patients reported the presence of small cysts as being associated with benignity in a non-mass lesion [32].

Imaging Correlation

For non-mass lesions, the presence of an imaging correlate at mammography, CEM, or MRI is more significant and predictive than any morphologic feature at ultrasound. In particular, correlation with architectural distortion, asymmetry, or suspicious calcifications at mammography, or abnormal enhancement at CEM or MRI, increases the probability of malignancy.

Clinical Correlation (clinical variables)

Similar to imaging correlation, the probability of malignancy increases in a non-mass lesion in the setting of a clinical symptom. Park et al [32] reported that 12.5% of the malignant non-mass lesions in their study were associated with nipple discharge, and 9.1% with palpability. There was no statistically significant correlation in malignant non-mass lesions with patient age or mammographic density.

Histopathology

Published literature reports that 10% to 54% of non-mass lesions are malignant [33]. A true non-mass lesion should be biopsied because the PPV is greater than 2%, especially when there is an imaging correlate on other modalities and/or an associated clinical symptom. Of the malignancies, DCIS and invasive lobular carcinoma are commonly encountered. Of the specific ductal subtypes, tubular or papillary features have been reported [34]. Commonly reported benign etiologies include: fibrocystic change, stromal fibrosis, fibroadenomatoid hyperplasia, sclerosing adenosis, radial scar, complex sclerosing lesion, granulomatous mastitis, intraductal papilloma, abscess, chronic mastitis, duct ectasia, atypical ductal hyperplasia, diabetic mastopathy, and lymphangioma.

Adjunctive Imaging Evaluation

Early studies show potential of elastography [35] and contrast-enhanced ultrasound [36] in differentiating between benign and malignant non-mass lesions detected at ultrasound.

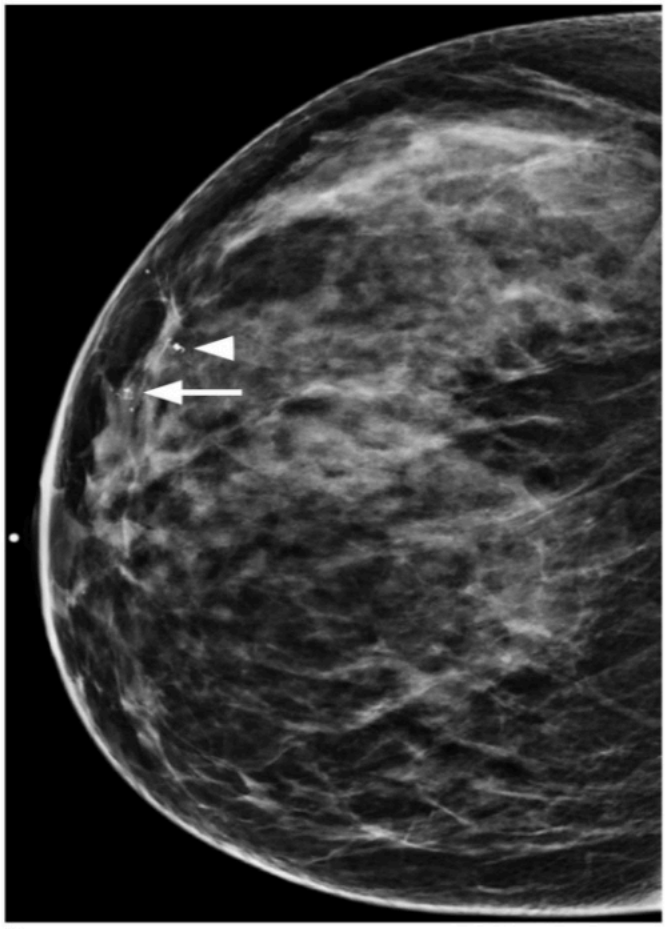

A

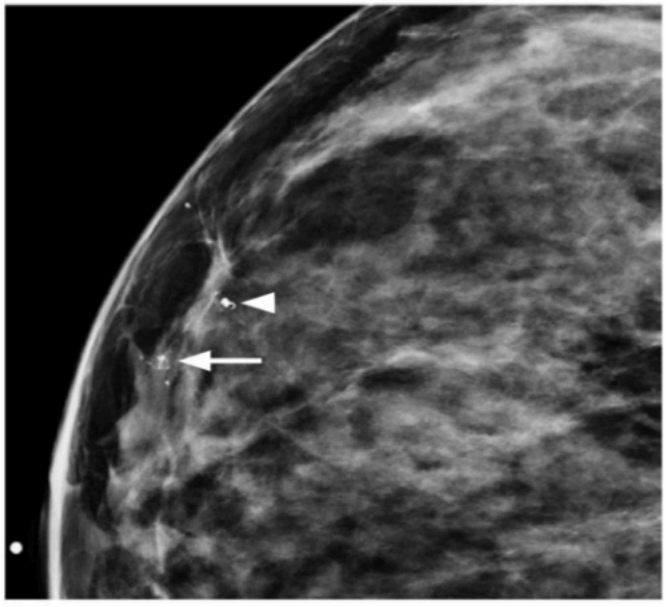

B

Figure 1 – NON-MASS LESION. Right CC mammogram (A) and close-up (B) show focal asymmetry with calcifications (arrow). A biopsy clip is noted (arrowhead).



C



D

Figure 1 – *(Continued)* NON-MASS LESION. Extended field-of-view (EFOV) US image (C) in the longitudinal plane shows segmental hypoechoic non-mass lesion with ductal extension (arrowhead) and echogenic foci representing calcifications (arrow). The EFOV image demonstrates the infiltrative features of this non-mass lesion. Transverse US image (D) shows the hypoechoic non-mass lesion with ductal extension (arrowhead) and echogenic foci representing calcifications (arrow). These US findings correlate with the mammographic focal asymmetry with calcifications. Pathology: Invasive ductal carcinoma and DCIS.

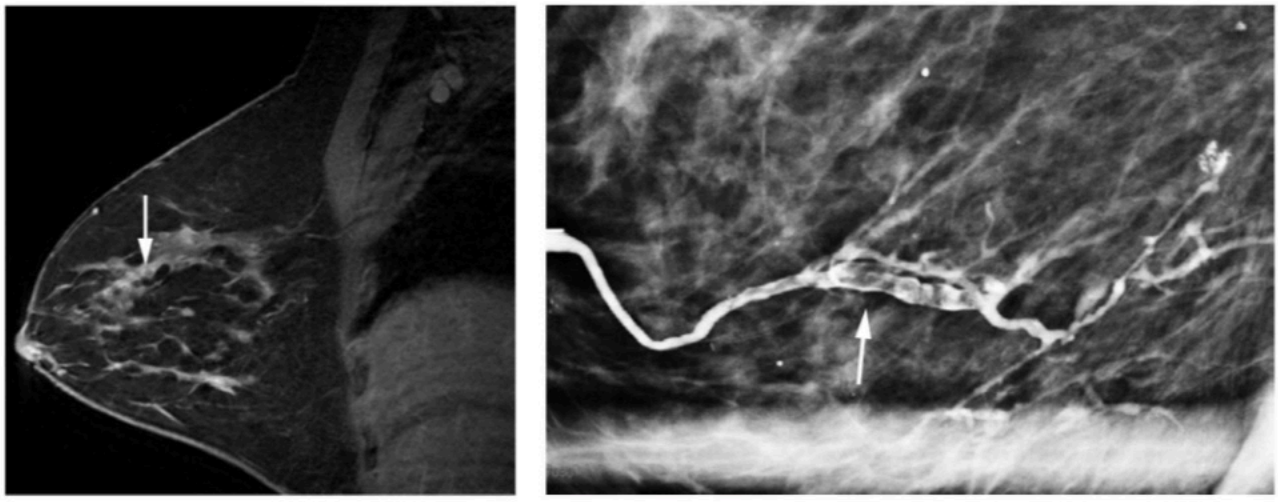

A B

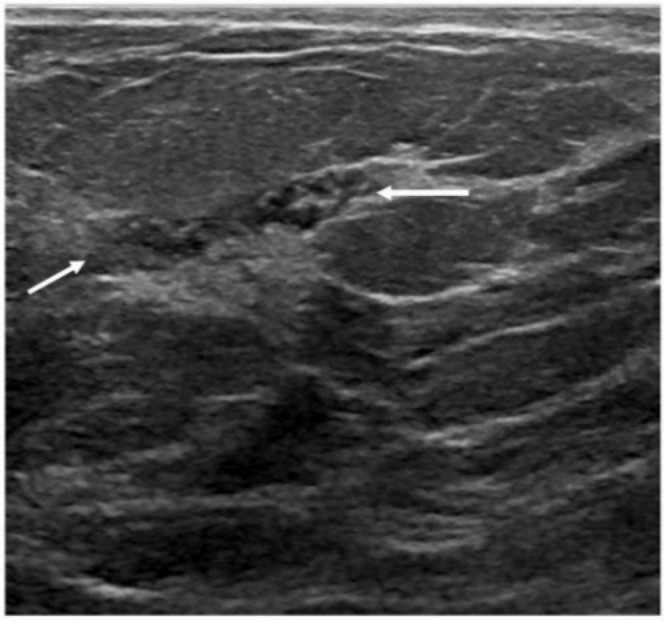

C

Figure 2 – NON-MASS LESION. Sagittal contrast-enhanced MR image of the right breast (A) in patient with nipple discharge shows a subtle linear non-mass enhancement (arrow). Right ML ductogram image (B) of corresponding region shows intraductal filling defects (arrow). US image of the right breast (C) shows a linear non-mass lesion (arrows) with heterogeneous echogenicity, correlating with the MRI and ductogram findings. Pathology: DCIS.

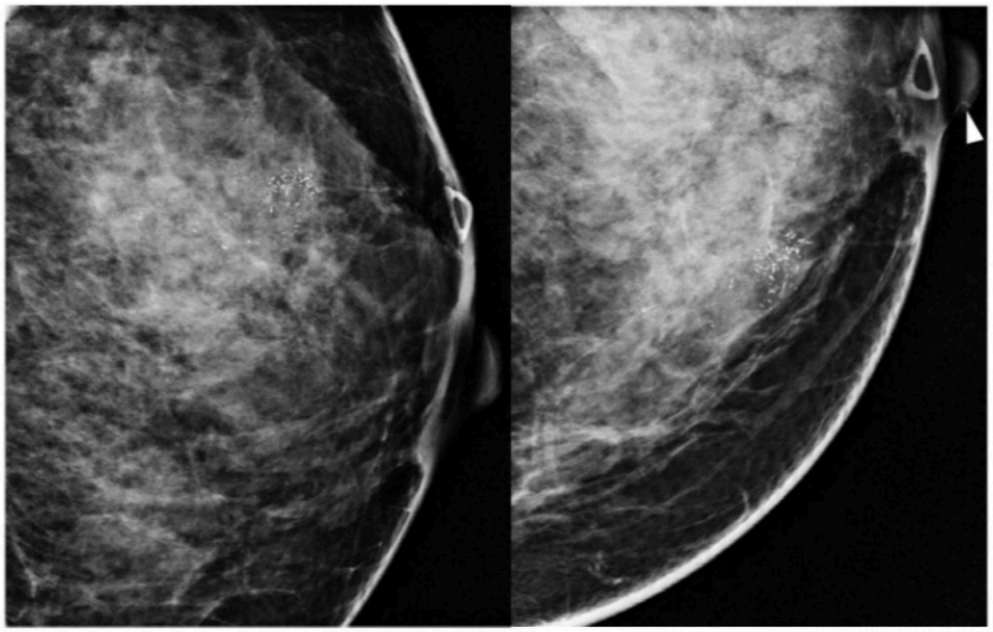

A



B

Figure 3 – NON-MASS LESION. Detail views of mammograms (A) in a patient presenting with palpable finding in left upper inner breast. Segmental fine pleomorphic calcifications are identified, with calcifications extending to the nipple (arrowhead). EFOV US image (B) shows heterogeneous segmental non-mass lesion with nipple involvement (arrow), correlating with the mammographic finding.

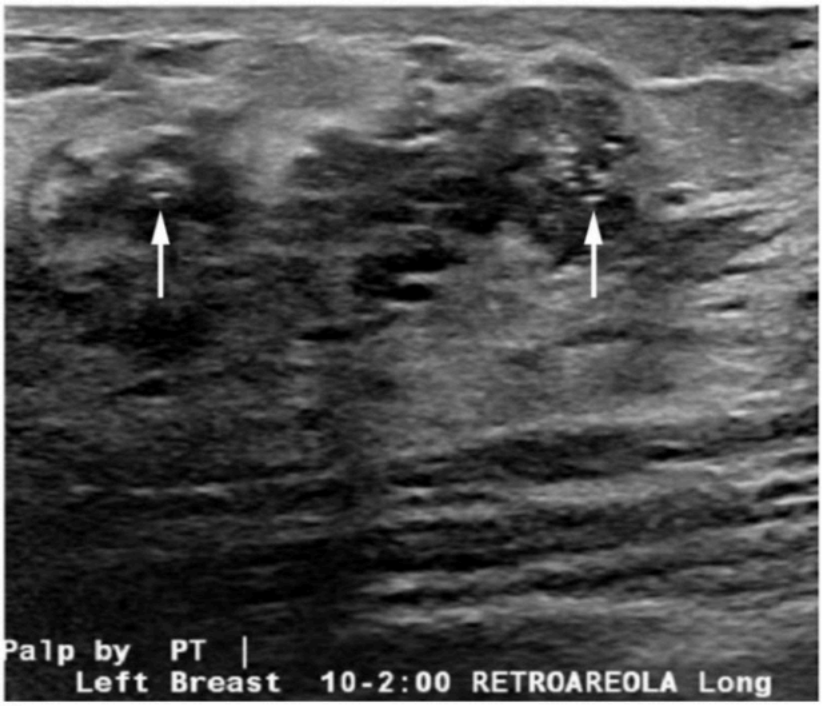

C

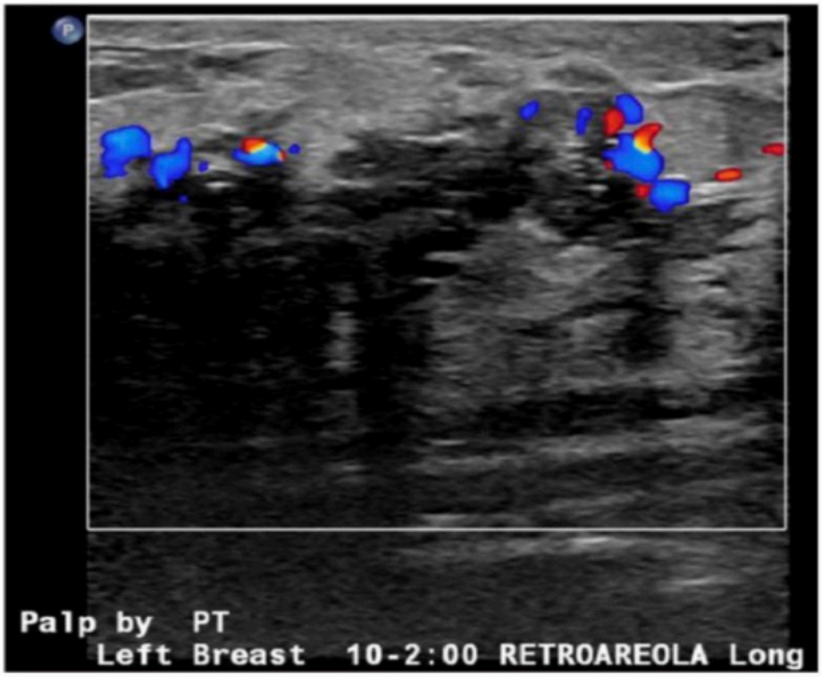

D

Figure 3 – *(Continued)* NON-MASS LESION. Longitudinal US image (C) shows the calcifications (arrows) within the segmental non-mass lesion. Note the hypervascularity associated with this lesion in the Doppler US image (D). Pathology: High grade DCIS.

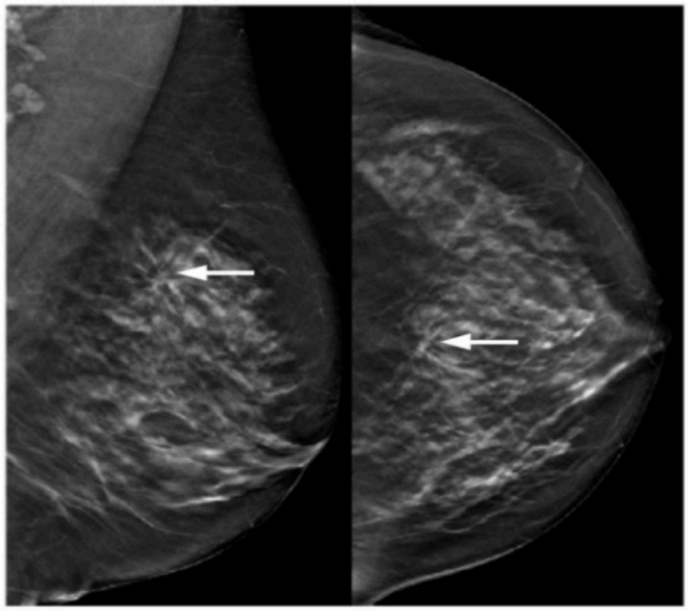

A

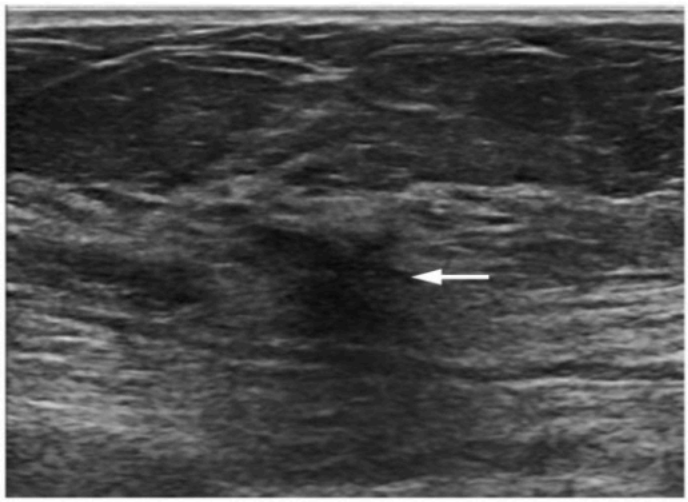

B

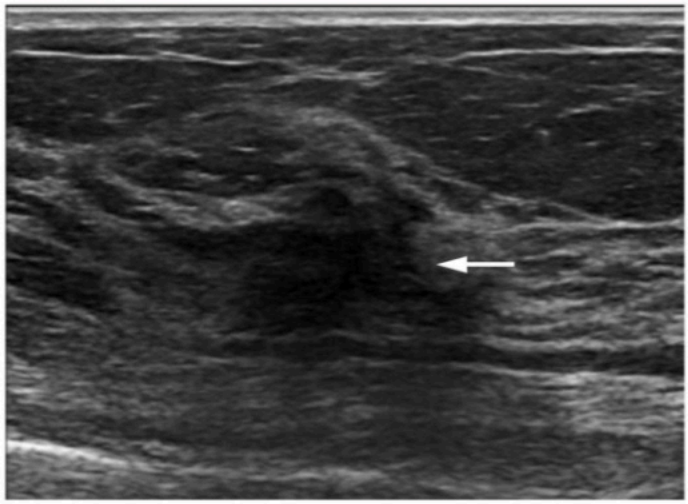

C

Figure 4 – NON-MASS LESION. MLO and CC DBT (A) show architectural distortion (arrows). Longitudinal (B) and transverse (C) US images targeted to the mammographic architectural distortion show a focal hypoechoic non-mass lesion (arrows). Note the associated subtle posterior shadowing and duct extension. The finding is more prominently seen in one plane (transverse plane in this case). Pathology: Grade 1 invasive ductal carcinoma.

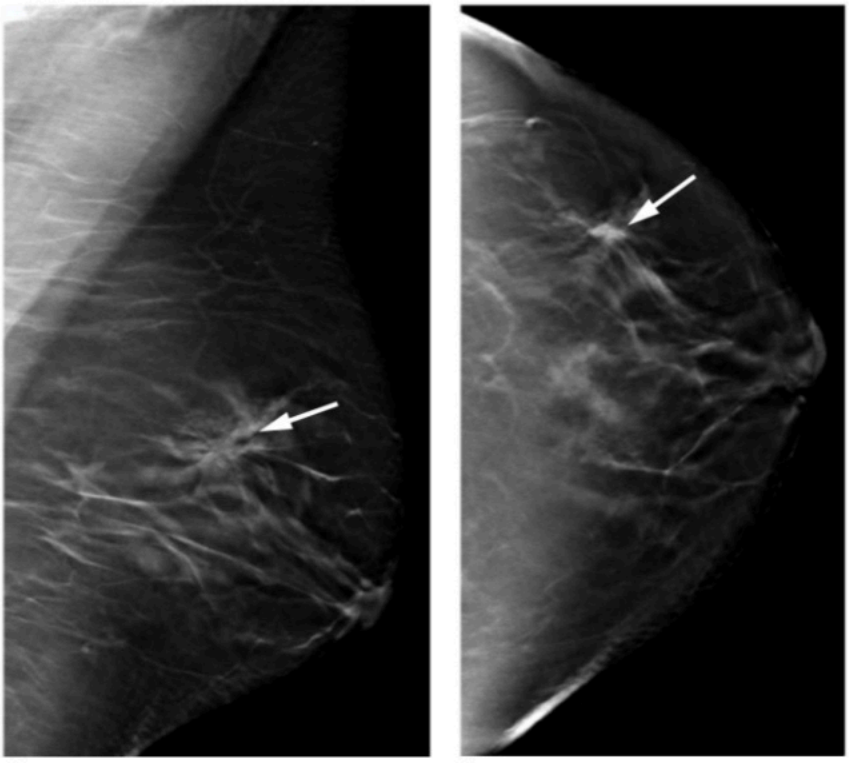

A B

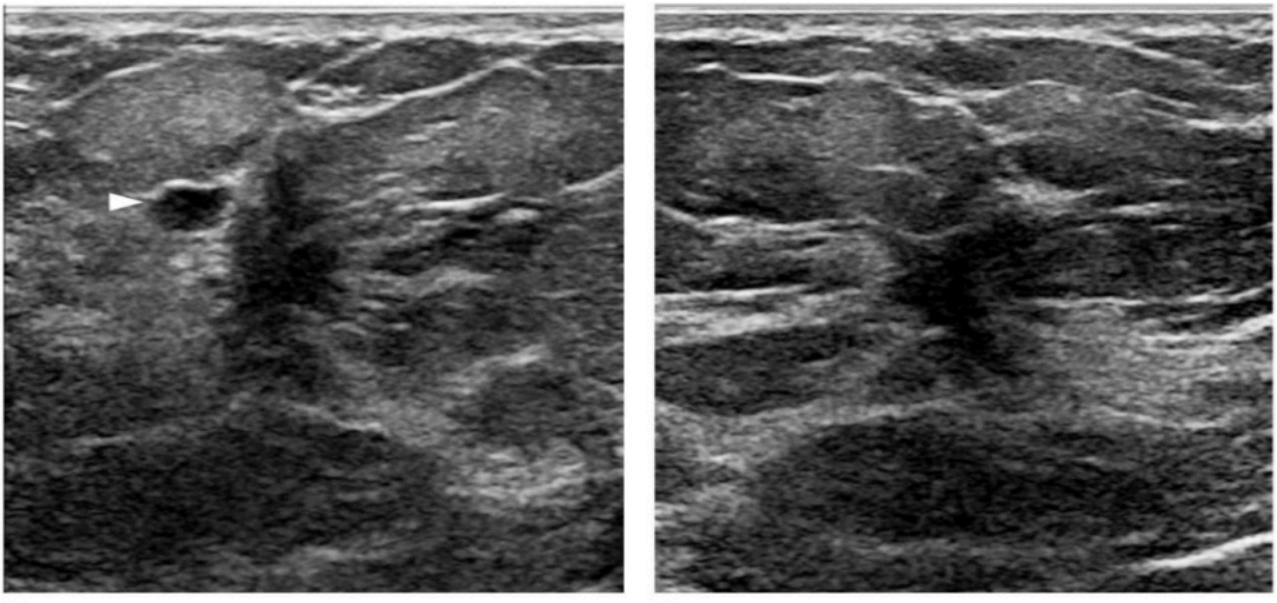

C D

Figure 5 – NON-MASS LESION. MLO (A) and CC (B) DBT images show architectural distortion (arrows). Longitudinal (C) and transverse (D) US images targeted to the mammographic architectural distortion show a focal hypoechoic non-mass lesion. Note that the finding very appears different in the 2 planes, lacking 3D conspicuity. An incidental cyst (arrowhead) is seen adjacent to the non-mass lesion in the longitudinal plane. Pathology: Radial scar.

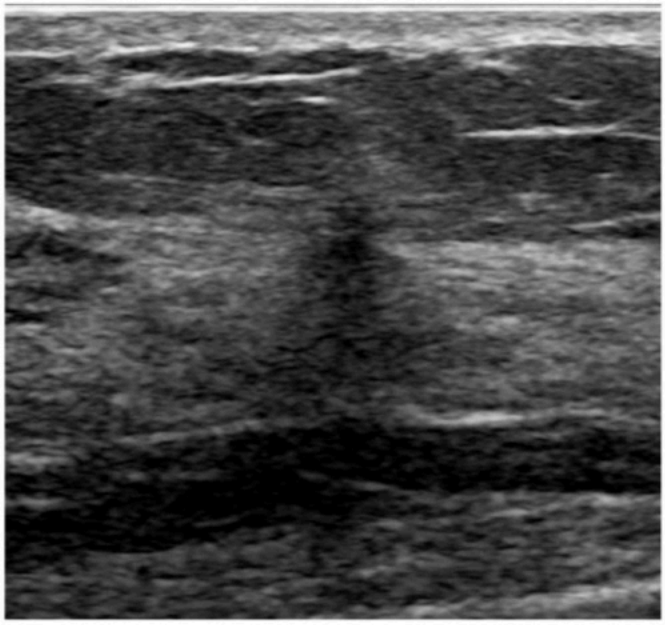

A

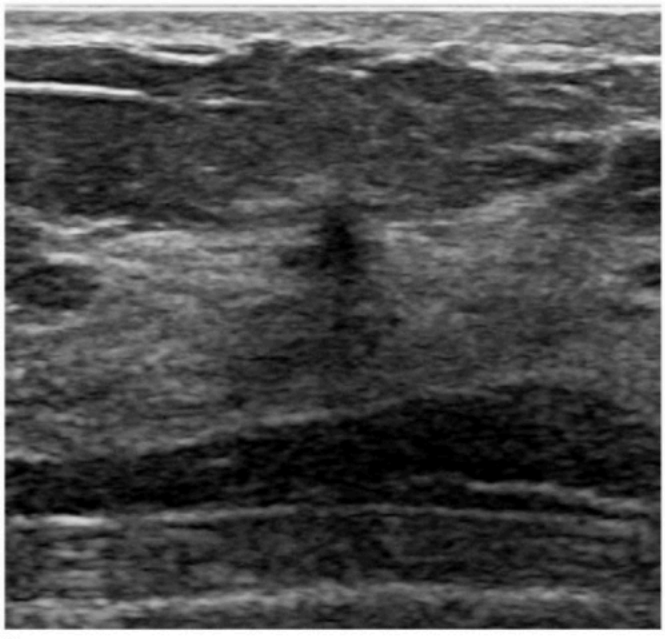

B

Figure 6 – NON-MASS LESION. Longitudinal (A) and transverse (B) US images show an incidental focal non-mass lesion with shadowing. In real-time scanning, this finding is planar and lacks 3-dimensionality. Although the two orthogonal images capture what may appear to be a mass, it was much more conspicuous in 1 plane than the orthogonal one during real-time scanning and therefore is more accurately characterized as a focal, hypoechoic, shadowing non-mass lesion. Pathology: Stromal fibrosis.

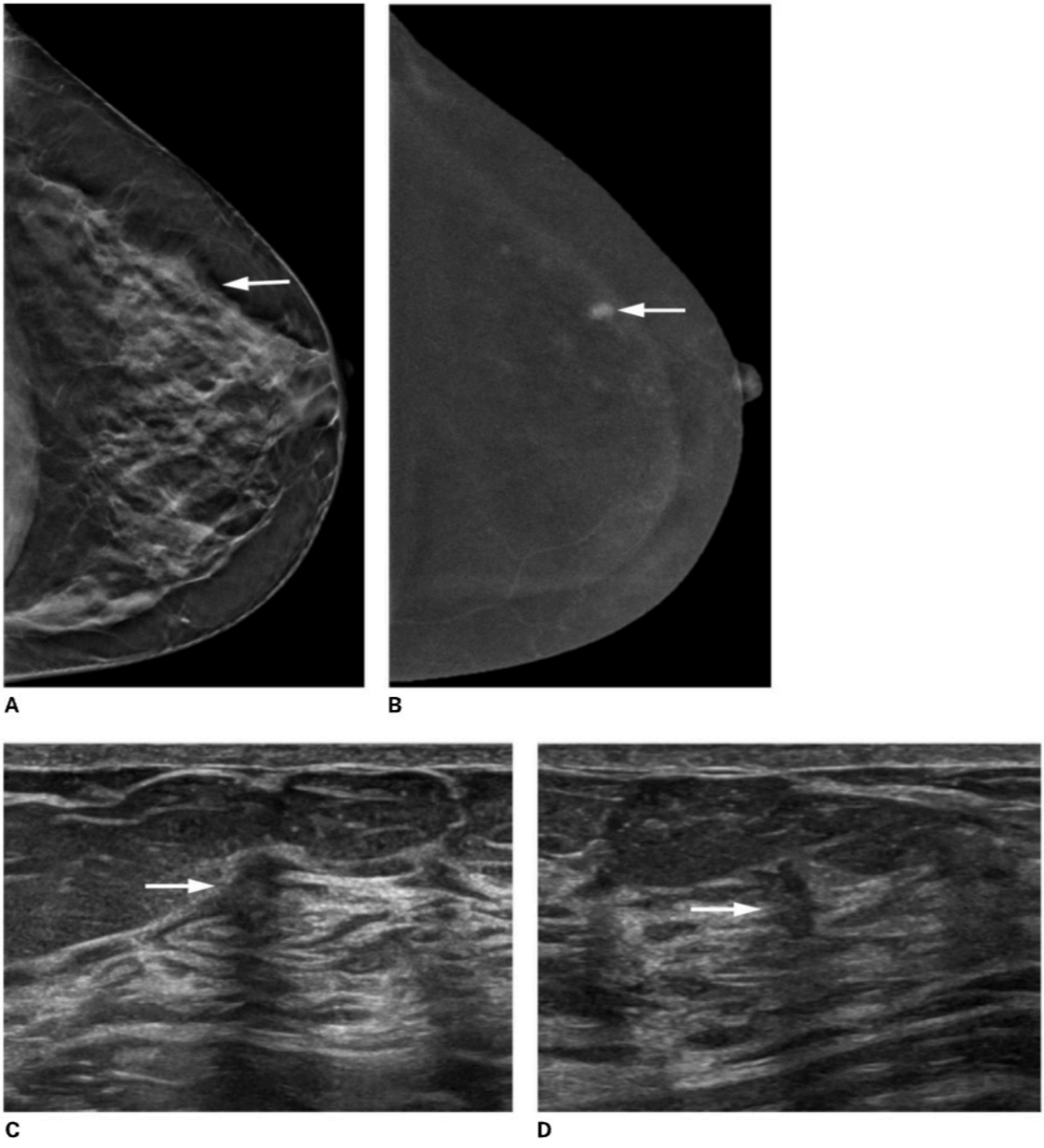

Figure 7 – NON-MASS LESION. Left CC mammogram (A) and contrast enhanced mammography (CEM) (B) in CC projection show architectural distortion (arrow) and enhancing mass (arrow), respectively. Longitudinal (C) and transverse (D) US images targeted to the mammographic and CEM findings show a focal shadowing hypoechoic non-mass lesion (arrows). Note the associated posterior shadowing and duct extension. Pathology: Invasive mammary carcinoma with predominantly tubular features, grade 1.

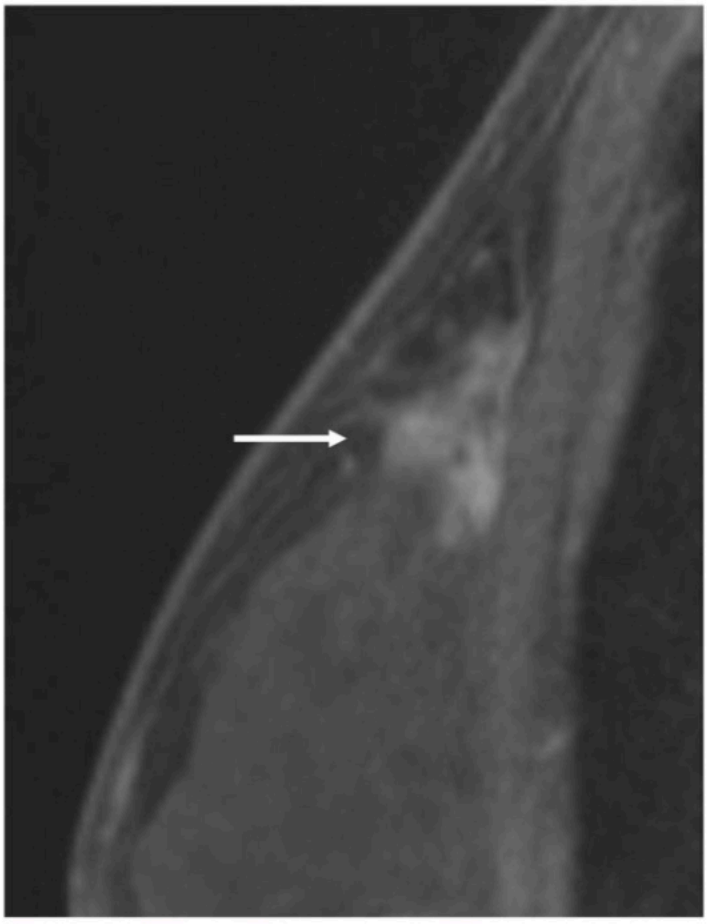

A

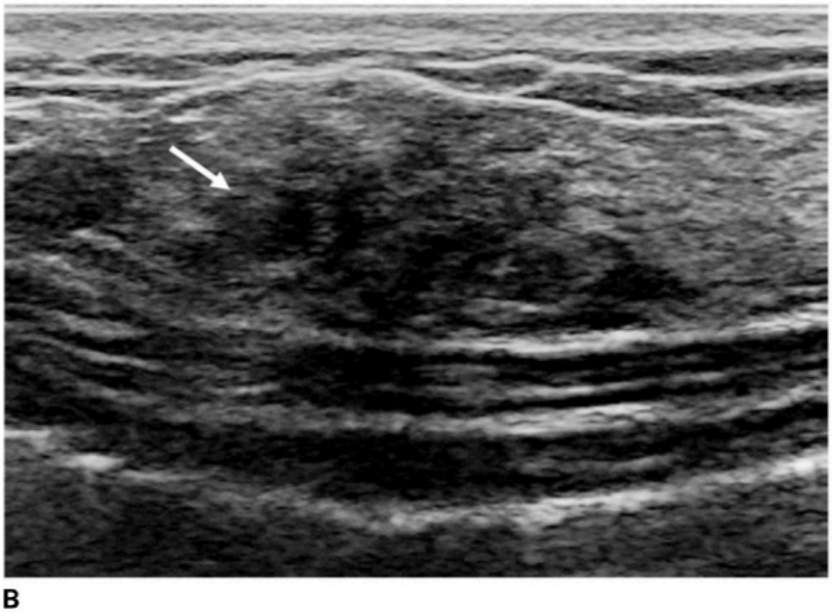

B

Figure 8 – NON-MASS LESION. Sagittal contrast-enhanced MRI (A) shows focal heterogeneous non-mass enhancement correlating with a palpable finding (arrow). Longitudinal US image (B) targeted to the palpable finding (which correlates with the MRI non-mass enhancement) shows a focal heterogeneous non-mass lesion with shadowing, lacking distinct margin or shape (arrow).

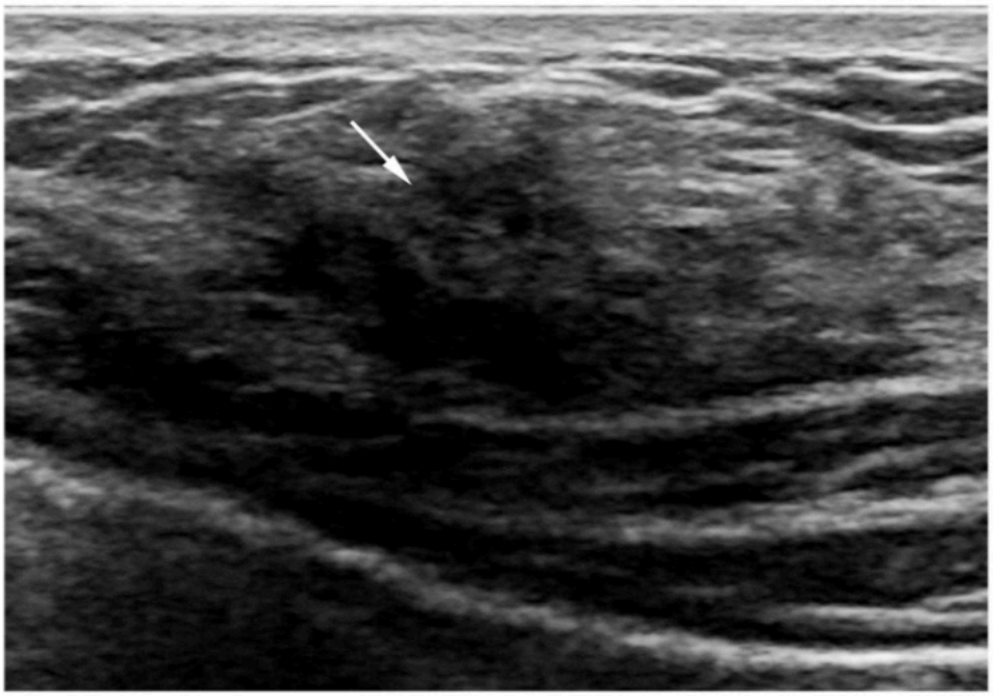

C

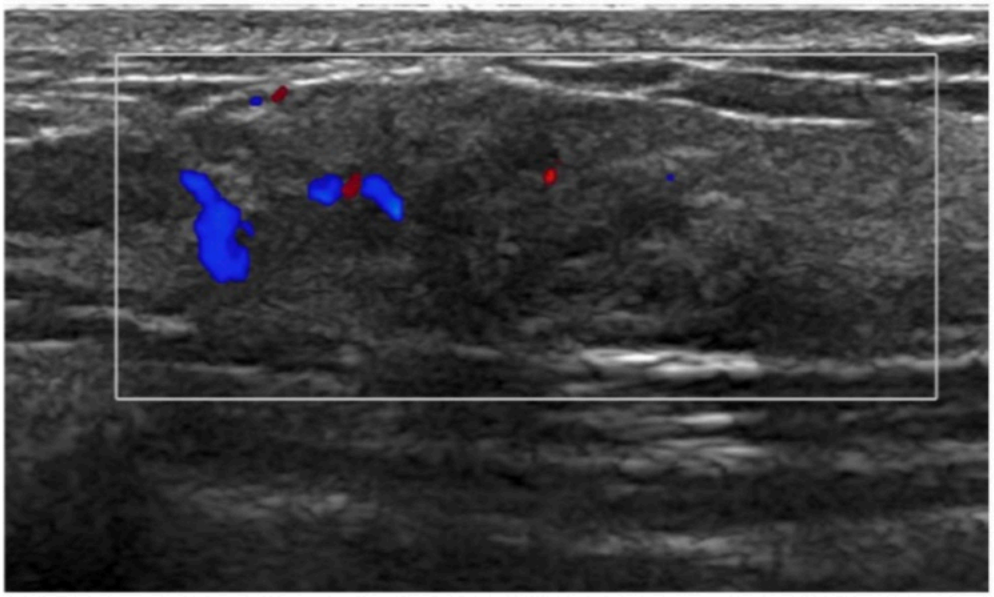

D

Figure 8 – *(Continued)* NON-MASS LESION. Transverse (C) and Doppler (D) US images targeted to the palpable finding (which correlates with the MRI non-mass enhancement) show a focal heterogeneous non-mass lesion with shadowing, lacking distinct margin or shape (arrow). Hypervascularity is seen with Doppler imaging, supporting the observation that this gray-scale finding is indeed a distinct finding (rather than heterogeneous background tissue). Pathology: Stromal fibrosis.

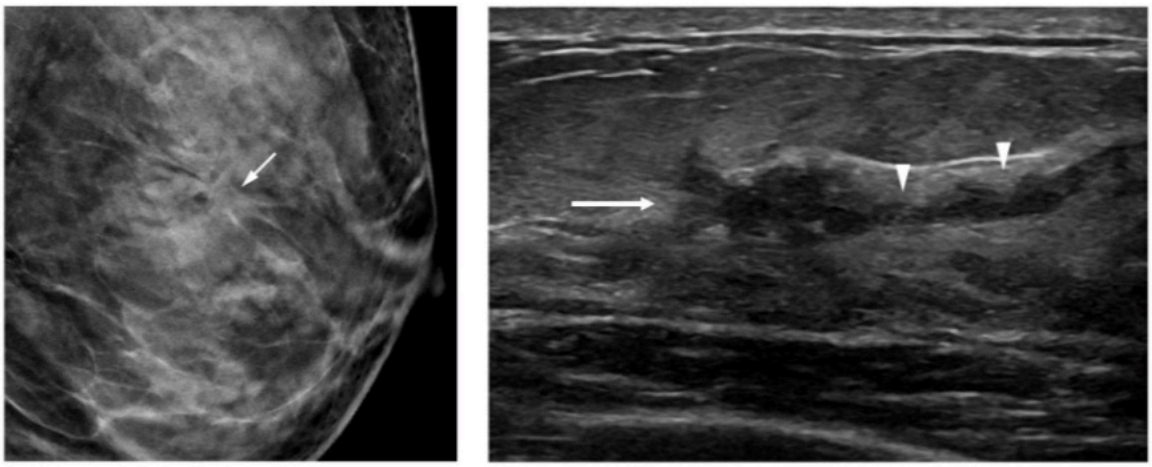

A C

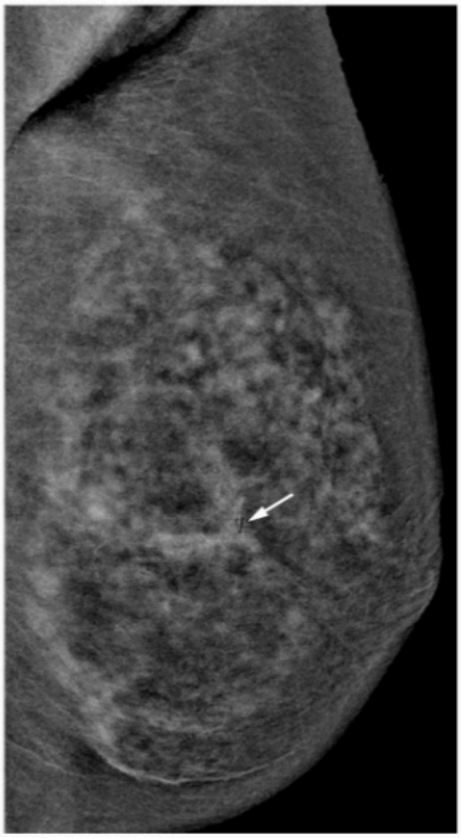

B

Figure 9 – NON-MASS LESION. Left spot DBT image in the LM projection (A) shows an architectural distortion (arrow). This is also seen on contrast enhanced mammography (CEM) in the LM projection (B). Note the non-enhancing biopsy clip (arrow) on CEM, which was performed after US-guided biopsy. Transverse US image (C) targeted to the mammographic architectural distortion shows hypoechoic linear non-mass lesion (arrow) with ductal extension (arrowheads) and no posterior features. Pathology: DCIS, which was upgraded to invasive lobular carcinoma at surgical excision.

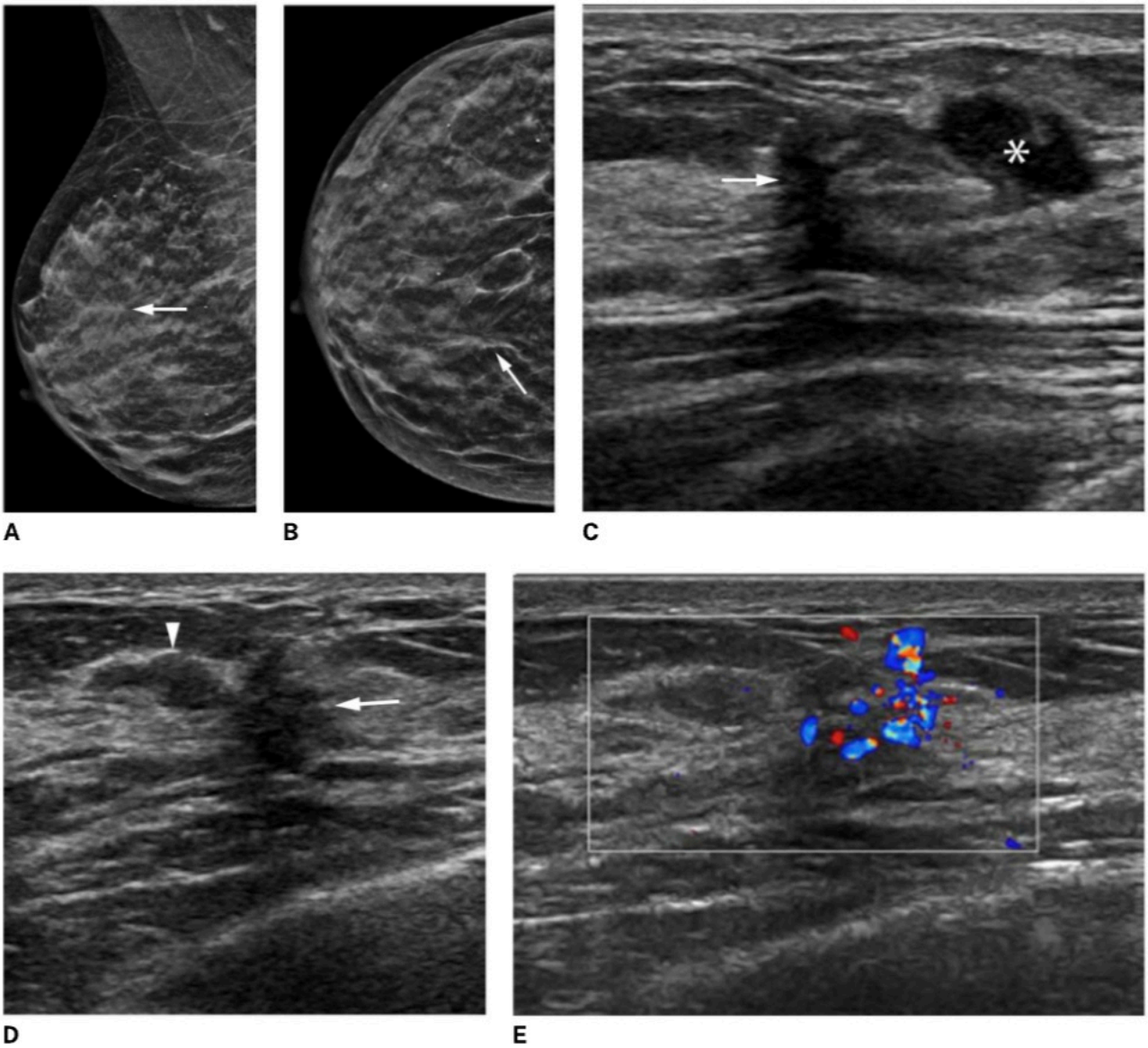

Figure 10 – NON-MASS LESION. MLO (A) and CC (B) synthetic mammograms (SM) of the right breast show architectural distortion (arrows). Longitudinal (C) and transverse (D) US images targeted to the mammographic architectural distortion show a focal hypoechoic shadowing non-mass lesion (arrows) with duct extension (arrowhead). Note the finding appears different in the 2 planes. An incidental cyst with debris that is better characterized on other images (asterisk) is seen adjacent to the non-mass lesion in the longitudinal plane. Hypervascularity is seen with Doppler imaging (E), supporting the observation that this gray-scale finding is indeed a true lesion (rather than heterogeneous background tissue). Pathology: Invasive tubular carcinoma.

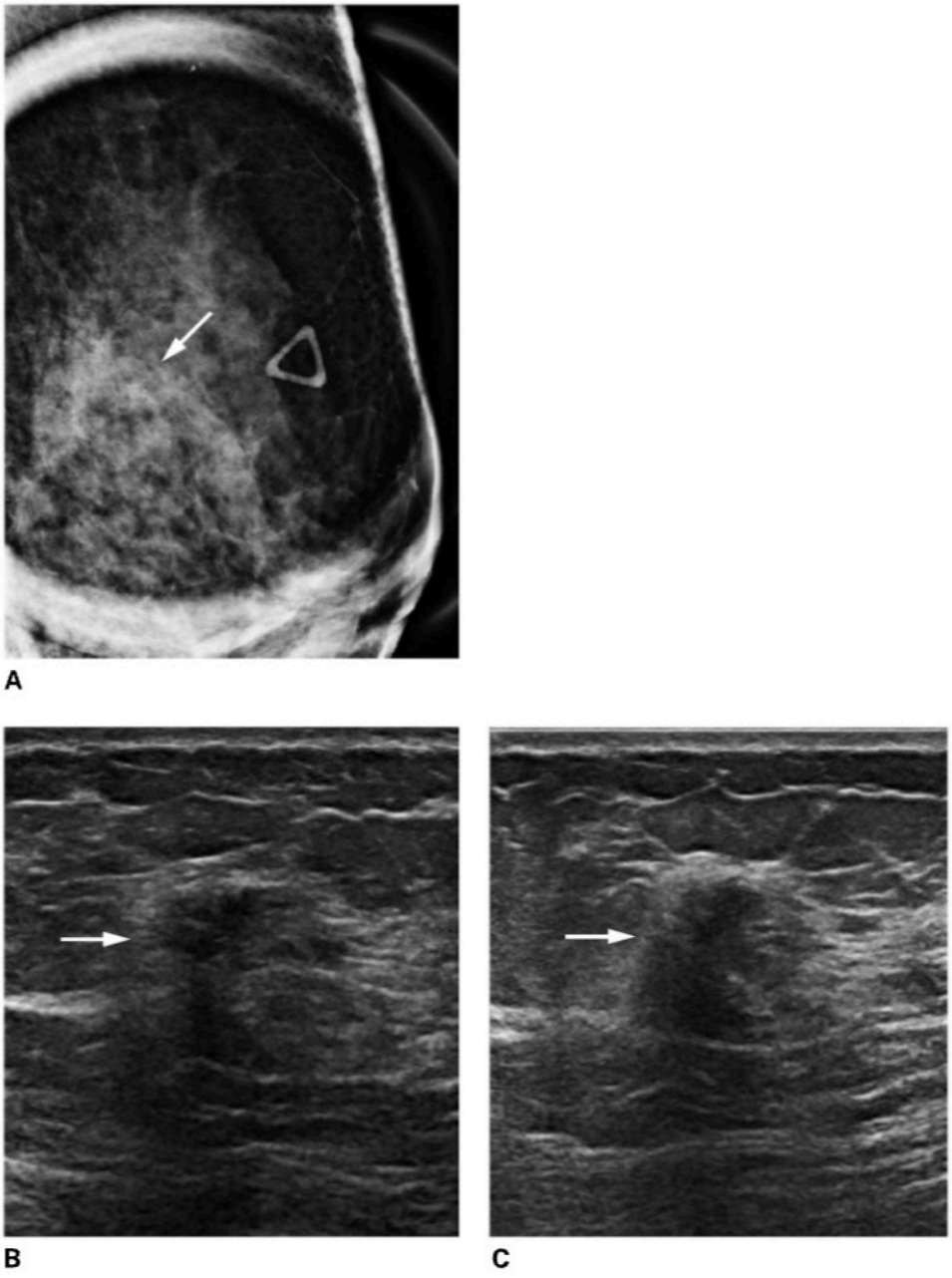

Figure 11 – NON-MASS LESION. Left spot magnification mammogram (A) in LM projection of a palpable lump shows a subtle asymmetry with associated round and amorphous calcifications (arrow). Longitudinal (B) and transverse (C) US images targeted to the palpable lump show a focal hypoechoic non-mass lesion (arrows) with subtle posterior shadowing. The finding appears different in the 2 planes. Note also the absence of a definable shape or margin. Pathology: Invasive lobular carcinoma.

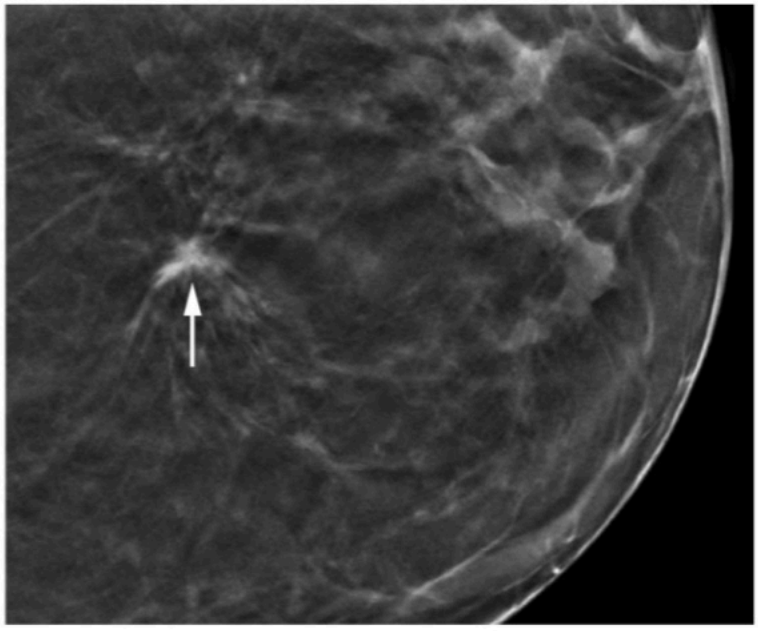

A

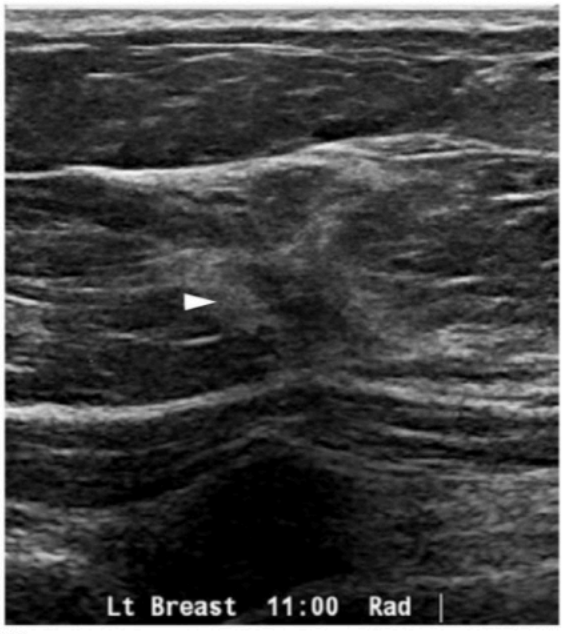

B

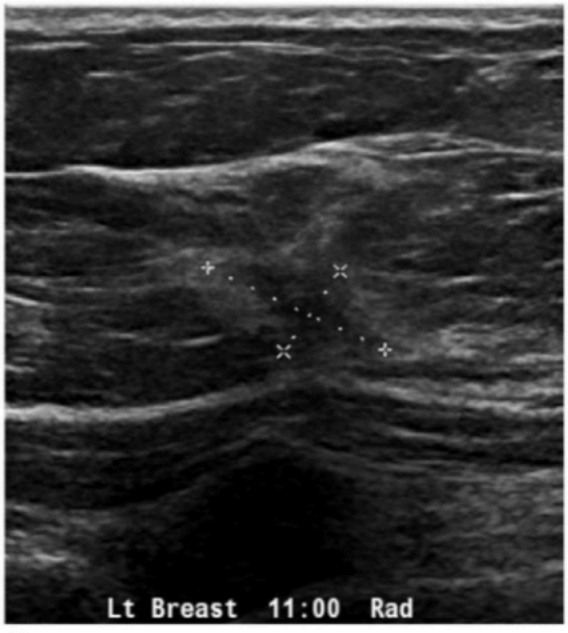

C

Figure 12 – NON-MASS LESION. Left spot compression DBT image in CC projection (A) shows an architectural distortion (arrow). US image in the radial plane without (B) and with (C) measurements (targeted to the mammographic architectural distortion). The US images show a focal hypoechoic non-mass lesion with echogenic rind (arrowhead in (B)) with no posterior features.



D

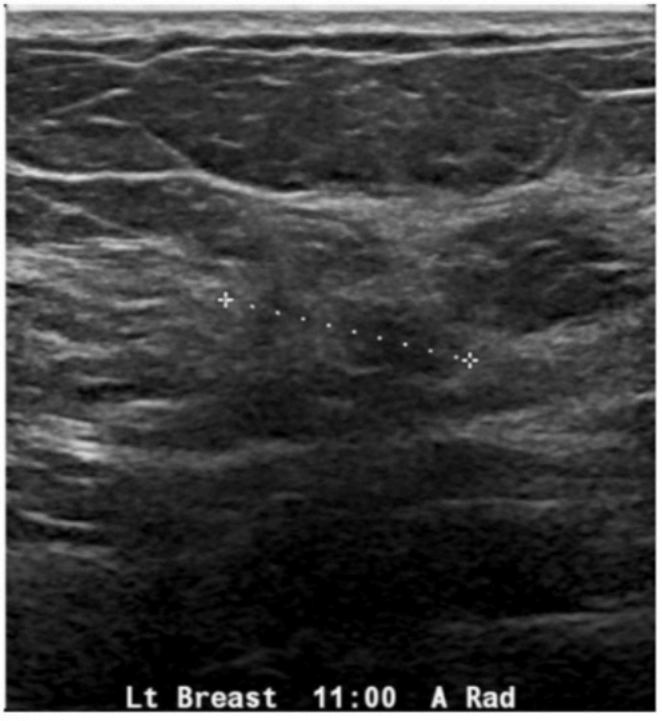

E

Figure 12 – *(Continued)* NON-MASS LESION. Ultrasound images in antiradial plane (D, E). The non-mass lesion is less conspicuous in the antiradial than the radial plane. The variation between the 2 planes of imaging suggests the lack of 3-dimensionality seen in masses, which is characteristic of a non-mass lesion. Pathology: DCIS, which was upgraded to invasive tubular carcinoma at surgical excision.

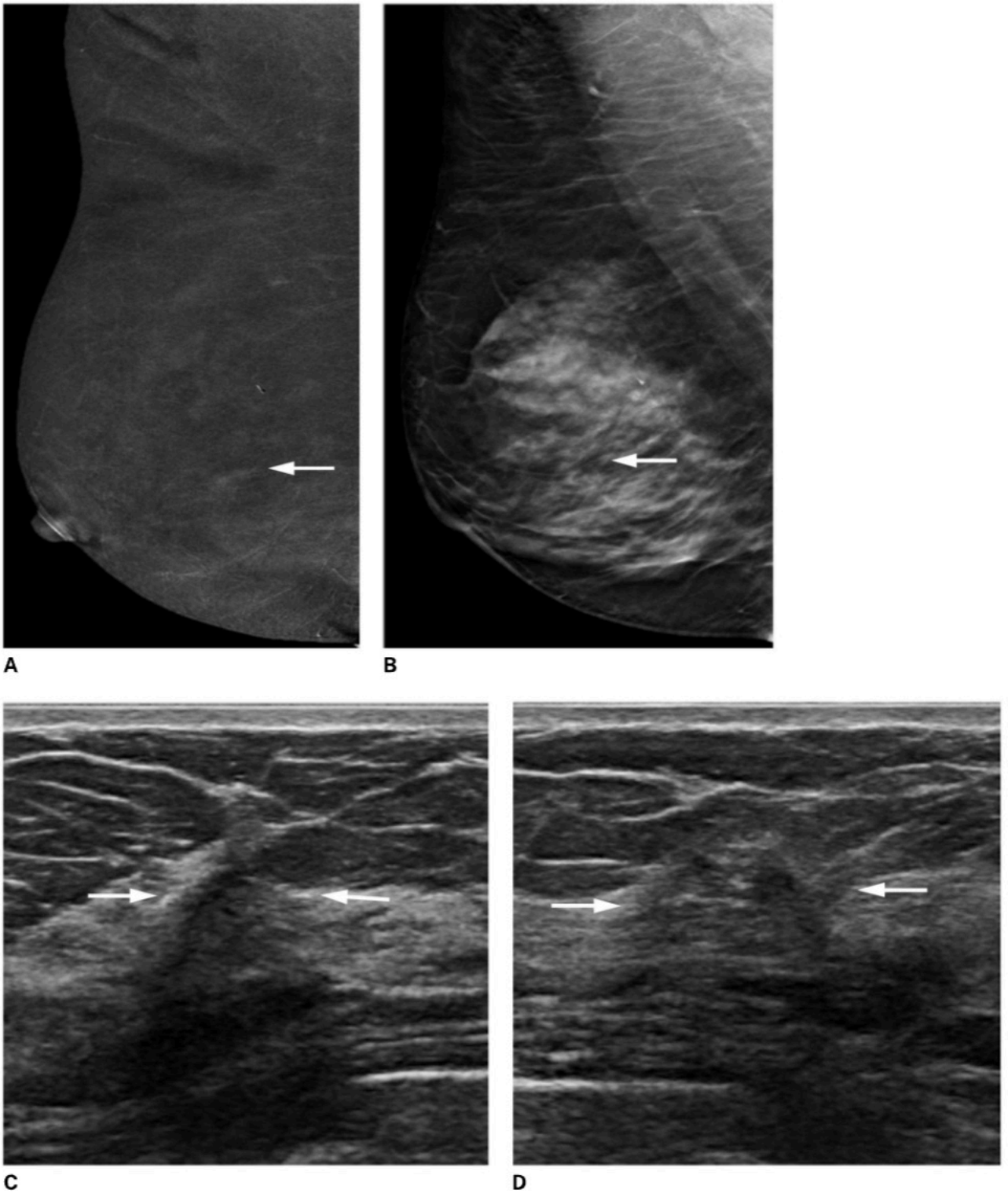

Figure 13 – NON-MASS LESION. CEM (A) and DBT (B) images in MLO projection show subtle contrast enhancement (arrow) and architectural distortion (arrow). Longitudinal (C) and transverse (D) US images targeted to imaging finding show a focal hypoechoic non-mass lesion (arrows) with subtle posterior shadowing. The finding appears different in the 2 planes. There is absence of a definable shape or margin. Pathology: Complex sclerosing lesion.



A

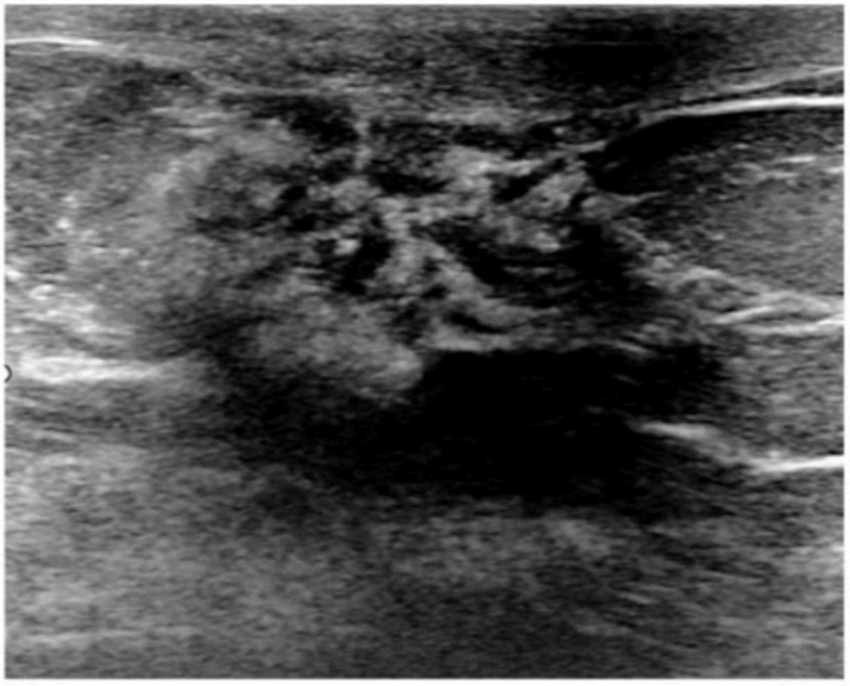

B

Figure 14 – NON-MASS LESION. Left DBT image in MLO projection (A) shows nipple retraction (arrow). Ultrasound of left retroareolar breast (B) shows focal heterogeneous shadowing non-mass lesion. Pathology: Invasive lobular carcinoma.



A

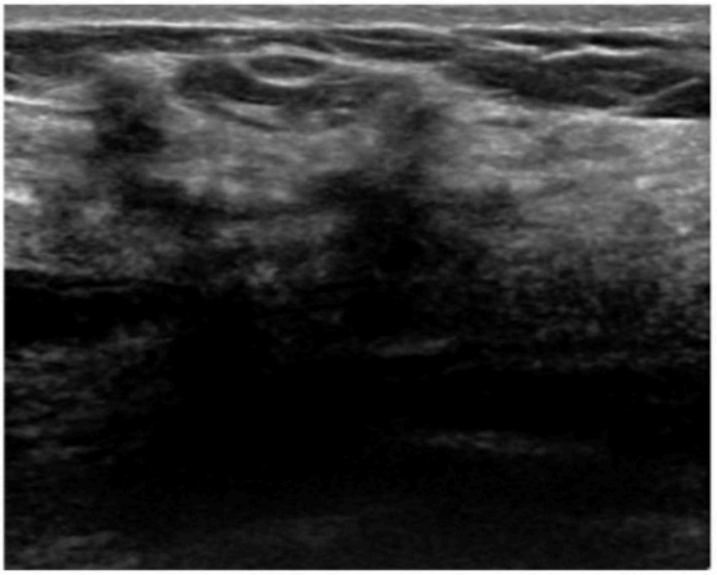

B

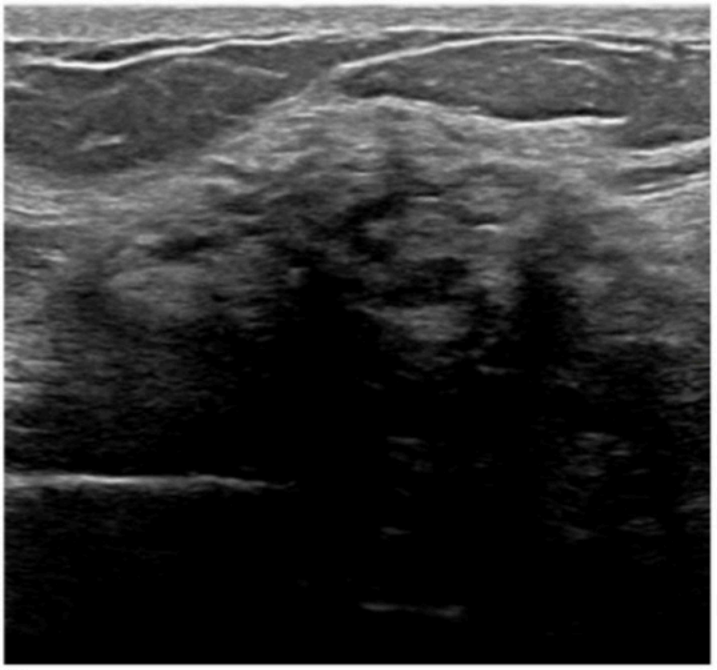

C

Figure 15 – NON-MASS LESION. Bilateral MLO DBT images (A) show large areas of subtle distortion in both breasts, predominately their upper extents. Bilateral whole-breast ultrasound was performed, with representative images of right breast 10:00 position (B) and left breast 3:00 position (C), showing regional hypoechoic non-mass lesions with shadowing in both breasts. Pathology: Diabetic mastopathy bilaterally.

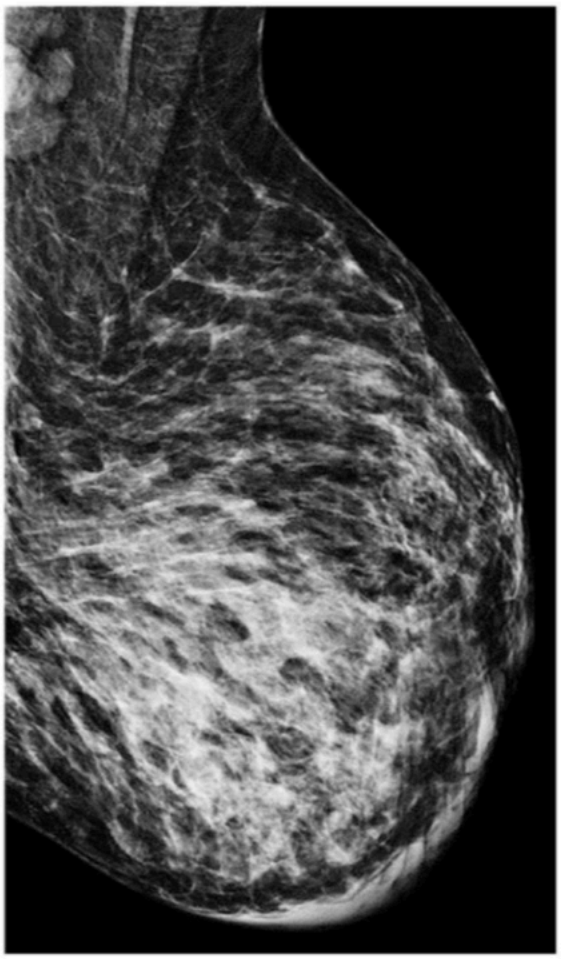

A

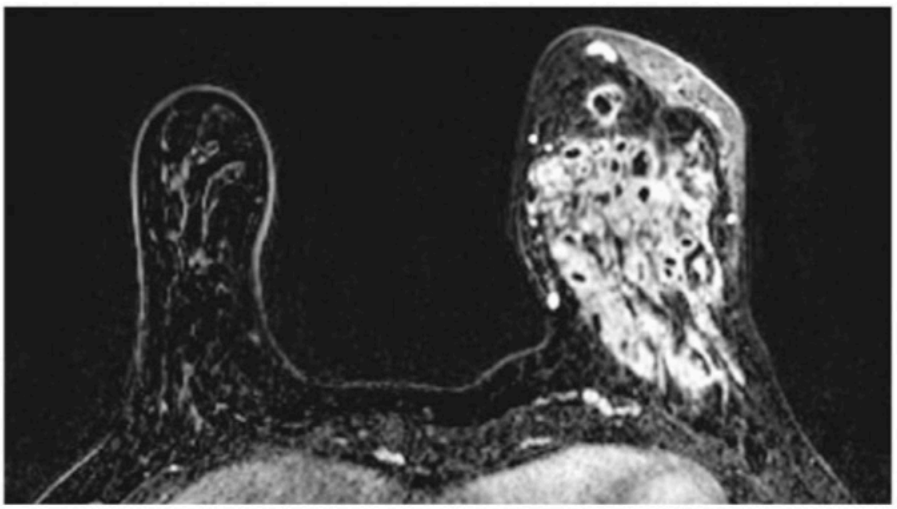

B

Figure 16 – NON-MASS LESION. Left MLO mammogram (A) shows skin thickening and global asymmetry compared to the right breast (not shown). MRI of both breasts in axial plane (B) shows asymmetric enlargement of the left breast, skin thickening and skin involvement, and non-mass enhancement involving the entire left breast.

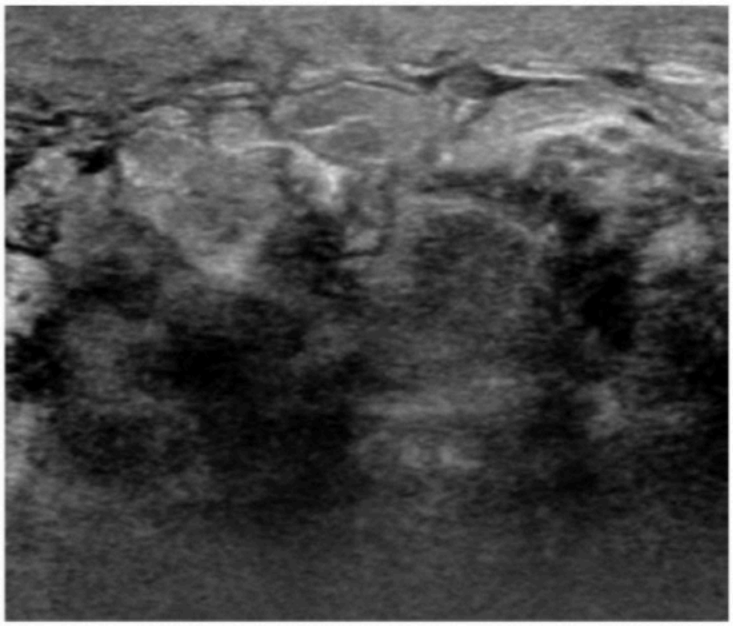

C

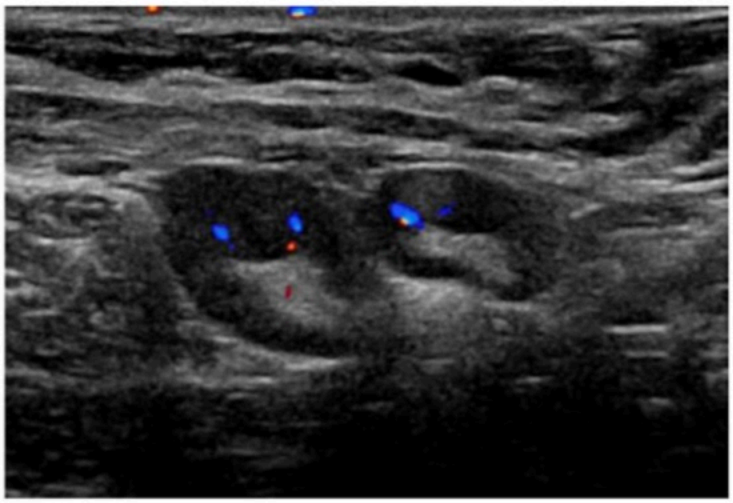

D

Figure 16 – *(Continued)* NON-MASS LESION. Ultrasound of the left breast (C) shows a shadowing hypoechoic regional heterogeneous non-mass lesion, associated with skin thickening and edema. Doppler ultrasound of left axilla (D) shows lymph nodes with eccentric cortical thickening. Pathology: Granulomatous mastitis. The left axillary adenopathy was presumed reactive.

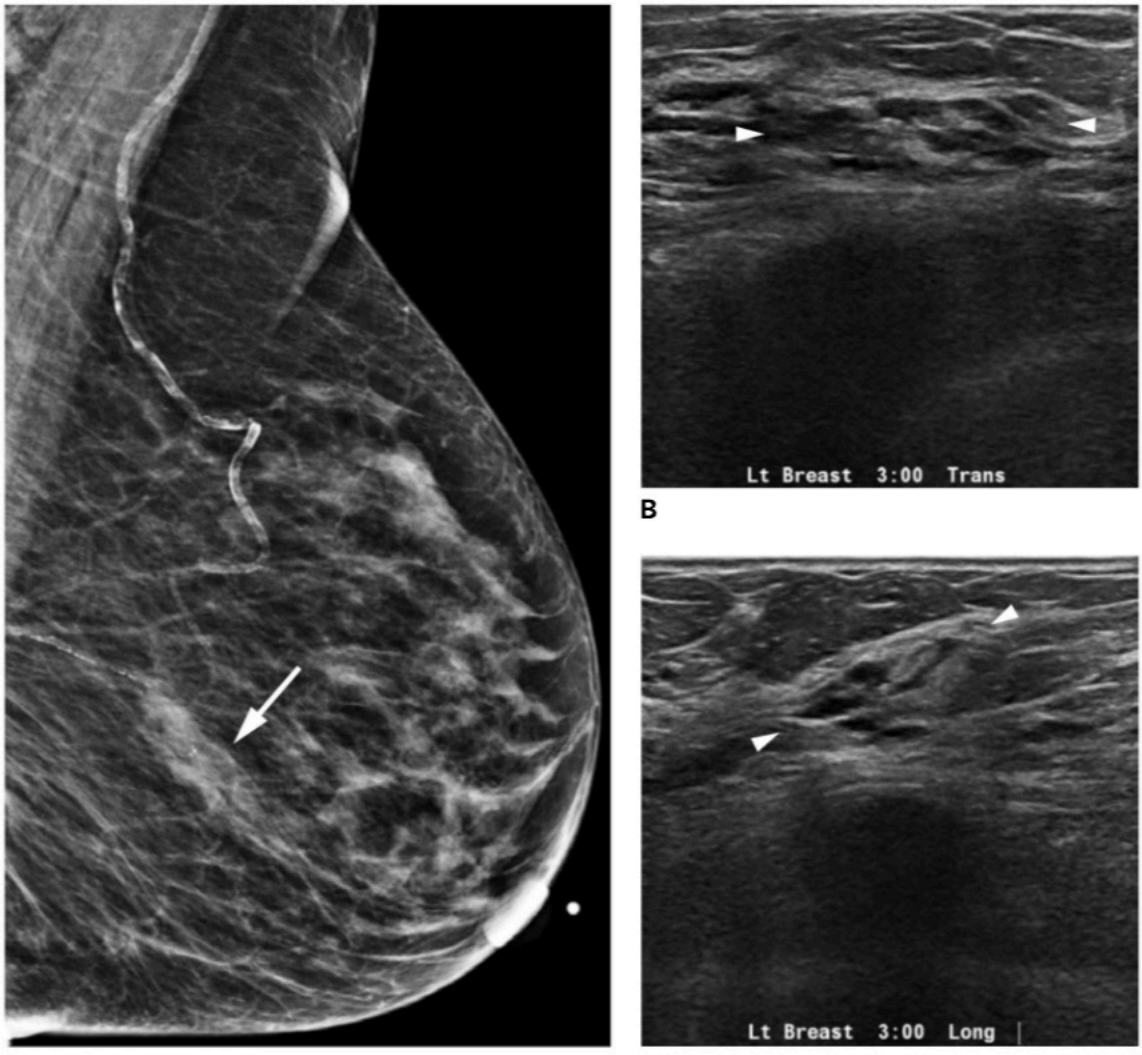

Figure 17 – NON-MASS LESION. Left MLO mammogram (A) shows a focal asymmetry (arrow) in the left breast 3:00 position, new since prior mammograms (CC mammogram not shown). Targeted ultrasound in the transverse (B) and longitudinal (C) planes show a heterogeneous non-mass lesion of mixed echogenicity with posterior enhancement (arrowheads). Pathology: Invasive ductal carcinoma.

D. CALCIFICATIONS

Calcifications can be recognized as echogenic foci, particularly when in a hypoechoic mass or distended lactiferous duct. High-frequency, high-resolution transducers can depict both micro and macrocalcifications, but morphology will not be as readily discernible as at mammography, and correlation with mammography is required for precise analysis. Not all echogenic foci detected on US are related to calcifications, and correlation with mammography (as indicated) can prevent misinterpretation.

Visualization of suspicious calcifications depends on size and depth, as well as the echo pattern of the surrounding tissue. Identification of calcifications also depends on technical parameters such as US equipment, transducer frequency, and operator image settings. Larger extent of calcifications, larger number of calcifications, segmental distribution, malignant etiology, and calcifications surrounded by hypoechoic tissue are more likely to be identified on sonography [37, 38]. Likewise, the calcifications of high grade, comedo-type DCIS are more often seen on US than the calcifications of low grade DCIS [39]. US evaluation of malignant calcifications detected on mammography may also identify a mass or non-mass lesion representing a mammographically occult invasive component. Overall, microcalcifications identified on sonography may have a higher positive predictive value for malignancy compared to microcalcifications seen only on mammography [40].

Calcifications may be described by morphology (macro vs. micro), location within or outside a mass or non-mass lesion, or within a duct. When suspicious calcifications are identified on US, US may be used to provide imaging guidance for percutaneous biopsy [41]. Ultrasound-guided biopsy is particularly useful if stereotactic biopsy is not available or difficult to perform [38]. Of note, specimen radiography is indicated when biopsy is performed for calcifications [27].

D. CALCIFICATIONS

1. MACROCALCIFICATIONS

Macrocalcifications are large enough to attenuate the US beam and are typically associated with posterior shadowing [37]. Common macrocalcifications identified on US may be due to degenerating fibroadenomas, oil cysts, or dystrophic calcifications. Postsurgical clips can also mimic the appearance of macrocalcifications with posterior shadowing. In these scenarios, correlation with mammography is essential to rule out the possibility of a small suspicious shadowing mass.

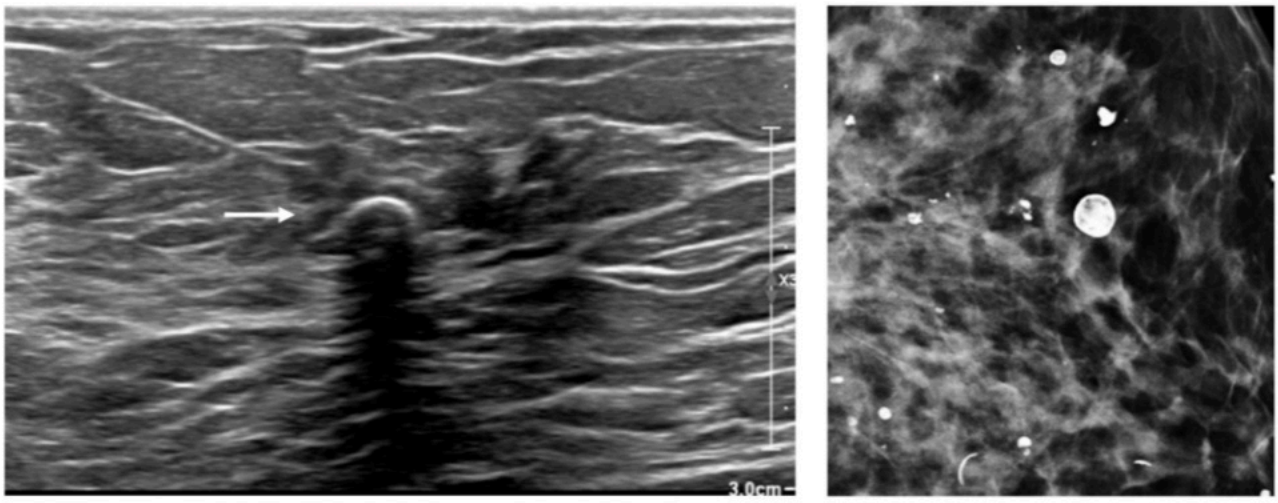

A B

Figure 1 – MACROCALCIFICATIONS. (A) Ultrasound shows coarse echogenic MACROCALCIFICATION associated with posterior shadowing within echogenic glandular tissue. The curvilinear hyperechoic line along the superficial margin is characteristic of MACROCALCIFICATIONS. An adjacent smaller echogenic MACROCALCIFICATION (arrow) is too small to attenuate the US beam, so there is no posterior shadowing. (B) Mammography shows the corresponding calcifications plus numerous additional calcifications that were not identified on US.

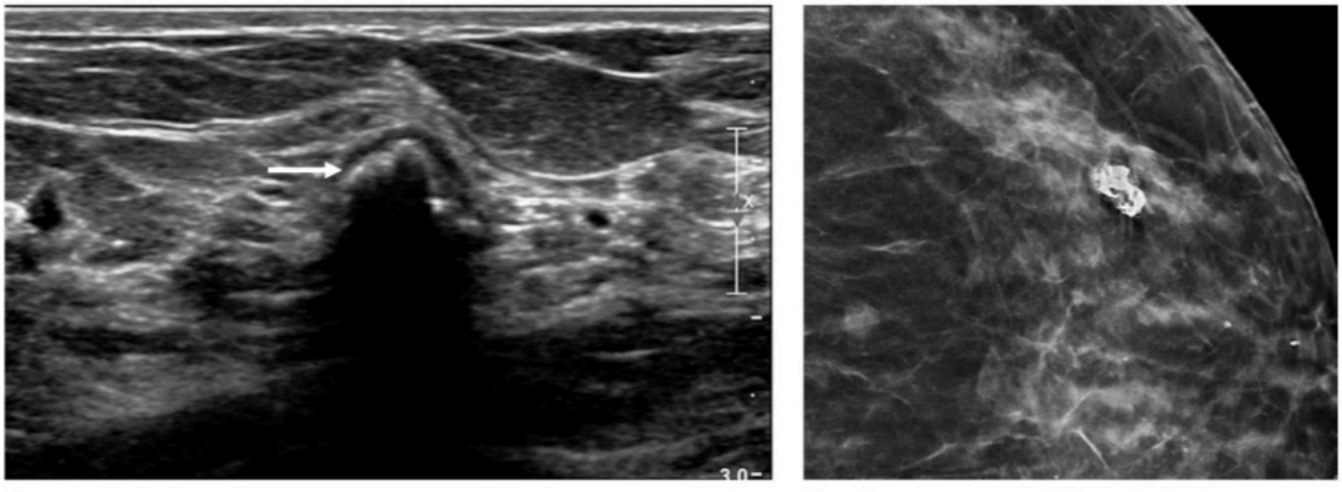

A B

Figure 2 – MACROCALCIFICATION. (A) US demonstrates a curvilinear echogenic MACROCALCIFICATION (arrow) with posterior shadowing corresponding to a benign dystrophic calcification present on the mammogram (B).

D. CALCIFICATIONS

2. MICROCALCIFICATIONS

Microcalcifications appear as tiny echogenic foci on US and are most conspicuous when located within a hypoechoic mass, non-mass lesion, or duct [38]. Because of their small size, microcalcifications are typically not associated with posterior shadowing and usually blend in with surrounding fibroglandular tissue, unless occurring within a large group. Posterior shadowing may be present if the microcalcifications are tightly grouped and thus attenuate the US beam. Echogenic Cooper's ligaments seen in cross section can have the appearance of tiny echogenic foci and are a source of artifact that can mimic microcalcifications.

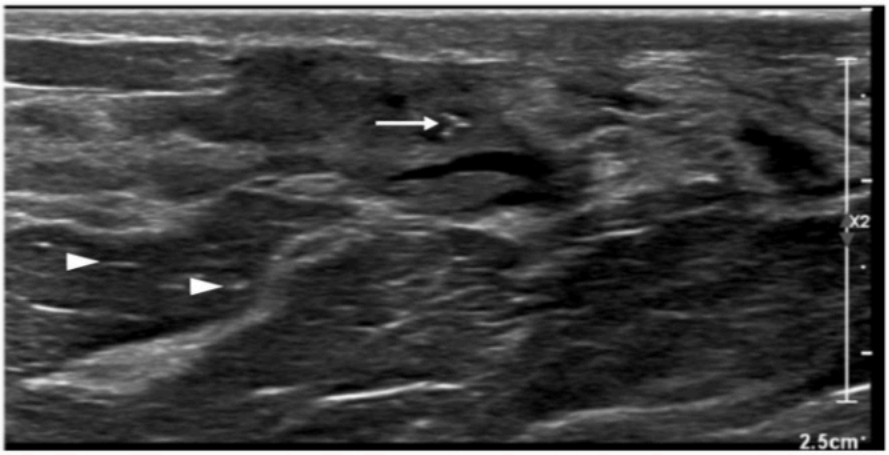

A

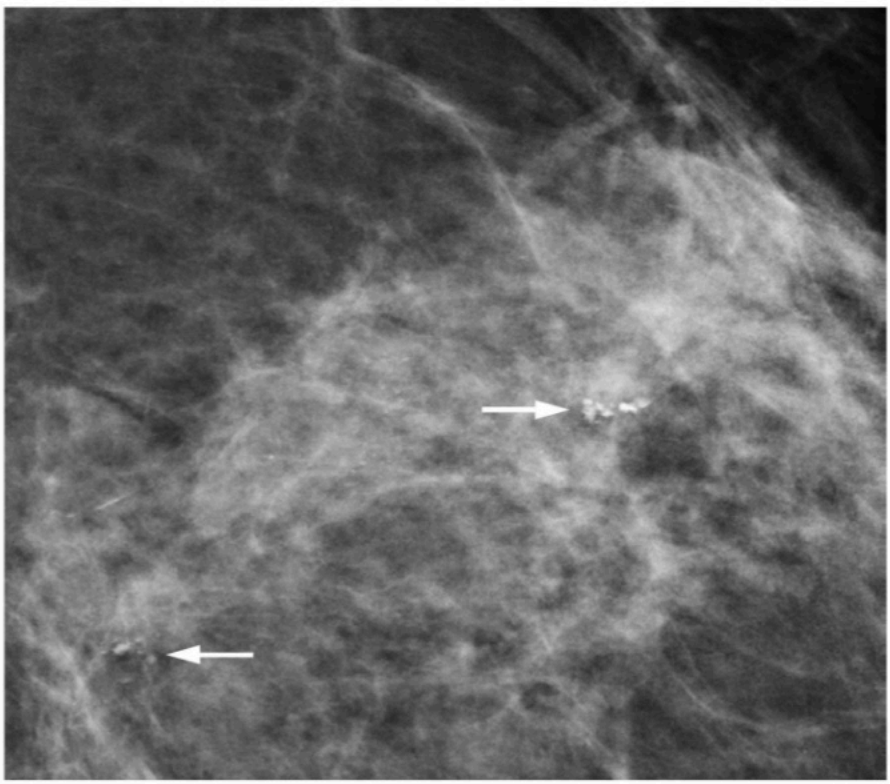

B

Figure 1 – MICROCALCIFICATIONS. Benign layered calcifications consistent with fibrocystic changes in a 45-year-old woman. (A) Supplemental screening breast US shows a hypoechoic microcyst with echogenic foci consistent with MICROCALCIFICATION (arrow), which are too small to be associated with posterior shadowing. Note that Cooper's ligaments on end can appear similar to microcalcifications (arrowheads). (B) Magnification mammography in the true lateral projection demonstrates layering calcifications (arrows).

D. CALCIFICATIONS

3. CALCIFICATIONS IN A MASS OR NON-MASS LESION

Because calcifications are echogenic on US, they are more conspicuous within hypoechoic breast masses than within echogenic glandular tissue. Calcifications may be identified within benign or malignant masses and non-mass lesions depicted on US.

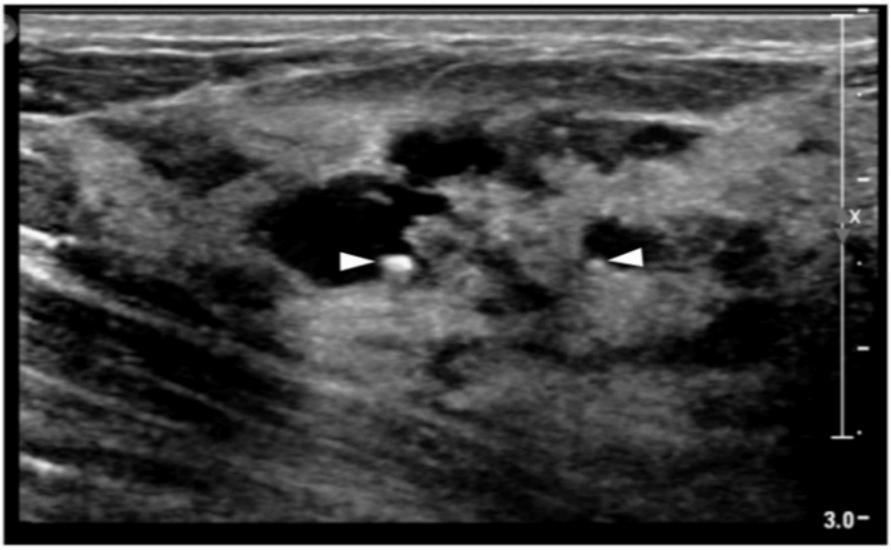

Figure 1 – CALCIFICATIONS IN A MASS. Echogenic layering calcifications within small cysts (arrowheads) seen on screening US. The calcifications are too small to attenuate the US beam.

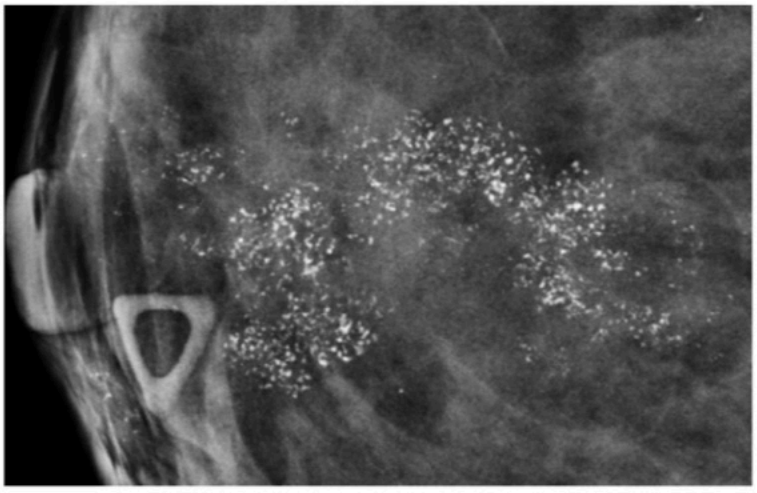

A

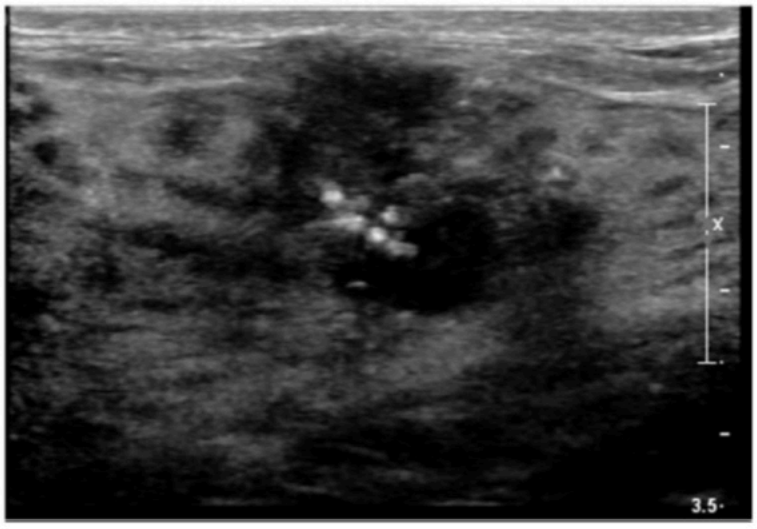

B

Figure 2 – CALCIFICATIONS IN A MASS. (A) ML magnified mammogram image shows segmental fine pleomorphic calcifications at the site of a palpable lump. (B) Corresponding ultrasound image shows echogenic calcifications within an irregular hypoechoic mass. Pathology (obtained from US-guided core needle biopsy): Grade 3 invasive ductal carcinoma with comedonecrosis.

D. CALCIFICATIONS

4. CALCIFICATIONS OUTSIDE OF A MASS OR NON-MASS LESION

At US, calcifications situated in fat or fibroglandular tissue are less conspicuous than when present within a mass or within a non-mass lesion. Small echogenic foci grouped in tissue may sometimes be identified because they have patterns different from those of acoustic speckle and transversely sectioned Cooper's ligaments or pectoral muscle fascicles. Because they occupy too small a portion of the acoustic beam, individual calcifications that are not coarse will not shadow. If calcifications are sufficiently numerous for a pattern to be discerned, they may be perceived as grouped in the area of tissue being examined with US. It is possible that calcifications outside of a mass reside within a non-mass lesion. Because non-mass lesion is a new BI-RADS descriptor, more investigation is needed to determine whether calcifications outside of a mass are always associated with a non-mass lesion on US.

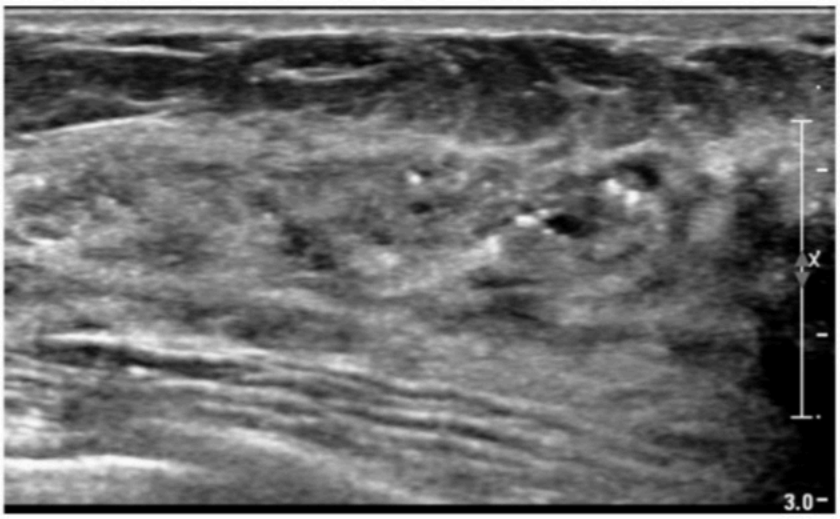

A

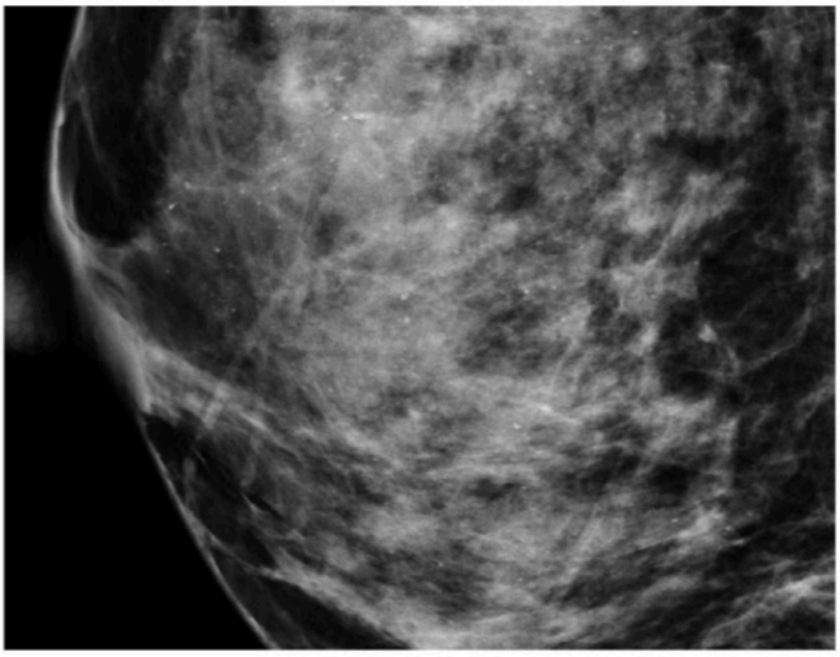

B

Figure 1 – CALCIFICATIONS OUTSIDE OF A MASS. (A) US performed to evaluate breast pain shows numerous echogenic microcalcifications within fibrocystic glandular tissue. These calcifications are not within a mass but may be considered to be within a non-mass lesion. (B) Right mammogram confirms diffuse round and amorphous microcalcifications. Note that more microcalcifications are seen on mammography compared to US.

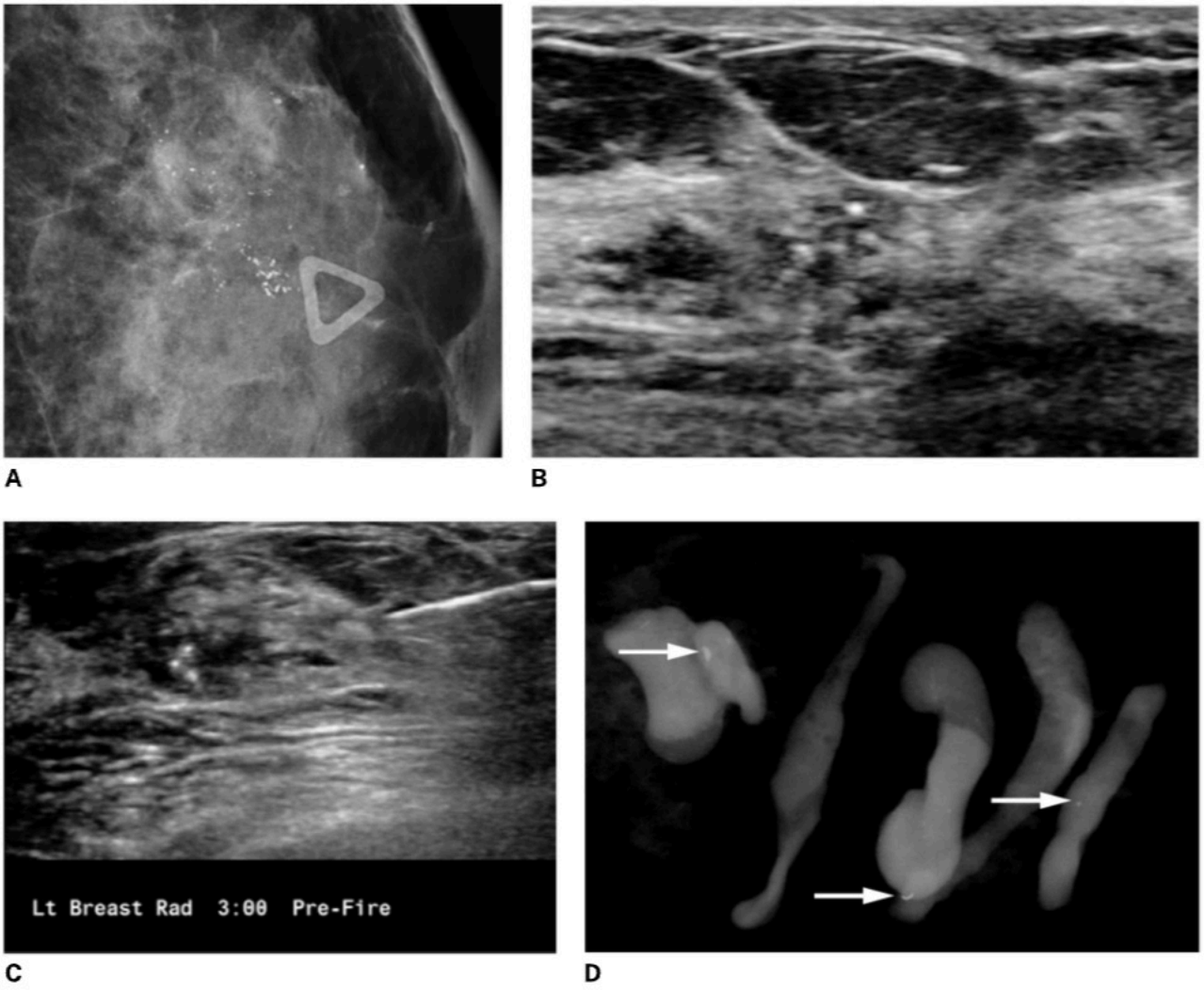

Figure 2 – CALCIFICATIONS OUTSIDE OF A MASS. (A) Mammography shows new fine pleomorphic calcifications in the left breast corresponding to a palpable mass. (B) Ultrasound shows multiple corresponding echogenic calcifications and may be considered to be within a non-mass lesion. (C) Ultrasound-guided biopsy was performed using a 12g vacuum assisted biopsy device. (D) The specimen radiograph shows a few calcifications (arrows). Pathology: Invasive ductal carcinoma, ultimately shown to be 0.5 cm in size, with 3 cm of associated DCIS.

D. CALCIFICATIONS

5. INTRADUCTAL CALCIFICATIONS

Ultrasonography may depict calcifications within a lactiferous duct, especially when distended and filled with an intraductal mass or hypoechoic contents. Ultrasound may detect both benign and malignant intraductal calcifications. Ultrasound of calcifications suspicious for DCIS may demonstrate an associated invasive component with extension beyond the duct.

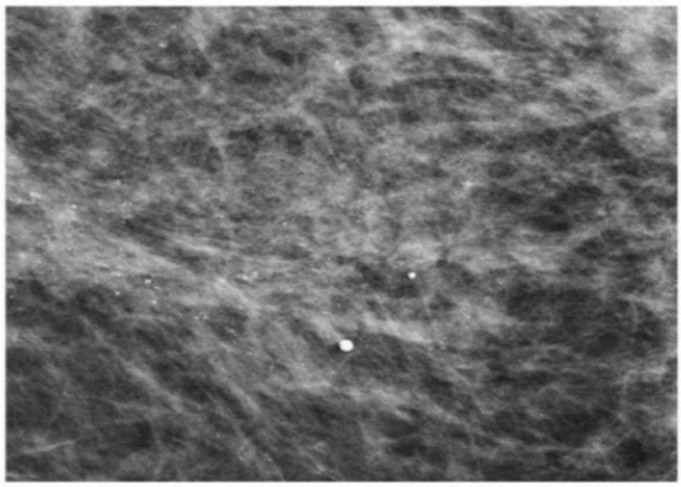

A

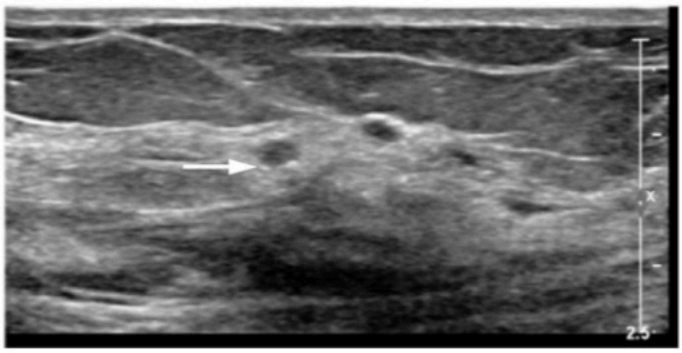

B

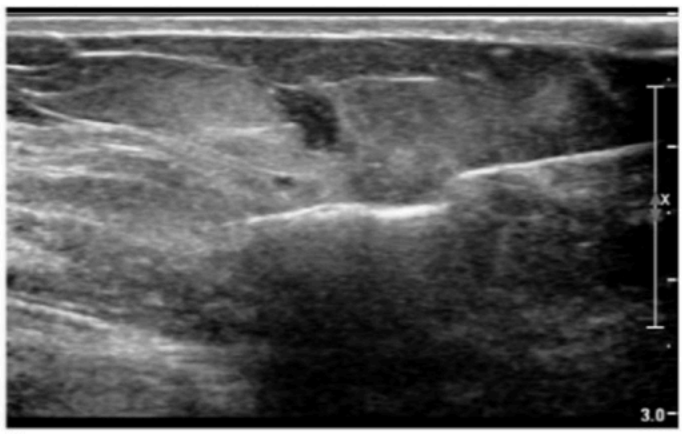

C

Figure 1 – CALCIFICATIONS WITHIN A DUCT. (A) Multiple fine pleomorphic calcifications in a segmental distribution in the left breast on mammography. (B) Ultrasound shows multiple small corresponding hypoechoic masses in a ductal distribution within the left breast. Associated echogenic foci (arrow) are consistent with CALCIFICATIONS WITHIN A DUCT and correspond to the finding on mammography. (C) US-guided biopsy was performed with a 12-gauge vacuum assisted device. Pathology: Usual ductal hyperplasia with calcifications.



A



B



C

Figure 2 – CALCIFICATIONS WITHIN A DUCT AND WITHIN A MASS. Paget's disease with left nipple changes. (A) Mammography shows an irregular mass with spiculated margins and associated calcifications extending to the left retroareolar region. (B) Ultrasound shows dilated hypoechoic ducts with echogenic calcifications extending to the nipple. (C) US also shows an irregular hypoechoic mass with calcifications and an echogenic rind. Pathology: Grade 3 invasive ductal carcinoma with extension of high-grade DCIS to the nipple epidermis.

E. ASSOCIATED FEATURES

Effects of a pathological process on its surroundings include: architectural distortion that may be manifested by compression of the tissue around the mass, obliteration of the tissue planes by an infiltrating lesion, straightening or thickening of Cooper's ligaments, aberrations of ductal patterns, and an echogenic rind. Most of these findings in the mammography lexicon are included in "architectural distortion." Findings of breast edema and skin thickening may be present, caused by inflammatory breast cancer, radiation therapy, mastitis, or a systemic process such as congestive heart failure. Color and power Doppler vascular findings of an abnormality and tissue stiffness characteristics (elastography) are also associated features. Associated features help to characterize findings and may support the distinction between malignant and benign findings. However, for management decision, lesion morphology supersedes associated features; reassuring associated features do not obviate the need to biopsy a morphologically suspicious finding.

1. ECHOGENIC PSEUDOCAPSULE

   Masses with an echogenic pseudocapsule have a thin white line surrounding an otherwise circumscribed margin. To be characterized as an echogenic pseudocapsule, the line must be uniformly thin and, importantly, must be visible around the entire margin of the mass. Oval or lobulated masses with a circumferential echogenic pseudocapsule and no suspicious features are very likely to be benign [29, 42–45], but other factors including interval growth must be considered. A round or irregular shaped mass typically should be biopsied regardless of the presence of an echogenic pseudocapsule.

   An echogenic pseudocapsule must be distinguished from an echogenic rind, which is a wider, more ill-defined echogenic band that surrounds some or all of the margin of a mass or non-mass lesion and disrupts the tissue planes adjacent to the mass. An echogenic pseudocapsule is often associated with a benign mass; in contrast, an echogenic rind is usually suspicious, and the nature of the mass must be confirmed either by imaging (e.g., fat necrosis) or biopsy.

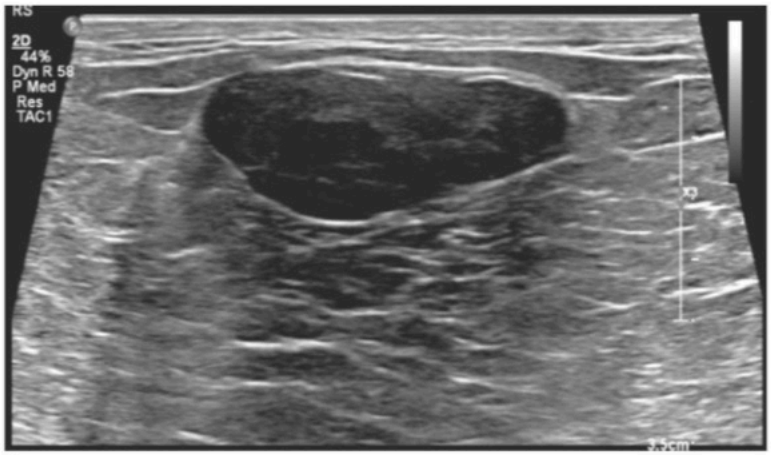

A

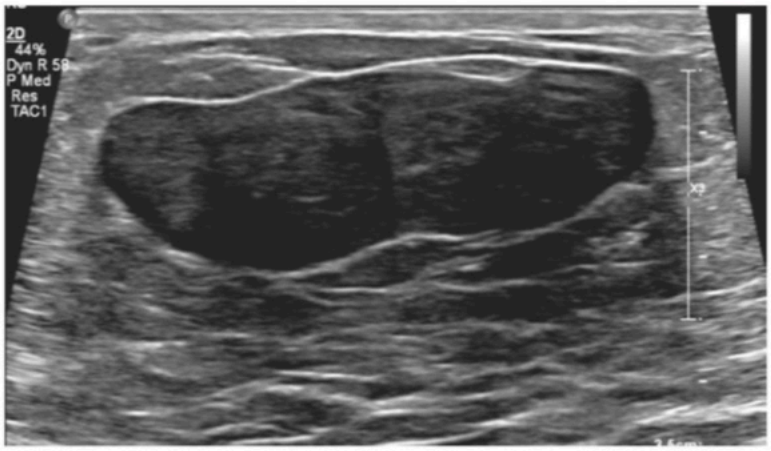

B

Figure 1 – ASSOCIATED FEATURE: ECHOGENIC PSEUDOCAPSULE. Radial (A) and antiradial (B) images of a lobulated, hypoechoic mass with parallel orientation and circumscribed margin. The mass has an associated ECHOGENIC PSEUDOCAPSULE that is uniformly thin and visible around all margins of the mass. Because this combination of features typically suggests a benign etiology, the mass was assessed as BI-RADS 3, probably benign, and 6-month imaging follow-up was recommended. The patient was then lost to follow-up but returned three years later, and the mass proved stable in size and appearance. Presumed diagnosis: Fibroadenoma.

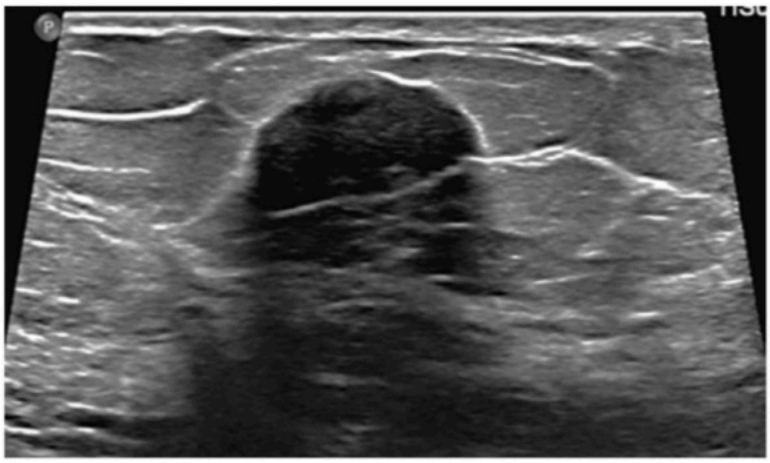

A

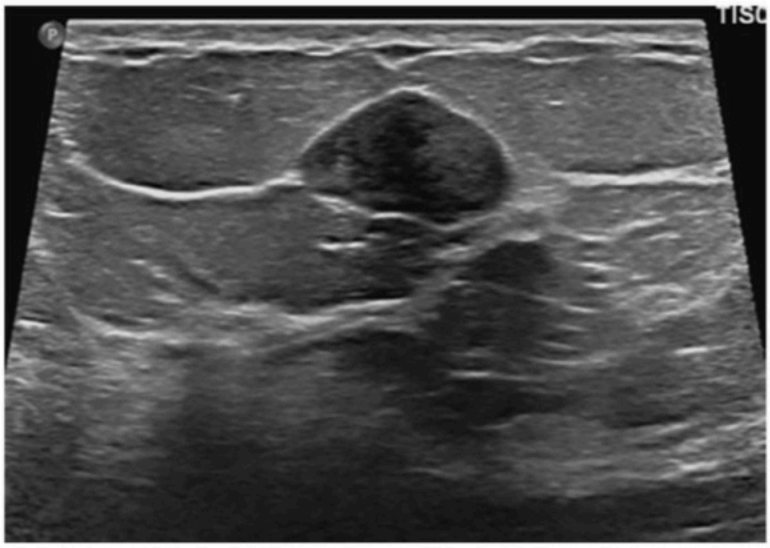

B

Figure 2 – ASSOCIATED FEATURE: ECHOGENIC PSEUDOCAPSULE. Radial (A) and antiradial (B) images of an oval, hypoechoic, shadowing mass with parallel orientation, circumscribed margin, and an ECHOGENIC PSEUDOCAPSULE that is uniformly thin and visible around the entire margin of the mass. The mass remained stable in size and appearance over a two-year time span. Presumed diagnosis: Fibroadenoma.

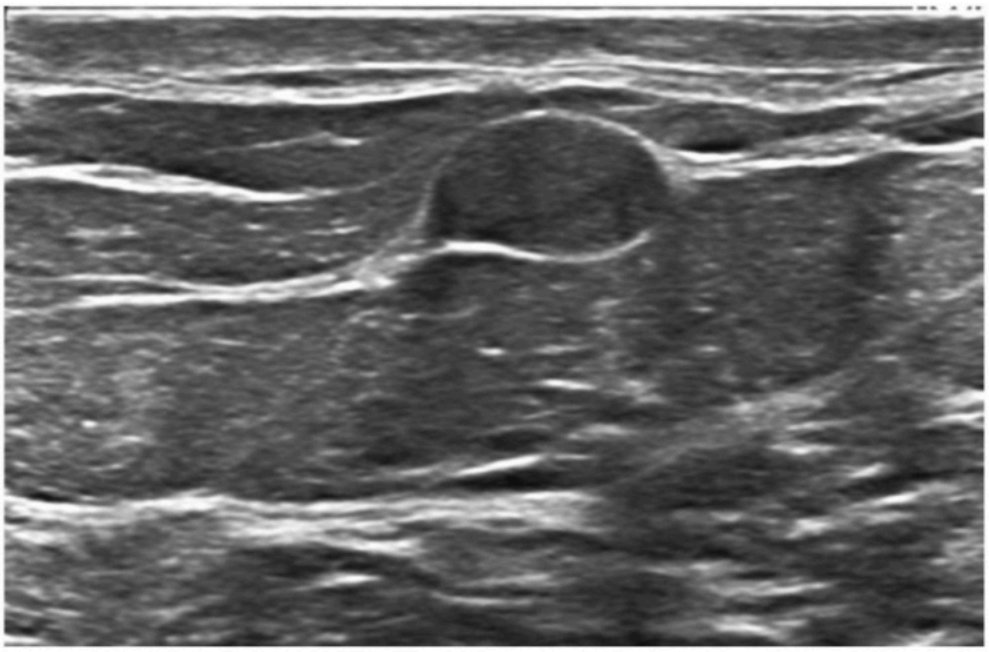

Figure 3 – ASSOCIATED FEATURE: ECHOGENIC PSEUDOCAPSULE. Ultrasound image of an oval, circumscribed, isoechoic mass with parallel orientation, no posterior features, and an ECHOGENIC PSEUDOCAPSULE. Although this combination of features is typically seen with benign masses, and the mass was assessed as BI-RADS category 3, probably benign, the patient requested a biopsy. Pathology: Fibroadenoma.

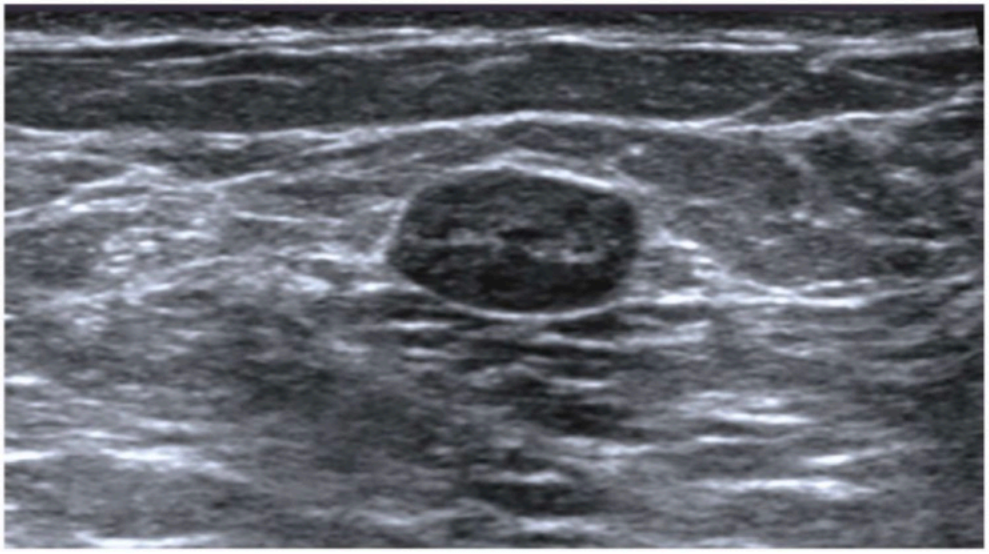

Figure 4 – ASSOCIATED FEATURE: ECHOGENIC PSEUDOCAPSULE. Ultrasound image of an oval, circumscribed mass with parallel orientation, no posterior features and an ECHOGENIC PSEUDOCAPSULE. This mass was followed with imaging and remained unchanged for two years. Presumptive diagnosis: Fibroadenoma.

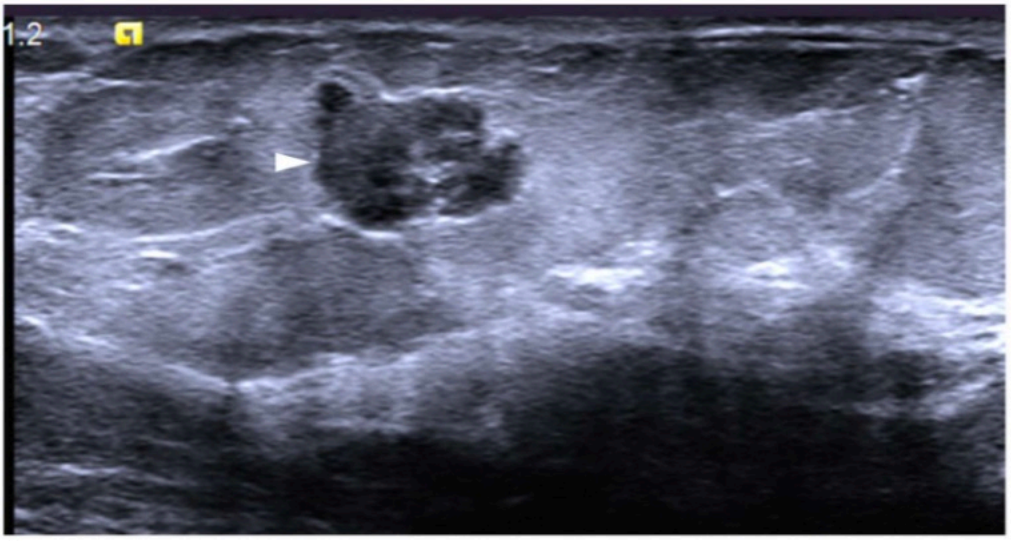

A

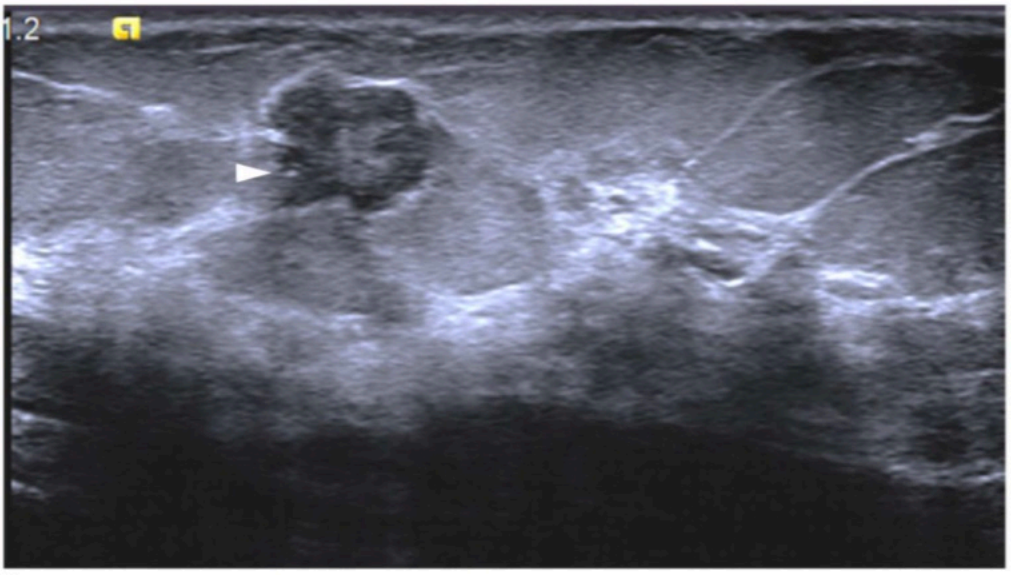

B

Figure 5 – Radial (A) and antiradial (B) ultrasound images of an irregular mass with angular margins. Although a thin echogenic line surrounds part of the mass margin, the line is discontinuous in several locations and is completely missing along a portion of the mass in both radial and antiradial images (arrowheads). Because the echogenic line is incomplete, the mass does not have an echogenic pseudocapsule. Regardless, the shape is irregular, and the margin is angular. Therefore, an echogenic pseudocapsule – even if present – would be irrelevant, and the mass is suspicious. Pathology: Invasive ductal carcinoma.

E. ASSOCIATED FEATURES

2. ECHOGENIC RIND

An echogenic rind refers to a thick echogenic band surrounding all or part of a breast mass or non-mass lesion. It disrupts the texture of the normal tissue surrounding the finding and likely represents a desmoplastic reaction or peritumoral edema.

Echogenic rinds can accompany benign and malignant findings, but the presence of this feature has a relatively high predictive value for malignancy [46–48]. An echogenic rind is a suspicious feature unless imaging features confirm the finding is definitively benign (e.g., a mass that clearly contains fat on a mammogram and represents fat necrosis), or the clinical scenario suggests potential infection, hematoma, or fat necrosis. When measuring the size of a mass or non-mass lesion, any associated echogenic rind should be included in the measurement. Studies confirm that including the rind in mass measurements provides the best correlate with the histologic measurement of tumor size [9, 10].

An echogenic rind must be distinguished from an echogenic pseudocapsule because they have essentially opposite implications. An echogenic rind is less sharply demarcated, thicker, and more variable in thickness than a uniformly thin echogenic pseudocapsule. An echogenic rind may be seen around a mass or non-mass lesion of any shape, but an echogenic pseudocapsule, which indicates a high likelihood of a benign mass, will typically only be seen associated with oval or lobulated masses.

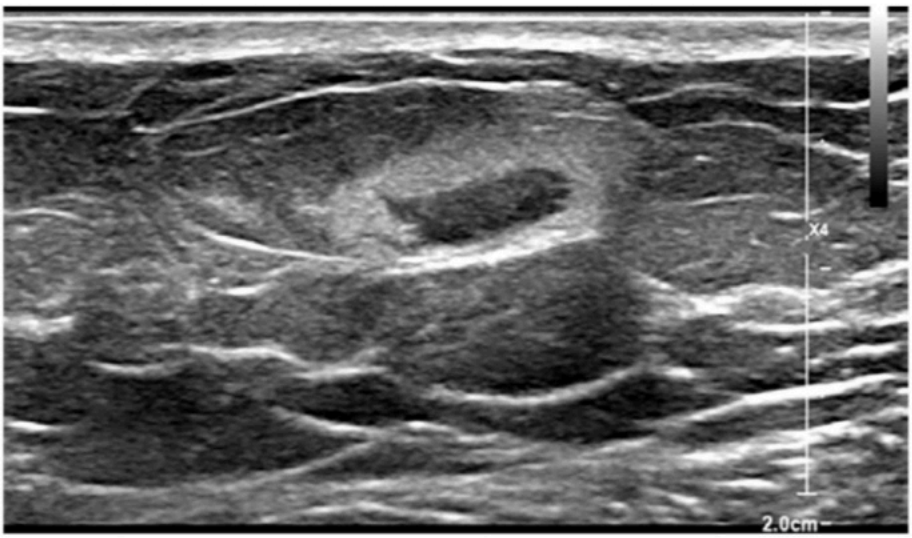

Figure 1 – ASSOCIATED FEATURE: ECHOGENIC RIND. Isoechoic, parallel mass with indistinct margin and a thick ECHOGENIC RIND in the subcutaneous fat. A mass with this combination of features lying in the subcutaneous fat raises the possibility of fat necrosis, and the mammogram should be closely inspected for a fat-containing superficial mass or asymmetry. In this case, fat could not be confirmed in the mass on mammography, and biopsy was performed. Pathology: Fat necrosis.

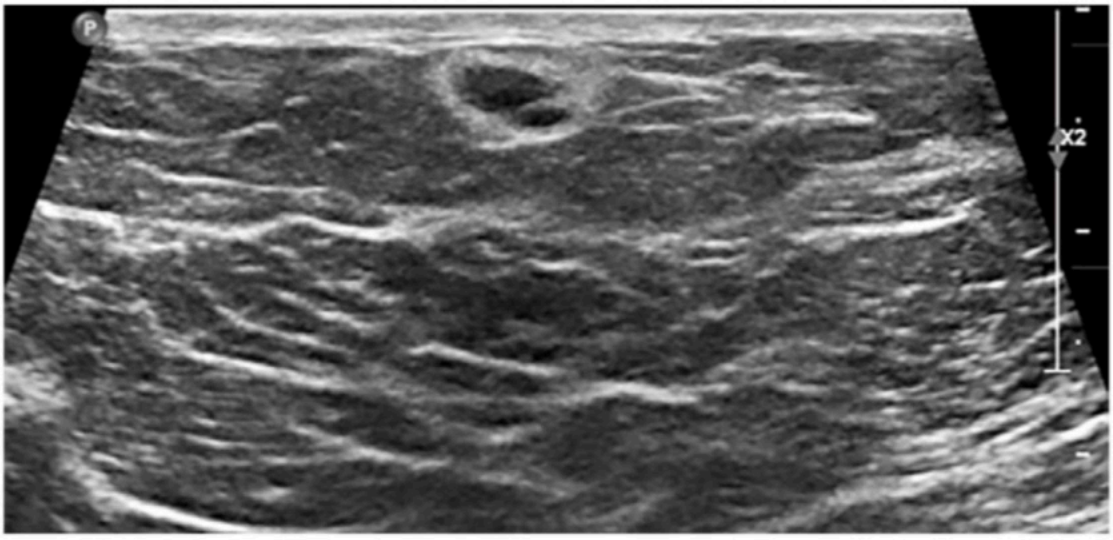

A

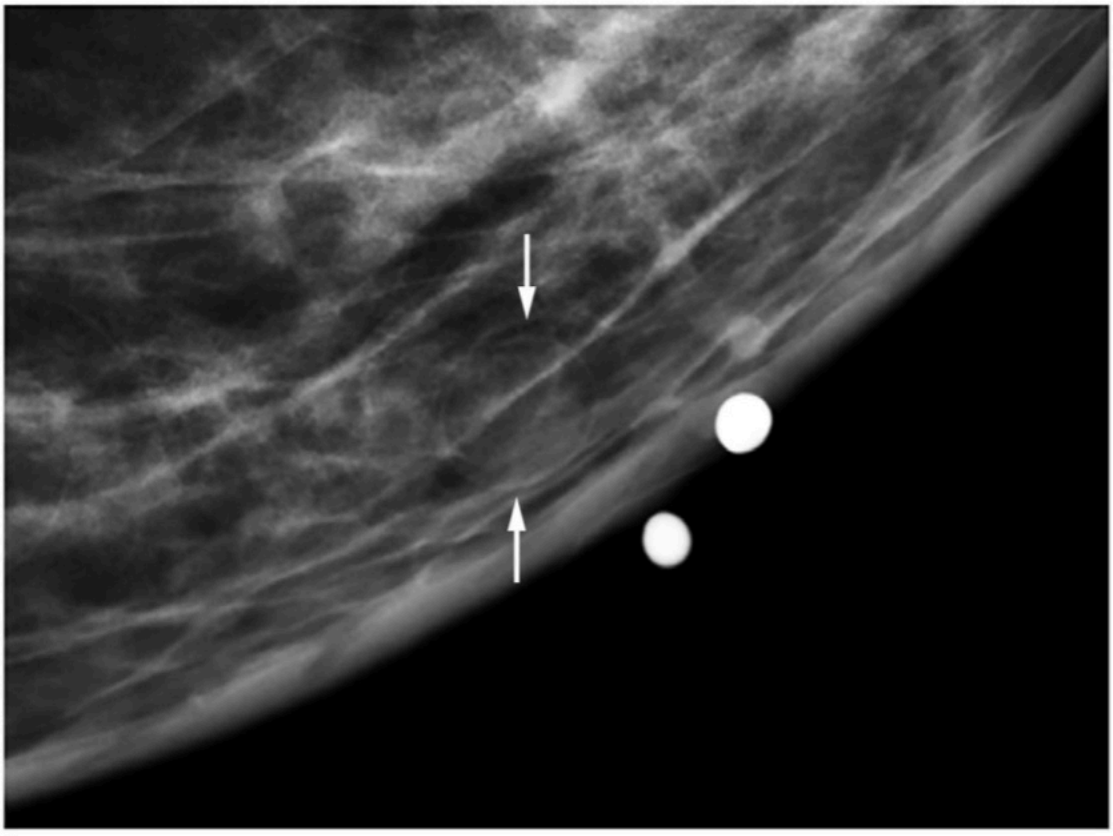

B

Figure 2 – ASSOCIATED FEATURE: ECHOGENIC RIND. Ultrasound image (A) demonstrates an oval, hypoechoic indistinct mass with parallel orientation and an associated ECHOGENIC RIND. The morphology and location of the mass in the subcutaneous fat suggests the possibility of fat necrosis. A radiopaque marker was placed over the mass, and a tangential view mammogram (B) confirms a corresponding fat-containing mass (arrows) that is diagnostic of benign fat necrosis. Note that the presence of an echogenic rind indicates the mass margin is non-circumscribed on US.

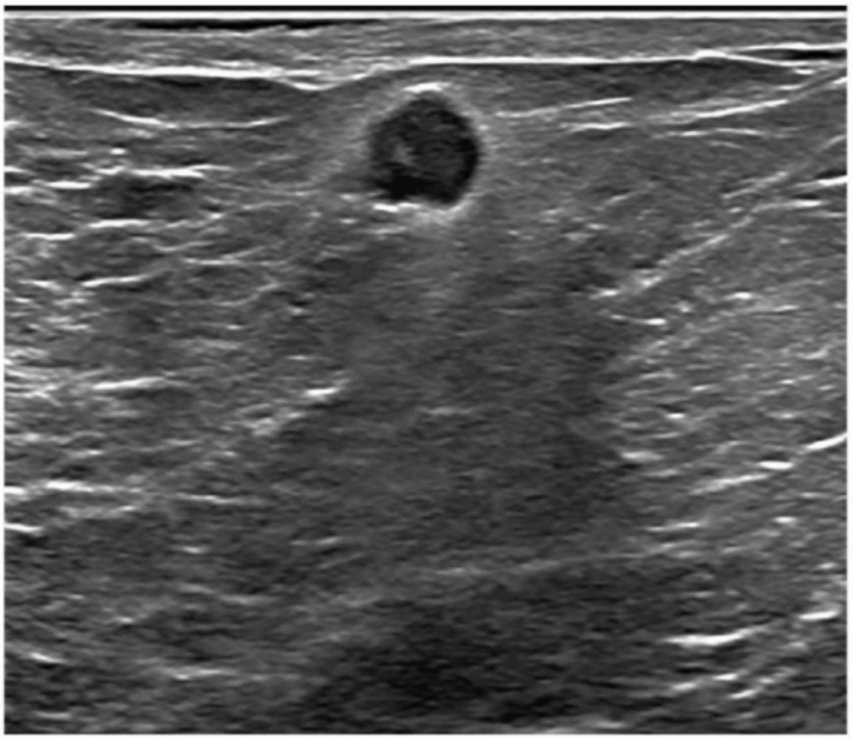

Figure 3 – ASSOCIATED FEATURE: ECHOGENIC RIND. Round, hypoechoic mass with indistinct margin and an ECHOGENIC RIND. Although the echogenic band around the mass is moderately uniform in thickness, it is too wide to be considered a pseudocapsule. It is also discontinuous – a feature that may be present with an ECHOGENIC RIND but not with an echogenic pseudocapsule. Pathology: Benign intraductal papilloma.

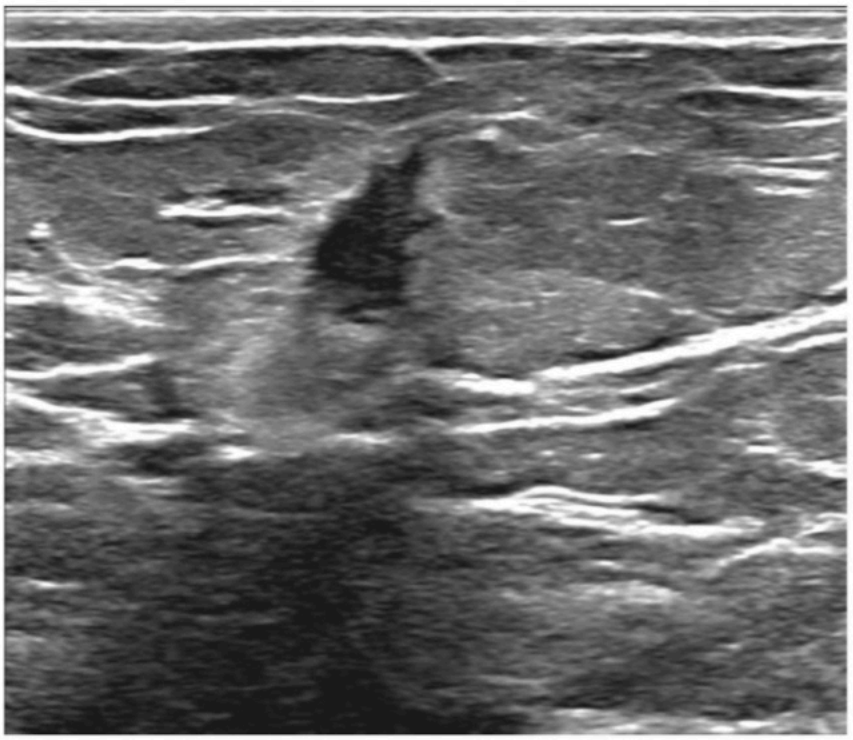

Figure 4 – ASSOCIATED FEATURE: ECHOGENIC RIND. Irregular, hypoechoic, non-parallel mass with angular margin and an ECHOGENIC RIND. This combination of findings is typically suspicious for malignancy, and this mass was assessed as BI-RADS category 4C, suspicious-high suspicion for malignancy. Fortunately, histopathology was benign and concordant. Pathology: Fibromatosis.

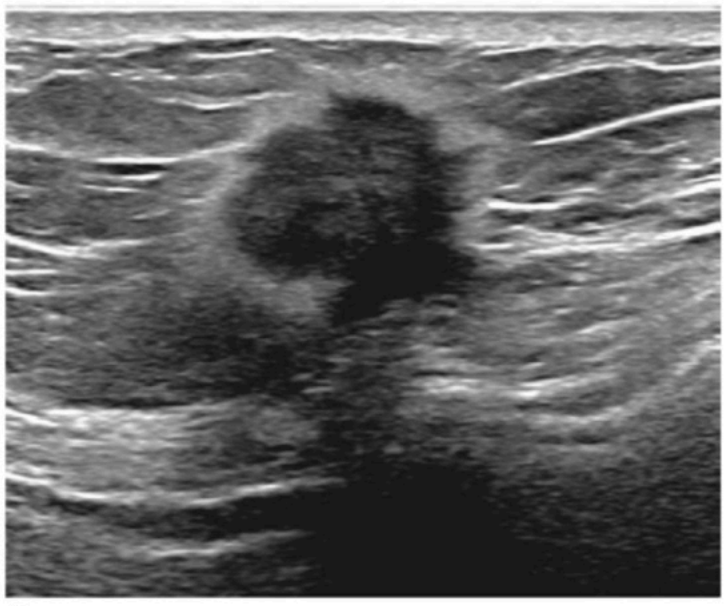

A



B

Figure 5 – ASSOCIATED FEATURE: ECHOGENIC RIND. Irregular, heterogeneous, non-parallel mass with spiculated margin and a robust ECHOGENIC RIND (A and B). The ECHOGENIC RIND should be included when measuring the size of this mass. Pathology: Invasive ductal carcinoma.

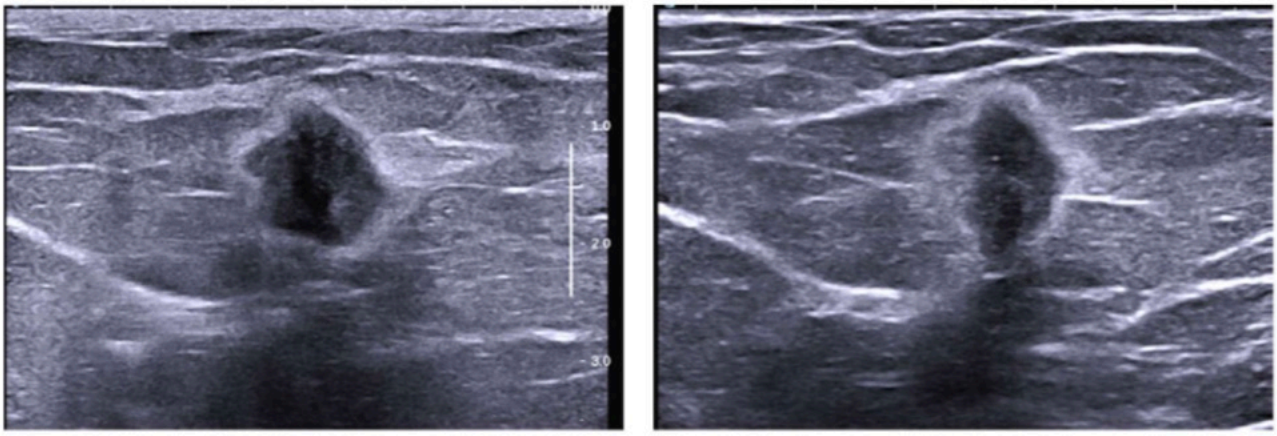

A B

Figure 6 – ASSOCIATED FEATURE: ECHOGENIC RIND. Radial (A) and antiradial (B) ultrasound images of a hypoechoic, lobulated mass with non-parallel orientation, indistinct margin and an ECHOGENIC RIND. The ECHOGENIC RIND disrupts the echotexture of the fat tissue surrounding the mass. The ECHOGENIC RIND should be included in all measurements of the mass. Pathology: Invasive ductal carcinoma.

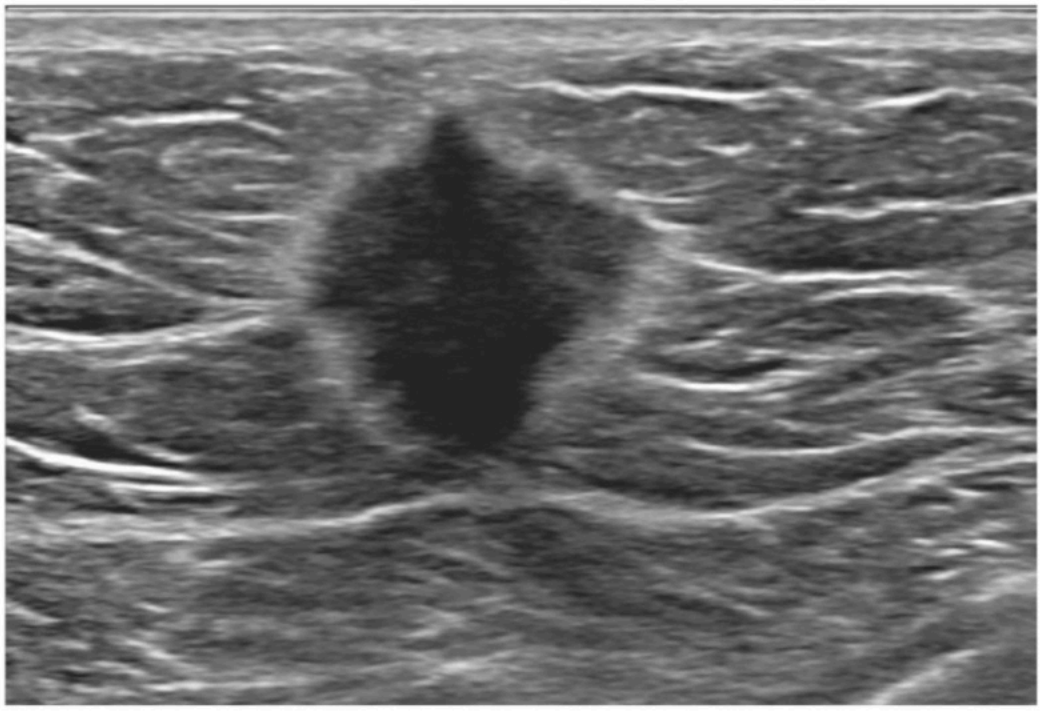

Figure 7 – ASSOCIATED FEATURE: ECHOGENIC RIND. Radial ultrasound image of an irregular, hypoechoic mass with an angular margin and an ECHOGENIC RIND. Pathology: Invasive ductal carcinoma.

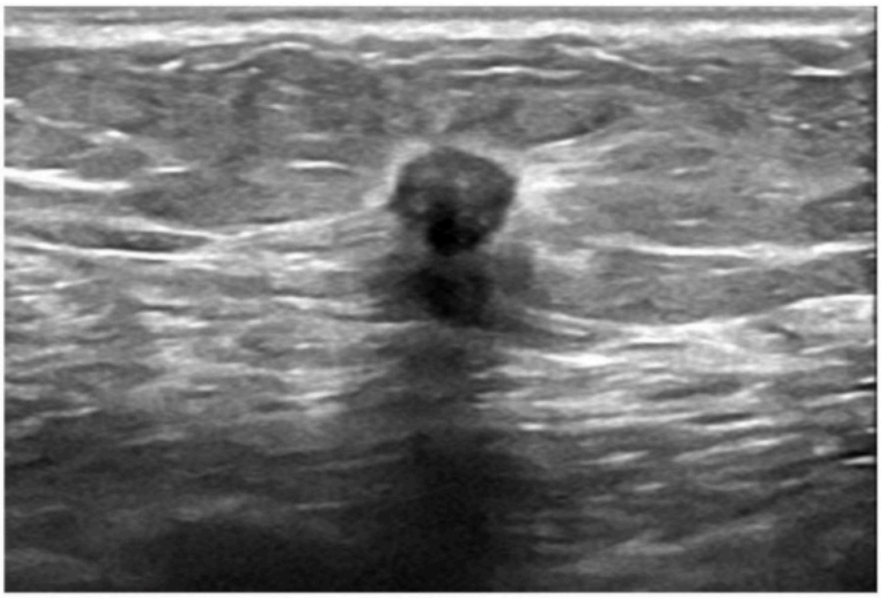

A

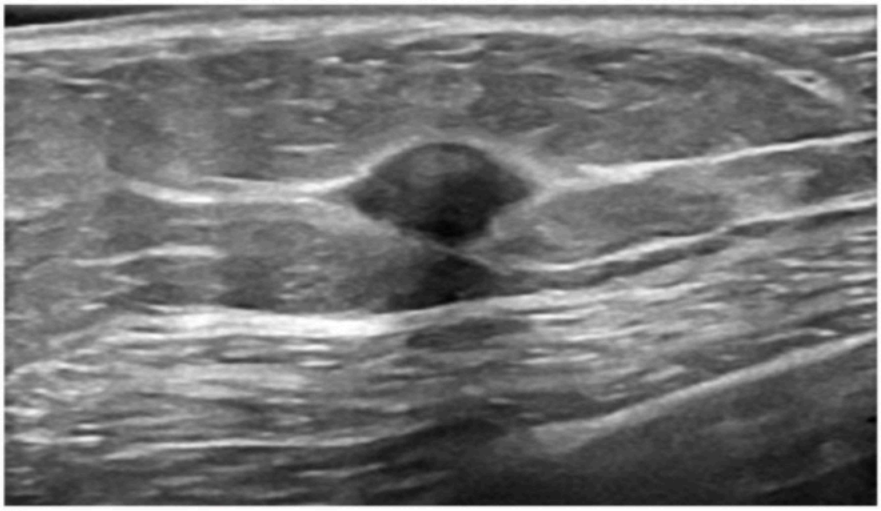

B

Figure 8 – ASSOCIATED FEATURE: ECHOGENIC RIND. Radial (A) and antiradial (B) ultrasound images of an oval, non-parallel mass with angular margin and posterior shadowing. There is associated architectural distortion and an ECHOGENIC RIND. Pathology: Invasive ductal carcinoma.

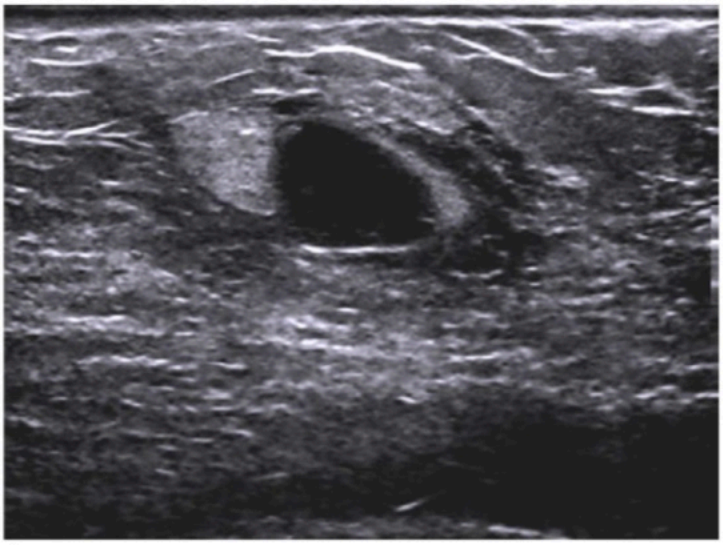

A

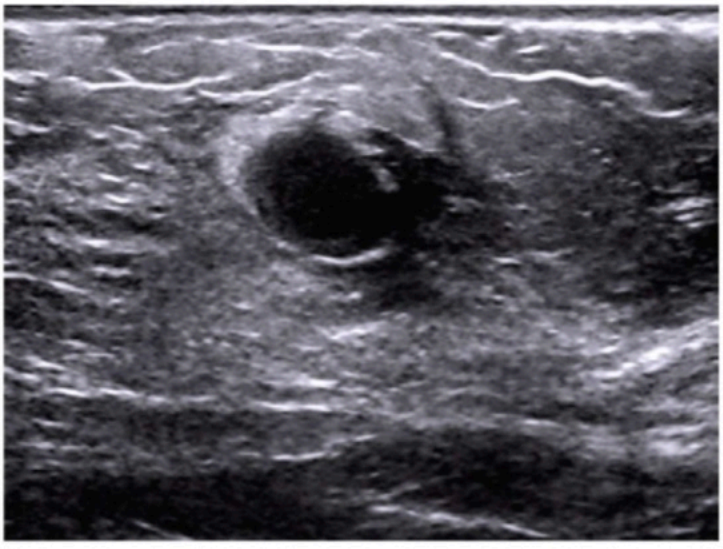

B

Figure 9 – ASSOCIATED FEATURE: ECHOGENIC RIND. Radial (A) and antiradial (B) ultrasound images of an oval, anechoic, indistinct mass with no posterior features. The presence of an ECHOGENIC RIND indicates this mass is not a simple cyst. Pathology: Metastasis from colon carcinoma.

E. ASSOCIATED FEATURES

3. ARCHITECTURAL DISTORTION

Architectural distortion is seen as thin lines radiating from a point and/or focal retraction or straightening of the breast parenchyma, representing distortion of tissue planes. It may be associated with a mass or non-mass lesion. Architectural distortion is commonly a sequela of postsurgical scarring, or it may represent a radial scar, increasingly detected with DBT. At the same time, architectural distortion may be the imaging manifestation of the desmoplastic reaction of a cancer.

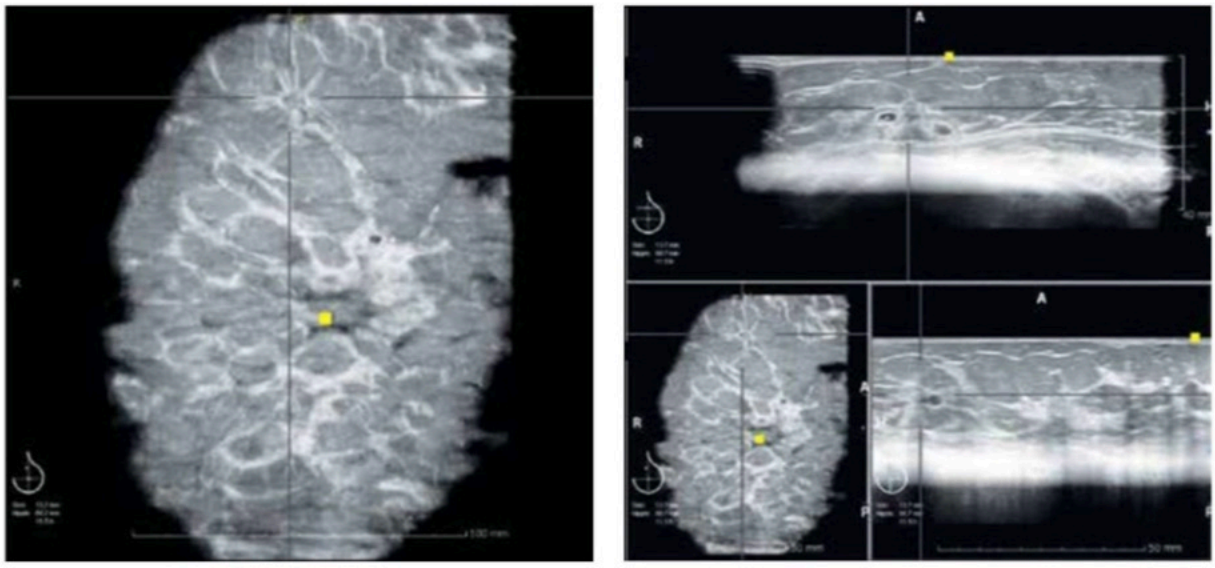

A B

Figure 1 – ASSOCIATED FEATURE: ARCHITECTURAL DISTORTION. Automated US, whole breast coronal reconstruction (A), shows crosshairs defining small isoechoic mass at 11:00 in the left breast with ARCHITECTURAL DISTORTION. (B) Top image is from the volumetric acquisition (transverse), crosshairs correlating the small mass with its appearance on the other views, coronal on lower left and sagittal on lower right image, to provide 3D depiction. Tissue composition is fatty, and the artifact or defect at the upper right edge of the coronal view is due to lack of contact of the transducer with the skin. Pathology: Invasive ductal carcinoma, grade 2. Note incidental nearby cysts.

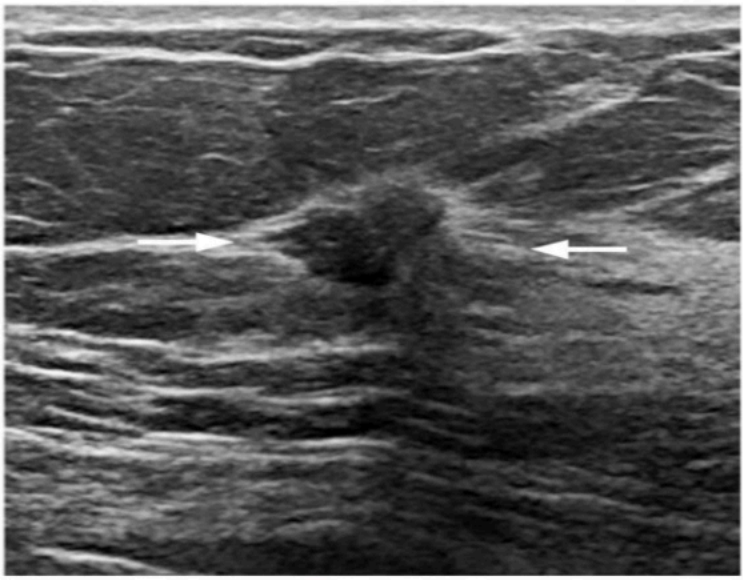

A

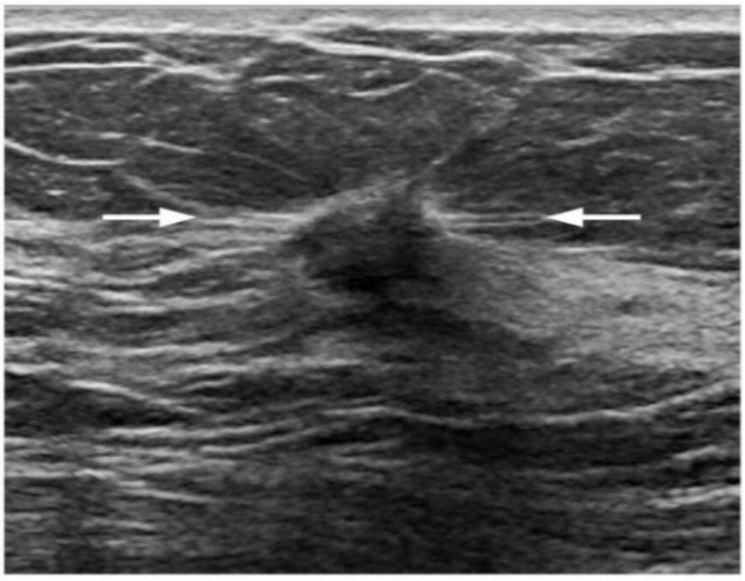

B

Figure 2 – ASSOCIATED FEATURE: ARCHITECTURAL DISTORTION: Longitudinal (A) and transverse (B) US images of an irregular, spiculated, hypoechoic mass. Note the ARCHITECTURAL DISTORTION of the adjacent tissues (arrows), manifesting as radiating lines and straightening of Cooper's ligaments surrounding the mass, representing desmoplastic reaction of the adjacent tissues.

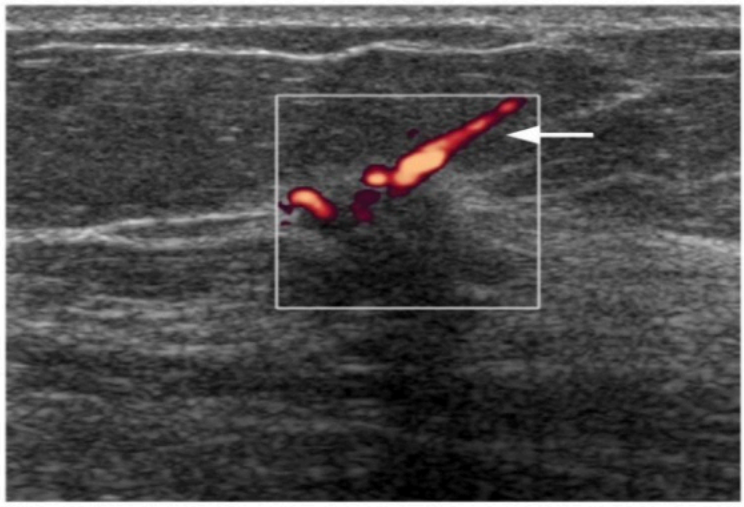

C

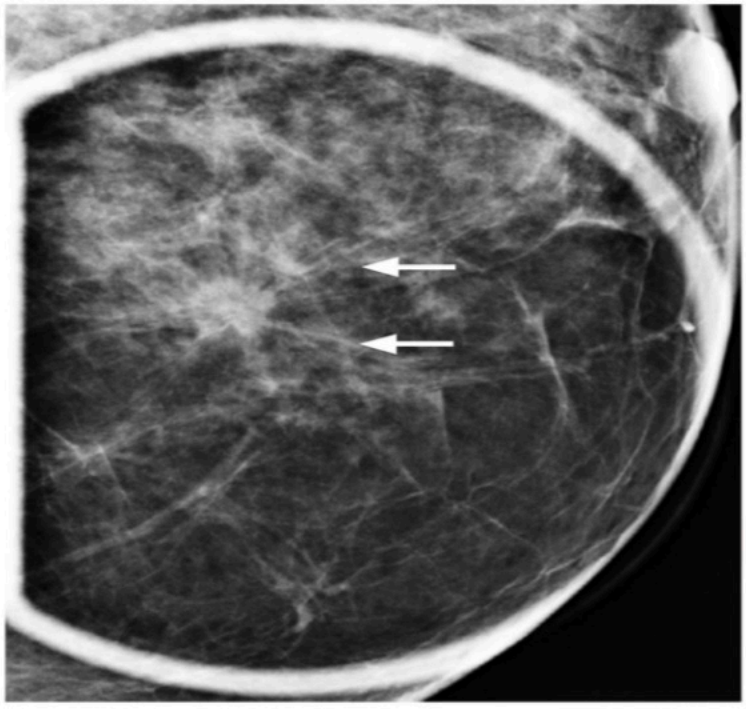

D

Figure 2 – *(Continued)* ASSOCIATED FEATURE: ARCHITECTURAL DISTORTION: Doppler US image in the transverse plane (C) and CC spot magnification mammogram (D) of the irregular spiculated mass. Note the vascularity (arrow in C) adjacent to ARCHITECTURAL DISTORTION seen at gray-scale imaging. The lines representing ARCHITECTURAL DISTORTION are also seen at mammography (arrows in D). Pathology: Grade 1 invasive carcinoma of mixed ductal and lobular histology.

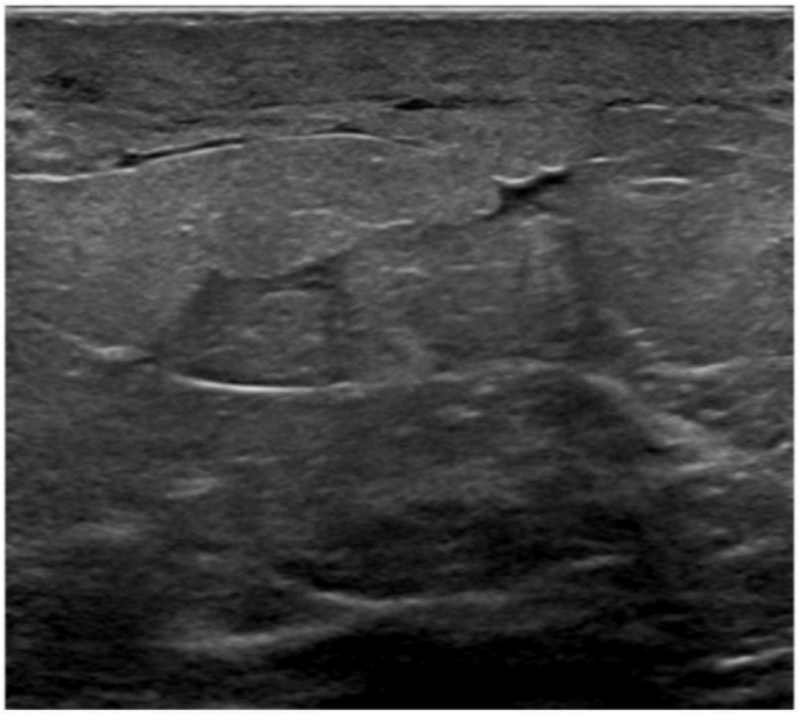

Figure 3 – ASSOCIATED FEATURE: ARCHITECTURAL DISTORTION: US image of patient with inflammatory breast carcinoma showing skin thickening, fluid intercalating in the tissue planes consistent with edema, areas of shadowing, and diffuse distortion of tissues. Pathology: Invasive ductal carcinoma.

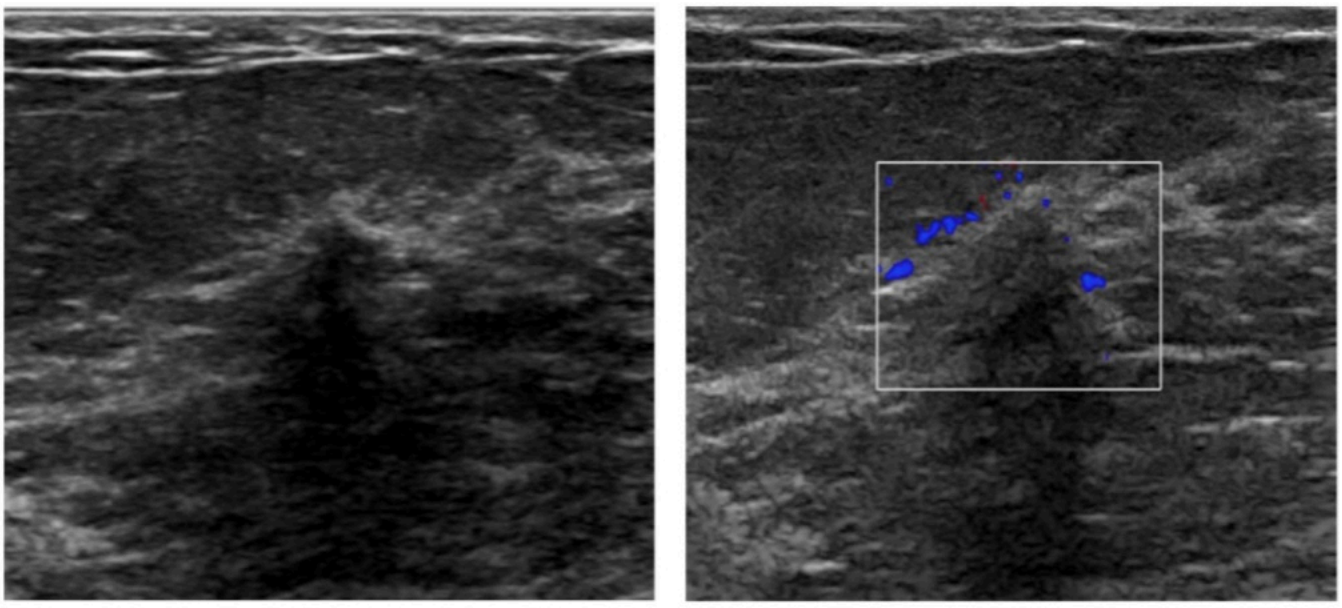

A B

Figure 4 – ASSOCIATED FEATURE: ARCHITECTURAL DISTORTION: Gray-scale (A) and Doppler (B) US images in the longitudinal plane of a hypoechoic irregular mass with radiating strands representing architectural distortion. Pathology: Stromal fibrosis.

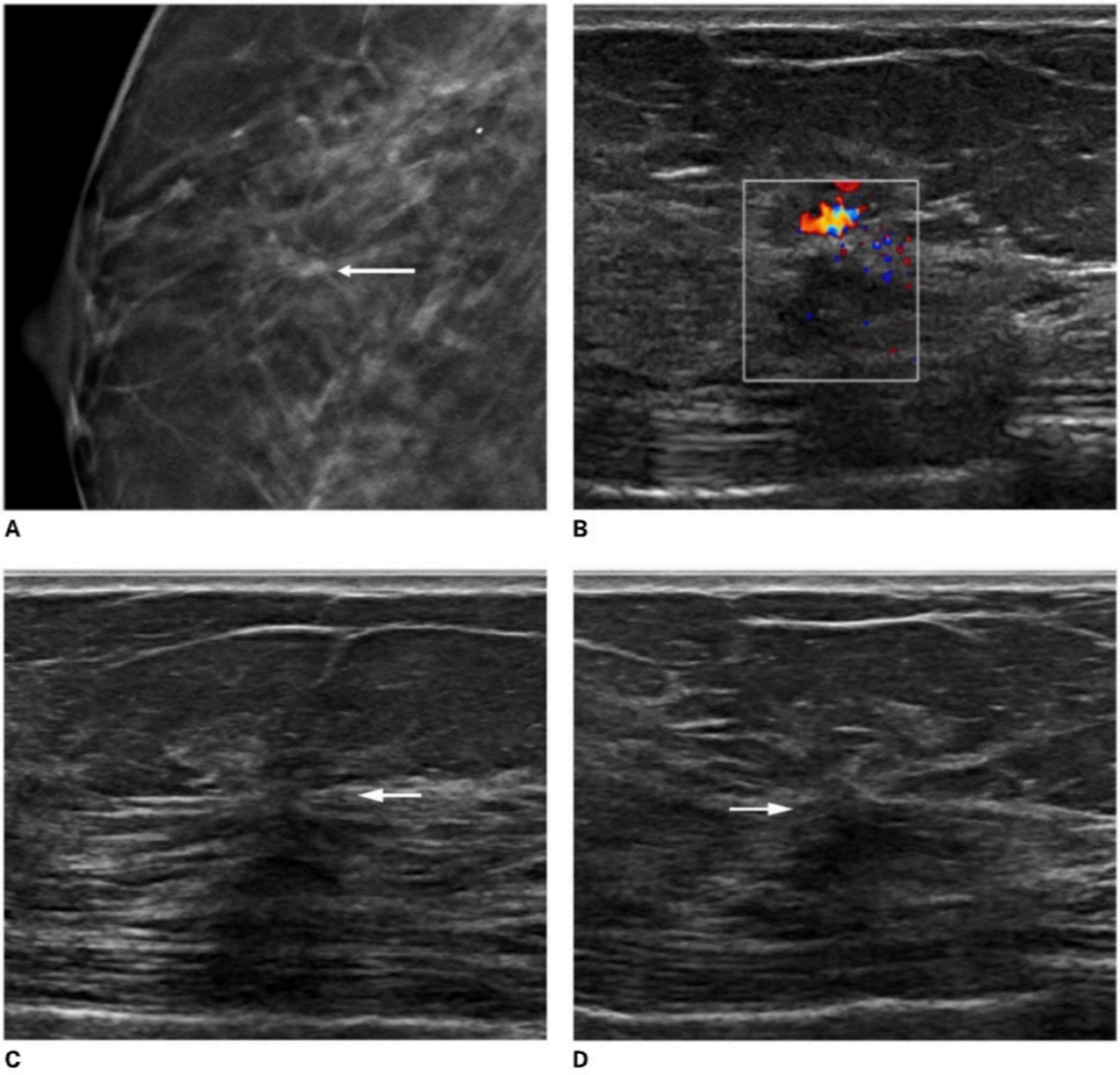

Figure 5 – ASSOCIATED FEATURE: ARCHITECTURAL DISTORTION: Spot compression DBT image (A) shows a subtle architectural distortion (arrow). Doppler US image (B) and gray-scale US images in the longitudinal (C) and transverse (D) planes show subtle architectural distortion (arrows). There are radiating lines and mild posterior shadowing but absence of a central mass. Pathology: Radial scar.

E. ASSOCIATED FEATURES

4. DUCT CHANGES

Breast ducts converge radially toward the nipple. Normally, ducts have a smooth contour and progressively dilate as they converge on the nipple, terminating in the ampulla, such that the retroareolar ducts are usually larger in caliber than peripheral ducts. Normal ducts can measure < 2 mm peripherally and < 3 mm in the retroareolar region, but this range of normal is highly variable.

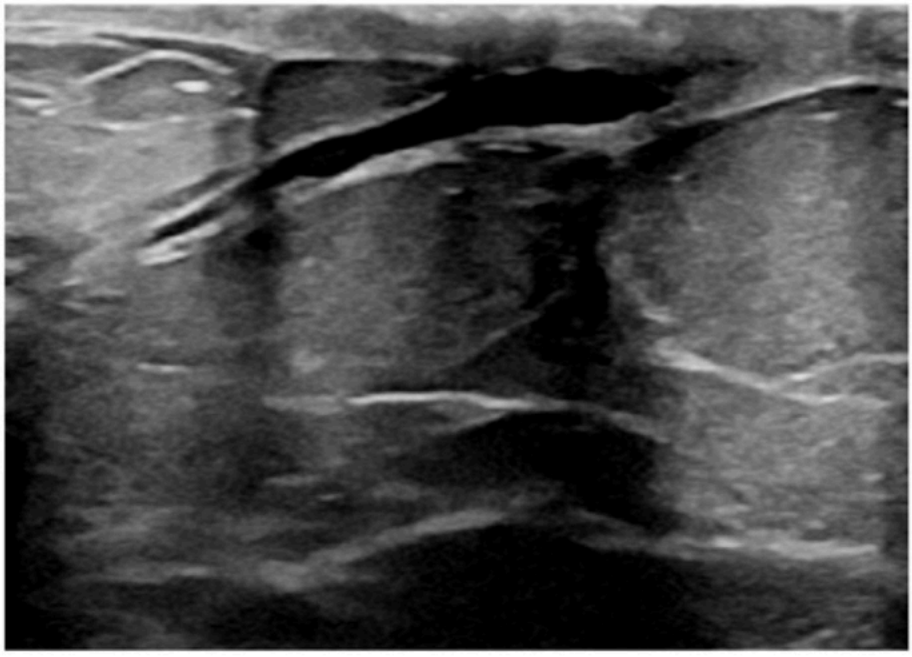

Figure 1 – ASSOCIATED FEATURE: DUCT CHANGES. Retroareolar US shows DUCT CHANGES, characterized by an asymmetric, unilateral dilated duct (detected on screening mammography) without filling defects. In retrospect, comparison mammograms demonstrated 5 years of stability, and this duct was assessed as benign.

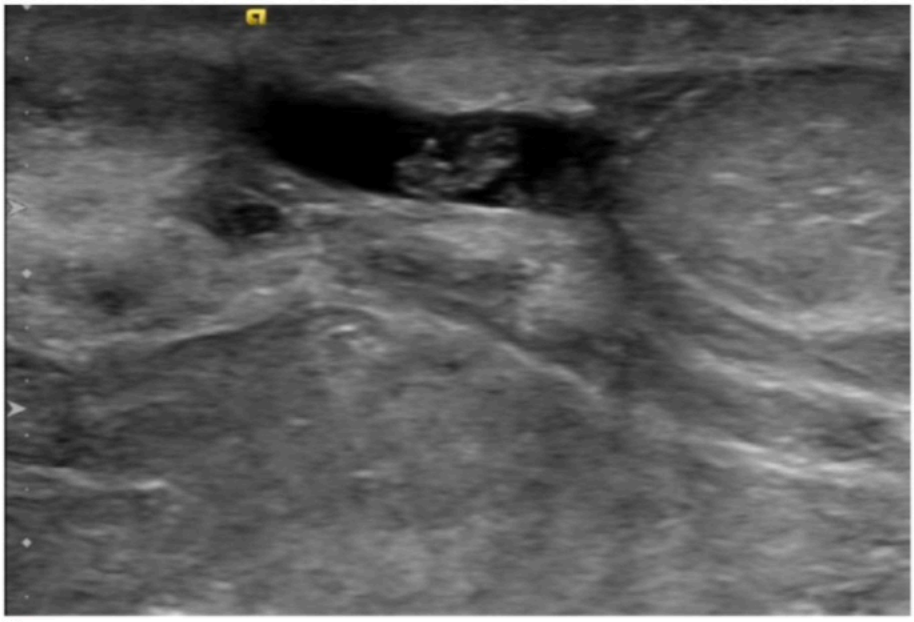

A

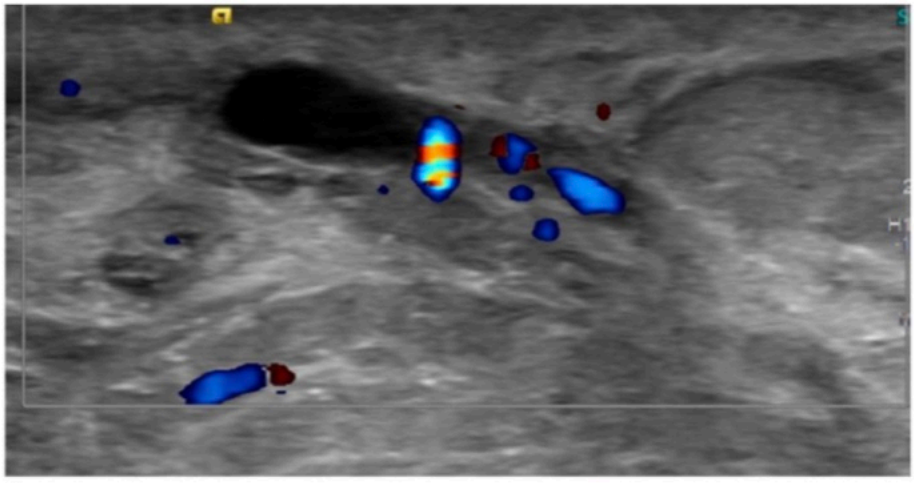

B

Figure 2 – ASSOCIATED FEATURE: DUCT CHANGES. A woman with clear left nipple discharge. US shows DUCT CHANGES with a dilated duct and an intraductal mass (A). The intraductal mass demonstrates internal vascularity on color Doppler (B). Pathology: Intraductal papilloma without atypia.

E. ASSOCIATED FEATURES

5. SKIN CHANGES

a. Skin Thickening

Skin thickening is defined as the skin thickness measuring > 2 mm, though in the periareolar area, normal skin thickness may be up to 4 mm [49]. Subtle skin thickening can be confirmed by demonstrating asymmetry compared to the contralateral breast skin thickness. Additionally, with skin thickening, there is often loss of the two echogenic lines that define the normal skin layer (see Figure 7, Anatomy: Normal Skin complex).

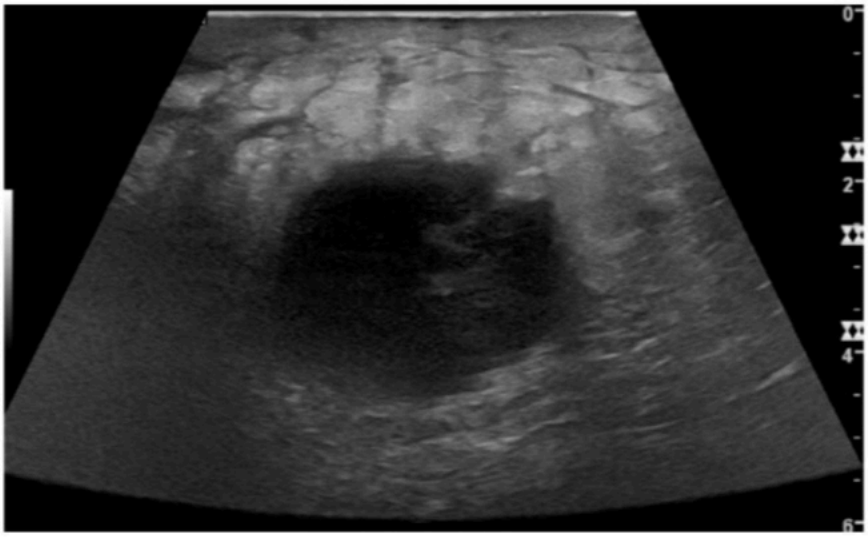

Figure 1 – SKIN CHANGES: SKIN THICKENING. A woman with clinical diagnosis of right inflammatory breast cancer. US shows a round indistinct hypoechoic mass with posterior enhancement. There is SKIN THICKENING and edema overlying the mass as well as loss of the two echogenic lines that define the normal skin layer. Pathology: Invasive ductal carcinoma.

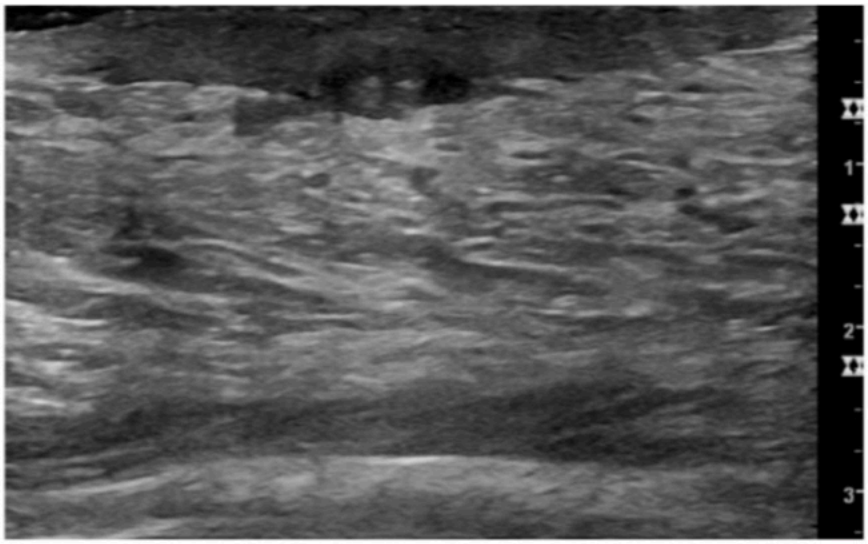

Figure 2 – SKIN CHANGES: SKIN THICKENING. A woman with right breast pain and erythema in the periareolar region. US shows focal SKIN THICKENING in the periareolar region, consistent with cellulitis/mastitis. There is also loss of the two echogenic lines that define the normal skin layer. No abscess is identified.

E. ASSOCIATED FEATURES

5. SKIN CHANGES

   b. Skin Retraction

   The skin surface is concave, indented, and appears fixed. Skin retraction may be associated with an underlying mass, architectural distortion, or postoperative scar.

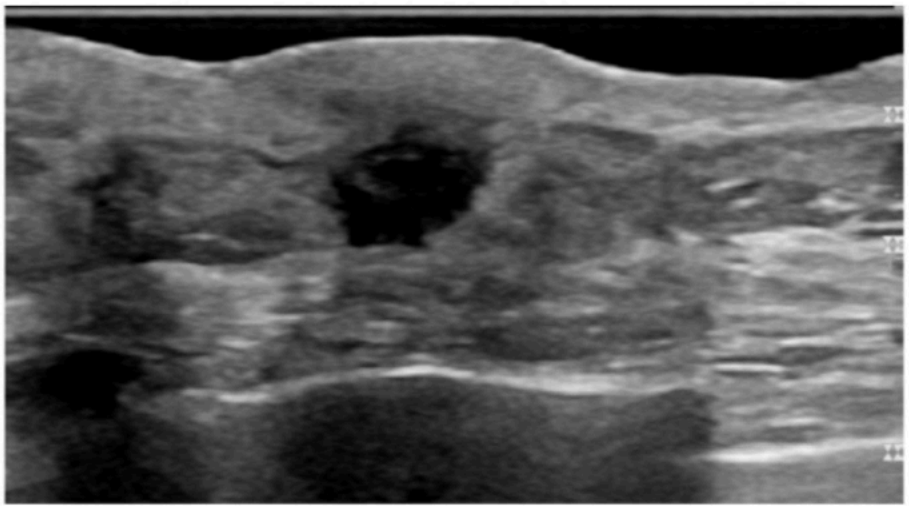

Figure 3 – SKIN CHANGES: SKIN RETRACTION and skin thickening. A woman with history of right mastectomy six years ago presents with a new oval indistinct hypoechoic mass in the mastectomy scar. US shows multiple areas of fixed skin indentation, indicative of SKIN RETRACTION from surgical scarring. There is also skin thickening. Pathology: Invasive ductal carcinoma.

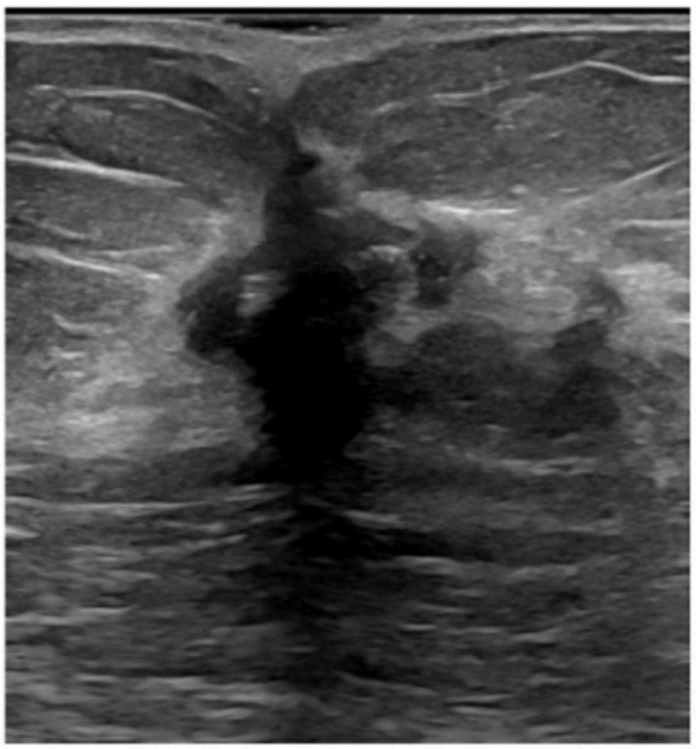

Figure 4 – SKIN CHANGES: SKIN RETRACTION. US shows an irregular, hypoechoic, non-parallel, shadowing mass with indistinct margin and overlying SKIN RETRACTION. Pathology: Invasive lobular carcinoma.

E. ASSOCIATED FEATURES

6. EDEMA

Edema is characterized by interconnected, arborizing hypoechoic or anechoic lines, representing either dilated lymphatics or interstitial fluid. Edema is often accompanied by skin thickening. It is helpful to distinguish edema as unilateral or bilateral. Unilateral edema suggests a focal process, such as inflammatory breast cancer, mastitis, or post-radiation therapy changes. Bilateral edema suggests a systemic disorder, such as congestive heart failure, renal failure, or central venous obstruction.

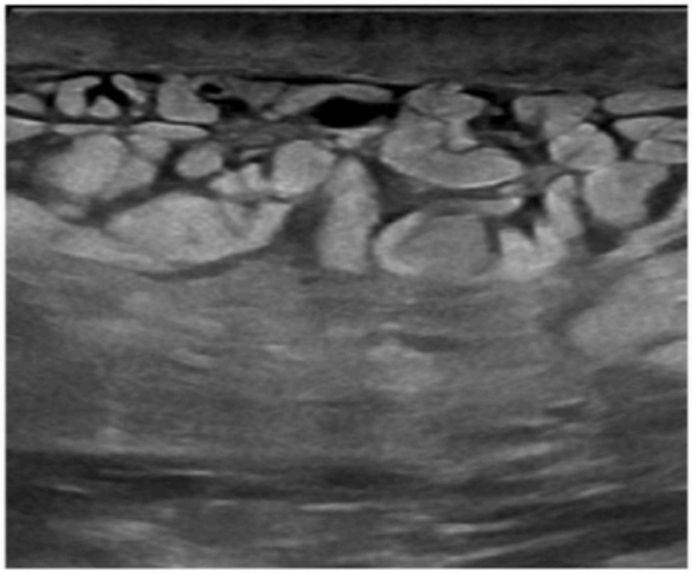

Figure 1 – ASSOCIATED FEATURE: EDEMA. A woman with end stage renal disease and chronic edema. US shows interstitial fluid in a reticulated pattern in the subcutaneous fat, indicating EDEMA. There is also skin thickening.

E. ASSOCIATED FEATURES

7. VASCULARITY

Vascularity is assessed using power and color Doppler. While vascular patterns may support some diagnoses, they cannot be used as the sole diagnostic criteria. No vascular pattern is specific for any particular diagnosis. Both benign and malignant masses may demonstrate increased, minimal, or no vascularity [50].

a. Avascular

Avascular lesions demonstrate no vascularity on color or power Doppler. Cysts are common avascular lesions. The absence of vascularity in a solid mass suggests that it has little or no blood flow. However, technical factors such as sensitivity settings for color Doppler (pulse repetition frequency should be set for slow flow) may suppress the display of vascularity, falsely making a lesion appear avascular. Additionally, transducer pressure should be minimal, as tissue compression may inadvertently occlude small vessels and give a false avascular assessment.

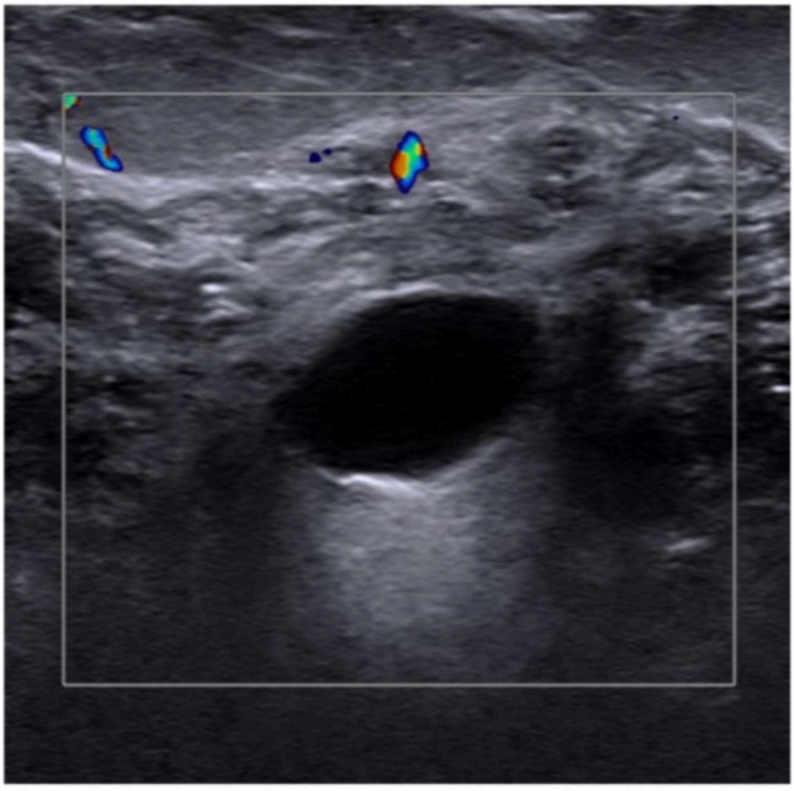

Figure 1 – VASCULARITY: AVASCULAR. This benign simple cyst is AVASCULAR. Absence of vascularity supports the conclusion that this lesion is fluid-filled.

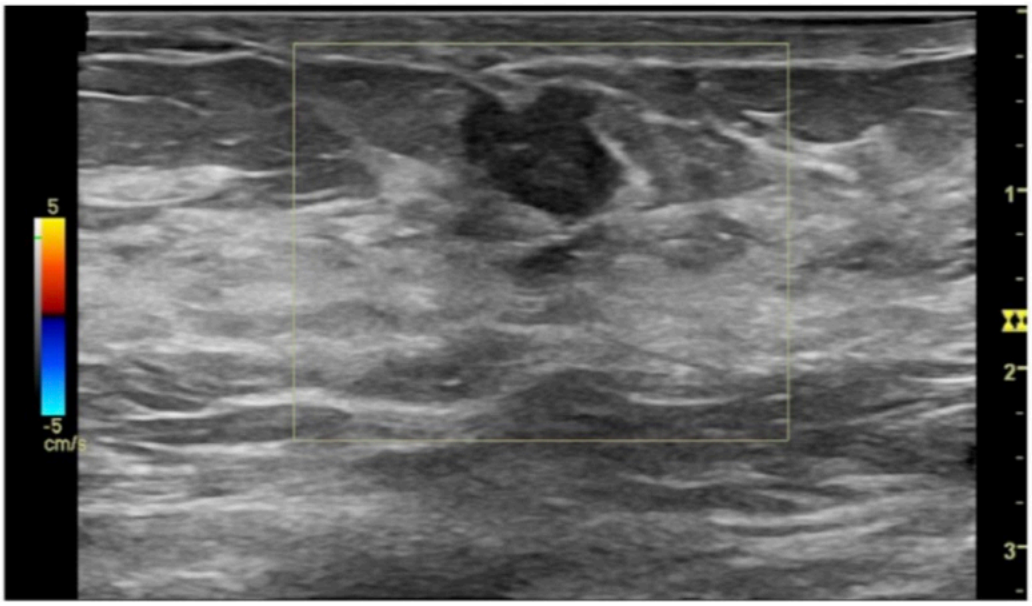

Figure 2 – VASCULARITY: AVASCULAR. US demonstrates an irregular, hypoechoic mass with angular margin. Color Doppler shows that this mass is AVASCULAR. However, the suspicious morphology supersedes the absence of vascularity, and US-guided core biopsy was performed. Pathology: Invasive ductal carcinoma.

E. ASSOCIATED FEATURES

7. VASCULARITY

b. Internal Vascularity

Internal vascularity on color Doppler indicates that blood vessels are present within the finding. Typically, internal vascularity confirms that a mass is solid or has solid components, as cysts do not contain internal blood vessels. When assessing internal vascularity of non-mass lesions, the frame of reference is not simply the presence or absence of internal flow (as with masses) but rather the degree of vascularity compared to normal tissue elsewhere in the breast or a similar location in the contralateral breast. In general, non-mass lesions would be expected to have increased vascularity relative to normal tissue elsewhere in the breast.

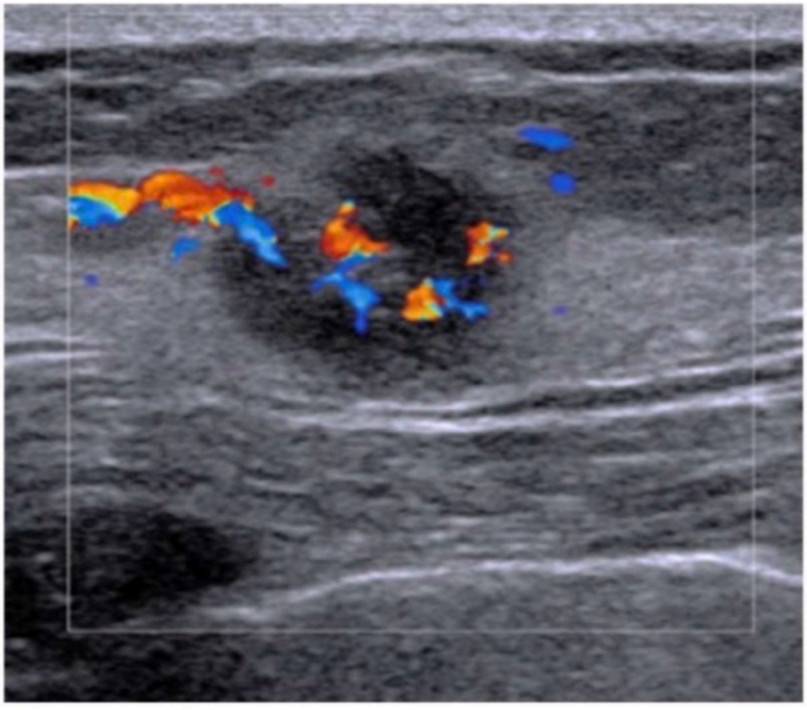

Figure 3 – VASCULARITY: INTERNAL VASCULARITY. An irregular mass with indistinct margin. Color Doppler shows INTERNAL VASCULARITY, consistent with a solid mass. Pathology: Invasive ductal carcinoma.

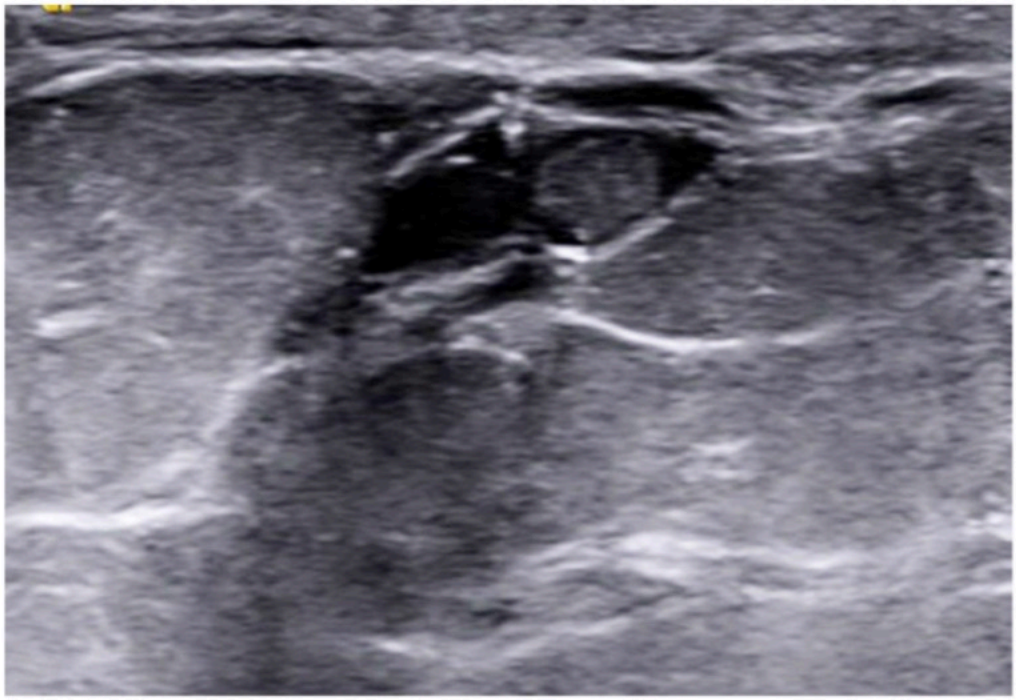

A

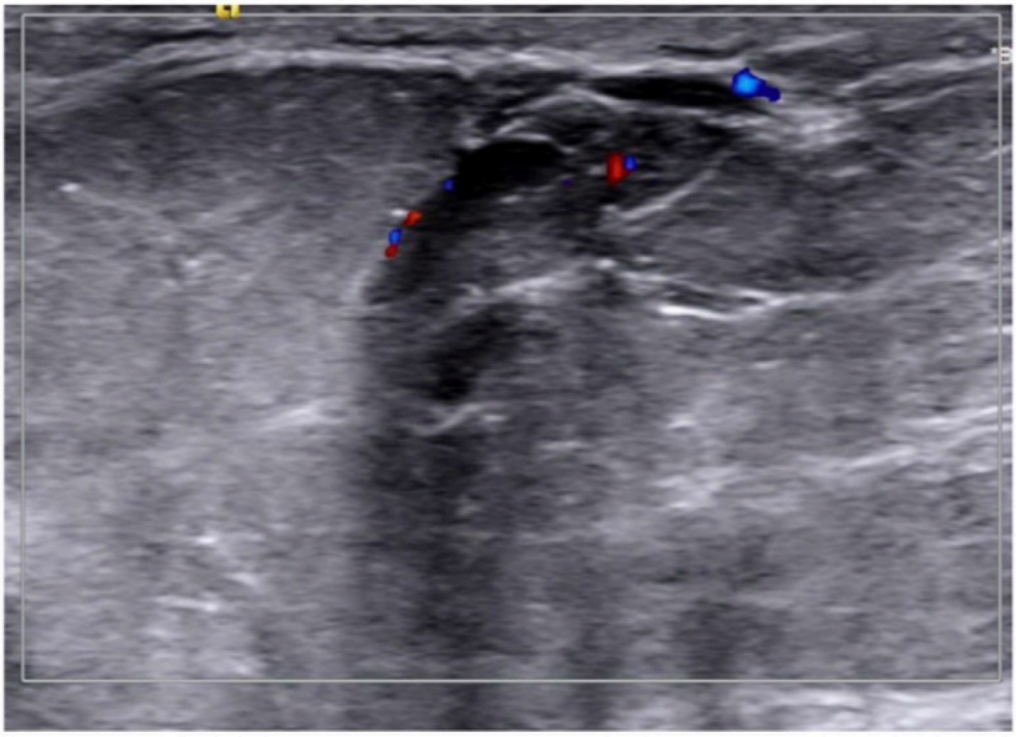

B

Figure 4 – VASCULARITY: INTERNAL VASCULARITY. Conventional grayscale US (A) shows an intraductal mass. Color Doppler (B) shows INTERNAL VASCULARITY within the intraductal mass. Pathology: Intraductal papilloma.

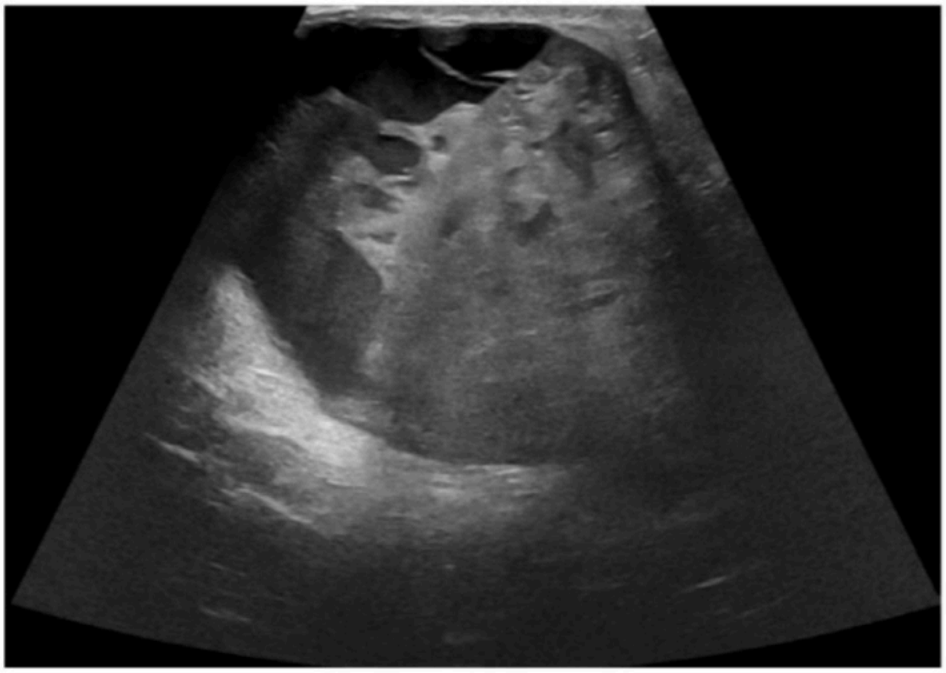

A

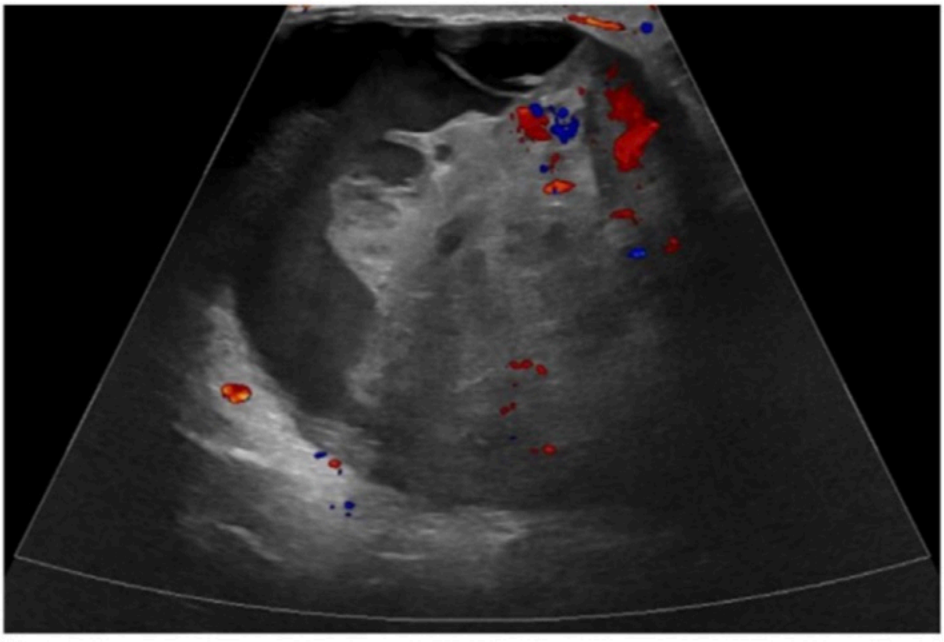

B

Figure 5 – VASCULARITY: INTERNAL VASCULARITY. A large mixed solid and cystic mass on grayscale US imaging (A). Color Doppler (B) confirms INTERNAL VASCULARITY within the solid component of the mass. Pathology: Invasive ductal carcinoma.

E. ASSOCIATED FEATURES

7. VASCULARITY

c. Peripheral vascularity

Peripheral vascularity is defined as a high number of blood vessels around the margin of a breast abnormality. Peripheral vascularity suggests that the tissue surrounding the abnormality is hyperemic, possibly due to tissue inflammation, infection, or neovascularization [51].

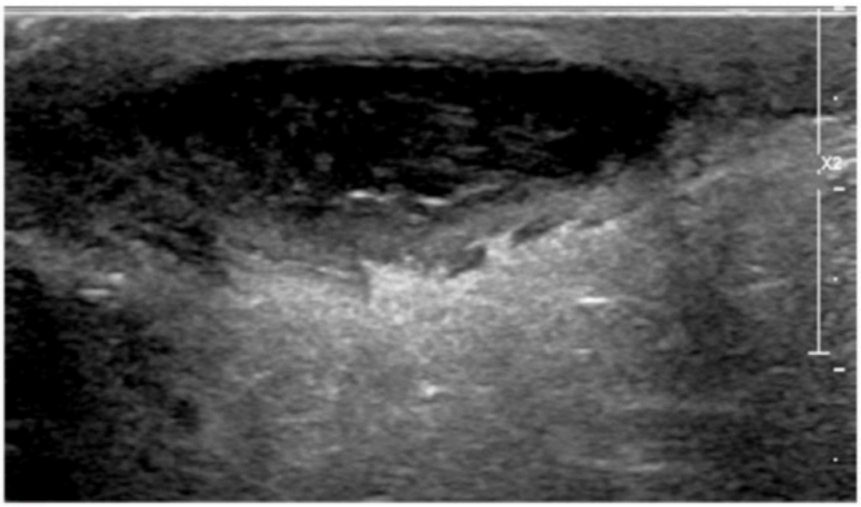

A

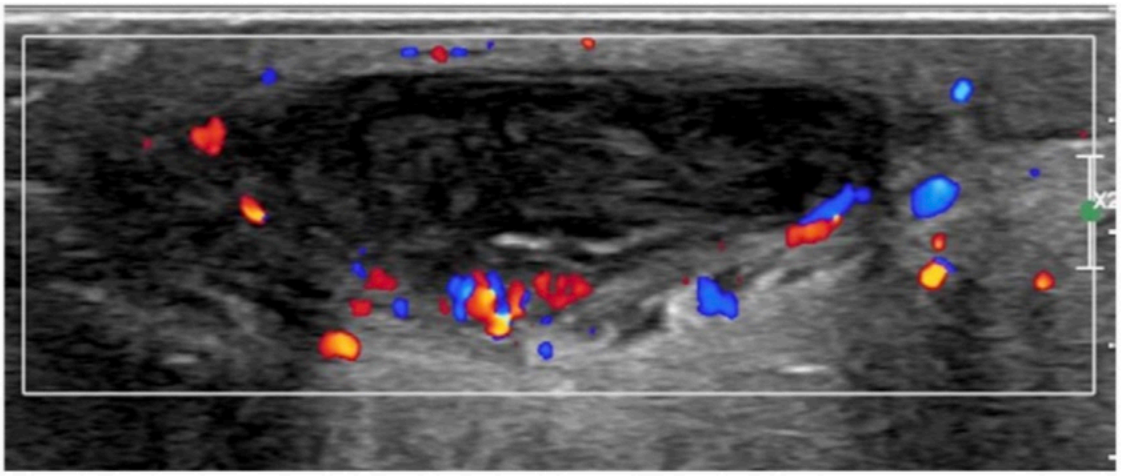

B

Figure 6 – VASCULARITY: PERIPHERAL VASCULARITY. Grayscale image of a superficial, periareolar mixed solid and cystic mass (A). Color Doppler image (B) shows PERIPHERAL VASCULARITY, indicating hyperemia in the surrounding tissue. Subsequent aspiration yielded pus. Cytology: Abscess.

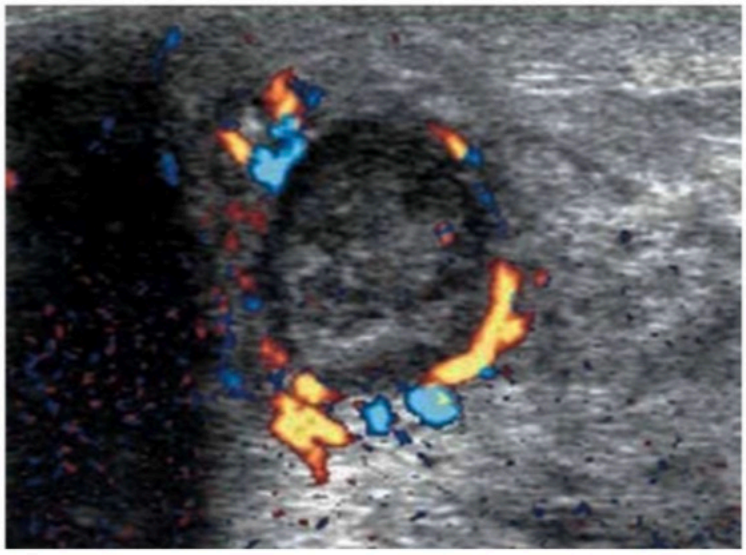

Figure 7 – VASCULARITY: PERIPHERAL VASCULARITY. Oval hypoechoic non-parallel circumscribed mass with PERIPHERAL VASCULARITY. Pathology: Abscess.

E. ASSOCIATED FEATURES

8. ELASTICITY ASSESSMENT

Elastography has been included in the lexicon because it is available as a feature on many US units, and it is important to define criteria and name descriptors for elasticity assessment. Elasticity is an assessment of the stiffness of a mass and its surrounding breast tissue. In general, malignant masses are expected to be stiffer than benign masses. However, there are many exceptions, with some malignancies being soft (e.g., mucinous carcinoma, DCIS, necrotic cancers) and some benign masses being hard (e.g., scarring, fibrosis, complex fibroadenomas [52]). Therefore, it must be emphasized that the ultrasonic criteria of mass shape, margin, and echogenicity are far more predictive for malignancy than stiffness, and elastography evaluation should not override the more predictive morphologic features of malignancy for patient management. Additionally, this technique is operator dependent, and image quality significantly impacts the accuracy of interpretation [53].

The primary utility of elastography involves improving the ability of ultrasonography to distinguish borderline versus suspicious masses [54, 55]. Specifically, if a mass demonstrates morphologic characteristics consistent with a BI-RADS category 3 assessment (probably benign) but suspicious elastography features, one may consider upgrading the final assessment to BI-RADS category 4A (low suspicion for malignancy). On the other hand, if a mass demonstrates morphologic characteristics consistent with a BI-RADS category 4A assessment (low suspicion for malignancy) but benign elastography features, one may consider downgrading the final assessment to BI-RADS category 3 (probably benign). Elastography's capability to further characterize borderline suspicious findings depends on the subcategorization of BI-RADS category 4 abnormalities into 4A, 4B, and 4C. Currently, elastography should not be applied to the downgrading of BI-RADS category 4B and 4C abnormalities.

Currently, there are two methods of elasticity measurement: strain elastography measures tissue stiffness via lesion compressibility; shear wave elastography measures the propagation speed of shear waves through tissue, as produced by acoustic force [54]. Ultimately, elasticity assessments are categorized as soft, intermediate, or hard. Stiffness assessments are typically displayed on a color scale or grayscale. Importantly, elastography techniques and stiffness scales vary by US vendor and may be configurable by the end user. As elastography techniques continue to evolve, radiologists and US vendors should agree upon a universally standard color scale and/or grayscale to promote consistency.

Quantitative and semi-quantitative measurements have been proposed for shear and strain elastography, respectively [56]. For shear wave elastography, shear wave propagation speed can be assessed in the breast tissue for a quantitative measurement, often reported in kPa or m/s. Since malignant masses are generally stiffer than benign masses, malignancies have higher elasticity measurements. In a large multinational study, the specificity of ultrasound for mass assessment significantly improved using quantitative maximum stiffness cutoff values of 160 kPa or greater for hard, suspicious lesions and 80 kPa or less for soft, probably benign lesions [54]. Stiffness was measured in the mass or the surrounding tissue. However, optimal stiffness cutoff values to distinguish benign and malignant masses have not yet been established and remain under investigation. Moreover, the threshold values cited above are vendor specific. Radiologists may internally monitor outcomes with their specific US units and review the elastography recommendations of their US unit vendors.

During elastography, benign masses often appear smaller on elastography images relative to the corresponding B-mode images, and malignant masses often appear larger on elastography images relative to the corresponding B-mode images. This observation has resulted in three semi-quantitative measures for strain elastography stiffness: elastography-to-B-mode

length (E/B) ratio, 5-point color scale (elasticity score), and strain ratio. For E/B ratio: Length measurement on the elastography image compared to the B-mode image results in the E/B ratio. An E/B ratio of 1 or higher is considered suspicious for malignancy, and an E/B ratio under 1 is more commonly associated with benign findings. With E/B ratio calculations, gray-scale elastography imaging may be more accurate than color elastography [57]. For the 5-point color scale, color elastography images are assessed: 1 = soft throughout, 2 = mixed soft and hard, 3 = hard but smaller on elastography than B-mode, 4 = hard and equal in size on elastography and B-mode, 5 = hard and larger on elastography than B-mode. A 5-point color scale score of 4 or 5 is considered suspicious for malignancy, and a 5-point color scale score of 3 or lower is more commonly associated with benign findings. For the strain ratio: a region of interest measuring the elasticity of normal subcutaneous fat is compared to a region of interest measuring the elasticity of the abnormality. The resultant strain ratio and cutoff values to distinguish malignancy versus benignity are not standardized at this time, and radiologists should review the elastography recommendations of their US unit vendor.

a. Soft

   Soft masses tend to be benign, though there are exceptions. Color coding is vendor-specific and, often, configurable by the end user. The elasticity scale should be checked on the US machine and recorded on the image.

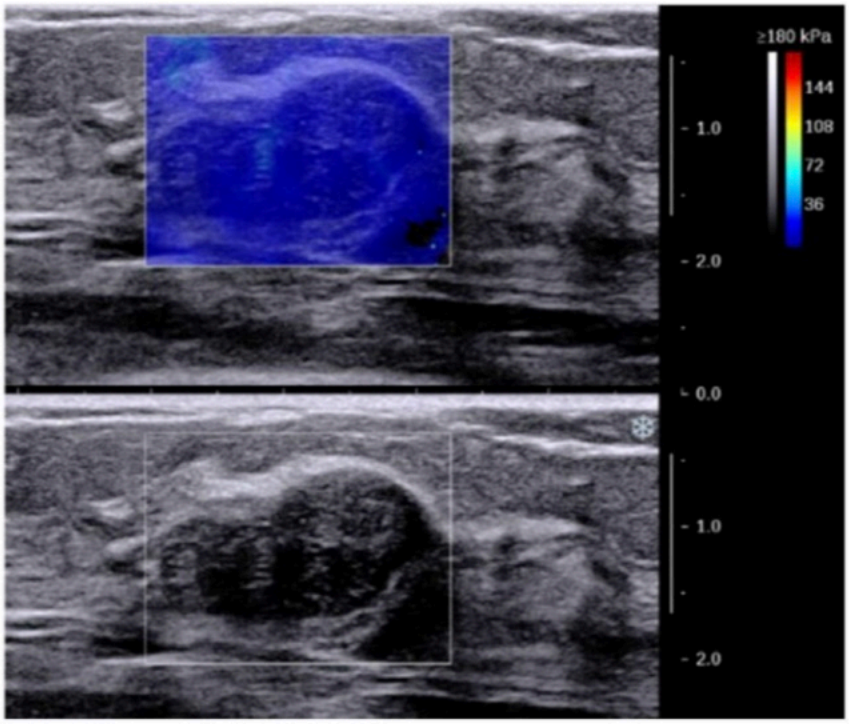

Figure 1 – ELASTICITY ASSESSMENT: SOFT. Shear wave elastogram (top) and corresponding B-mode US image (bottom) show a lobulated hypoechoic mass with circumscribed margin. The elastogram shows a uniformly SOFT mass. On this US machine's color scale, blue represents soft and red represents hard. This mass has a homogeneously blue color, indicating a stiffness < 36 kPa on this US machine. Pathology: Fibroadenoma.

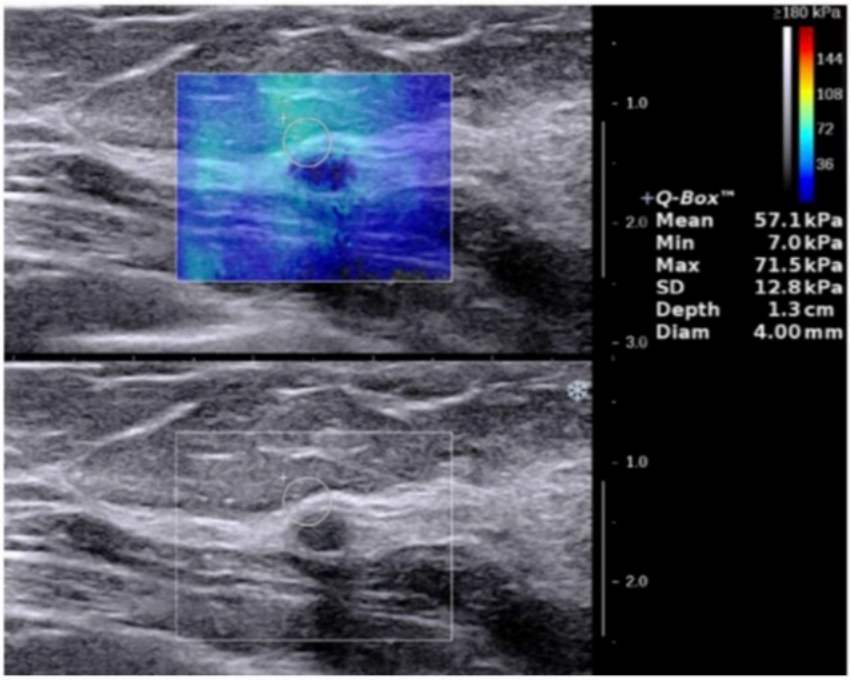

Figure 2 – ELASTICITY ASSESSMENT: SOFT. Shear wave elastogram (top) and corresponding B-mode US image (bottom) show an oval hypoechoic mass with circumscribed margin. The elastogram shows a predominantly SOFT mass. On this US machine's color scale, blue represents soft and red represents hard. Quantitative elasticity assessment of the stiffest area at the periphery of the mass (circle) shows a maximum stiffness of 71.5 kPa, which is SOFT according to a large multinational study that used this same US vendor [54]. Pathology: Non proliferative breast disease consisting of a few small cysts and patchy stromal fibrosis.

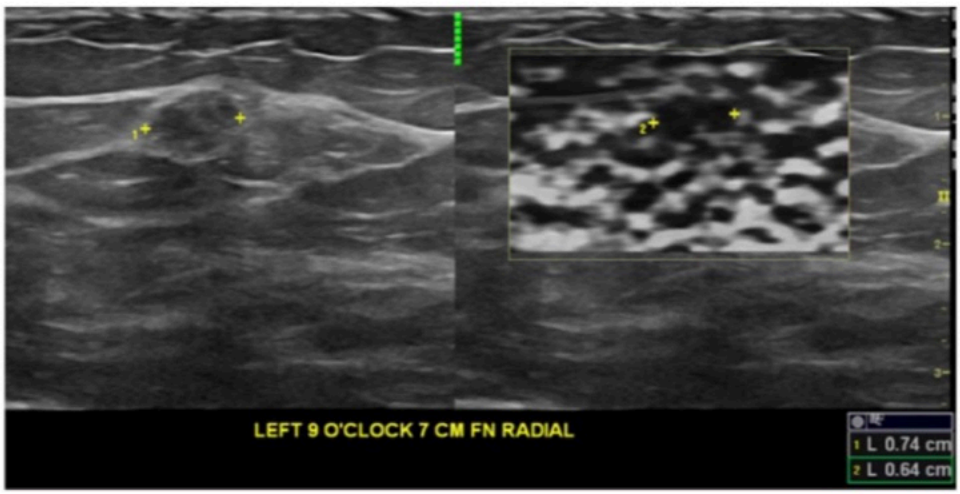

Figure 3 – ELASTICITY ASSESSMENT: SOFT. Conventional B-mode US image (left) and a corresponding grayscale strain elastogram (right) of an oval mass with parallel orientation and indistinct margin. The mass was measured on both images, and the elastography-to-B-mode length (E/B) ratio calculated as 0.64/0.74 = 0.86. An E/B ratio less than 1 suggests a SOFT benign mass. This mass was unchanged in size compared to an US from 4 years prior, and it was assessed as benign based on this size stability and elastography characteristics.

E. ASSOCIATED FEATURES

8. ELASTICITY ASSESSMENT

b. Intermediate

Intermediate stiffness assessments are not specific for benign or malignant diagnoses. Color coding is vendor-specific and, often, configurable by the end user. The elasticity scale should be checked on the US machine and recorded on the image.

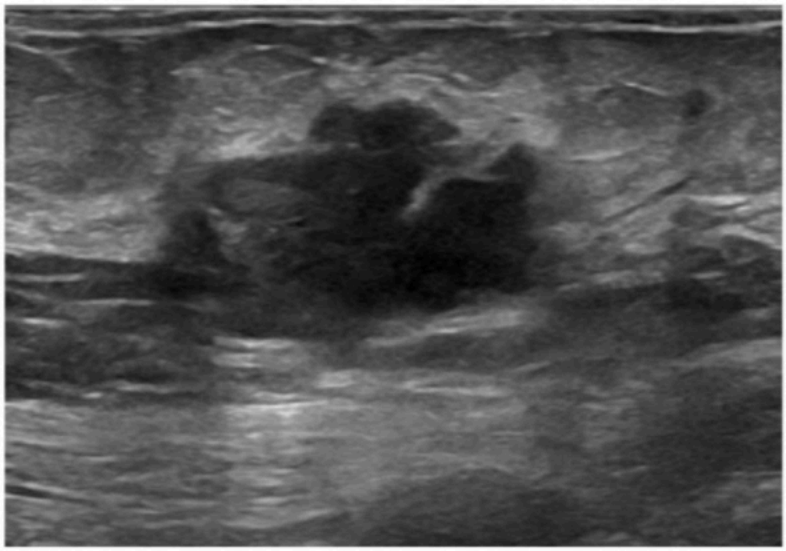

A

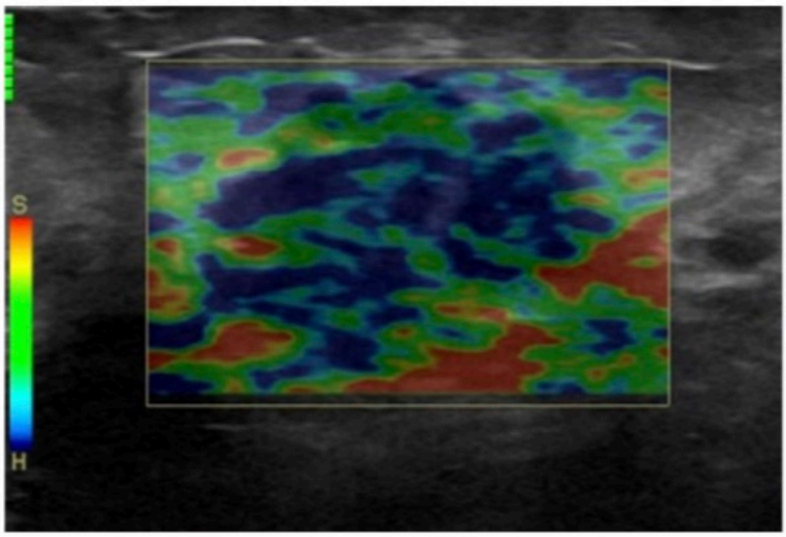

B

Figure 1 – ELASTICITY ASSESSMENT: INTERMEDIATE. Conventional B-mode US imaging (A) shows an irregular hypoechoic mass with microlobulated margin. Corresponding color strain elastogram (B) shows mixed hard and soft stiffness, which is INTERMEDIATE. On this US machine, blue represents hard and red represents soft. With a mixed hard and soft appearance, the 5-point color scale score is 2, which suggests a benign mass. This example supports the recommendation that morphologic characteristics supersede elastography. Since this mass has suspicious morphology, biopsy was still recommended. Pathology: Invasive ductal carcinoma.

E. ASSOCIATED FEATURES

8. ELASTICITY ASSESSMENT

c. Hard

Hard lesions tend to be malignant, though there are exceptions. Color coding is vendor-specific and, often, configurable by the end user. The elasticity scale should be checked on the US machine and recorded on the image.

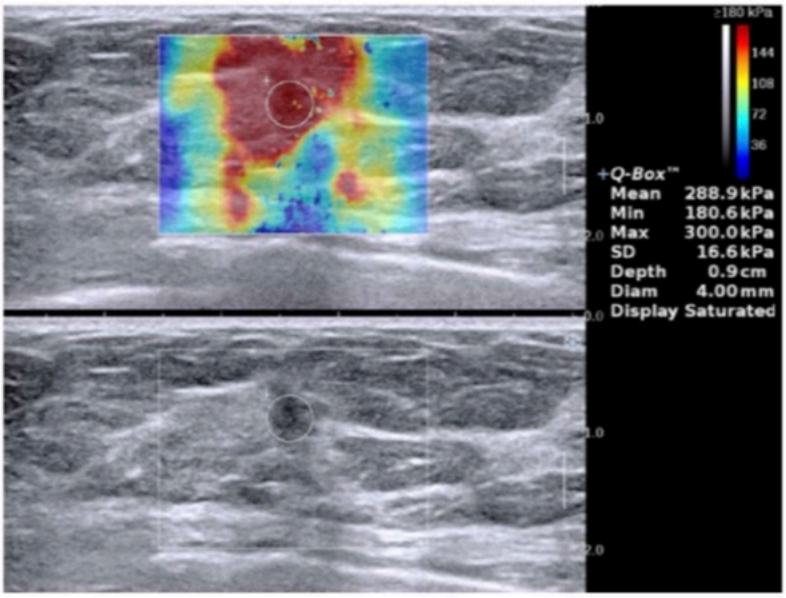

Figure 1 – ELASTICITY ASSESSMENT: HARD. Shear wave elastogram (top) and corresponding conventional B-mode image (bottom) show an irregular non-parallel hypoechoic mass with indistinct margin. In the shear wave elastogram (top), red represents hard and blue represents soft. This mass is HARD. Quantitative elasticity assessment (circle) shows a maximum stiffness of 300.0 kPa, which is HARD according to a large multi-institutional study that used this same US vendor [54]. Pathology: Invasive ductal carcinoma.

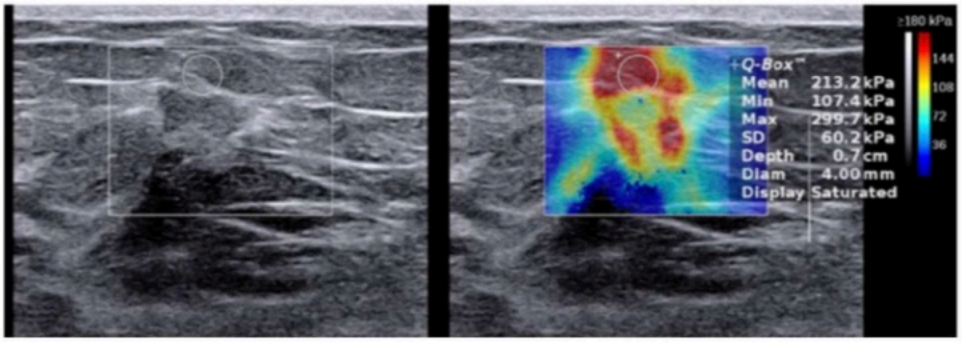

Figure 2 – ELASTICITY ASSESSMENT: HARD. Conventional B-mode image (left) shows a subtle irregular isoechoic mass with angular margin. In the corresponding shear wave elastogram (right), red represents hard and blue represents soft. This mass is HARD around the echogenic rind. Quantitative elasticity measurement (circle) shows a maximum stiffness of 299.7 kPa, which is HARD according to a large multinational study that used this same US vendor [54]. Pathology: Invasive ductal carcinoma.

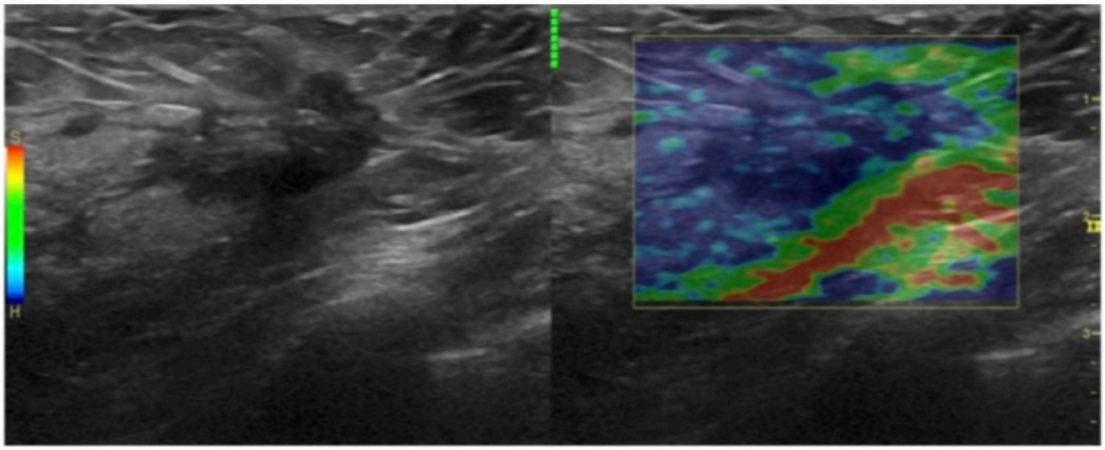

Figure 3 – ELASTICITY ASSESSMENT: HARD. Conventional B-mode US image (left) and a corresponding color strain elastogram (right) show an irregular hypoechoic mass with spiculated margin. This US machine displays hard as blue and soft as red. The mass is HARD, and the hard area (blue area on this US machine) appears larger on the elastogram relative to the size of the mass on the B-mode image. Therefore, the 5-point color scale score is 5, which is consistent with a malignant mass. Pathology: Invasive ductal carcinoma.

F. SPECIAL CASES

Special cases are those with a unique diagnosis or pathognomonic findings.

1. SIMPLE CYST

   The diagnosis and management of cystic breast lesions are addressed in detail in the Guidance section. A simple cyst has the following features: it is circumscribed, round or oval, anechoic (not hypoechoic), thin walled, and often shows posterior enhancement. When all four features are depicted, this establishes the diagnosis of simple cyst, a characteristically benign finding.

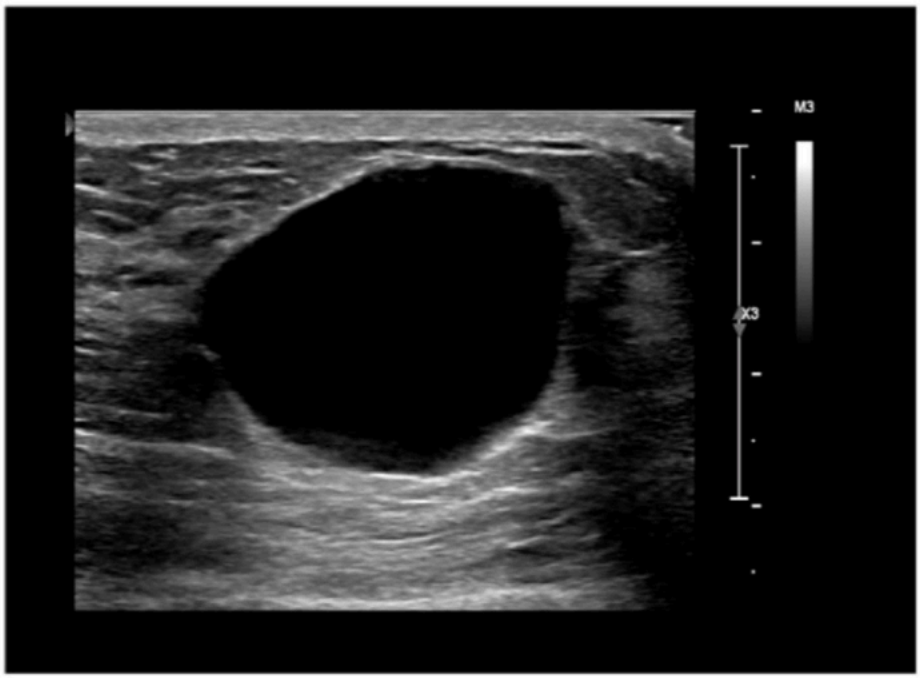

Figure 1 – SPECIAL CASES: SIMPLE CYST. This simple cyst is oval, anechoic, and thin-walled, and it demonstrates posterior enhancement. Note the gain is set so the subcutaneous fat appears medium gray, and the focal zone is identified in the middle one third of the cyst with good visualization of the posterior tissue including the pectoralis muscle.



A

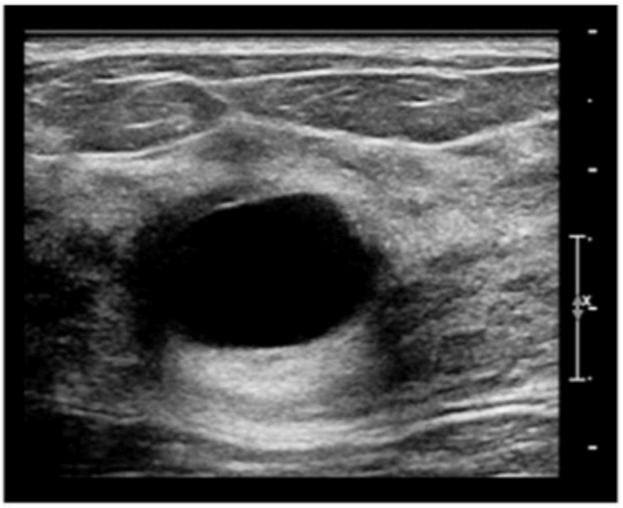

B

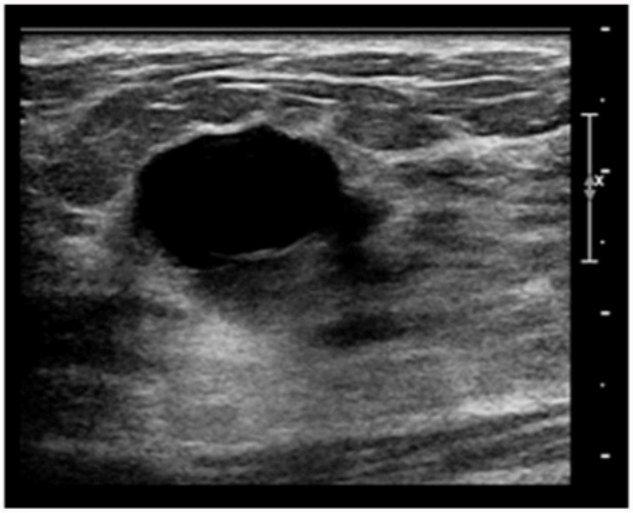

C

Figure 2 – SPECIAL CASES: SIMPLE CYST. The radial image (A) shows anechoic, circumscribed masses, with one located superficially relative to the other. The antiradial image of the deeper mass is shown in (B), while the antiradial image of the more superficial one is depicted in (C). When masses are grouped as these cysts are, they may not all lie in the same plane, and their margins may not appear clearly defined on all images. To differentiate similar masses in close proximity, measuring the depth from the skin to the anterior aspect of the mass can be helpful.

F. SPECIAL CASES

2. CLUSTERED MICROCYSTS

The lesion consists of a cluster of anechoic masses, with thin (< 0.5 mm) intervening septations and *no discrete solid* component within any of the locules. The classic criteria suggest each individual cystic space should measure less than 2- to 3-mm. However, one study demonstrated no increase in malignancy when the size criterion was increased to 7 mm [58]. While the conglomerate margin may appear microlobulated due to individual small cysts, the margin should not be indistinct. Tissue diagnoses associated with clustered microcysts include fibrocystic changes and apocrine metaplasia.

Clustered microcysts are common, seen in up to 6% of ultrasound examinations [59]. In a recent review, the outcome of clustered microcysts on breast ultrasound exams has an extremely low rate of malignancy [60]. Microcysts are assessed as benign (BI-RADS assessment category 2), especially when multiple or identified in the context of other fibrocystic changes. However, the presence of an indistinct margin or a discrete solid component should prompt a BI-RADS 4 suspicious assessment, with recommendation for biopsy, particularly if the mass is new or in a post-menopausal patient.

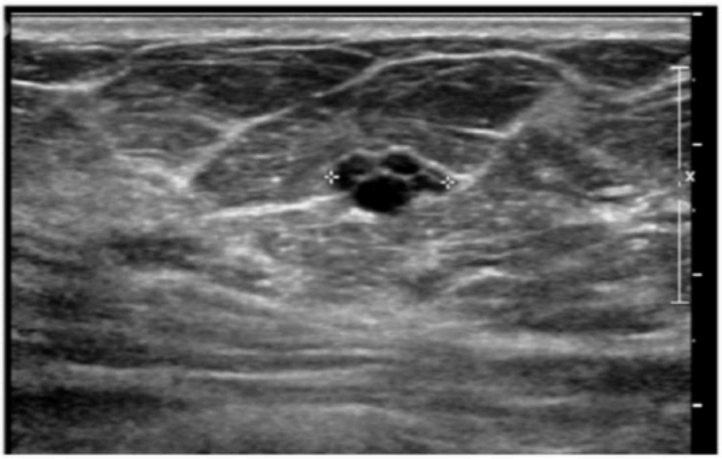

A

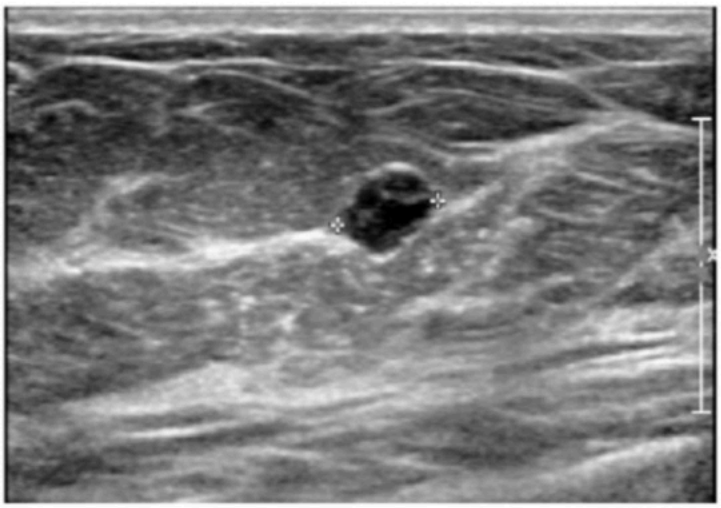

B

Figure 1 – SPECIAL CASES: CLUSTERED MICROCYSTS shown in radial (A) and antiradial planes (B). No solid component is present in any of the tiny cysts. An assessment of benign (BI-RADS category 2) is appropriate.

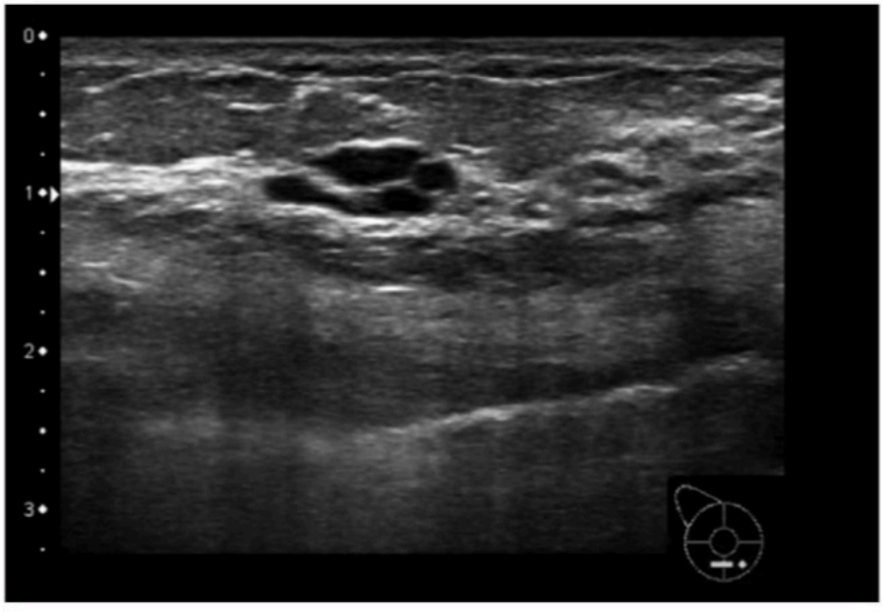

A

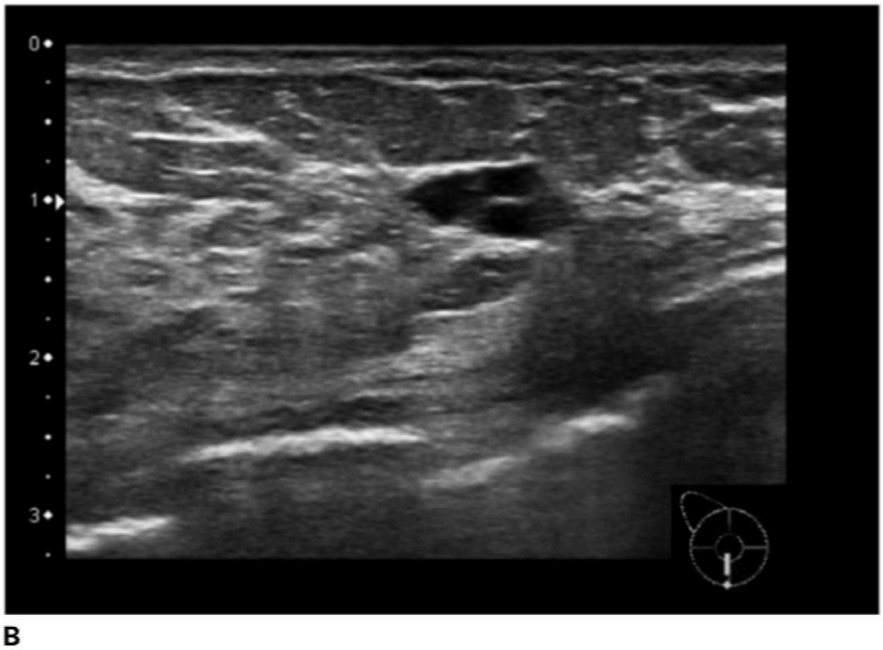

B

Figure 2 – SPECIAL CASES: CLUSTERED MICROCYSTS. Orthogonal US images (A and B) show elongation and distention of the lobule by a grouping of distended acini.

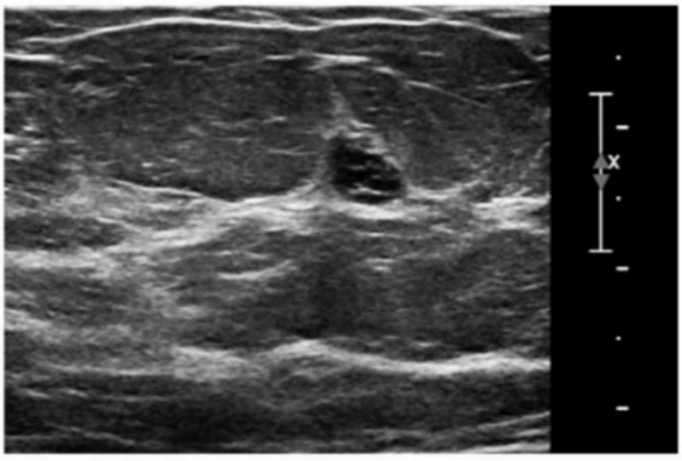

Figure 3 – SPECIAL CASES: CLUSTERED MICROCYSTS. Individual cysts measure < 2–3 mm. No solid component was identified on real-time scanning.

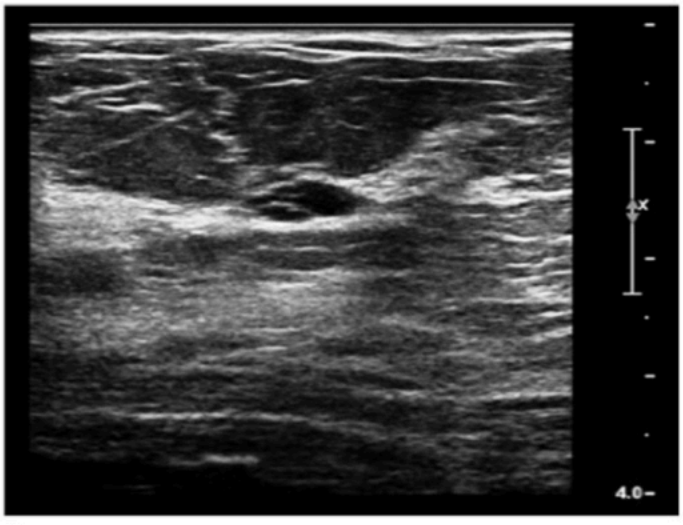

A

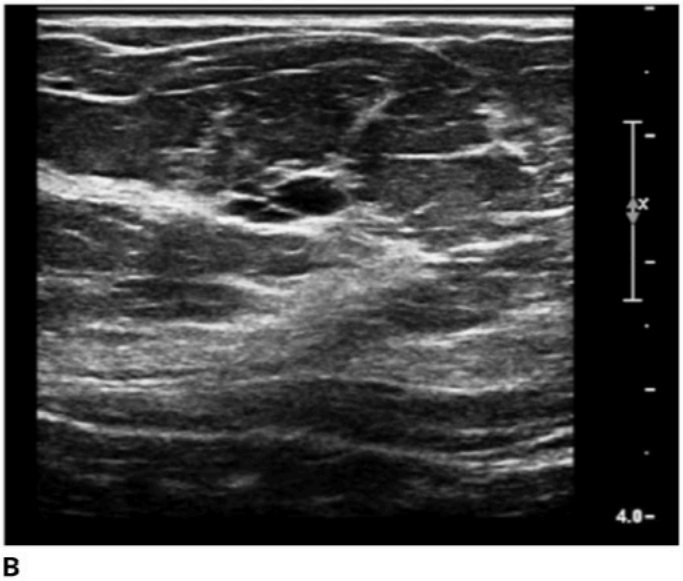

B

Figure 4 – SPECIAL CASES: CLUSTERED MICROCYSTS. This patient, who had multiple bilateral simple and complicated cysts (not shown), also has a grouping of CLUSTERED MICROCYSTS found incidentally (orthogonal views, (A) and (B)) during US screening. Assessment was benign (BI-RADS category 2).

F. SPECIAL CASES

3. COMPLICATED CYST

These are cysts that contain debris, without a discrete solid component, and have a thin wall. Often the debris manifests as diffuse, homogeneous low-level echoes. Sometimes the debris may have a layered appearance that can shift slowly with changes in the patient's position or appear as diffuse mobile scintillating reflectors. Complicated cysts are benign.

Note: The presence of a discrete solid component (including a solid mural nodule) should cause what otherwise might be considered a complicated cyst to be described as a mixed solid and cystic mass.

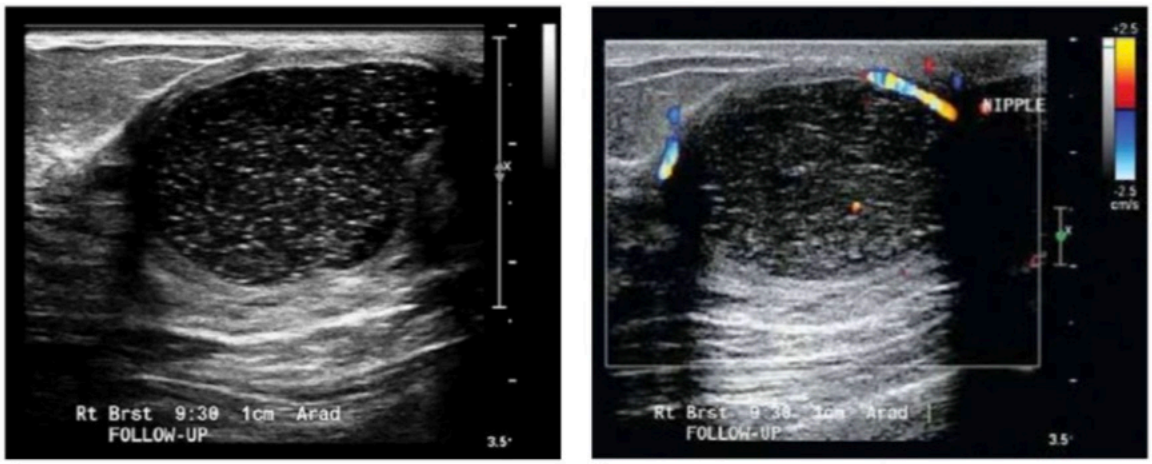

A B

Figure 1 – SPECIAL CASES: COMPLICATED CYST. A woman presented with a palpable mass just lateral to the nipple. This COMPLICATED CYST meets nearly all the sonographic criteria that define a simple cyst but contains diffuse low-level internal echoes (A) and shows visible rim vascularity (B). The wall is thick and isoechoic, indicating acute inflammation, unlike the thin echogenic walls of non-inflamed cysts. However, its inward border is smooth. A large vessel parallel to the pericystic thickening is characteristic of an inflamed cyst. Also note the artifactual color signal within the complicated cyst correlating to movement of the internal echoes (B). The cyst contents may shift due to the ultrasound beam's imparted acoustic energy, resulting in scintillating echoes, often intensified by applying Doppler.

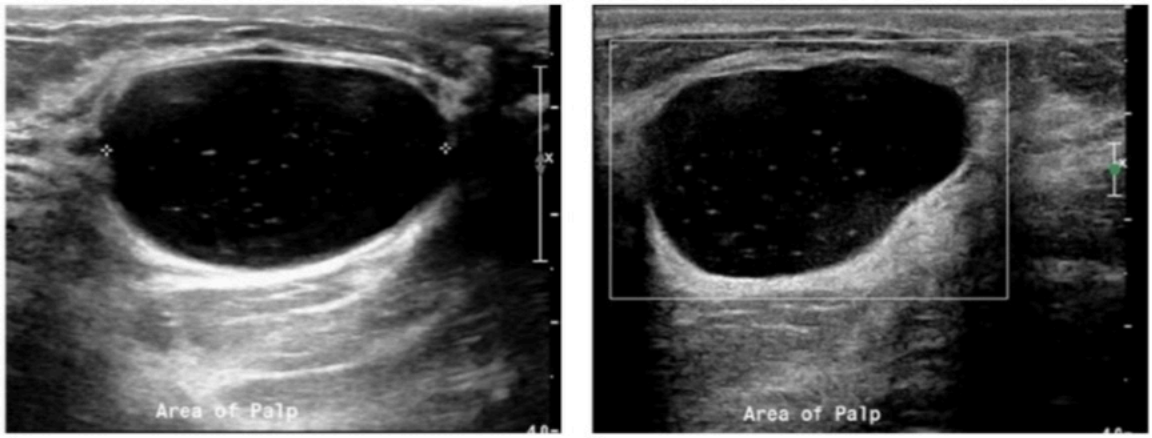

A B

Figure 2 – SPECIAL CASES: COMPLICATED CYST. Complicated cyst with scintillating echoes that move during real time imaging (radial (A) and antiradial (B)).

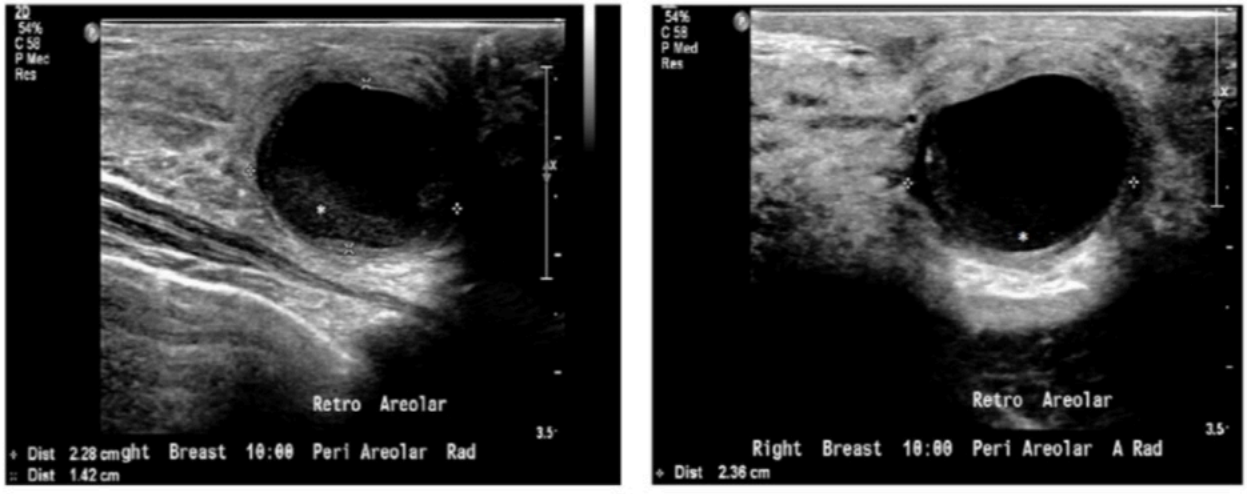

A B

Figure 3 – SPECIAL CASES: COMPLICATED CYST. Radial (A) and antiradial (B) images of a complicated cyst exhibiting dependent echoes (*), which were observed to be mobile during real time scanning. Findings are consistent with an inflamed cyst and a benign finding.

F. SPECIAL CASES

4. MASS IN OR ON SKIN

These masses are usually clinically apparent and include sebaceous or epidermal inclusion cysts, keloids, moles, pimples, neurofibromas, and accessory nipples. Rarely, a mass in the skin is found to be a metastasis, particularly in the setting of a mastectomy scar; however, in those cases clinical information about a primary tumor will likely be available to guide image interpretation. It is important to recognize the interface between skin and parenchyma and to establish that the mass is at least partially within the two thin echogenic bands of skin.



A



B

Figure 1 – SPECIAL CASES: MASS IN OR ON SKIN. A sebaceous cyst has formed between the two layers of skin (A and B, orthogonal views). The skin layers enclosing the mass are best seen on (B) (arrows). With use of a gel offset or offset pad, a tract traversing the skin can sometimes be seen through which the fatty contents of a sebaceous cyst are occasionally extruded.



A

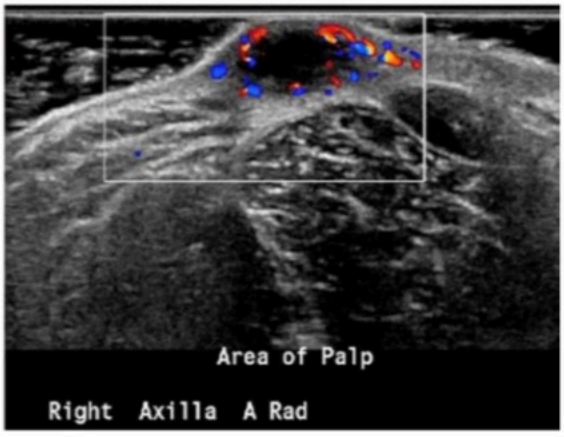

B

Figure 2 – SPECIAL CASES: MASS IN OR ON SKIN. Two images ((A) B-mode; (B) color Doppler) demonstrate a complicated cyst within the epidermis. The hyperechoic surrounding tissue enveloping is known as the "claw sign" (arrows). Using a generous amount of gel on the skin as a standoff allows for optimal visualization of this superficial lesion.

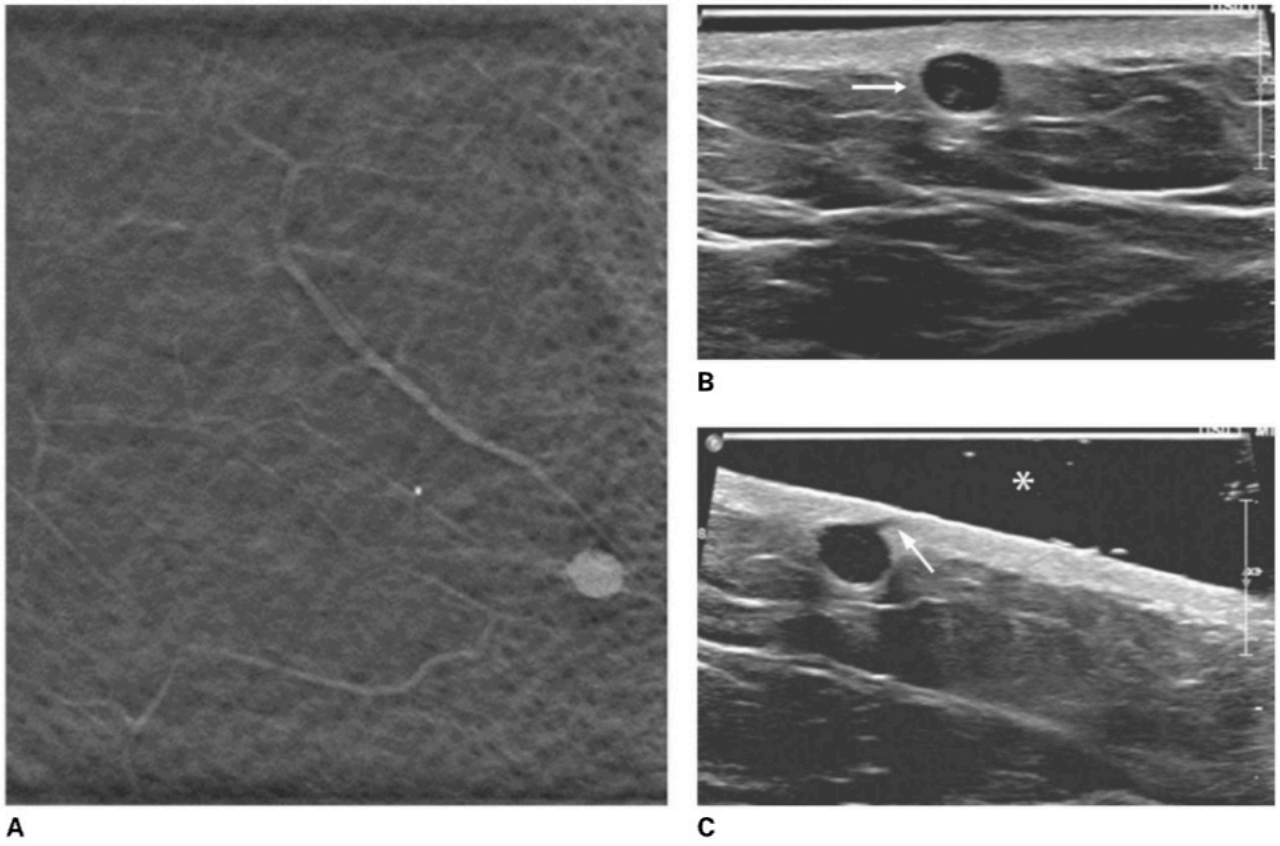

Figure 3 – SPECIAL CASES: MASS IN OR ON SKIN. A 5-mm oval circumscribed mass is seen in the subcutaneous fat of the right breast (A). Two grayscale images of the right breast reveal an oval nearly anechoic mass with posterior enhancement in the skin consistent with an epidermal inclusion cyst (B, C). In both (B) and (C), the focal zone was properly positioned within the first 1 cm of the breast. However, the angle of insonance was not optimal to show the tract to the skin in (B). In (C), the angle of insonance was changed to show the tract to the skin (arrow). Along with the sizable amount of gel (*) used, the optimized angle of insonance allowed the tract to be well visualized in (C), characteristic of an epidermal inclusion cyst.

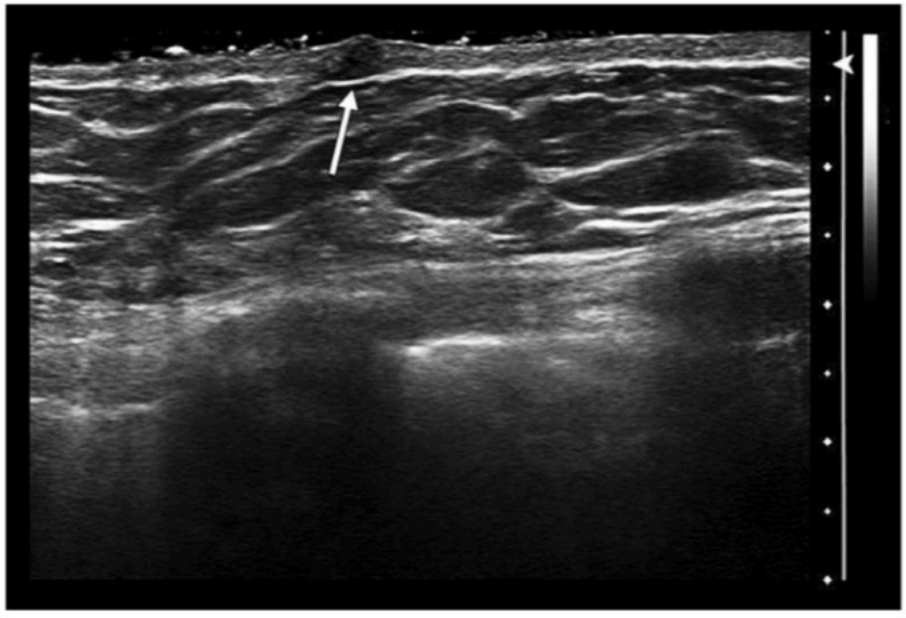

Figure 4 – SPECIAL CASES: MASS IN OR ON SKIN. An accessory nipple (arrow) may form along each of the embryonic milk lines that extend from axilla to groin.

F. SPECIAL CASES

5. FOREIGN BODY (EXCLUDING IMPLANTS)

Foreign bodies include biopsy marker clips or localization seeds, surgical clips, wires, retained catheter sleeves, cardiac devices, injected or leaked silicone or paraffin, metal or glass related to trauma. Because foreign bodies have a variety of appearances on ultrasound, clinical history and mammographic correlation are often crucial in establishing the presence and nature of foreign matter within the patient. Most foreign bodies are echogenic with a variable appearance depending on their shape and size. Small and thin foreign bodies, such as retained wires, may not be detectable on ultrasound, as echogenic structures may blend into the surrounding echogenic fibroglandular tissue and Cooper's ligaments.

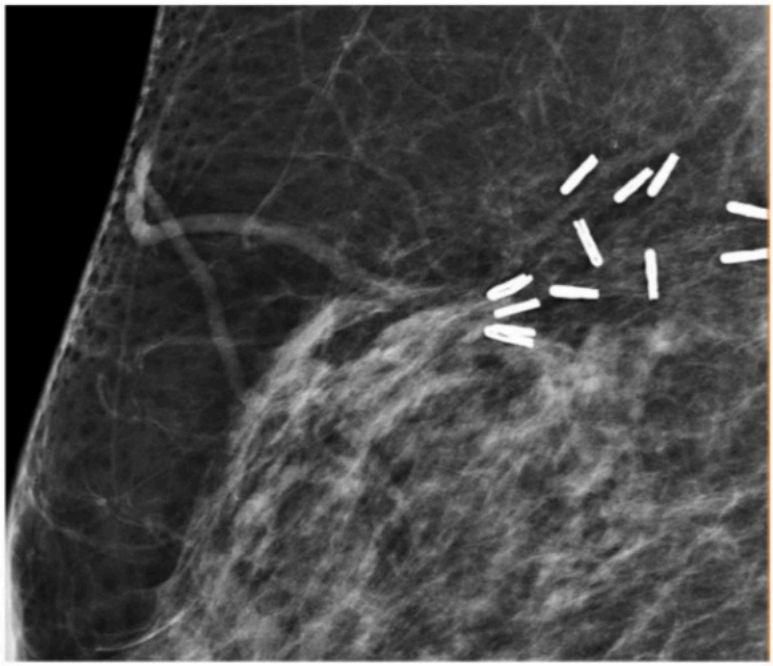

A

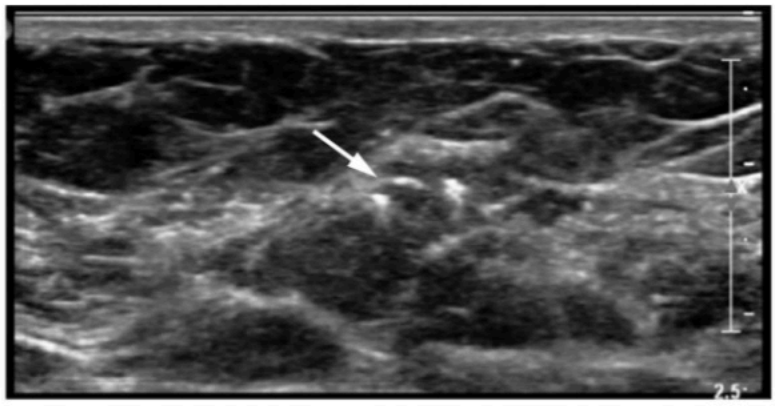

B

Figure 1 – SPECIAL CASES: FOREIGN BODY EXCLUDING IMPLANTS. A 58-year-old woman with a remote history of right lumpectomy. Right mammogram (A) demonstrates multiple surgical clips at the lumpectomy site. The surgical clips have an echogenic appearance on US (B) (arrow).

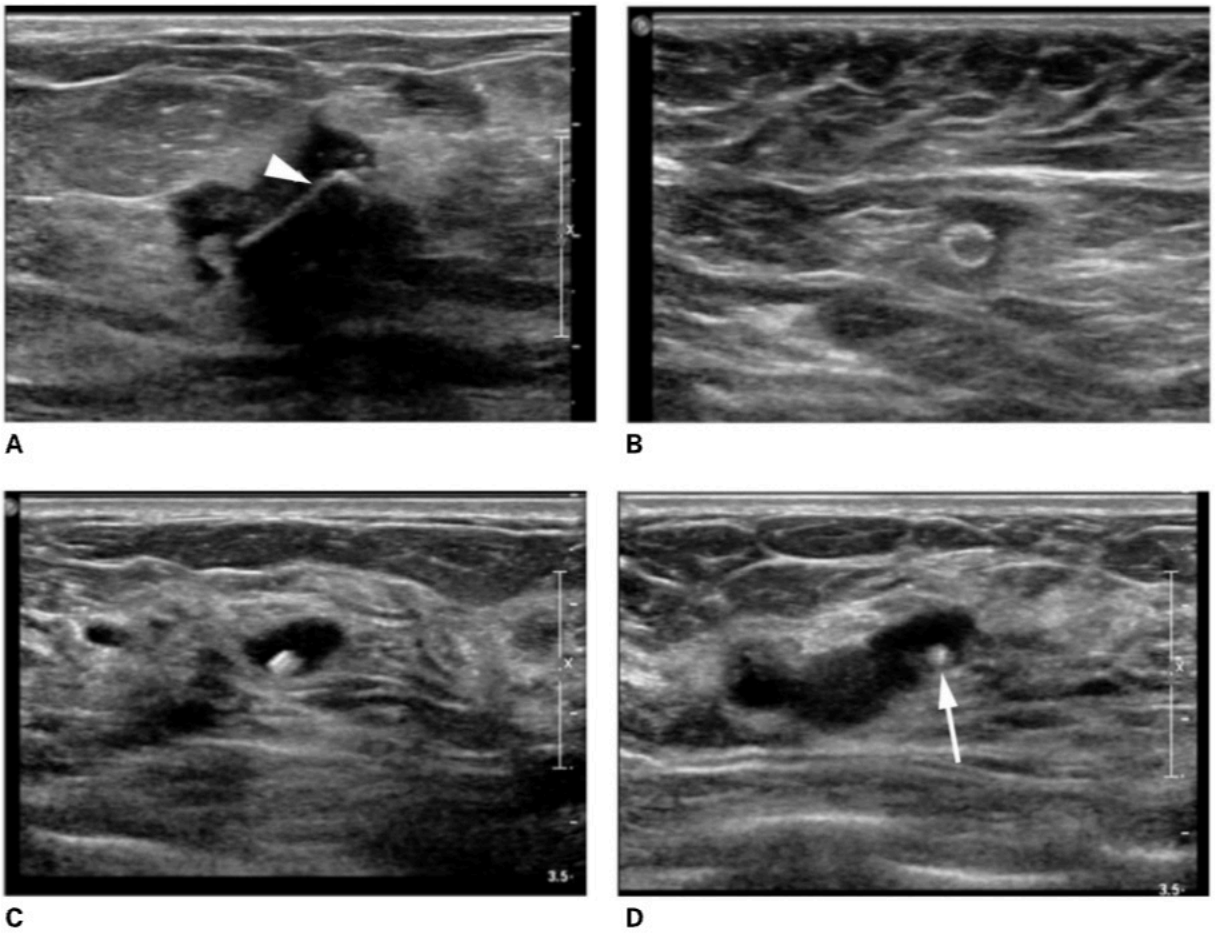

Figure 2 – SPECIAL CASES: FOREIGN BODY EXCLUDING IMPLANTS. The variable ultrasound appearance of biopsy marker clips placed after core needle biopsy. (A) Linear echogenic marker embedded in collagen (arrow) deployed immediately following US core needle biopsy of an invasive ductal carcinoma. (B) Q-shaped marker within a biopsy-proven metastatic axillary node, now decreased in size due to neoadjuvant systemic therapy. (C) Echogenic marker clip within a dilated duct one year following core needle biopsy of a benign intraductal papilloma. (D) The orthogonal view of the same case in (C), shows the clip (arrow) within the duct and adjacent to the benign papilloma.

F. SPECIAL CASES

6. IMPLANTS

Although not as sensitive as MRI, US can detect intracapsular and extracapsular silicone rupture with a reported sensitivity of 30-75% [61]. Imaging is not necessary to assess saline implant integrity, as this is a clinical assessment. Both silicone and saline within normal implants will appear anechoic with a curvilinear echogenic capsule. The normal implant shell manifests as two parallel echogenic lines on US.

Intracapsular rupture of a silicone implant may have a "stepladder" appearance when multiple layers of the shell are collapsed anteriorly. Extracapsular silicone associated with a ruptured implant will have a characteristic "snowstorm" appearance [61]. This is related to echogenic noise artifact which obscures the posterior tissue. If large enough, extravasated silicone may also appear as an anechoic mass similar to the silicone within the implant. Extravasated free silicone or silicone gel bleed may travel through lymphatics and deposit in lymph nodes, which then exhibit similar imaging characteristics.

Fluid collections around silicone implants should be evaluated carefully. While small peri-implant fluid collections are usually insignificant, large or increasing peri-implant fluid may indicate the rare presence of breast implant-associated anaplastic large cell lymphoma (BIA-ALCL), a recently recognized non-Hodgkin lymphoma of T-cell origin, most often associated with textured breast implants [62]. Patients with BIA-ALCL typically present with breast swelling, asymmetry or pain occurring more than one year after implant placement [62]. Ultrasound is the first line imaging modality of choice and may show a large or increasing peri-implant fluid collection, and an associated mass may be present [63]. The specificity of ultrasound is low, as peri-implant fluid collections may be related to more common benign entities such as inflammation, infection or implant rupture. Diagnosis can be made by large volume US-guided aspiration with cytologic and microbiological evaluation of the peri-implant effusion, as well as biopsy of any associated mass [63]. At least 10-50 ml of fluid is necessary and should be specifically tested with flow cytometry, CD30 and other lineage-associated markers to evaluate for BIA-ALCL [64].



A

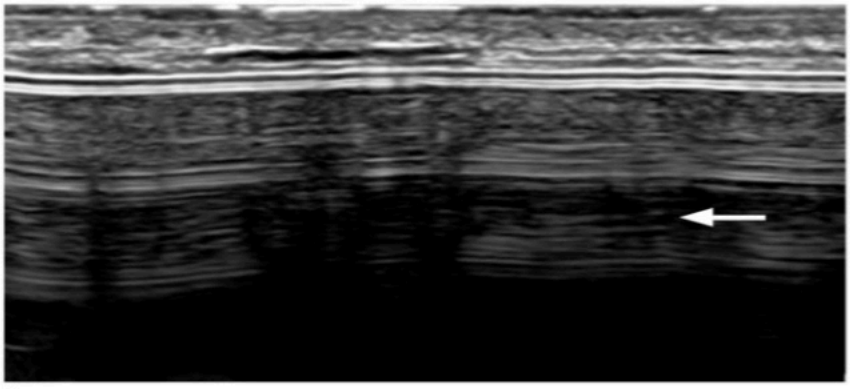

B

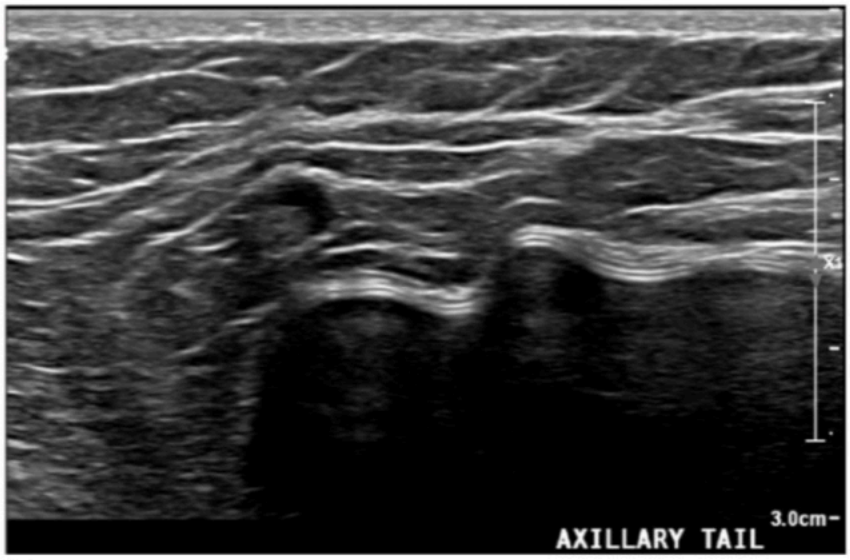

C

Figure 1 – SPECIAL CASES: IMPLANTS. Three different normal implants. (A) Normal implant appearance on US with an anechoic lumen surrounded by an echogenic envelope. Low-level echoes may be seen within the implant and anterior reverberation artifacts (arrows) are common, also present and more extensive in (B). (C) Intact implant with normal folds.

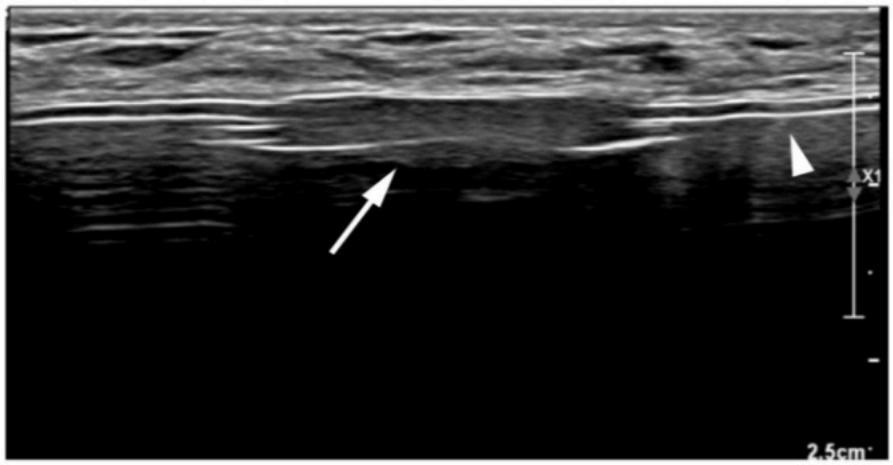

A

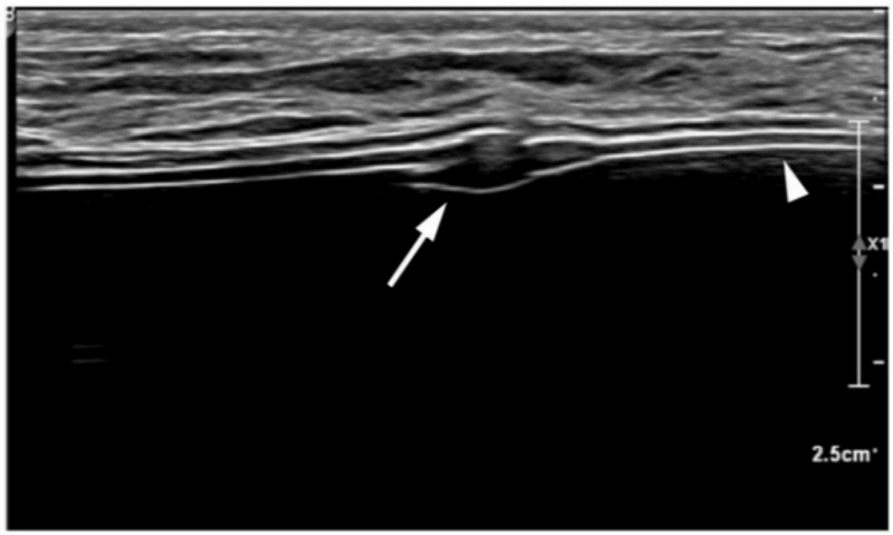

B

Figure 2 – SPECIAL CASES: IMPLANTS. Normal saline implant. Radial (A) and antiradial (B) views demonstrate the two parallel echogenic lines of the implant shell (arrowhead). The oval, hypoechoic implant valve (arrows) is located along the implant shell.

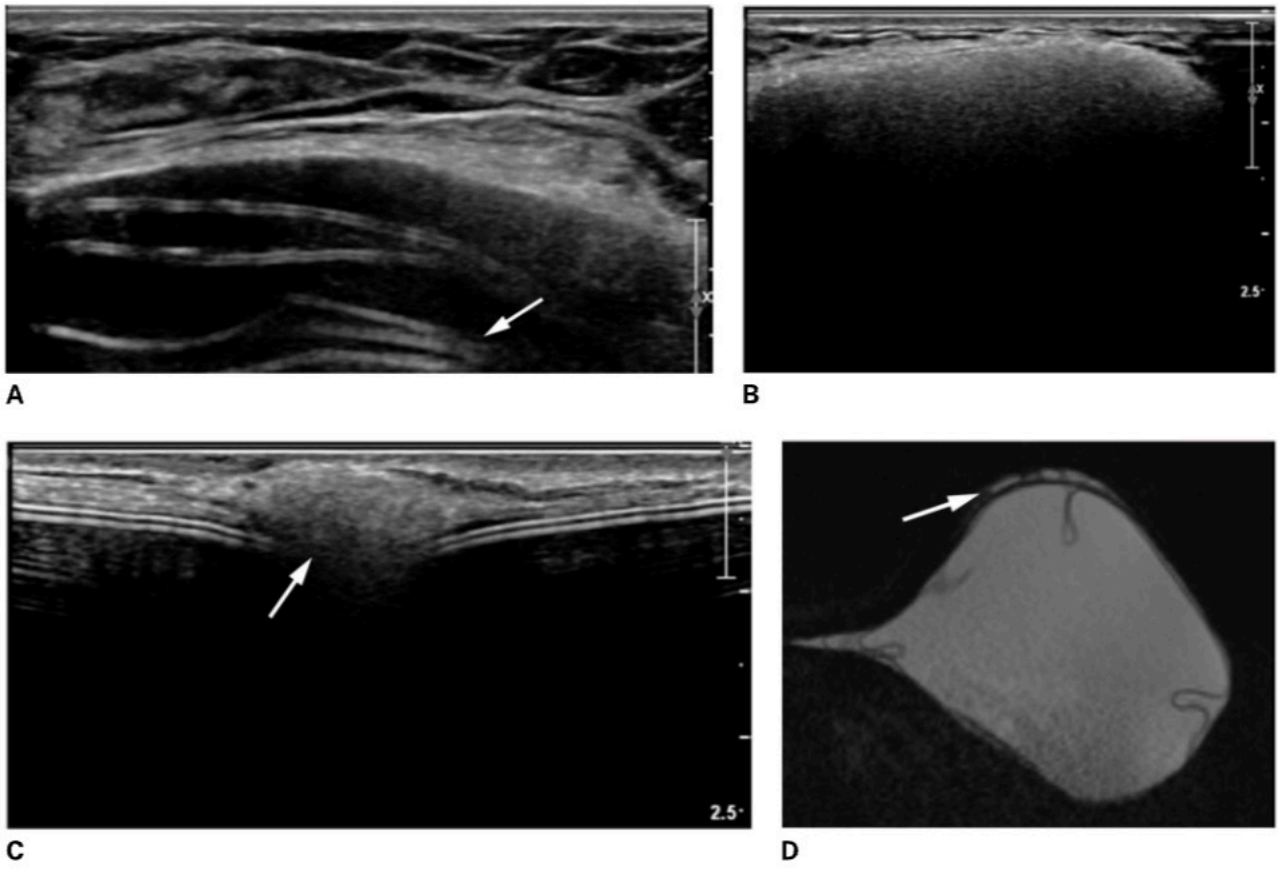

Figure 3 – SPECIAL CASES: IMPLANTS. Three different abnormal implants. (A) US shows the stepladder appearance within the implant (arrow), due to the collapsed implant shell and consistent with intracapsular rupture. (B) US reveals a snowstorm appearance and echogenic noise consistent with extracapsular rupture of a silicone implant. (C) Uncollapsed extracapsular rupture of silicone implant. Echogenic silicone is present with a more subtle snowstorm appearance (arrow). (D) Axial non-contrast MR silicone bright series of the same patient in (C) also demonstrates extracapsular silicone implant rupture with extracapsular silicone (arrow).

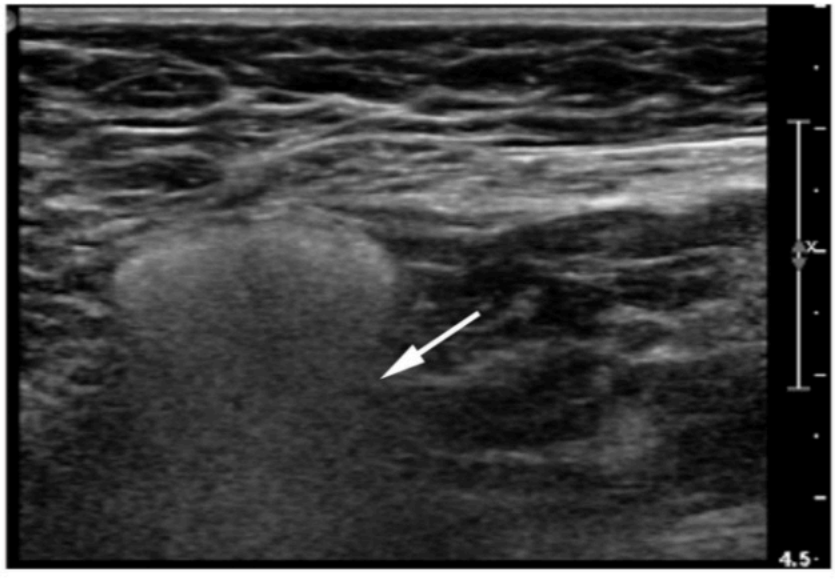

Figure 4 – SPECIAL CASES: IMPLANTS. Silicone uptake located within an axillary node in a patient with a history of ruptured implants, which were subsequently removed. The silicone has a snowstorm appearance (arrow) due to echogenic noise and acoustic scatter. Given the pertinent clinical history of previous placement of a silicone implant, no interventional procedure is necessary to establish the diagnosis of extracapsular silicone.

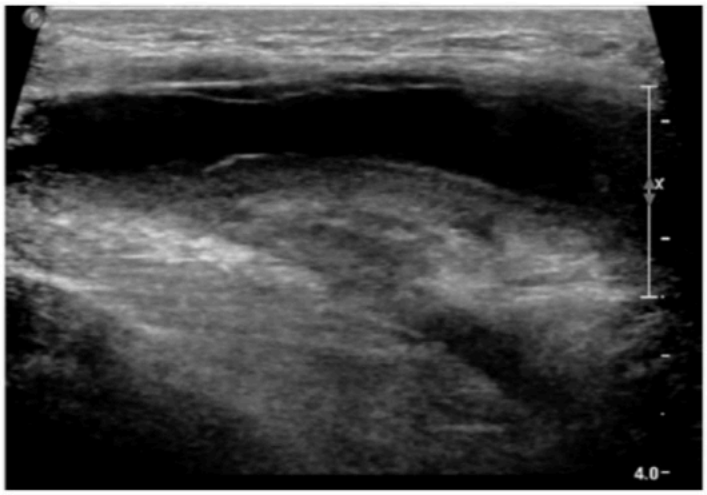

A

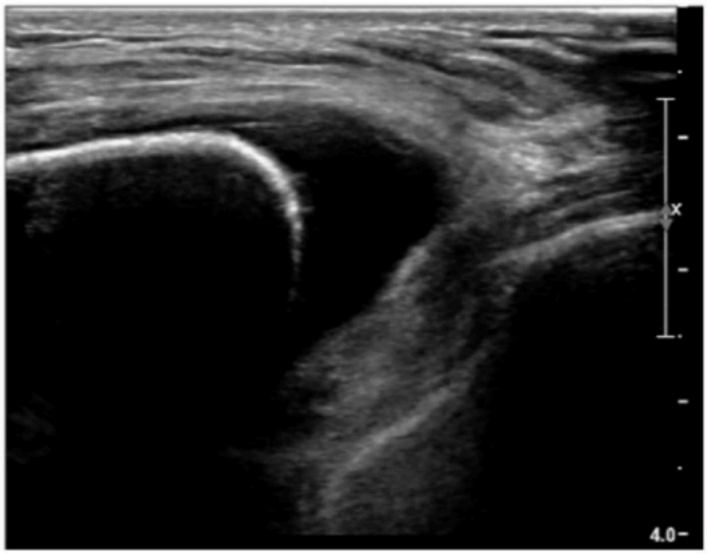

B

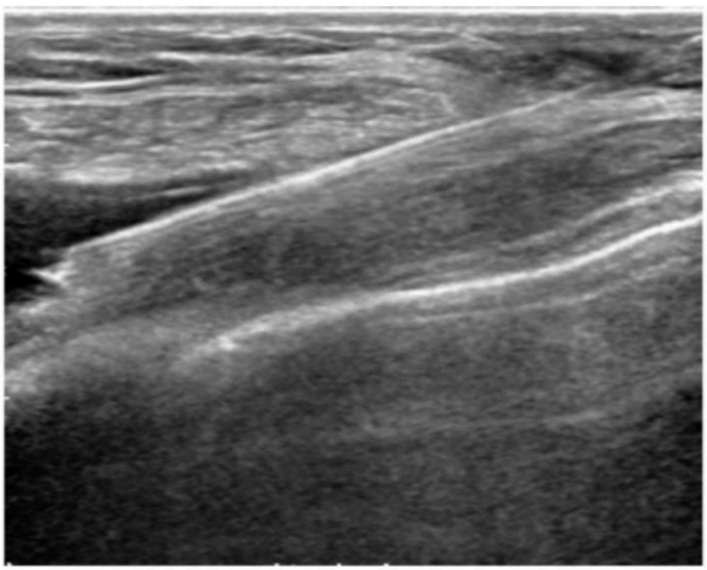

C

Figure 5 – SPECIAL CASES: IMPLANTS. Peri-implant fluid collection in a patient with left breast swelling and pain, several years following textured implant placement. (A) and (B) show an anechoic fluid collection surrounding the left implant. The differential diagnosis includes a seroma, but BIA-ALCL can have a similar appearance, though typically associated with larger amounts of fluid (> 50 cc). (C) Ultrasound-guided aspiration was performed because the patient was symptomatic, and cytologic evaluation of the fluid showed no evidence of BIA-ALCL. The patient subsequently had the implant removed. Pathology: Chronic inflammation.

F. SPECIAL CASES

7. POSTSURGICAL CHANGES, INCLUDING FLUID COLLECTIONS

The only postsurgical sonographic findings that are characteristically benign involve fluid collections, especially postoperative seromas that appear entirely cystic. Seromas may have septations, internal debris or contain both cystic and solid-appearing components, but they should be avascular. Most other postsurgical findings, especially those involving scar tissue, usually display suspicious sonographic findings, such as posterior shadowing, hypoechogenicity, irregular shape, occasionally spiculated margin, and architectural distortion. To avoid unnecessary biopsy, interpretation of breast imaging studies of the treated breast should be made with reference to clinical history of previous surgery, with a skin scar apparent by visual inspection at the location of the sonographic findings often sufficient. If there is uncertainty whether the ultrasound finding correlates with the scar and mammographic finding, a linear scar marker can be placed on the skin at the site of incision with a mammographic view tangential to the scar marker that correlated with US findings. The histopathology of the tumor, margin status at the time of excision, and history of radiation therapy and chemotherapy should also be taken into account when imaging findings are interpreted. Comparison with previous studies is crucial for accuracy in follow-up.

Postsurgical scars commonly evolve over time, usually contracting as they develop marginal indistinctness and spiculation. These interval changes are observed more commonly at mammography but increasingly are observed with screening whole-breast US. The common postsurgical changes of edema and skin thickening, which tend to decrease in extent and severity over time, are depicted equally well with mammography and US, and in this context are considered to be benign. The remaining postsurgical changes that are visible at US are more accurately assessed at mammography.

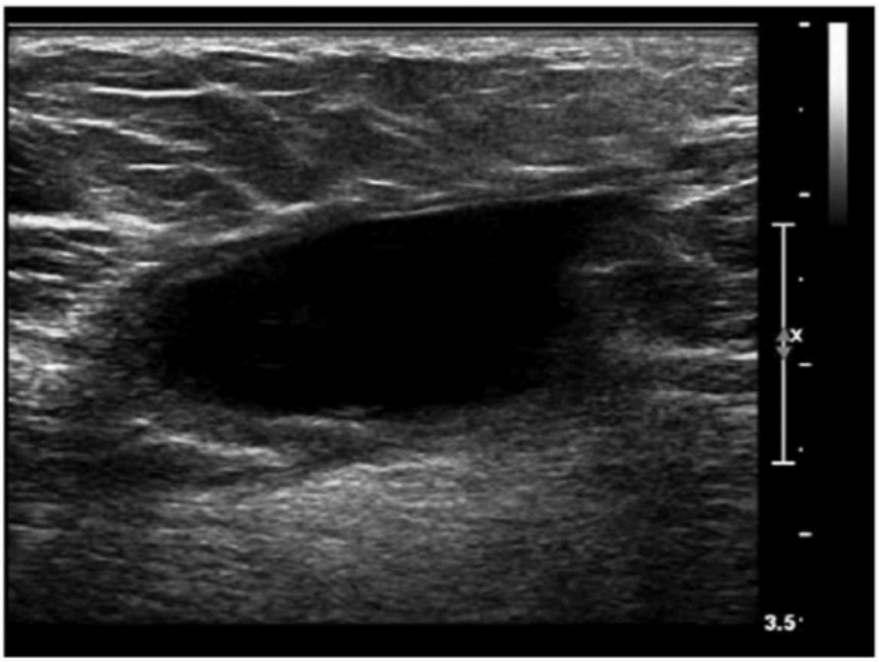

A

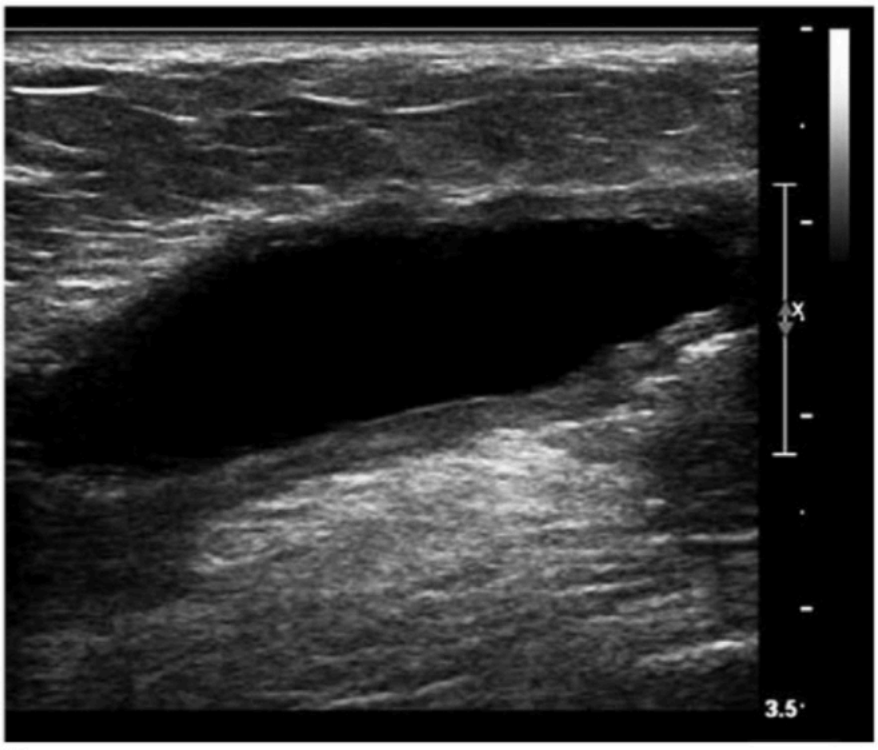

B

Figure 1 – SPECIAL CASES: POSTSURGICAL CHANGES, INCLUDING FLUID COLLECTION. Six months after lumpectomy and radiation therapy for invasive ductal carcinoma and DCIS, baseline post-treatment US shows elliptical FLUID COLLECTION on orthogonal US planes (A and B). The thickened wall of the seroma on the US images is of no significance.

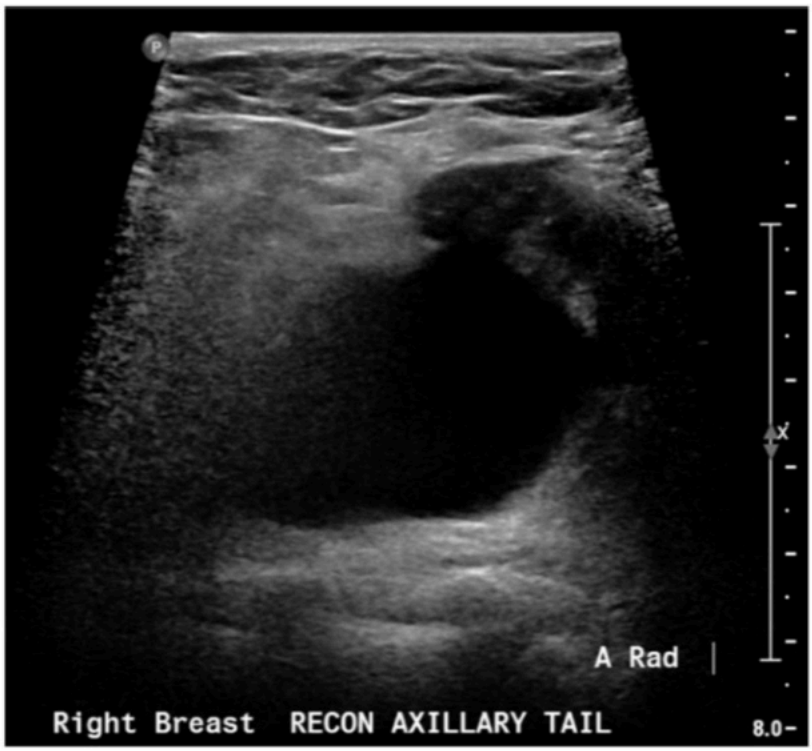

A

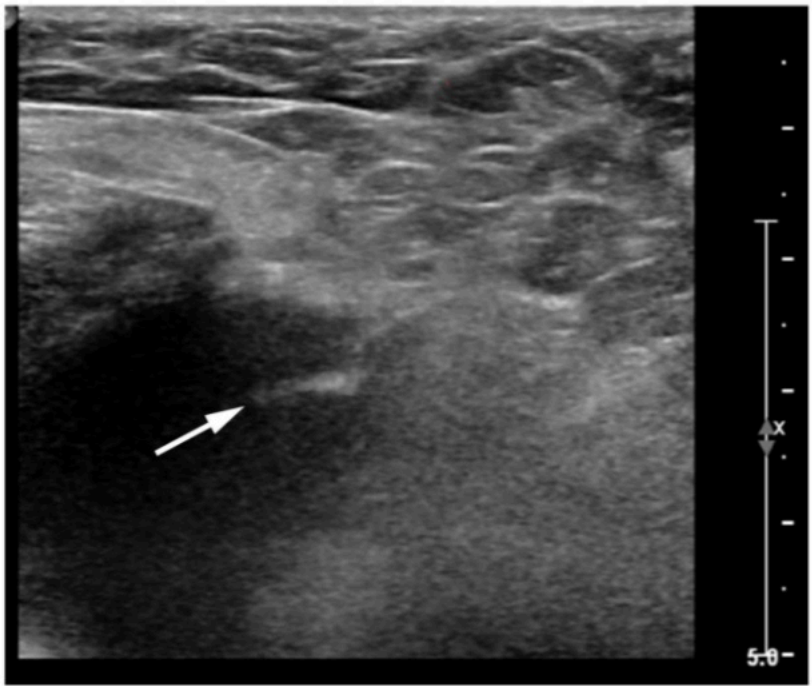

B

Figure 2 – SPECIAL CASES: POSTSURGICAL CHANGES, INCLUDING FLUID COLLECTION. Three weeks after breast reconstruction with deep inferior epigastric perforator (DIEP) flap, a tender fluid collection was palpated in the right axillary tail. (A) Ultrasound shows a corresponding anechoic lobulated mass consistent with a fluid collection. (B) As per surgeon's request, the fluid collection was successfully drained with US guidance. Note needle tip within the collection (arrow). The fluid was sent to microbiology and was negative for bacterial growth.

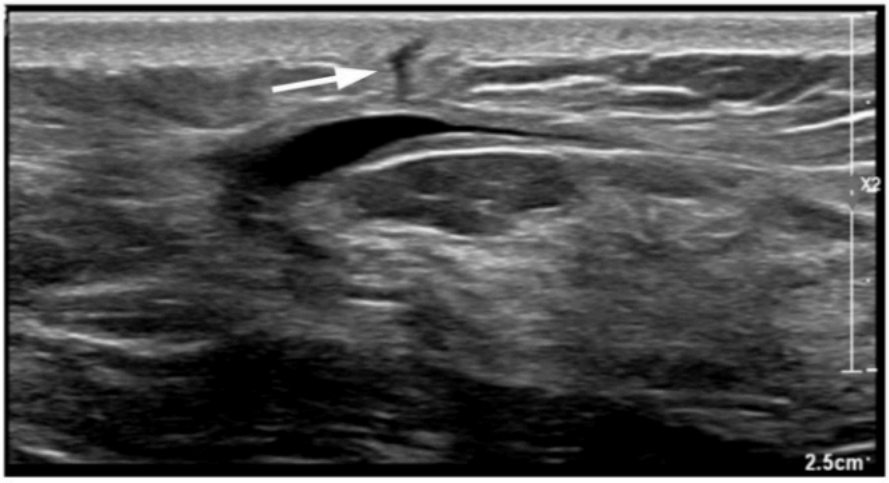

A

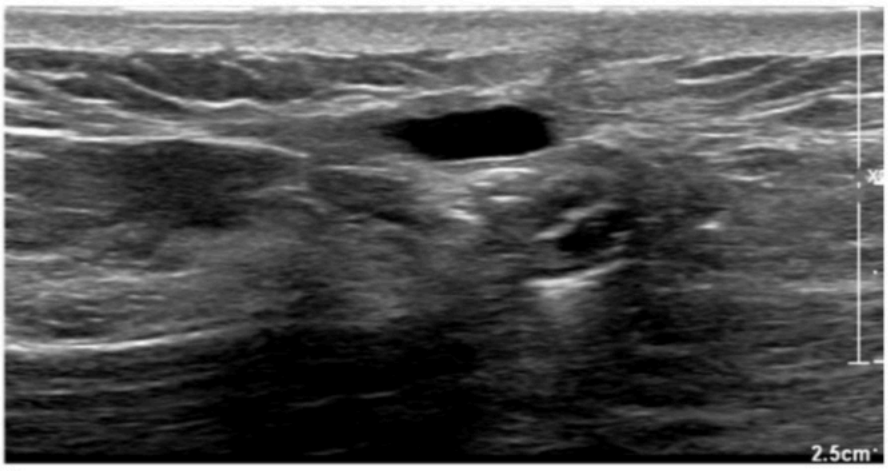

B

Figure 3 – SPECIAL CASES: POSTSURGICAL CHANGES, INCLUDING FLUID COLLECTION. Two years after lumpectomy and radiation therapy for invasive ductal carcinoma. (A) Screening whole-breast US shows an oval anechoic fluid collection remaining at the lumpectomy site, consistent with a seroma. Note the track of the scar extending to the skin (arrow). (B) Antiradial plane also confirms the presence of a simple seroma.

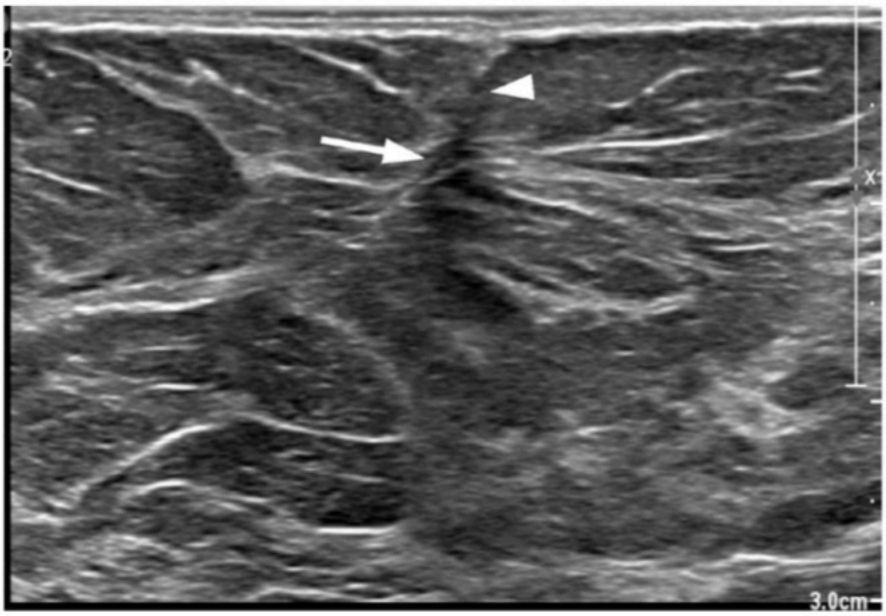

A

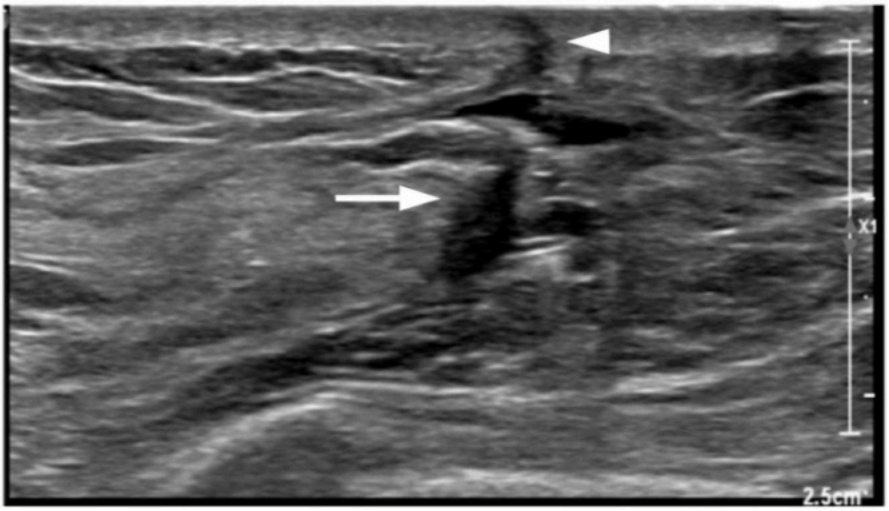

B

Figure 4 – SPECIAL CASES: POSTSURGICAL CHANGES. Screening whole-breast US in two separate patients with a history of breast cancer and lumpectomy. (A) A subtle hypoechoic distortion (arrow) associated with a track to the skin incision/scar (arrowhead). (B) An irregular hypoechoic mass (arrow) with a track to the skin incision/scar (arrowhead). Both findings are consistent with benign scar tissue and correlated with stable postsurgical changes on mammography (not shown).

F. SPECIAL CASES

8. FAT NECROSIS

Fat necrosis may be related to surgical or non-surgical breast trauma and has a variety of appearances on mammography and US [65]. In the acute phase, early fat necrosis will present on US as local edema of the breast fat and will transform into a mixed solid and cystic mass, a complicated cyst or an anechoic cyst, often within 2-6 months. After 1-2 years, fat necrosis may evolve to a calcified oil cyst or spiculated mass, both associated with posterior shadowing and the latter more often associated with surgical trauma. Although the US appearance of fat necrosis may be variable and be associated with suspicious findings, correlation with mammography often confirms the benign diagnosis. Oil cysts (whether solitary or multiple, calcified or non-calcified) are characteristically benign on mammography but not necessarily so on US. Hence, when fat necrosis is suspected at US, and when other more suspicious sonographic features are displayed that potentially represent fat necrosis, the next step before rendering a final assessment should be correlation with a concurrent mammography examination that likely will justify a benign (BI-RADS category 2) assessment that cannot be made with US alone.

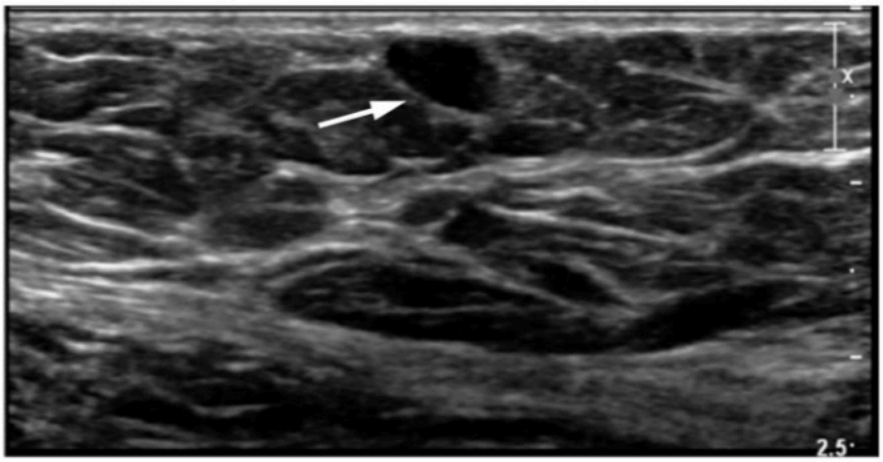

A

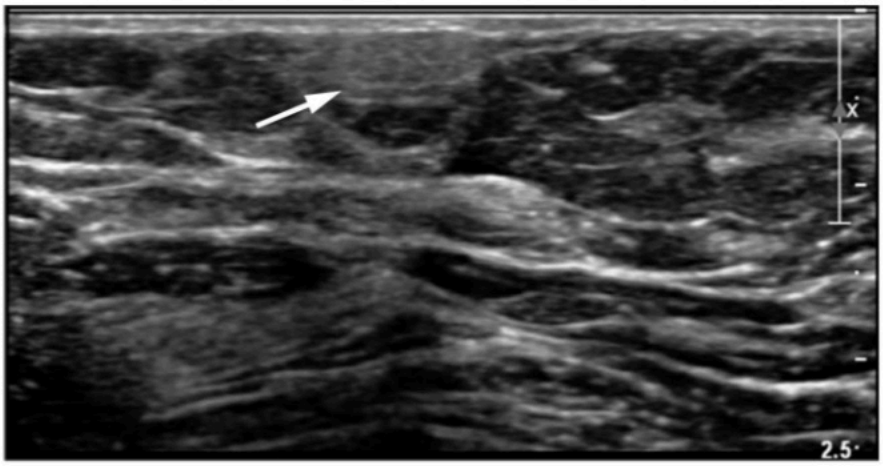

B

Figure 1 – SPECIAL CASES: FAT NECROSIS. (A) Targeted US shows an anechoic circumscribed palpable mass (arrow) in a patient with a history of mastectomy. (B) Follow-up ultrasound 6 months later reveals evolution of the mass which became hyperechoic, consistent with fat necrosis (arrow).

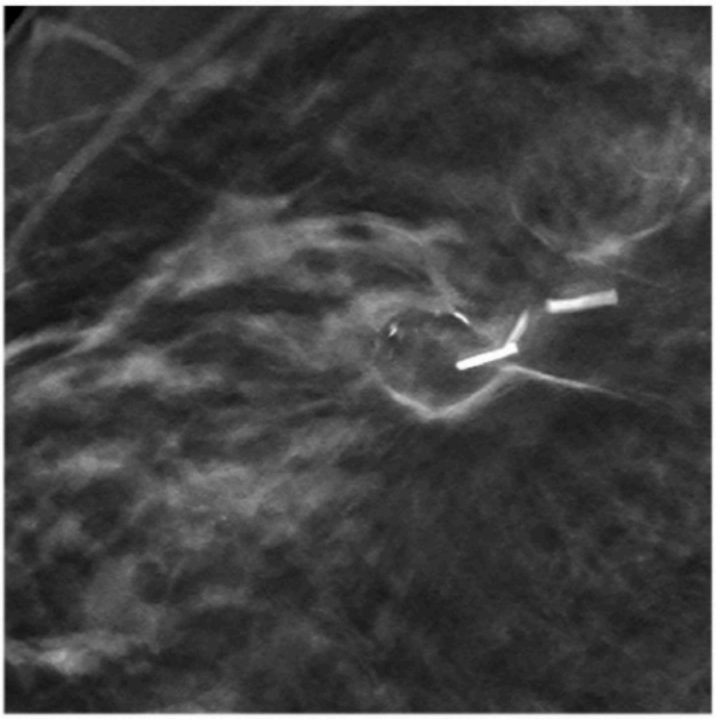

A

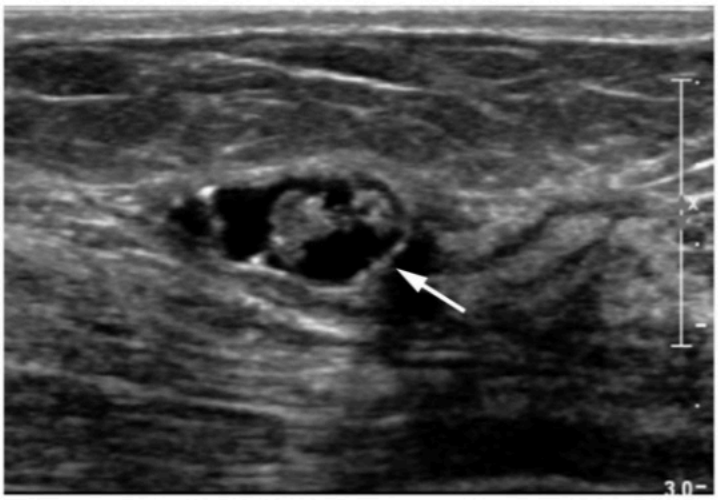

B



C

Figure 2 – SPECIAL CASES: FAT NECROSIS. (A) DBT image shows classic features of benign fat necrosis with a fat density mass exhibiting rim calcification and a surgical clip. (B) US shows a corresponding mixed solid and cystic mass with echogenic rim calcifications (arrow). (C) The echogenic surgical clip (arrow) is also noted within the mass.



A

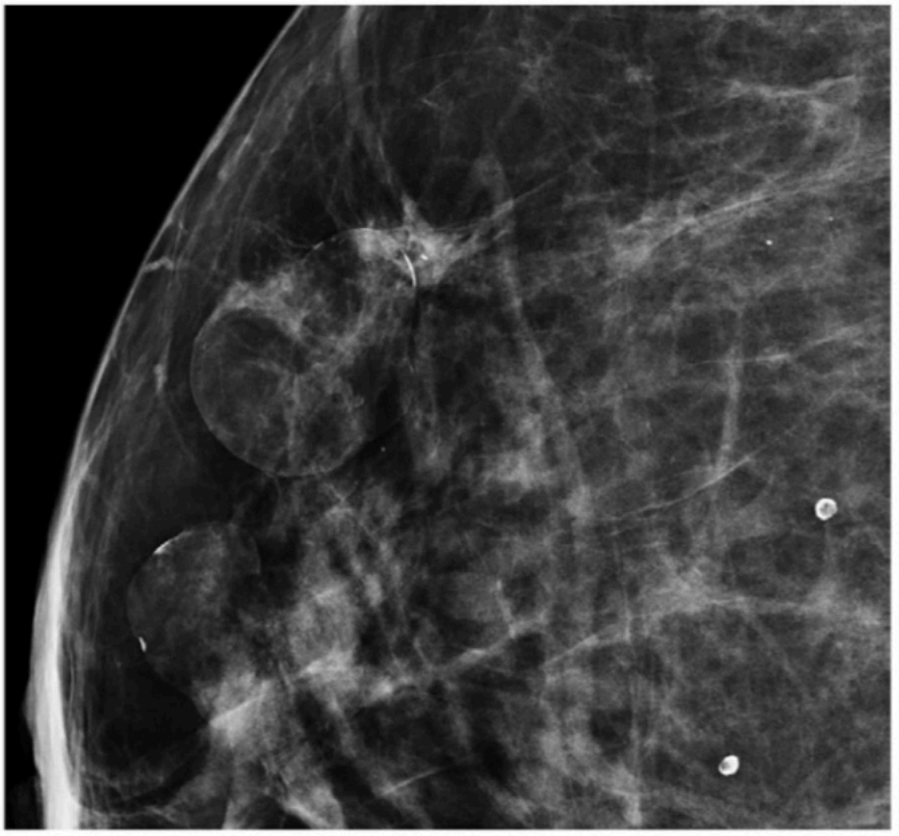

B

Figure 3 – SPECIAL CASES: FAT NECROSIS. (A) Hypoechoic lobulated mixed solid and cystic masses. These were avascular on Doppler interrogation. (B) Corresponding fat containing benign masses seen on mammography.

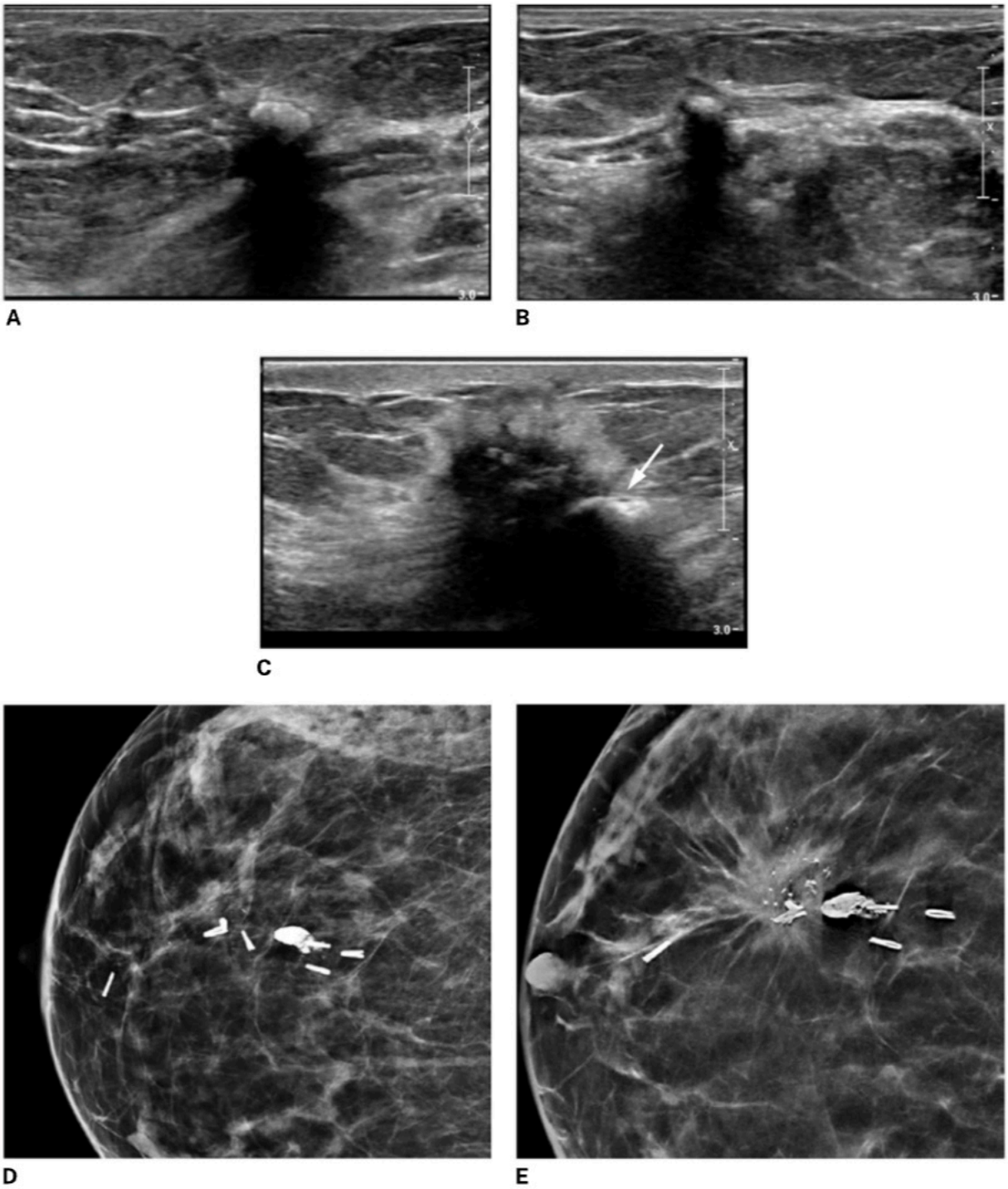

Figure 4 – US shows stable calcified fat necrosis associated with posterior shadowing at the lumpectomy scar (A and B). One year later (C), US shows the lumpectomy scar has enlarged with development of a new irregular spiculated hypoechoic mass with additional posterior shadowing and an echogenic rind extending to skin. The prior, now displaced, rim calcification can be seen at the lower right aspect of the new mass (arrow). (D) and (E) are the corresponding mammograms obtained one year apart confirming unfavorable change, with a new spiculated mass at the lumpectomy site seen in (E). Pathology: Recurrent invasive ductal carcinoma.

F. SPECIAL CASES

9. POST-TRAUMATIC CHANGES (NON-SURGICAL)

Breast trauma may present as a small or large painful, palpable mass or area of thickening that can be accompanied by breast swelling. Ultrasound may demonstrate findings consistent with a hematoma in the acute phase that will evolve over time, or fat necrosis which is seen later during post-trauma changes. Careful correlation with patient history is essential, although patients may not recall minor injuries and bruises to the breast that may still result in findings on physical breast exam or breast imaging.

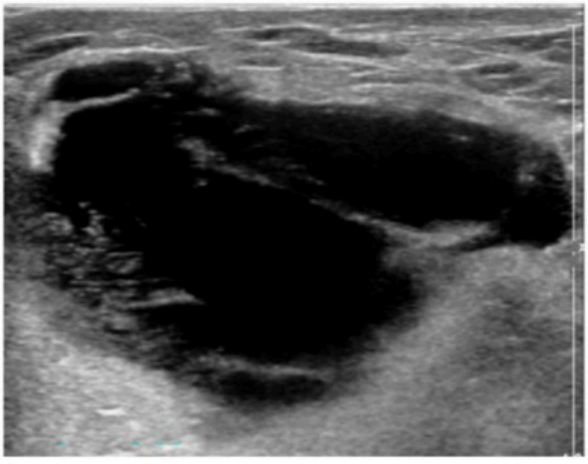

A

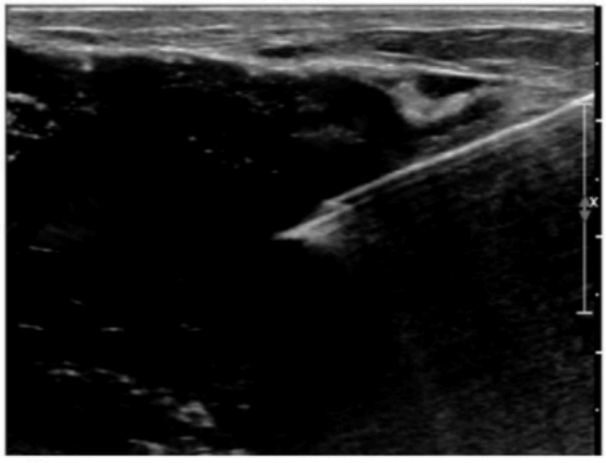

B

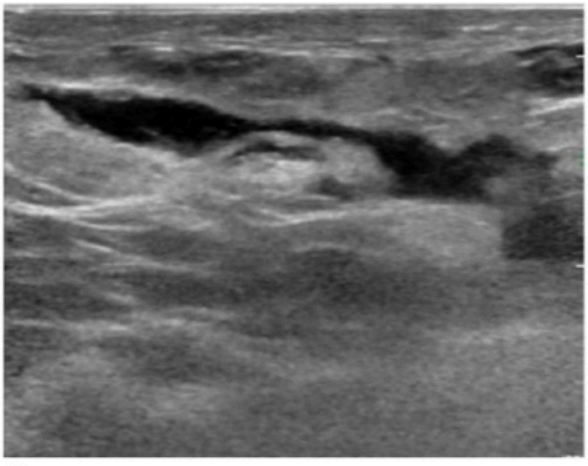

C

Figure 1 – SPECIAL CASES: POST-TRAUMATIC CHANGES (NON-SURGICAL). (A) Large multiseptated mixed solid and cystic mass in a patient presenting with breast pain and swelling 1 week following a car accident. These findings are consistent with a hematoma which was successfully aspirated with US guidance, providing immediate symptomatic relief (B and C). Pathology: Hematoma.

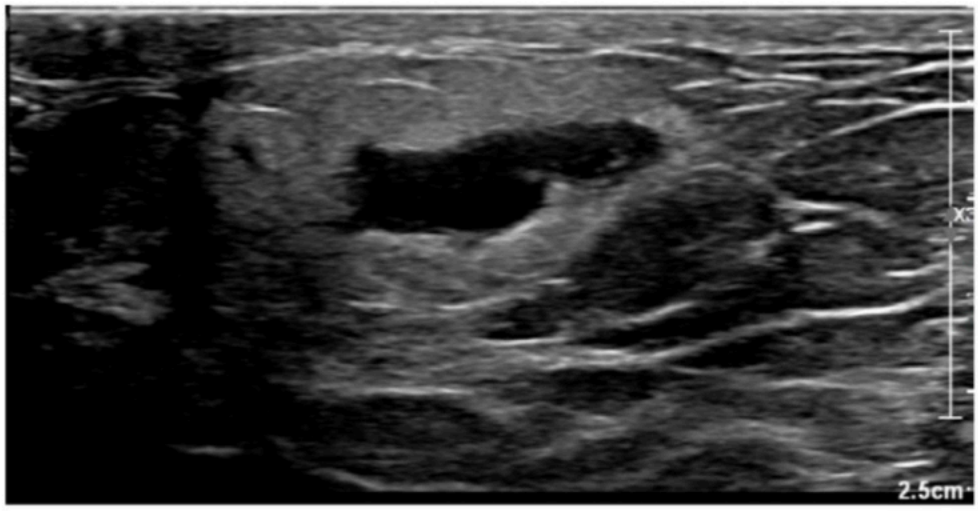

A

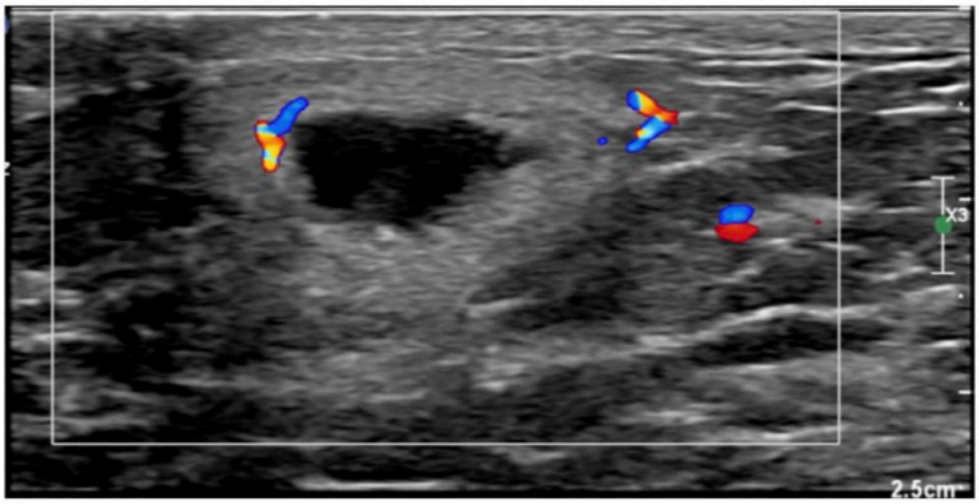

B

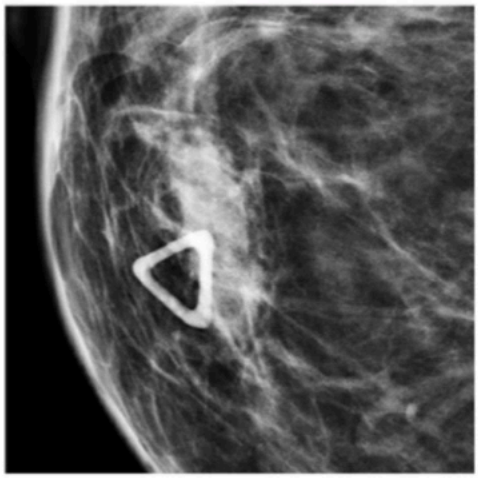

C

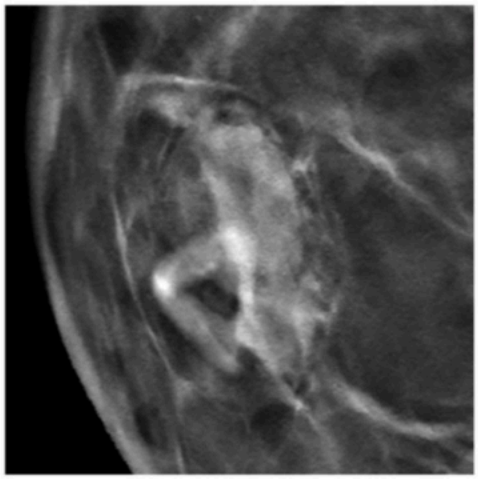

D

Figure 2 – SPECIAL CASES: POST-TRAUMATIC CHANGES (NON-SURGICAL). (A) Oval hypoechoic mass with a thick echogenic rind in the region of palpable concern in a patient presenting with focal right beast pain and a history of bruising in the area. (B) Color Doppler shows peripheral hypervascularity. Digital mammography (C) and DBT (D) demonstrate a corresponding oval mass containing some fat density. This mass was no longer present when the patient returned for mammography 2 years later (not shown), consistent with a hematoma that resolved.

F. SPECIAL CASES

10. ABSCESS

Abscesses typically present with a palpable breast lump associated with pain, swelling, and erythema and are most common during the reproductive years. Puerperal abscesses are related to lactation and non-puerperal abscesses are often associated with smoking, Black race, and medical conditions such as diabetes, obesity, and steroid treatment. Ultrasound is the imaging modality of choice as young age and severe pain may preclude mammography. In women over 30 years of age, mammography can also be performed but may be deferred until acute pain and swelling resolve.

Ultrasound features of abscesses include a heterogeneous predominantly hypoechoic mass with posterior enhancement associated with a thick wall, loculation and increased peripheral vascularity, as well as increased echogenicity of surrounding tissue due to parenchymal edema, and skin thickening. In addition to antibiotic treatment, ultrasound-guided aspiration of the abscess fluid may be performed for symptomatic relief and to shorten the duration of illness [66].

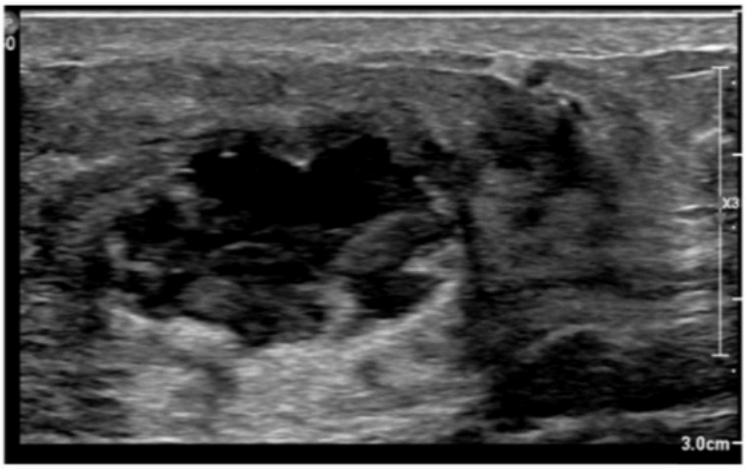

A

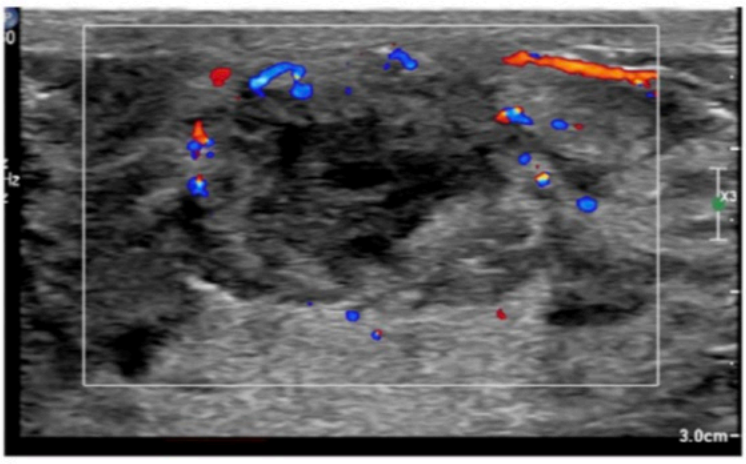

B

Figure 1 – SPECIAL CASES: ABSCESS. Patient presenting with a painful erythematous retroareolar mass. (A) B-mode US reveals a mixed solid and cystic mass. Echogenic portions are consistent with debris. (B) Color Doppler shows peripheral hypervascularity but no internal flow. These findings are consistent with an abscess, which was aspirated with US guidance. The patient was also treated with antibiotics. Pathology: Abscess.

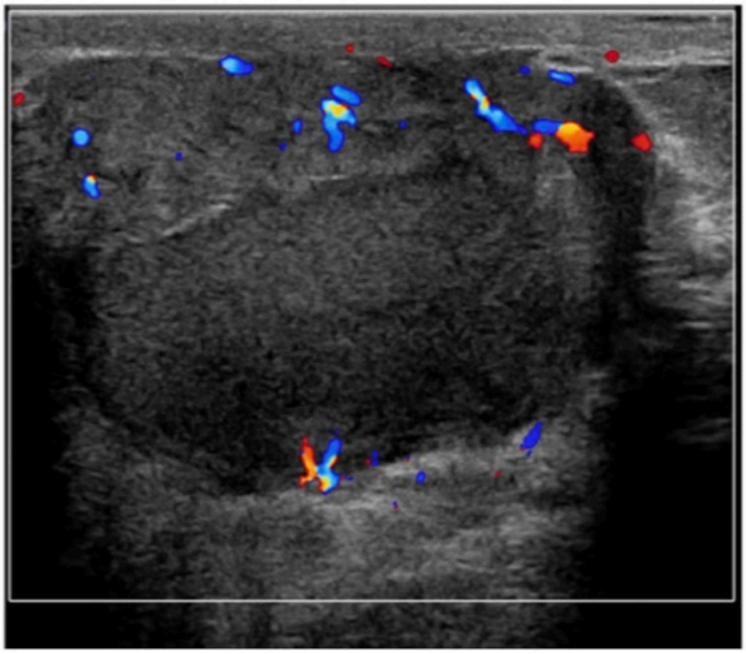

A



B

Figure 2 – SPECIAL CASES: ABSCESS. Painful erythematous breast mass in a lactating patient. (A) Mixed solid and cystic oval mass with peripheral vascularity and skin thickening at the region of palpable concern. This abscess was partially aspirated, and the patient was treated with antibiotics. (B) Follow-up US 2 months later shows a residual anechoic fluid collection. Pathology: Abscess.

F. SPECIAL CASES

11. VASCULAR ABNORMALITIES

Vascular lesions of the breast are typically benign and uncommon. Etiologies include arteriovenous malformation (AVM), pseudoaneurysm and superficial thrombophlebitis (Mondor's disease), as well as hemangioma and venous malformations [67]. AVMs are typically congenital or developmental anomalies, whereas pseudoaneurysms are acquired (usually the result of breast trauma and, rarely, the sequelae of image-guided core needle biopsy). Superficial venous thrombophlebitis within the breast typically presents as a palpable cord with or without associated pain [68].

a. AVMs (including pseudoaneurysm)

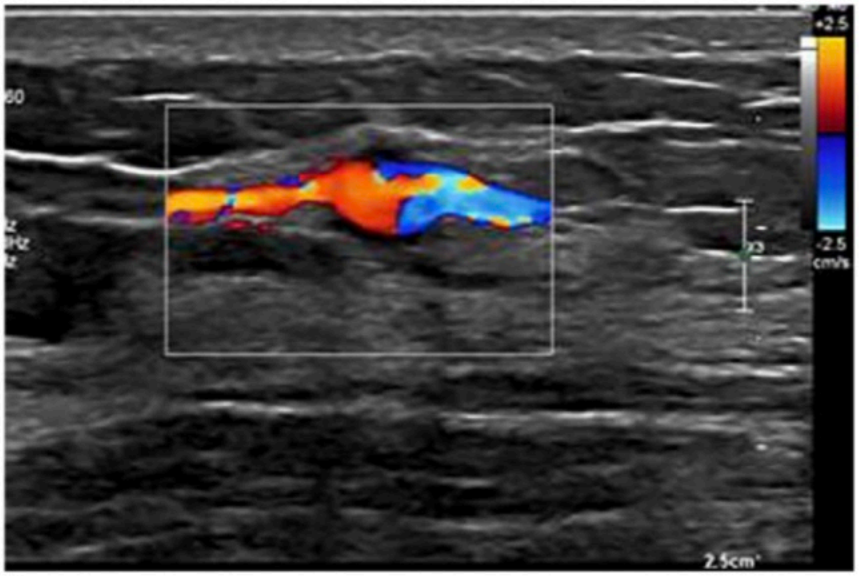

A

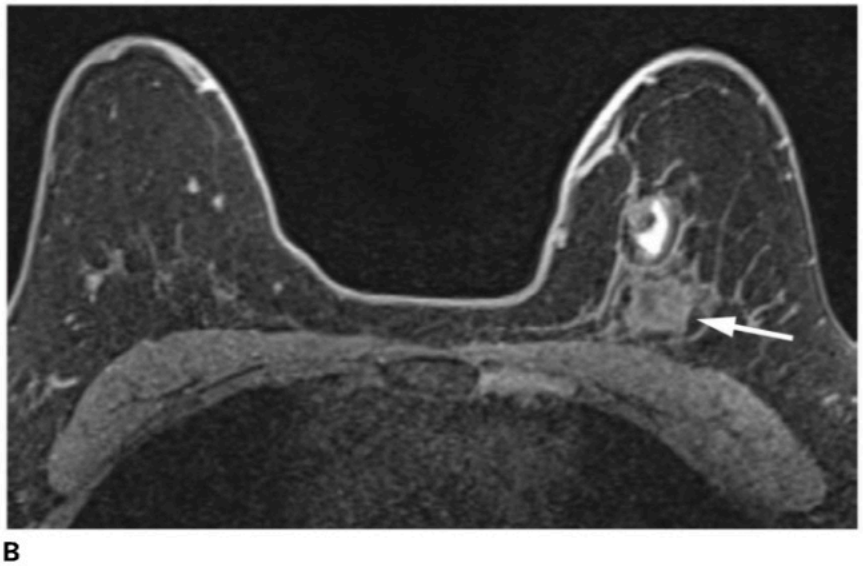

B

Figure 1 – SPECIAL CASES: VASCULAR ABNORMALITIES-PSEUDOANEURYSM. (A) Color Doppler ultrasound depicts the rare complication of a pseudoaneurysm, which developed after US-guided vacuum-assisted biopsy of a 1.9 cm cancer. (B) Pre-contrast T1W MR shows the cancer posteriorly in the left breast (arrow) with a high signal hematoma located directly anterior to it, most likely due to the pseudoaneurysm.

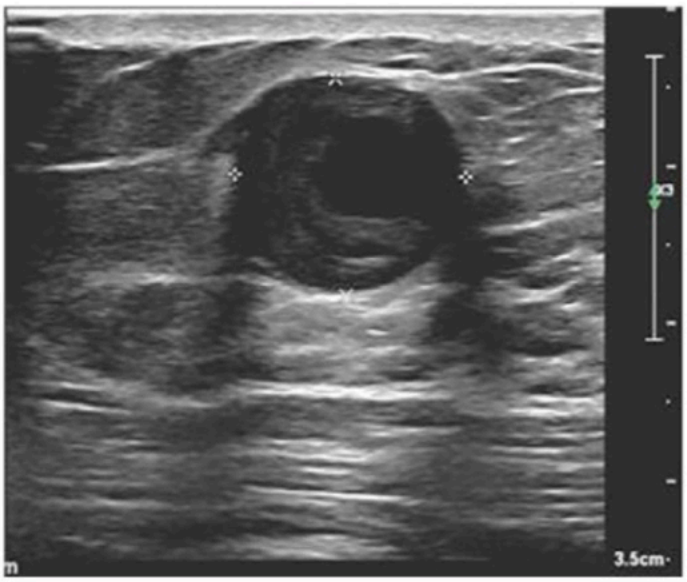

A

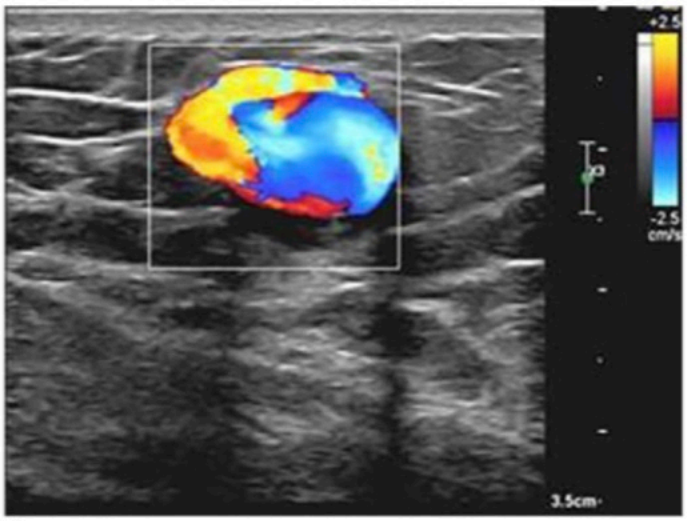

B

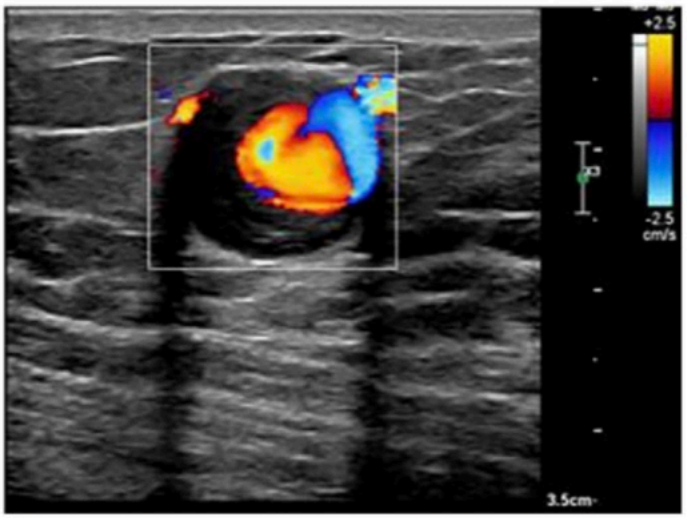

C

Figure 2 – SPECIAL CASES: VASCULAR ABNORMALITIES-PSEUDOANEURYSM. Patient with a new palpable mass in the right breast following moderate emesis related to viral gastroenteritis. (A) Oval mixed solid and cystic mass with posterior enhancement. (B) and (C) Color Doppler interrogation shows the bidirectional and swirling blood flow pattern, also known as the "ying-yang" sign, consistent with a pseudoaneurysm.

F. SPECIAL CASES

11. VASCULAR ABNORMALITIES

    b. Superficial Thrombophlebitis (Mondor's disease)

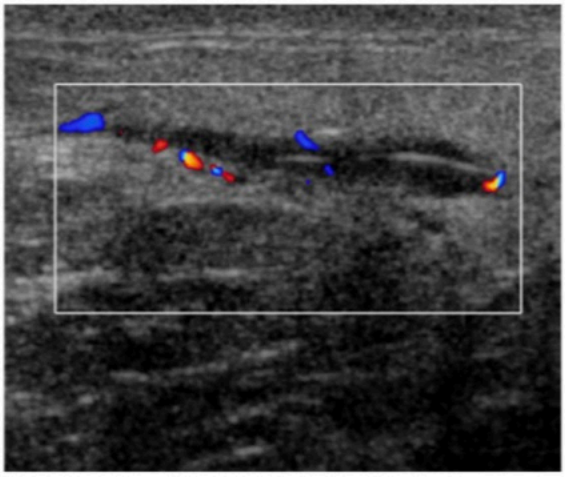

A

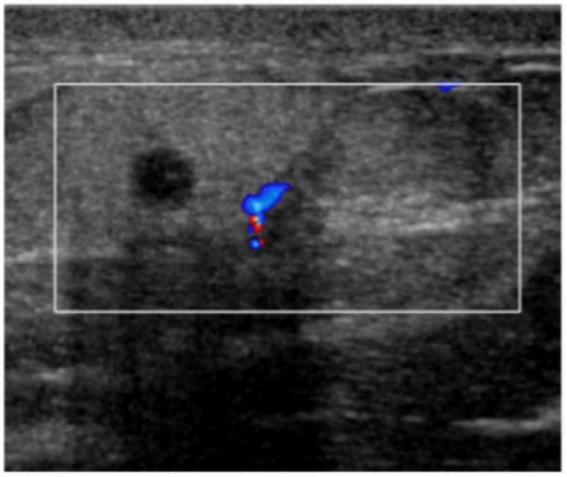

B



C

Figure 3 – SPECIAL CASES: VASCULAR ABNORMALITIES-SUPERFICIAL THROMBOPHLEBITIS (MONDOR'S DISEASE). Patient with a palpable elongated firm lump in the right breast. Radial (A) and antiradial planes with color Doppler (B) show a corresponding tubular, non-compressible structure without internal vascularity. The findings are consistent with superficial thrombophlebitis. The lack of a beaded appearance of the thrombosed superficial vein indicates that the clot is older and retracted. (C) Mammography shows fatty breast tissue and a prominent vessel in the palpable region of concern which was superficial in the lateral aspect of the breast. The palpable mass resolved on follow-up clinical exam.

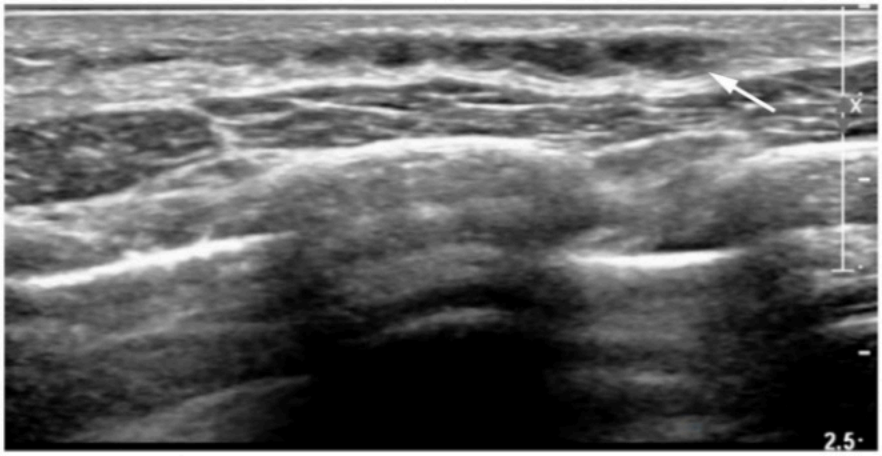

A

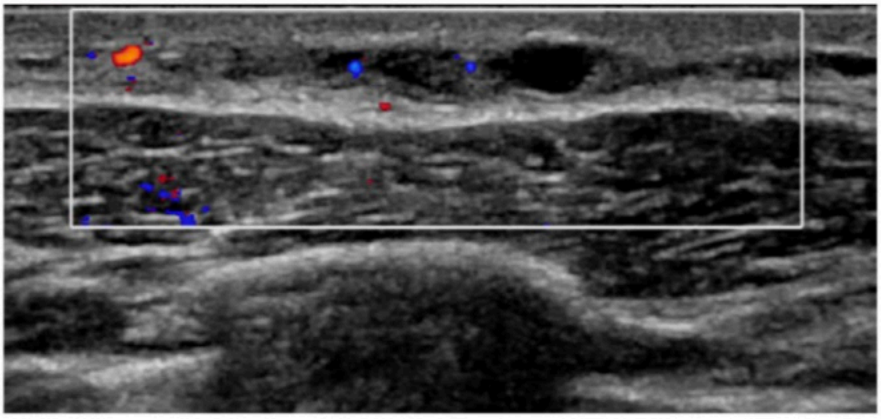

B

Figure 4 – SPECIAL CASES: VASCULAR ABNORMALITIES-SUPERFICIAL THROMBOPHLEBITIS (MONDOR'S DISEASE). Patient with a tender, palpable 5 cm tubular band in the left outer breast. A) Tubular hypoechoic non-compressible structure with some internal echoes corresponding to a palpable cord just below the skin interface (arrow). B) Color Doppler shows no internal flow. The findings are consistent with acute superficial thrombophlebitis which resolved on the follow-up clinical exam.

G. LYMPH NODES

Lymph nodes are normal findings in the breast and in the axilla. Morphologically, they are oval or reniform in shape and circumscribed in margin. Lymph nodes consist of two parts: 1) hypoechoic cortex; 2) echogenic hilum containing fat. The presence of Doppler signal flow into and out of the hilum representing the afferent and efferent blood vessels is helpful in recognizing lymph nodes.

Following is an outline of the parameters that may be used to characterize a lymph node at US [1, 69, 70].

a. Size

b. Shape

   i. Oval or reniform

   ii. Lobulated

      - Round
      - Irregular

c. Cortical thickening (> 3 mm)

   i. Diffuse, concentric, uniform: be wary of technical parameters such as oblique angle of insonation that may falsely increase apparent cortical thickening, both concentric and focal. Real-time scanning should help identify true cortical thickening.

   ii. Focal, eccentric: hypoechoic cortical bulge may be seen in nodal metastases, representing tumor cells trapped in the follicles in the cortex of the lymph node.

d. Margin

   i. Circumscribed

   ii. Non-circumscribed: indistinctness of margin may be a sign of extranodal extension of tumor

e. Hilum

   i. Hilar compression or displacement

      Note that the presence of fat in a nodal hilus does not exclude metastatic involvement; the hilar fat may be compressed or displaced by the metastasis or other pathology. A pathological node may present with diminished or eccentrically located hilar fat.

   ii. Hilar effacement or replacement

      Tumor involvement of the lymph node can result in a spectrum of morphological changes [1, 69, 70]. On the benign-appearing end of the spectrum, a node may show either echogenic fatty hilum only or mostly fatty hilum surrounded by a thin (≤ 3 mm) nearly imperceptible hypoechoic cortex. When a node becomes reactive or subtly involved by tumor, the hypoechoic cortex may become diffusely thickened (> 3 mm) and/or assume a generalized lobulated thickened appearance, as shown in the setting of vaccine-induced reactive adenopathy [71] and nodal metastases of lobular histology [72]. On the malignant-appearing end of the spectrum, the cortical lobulation may be focal, the hilum may be compressed or displaced, or there may be complete absence of the fatty hilum when the entire node is replaced by tumor cells +/– lymphocytes. When there is complete absence of a fatty hilum, there is a high probability of the lymph node being malignant. Nodal hypoechogenicity (representing tumor cells +/– abnormal lymphocytes) has extended beyond or expanded the

cortex because of the ongoing pathological process. The shape is usually round or irregular at this stage, but it would be considered abnormal even if it remains oval.

f. Echogenic foci

Echogenic foci representing calcifications may be seen in lymph nodes. Correlation with clinical history and mammography is helpful in determining etiology. Posterior shadowing may be seen in the setting of granulomatous disease with densely calcified nodes, which are benign. Malignant calcifications may be seen as punctate echogenic foci. Echogenic foci in lymph nodes may also represent foreign bodies, such as marker clips (after biopsy, especially in the setting of planned targeted axillary dissection) or preoperative localization devices (e.g., localizer seeds). Other etiologies of echogenic foci include particles from tattoo ink or gold injection for rheumatoid arthritis.

g. Symmetry

Normal lymph nodes generally appear symmetric when comparing between the right and the left side, and symmetry may be a helpful indicator of benignity when assessing a lymph node that is borderline in morphology.

h. Interval change

Replacement of a node by tumor may be gradual and most readily detected through interval change. However, images of normal-appearing lymph nodes in an axilla may not be recorded at US, so it may not be possible to assess for interval sonographic change. On the other hand, increasing nodal size at mammography or MRI may be a cause for concern and underlie a recommendation for biopsy. In this case, it is important to measure the node in the same, or similar, projection on the current and previous mammograms.

i. Clinical correlation

Breast cancer generally metastasizes via lymphatic (rather than hematogenous) spread. Hence, malignancy must be considered in the setting of an abnormal node at ultrasound. At the same time, there are many benign or non-breast-cancer etiologies for an abnormal node, such as autoimmune processes, connective tissue disorders, granulomatous disease, lymphoma, or vaccine-related adenopathy (as seen with COVID-19, influenza, pneumococcus, shingles, and other vaccinations). Correlation with clinical history is of utmost importance for optimal patient management.

G. LYMPH NODES

1. LYMPH NODES — INTRAMAMMARY

Intramammary lymph nodes may exist throughout the breast, but they are most commonly seen in the upper outer quadrant and in the posterior third (especially the axillary tail). They may be seen adjacent to blood vessels. The usual size of normal intramammary lymph nodes ranges from 3 to 4 mm up to approximately 1 cm, but they may be larger. Given their usual small size, the echogenic fat may be challenging to visualize. Use of Doppler imaging is helpful in such situations to identify the hilum, where the afferent artery and efferent vein reside. When the classic features of an intramammary lymph node are depicted, the finding may be considered benign. However, breast cancer may metastasize to intramammary lymph nodes, in which case they may be enlarged and appear round or irregular. Metastases to intramammary lymph nodes are considered the same as metastases to axillary level I nodes in TNM staging.

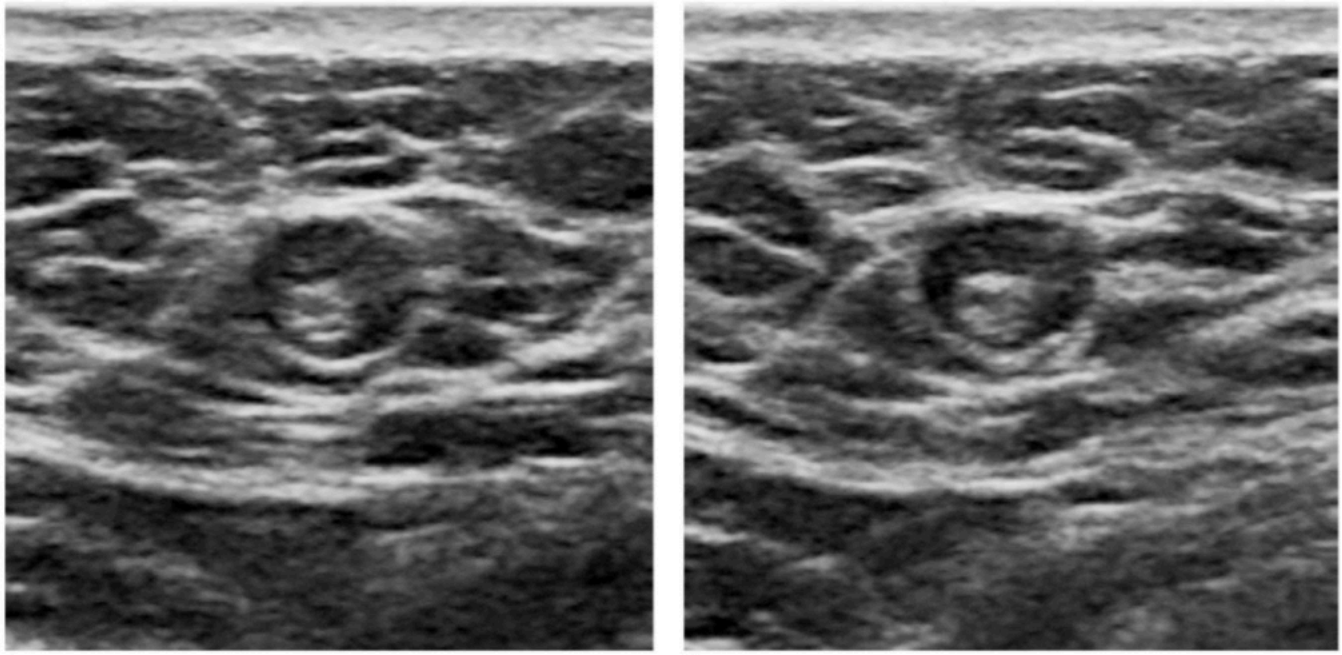

A B

Figure 1 – LYMPH NODES – INTRAMAMMARY, NORMAL. Longitudinal (A) and transverse (B) US images of an incidentally identified normal intramammary lymph node. Note the central hilar fat surrounded by 2-mm cortex.

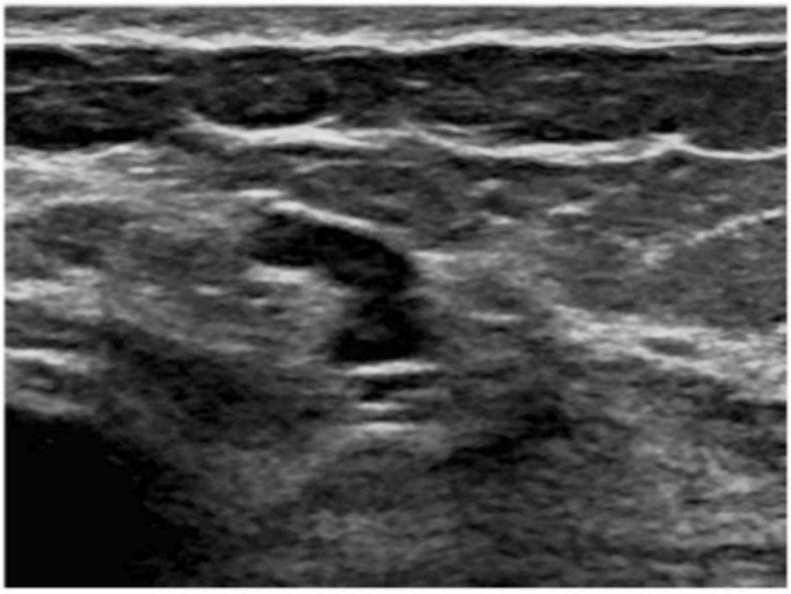

A

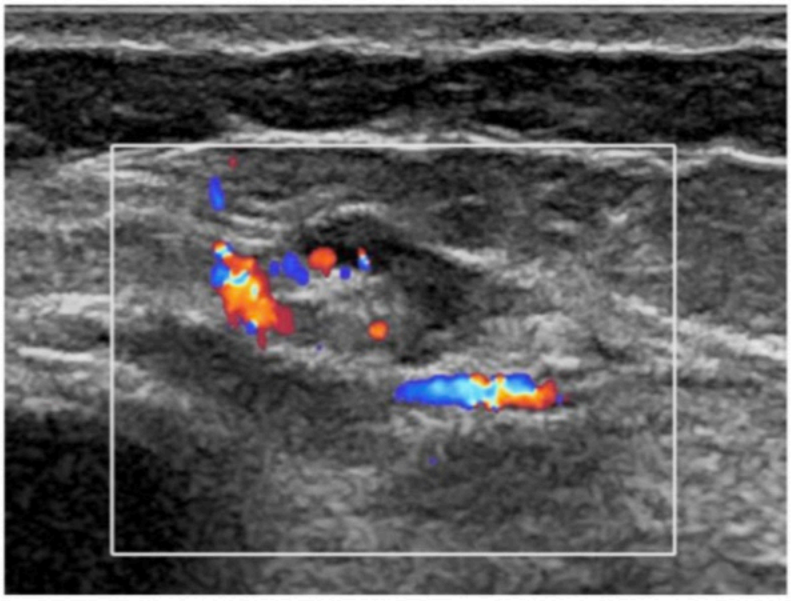

B

Figure 2 – LYMPH NODES – INTRAMAMMARY, NORMAL. Transverse (A) and Doppler (B) US images of an incidentally identified normal intramammary lymph node. Note the Doppler signal in the region of the echogenic hilum indicating normal afferent and efferent blood flow into and out of the node.

G. LYMPH NODES

2. LYMPH NODES — AXILLARY

Morphologically abnormal axillary lymph nodes may warrant comment, clinical correlation, and additional evaluation, especially if they are new or considerably larger or rounder when compared to a previous examination. There is no upper limit of size for an axillary lymph node with normal morphology. The larger the lymph node, the thinner the hypoechoic cortex should appear relative to the overall size of the node, and central echogenic hilar fat should be seen. At the same time, even when a lymph node is not enlarged, the compression, displacement, or absence of fatty hilum suggests pathology, as do cortical morphological abnormalities and marked hypoechogenicity. However, there is no specific sonographic feature that reliably distinguishes a nodal metastasis from a benign reactive node. Because of individual variability in the size and number of axillary lymph nodes, assessment of side-to-side symmetry between the right and left axillae is often helpful.

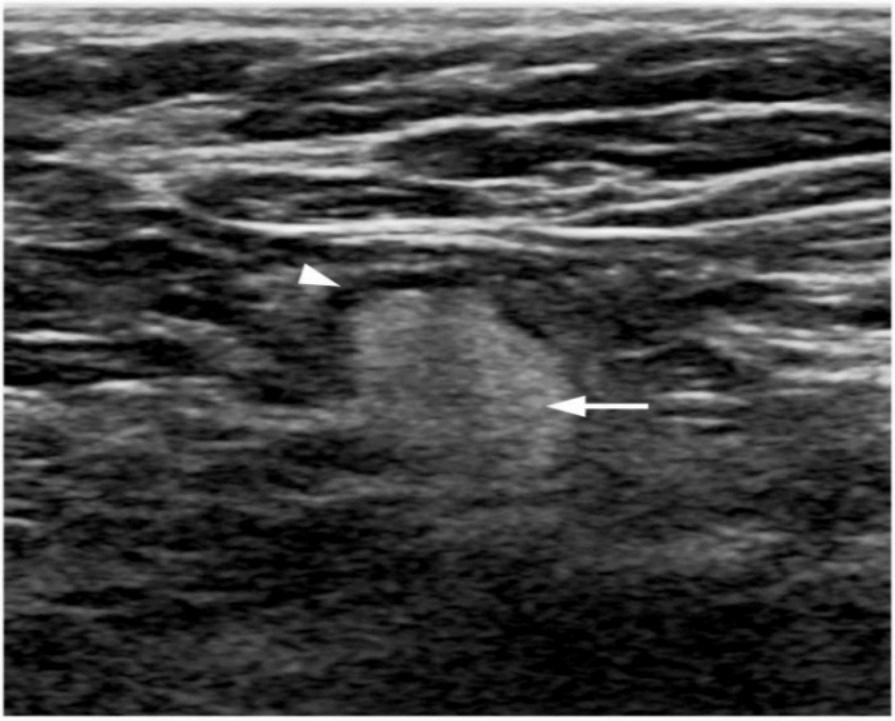

Figure 1 – LYMPH NODES – AXILLARY, NORMAL. US images of an incidentally identified normal axillary lymph node. Note that this node is composed predominantly of echogenic hilum (arrow) with a nearly imperceptible rim of hypoechoic cortex (arrowhead).

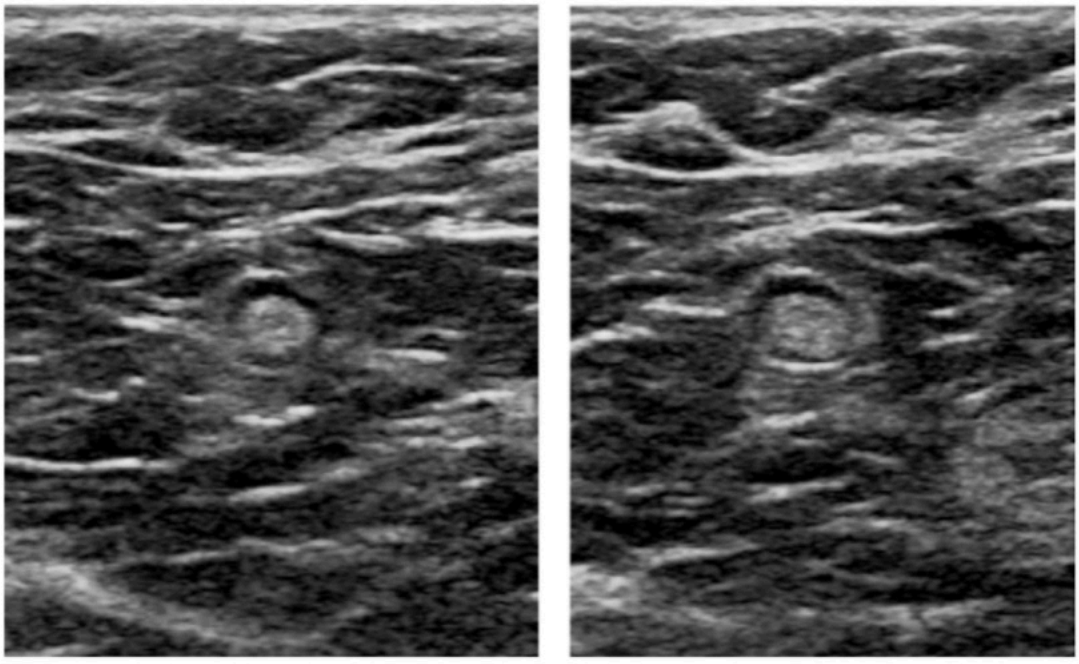

A B

Figure 2 – LYMPH NODES – AXILLARY, NORMAL. Longitudinal (A) and transverse (B) US images of a normal axillary lymph node. Note the central hilar fat surrounded by 2-mm hypoechoic cortex.

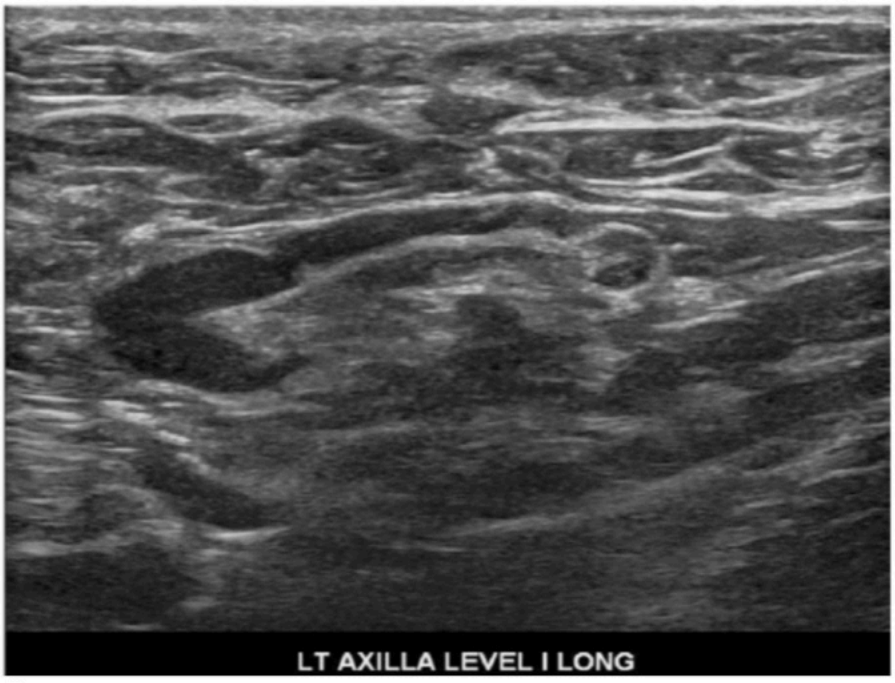

A

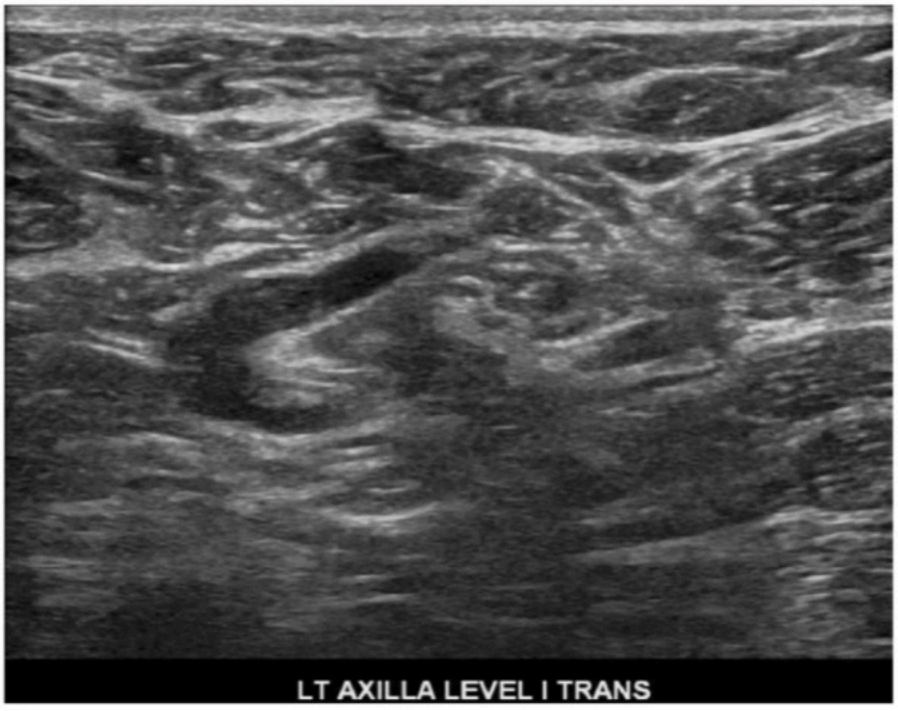

B

Figure 3 – LYMPH NODES – AXILLARY, NORMAL. Longitudinal (A) and transverse (B) US images of a normal axillary lymph node. Note the central hilar fat is predominantly echogenic relative to the hypoechoic cortex. Although the overall size of this node is > 3 cm, it is composed largely of echogenic hilum and hence consistent with a normal node.

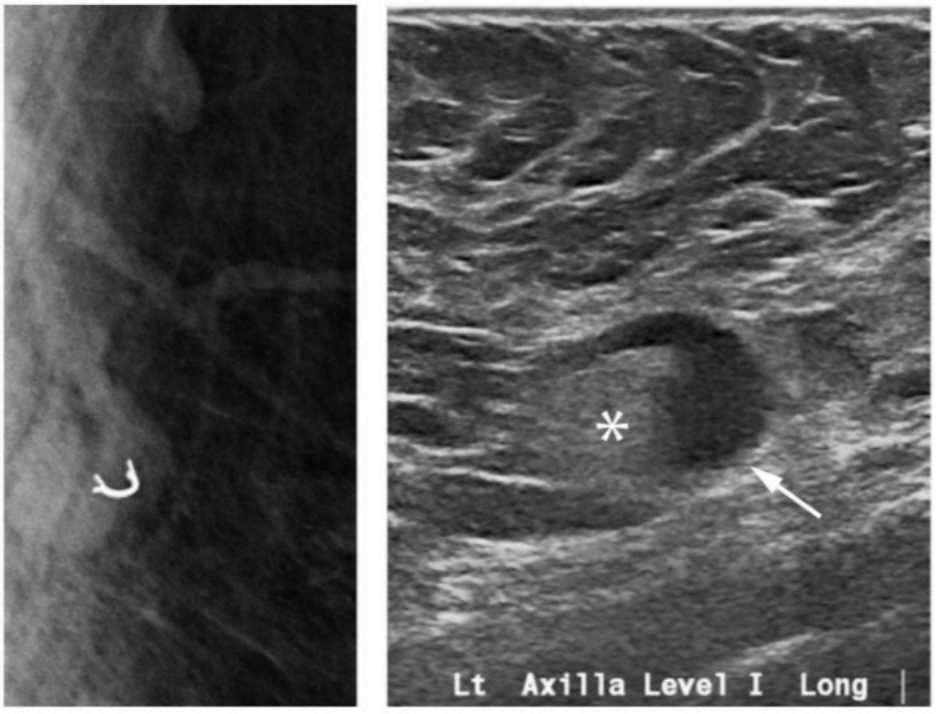

A B

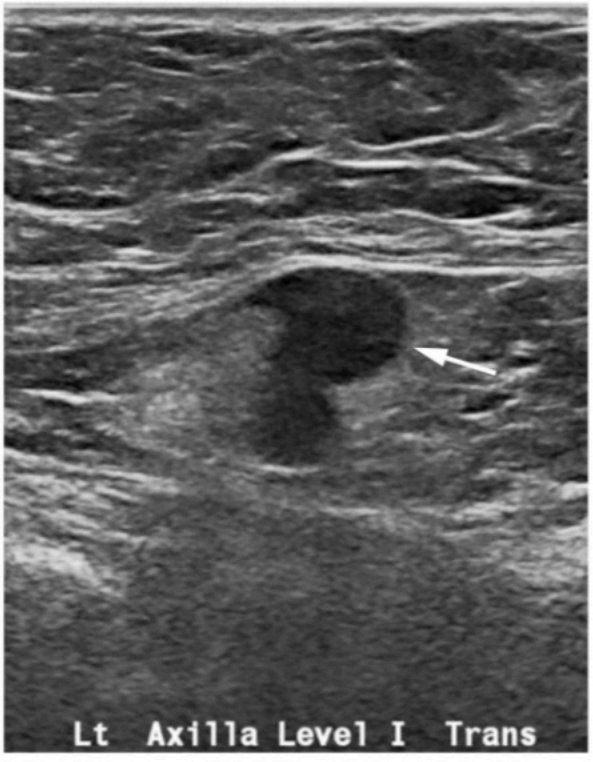

C

Figure 4 – LYMPH NODES – AXILLARY, ABNORMAL. MLO mammogram of the left axilla (A) showing a metastatic axillary lymph node with marker clip. Longitudinal (B) and transverse (C) US images of the metastatic axillary lymph node. Despite the presence of the echogenic fatty hilum (asterisk), there is focal cortical thickening and lobulation (arrows) representing metastatic deposits, measuring up to 7 mm and best seen in the transverse plane.

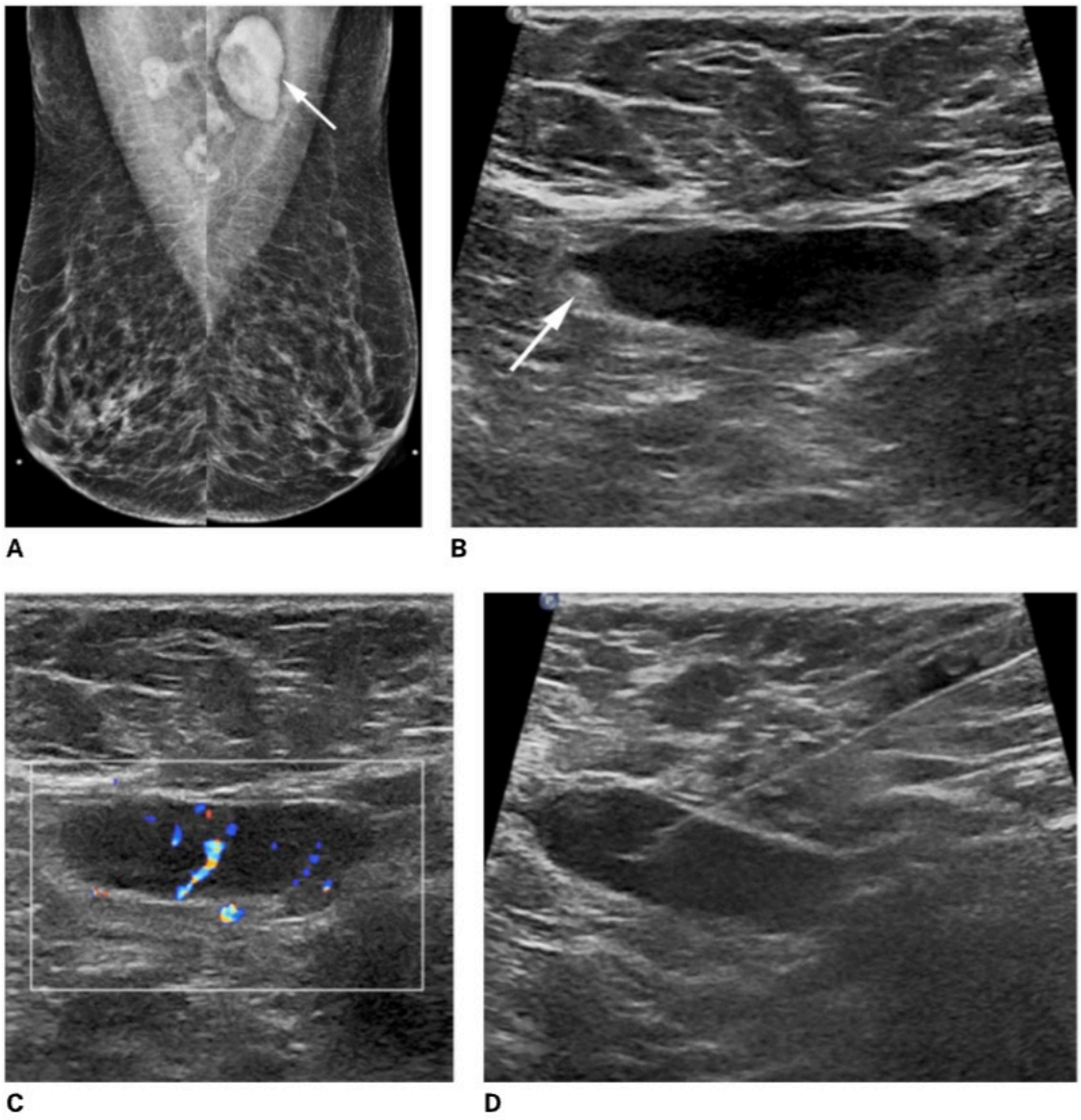

Figure 5 – LYMPH NODES – AXILLARY, ABNORMAL. Bilateral MLO mammograms (A) show an abnormal node in the left axilla (arrow). While it maintains an oval reniform shape with some retained fatty hilum, it is enlarged with a thickened cortex and appears different from the other nodes. The mammogram examination is otherwise negative, and the patient is asymptomatic. Corresponding longitudinal US (B) image of the abnormal node show that despite the maintenance of the oval reniform shape, the echogenic hilum (arrow) is compressed and displaced, and the hypoechoic cortex is uniformly thickened (> 10 mm). Doppler US image in the transverse plane (C) shows increased vascularity in the cortex of the abnormal node. US-guided fine-needle aspiration biopsy image (D) shows the echogenic needle sampling the cortex. Cytological evaluation revealed polytypic lymphoid population, favoring a reactive process (such as connective tissue or autoimmune disorder). Imaging and clinical stability 2 years later (without evidence of malignancy) support the non-malignant diagnosis.

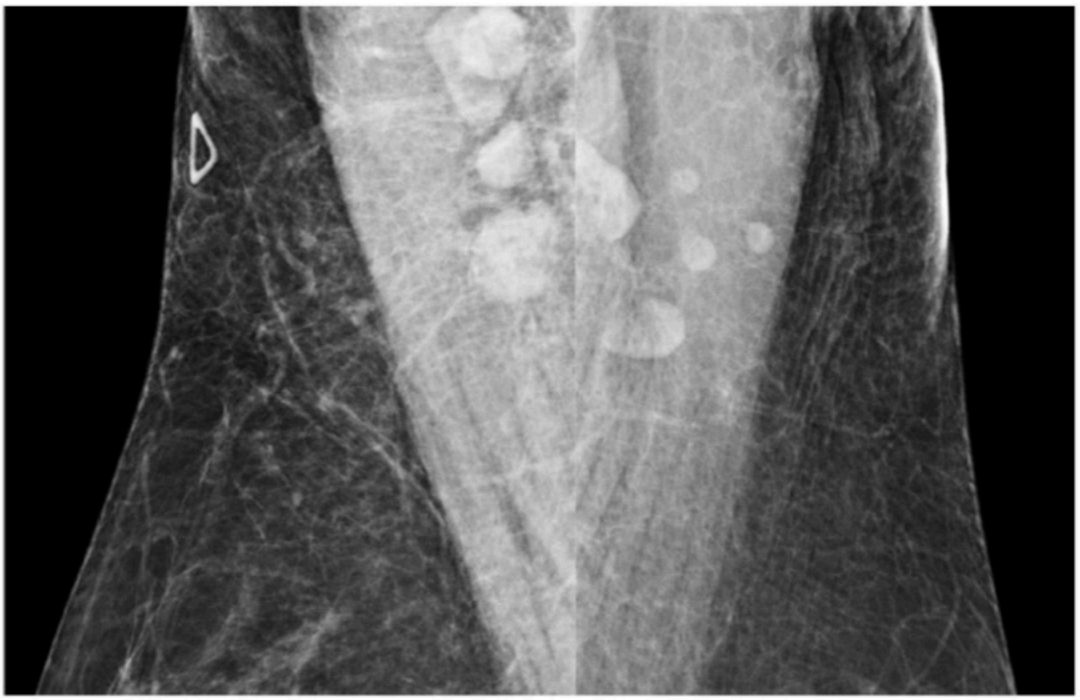

A

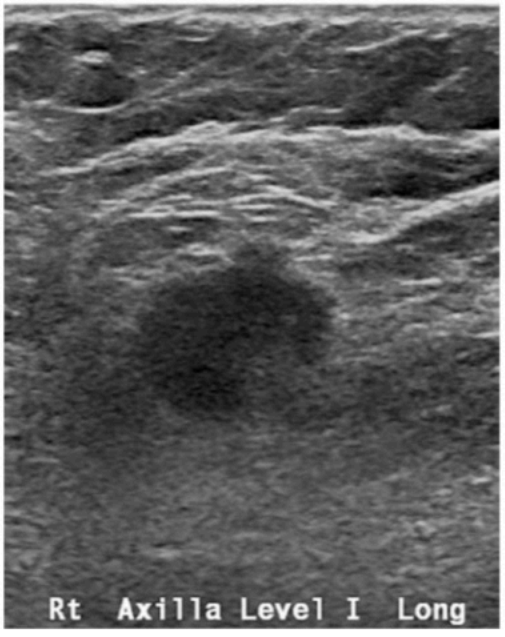

B

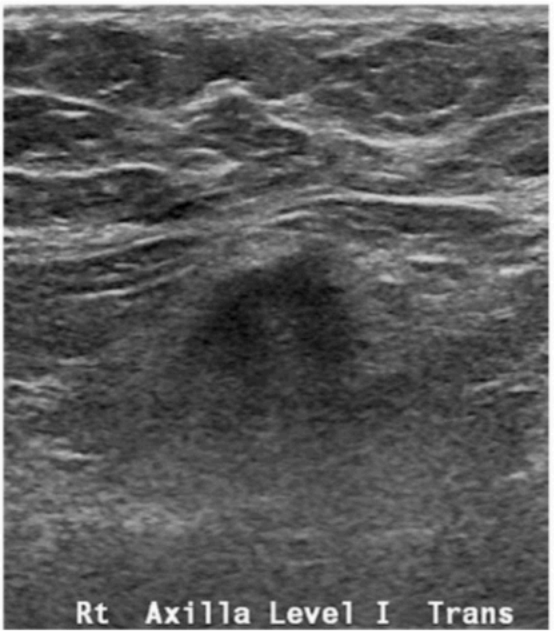

C

Figure 6 – LYMPH NODES – AXILLARY, ABNORMAL. Bilateral MLO mammograms of the axillae (A) in a patient with newly diagnosed right breast cancer. There are palpable nodes in the right axilla, denoted by the triangular marker. The nodes in the right axilla appear asymmetrically enlarged compared with those in the left axilla. Longitudinal (B) and transverse (C) US images of one of the palpable axillary nodes. This is a malignant node. There is near complete obliteration of the fatty hilum. The margin is non-circumscribed; the indistinctness of the margin suggests extranodal extension, which was confirmed at surgery.

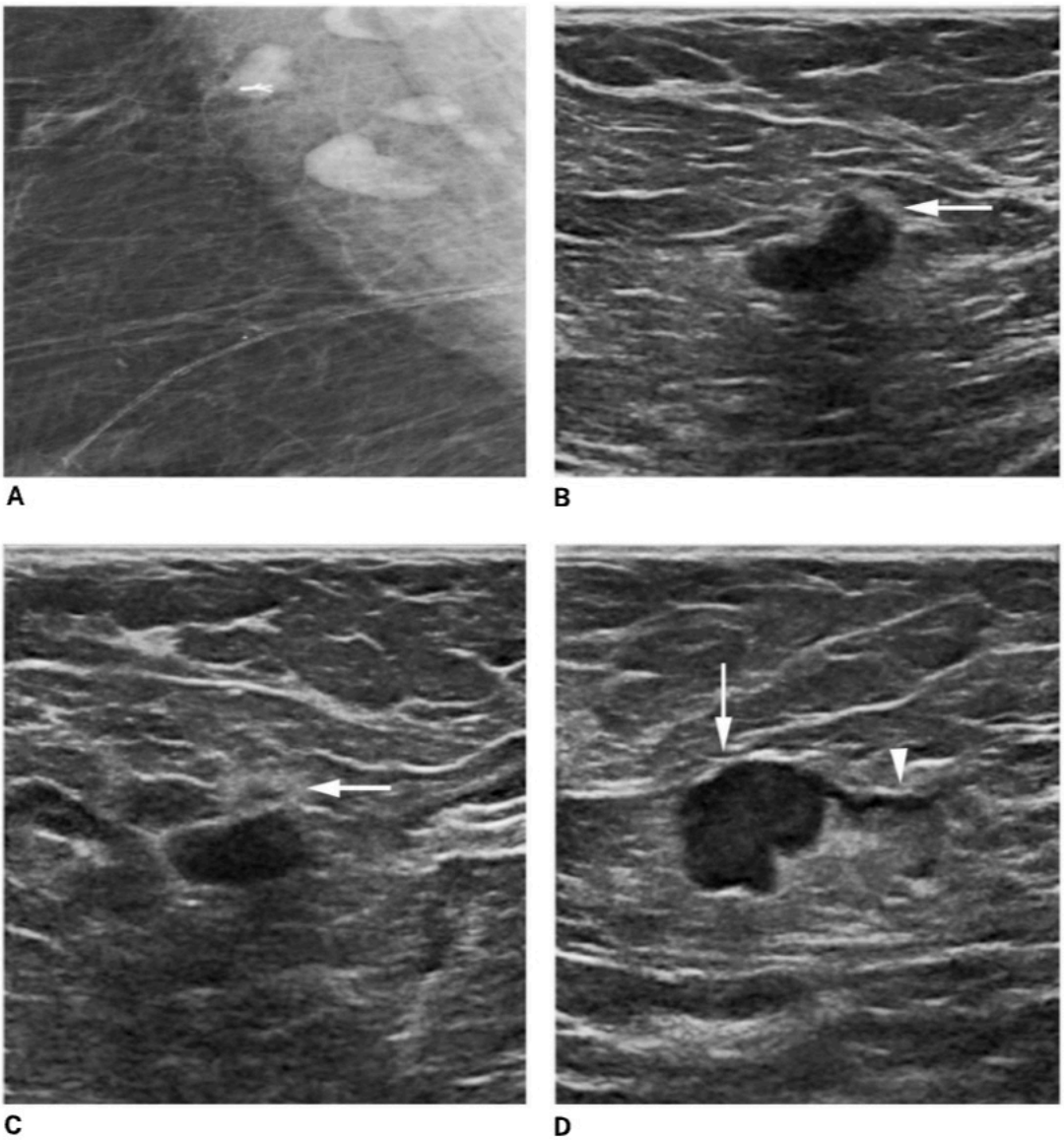

Figure 7 – LYMPH NODES – AXILLARY, ABNORMAL. MLO mammogram of the right axilla (A) in a patient with newly diagnosed right breast cancer, showing metastatic adenopathy, including a biopsied axillary lymph node with marker clip and complete loss of the fatty hilum. Corresponding longitudinal (B) and transverse (C) US images of the biopsied metastatic axillary lymph node. Note that there is complete loss of the echogenic hilum and that the node is completely hypoechoic. The shape is irregular. There is suggestion of an echogenic rind (arrows), similar to the reaction that may be seen at ultrasound imaging of breast cancers. US images of an additional node in the right axilla (D). There is eccentric focal cortical thickening (arrow), compared with the adjacent thin rim of hypoechoic cortex (arrowhead). The focal cortical lobulation primarily represents tumor deposits. The echogenic hilum is displaced by the focal cortical lobulation.

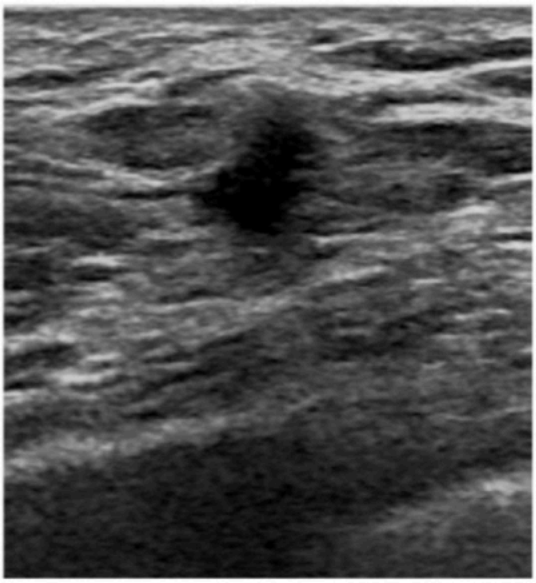

A



B

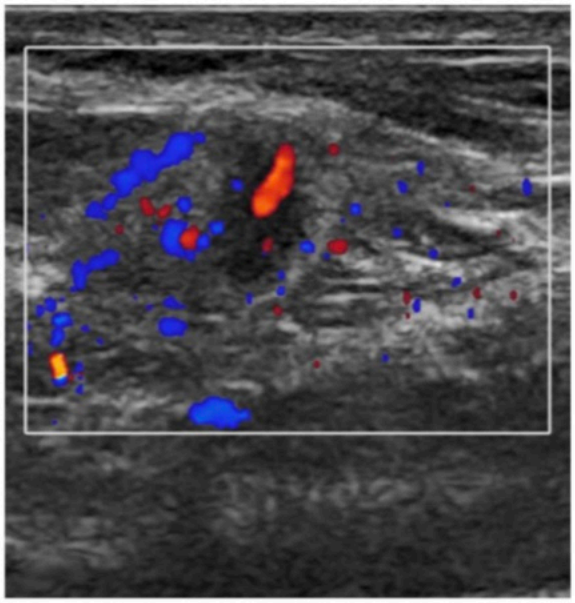

C

Figure 8 – LYMPH NODES – AXILLARY, ABNORMAL. Longitudinal (A) and transverse (B) US images of an axillary node in a patient with recent diagnosis of locally invasive breast cancer of ductal histology in the ipsilateral breast. The nodal shape is irregular, the margin is non-circumscribed, and the fatty hilum has been completely replaced. There is an echogenic rind (best seen in B), similar to the reaction that may be seen at ultrasound imaging of breast cancers. Doppler US in the transverse plane (C) shows an extra-hilar penetrating vessel (shown in red) in the malignant node.

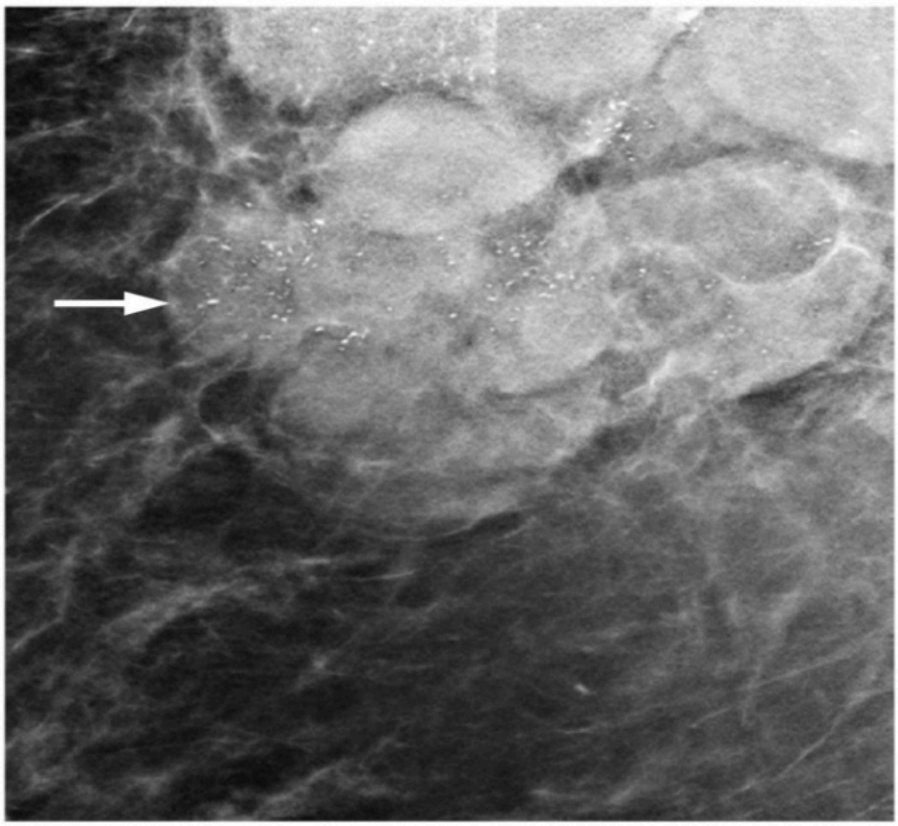

A

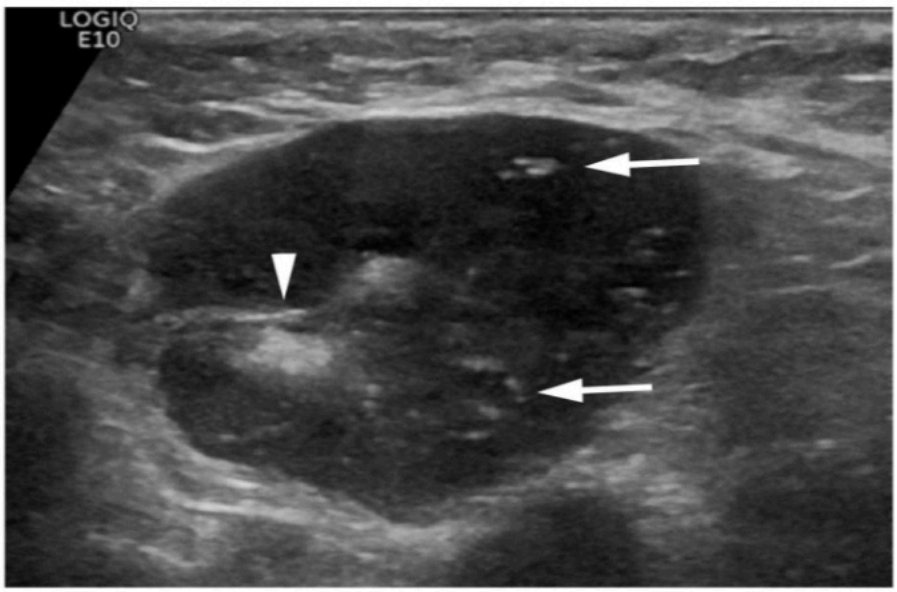

B

Figure 9 – LYMPH NODES – AXILLARY, ABNORMAL. MLO mammogram of the right axilla (A) showing matted malignant adenopathy (in patient with ipsilateral breast cancer) containing fine pleomorphic calcifications (arrow). Corresponding transverse US image of one of the axillary nodes (B) shows multiple echogenic foci representing the malignant microcalcifications (arrows) and compression of the fatty hilum (arrowhead).

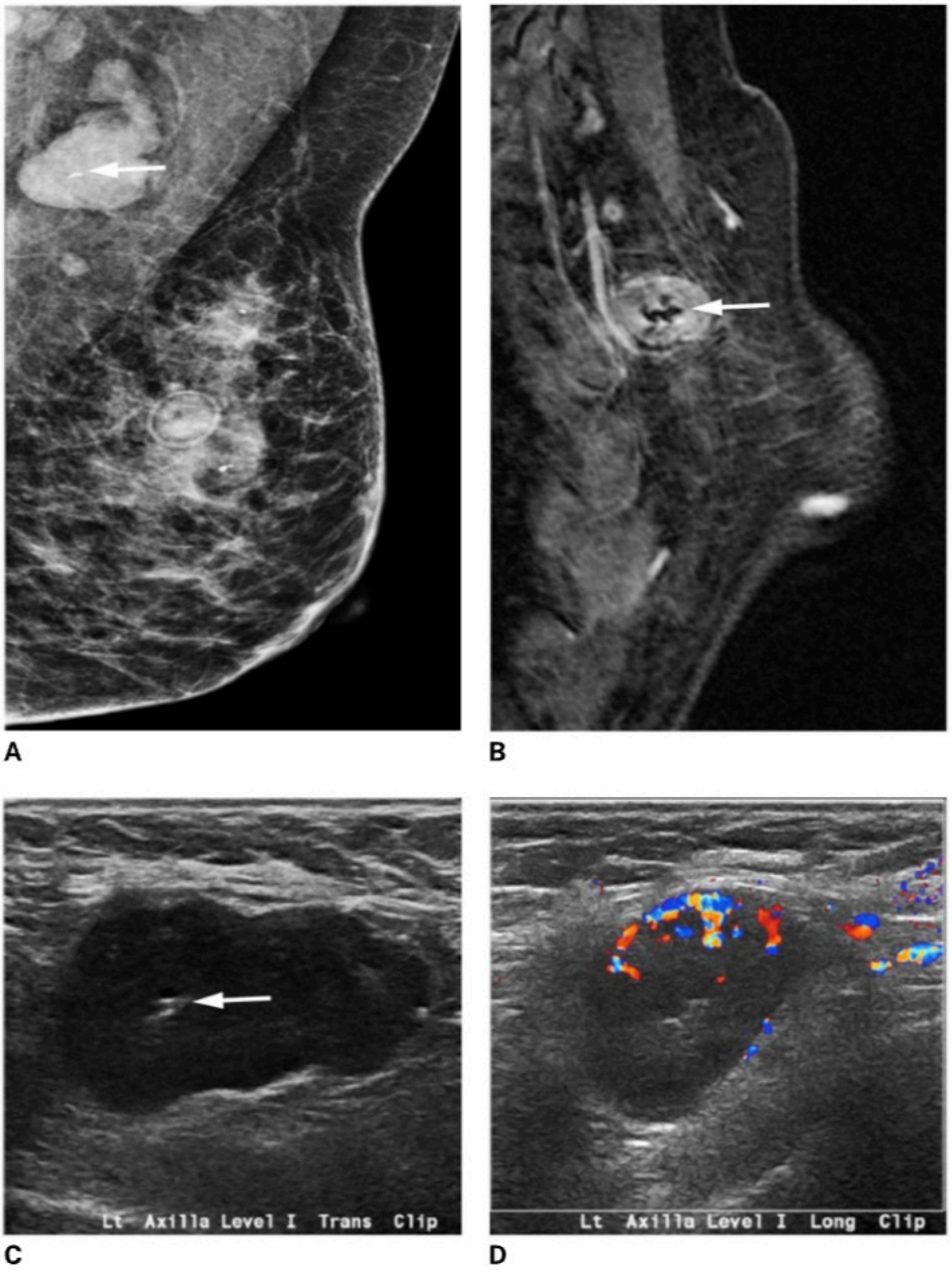

Figure 10 – LYMPH NODES – AXILLARY, ABNORMAL. Left MLO mammogram (A) and sagittal contrast-enhanced MRI of the left breast (B) in a patient with newly diagnosed left breast cancer and left axillary adenopathy. Marker clip indicates the biopsied node (documenting metastatic nodal involvement), seen as a radiodense foreign body at mammography (arrow) and as a signal void at MRI (arrow). Transverse (C) US image of the biopsied node that revealed metastatic nodal involvement. The marker clip is seen as a linear echogenic focus (arrow). Although the margin is circumscribed, the fatty hilum has been completely replaced, indicating metastatic involvement. Doppler US image in the longitudinal plane (D) reveals increased vascularity in the cortex.

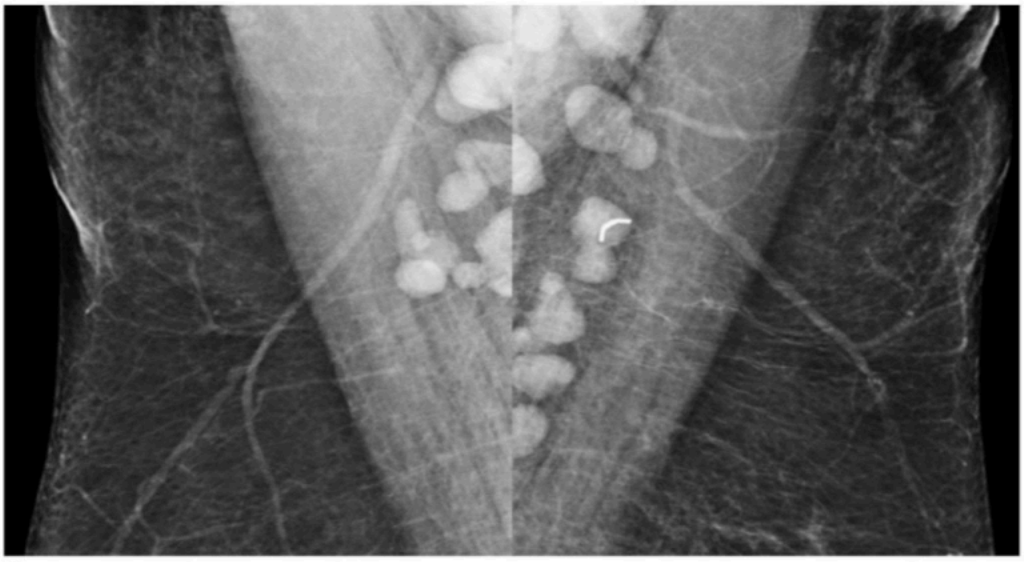

A

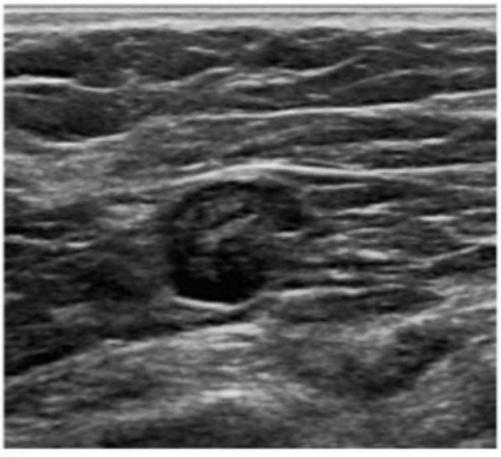

B

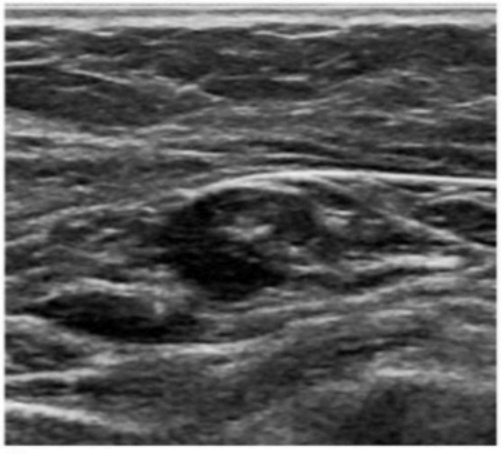

C

Figure 11 – LYMPH NODES – AXILLARY, ABNORMAL. Bilateral MLO mammograms (A) of the axillae in a patient with newly diagnosed left breast cancer. Patient has a history of chronic lymphocytic leukemia and generalized enlarged nodes. One of the axillary nodes was biopsied and marked with a clip. Longitudinal (B) and transverse (C) US images of the axillary node that had undergone biopsy. Note the diffuse cortical thickening of > 3 mm and compression of the fatty hilum. Pathology: Chronic lymphocytic leukemia and no evidence of adenocarcinoma to suggest breast cancer metastasis.

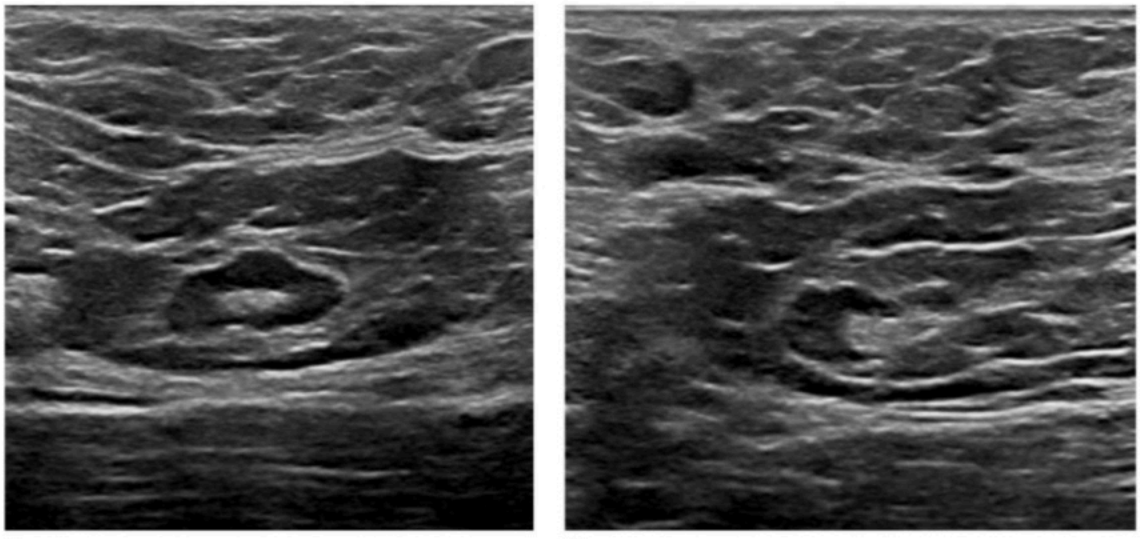

A B

Figure 12 – LYMPH NODES – AXILLARY, ABNORMAL. Longitudinal (A) and transverse (B) US images of the left axilla in a patient with recent history of COVID-19 vaccination in the left arm. Note the mild diffuse cortical thickening of 5 mm with preservation of the fatty hilum. There were multiple other nodes in the left axilla with similar cortical thickening, as expected for reactive adenopathy.

In staging breast cancer, regional (not metastatic or stage 4) nodal disease includes tumor spread to the ipsilateral axilla, internal mammary chain, or supraclavicular space. These are termed regional nodal basins. Any metastases to the contralateral nodal basins would be stage 4 metastatic disease. Ultrasound of the nodal regions may be performed to effectively determine the N stage [1, 70, 73, 74].

From the surgical perspective, the axilla is divided into three levels: I, II, and III. The pectoralis minor muscle serves as the landmark, with the following definitions:

a. Level I: lateral to the lateral margin of the pectoralis minor muscle.

b. Level II: posterior to the pectoralis minor muscle, or between the pectoralis major and pectoralis minor muscles (also known as interpectoral node or Rotter's node); to guide surgical excision, an abnormal interpectoral node (i.e. Rotter's node) should be specified as such rather than generically referred to as a level II node.

c. Level III: medial to the medial margin of the pectoralis minor muscle.

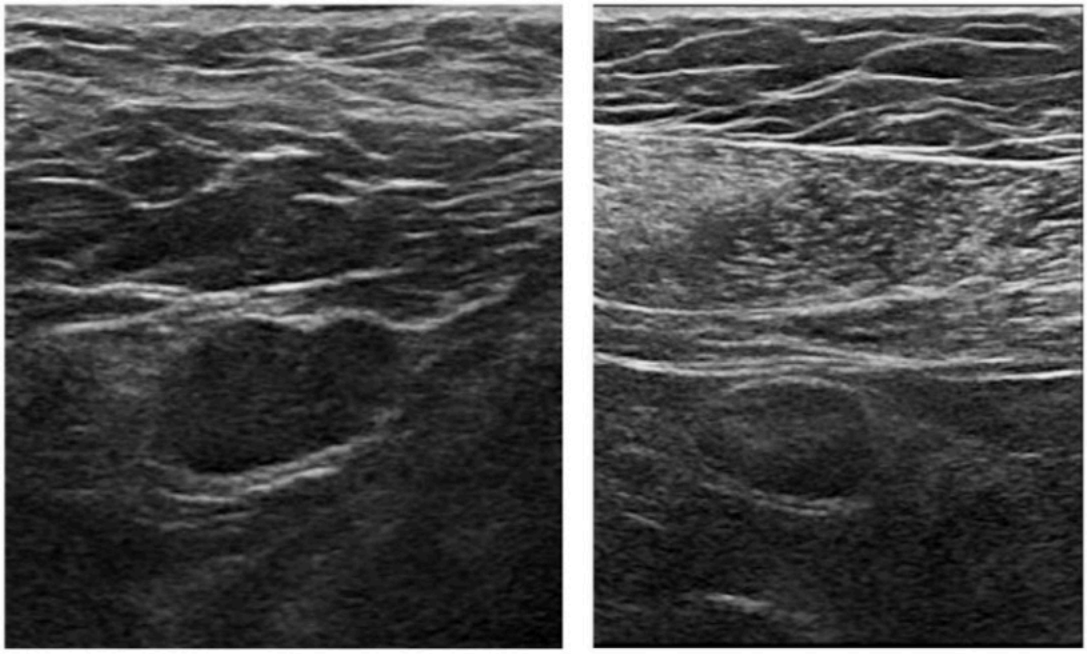

A B

Figure 13 – LYMPH NODES – AXILLARY, ABNORMAL. Ultrasound of the left axilla shows lymph nodes of abnormal morphology (hypoechoic with replacement of fatty hilum) in level I (A) and level II (B), consistent with regional nodal metastases.

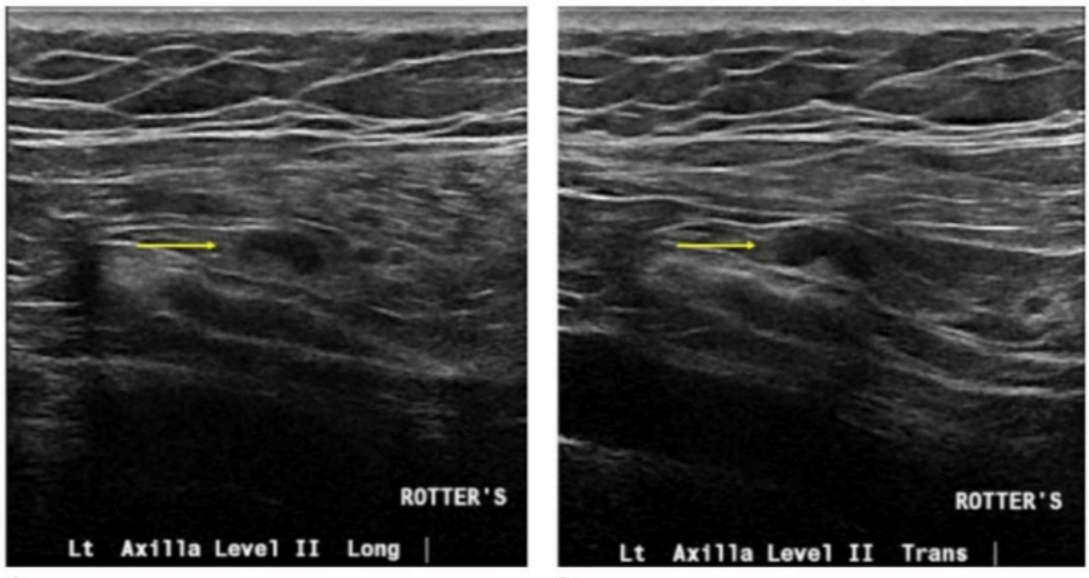

A B

Figure 14 – LYMPH NODES – AXILLARY, ABNORMAL. Longitudinal (A) and transverse (B) ultrasound of the left axilla level II reveals a lymph node between the pectoralis major and pectoralis minor muscles, known as an interpectoral or Rotter's node (arrows).

G. LYMPH NODES

3. LYMPH NODES — INTERNAL MAMMARY

Using the sternum and ribs as landmarks, internal mammary spaces 1 through 4 may be imaged with ultrasound [1, 70, 73–75]. The identification of a node with abnormal morphology is suspicious for nodal metastasis in the setting of ipsilateral breast cancer. While not currently the standard-of-care, US-guided biopsy using fine-needle aspiration technique may be performed [75]. Alternatively, adjunctive imaging modalities including MRI and PET-CT have been reported to be sensitive for the detection of tumor involvement [1].

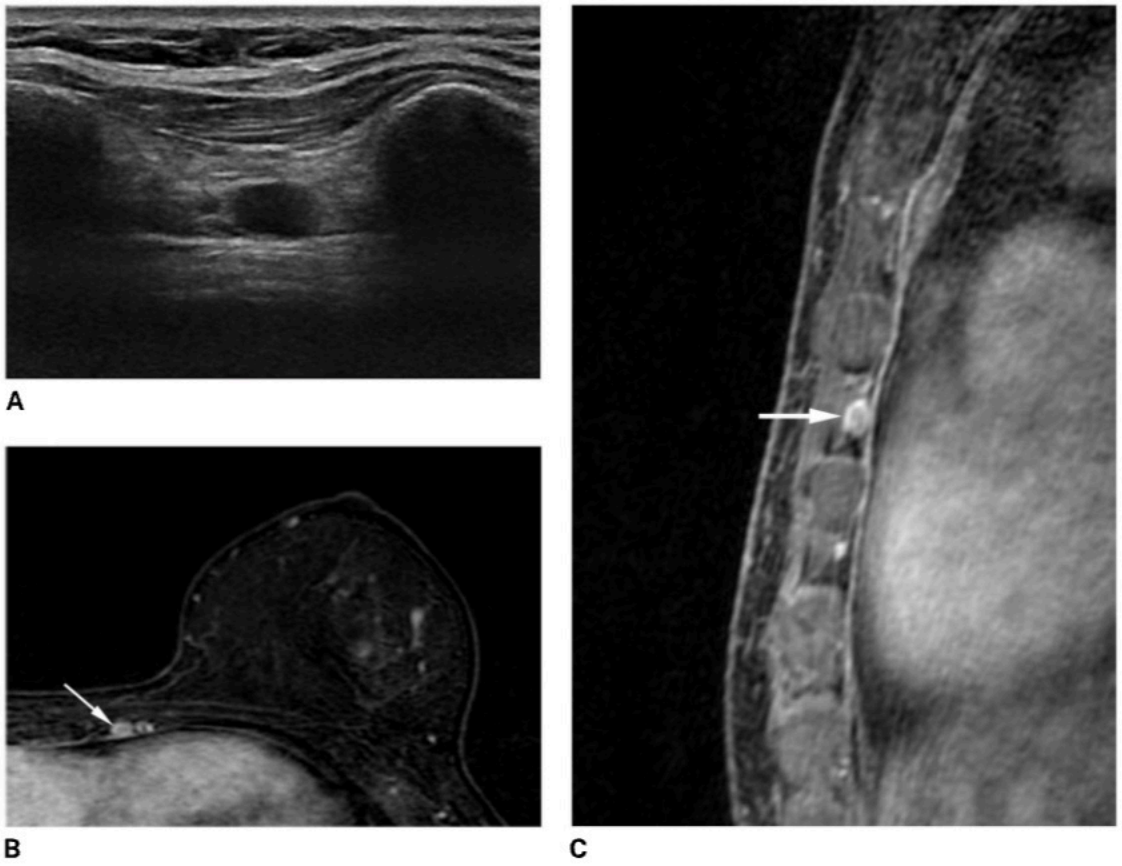

A

B

C

Figure 1 – LYMPH NODES – INTERNAL MAMMARY, ABNORMAL. Ultrasound of the third internal mammary space shows a completely hypoechoic node between two ribs, with loss of the normal echogenic fatty hilum (A). In the setting of newly diagnosed ipsilateral cancer, this is suspicious for nodal metastasis to the internal mammary chain. Adenopathy (arrows) was also seen in axial (B) and sagittal (C) MRI.

G. LYMPH NODES

4. LYMPH NODES — SUPRACLAVICULAR

Tumor involvement of the ipsilateral supraclavicular node(s) is considered to be the highest N stage that is still confined to regional disease (N3c). Ultrasound of the supraclavicular space can be considered, especially when there is clinical and/or imaging evidence of nodal metastases to the lower regional nodal basins (such as the axilla), as accurate information regarding the highest regional nodal basin(s) affects stage and possibly management [1, 70, 73].

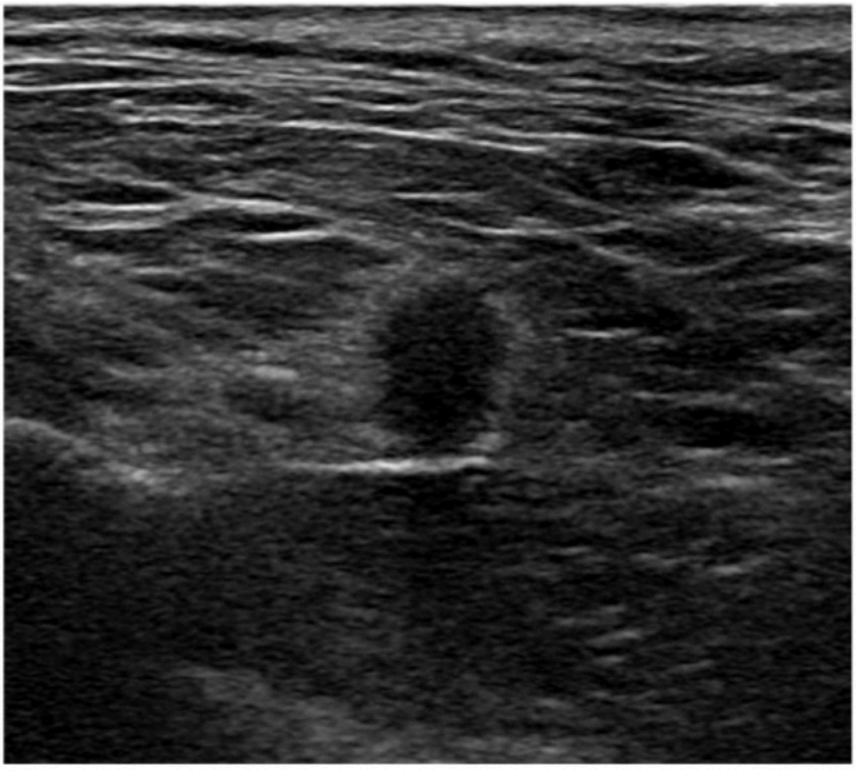

A

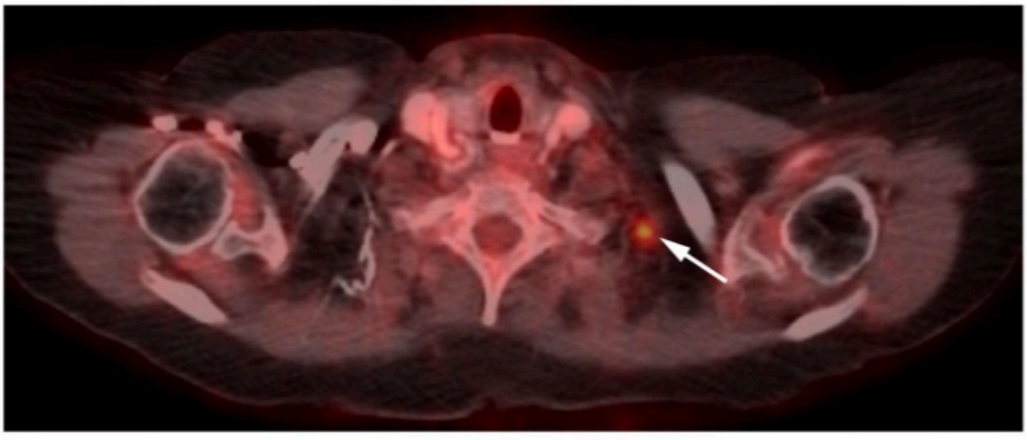

B

Figure 1 – LYMPH NODES – SUPRACLAVICULAR, ABNORMAL. (A) Nodal staging ultrasound shows an abnormal left supraclavicular lymph node, with complete effacement of fatty hilum and an indistinct margin in keeping with extranodal extension, along with an echogenic rind. (B) PET-CT image confirms adenopathy in the supraclavicular region (arrow). Pathology: US-guided fine needle aspiration biopsy confirmed tumor involvement.

H. LOCATION OF FINDING

The location of a salient finding should be described to facilitate easy identification in the future and correlation with clinical findings. The laterality of the finding as left or right should always be reported. The position of the finding within the breast should be described by clock face or if large, by quadrant. Depth or distance from the nipple to the center of the finding should be reported. If the finding is large, distance to its anterior and posterior extents can be included. Also, it may be helpful to describe the anatomic zone where the finding lies to facilitate lesion identification when correlating among modalities. For example, noting that a mass lies at the subcutaneous fat-fibroglandular zone junction may allow easier search and more confident identification when mammographic or MRI correlation is performed.

Finding location should be described by laterality first, followed by clock face and/or quadrant, and then depth or distance from the nipple. The following are examples of a finding location description.

1. LATERALITY

   Laterality indicates the right or left breast.

2. LOCATION IN BREAST AS CLOCK FACE (PREFERRED) OR QUADRANT

   Clock face is oriented based on the patient facing the observer and should be specified using a whole number. For example, 3:00 is in the lateral left breast and the medial right breast. Quadrants refer to smaller sub-divisions of the breast, including upper outer, upper inner, lower outer, and lower inner portions of the breast and should be used with ultrasound only when findings are large and span several clock face locations.

3. DEPTH AND/OR DISTANCE FROM THE NIPPLE

   Describe the location based on depth (anterior, middle, posterior) or distance from the nipple in whole centimeters (e.g., 2 cm from the nipple, not 2.3 cm from the nipple). Using smaller distance increments implies a higher level of precision than is possible across readers and modalities. If findings are between whole cm locations, the closest whole cm location should be selected and used.

   The distance from the nipple is measured from the base of the nipple to the center of the finding. If the finding is close to the nipple, it is important to describe how far the anterior extent of the imaging finding is from the nipple to assist with surgical planning. If the finding is large, distance to its anterior and posterior extents can also be included, to assist with surgical planning. If the findings are close to the skin, pectoralis muscle or chest wall, describe the distance of the findings to these structures. Due to differences in patient positioning and other technique factors, distance from the nipple, skin, pectoralis muscle and chest wall may vary across modalities.

   It may be helpful to describe the anatomic zone where the finding lies to facilitate lesion identification when correlating among modalities. For example, noting that a mass lies at the subcutaneous fat-fibroglandular zone junction may allow for more efficient search and more confident identification when ultrasound evaluation is undertaken.

III. REPORTING SYSTEM

A. ASSESSMENT CATEGORIES

Table 2. Concordance Between BI-RADS® Assessment Categories and Management Recommendations

Assessment	Management	Likelihood of Cancer
Category 0: Incomplete: Need Additional Imaging Evaluation OR Category 0: Incomplete: Need Prior Imaging for Comparison	Recall for additional imaging Need comparison to prior examination(s)	N/A
Category 1: Negative	Routine screening	Essentially 0% likelihood of malignancy
Category 2: Benign	Routine screening	Essentially 0% likelihood of malignancy
Category 3: Probably Benign	Short-interval (6-month) follow-up or continued surveillance (12 months)	> 0% but ≤ 2% likelihood of malignancy
Category 4: Suspicious Category 4A: *Low suspicion* for malignancy Category 4B: *Moderate suspicion* for malignancy Category 4C: *High suspicion* for malignancy	Tissue diagnosis	> 2% but < 95% likelihood of malignancy > 2% to ≤ 10% likelihood of malignancy > 10% to ≤ 50% likelihood of malignancy > 50% to < 95% likelihood of malignancy
Category 5: Highly Suggestive of Malignancy	Tissue diagnosis	≥ 95% likelihood of malignancy
Category 6: Known Biopsy-Proven Malignancy	Clinical follow-up with surgeon and/or oncologist, and definitive local therapy (usually surgery) when clinically appropriate	N/A

1. Assessment is incomplete: There is a finding for which additional imaging evaluation is needed to render a final diagnosis, with two potential actions:

   Category 0: Incomplete: Need Additional Imaging Evaluation

   or

   Incomplete: Need Prior Images for Comparison

   Recent amendments to MQSA regulations, which took effect on Sept. 10, 2024, resulted in the creation of two new assessment categories for mammography under category 0 (replacing the previous combined descriptive verbiage of "Category 0: Incomplete: Need additional imaging evaluation and/or Prior imaging comparison"). The two new MQSA-required categories are: **Category 0: Incomplete: Need additional imaging evaluation**, used to indicate that the examination is incompletely evaluated, and the recommendation is for additional imaging evaluation (e.g., supplementary mammographic views and/or US); and **Category 0: Incomplete: Need prior mammograms for comparison**, to be used if retrieval of previous examinations for comparison is indicated before a final assessment can be rendered. For consistency, this updated verbiage has been generalized across the Manual for the other modalities. However, since prior studies desired for comparison may not be limited to mammograms, the terminology in the sections other than the Mammography chapter has been modified to say **Category 0: Incomplete: Need prior imaging for comparison.**

   Category 0: Incomplete: Need additional imaging evaluation, this assessment is almost always used in a screening situation to recall a patient for diagnostic evaluation. A screening breast US is assigned Category 0: Incomplete: Need additional imaging evaluation when the examination is interpreted after the patient leaves the facility and additional imaging is needed to assess an abnormal finding. It is also used when the patient remains at the facility for immediate results and additional diagnostic breast US is performed to further evaluate a potentially abnormal finding detected with screening US. In this situation, the final report may communicate a single overall assessment (that reflects the combined results of the screening and diagnostic portions of the exam), because the screening and subsequent additional imaging will have been completed in a single visit. However, the screening portion of the exam should be assigned a category 0 for audit purposes. (For further information please refer to the Auditing and Outcomes Monitoring section on page 801.)

   Under unusual circumstances, assessment category 0 may be used in a diagnostic US report, such as when equipment or personnel are not immediately available to perform a needed concurrent diagnostic mammography examination, or when the patient is unable or unwilling to wait for completion of a full diagnostic examination. Category 0 should ***rarely*** be used for diagnostic breast imaging findings that warrant further evaluation with another modality such as MRI. In almost all cases, the interpreting physician should issue a final assessment and recommendation in the US report, which may be composite with diagnostic mammography. If a finding is suspicious on US, a category 0 assessment with recommendation for MRI is inappropriate, as MRI should not obviate biopsy of a sonographically suspicious finding.

   Category 0: Incomplete: Need prior imaging for comparison, category 0 should also be used when prior imaging is unavailable for comparison. This category 0 assessment is appropriate only when such comparison is required to make a final assessment. If a finding is inherently suspicious, awaiting prior imaging may unnecessarily delay an inevitable biopsy recommendation. When category 0 is used in the context of awaiting prior examinations for comparison, there should be in place a tracking system guaranteeing with 100% reliability that a final assessment will be issued within 30 days (preferably sooner), even if prior examinations do not become available. Some breast imaging practices may reasonably choose never to use category 0 in the context of awaiting prior examinations if they do not have a 100% reliable

tracking system. If an US examination is assessed as category 0 in the context of awaiting prior examinations and then the prior examinations do become available, an addendum to the initial US report should be issued, including revised assessment and management recommendations. For auditing purposes, the revised assessment should replace the initial assessment.

2. Assessment is complete:

Category 1: Negative

This is a normal examination with no pertinent findings. The corresponding management recommendation should be routine age-appropriate screening.

Category 2: Benign

As with category 1, this is a "normal" assessment, but the radiologist chooses to describe a benign finding in the US report. For example, the interpreter may choose to describe benign cysts, postsurgical fluid collections, breast implants, or benign masses, while still concluding that there is no sonographic evidence of malignancy. When there are one or more incidental benign findings, the radiologist may choose not to describe such findings, in which case the examination should be assessed as negative (category 1). As with category 1 assessments, category 2 assessments indicate that there is no sonographic evidence of malignancy and should be followed by the management recommendation for routine age-appropriate screening.

Category 3: Probably Benign (Guidance section, see page 481)

A category 3 assessment indicates that a finding is identified as having a very low (≤ 2%) likelihood of malignancy. To establish benignity of a solid mass with benign morphology, surveillance imaging is necessary to document long-term stability. The initial follow-up interval is usually 6 months, involving the breast(s) containing the probably benign finding(s). Assuming stability at this 6-month examination, a category 3 assessment again is rendered with a recommendation for a second follow-up examination in 6 months. Again, assuming stability at this second follow-up, the examination is once more assessed as category 3, but now the recommended follow-up interval usually is lengthened to 1 year due to the already-established 12-month stability. Note that although the 1-year follow-up coincides with the routine screening interval in the United States, a category 3 assessment is nonetheless rendered, to indicate that the period of imaging surveillance is still underway and the subsequent examination should be scheduled as diagnostic rather than screening. Assuming stability at the 24-month US exam, a category 3 assessment may optionally be rendered with a recommended follow-up interval exam in an additional 12 months. As with surveillance using mammography, after establishing 2 years of stability, the final assessment category may be changed to benign (BI-RADS category 2). A benign evaluation may also be rendered before completion of category 3 analysis if, in the opinion of the radiologist, the finding has no chance of malignancy and is thus a category 2. Alternatively, during surveillance imaging, if the probably benign mass changes in morphology or increases in size, the final assessment should be changed to suspicious (BI-RADS category 4) with recommendation for biopsy.

There are some imaging findings with suspicious features that overlap between benign and malignant, but the clinical scenario and mammographic features strongly favor a benign etiology such as an abscess, hematoma, fat necrosis, or reactive lymph node. Although suspicious sonographic features such as angular margin, and non-parallel orientation may be present, the radiologist, in the appropriate clinical setting, may justifiably believe that the abnormality will decrease or resolve at follow-up. In these unique scenarios, a category 3 assessment can be rendered with a short-term interval follow-up ultrasound to avoid biopsy. In these select cases, the follow-up period may be less than the usual 6 months for findings expected to change over a shorter time frame (e.g., probable hematoma presenting as a mixed solid and cystic

mass directly at the site of known trauma). For suspected abscess treated with antibiotics or post-traumatic hematoma, the interval may be as short as 2–4 weeks. If the abnormality resolves or decreases in size at follow-up, an assessment of negative (BI-RADS category 1) or benign (BI-RADS category 2) can be rendered without 2 years of follow-up. On the other hand, if an abnormality with suspicious features fails to resolve or increases in size, biopsy may be indicated.

Assessment category 3, probably benign, is ***not*** an indeterminate category for use when the radiologist is unsure whether to render a benign (BI-RADS category 2) or suspicious (BI-RADS category 4) assessment. Assessment category 3 is specifically reserved for imaging findings known to have > 0% but ≤ 2% likelihood of malignancy. ***For US, there is robust evidence that a solid mass with a circumscribed margin, oval shape, and parallel orientation (most commonly fibroadenoma), and an isolated complicated cyst (with diffuse low-level nonmobile internal echoes that cannot be confidently distinguished from a circumscribed hypoechoic solid mass) have a likelihood of malignancy in the defined (≤ 2%) probably benign range, for which short-interval (6-month) follow-up sonography and then periodic sonographic surveillance may represent appropriate management*** [76–78]. The use of assessment category 3 for sonographic findings other than these two should be considered only if the radiologist has personal experience to justify a watchful-waiting approach, preferably involving observation of a sufficient number of cases of the sonographic finding to suggest a likelihood of malignancy within the defined (≤ 2%) probably benign range.

As with screening mammography, category 3 assessment should not be made at screening US. In theory, a finding at screening ultrasound warrants a category 0 assessment with additional imaging to include diagnostic US. When appropriate, the category 3 assessment should then be issued on the subsequent diagnostic US exam. However, in practicality, screening US is often interpreted online, and when needed, additional US views are obtained as part of the diagnostic US examination while the patient remains in the breast imaging facility. In this scenario, it may be cumbersome to issue two separate breast US reports for the screening and diagnostic US exams. Thus, a single breast imaging report may be issued that combines the findings of both screening and diagnostic components of the examination. Hence, this combined report may render a category 3 assessment because the screening and diagnostic workup are essentially completed simultaneously (but each is audited separately "behind the scenes"). (This issue is discussed in more detail in Frequently Asked Question #2 for US in the Audit and Outcomes Monitoring section on page 856). Note that for auditing purposes (which may be separate from reporting), the screening component of such a category 3 assessed US examination will be audit-positive because additional imaging beyond standard images were obtained (BI-RADS category 0) but the diagnostic portion will be audit-negative because a biopsy recommendation was not issued.

Category 4: Suspicious

This category is reserved for findings that are sufficiently suspicious to justify biopsy but do not necessarily have the classic appearance of malignancy. The ceiling for category 3 assessment is a 2% likelihood of malignancy, and the floor for category 5 assessment is 95%. Therefore, category 4 assessments cover the wide range of malignancy likelihood greater than 2% and less than 95%. To facilitate informed decision-making, the radiologist should further subdivide category 4 into 4A, 4B, and 4C. Malignancy likelihood of these subcategories: 4A = > 2% to ≤ 10%; 4B = > 10% to ≤ 50%; 4C = > 50% to < 95%. Given the probabilities of malignancy, category 4 assessments will almost always necessitate a biopsy recommendation, unless patient co-morbidities or preference confound this recommendation. In the scenario where biopsy is recommended, but the patient and/or referring provider opt against this recommendation, the category 4 assessment should still be rendered, and the report should explain the reason for the management recommendation deviation.

Category 5: Highly Suggestive of Malignancy

Category 5 assessments indicate a very high probability (≥ 95%) of malignancy. The current rationale for using a category 5 assessment is to identify lesions for which percutaneous tissue sampling is expected to yield a malignant diagnosis. If the pathology results are non-malignant, these results would be deemed discordant, resulting in the recommendation for repeat biopsy (needle biopsy or surgical excision). Given the high suspicion of malignancy, category 5 assessments will always necessitate a biopsy recommendation, unless patient co-morbidities or preference confound this recommendation. In the scenario where biopsy is recommended, but the patient and/or referring provider opts against this recommendation, the category 5 assessment should still be rendered, and the report should explain the reason for the management recommendation deviation.

Category 6: Known Biopsy-Proven Malignancy

This category is reserved for examinations performed in patients with known, biopsy-proven malignancy in the imaged breast (imaging performed after percutaneous biopsy but prior to definitive local therapy). A category 6 assessment is only appropriate when there are no abnormalities other than the known cancer that might need additional evaluation. If there are other abnormalities in the imaged breast that warrant additional evaluation (i.e., biopsy or further imaging evaluation), the resultant assessment for these additional abnormalities would take management priority over the category 6 assessment for the known cancer.

Given a known cancer diagnosis, the management recommendation should be "Clinical follow-up with surgeon and/or oncologist, and definitive local therapy (usually surgery) when clinically appropriate". This management recommendation acknowledges that the patient should follow-up with a cancer specialist for treatment options. Of note, the 5th Edition of the BI-RADS Atlas linked a recommendation of "surgical excision when clinically appropriate" to a category 6 assessment. However, for select patient populations, there are ongoing studies to determine whether some breast cancers, particularly low-grade ductal carcinoma in situ, may safely undergo active surveillance rather than surgical excision [79]. There is also ongoing research regarding the effectiveness of percutaneous breast cancer treatment methods [80]. This new language purposefully broadens the recommended cancer treatment scope to include surgical and non-surgical options.

B. REPORT ORGANIZATION

The report should be concise and organized using the following structure:

Table 3. Report Organization

1.	Indication for the exam
2.	Comparison to previous examination(s)
3.	Technique
4.	Tissue composition
5.	Findings
6.	Composite report(s) (if applicable)
7.	Assessment
8.	Management recommendations

Consistent use of BI-RADS descriptors for US, as for mammography and MRI, facilitates lesion assessment and clarifies communication with providers and patients. Structured, software-based reporting should be based on BI-RADS terminology.

1. INDICATION FOR THE EXAM

   New to this version of BI-RADS are structured categories for the major clinical indications for breast imaging, with associated optional subcategories and relevant clinical histories. These structured categories should be used when creating reports for all modalities. Use of structured indications (outlined below) is recommended to aid in achieving report clarity and outcomes monitoring, including method of cancer detection (Table 4).

   The most common indications for breast US are confirmation and characterization of focal signs/symptoms or abnormalities on other imaging modalities, guidance of interventional procedures, and as the initial imaging technique for young, pregnant, or lactating patients. In asymptomatic women with dense breasts, another indication may be supplemental whole-breast screening. Please see clinical indications in Table below, which are independent of imaging modality. Additional indications are listed in the ACR Practice Parameter for the Performance of a Diagnostic Breast Ultrasound Examination [4].

Table 4. Structured Exam Indications

Major Indication	Optional Subcategory Indication	Relevant History to Report, if known
Asymptomatic Screening	• Elevated risk • Dense breasts • Prior breast cancer, treatment completed • Other	• Gene mutation • Estimated cancer risk • Prior breast cancer history
Diagnostic Work-up	• Clinical findings • Imaging findings • Follow-up category 3 • Follow-up after biopsy • Implant assessment • Other	• Clinical finding type • Imaging finding type
Diagnostic: Current Breast Cancer	• Extent of disease before treatment/therapy • Response during or after neoadjuvant therapy • Other	• Location and size of cancer on prior imaging evaluation

2. COMPARISON TO PREVIOUS EXAMIATION(S)

   It is recommended that the dates of comparison US exams be listed. Additionally, breast US should be correlated with physical exam findings, mammography, MRI, or other imaging studies, and the dates of these exams can be listed. If no comparison exams are available, this should be specified as “none.”

3. TECHNIQUE

   The technique section should describe how the US exam was performed. This information includes the scope of the scan; whether targeted to a specific location of the breast or

encompassing the entire breast. If a lesion was evaluated with color or power Doppler or with strain or shear-wave elastography, these techniques should be reported. In certain situations, it may be beneficial to describe the position of the patient during the examination (e.g., "The breasts were imaged in both supine and lateral decubitus positions." or "The patient was imaged in seated position, the position in which she feels the left breast thickening best.").

Unless stated otherwise, US exams can be assumed to be handheld. If an automated whole-breast scanning system was used, this should be specified. Some automated whole-breast US systems acquire and display 3D formatted images in coronal, sagittal, and/or transverse planes. Where possible, the interpretation structure outlined in and the reporting procedures described throughout this Reporting section should be followed when interpreting automated whole-breast US exams.

4. TISSUE COMPOSITION

Tissue composition may be reported in its own section of the report or embedded at the beginning of the Findings section. The US descriptors for tissue composition are subdivided into tissue pattern and glandular tissue component. The three descriptors for tissue pattern are "homogeneous background echotexture-fat," "homogeneous background echotexture-fibroglandular," and "heterogeneous background echotexture" (Table 5). These descriptors correspond loosely to the four density descriptors of mammography and the four fibroglandular tissue descriptors of MRI. Tissue composition is further characterized by glandular tissue component. The amount of glandular tissue compared to stromal tissue is categorized as minimal, mild, moderate, and marked. Please see Section II.A. in this BI-RADS Ultrasound section for further discussion of tissue composition.

Table 5. Tissue Composition

Tissue Pattern
a. Homogeneous background echotexture-fat
b. Homogeneous background echotexture- fibroglandular
c. Heterogeneous background echotexture
Glandular Tissue Component
a. Minimal (< 25% glandular tissue)
b. Mild (25 to 49% glandular tissue)
c. Moderate (50 to 74% glandular tissue)
d. Marked (≥ 75% glandular tissue)

5. FINDINGS

Using lexicon terminology, the description of important findings should be made sequentially for each breast in order of clinical relevance. For example, all relevant findings for the left breast should be described followed by all relevant findings for the right breast. These findings' descriptions should include:

a. Characterization of a mass using echo pattern and the morphological descriptors of shape, margin, and orientation. Notes should be made of the lesion's effect on the surrounding tissue, such as architectural distortion and skin thickening. Other features, such as posterior features, as well as techniques, such as Doppler and elastography, should only be described for pertinent positives. For screening ultrasound examinations, characteristically benign findings may be reported (assessment category 2), but it is not obligatory, and the appropriate assessment would then be negative (assessment category 1).

b. For important findings, size should be reported in three dimensions when possible. When measurement of three dimensions is not possible (e.g., non-mass lesions primarily visualized in one plane), as many measurable size dimensions as possible should be reported. When multiple incidental benign cysts (simple and/or complicated) are present, it is not necessary to report the measurements of every cyst.

c. Locations of all important finding(s) should be reported using clock-face location and distance from the nipple. When more than one finding is located in the same scan frame or in the same locale, measurement of the distance from the skin to the center of each finding may help to differentiate one lesion from another. This distance from skin to finding may be particularly useful when one mass is singled out for biopsy, and others are depicted in the field. If the finding is close to the nipple, it is important to describe how far the anterior extent of the imaging finding is from the nipple base to assist with surgical planning. If the finding is large, distance to its anterior and posterior extents can also be included, to assist with surgical planning. If the findings are close to the skin, pectoralis muscle or chest wall, describe the distance of the findings to these structures. Due to differences in patient positioning and other technique factors, distance from the nipple, skin, pectoralis muscle and chest wall may vary across modalities.

   It may be helpful to describe the anatomic zone where the finding lies to facilitate lesion identification when correlating among modalities. For example, noting that a mass lies at the subcutaneous fat-fibroglandular zone junction may allow for more efficient search and more confident identification when comparison to other modalities is undertaken.

d. As with mammography, multiple bilateral circumscribed masses usually are assessed as benign due to their multiplicity and benign morphology (assessment category 2) [12]. In the unusual circumstance in which the interpreting physician chooses to describe multiple benign-appearing masses individually within the US report, the masses should be reported in list format by breast, by location within the breast, and by size. This type of report will be clearer, and, if surveillance is suggested as management, the performer of the subsequent examination will appreciate a concise list rather than lengthy loose text.

e. If an US finding correlates with a finding on another imaging modality (e.g., mammography or MRI) or with a clinical finding (e.g., palpable lump), this correlation should be reported. Similarly, if an US finding is incidental and does not correlate with a finding described on another imaging modality or clinical exam, the incidental nature of this US finding should be reported. Such correlation statements will clarify potential confusion for report readers.

6. COMPOSITE REPORTS

When more than one type of imaging modality examination is performed concurrently (on the same day), it is preferable that the examinations be reported together. To facilitate coding and billing, the exam findings for each imaging modality should be described in separate paragraphs. The assessment should be unified into an overall assessment with combined management recommendations that incorporate conclusions from all imaging modalities. In general, when the assessments for two examinations differ, the overall assessment (and concordant management recommendations) should reflect the more abnormal of the individual assessments (unless a category 0 assessment has been resolved as benign by the additional same-day imaging). Such prioritization of the overall assessment will ensure that the more time-sensitive management actions occur sooner. The following hierarchy of decreasing abnormality should be used as a general guide, where the most abnormal assessment (category 5) takes precedence over the less abnormal assessments: category 5, 4, 0, 6, 3, 2, 1 (Table 6).

Table 6. Abnormality Hierarchy

BI-RADS Assessment Category	Degree of Abnormality
5	Highest
4	
0	
6	
3	
2	
1	Lowest

Exceptions to this rule occur when the characteristically benign features of a given finding on one imaging modality supersedes the less specifically benign features of the same finding on the other examination. For example, an oval, circumscribed mass at mammography is not specifically benign, but if concurrent US characterizes this same mass as a simple cyst, the mass may be assessed as benign (category 2). There is an exception to this rule with breast MRI. Breast MRI exams are often performed and interpreted separately from other diagnostic breast imaging modalities, sometimes by different radiologists.

7. ASSESSMENT

   The assessment section should explicitly state the overall final assessment using BI-RADS US categories 1–6 and the phrases associated with them (see Ultrasound section III. A of the BI-RADS v2025 Manual). In some cases, the interpreting physician may render an incomplete assessment (category 0) in order to request additional examination(s), such as mammography, comparison with previous but currently unavailable examinations, or additional physician-performed real-time scanning after either a sonographer-produced, real-time or automated whole-breast screening US examination.

8. MANAGEMENT RECOMMENDATIONS

   The report should conclude with a summary statement of each pertinent finding and its associated management recommendation, as per the ACR Practice Parameter for Communication of Diagnostic Imaging Findings [81]. This summary section consolidates the overall exam findings for the ordering provider. Clear management recommendations should be included for each listed pertinent finding. Recommendations may include routine age-appropriate screening, surveillance imaging for a probably benign mass, percutaneous or surgical biopsy, and clinical management. If a finding is suspicious and warrants biopsy, this biopsy recommendation should be explicit and not left to the discretion of the ordering provider. Furthermore, if an imaging-guided interventional procedure is recommended, the type of imaging for the procedure should be indicated, for example, stereotactic, US, or MRI guidance.

C. WORDING OF REPORT

The report should be organized as in section III. B. The report should be succinct, using terminology from the latest approved lexicon without embellishment. Definitions of lexicon terms should not be included in the report. If the radiologist conducted any important verbal discussions with the patient and/or ordering provider, these discussions should be documented in the Management section or in an addendum to the report. Other aspects of the report should comply with the current ACR Practice Parameter for Communication of Diagnostic Imaging Findings [81].

IV. GUIDANCE

This is the third version of the ultrasound BI-RADS lexicon, published at a time when ultrasound is firmly established as a fundamental core modality in imaging benign and malignant breast disease. Not only is ultrasound long acknowledged as an indispensable diagnostic modality for assessment of mammographic and/or clinical findings, but it is also now firmly established as a screening tool and a means to guide biopsy, including when targeted to an abnormality detected on other imaging tests such as MRI or CEM.

A. TISSUE COMPOSITION

Since the implementation of federally mandated mammographic breast density reporting legislation in the United States on September 10, 2024, the performance of breast ultrasound as an adjunctive screening modality to mammography in women with dense breasts will undoubtedly increase. At the same time, we are increasingly accruing knowledge regarding the clinical significance of overall breast density as well as its subcomponents.

Breast density at mammography is associated with a decrease in mammographic sensitivity ("masking effect") and an increase in risk of breast cancer. While research and data are not as extensive in these areas for ultrasound, we do know that tissue composition affects the detection of lesions with ultrasound, and recent research is showing that ultrasound may also serve to assess risk. In Tissue Composition, we have continued the description of the three tissue patterns of background echotexture used in the prior edition (homogeneous, heterogeneous — fat, heterogeneous — fibroglandular), but we are additionally introducing a new element termed glandular tissue component (GTC). This new element of GTC is predicated on the principle that ultrasound can be used to distinguish between glandular tissue (which appears hypoechoic) and fibrous stroma (which appears relatively echogenic). We propose a classification schema to semi-quantify the amount of glandular tissue compared to stromal tissue using the terms minimal (< 25% of hypoechoic glandular tissue within the echogenic fibrous stroma), mild (25% – 49%), moderate (50% – 74%), and marked (> 75%), similar to that of background parenchymal enhancement at MRI. High GTC has been found to be associated with no or only mild lobular involution, and it is perhaps this relationship that accounts for the observed association between GTC and breast cancer risk [19, 20, 22, 82]. As with any new concept, especially in ultrasound which is highly operator dependent, assessing GTC properly will require learning and experience. Nevertheless, we believe that it is appropriate to introduce this new element so that awareness can be raised and knowledge can be gained regarding the anatomy, physiology, and pathophysiology underlying breast cancer.

B. BREAST ULTRASOUND LEXICON

At its heart, BI-RADS is a lexicon for communication, and descriptions for morphology play a key role in predicting the probability of any lesion being a cancer.

1. MASS SHAPE: LOBULATED MASS

   In the 2013 Edition of BI-RADS, the term lobular was removed from the lexicon as a shape descriptor, leaving the terms the oval, round, and irregular. However, there are many sonographic masses that are not strictly oval, round, or irregular, and we are thus re-introducing a term that more specifically describes a mass which is generally oval in shape but displays surface undulations, also applicable in mammography and MRI. The term "lobulated" will be used rather than "lobular" (with intention to avoid confusion with lobular carcinoma,

especially as perceived by any lay person reading the report). "Lobulated" is a shape descriptor for a mass, designed to communicate most specifically what the mass looks like. The term is insufficiently specific at ultrasound to establish benignity or diagnose malignancy but does convey a slight increase in suspicion compared to an oval mass.

2. MASS: ECHO PATTERN CHANGE

   In another effort to clarify language, we changed the Echo Pattern term "complex cystic and solid" to "mixed solid and cystic" since the solid component of such a mass is likely of higher clinical significance than the cystic component and because the word "complex" may be confused with the complicated cyst.

3. POSTERIOR FEATURES

   In Posterior Features, the term "combined pattern" has been removed as a descriptor of shadowing, with the three remaining terms now being "none", "enhancement", and "shadowing." This was changed with the recognition that any degree of shadowing emanating from the substance of a mass is significant, even if there is associated enhancement from another portion of the mass.

4. CALCIFICATIONS

   As ultrasound technology improves, we are now increasingly able to visualize calcifications on their own (without necessarily being associated with a mass or duct). Therefore, under Calcifications, we proposed the added categories of "microcalcifications" versus "macrocalcifications" in this version, which can be described in addition to the anatomic location of the calcifications (in a mass or non-mass lesion, outside of a mass or non-mass lesion, or intraductal). This supplementary description can help shorten a list of differential diagnoses, just as recognition of large or coarse calcifications on mammography suggests a benign process.

5. ECHOGENIC RIND

   Echogenic rind is now a lexicon term in Associated Features. This refers to the echogenic or bright band of tissue that can be seen surrounding a lesion. We selected this term because it is immediately understandable and evocative of the imaging finding — a thick white band around a lesion. Rinds are thick. Rinds surround. An echogenic rind is typically found with either malignancy or fat necrosis, though other benign entities can occasionally demonstrate a rind. Because it is one of the most predictive features for malignancy at ultrasound, we proposed a term that will evoke an immediate suspicious connotation. An echogenic rind is thick and non-uniform, and it surrounds a lesion of any shape. In contrast, the echogenic pseudocapsule (a feature suggesting benignity) is thin and uniform, and it usually surrounds an oval mass.

6. NON-MASS LESION

   As newer modalities (such as MRI, CEM and MBI) become increasingly common in clinical practice, findings (some of which are cancers) heretofore unseen are being detected. This development has resulted in the rising utilization of ultrasound as an adjunctive modality to target these types of sometimes subtle finding(s) seen on the other modalities, not only to further characterize but also to serve as potential biopsy guidance. The use of ultrasound to target potential lesions initially detected at other modalities, coupled with the improvement in ultrasound technology and high-resolution transducers, has resulted in the increased identification of sonographic findings of clinical significance that do not meet the definition of a mass. Hence, we are introducing a new category of sonographic findings in this version of BI-RADS, termed "non-mass lesion," akin to the non-mass enhancement that is seen at MRI or CEM. Though the terminology is new to this version of BI-RADS,

the concept and even the descriptor have been clinically used by some practitioners for many years. It is important to note that a non-mass lesion is not simply heterogeneous breast tissue. A non-mass lesion should be a distinct anatomic entity, imaged reproducibly by different operators and, not infrequently, correlated with a finding at mammography, MRI, or CEM. With the codification of this category of lesions in BI-RADS, additional data can be collected and analyzed about its significance in clinical practice.

C. LYMPH NODES

The discussion on lymph nodes has been greatly expanding in this version. Nearly all breast cancers metastasize via the lymphatic system, and nodal staging is an important component determining the overall cancer stage. Importantly, cancer stage determines prognosis and dictates treatment. Therefore, accurate nodal staging is vital to optimal patient care. Surgical nodal staging historically has been the gold standard. In recent years, imaging is playing an increasingly important role in nodal staging, particularly as neoadjuvant therapy is increasingly administered to downstage disease (including nodal disease) before surgery. Additionally, surgical nodal staging, even with extensive axillary lymph node dissection, generally evaluates only the axillary levels I and II, but not level III, internal mammary chain, or the supraclavicular space.

Ultrasound is an excellent modality for assessing the morphology of the individual node. As the node becomes invaded by tumor, morphological changes in the node can be seen, including alterations in the cortical-hilar relationship. The published literature in breast ultrasound has shown that cortical thickening of > 3 mm raises concern for metastatic nodal involvement. This version discusses not only nodal morphology (both normal and abnormal), but also the anatomic regions that comprise the N stage of TNM staging. For the first time in BI-RADS, the three levels of the axilla will be detailed, with the pectoralis minor muscle as the landmark in anatomic delineation. The internal mammary chain node may also be imaged with ultrasound, as can supraclavicular nodes. Ultrasound is unique as a modality in that it may readily image all the regional nodal basins in breast cancer, as well as serve as a means to guide biopsy for definitive tissue diagnosis of malignancy and provide information regarding biomarkers.

V. FREQUENTLY ASKED QUESTIONS

1. ***Should breast density at ultrasound be assigned at both screening and diagnostic imaging?***

   Tissue composition at ultrasound may be considered the counterpart to breast density at mammography. Yes, tissue composition may be assigned at both screening and diagnostic imaging. Of note, while assignment of breast density at mammography is mandated by federal law, there is no such mandate for breast ultrasound. Additionally, if targeted (versus whole-breast) ultrasound was performed for diagnostic indication(s), then assignment of breast density may be limited since only a portion of the breast might be imaged.

2. ***Does GTC (glandular tissue component) assessment with ultrasound only apply to women with dense breasts at mammography?***

   No. GTC assessment is in many ways similar to breast background parenchymal enhancement (BPE) at MRI. GTC is applicable to women with dense and non-dense breasts. Larger amounts of GTC has been shown to be a potential breast cancer risk marker, independent of breast density. As such, GTC is applicable to women with dense and non-dense breasts, as is BPE on MRI.

3. ***How does one distinguish between normal heterogeneous breast tissue at ultrasound versus a non-mass lesion at ultrasound?***

   As with any ultrasound assessment, experience and real-time scanning help in determining a true lesion versus normal tissue. In the case of a non-mass lesion at ultrasound, the finding should be reproducible by different sonologists/sonographers and identifiable in at least two planes (even though it may be much more conspicuous in one plane). When there is a correlate on other imaging modalities (e.g., mammography, CEM, MRI), then there is strong support that the finding in question is indeed a non-mass lesion and not simply heterogeneous but otherwise normal breast tissue.

4. ***How often does a non-mass lesion have a correlate on another imaging modalities?***

   With non-mass lesions, there is no requirement for a correlate on another imaging modality. While it is known that the probability of malignancy increases for a non-mass lesion at ultrasound when there is a correlate on another imaging modality, the precise answer to this question is unknown currently. The BI-RADS lexicon serves as a tool for data collection in furthering our understanding of imaging findings and determining their clinical significance. It is hoped that with the introduction of the category of non-mass lesion in the BI-RADS ultrasound lexicon, data may be collected to derive management guidance and improve patient care.

5. ***Can screening US be assessed as BI-RADS 3?***

   Similar to screening mammography, the assessment of BI-RADS 3 is discouraged based only on screening ultrasound images. With prompt and thorough diagnostic imaging evaluation of potentially abnormal findings detected at screening ultrasound, which may include additional ultrasound images (beyond those obtained at screening ultrasound) as well as correlation with both screening and/or diagnostic mammography, subtle cancers may be identified instead of being mistakenly assessed as probably benign. Similarly, immediate diagnostic evaluation (rather than delayed evaluation at 6 months due to a BI-RADS 3 being rendered directly from screening) may reveal definitively benign features such as fat within a lesion, precluding the need for unnecessary follow-up.

6. ***Can a screening US be assessed as BI-RADS 4 of 5?***

   Similar to screening mammography, the assessment of BI-RADS 4 or 5 is discouraged at screening ultrasound. Diagnostic imaging (ultrasound and mammography) may reveal additional lesions for biopsy planning and better define extent of disease.

7. ***Should we be assessing the level of axillary nodes on US and is it even possible/accurate to assess level II and III nodes on US?***

   In the current (8th) edition of the AJCC Breast Cancer Staging Manual, regional nodal staging considers lymph node(s) at all three levels of the axilla, the internal mammary chain, and the supraclavicular space. The use of ultrasound to assess level I versus level II versus level III axillary nodes has been described in the published literature and routinely practiced in some facilities. Whether or not any one facility should be using ultrasound for such assessment depends on various factors: 1) level of experience and expertise in using ultrasound for such assessment; 2) if and how such information contributes to clinical care of the patient at any particular facility; 3) whether and how accessible is MRI for regional nodal staging at any particular facility.

8. ***Should we be imaging the internal mammary nodal basin or the supraclavicular nodal basin using US when we are staging breast cancer?***

   This information is part of breast cancer staging. Whether or not any one facility should be using ultrasound for such assessment depends on various factors: 1) level of experience and expertise in using ultrasound for such assessment; 2) if and how such information contributes to clinical care of the patient at any particular facility; 3) whether and how accessible is MRI for regional nodal staging at any particular facility. Of note, breast MRI often does not include the supraclavicular region in its field of view (FOV), so ultrasound is considered the modality of choice in imaging the supraclavicular nodal basin.

9. ***A patient presents with a palpable lump for 1 year, with clinical and imaging features consistent with a chronic abscess. What is the BI-RADS assessment?***

   Given that the imaging features are consistent with a chronic abscess, this may be assessed as BI-RADS 2, benign. Even in the setting of a BI-RADS 2 assessment, ultrasound-guided aspiration may be performed for symptomatic indications and/or microbiological evaluation (e.g. culture and sensitivities). The imaging assessment and the management recommendation are uncoupled from each other.

10. ***If the chronic abscess in the scenario above cannot be aspirated, and I proceed to perform a core biopsy followed by referral to a clinician for antibiotics, what is the BI-RADS assessment?***

    The BI-RADS assessment remains BI-RADS 2 benign, based on the imaging features. However, if there is any consideration that the finding may be cancer rather than chronic abscess or granulomatous mastitis, then BI-RADS 4 suspicious assessment should be rendered.

11. ***If a patient has a BI-RADS 3 finding, identified only on screening or targeted US, and undergoing 6-, 12- and 24-month ultrasound surveillance, when her next routine mammogram is due, should it be a screening or diagnostic mammogram?***

    The answer to this question depends on the workflow of the particular facility. For patient convenience, it is recommended that ultrasound and mammography be performed on the same day. Whether that mammography is best scheduled as a screening versus a diagnostic examination depends on the particular facility.

12. *If a benign finding (e.g. simple cyst) is identified on screening ultrasound, what is the appropriate BI-RADS assessment?*

There are two potential scenarios in this question.

If no additional images beyond the standard screening images are captured, then the radiologist may either interpret this study as BI-RADS 1 negative (and not mention the simple cyst) or BI-RADS 2 benign (and describe the simple cyst in the report). Each center may decide for itself what constitutes "standard screening images." These will include those prescribed in the ACR Practice Parameter for the Performance of a Diagnostic Breast Ultrasound Examination but might also include pertinent benign findings which the operator wishes to document, such as a cyst with a mammogram correlate or a stable benign solid mass. Please note, these additional images cannot include findings that require further immediate action or recall. If those images were included, the exam would, by definition, become a BI-RADS 0 assessment.

If additional imaging is required for a finding and it is performed in the same setting and shown to be benign, then the radiologist should interpret this overall study as BI-RADS 2, benign. For purpose of audit, however, the radiologist should count this as two separate exams: BI-RADS 0 incomplete: needs additional imaging for the screening component and BI-RADS 2 benign for the diagnostic component (i.e. the additional images beyond the usual screening images).

13. *Is it appropriate to assess an US finding as BI-RADS 0 if an MRI or CEM exam is recommended for problem-solving?*

Using a BI-RADS 0 assessment on an ultrasound exam in order to recommend MRI, CEM or mammography in the setting of "problem-solving" should be used only in rare circumstances and only if there is high likelihood that the finding is benign and that added imaging will confirm such, thereby negating the need for biopsy or surveillance follow-up. An example might be probable fat necrosis whose etiology could be readily confirmed upon correlation with mammography. If this approach is used, contingency management recommendations (should the finding not be fully characterized with added imaging) should be specifically outlined in the US report (e.g., if mammographic findings characteristic of fat necrosis are not identified as a correlate for this US finding, ultrasound-guided biopsy should be performed). If the original US finding is potentially or substantially suspicious for cancer on ultrasound, added imaging should not routinely be recommended and the finding should undergo "up-front" biopsy.

14. *Does an abscess undergoing antibiotic treatment require follow-up ultrasound imaging to resolution? If so, would this be assessed as BI-RADS 3 or BI-RADS 2?*

The answer depends on whether the imaging findings are classic for an abscess versus likely representing an abscess. If the former, then the finding would be assessed as BI-RADS 2 benign, with no need for follow-up ultrasound. If the latter, then the finding would be assessed as BI-RADS 3 probably benign, with recommendation for follow-up ultrasound.

15. *If a probably benign sonographic mass is identified (i.e. oval hypoechoic mass with circumscribed margin and parallel orientation), but the patient requests biopsy rather than short-term interval ultrasound, would this be assessed as BI-RADS 3 or BI-RADS 4A?*

This mass should be assessed as BI-RADS 3 probably benign, with recommendation for biopsy based on patient preference. This is an example where the imaging assessment and the management recommendation are uncoupled.

16. *MRI reveals a BI-RADS 4 suspicious finding, for which "second-look" or "MRI-directed" ultrasound is recommended for imaging guided biopsy. If no sonographic is identified (i.e. MRI-directed*

ultrasound is normal), should be the ultrasound be assessed as BI-RADS 4 suspicious or BI-RADS 1 negative?

In this scenario, the "second-look" or "MRI-directed" ultrasound should be assessed as BI-RADS 1 negative, with management recommendation for MRI-guided biopsy. This is an example where the imaging assessment and the management recommendation are uncoupled. In the optimal setting, the MR report would have outlined specific contingency management (e.g. if MR-directed US is negative, MR-guided biopsy should be performed). Note that the term "second-look" ultrasound should be avoided as it implies that a "first-look" ultrasound has been performed. The terms "targeted", "MRI-targeted", "directed", or "MRI-directed" ultrasound should be used.

For General FAQs (those that apply to multiple modalities), please see page 869.

APPENDIX A — ULTRASOUND LEXICON SUMMARY FORM

ACR–BI-RADS® — ULTRASOUND SUMMARY LEXICON FORM

For each of the following categories, select the term that best describes the dominant feature.

BREAST TISSUE		
A. Tissue composition: The background echotexture of the breast may affect the sensitivity of breast sonograms for lesion detection. *(select one)*		
1. Tissue pattern	a. Homogeneous background echotexture — fat	Fat lobules and uniformly echogenic bands of supporting structures comprise the bulk of breast tissue
	b. Homogeneous background echotexture — fibroglandular	A thick zone of homogeneously echogenic fibroglandular parenchyma is present beneath the isoechoic layer of subcutaneous fat lobules
	c. Heterogeneous background echotexture	The breast echotexture is characterized by multiple small areas of relative increased and decreased echogenicity
2. Glandular tissue component	a. Minimal	GTC is < 25% of the overall fibroglandular tissue (FGT)
	b. Mild	GTC is between 25% to 49% of overall FGT
	c. Moderate	GTC is between 50% to 74% of overall FGT
	d. Marked	GTC is ≥ 75% of overall FGT
FINDINGS		
B. Masses: A mass is 3-dimensional and occupies space. In 2D ultrasound, it should be seen in two different planes; with volumetric acquisitions, in three planes.		
1. Shape *(select one)*	a. Oval	Elliptical or egg-shaped
	b. Lobulated	Generally oval shape but exhibits one or more indentations resulting in an undulating contour
	c. Round	Spherical or ball-shaped
	d. Irregular	Neither oval, lobulated or round with acute angle protrusions
2. Orientation *(select one)*	a. Parallel	The horizontal dimension of the mass is greater than the anteroposterior dimension in all US orientations
	b. Non-parallel	The anteroposterior dimension of the mass is equal to or greater than the horizontal dimension in any ultrasound orientation
3. Margin *(select one)*	a. Circumscribed	Well-defined, with a sharp transition between the mass and the surrounding tissue. For a mass to be described as circumscribed at ultrasound, the entire margin must be sharply defined
	b. Non-circumscribed	Any portion of the margin is non-circumscribed
	i. Indistinct	All or some portion of the margin is poorly defined or fuzzy with no sharp demarcation from the surrounding tissue
	ii. Angular	Some or all of the margin has sharp corners, often forming acute angles

	iii. Microlobulated	Characterized by short-cycle 2–3 mm undulations or ripples. Microlobulated describes the margin while lobulated describes the shape of a mass
	iv. Spiculated	Characterized by sharp lines radiating from the mass, often a sign of malignancy
4. Echo pattern *(select one)*	a. Anechoic	Without internal echoes
	b. Hyperechoic	Having increased echogenicity relative to fat or equal to fibroglandular tissue
	c. Isoechoic	Same echogenicity as subcutaneous fat and may be relatively inconspicuous
	d. Hypoechoic	Less echogenic than fat but not anechoic (i.e., darker gray than fat but not black)
	e. Heterogeneous	Displays a mix of echo patterns
	f. Mixed solid and cystic	Contains both solid (iso-, hypo-, or hyperechoic) and cystic or fluid (anechoic) components. The important feature is the solid component
5. Posterior features *(select one)*	a. No posterior features	No shadowing or enhancement deep to the mass
	b. Enhancement	An echogenic column deep to the mass is brighter than that seen in the adjacent tissue at a similar depth
	c. Shadowing	The area posterior to the mass (shadowing column) is darker than the tissue at the same depth to either side of the mass; edge shadows should be disregarded
C. Non-mass lesions: A discrete finding that can be identified as distinctly different from normal tissue, is seen in 3 dimensions but lacks the discrete margination of a mass and cannot be assigned a specific shape. *(select one for each category)*		
1. Distribution	a. Regional	A large geographic area that does not conform to a linear or segmental distribution
	b. Focal	A small, confined area
	c. Linear	A longitudinal area arrayed in a line that may conform to a ductal distribution
	d. Segmental	A triangular area with base toward the pectoralis muscle and apex toward that nipple that conforms to a segment of the breast
2. Echo pattern	a. Hyperechoic	Echogenicity is increased relative to fat, often equal to fibroglandular tissue
	b. Heterogeneous	Echogenicity that is a mixture of echogenic patterns
	c. Hypoechoic	Echogenicity that is decreased relative to fat; darker gray than fat but not black
3. Posterior features	a. No posterior features	No shadowing or enhancement posterior to the lesion
	b. Enhancement	Tissue posterior to the lesion appears brighter and hyperechoic compared to the tissue at the same depth on either side of the lesion
	c. Shadowing	Tissue posterior to the lesion appears darker and hypoechoic compared to the tissue at the same depth on either side of the lesion
D. Calcifications: Calcifications can be recognized as echogenic foci, particularly when in a hypoechoic mass, non-mass lesion or distended lactiferous duct. High-frequency, high-resolution transducers can depict both micro and macrocalcifications, but morphology will not be as readily discernible as at mammography, and correlation with mammography is required for precise analysis. *(select all that apply)*		
1. Macrocalcifications	Calcifications that are large enough to attenuate the US beam and are typically associated with posterior shadowing	
2. Microcalcifications	Tiny echogenic foci on US which are most conspicuous when located within a hypoechoic mass, non-mass lesion or duct	
3. Calcifications in a mass or non-mass lesion	Calcifications within benign or malignant masses and non-mass lesions depicted on US	

4. Calcifications outside of a mass or non-mass lesion	Calcifications situated in fat or fibroglandular tissue which are often less conspicuous than when present within a mass or within a non-mass lesion	
5. Intraductal calcifications outside of a mass	Calcifications within a lactiferous duct	
E. Associated features *(select all that apply)*		
1. Echogenic pseudocapsule		Thin white line surrounding an otherwise circumscribed margin which must be uniformly thin and, importantly, must be visible around the entire margin of the mass
2. Echogenic rind		A thick echogenic band surrounding all or part of a mass or non-mass lesion which disrupts the texture of the normal tissue surrounding
3. Architectural distortion		Thin lines radiating from a point and/or focal retraction or straightening of the breast parenchyma, representing distortion of tissue planes
4. Duct changes		Manifested by cystic dilation of a duct or ducts involving irregularities in caliber and/or arborization, extension of duct(s) to or from a malignant mass, or the presence of an intraductal mass, thrombus, or detritus
5. Skin changes *(select one)*	a. Skin thickening	Focal or diffuse skin thickening-more than 2 mm in thickness (up to 4 mm in the periareolar area and inframammary fold)
	b. Skin retraction	The skin surface is concave, indented, and appears fixed
6. Edema		Characterized by interconnected, arborizing hypoechoic or anechoic lines, representing either dilated lymphatics or interstitial fluid
7. Vascularity *(select one)*	a. Avascular	No vascularity on color or power Doppler
	b. Internal vascularity	Blood vessels are present within the finding
	c. Peripheral hypervascularity	A high number of blood vessels around the margin of a breast abnormality
8. Elasticity assessment *(select one)*		Stiffness as a feature of masses may be considered along with their much more important morphologic characteristics
	a. Soft	The finding stiffness is soft; tend to be benign, though there are exceptions
	b. Intermediate	Mixed hard and soft stiffness
	c. Hard	Hard stiffness; tend to be malignant, though there are exceptions
F. Special cases: Cases with a unique diagnosis or pathognomonic findings. *(select all that apply)*		
1. Simple cyst		Mass that is circumscribed, round or oval, circumscribed, anechoic, characterized by thin wall and often shows posterior enhancement
2. Clustered microcysts		Consists of a cluster of anechoic masses, with thin (< 0.5 mm) intervening septations and ***no discrete solid*** component within any of the locules
3. Complicated cysts		Characterized by homogeneous low-level internal echoes; may have layered appearance which may shift slowly with changes in the patient's position; may contain echogenic foci that appear to scintillate as they shift
4. Mass in or on skin		These masses are clinically apparent and may include sebaceous or epidermal inclusion cysts, keloids, moles, pimples, neurofibromas, and accessory nipples
5. Foreign body		May include biopsy marker clips or localization seeds, surgical clips, wires, retained catheter sleeves, cardiac devices, injected or leaked silicone or paraffin, metal or glass related to trauma

6. Implants		Both silicone and saline within normal implants will appear anechoic with a curvilinear echogenic capsule
7. Postsurgical changes, including fluid collection		Some changes involve fluid collections, especially postoperative seromas that appear entirely cystic or may have septations, internal debris or contain both cystic and solid-appearing components, but they should be avascular. Most other postsurgical findings, especially those involving scar tissue, may display suspicious findings, such as shadowing, hypoechogenicity, irregular shape, occasionally spiculated margin, and/or architectural distortion
8. Fat necrosis		May be related to surgical or non-surgical breast trauma and has a variety of appearances on US
9. Post-traumatic (non-surgical changes)		Findings consistent with a hematoma in the acute phase that will evolve over time, or fat necrosis which is seen later in the evolution of post-trauma changes
10. Abscess		Typically present with a palpable breast lump associated with pain, swelling, and erythema
11. Vascular abnormalities	a. AVMs (arteriovenous malformations/ pseudoaneurysms	Usually benign. May be developmental (AVMs) or acquired (pseudoaneurysms)
	b. Superficial thrombophlebitis (Mondor's disease)	Typically presents as a palpable cord with or without associated pain
G. Lymph nodes *(select all that apply)*		
1. Intramammary		May exist throughout the breast, but most commonly seen in the upper outer quadrant (especially the axillary tail). May be seen adjacent to blood vessels. The usual size of normal ranges from 3 to 4 mm up to approximately 1 cm, but they may be larger.
2. Axillary	a. Level I	Lateral to the lateral margin of the pectoralis minor muscle
	b. Level II	Posterior to the pectoralis minor muscle, or between the pectoralis major and pectoralis minor muscles (also known as interpectoral node or Rotter's node)
	c. Level III	Medial to the medial margin of the pectoralis minor muscle
3. Internal mammary		Using the sternum and ribs as landmarks, internal mammary spaces 1 through 4 may be imaged with ultrasound
4. Supraclavicular		Tumor involvement of the ipsilateral supraclavicular node(s) is the highest N stage that is still confined to regional disease (N3c)
H. Location of finding		
1. Laterality	Indicates right or left breast	
2. Location in breast	Clock face (preferred) or quadrant (for large findings)	
3. Depth and/or distance from nipple	Distance from nipple is measured from base of nipple to center of finding	

ASSESSMENT CATEGORIES (select one)		
Incomplete Assessment	**Management**	**Likelihood of Cancer**
Category 0: Incomplete: Need Additional Imaging Evaluation OR Category 0: Incomplete: Need Prior Imaging for Comparison	Recall for additional imaging Need comparison to prior exam (s)	N/A

Final Assessment	Management	Likelihood of Cancer
Category 1: Negative	Routine screening	Essentially 0% likelihood of malignancy
Category 2: Benign	Routine screening	Essentially 0% likelihood of malignancy
Category 3: Probably Benign	Short-interval (6-month) follow-up or continued surveillance (12 month)	> 0% but ≤ 2% likelihood of malignancy
Category 4: Suspicious	Tissue diagnosis	> 2% but < 95% likelihood of malignancy
Category 5: Highly Suggestive of Malignancy	Tissue diagnosis	≥ 95% likelihood of malignancy
Category 6: Known Biopsy-Proven Malignancy	Clinical follow-up with surgeon and/or oncologist, and definitive local therapy (usually surgery) when clinically appropriate	N/A

REFERENCES

1. Chang JM, Leung JWT, Moy L, Ha SM, Moon WK. Axillary Nodal Evaluation in Breast Cancer: State of the Art. Radiology 2020;295:500–15.
2. Brown TP, Ringrose C, Hyland RE, Cole AA, Brotherston TM. A method of assessing female breast morphometry and its clinical application. Br J Plast Surg 1999;52:355–9.
3. Willson SA, Adam EJ, Tucker AK. Patterns of breast skin thickness in normal mammograms. Clin Radiol 1982;33:691–3.
4. American College of Radiology. ACR Practice Parameter for the Performance of a Diagnostic Breast Ultrasound Examination. Available at: https://gravitas.acr.org/PPTS/GetDocumentView?docId=124. Accessed September 30, 2025.
5. Ying M, Sin MH. Comparison of extended field of view and dual image ultrasound techniques: accuracy and reliability of distance measurements in phantom study. Ultrasound Med Biol 2005;31:79–83.
6. Mesurolle B, Helou T, El-Khoury M, Edwardes M, Sutton EJ, Kao E. Tissue harmonic imaging, frequency compound imaging, and conventional imaging: use and benefit in breast sonography. J Ultrasound Med 2007;26:1041–51.
7. Sivarajah RT, Brown K, Chetlen A. "I can see clearly now." fundamentals of breast ultrasound optimization. Clin Imaging 2020;64:124–35.
8. American College of Radiology. ACR Practice Parameter for the Performance of Ultrasound-Guided Percutaneous Breast Interventional Procedure. Available at: https://gravitas.acr.org/PPTS/GetDocumentView?docId=125. Accessed September 30, 2025.
9. Joekel J, Eggemann H, Costa SD, Ignatov A. Should the hyperechogenic halo around malignant breast lesions be included in the measurement of tumor size? Breast Cancer Res Treat 2016;156:311–17.
10. Meier-Meitinger M, Haberle L, Fasching PA, et al. Assessment of breast cancer tumour size using six different methods. Eur Radiol 2011;21:1180–7.
11. Berg WA. BI-RADS 3 on Screening Breast Ultrasound: What Is It and What Is the Appropriate Management? J Breast Imaging 2021;3:527–38.
12. Berg WA, Zhang Z, Cormack JB, Mendelson EB. Multiple bilateral circumscribed masses at screening breast US: consider annual follow-up. Radiology 2013;268:673–83.
13. American College of Radiology. ACR Practice Parameter for the Performance of Whole-Breast Ultrasound for Screening and Staging. Available at: https://gravitas.acr.org/PPTS/GetDocumentView?docId=61. Accessed September 30, 2025.
14. Berg WA, Blume JD, Cormack JB, et al. Combined screening with ultrasound and mammography vs mammography alone in women at elevated risk of breast cancer. JAMA 2008;299:2151–63.
15. Ohuchi N, Suzuki A, Sobue T, et al. Sensitivity and specificity of mammography and adjunctive ultrasonography to screen for breast cancer in the Japan Strategic Anti-cancer Randomized Trial (J-START): a randomised controlled trial. Lancet 2016;387:341–48.
16. Tagliafico AS, Mariscotti G, Valdora F, et al. A prospective comparative trial of adjunct screening with tomosynthesis or ultrasound in women with mammography-negative dense breasts (ASTOUND-2). Eur J Cancer 2018;104:39–46.

17. Berg WA, Vourtsis A. Screening Breast Ultrasound Using Handheld or Automated Technique in Women with Dense Breasts. J Breast Imaging 2019;1:283–96.

18. Tang G, An X, Xiang H, Liu L, Li A, Lin X. Automated Breast Ultrasound: Interobserver Agreement, Diagnostic Value, and Associated Clinical Factors of Coronal-Plane Image Features. Korean J Radiol 2020;21:550–60.

19. Lee SH, Moon WK. Glandular Tissue Component on Breast Ultrasound in Dense Breasts: A New Imaging Biomarker for Breast Cancer Risk. Korean J Radiol 2022;23:574–80.

20. Lee SH, Ryu HS, Jang MJ, et al. Glandular Tissue Component and Breast Cancer Risk in Mammographically Dense Breasts at Screening Breast US. Radiology 2021;301:57–65.

21. Figueroa JD, Pfeiffer RM, Brinton LA, et al. Standardized measures of lobular involution and subsequent breast cancer risk among women with benign breast disease: a nested case–control study. Breast Cancer Res Treat 2016;159:163–72.

22. McKian KP, Reynolds CA, Visscher DW, et al. Novel breast tissue feature strongly associated with risk of breast cancer. J Clin Oncol 2009;27:5893–8.

23. Kuba MG, Giess CS, Wieczorek TJ, Lester SC. Hyperechoic malignancies of the breast: Underlying pathologic features correlating with this unusual appearance on ultrasound. Breast J 2020; 26:643–52.

24. Linda A, Zuiani C, Lorenzon M, et al. Hyperechoic lesions of the breast: not always benign. AJR Am J Roentgenol 2011;196:1219–24.

25. Nam SY, Ko ES, Han BK, et al. Ultrasonographic hyperechoic lesions of the breast: are they always benign? Acta Radiol 2015;56:18-24.

26. Nassar L, Issa G, Farah Z, El Zein Y, Berjawi G. Predictors of Malignancy in Hyperechoic Breast Lesions. J Ultrasound Med 2016;35:783–90.

27. Baad M, Lu ZF, Reiser I, Paushter D. Clinical Significance of US Artifacts. Radiographics 2017;37:1408–23.

28. Baker JA, Soo MS, Rosen EL. Artifacts and pitfalls in sonographic imaging of the breast. AJR Am J Roentgenol 2001;176:1261–6.

29. Hong AS, Rosen EL, Soo MS, Baker JA. BI-RADS for sonography: positive and negative predictive values of sonographic features. AJR Am J Roentgenol 2005;184:1260–5.

30. Uematsu T. Non-mass-like lesions on breast ultrasonography: a systematic review. Breast Cancer 2012;19:295–301.

31. Park JW, Ko KH, Kim EK, Kuzmiak CM, Jung HK. Non-mass breast lesions on ultrasound: final outcomes and predictors of malignancy. Acta Radiol 2017;58:1054–60.

32. Park KW, Park S, Shon I, et al. Non-mass lesions detected by breast US: stratification of cancer risk for clinical management. Eur Radiol 2021;31:1693–706.

33. Choe J, Chikarmane SA, Giess CS. Nonmass Findings at Breast US: Definition, Classifications, and Differential Diagnosis. Radiographics 2020;40:326–35.

34. Kim HR, Jung HK. Histopathology findings of non-mass cancers on breast ultrasound. Acta Radiol Open 2018;7:2058460118774957.

35. Hong S, Li W, Gao W, et al. Diagnostic performance of elastography for breast non-mass lesions: A systematic review and meta-analysis. Eur J Radiol 2021;144:109991.

36. Zhang F, Jin L, Li G, et al. The role of contrast-enhanced ultrasound in the diagnosis of malignant non-mass breast lesions and exploration of diagnostic criteria. Br J Radiol 2021;94:20200880.

37. Berg WA, Leung J. *Diagnostic Imaging: Breast E-Book*: Elsevier Health Sciences; 2019.

38. Wu J, Kong R, Tian S, et al. Advances in Ultrasound-Guided Vacuum-Assisted Biopsy of Breast Microcalcifications. Ultrasound Med Biol 2021;47:1172–81.

39. Yang WT, Tse GM. Sonographic, mammographic, and histopathologic correlation of symptomatic ductal carcinoma in situ. AJR Am J Roentgenol 2004;182:101–10.

40. Soo MS, Baker JA, Rosen EL. Sonographic detection and sonographically guided biopsy of breast microcalcifications. AJR Am J Roentgenol 2003;180:941–8.

41. Cho N, Moon WK, Cha JH, et al. Ultrasound-guided vacuum-assisted biopsy of microcalcifications detected at screening mammography. Acta Radiol 2009;50:602–9.

42. Chala L, Endo E, Kim S, et al. Gray-scale sonography of solid breast masses: diagnosis of probably benign masses and reduction of the number of biopsies. J Clin Ultrasound 2007;35:9–19.

43. Cole-Beuglet C, Soriano RZ, Kurtz AB, Goldberg BB. Ultrasound analysis of 104 primary breast carcinomas classified according to histopathologic type. Radiology 1983;147:191–6.

44. Skaane P, Engedal K. Analysis of sonographic features in the differentiation of fibroadenoma and invasive ductal carcinoma. AJR Am J Roentgenol 1998;170:109–14.

45. Stavros AT, Thickman D, Rapp CL, Dennis MA, Parker SH, Sisney GA. Solid breast nodules: use of sonography to distinguish between benign and malignant lesions. Radiology 1995;196:123–34.

46. Watanabe T, Yamaguchi T, Tohno E, et al. B-mode ultrasound diagnostic flowchart for solid breast masses: JABTS BC-01 study. J Med Ultrason (2001) 2021;48:71–81.

47. Costantini M, Belli P, Lombardi R, Franceschini G, Mule A, Bonomo L. Characterization of solid breast masses: use of the sonographic breast imaging reporting and data system lexicon. J Ultrasound Med 2006;25:649-59; quiz 61.

48. Durmus T, Stockel J, Slowinski T, Thomas A, Fischer T. The hyperechoic zone around breast lesions - an indirect parameter of malignancy. Ultraschall Med 2014;35:547–53.

49. Dylke ES, Benincasa Nakagawa H, Lin L, Clarke JL, Kilbreath SL. Reliability and Diagnostic Thresholds for Ultrasound Measurements of Dermal Thickness in Breast Lymphedema. Lymphat Res Biol 2018;16:258–62.

50. Raza S, Baum JK. Solid breast lesions: evaluation with power Doppler US. Radiology 1997; 203:164–8.

51. Karstrup S, Hegedus L, Holm HH. Acute change in parathyroid function in primary hyperparathyroidism following ultrasonically guided ethanol injection into solitary parathyroid adenomas. Acta Endocrinol (Copenh) 1993;129:377–80.

52. Chang JM, Won JK, Lee KB, Park IA, Yi A, Moon WK. Comparison of shear-wave and strain ultrasound elastography in the differentiation of benign and malignant breast lesions. AJR Am J Roentgenol 2013;201:W347–56.

53. Chang JM, Moon WK, Cho N, Kim SJ. Breast mass evaluation: factors influencing the quality of US elastography. Radiology 2011;259:59–64.

54. Berg WA, Cosgrove DO, Dore CJ, et al. Shear-wave elastography improves the specificity of breast US: the BE1 multinational study of 939 masses. Radiology 2012;262:435–49.

55. Park SY, Kang BJ. Combination of shear-wave elastography with ultrasonography for detection of breast cancer and reduction of unnecessary biopsies: a systematic review and meta-analysis. Ultrasonography 2021;40:318–32.

56. Barr RG, Nakashima K, Amy D, et al. WFUMB guidelines and recommendations for clinical use of ultrasound elastography: Part 2: breast. Ultrasound Med Biol 2015;41:1148–60.

57. Barr RG, De Silvestri A, Scotti V, et al. Diagnostic Performance and Accuracy of the 3 Interpreting Methods of Breast Strain Elastography: A Systematic Review and Meta-analysis. J Ultrasound Med 2019;38:1397–404.

58. Berg WA. Sonographically depicted breast clustered microcysts: is follow-up appropriate? AJR Am J Roentgenol 2005;185:952–9.

59. Goldbach AR, Tuite CM, Ross E. Clustered Microcysts at Breast US: Outcomes and Updates for Appropriate Management Recommendations. Radiology 2020;295:44–51.

60. Greenwood HI, Lee AY, Lobach IV, Carpentier BM, Freimanis RI, Strachowski LM. Clustered Microcysts on Breast Ultrasound: What Is an Appropriate Management Recommendation? AJR Am J Roentgenol 2017;209:W395–W99.

61. Seiler SJ, Sharma PB, Hayes JC, et al. Multimodality Imaging-based Evaluation of Single-Lumen Silicone Breast Implants for Rupture. Radiographics 2017;37:366–82.

62. Marra A, Viale G, Pileri SA, et al. Breast implant-associated anaplastic large cell lymphoma: A comprehensive review. Cancer Treat Rev 2020;84:101963.

63. Sharma B, Jurgensen-Rauch A, Pace E, et al. Breast Implant-associated Anaplastic Large Cell Lymphoma: Review and Multiparametric Imaging Paradigms. Radiographics 2020;40:609–28.

64. Jaffe ES, Ashar BS, Clemens MW, et al. Best Practices Guideline for the Pathologic Diagnosis of Breast Implant-Associated Anaplastic Large-Cell Lymphoma. J Clin Oncol 2020;38:1102–11.

65. Strachowski L, Berg W. *Trauma, Diagnostic Imaging: Breast 3rd edition*: Elsevier; 2020.

66. Vashi R, Hooley R, Butler R, Geisel J, Philpotts L. Breast imaging of the pregnant and lactating patient: physiologic changes and common benign entities. AJR Am J Roentgenol 2013;200:329–36.

67. Jesinger RA, Lattin GE, Jr., Ballard EA, Zelasko SM, Glassman LM. Vascular abnormalities of the breast: arterial and venous disorders, vascular masses, and mimic lesions with radiologic-pathologic correlation. Radiographics 2011;31:E117–36.

68. Shetty MK, Watson AB. Mondor's disease of the breast: sonographic and mammographic findings. AJR Am J Roentgenol 2001;177:893–6.

69. Bedi DG, Krishnamurthy R, Krishnamurthy S, et al. Cortical morphologic features of axillary lymph nodes as a predictor of metastasis in breast cancer: in vitro sonographic study. AJR Am J Roentgenol 2008;191:646–52.

70. Chung HL, Le-Petross HT, Leung JWT. Imaging Updates to Breast Cancer Lymph Node Management. Radiographics 2021;41:1283–99.

71. Chung H, Whitman G, Leung J, Sun J, Middleton L, Le-Petross H. Ultrasound features to differentiate COVID-19 vaccine-induced benign adenopathy from breast cancer related malignant adenopathy. Academic Radiology 2022;29:1004–12.

72. Chung HL, Tso HH, Middleton LP, Sun J, Leung JWT. Axillary Nodal Metastases in Invasive Lobular Carcinoma Versus Invasive Ductal Carcinoma: Comparison of Node Detection and Morphology by Ultrasound. AJR Am J Roentgenol 2022;218:33–41.

73. Lane DL, Adeyefa MM, Yang WT. Role of sonography for the locoregional staging of breast cancer. AJR Am J Roentgenol 2014;203:1132–41.

74. Wang W, Qiu P, Li J. Internal mammary lymph node metastasis in breast cancer patients based on anatomical imaging and functional imaging. Breast Cancer 2022;29:933–44.

75. Dogan BE, Dryden MJ, Wei W, et al. Sonography and Sonographically Guided Needle Biopsy of Internal Mammary Nodes in Staging of Patients With Breast Cancer. AJR Am J Roentgenol 2015;205:905–11.

76. Berg WA, Blume JD, Cormack JB, Mendelson EB, Madsen EL, Investigators A. Lesion detection and characterization in a breast US phantom: results of the ACRIN 6666 Investigators. Radiology 2006;239:693–702.

77. Berg WA, Sechtin AG, Marques H, Zhang Z. Cystic breast masses and the ACRIN 6666 experience. Radiol Clin North Am 2010;48:931–87.

78. Sickles EA. Periodic mammographic follow-up of probably benign lesions: results in 3,184 consecutive cases. Radiology 1991;179:463–8.

79. Ryser MD, Worni M, Turner EL, Marks JR, Durrett R, Hwang ES. Outcomes of Active Surveillance for Ductal Carcinoma in Situ: A Computational Risk Analysis. J Natl Cancer Inst 2016;108.

80. Toi M, Kinoshita T, Benson JR, et al. Non-surgical ablation for breast cancer: an emerging therapeutic option. Lancet Oncol 2024;25:e114–e25.

81. American College of Radiology. ACR Practice Parameter for Communication of Diagnostic Imaging Findings. Available at: https://gravitas.acr.org/PPTS/GetDocumentView?docId=74. Accessed September 30, 2025.

82. Figueroa JD, Pfeiffer RM, Brinton LA, et al. Standardized measures of lobular involution and subsequent breast cancer risk among women with benign breast disease: a nested case-control study. Breast Cancer Res Treat 2016;159:163–72.



ACR BI-RADS® v2025

Magnetic Resonance Imaging

Wendy B. DeMartini, MD, Chair

Roberta M. Strigel, MD, MS, Vice-Chair
Katja Pinker, MD, PhD
Habib Rahbar, MD
Lilian C. Wang, MD



American College of Radiology™

TABLE OF CONTENTS

PREFACE 502

INTRODUCTION 503

I. ACQUISITION PARAMETERS 504

II. BREAST IMAGING LEXICON — MRI 508

A. AMOUNT OF FIBROGLANDULAR TISSUE (FGT) 510

B. BACKGROUND PARENCHYMAL ENHANCEMENT (BPE) 513

C. MASSES 519

D. NON-MASS ENHANCEMENT (NME). 548

E. ENHANCEMENT KINETICS. 577

F. LYMPH NODES 584

G. ASSOCIATED FEATURES 605

H. OTHER FINDINGS — TYPICALLY BENIGN 627

I. LOCATION OF FINDING 654

J. IMPLANTS AND OTHER TYPES OF AUGMENTATION 655

III. REPORTING SYSTEM 702

A. ASSESSMENT CATEGORIES 702

B. REPORT ORGANIZATION 710

C. WORDING OF REPORT. 713

IV. GUIDANCE 714

V. FREQUENTLY ASKED QUESTIONS 716

APPENDIX A — MRI LEXICON SUMMARY FORM 717

PREFACE

This illustrated BI-RADS® v2025 Manual chapter on Breast MRI builds upon the previous 5th Edition Atlas (2013). This new version retains a significant amount of the prior content and concepts but also contains changes that reflect evolving MRI acquisition techniques, important clinical considerations, and the results of interval scientific literature. As is true across all of the BI-RADS breast imaging modalities, the purpose of the structured breast MRI lexicon and reporting system is to standardize reporting language to facilitate clear communication and best outcomes for patients and providers. Appropriate use of BI-RADS is also critical to audit performance outcomes and for research purposes.

In this BI-RADS v2025 Manual, the lexicon and figures have been updated and expanded with new image examples from high quality breast MRI examinations. Each figure legend describes several features of the imaging finding. In the legend the dominant lexicon feature being illustrated is shown in capital letters, and additional descriptors are in lower case (e.g., "Lobulated, circumscribed, rim enhancing MASS"). Where possible, the biopsy-proven pathology of the finding is also included. In this new version of the Manual, the lexicon descriptors within a given category that cross the BI-RADS modalities, are arranged from least to most suspicious, where appropriate.

The BI-RADS v2025 Manual chapter on Breast MRI is designed for everyday practice. The Manual is also a dynamic document for which feedback is welcomed and will be considered for future updates. The Committee on BI-RADS appreciates comments and/or suggestions from its users and requests that these be submitted by e-mail to the ACR. However, prior to submitting comments or suggestions, please first visit the ACR BI-RADS web site at https://www.acr.org/Clinical-Resources/Clinical-Tools-and-Reference/Reporting-and-Data-Systems/BI-RADS, which displays committee approved responses to Frequently Asked Questions. Note that it is anticipated that future Manual updates can occur at shorter intervals due to a new electronic publication format.

All breast imaging reporting system vendors licensed to use BI-RADS terminology in their software will have access to the files for this version of the Manual in sufficient time to update their applications within the 180 days stipulated by the signed license agreement they have with the American College of Radiology (ACR). Users should verify that their equipment has been updated with the most recent software or request updates from their vendors to ensure that their automated reporting is up to date and accurate.

Committee on BI-RADS®
American College of Radiology
E-mail: RADS@acr.org

Wendy B. DeMartini, MD, FSBI
Chair, Subcommittee on BI-RADS® MRI

INTRODUCTION

This BI-RADS - Breast MRI system reflects the current state of the breast MRI field, with an emphasis on clinically applicable concepts and language. Breast MRI remains an evolving area, and subsequent updates will reflect continued advances in image acquisition and interpretation.

The ACR BI-RADS — MRI is divided into five sections and one appendix.

SECTION I: Acquisition Parameters

SECTION II: Breast Imaging Lexicon - MRI

SECTION III: Reporting System

SECTION IV: Guidance

SECTION V: Frequently Asked Questions

APPENDIX A — MRI Lexicon Summary Form

The following are brief summaries of each section.

I. Acquisition Parameters

This section describes the key concepts and reporting of image acquisition techniques, including newer and evolving areas such as abbreviated protocols and diffusion weighted imaging.

II. Breast Imaging Lexicon - MRI

This section describes the key concepts and terminology for reporting the tissue properties and significant findings in the breast and for regional lymph nodes. Multiple image examples are included. Enhancement morphology (appearance features) remains most important for characterizing breast MRI findings, and the majority of image examples illustrate morphologic features. Enhancement kinetics may also be helpful in assessment of MRI lesions for which the morphology is not definitively benign or suspicious.

III. Reporting System

This section describes the organized approach for reporting including assessment categories and management recommendations. The key concepts for use and reporting of clinical indications, relevant clinical history and comparison examinations are also described.

IV. Guidance

This section offers further detail and guidance for potentially challenging areas of BI-RADS application. It also describes the major changes compared to the prior BI-RADS Edition.

V. Frequently Asked Questions

Frequently asked questions are addressed.

Appendix A

The appendix contains a table of standardized terminology and abbreviations for MRI.

I. ACQUISITION PARAMETERS

A. OVERVIEW

There is no single protocol for performing high quality contrast-enhanced breast MRI. However, several basic principles should be followed. Breast MRI sequences should balance spatial resolution, temporal resolution, signal-to-noise ratio and field-of-view.

Detailed standards for protocols can be found in the ACR Practice Parameter for the Performance of Contrast-Enhanced Magnetic Resonance Imaging (MRI) of the Breast [1] and the ACR Breast MRI Accreditation Program [2].

An MR scanner with sufficient field strength to achieve high spatial resolution should be used. Typically, 1.5T or a higher field strength is required to achieve sufficient quality**.** A dedicated bilateral breast coil should be used, and simultaneous bilateral acquisition should be performed. Bilateral imaging allows evaluation of the bilateral breasts and regional lymph nodes, and in the setting of mastectomy allows assessment of the mastectomy site with or without reconstruction. Bilateral imaging also improves interpretation, as having the contralateral breast is helpful to compare the level and pattern of background parenchymal enhancement between breasts and for the detection of subtle unique abnormalities.

Gadolinium contrast is currently required for breast cancer detection and assessment, and contrast should be administered using a weight-based dose. Non-contrast breast MRI methods for cancer detection are investigational at this time. Breast MRI that is performed only to assess implant integrity does not require contrast.

Protocols should be standardized as much as possible across different magnets within a practice, particularly for the timing of the early (previously "initial") post-contrast sequence, defined as the series obtained at approximately 60–120 seconds after administration of contrast, the usual standard clinical sequence timepoint when the majority of breast cancers are most evident. Standardization provides consistency for technologists and radiologists and allows better comparison of examinations over time for an individual patient.

Breast MRI reports should describe the key acquisition techniques, including the field strength and pulse sequences utilized. Contrast enhanced exams should include the dose and type of gadolinium contrast agent and the details of contrast injection. Temporal resolution (including any delay after contrast administration, number and length of post-contrast sequences) should be reported for dynamic contrast enhanced (DCE) series. When utilized, computer aided evaluation of kinetics or other post-processing techniques should also be described. Since most parameters will remain constant, standardized language for MRI techniques can be used in the reports. Finally, significant imaging artifacts such as from patient motion, susceptibility artifacts, fat suppression failure/inhomogeneity, and suboptimal contrast injection should be described.

B. STANDARD "FULL PROTOCOL" CONTRAST ENHANCED MRI

Dynamic contrast-enhanced (DCE) MRI is the foundation of clinical breast MRI, and contrast is currently required for breast cancer detection. During DCE MRI, the uptake and washout of a gadolinium contrast agent in breast tissue is observed over time using pre- and post-contrast imaging series. Breast cancers are characterized by abnormal highly permeable neovascularity and typically enhance quickly with early enhancement in the 60–120 seconds after contrast administration. Therefore, it is important to acquire an early post-contrast sequence in this time frame, because this is when most cancers will be avidly enhancing but background

parenchymal enhancement (BPE) is less likely to have increased to maximum. The early post-contrast sequence at 60–120 seconds is the first post-contrast series in many protocols, but in some techniques may be preceded by other post-contrast images, such as in "faster" protocols with very high temporal resolution initial images that are possible with newer techniques.

Morphologic features, such as for a mass the shape and margin, remain the most important MRI characteristics in predicting malignancy, and routine clinical protocols should prioritize achieving high spatial resolution imaging to best depict morphology. Assessment of the contrast enhancement over time using signal time intensity curves for kinetics may also help characterize MRI findings for which the morphology is not definitively benign or suspicious.

Early phase (previously called initial phase) contrast enhancement describes the enhancement-related signal intensity that occurs in the first 60–120 seconds after contrast injection, and in particular the change in intensity comparing the early time point to the pre-contrast time point. The name for this timepoint has been changed to early compared to the prior BI-RADS Edition because there may be other initial timepoints acquired using faster techniques, see discussion below. Delayed phase contrast enhancement describes the enhancement-related signal intensity that occurs after the first 60–120 seconds after contrast injection or when the curve begins to change, and in particular the change in intensity comparing the delayed time point to the early post-contrast time point. These signal intensity changes over time on the post-contrast series create the signal intensity time curve used for kinetics assessments. Time intensity curves and kinetics are not truly quantitative. Importantly, they vary according to the MR magnet, coil, contrast agent, pulse sequences, timing of post-contrast images and other factors. In addition, there is imperfect reproducibility in kinetics assignment for the same MRI lesions across computer-aided systems [3], and across radiologists [4].

Standard "full protocol" breast MRI examinations have at least two post-contrast series and typically include the following sequences:

1) 3-plane localizer
2) T2-weighted series (e.g., fluid sensitive T2 or STIR with sufficient T2-weighting to demonstrate fluid signal hyperintensity, for simplicity referred to as T2 in the remainder of this MRI section)
3) Non-contrast series without fat suppression, often T1-weighted
4) T1-weighted dynamic contrast-enhanced (DCE) with one pre- and at least two post-contrast series

The DCE series are optimally viewed with fat removal to better demonstrate lesion enhancement. Fat removal may be achieved by acquiring the DCE MRI sequences with active fat suppression or by creation of separate subtracted series. Most U.S. practices achieve fat removal by active fat suppression on the acquired DCE sequences and also create post-processed subtraction images to remove non-enhancing structures. Alternatively, some practices do not perform active fat suppression and rely only on post-processed subtraction images for fat signal removal. Subtracted images can be impacted by patient motion between the sequences that are subtracted which can result in artifactual "pseudoenhancement," and radiologists should be alert to this potential artifact.

C. ABBREVIATED CONTRAST ENHANCED MRI

There is much interest in shorter "abbreviated" MRI acquisition protocols that may reduce cost and improve access to breast MRI. There is no single definition for what constitutes an abbreviated MRI examination, but total scan times are usually less than 10 minutes. At minimum, a 3-plane localizer and a T1-weighted pre and single post-contrast series with or without active

fat suppression are included. Some protocols may also include a T2-weighted series. As with full protocol MRI, it is important to acquire an early post-contrast series 60–120 seconds after contrast at the time of maximum enhancement for most breast cancers and the largest contrast difference from background parenchymal enhancement.

Abbreviated MRI has been investigated and implemented at some sites as a tool for supplemental screening. There is ongoing research into whether abbreviated protocols are sufficient for other breast clinical indications.

Interpretation of abbreviated MRI is similar to that of a full protocol, but if only a single early post-contrast sequence is performed there is no delayed phase kinetics. Early post-contrast kinetics can still be assessed, as can even earlier kinetics if a "fast" or "ultrafast" protocol is being used.

D. DIFFUSION WEIGHTED IMAGING

There is continued interest in diffusion weighted imaging (DWI), a non-contrast MRI technique that can augment DCE information including distinguishing benign from malignant findings. DWI measures the mobility of water molecules within tissue, reflecting the cellular microenvironment. Breast cancers typically demonstrate reduced water diffusivity relative to normal and benign tissue.

For DWI, motion-sensitizing gradients are applied during image acquisition, and the DW signal intensity is proportional to water mobility within a voxel. The apparent diffusion coefficient (ADC) is the rate of diffusion defined as the average area occupied by a water molecule per unit time (in mm^2/second). ADC values are calculated using image acquisitions at two or more different b-values. The b-value reflects the strength and timing of the imaging gradients used to generate diffusion-weighted images. The higher the b-value, the stronger the diffusion effects. ADC values quantitatively reflect a composite of tissue factors affecting net water mobility in each voxel including microcirculation, cellular density, organization, and membrane integrity. Requirements for DWI of the breast include specification of b values (typically 0 and 800 with additional higher b-values optional), repetition and echo times, spatial resolution and fat removal.

Because breast cancers typically exhibit hindered water diffusion, they exhibit higher DWI signal on high b-value images and lower ADC values compared with normal and benign breast tissue. DWI information has been shown to complement DCE MRI to help distinguish between benign and malignant findings to decrease unnecessary biopsies, predict and monitor response to neoadjuvant therapy, and stratify ductal carcinoma in situ from invasive disease. There is ongoing research for use of DWI as a component of non-contrast MRI protocols for screening.

Guidelines for reporting DWI findings are not a component of BI-RADS at this time. The Breast MRI DWI international working group statement [5] classification system may be used, categorizing diffusion level as very low, low, intermediate, high, and very high. Due to the promise of DWI, it is anticipated that a BI-RADS working group will be convened to create a DWI lexicon supplement to the Breast MRI section.

E. OTHER ADVANCED MRI TECHNIQUES

Advanced faster very high temporal resolution (e.g., "fast," "ultrafast") protocols are now available on some MRI scanners. These achieve higher temporal resolution while preserving high spatial resolution, allowing multiple early post-contrast acquisitions. If utilized, the faster frequent early sampling of the signal intensity time curve allows additional analysis in the first two minutes after contrast prior to early enhancement, while still supporting analysis of early and delayed enhancement. This early faster sampling can provide parameters including time-to-early

enhancement, slope of the contrast uptake curve, area under the signal time intensity curve, and identification of findings that enhance first in the breast (before BPE) as factors which may prove useful in lesion assessment.

Other techniques, such as proton MR spectroscopy, Na MRI, chemical exchange saturation transfer (CEST), hypoxia imaging and ultra-high field strength MRI (e.g., 7T) remain investigational at this time.

II. BREAST IMAGING LEXICON — MRI

Table 1. BI-RADS® Breast MRI Lexicon Overview

Breast Tissue	Terms	
A. Amount of fibroglandular tissue (FGT)	(A) Almost entirely fatty (B) Scattered fibroglandular tissue (C) Heterogeneous fibroglandular tissue (D) Extreme fibroglandular tissue	
B. Background parenchymal enhancement (BPE)	1. Level	a. Minimal (includes no enhancement) b. Mild c. Moderate d. Marked
	2. Symmetry	a. Symmetric b. Asymmetric
Findings	**Terms**	
C. Masses	1. Shape	a. Oval b. Lobulated c. Round d. Irregular
	2. Margin	a. Circumscribed b. Non-circumscribed i. Indistinct ii. Spiculated
	3. Internal enhancement pattern	a. Homogeneous b. Dark internal septations c. Heterogeneous d. Thick rim enhancement
	4. T2 signal intensity	a. Hyperintense b. Not hyperintense
D. Non-mass enhancement (NME)	1. Distribution	a. Diffuse b. Regional c. Focal d. Linear e. Segmental
	2. Internal enhancement pattern	a. Homogeneous b. Heterogeneous c. Clumped d. Clustered ring
E. Enhancement kinetics	1. Early phase	a. Slow b. Medium c. Fast
	2. Delayed phase	a. Persistent b. Plateau c. Washout

F. Lymph nodes	1. Intramammary	a. Normal b. Abnormal
	2. Axillary	a. Normal b. Abnormal
	3. Internal mammary	a. Normal b. Abnormal
G. Associated features	1. Nipple retraction 2. Nipple involvement 3. Skin retraction 4. Skin thickening 5. Skin involvement 6. Pectoralis muscle involvement 7. Chest wall involvement 8. Peritumoral edema	
H. Other findings — typically benign	1. High T1 duct signal 2. Cysts 3. Postoperative collections (hematoma/seroma) 4. Post-therapy skin thickening and trabecular thickening 5. Non-enhancing mass 6. Signal void 7. Fat necrosis 8. Hamartoma 9. Enhancing skin lesions	
I. Location of finding	1. Laterality 2. Location in breast 3. Depth 4. Distance from nipple	
J. Implants and other types of augmentation	1. Location	a. Prepectoral b. Retropectoral
	2. Material	a. Saline i. Intact ii. Ruptured b. Silicone i. Intact ii. Ruptured c. Other implant/augmentation material
	3. Lumen type	a. Single b. Double
	4. Intracapsular silicone findings	a. Radial folds (normal variant) b. Signs of intracapsular rupture i. Subcapsular line ii. Keyhole sign iii. Linguine sign c. Water droplets
	5. Extracapsular silicone findings	a. Breast b. Lymph nodes
	6. Focal contour bulge	
	7. Peri-implant fluid	

A. AMOUNT OF FIBROGLANDULAR TISSUE (FGT)

The amount of fibroglandular tissue (FGT) is the relative volume of the breast comprised of the fibroglandular structures. On breast MRI the amount or volume of fibroglandular tissue is visible in 3 dimensions. Unlike mammography for which the breast density due to the amount of FGT impacts accuracy, on MRI larger amounts of FGT do not impact diagnostic performance.

The amount FGT should be subjectively assessed and assigned based on the relative volume of the breast comprised of fibroglandular tissue on T1-weighted imaging with or without fat removal. Similar to mammographic breast density assessment, the amount of fibroglandular tissue is not reported using percentages. The term density should not be used to describe MRI FGT as density is an x-ray imaging not MRI property.

The amount of FGT should be reported in one of four categories:

(A) Almost entirely fatty

(B) Scattered fibroglandular tissue

(C) Heterogeneous fibroglandular tissue

(D) Extreme fibroglandular tissue

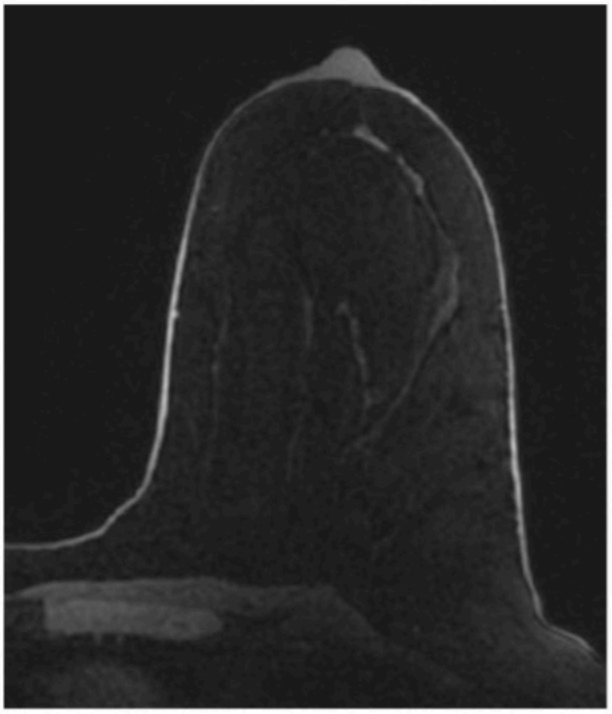

Figure 1 – AMOUNT OF FIBROGLANDULAR TISSUE: ALMOST ENTIRELY FATTY. Fat-suppressed non-contrast T1W image.

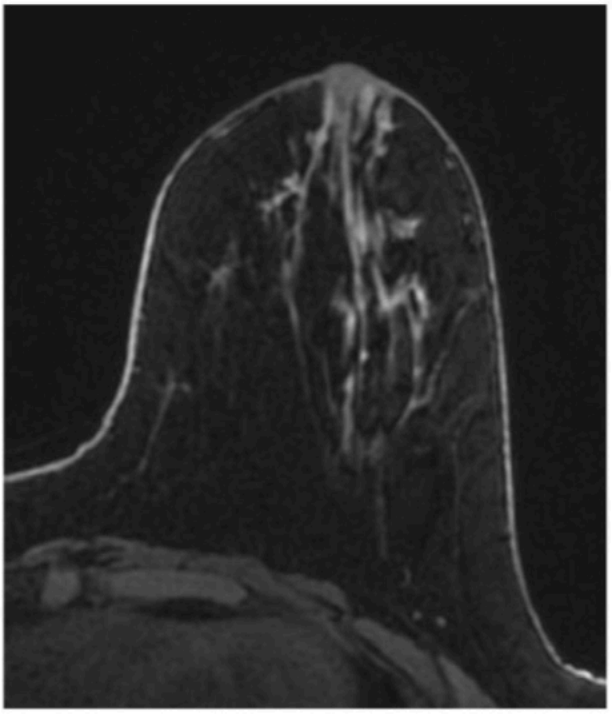

Figure 2 – AMOUNT OF FIBROGLANDULAR TISSUE: SCATTERED FIBROGLANDULAR TISSUE. Fat-suppressed non-contrast T1W image.

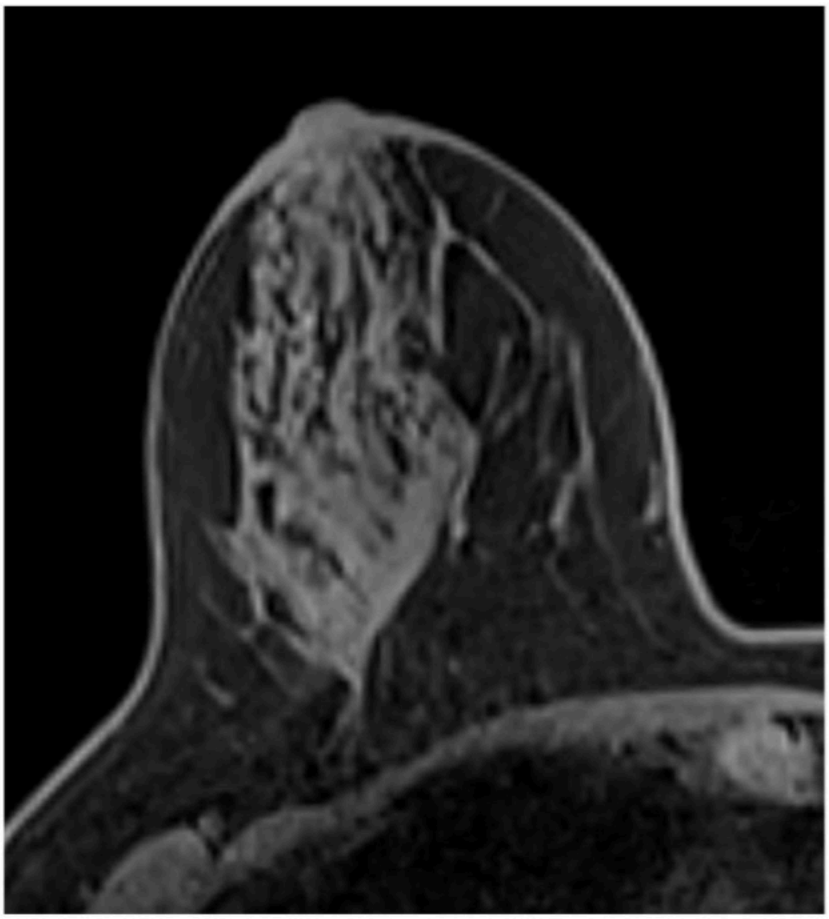

Figure 3 – AMOUNT OF FIBROGLANDULAR TISSUE: HETEROGENEOUS FIBROGLANDULAR TISSUE. Fat-suppressed non-contrast T1W image.

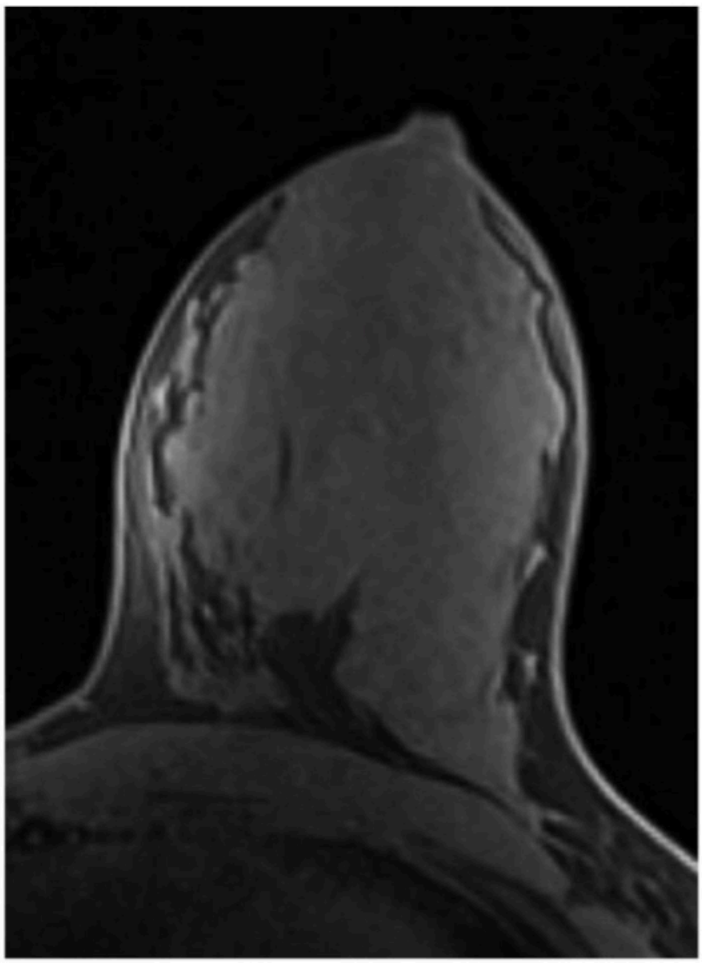

Figure 4 – AMOUNT OF FIBROGLANDULAR TISSUE: EXTREME FIBROGLANDULAR TISSUE. Fat-suppressed non-contrast T1W image.

B. BACKGROUND PARENCHYMAL ENHANCEMENT (BPE)

Background parenchymal enhancement (BPE) is benign, physiologic enhancement of the fibroglandular tissue. BPE is common, particularly in premenopausal patients. Typical BPE patterns include a peripheral "picture-frame" or "cortical" appearance, and a pattern of scattered dots of enhancement throughout the breast. BPE can also appear as more complex patterns including somewhat mass-like and non-mass-like areas of enhancement.

The level of BPE should be subjectively assessed using the early post-contrast images (60–120 seconds after contrast). The BPE level is based on the qualitative proportion or amount of fibroglandular tissue demonstrating benign-appearing enhancement. If subtracted series are used to assess BPE it is important to check for motion between the pre- and post-contrast series for appropriate categorization of BPE, since motion misregistration may create "pseudoenhancement" on the subtracted images.

The BPE level should be reported in one of four categories:

a) Minimal (includes no enhancement)

b) Mild

c) Moderate

d) Marked

BPE may be symmetric or asymmetric. It is optional to report the symmetry/asymmetry of BPE. If asymmetric, BPE may be assigned individually for each breast, or alternatively overall across both breasts using the higher BPE level. Common causes for asymmetric BPE include prior breast cancer treated with partial mastectomy and radiation therapy which results in lower level of ipsilateral BPE, and asymmetric amounts of fibroglandular tissue.

1. BPE LEVEL

    a. Minimal (includes no enhancement)

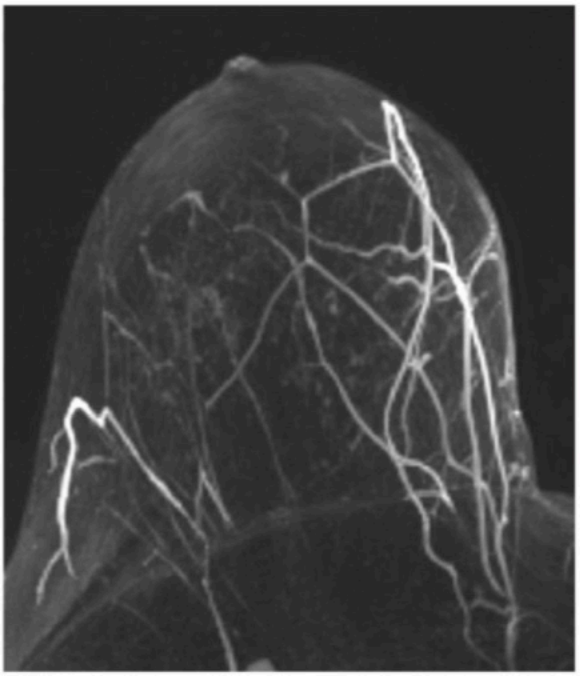

Figure 1 – BACKGROUND PARENCHYMAL ENHANCEMENT: MINIMAL. Early post-contrast T1W maximum intensity projection image.

B. BACKGROUND PARENCHYMAL ENHANCEMENT (BPE)

1. BPE LEVEL

   b. Mild

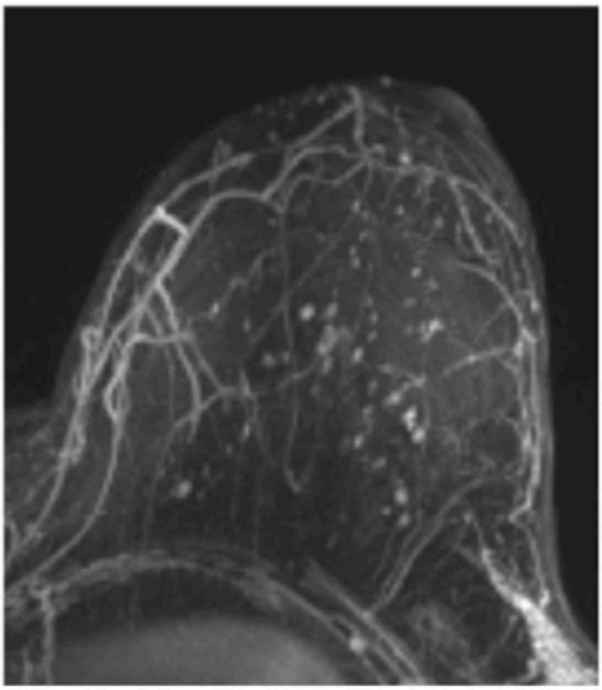

Figure 2 – BACKGROUND PARENCHYMAL ENHANCEMENT: MILD. Early post-contrast T1W maximum intensity projection image.

B. BACKGROUND PARENCHYMAL ENHANCEMENT (BPE)

1. BPE LEVEL
    c. Moderate

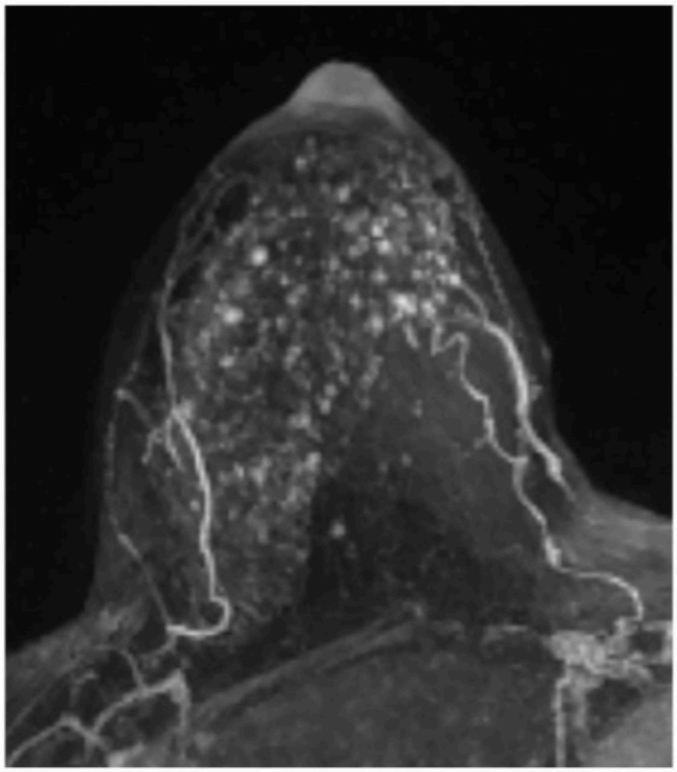

Figure 3 – BACKGROUND PARENCHYMAL ENHANCEMENT: MODERATE. Early post-contrast T1W maximum intensity projection image.

B. BACKGROUND PARENCHYMAL ENHANCEMENT (BPE)

1. BPE LEVEL

   d. Marked

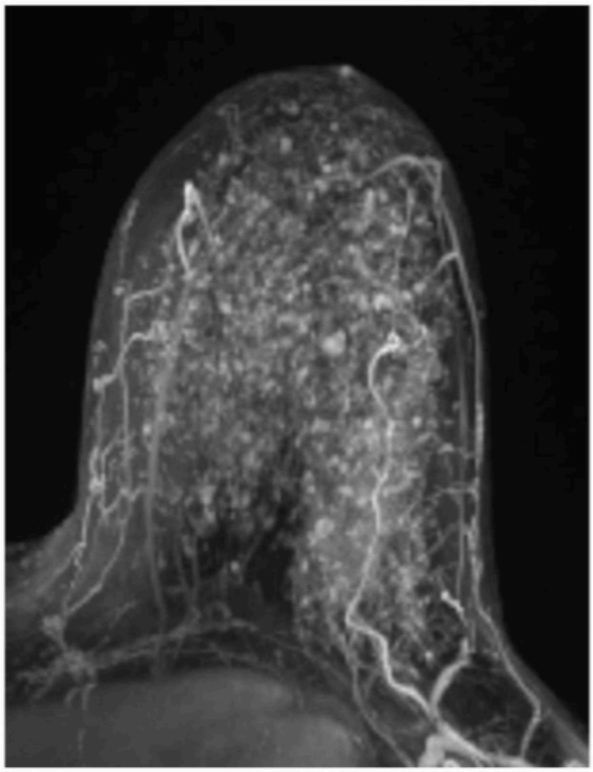

Figure 4 – BACKGROUND PARENCHYMAL ENHANCEMENT: MARKED. Early post-contrast T1W maximum intensity projection image.

B. BACKGROUND PARENCHYMAL ENHANCEMENT (BPE)

2. SYMMETRY

   a. Symmetric

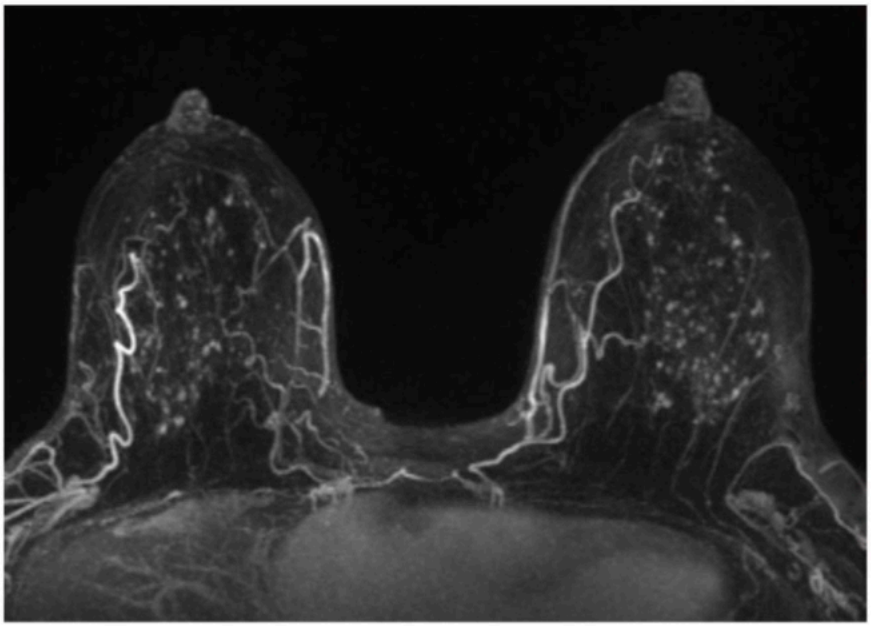

Figure 1 – BACKGROUND PARENCHYMAL ENHANCEMENT: SYMMETRIC. Moderate, SYMMETRIC BPE. Early post-contrast T1W maximum intensity projection image.

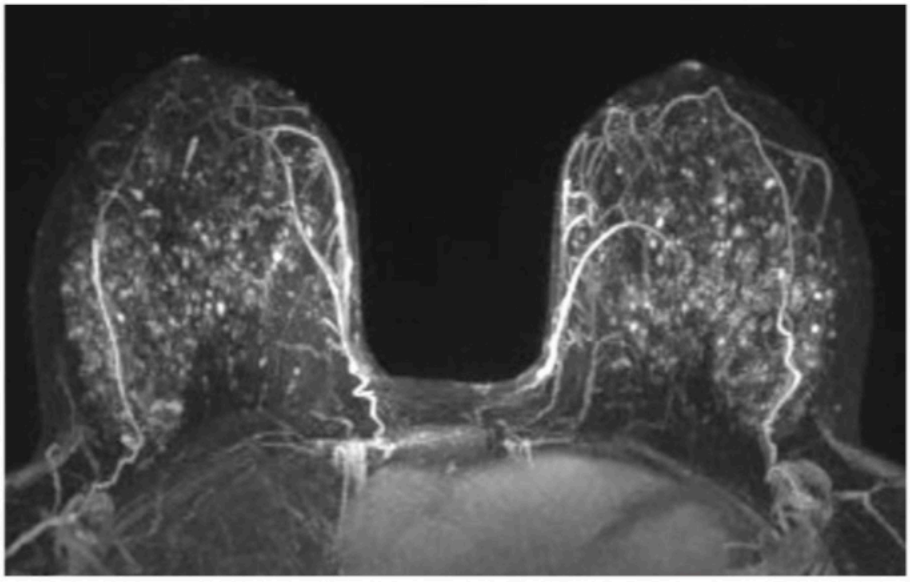

Figure 2 – BACKGROUND PARENCHYMAL ENHANCEMENT: SYMMETRIC. Marked, SYMMETRIC BPE. Early post-contrast T1W maximum intensity projection image.

B. BACKGROUND PARENCHYMAL ENHANCEMENT (BPE)

2. SYMMETRY

   b. Asymmetric

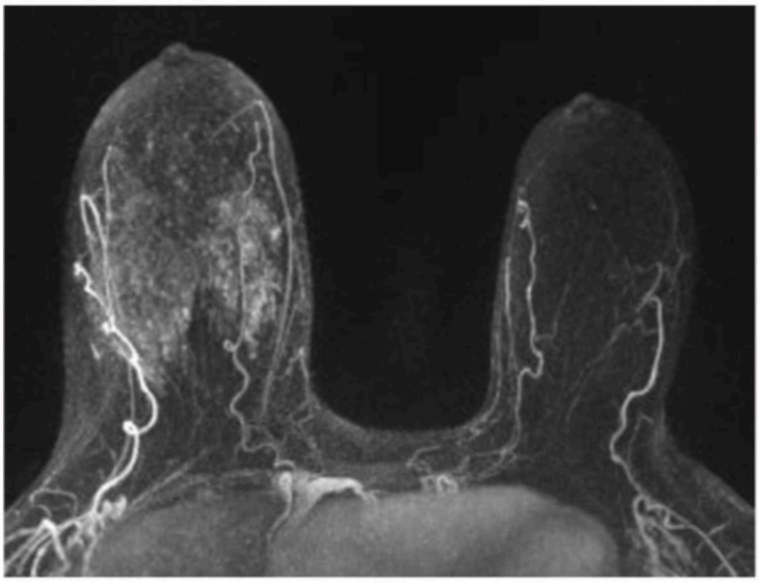

Figure 3 – BACKGROUND PARENCHYMAL ENHANCEMENT: ASYMMETRIC (moderate on the right; minimal on the left). Early post-contrast T1W maximum intensity projection image. History of left breast partial mastectomy and radiation therapy.

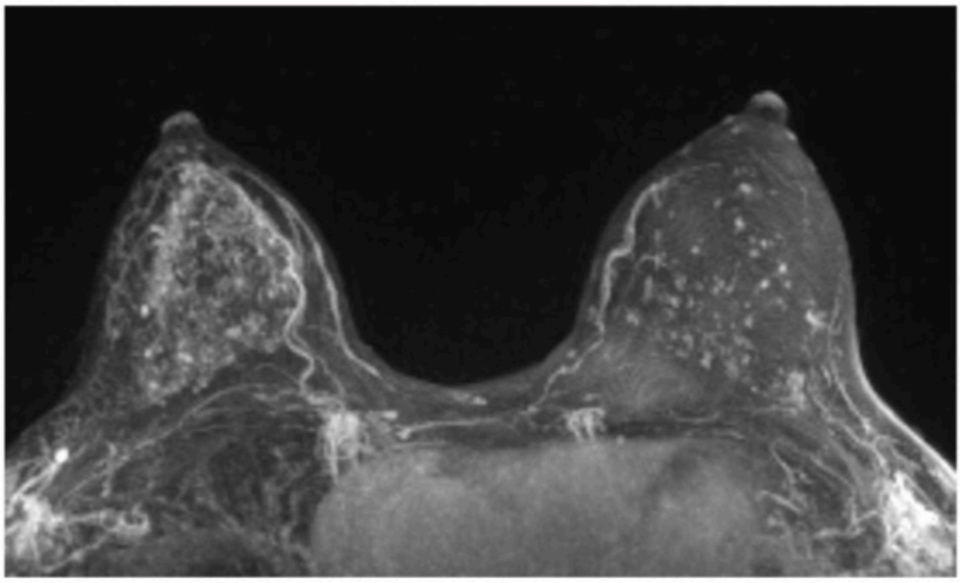

Figure 4 – BACKGROUND PARENCHYMAL ENHANCEMENT: ASYMMETRIC (marked on the right; mild on the left). Early post-contrast T1W maximum intensity projection image.

MRI FINDINGS OVERVIEW

There are two primary enhancing breast MRI finding types, masses and non-mass enhancement. To be deemed significant, enhancing findings should be morphologically unique and distinct from BPE.

The term focus has been removed from the lexicon for multiple reasons. Most small dots of enhancement are benign and should appropriately be dismissed as benign. Further, for a truly unique enhancing finding ≤ 5 mm in size, modern MRI techniques typically allow characterization as a small mass (meets criteria/features of a mass) or focal NME (does not meet criteria/features of a mass). There has also been inconsistent understanding and use of the term focus in clinical practice and in the literature. Future research should investigate the predictive morphologic and kinetic features of such small masses and NME, optimally in multi-site prospective studies.

C. MASSES

A mass is a 3-dimensional, space-occupying structure with a defined shape and convex-outward contour.

Enhancing masses are characterized morphologically by shape, margin, and internal enhancement pattern after administration of contrast. These enhancement features should be assessed on the early post-contrast series. For some masses, signal intensity on T2-weighted sequences may also be useful. Enhancement kinetics may also help characterize MRI masses for which the morphology is not definitively benign or suspicious.

Not all mass features must be used in describing a mass. In general, the description of a mass should include at least shape and margin. When they influence assessment, internal enhancement and/or T2 signal intensity and/or kinetics should also be described.

Of MRI features, the following are more frequently associated with benign outcomes, but malignancies can also have these features, and combinations of features must be considered.

- Oval shape
- Circumscribed margin
- Homogeneous internal enhancement
- T2 hyperintensity, if also oval and circumscribed and with homogeneous internal enhancement or dark internal septations. Based on the existing data and expert practice, a mass with all of these features has a likelihood of cancer ≤ 2% [4]

C. MASSES

1. SHAPE

   a. Oval

   A mass that is elliptical or egg-shaped with one axis longer than the other two and no undulations.

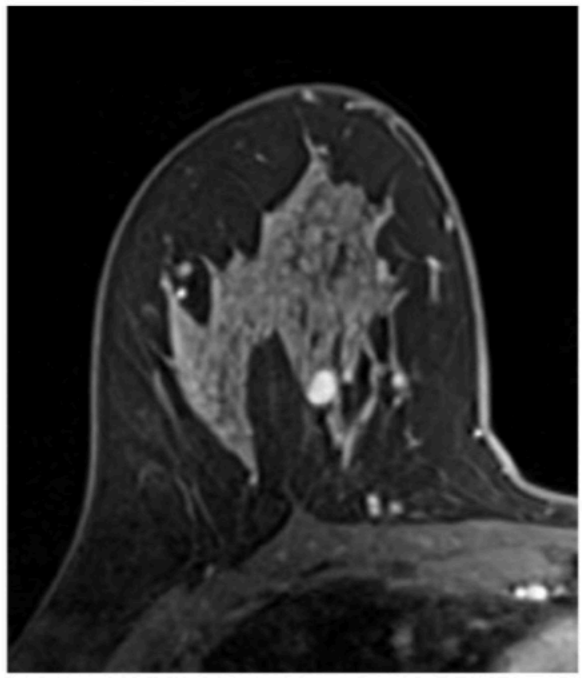

Figure 1 – OVAL, circumscribed, homogeneous mass. Fat-suppressed early post-contrast T1W image. Etiology: Long-term stability, benign.

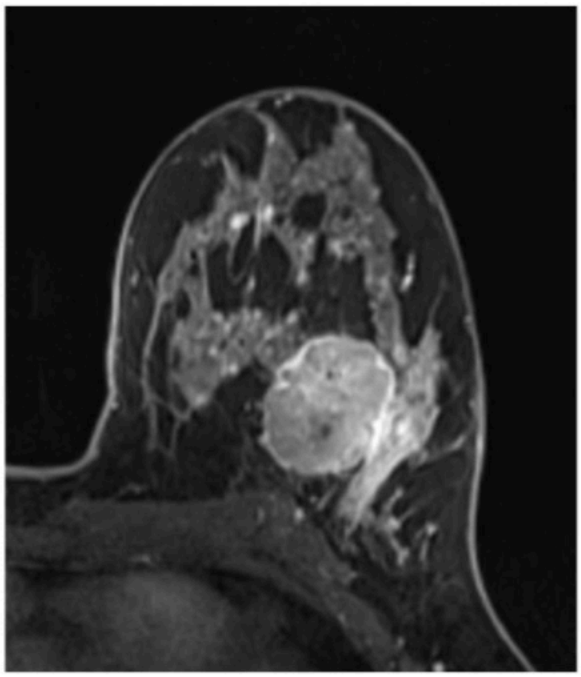

Figure 2 – OVAL, indistinct, heterogeneous mass. Fat-suppressed early post-contrast T1W image. Pathology: Invasive ductal carcinoma.

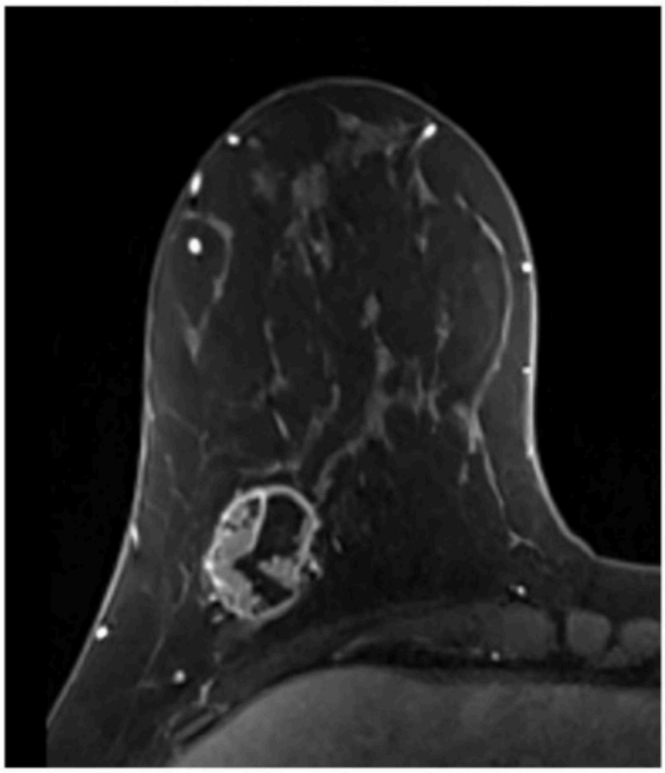

Figure 3 – OVAL, indistinct, heterogeneous mass. Fat-suppressed early post-contrast T1W image. Pathology: Invasive ductal carcinoma.

C. MASSES

1. SHAPE

   b. Lobulated

   A lobulated mass displays one or more indentations resulting in an undulating contour. In the prior Atlas, a mass with a few gentle lobulations was included in the oval shape category.

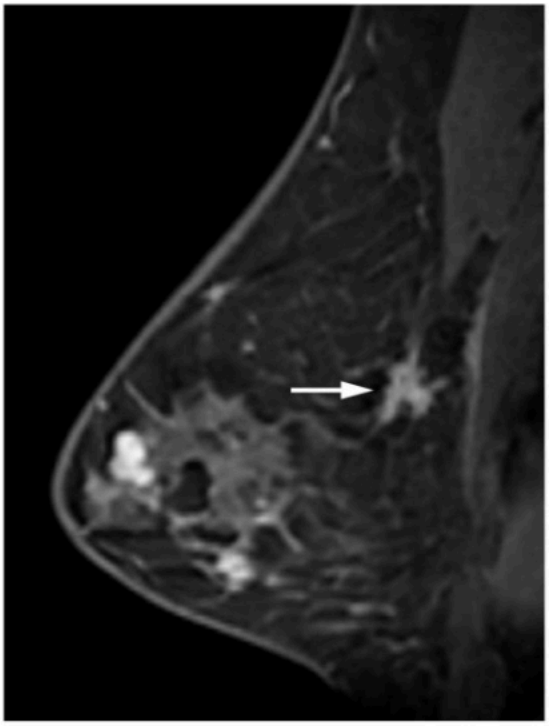

Figure 1 – LOBULATED, circumscribed, heterogeneous mass. Fat-suppressed early post-contrast T1W image. Pathology: Fibroadenoma. (Also note invasive ductal carcinoma in the upper posterior breast denoted by an arrow.)

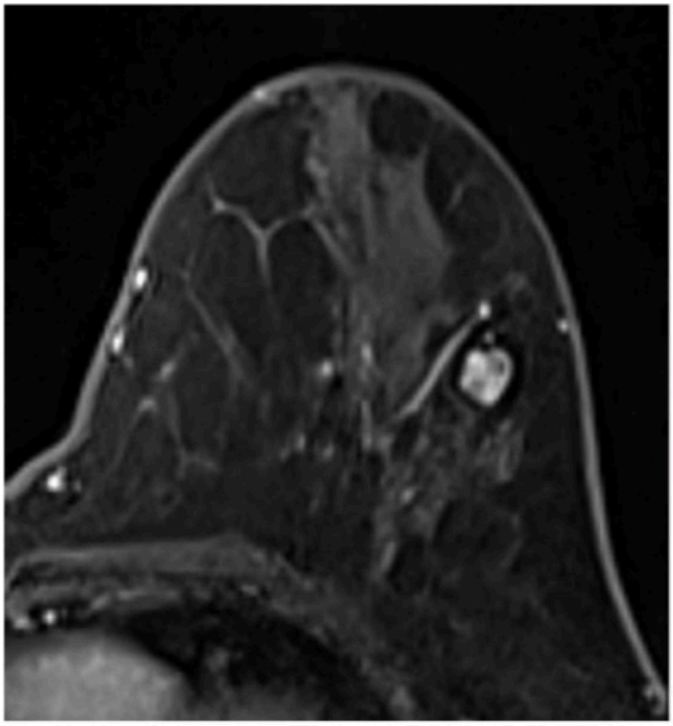

Figure 2 – LOBULATED, circumscribed, heterogeneous mass. Fat-suppressed early post-contrast T1W image. Pathology: Fibroadenoma.

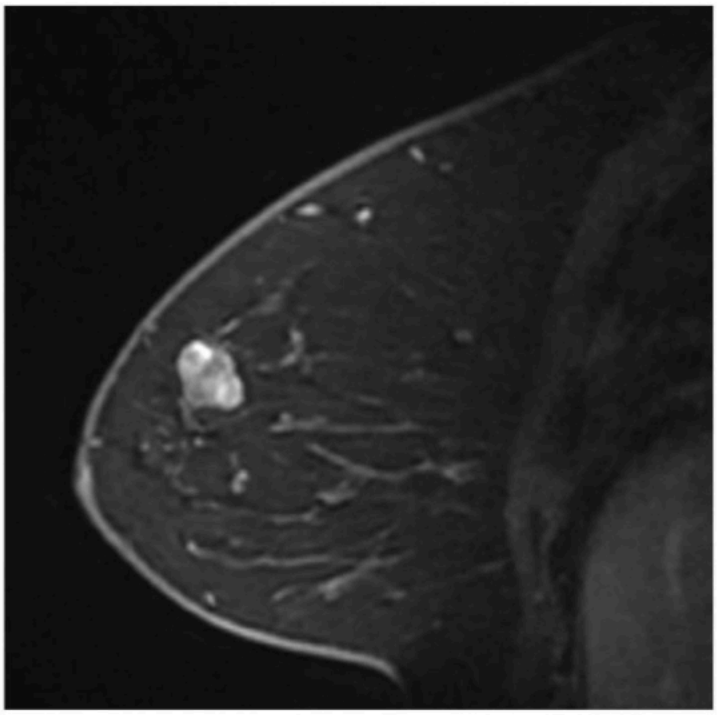

Figure 3 – LOBULATED, circumscribed, heterogeneous mass. Fat-suppressed early post-contrast T1W image. Pathology: Fibroadenoma.

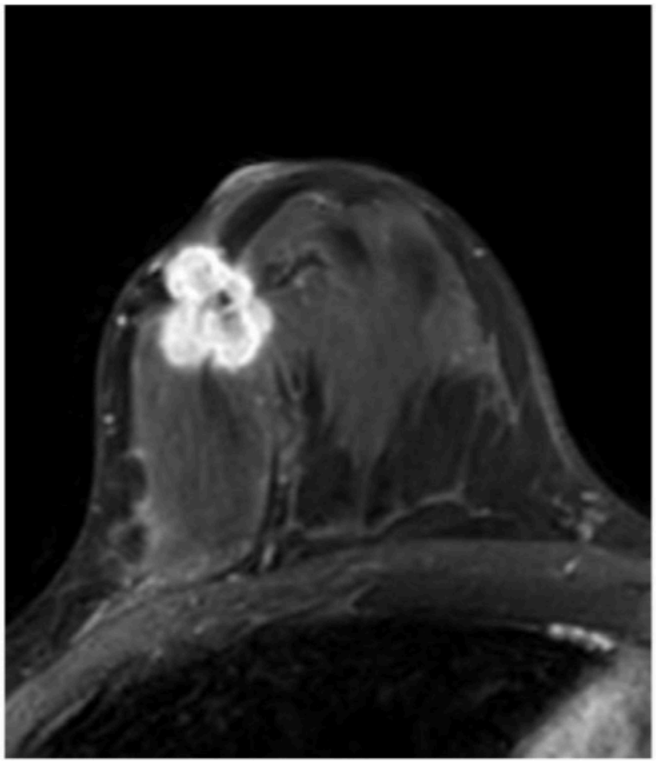

Figure 4 – LOBULATED, indistinct, heterogeneous mass. Fat-suppressed early post-contrast T1W image. Pathology: Invasive ductal carcinoma.

C. MASSES

1. SHAPE

   c. Round

   A mass that is spherical or ball-shaped, similar in diameter in all three axes.

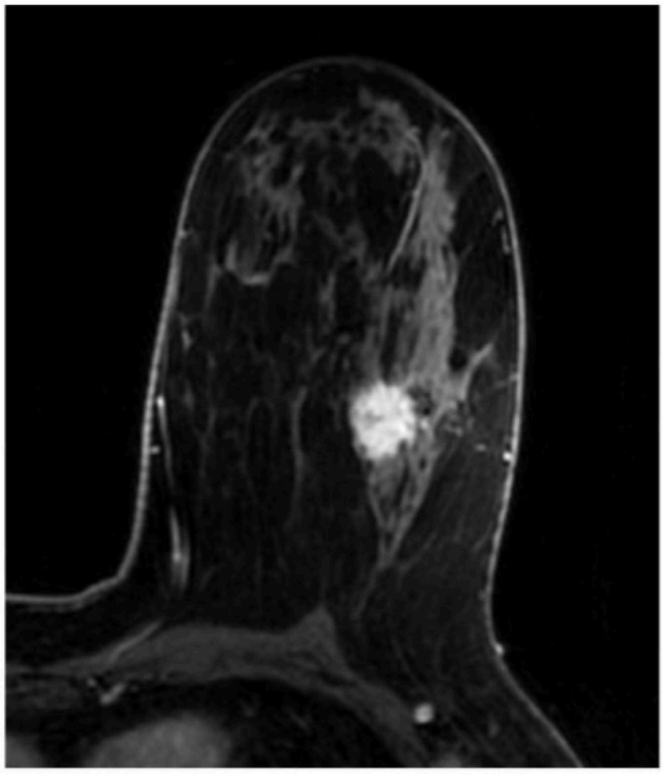

Figure 1 – ROUND, indistinct, heterogeneous mass. Fat-suppressed early post-contrast T1W image. Pathology: Invasive ductal carcinoma.

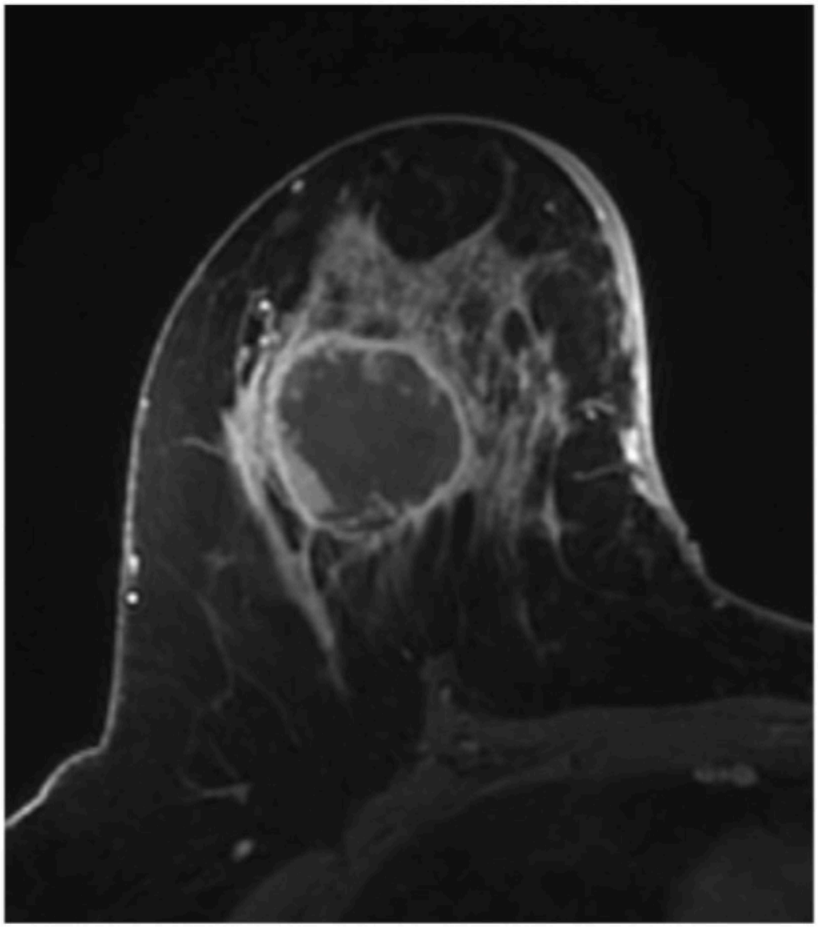

Figure 2 – ROUND, indistinct, thick rim enhancing mass. Fat-suppressed early post-contrast T1W image. Pathology: Invasive ductal carcinoma.

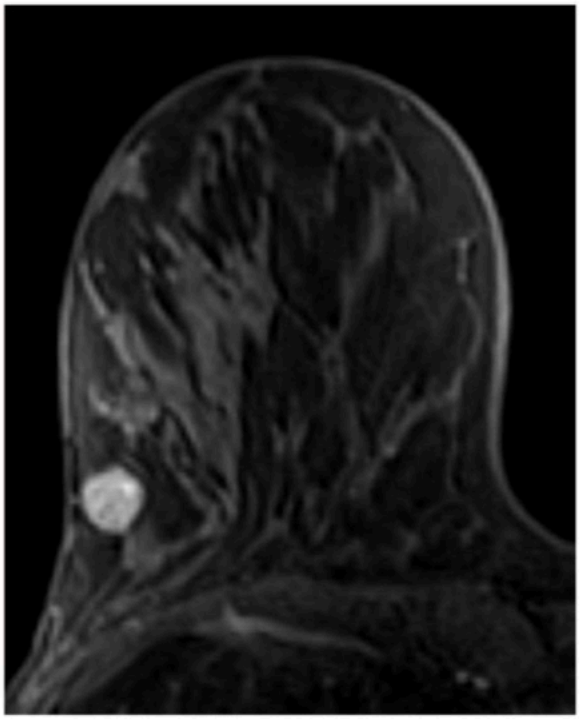

Figure 3 – ROUND, circumscribed, heterogeneous mass. Fat-suppressed early post-contrast T1W image. Pathology: Fibroadenoma.

C. MASSES

1. SHAPE

   d. Irregular

   A mass that is neither oval, lobulated, nor round is irregular in shape. It has acute angle protruding portions. Irregular shape often implies a suspicious finding.

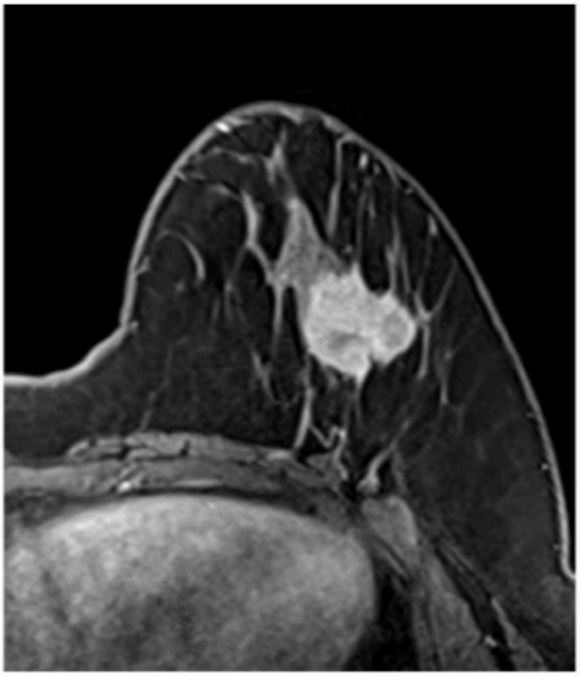

Figure 1 – IRREGULAR, spiculated, heterogeneous mass. Fat-suppressed early post-contrast T1W image. Pathology: Invasive ductal carcinoma.

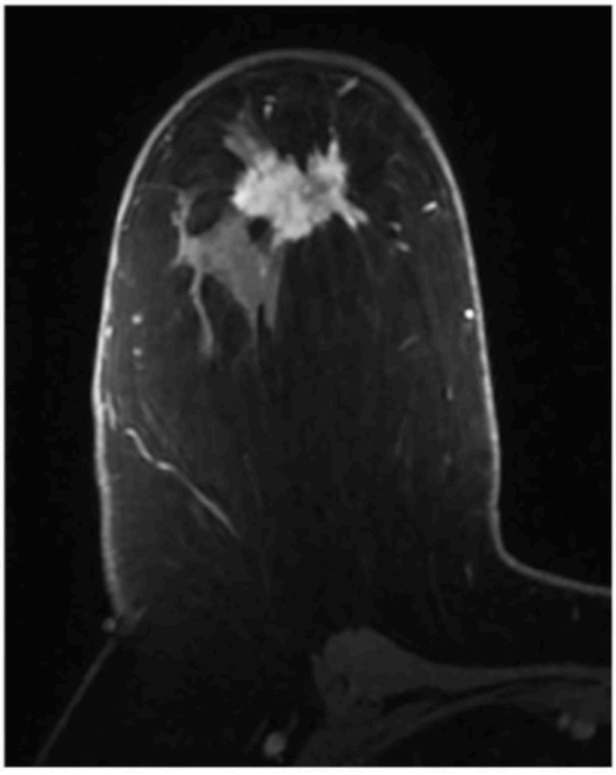

Figure 2 – IRREGULAR, spiculated, heterogeneous mass. Fat-suppressed early post-contrast T1W image. Pathology: Invasive ductal carcinoma.

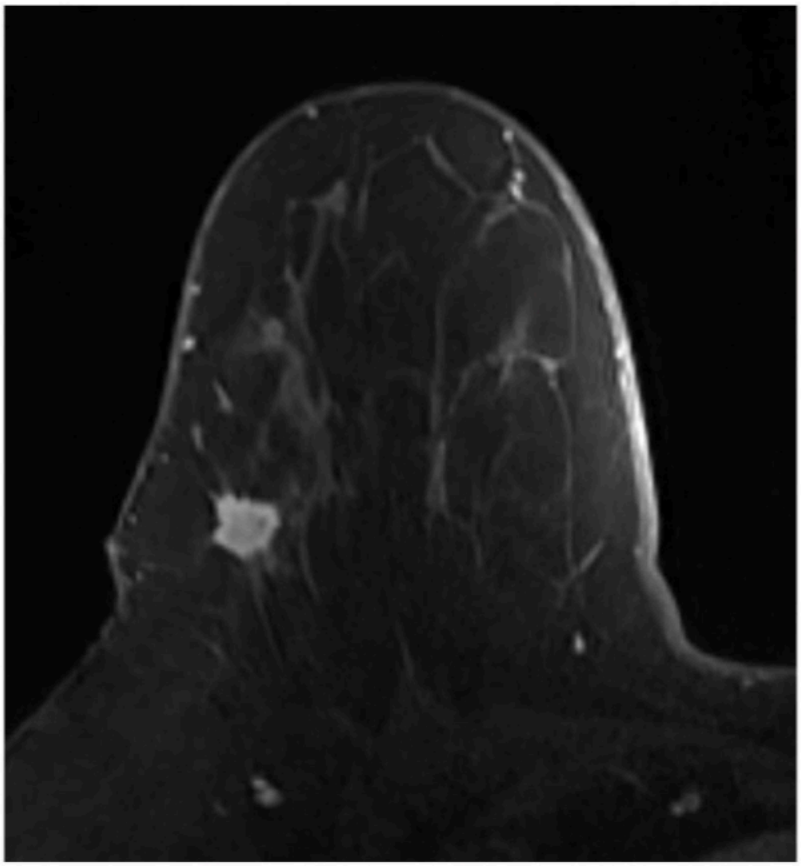

Figure 3 – IRREGULAR, spiculated, heterogeneous mass. Fat-suppressed early post-contrast T1W image. Pathology: Invasive ductal carcinoma.

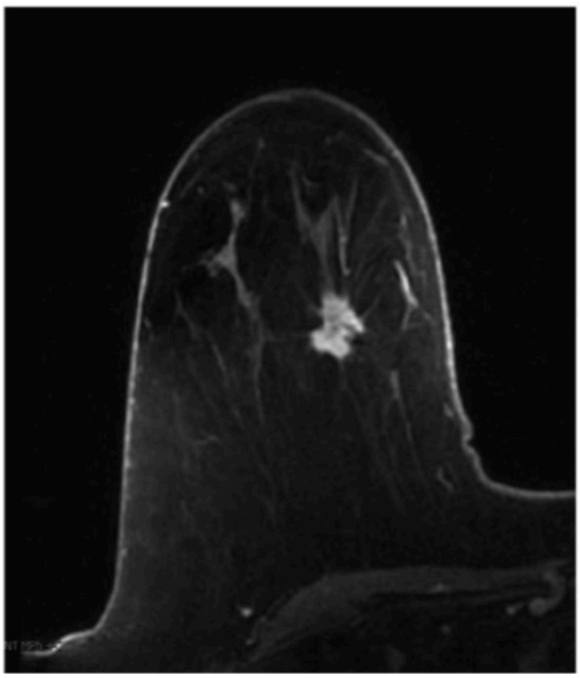

Figure 4 – IRREGULAR, spiculated, heterogeneous mass. Fat-suppressed early post-contrast T1W image. Pathology: Invasive ductal carcinoma.

C. MASSES

2. MARGIN

The margin is the edge or border of the lesion relative to the surrounding breast tissue. The margin may be circumscribed or non-circumscribed. Non-circumscribed is further categorized as indistinct (historically irregular) or spiculated.

a. Circumscribed

The margin is smooth and sharply demarcated with an abrupt transition between the lesion and the surrounding tissue. The entire margin must be well defined for a mass margin to be described as circumscribed on MRI, unlike mammography. A mass for which any portion of the margin is non-circumscribed should be classified using the more suspicious margin descriptor.

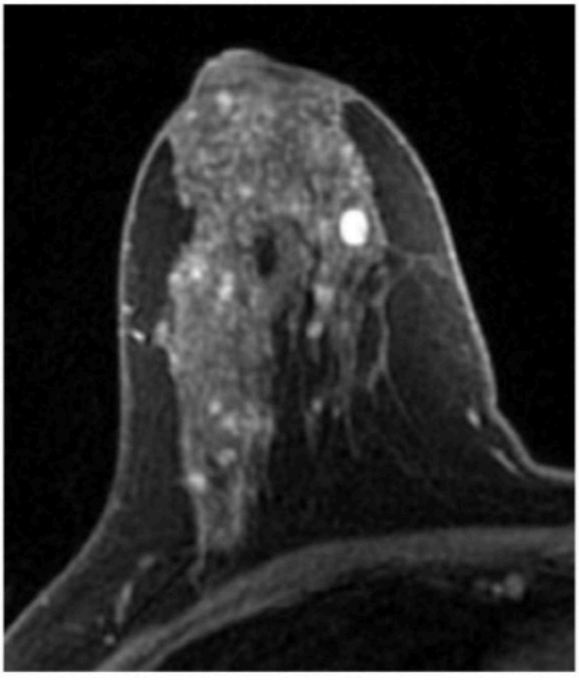

Figure 1 – Oval, CIRCUMSCRIBED, homogeneous mass. Fat-suppressed early post-contrast T1W image. Pathology: Fibroadenoma.

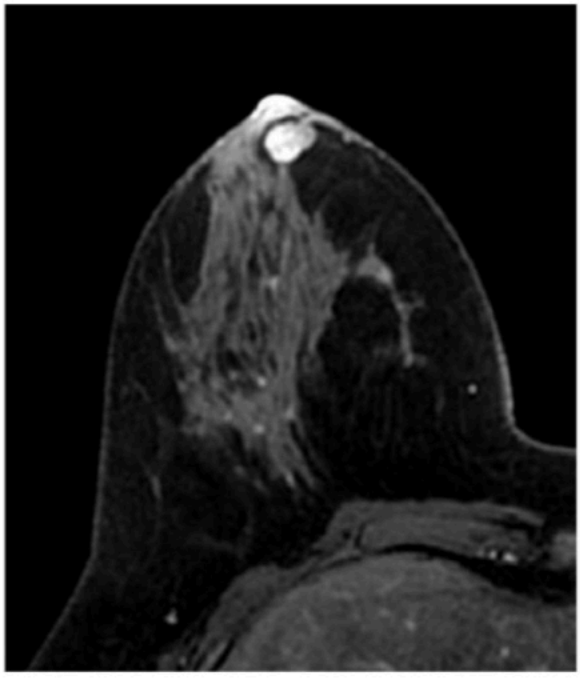

Figure 2 – Oval, CIRCUMSCRIBED, heterogeneous mass. Fat-suppressed early post-contrast T1W image. Etiology: Long-term stability, benign.

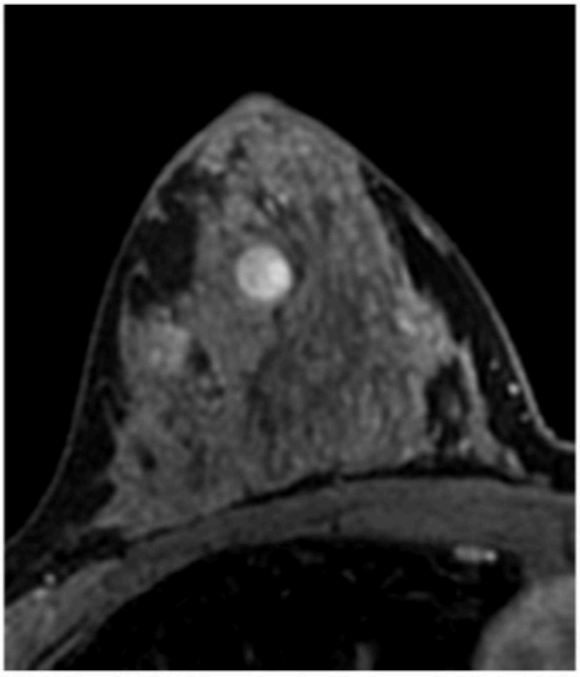

Figure 3 – Round, CIRCUMSCRIBED, heterogeneous mass. Fat-suppressed early post-contrast T1W image. Pathology: Fibroadenoma.

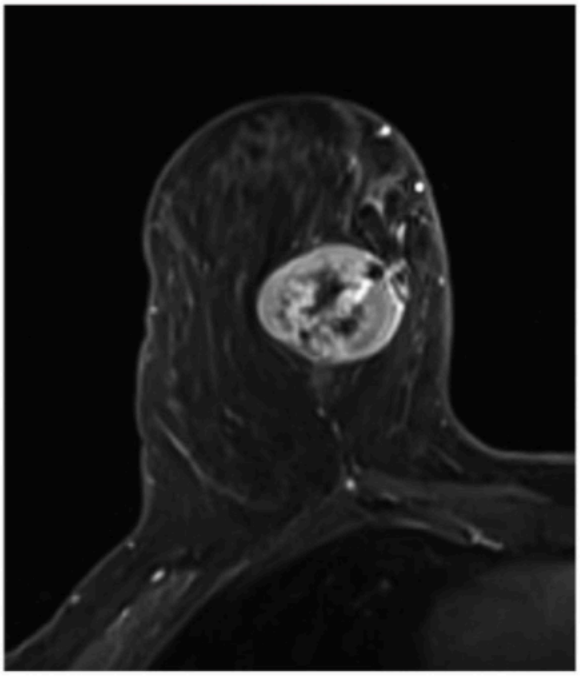

Figure 4 – Oval, CIRCUMSCRIBED, heterogeneous mass. Fat-suppressed early post-contrast T1W image. Pathology: Invasive ductal carcinoma.

C. MASSES

2. MARGIN

b. Non-circumscribed

i. Indistinct (historically irregular).

The margin is composed of edges that are uneven but not spiculated. The term irregular was replaced by indistinct as a margin descriptor in this Manual to avoid duplication with the term irregular as a shape descriptor and to harmonize with margin descriptors for the other modalities.

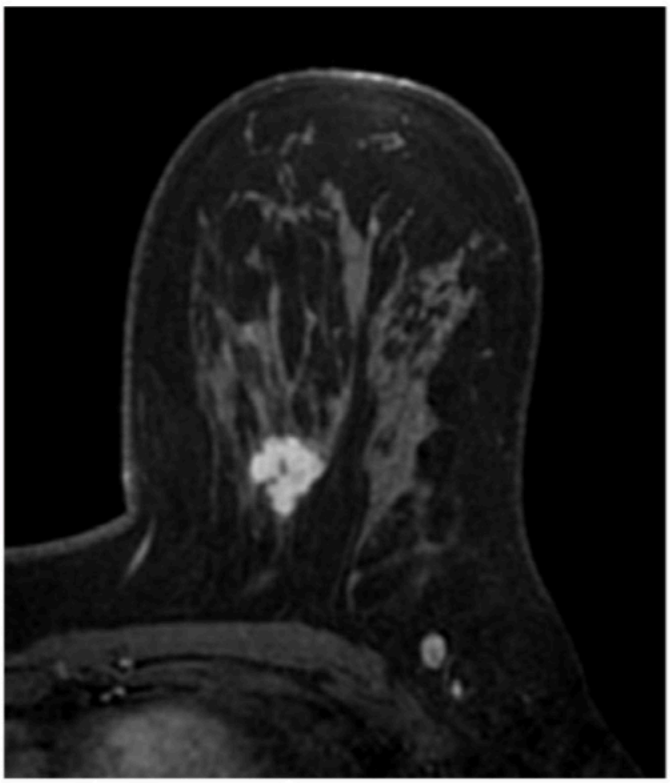

Figure 1 – Irregular, INDISTINCT, heterogeneous mass. Early post-contrast T1W subtracted image. Pathology: Invasive ductal carcinoma.

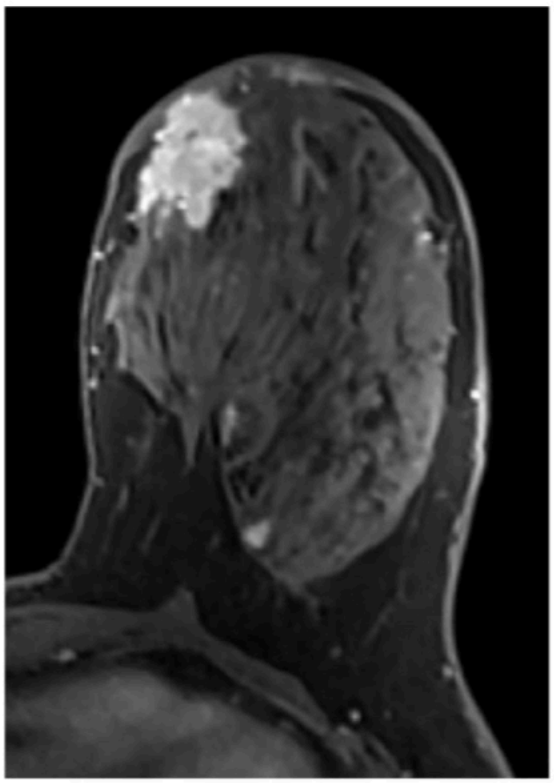

Figure 2 – Irregular, INDISTINCT, heterogeneous mass. Fat-suppressed early post-contrast T1W image. Pathology: Invasive ductal carcinoma.

C. MASSES

2. MARGIN

b. Non-circumscribed

ii. Spiculated

The margin is characterized by lines radiating from the mass. This mass margin is the most suspicious for malignancy.

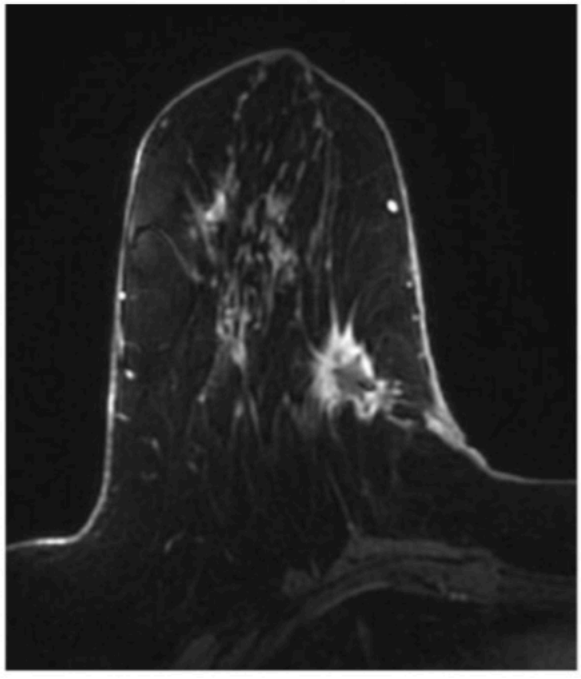

Figure 1 – Irregular, SPICULATED, thick rim enhancing mass. Fat-suppressed early post-contrast T1W image. Pathology: Invasive lobular carcinoma.

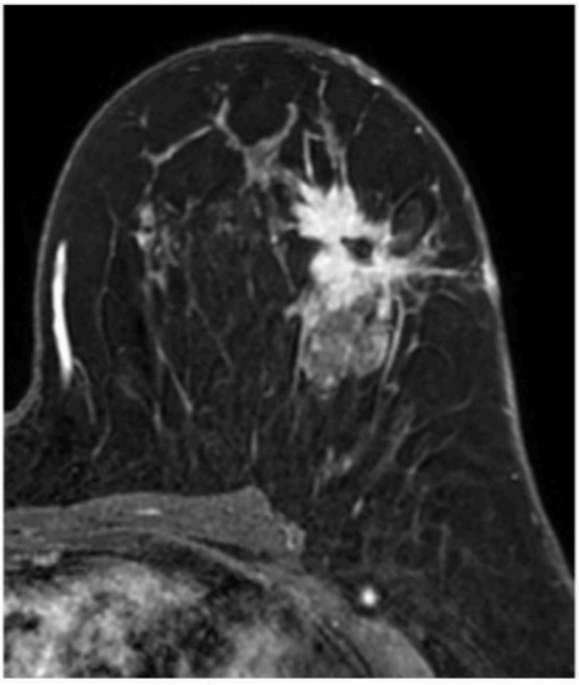

Figure 2 – Irregular, SPICULATED, heterogeneous mass. Fat-suppressed early post-contrast T1W image. Pathology: Invasive ductal carcinoma.

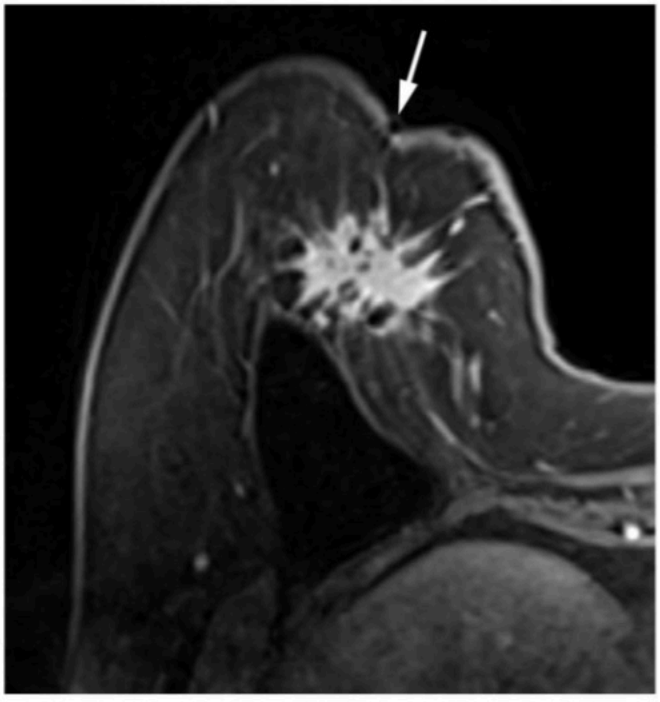

Figure 3 – Irregular, SPICULATED, heterogeneous mass. Associated skin retraction (arrow). The patient also has a breast implant. Fat-suppressed early post-contrast T1W image. Pathology: Invasive ductal carcinoma.

C. MASSES

3. INTERNAL ENHANCEMENT PATTERN

Internal enhancement describes the visualized enhancement pattern within the mass.

a. Homogeneous

There is confluent uniform enhancement of the mass.

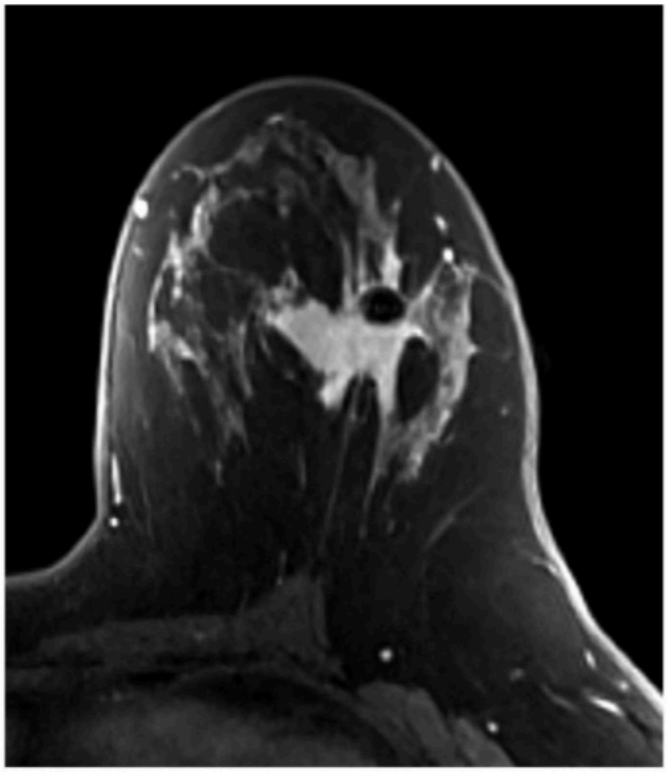

Figure 1 – Irregular, spiculated, HOMOGENEOUS mass. Fat-suppressed early post-contrast T1W image. Pathology: Invasive ductal carcinoma.

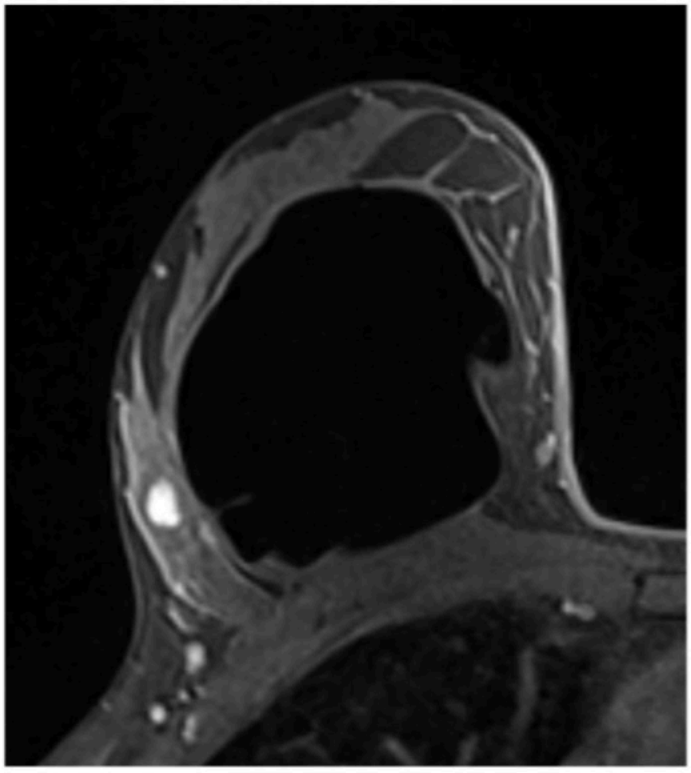

Figure 2 – Lobulated, circumscribed, HOMOGENEOUS mass. Fat-suppressed early post-contrast T1W image. Pathology: Fibroadenoma.

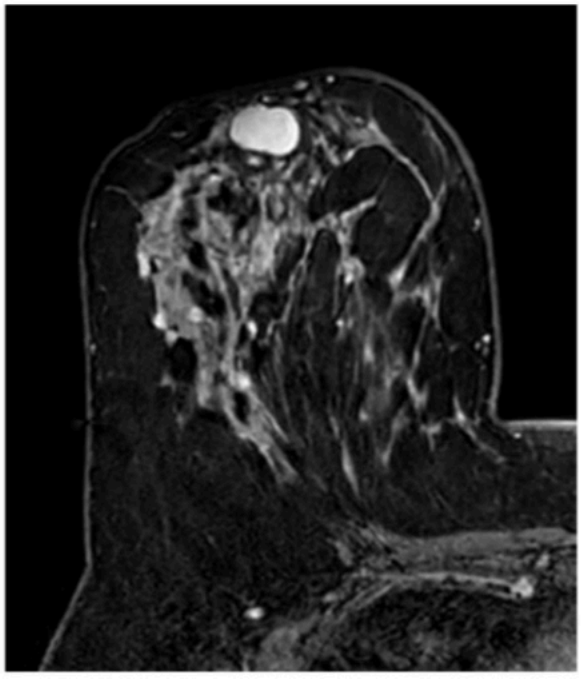

Figure 3 – Lobulated, circumscribed, HOMOGENEOUS mass. Fat-suppressed early post-contrast T1W image. Pathology: Fibroadenoma.

C. MASSES

3. INTERNAL ENHANCEMENT CHARACTERISTICS

b. Dark Internal Septations

There are dark non-enhancing lines within the mass. Dark internal septations are suggestive of a fibroadenoma, but only if the other morphologic features of shape and margin support this etiology.

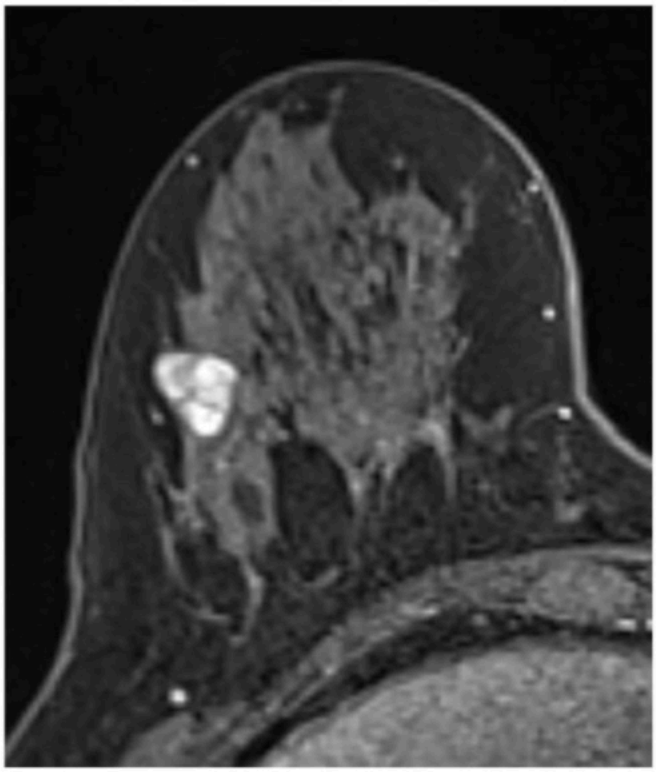

Figure 1 – Lobulated, circumscribed mass with DARK INTERNAL SEPTATIONS. Fat-suppressed early post-contrast T1W image. Pathology: Fibroadenoma.

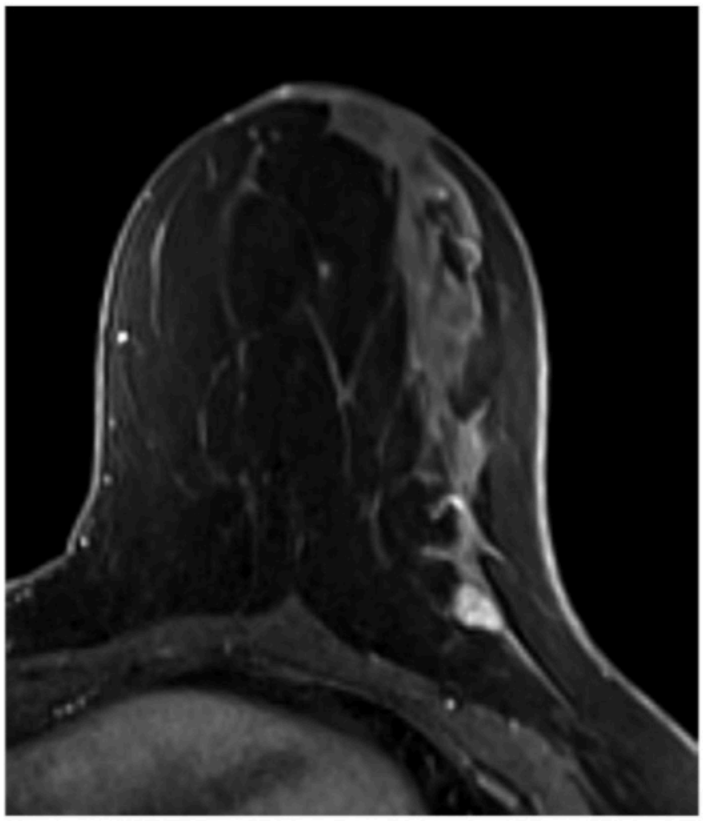

Figure 2 – Oval, circumscribed mass with DARK INTERNAL SEPTATIONS. Fat-suppressed early post-contrast T1W image. Etiology: Long-term stability, benign.

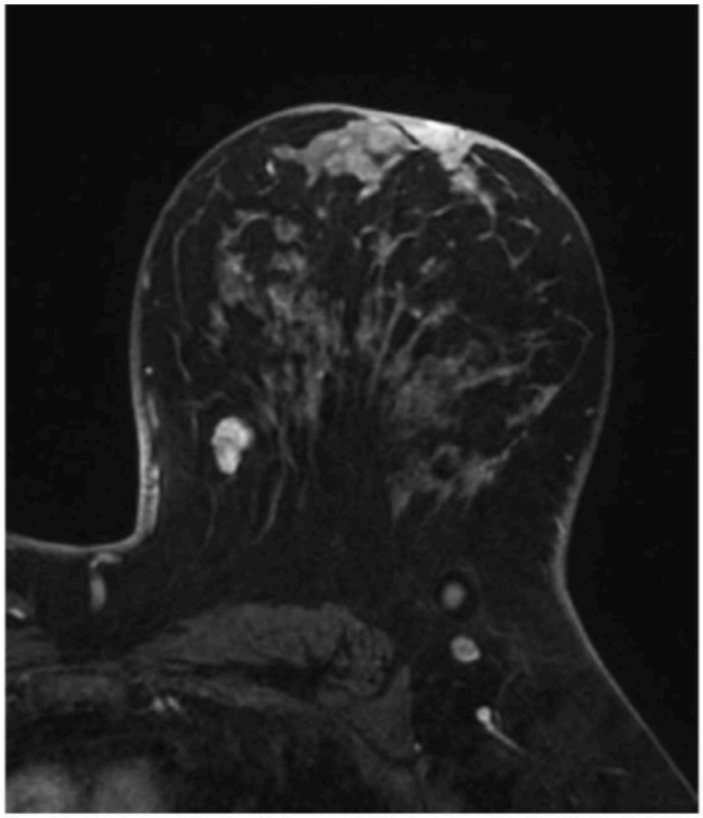

Figure 3 – Lobulated, circumscribed mass with DARK INTERNAL SEPTATIONS. Fat-suppressed early post-contrast T1W image. Pathology: Fibroadenoma.

C. MASSES

3. INTERNAL ENHANCEMENT CHARACTERISTICS

c. Heterogeneous

There is varied, non-uniform enhancement within the mass.

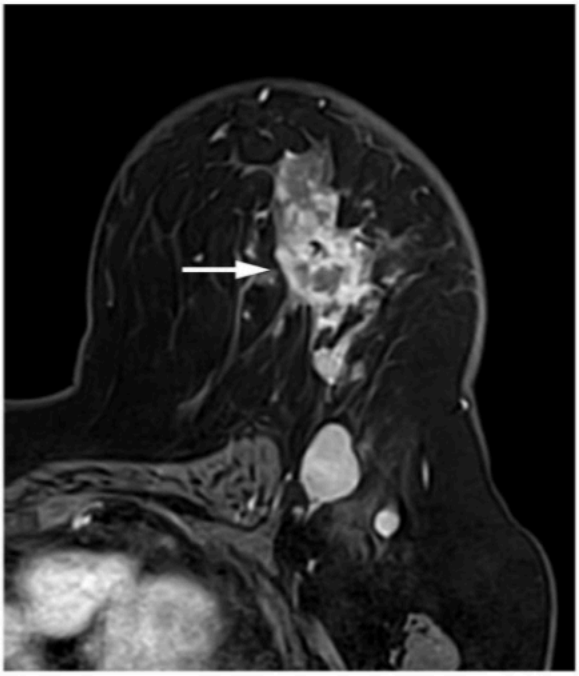

Figure 1 – Irregular, indistinct, HETEROGENEOUS mass (arrow). Fat-suppressed early post-contrast T1W image. Note also the abnormal level I axillary lymph node posteriorly consistent with metastatic disease. Pathology: Invasive ductal carcinoma.

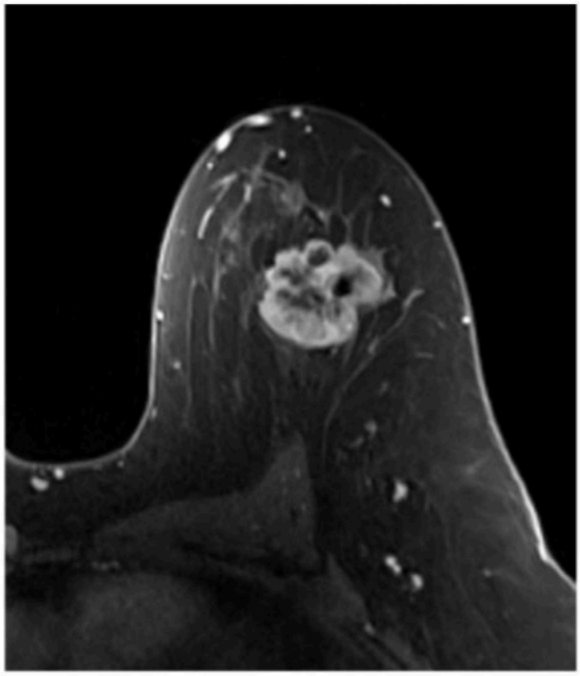

Figure 2 – Irregular, indistinct, HETEROGENEOUS mass. Fat-suppressed early post-contrast T1W image. Pathology: Invasive ductal carcinoma.

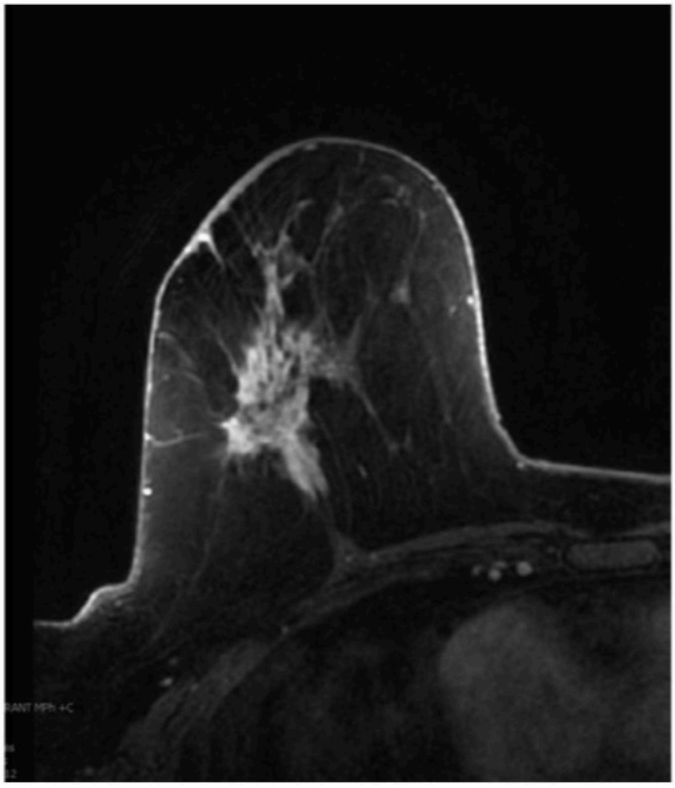

Figure 3 – Irregular, spiculated, HETEROGENEOUS mass. Fat-suppressed early post-contrast T1W image. Pathology: Invasive lobular carcinoma.

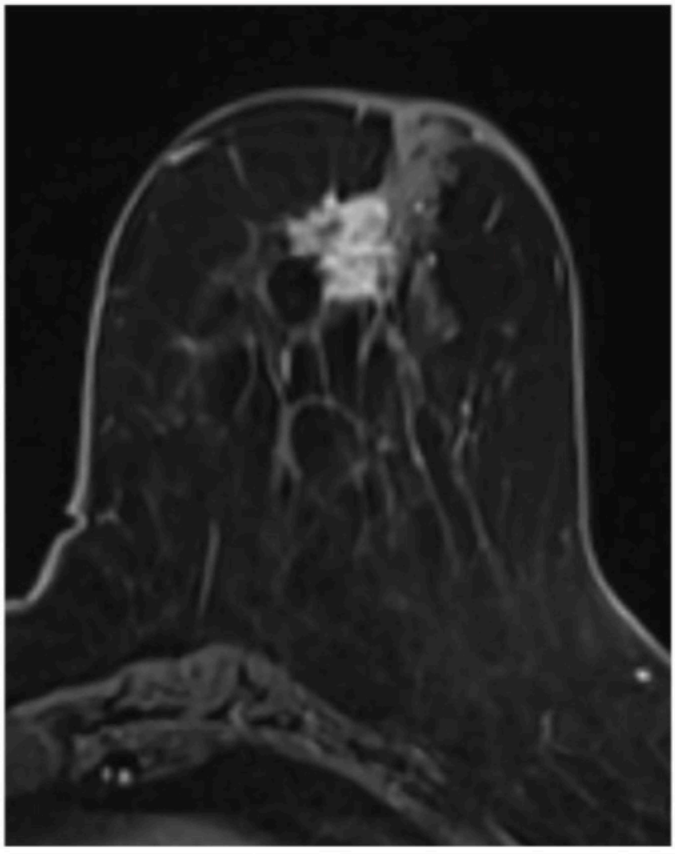

Figure 4 – Irregular, spiculated, HETEROGENEOUS mass. Fat-suppressed early post-contrast T1W image. Pathology: Invasive lobular carcinoma.

C. MASSES

3. INTERNAL ENHANCEMENT CHARACTERISTICS

d. Thick Rim Enhancement (previously called rim enhancement)

Enhancement that is thick, sometimes uneven, and more pronounced at the periphery of the mass. The addition of the term "thick" to the descriptor compared to the previous edition is to emphasize the difference in appearance of this typically suspicious type of enhancement to the benign thinner peri-cystic enhancement that can be seen with cysts. Careful evaluation of the inner contour of rim enhancement can help distinguish benign (smooth inner contour, "solar eclipse" appearance) peri-cystic enhancement from suspicious (uneven inner contour) thick rim enhancement.

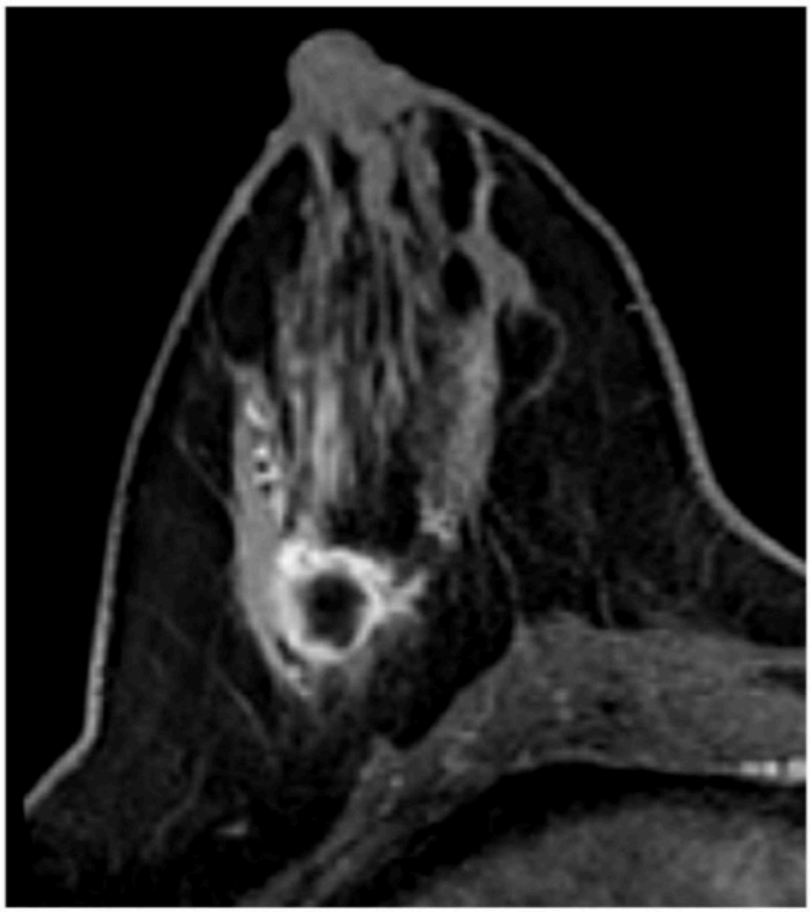

Figure 1 – Irregular, indistinct mass with THICK RIM ENHANCEMENT. Fat-suppressed early post-contrast T1W image. Pathology: Invasive ductal carcinoma.

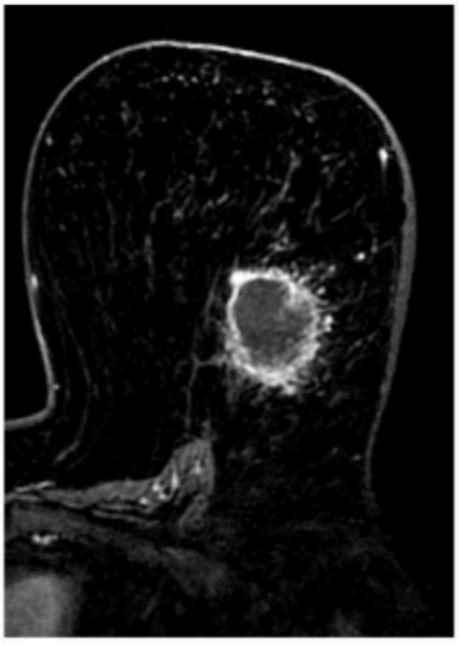

Figure 2 – Oval, indistinct mass with THICK RIM ENHANCEMENT. Fat-suppressed early post-contrast T1W image. Pathology: Invasive ductal carcinoma.

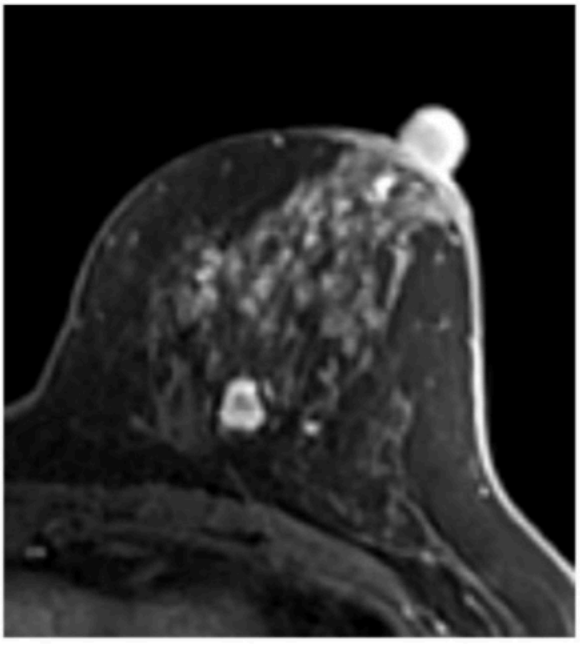

Figure 3 – Irregular, indistinct mass with THICK RIM ENHANCEMENT. Fat-suppressed early post-contrast T1W image. Pathology: Invasive ductal carcinoma.

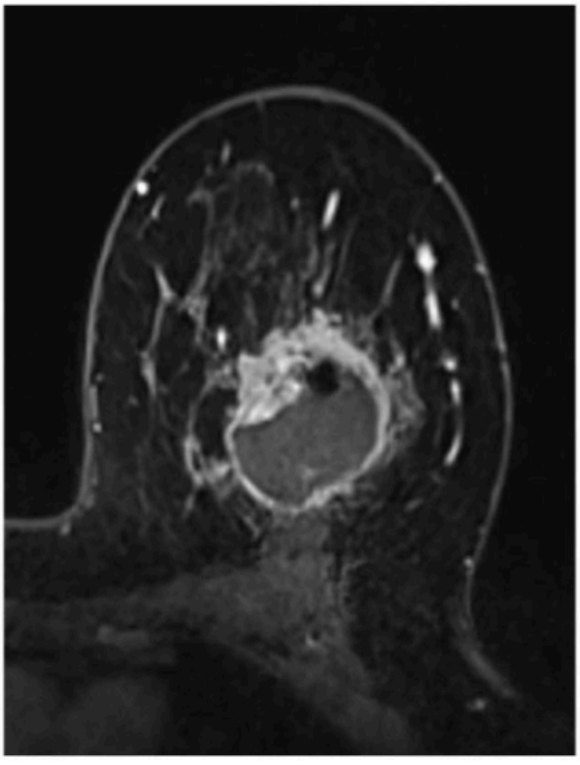

Figure 4 – Oval, indistinct mass with THICK RIM ENHANCEMENT. Fat-suppressed early post-contrast T1W image. Pathology: Invasive ductal carcinoma.

C. MASSES

4. T2 SIGNAL INTENSITY

Although both benign and malignant enhancing masses can be hyperintense on T2-weighted sequences, based on expert opinion and existing data, a T2 hyperintense mass that is also oval and circumscribed and demonstrates homogeneous internal enhancement or dark internal septations, has a low probability of malignancy of ≤ 2% [6]. Therefore, T2 signal intensity should be assessed and specifically reported when it influences assessments and recommendations, such as for the masses with the features described above. T2 signal intensity does not need to be reported for masses that are definitively benign or suspicious based on their morphology features.

T2 intensity should be categorized as hyperintense, or not hyperintense. The signal intensity should be assessed subjectively, using a normal lymph node as an internal standard.

a. Hyperintense — the mass is uniformly bright throughout and "lymph node bright," i.e. as bright as a normal-appearing axillary or intramammary lymph node.

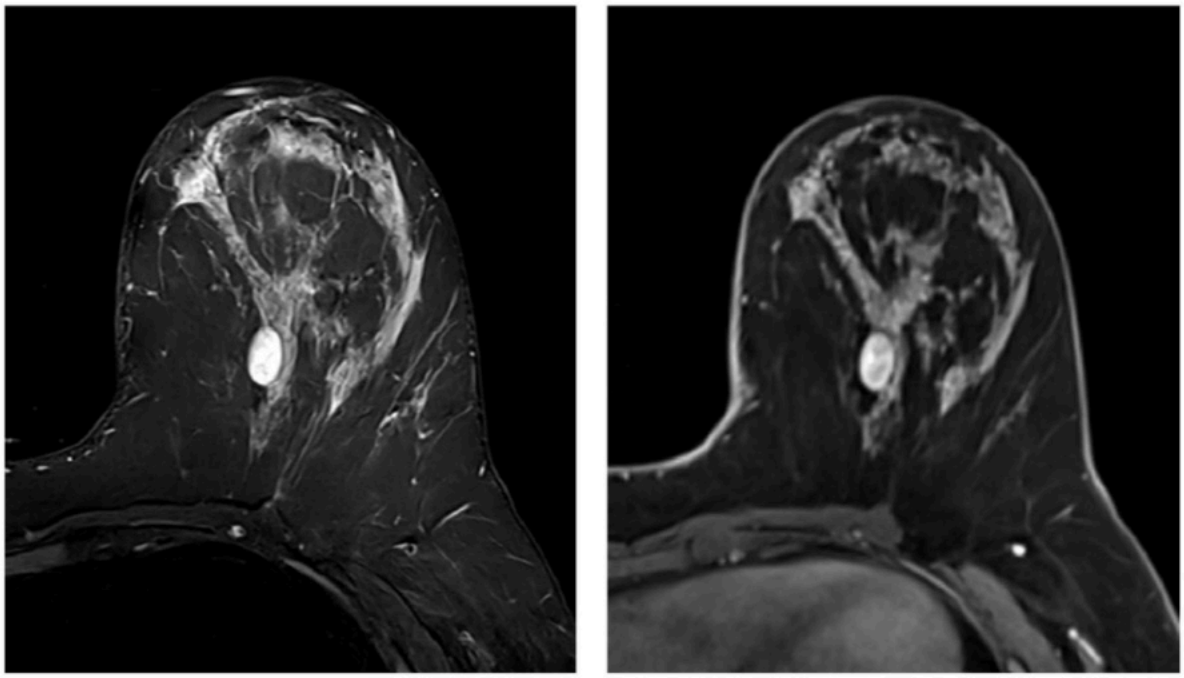

A B

Figure 1 – Oval, circumscribed heterogeneous mass with T2 SIGNAL INTENSITY HYPERINTENSE.
(A) Fat-suppressed T2W image. (B) Fat-suppressed early post-contrast T1W image. Pathology: Fibroadenoma.

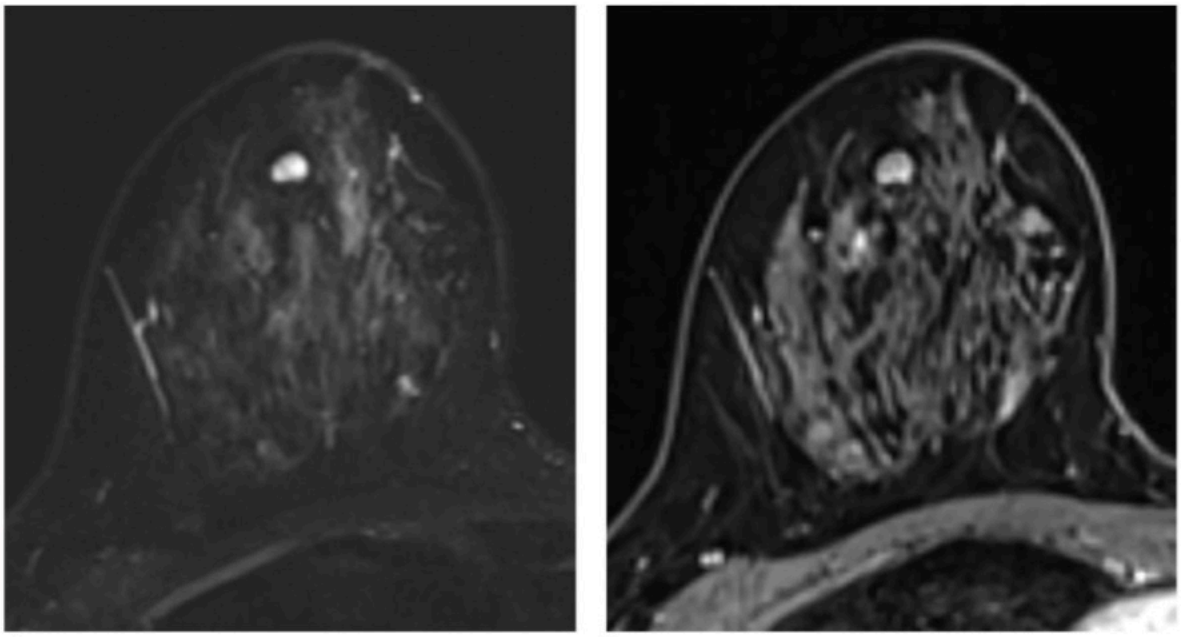

A B

Figure 2 – Oval, circumscribed heterogeneous mass with T2 SIGNAL INTENSITY HYPERINTENSE.
(A) Fat-suppressed T2W image. (B) Fat-suppressed early post-contrast T1W image. Pathology: Fibroadenoma.

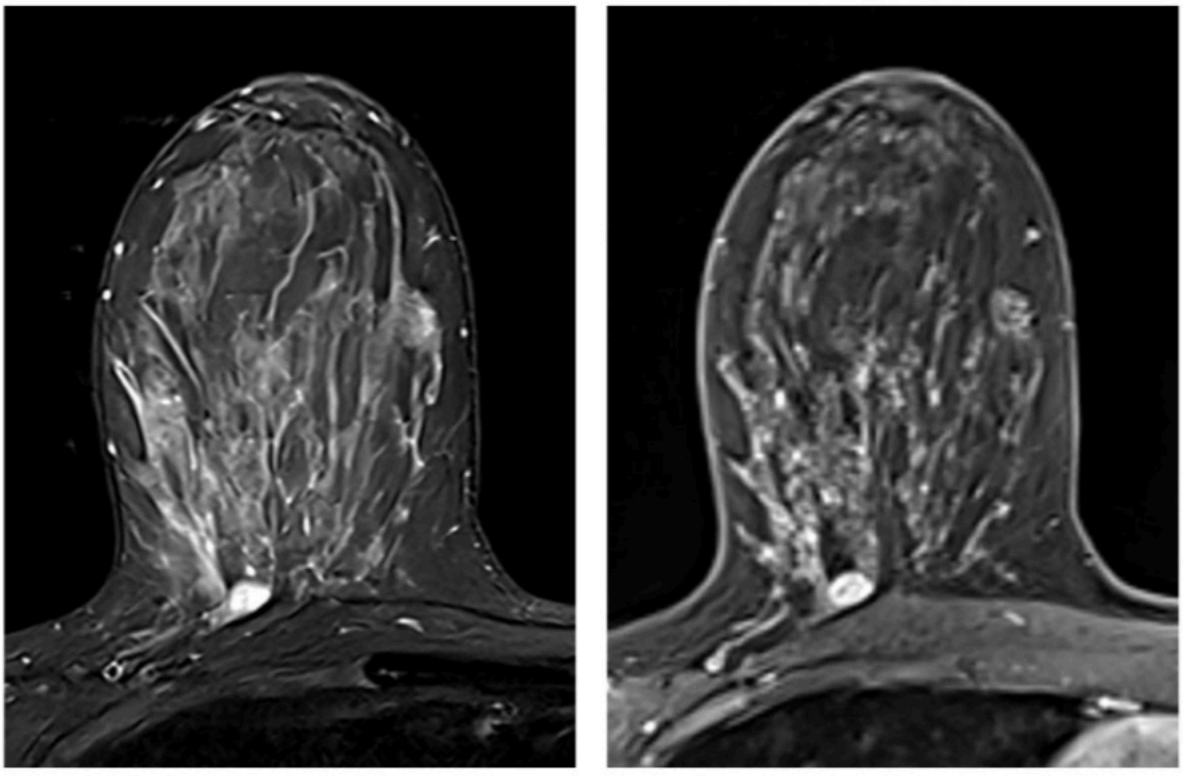

A B

Figure 3 – Oval, circumscribed heterogeneous mass with T2 SIGNAL INTENSITY HYPERINTENSE.
(A) Fat-suppressed T2W image. (B) Fat-suppressed early post-contrast T1W image. Pathology: Fibroadenoma.

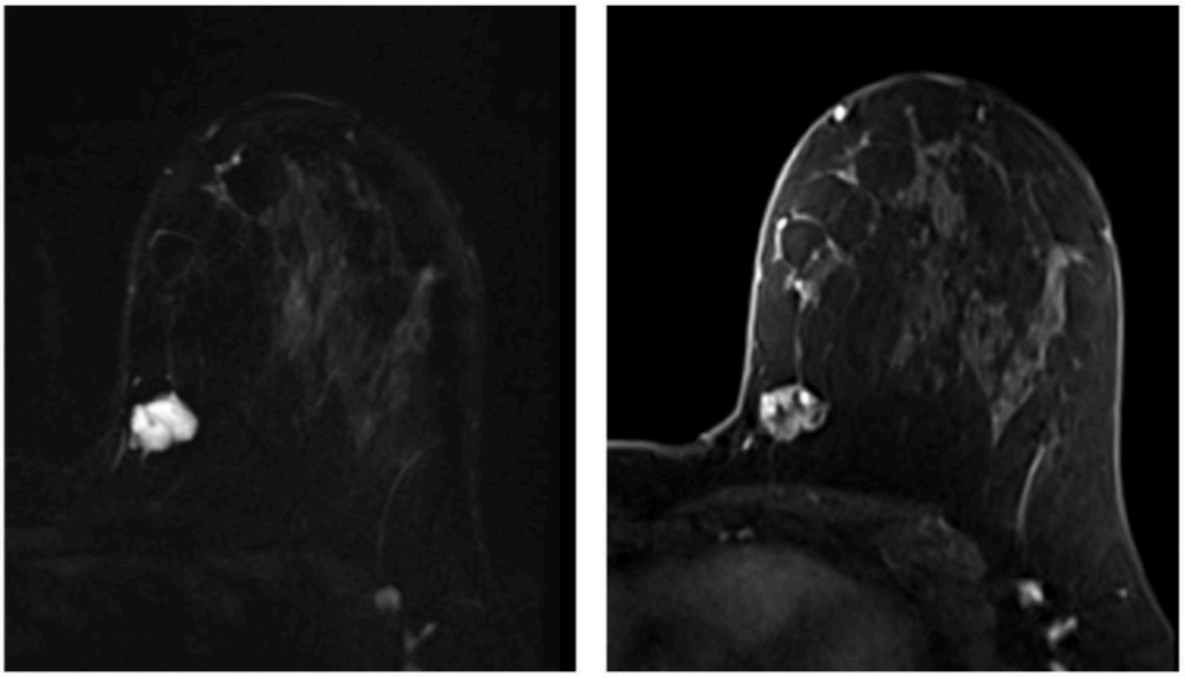

A B

Figure 4 – Lobulated, indistinct, heterogeneous mass with T2 SIGNAL INTENSITY HYPERINTENSE. (A) Fat-suppressed T2W image. (B) Fat-suppressed early post-contrast T1W image. Pathology: Mucinous carcinoma.

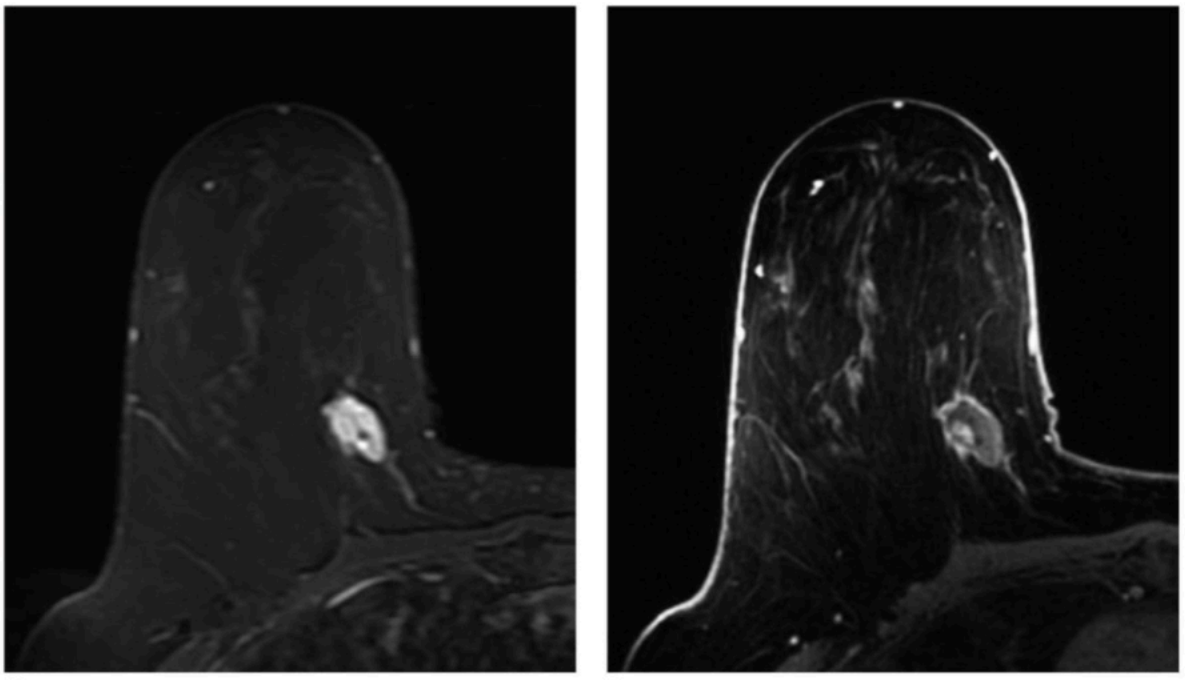

A B

Figure 5 – Oval, indistinct, heterogeneous mass with T2 SIGNAL INTENSITY HYPERINTENSE. (A) Fat-suppressed T2W image. (B) Fat-suppressed early post-contrast T1W image. Pathology: Invasive ductal carcinoma with mucinous features.

C. MASSES

4. T2 SIGNAL INTENSITY

   b. Not Hyperintense — The mass is not uniformly bright throughout nor "lymph node bright."

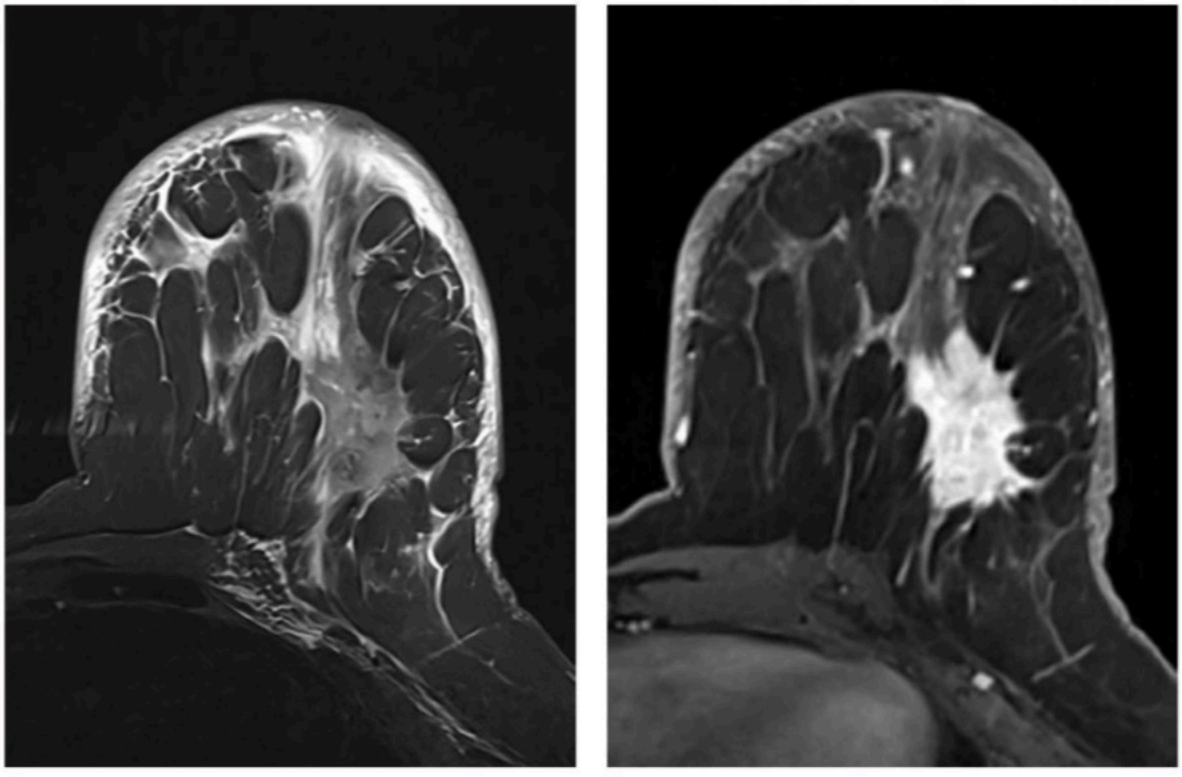

A B

Figure 1 – Irregular, spiculated, heterogeneous mass with T2 SIGNAL INTENSITY NOT HYPERINTENSE. (A) Fat-suppressed T2W image. (B) Fat-suppressed early post-contrast T1W image. Pathology: Invasive ductal carcinoma.

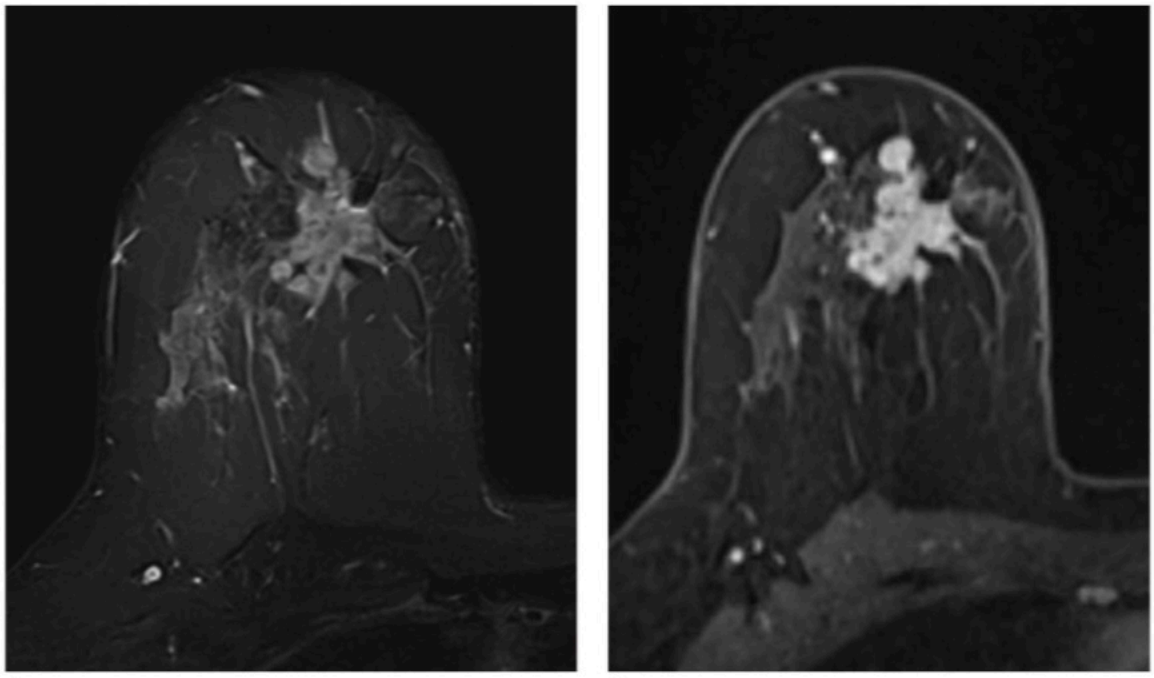

A B

Figure 2 – Irregular, indistinct, heterogeneous mass with T2 SIGNAL INTENSITY NOT HYPERINTENSE. (A) Fat-suppressed T2W image. (B) Fat-suppressed early post-contrast T1W image. Pathology: Invasive ductal carcinoma.

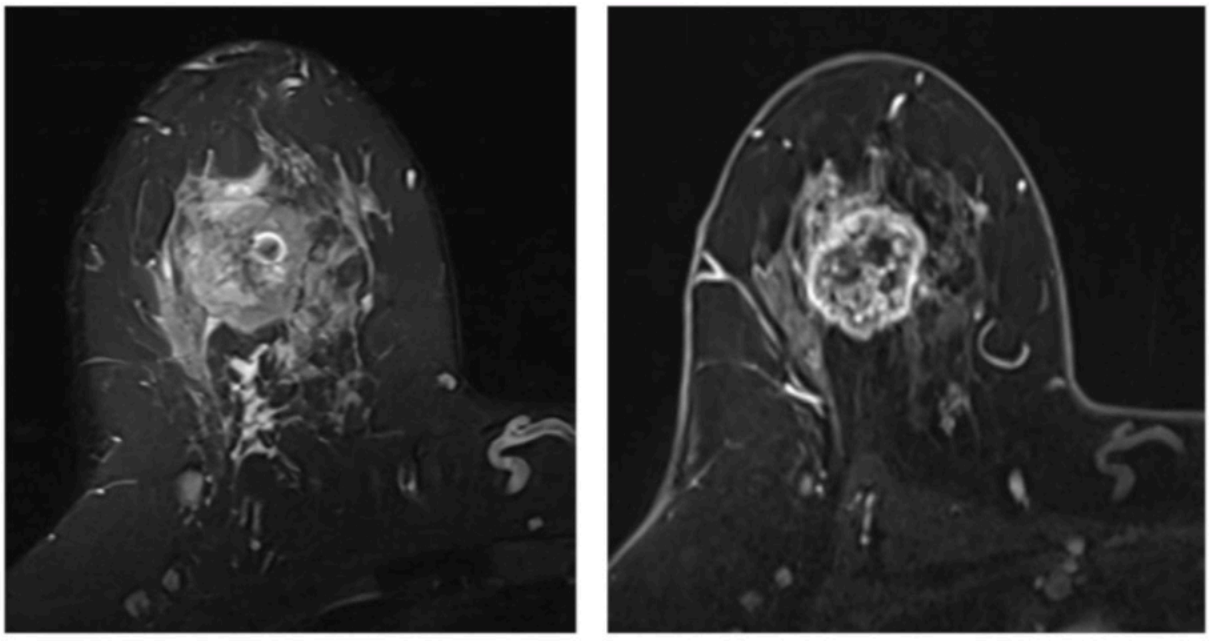

A B

Figure 3 – Oval, indistinct heterogeneous mass with T2 SIGNAL INTENSITY NOT HYPERINTENSE. (A) Fat-suppressed T2W image. (B) Fat-suppressed early post-contrast T1W image. Pathology: Invasive ductal carcinoma.

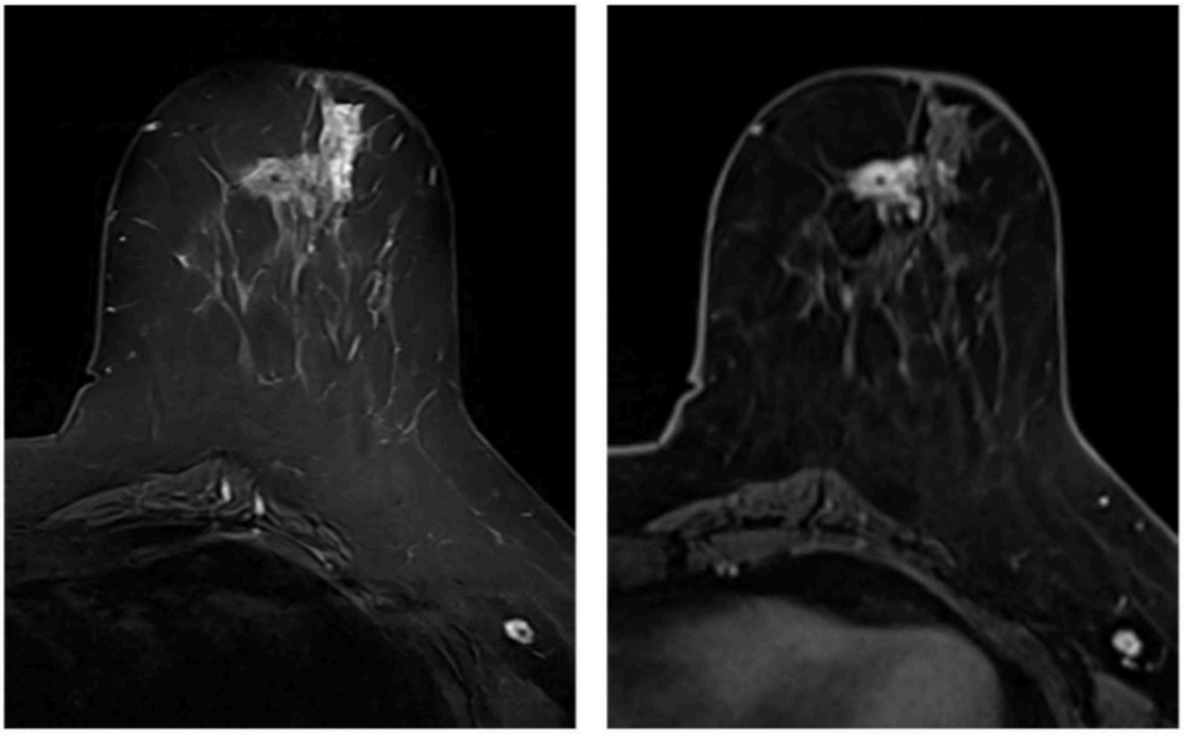

A B

Figure 4 – Irregular, indistinct, heterogeneous mass with T2 SIGNAL INTENSITY NOT HYPERINTENSE. Portions of the mass are hypointense relative to the left axillary lymph node. (A) Fat-suppressed T2W image. (B) Fat-suppressed early post-contrast T1W image. Pathology: Invasive ductal carcinoma.

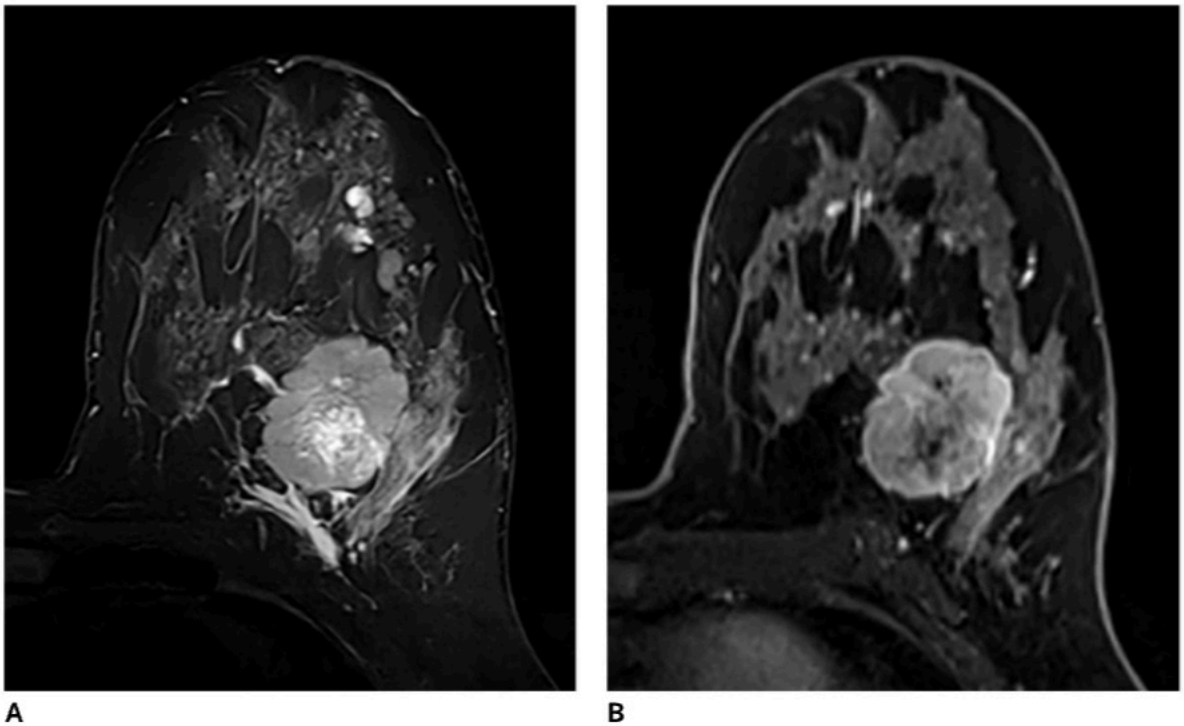

A B

Figure 5 – Irregular, indistinct, heterogeneous mass showing T2 SIGNAL INTENSITY NOT HYPERINTENSE (except for central necrosis). (A) Fat-suppressed T2W image. (B) Fat-suppressed early post-contrast T1W image. Pathology: Invasive ductal carcinoma.

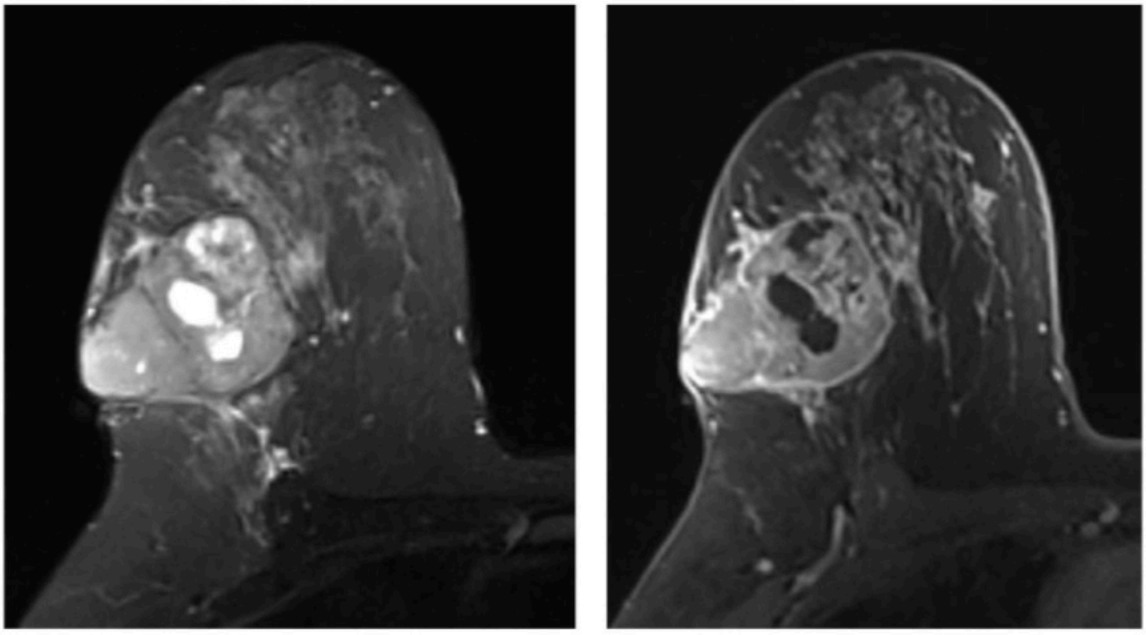

A B

Figure 6 – Oval, indistinct, heterogeneous mass with T2 SIGNAL INTENSITY NOT HYPERINTENSE (except for central necrosis). (A) Fat-suppressed T2W image. (B) Fat-suppressed early post-contrast T1W image. Pathology: Invasive ductal carcinoma.

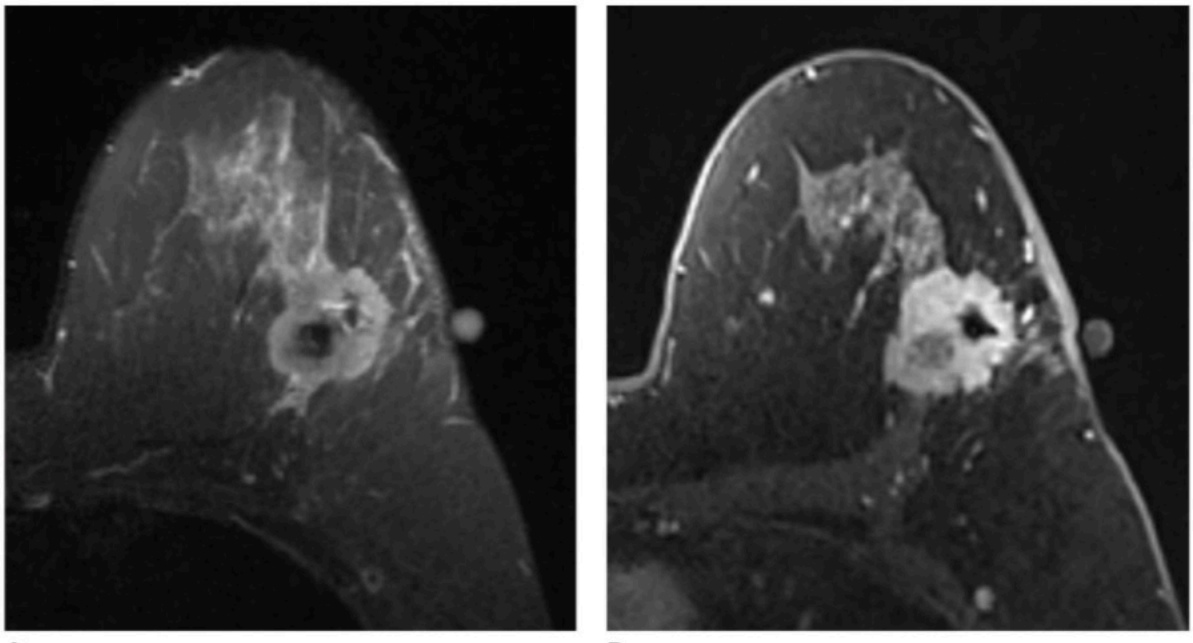

A B

Figure 7 – Irregular, indistinct, heterogeneous mass with T2 SIGNAL INTENSITY NOT HYPERINTENSE. (A) Fat-suppressed T2W image. (B) Fat-suppressed early post-contrast T1W image. Pathology: Invasive ductal carcinoma.

D. NON-MASS ENHANCEMENT (NME)

Non-mass enhancement (NME) is a unique area of enhancement that is distinct from normal background enhancement and is not a mass. NME may extend over small or large areas and often has interspersed areas of FGT or fat between the enhancing components. When deciding to characterize enhancement as a mass or NME, intervening tissue and/or fat or NME-type distribution pattern suggest the enhancement may be better described as NME.

NME is characterized morphologically by distribution and internal enhancement pattern. These enhancement features should be assessed on the early post-contrast series. Kinetics may also help characterize NME for which the morphology is not definitively benign or suspicious.

Not all non-mass enhancement features must be used in describing NME. In general, the description should include at least distribution and internal enhancement. When they influence assessment, enhancement kinetics should also be described.

1. DISTRIBUTION

   a. Diffuse

      Diffuse describes enhancement distributed throughout a large portion of the breast, typically 2 or more quadrants.

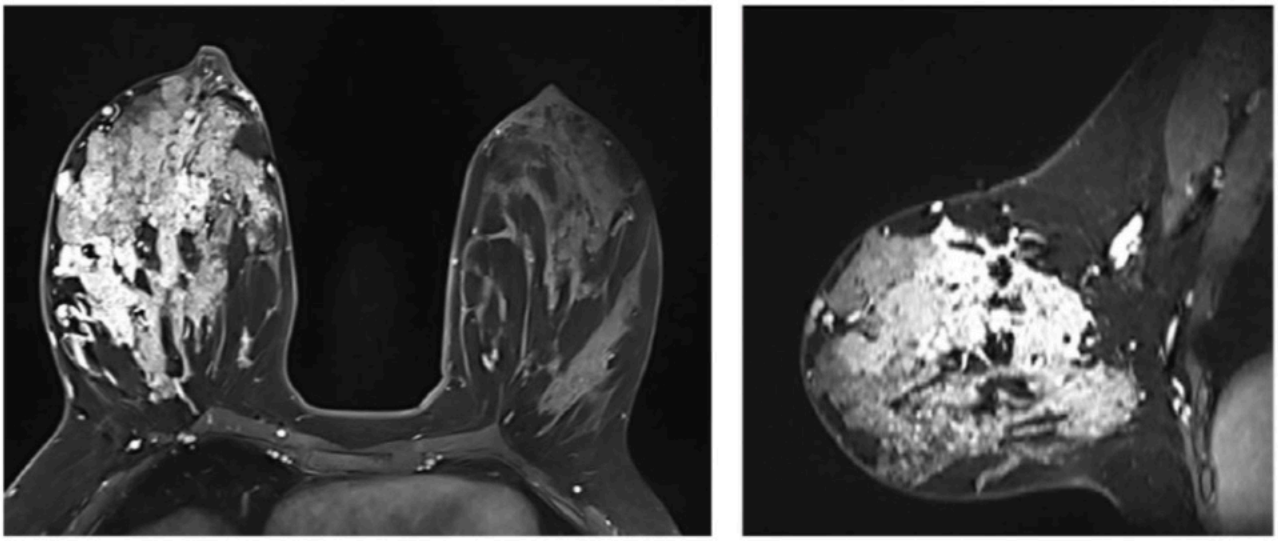

A B

Figure 1 – DIFFUSE, heterogeneous NME. Fat-suppressed early post-contrast T1W (A) axial and (B) right sagittal images. Pathology: DCIS with microinvasion.

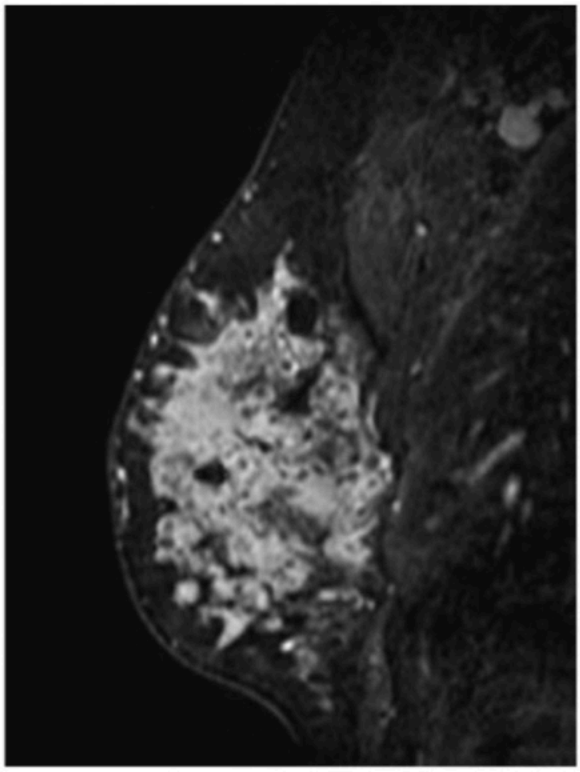

Figure 2 – DIFFUSE, clustered ring NME.
Fat-suppressed early post-contrast T1W image.
Pathology: Invasive ductal carcinoma and DCIS.

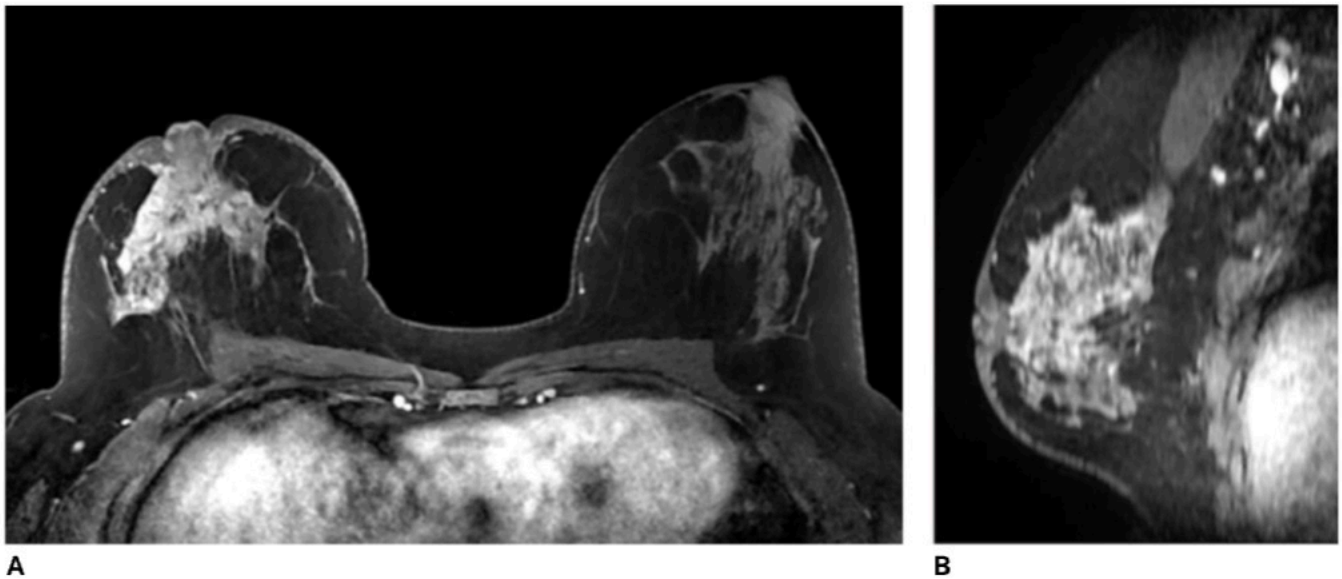

A B

Figure 3 – DIFFUSE, heterogeneous NME. Fat-suppressed early post-contrast T1W (A) axial and (B) sagittal images.
Pathology: Invasive lobular carcinoma.

D. NON-MASS ENHANCEMENT (NME)

1. DISTRIBUTION

   b. Regional

   Regional describes enhancement that occupies a volume of the breast that is typically more than one quadrant, but which is not diffuse and does not follow a segmental or linear distribution.

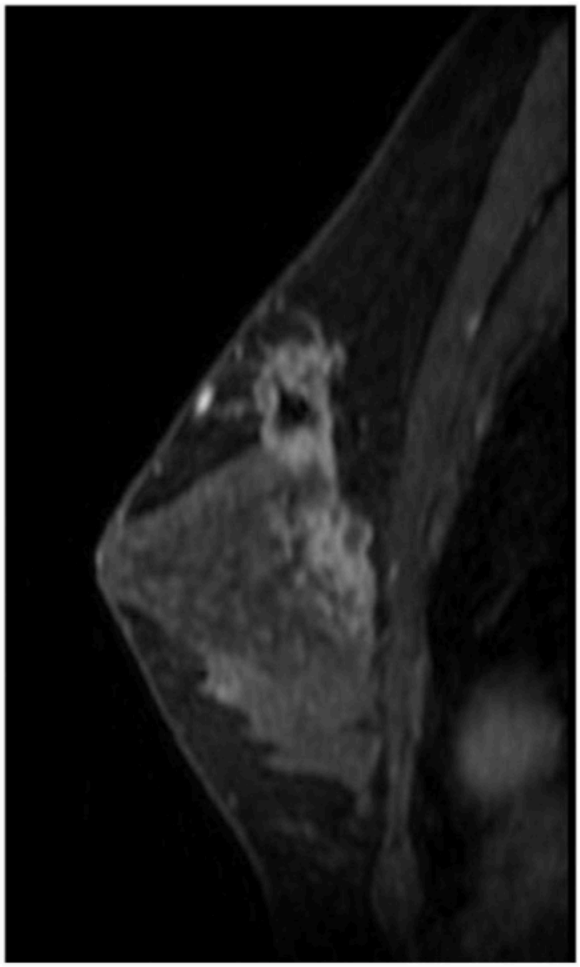

Figure 1 – REGIONAL, heterogeneous NME.
Fat-suppressed early post-contrast T1W image.
Pathology: Invasive ductal carcinoma and DCIS.

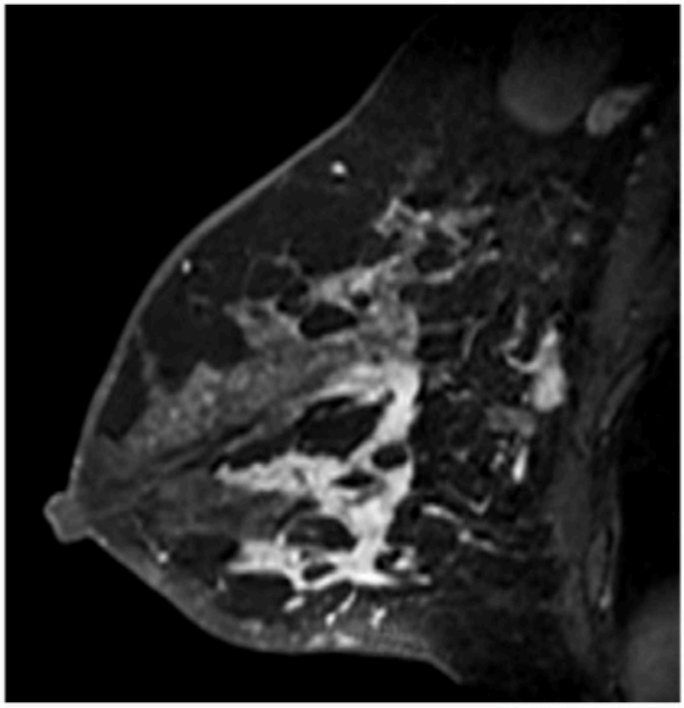

Figure 2 – REGIONAL, homogeneous NME. Fat-suppressed early post-contrast T1W image. Pathology: Invasive carcinoma with mixed ductal and lobular features, DCIS.

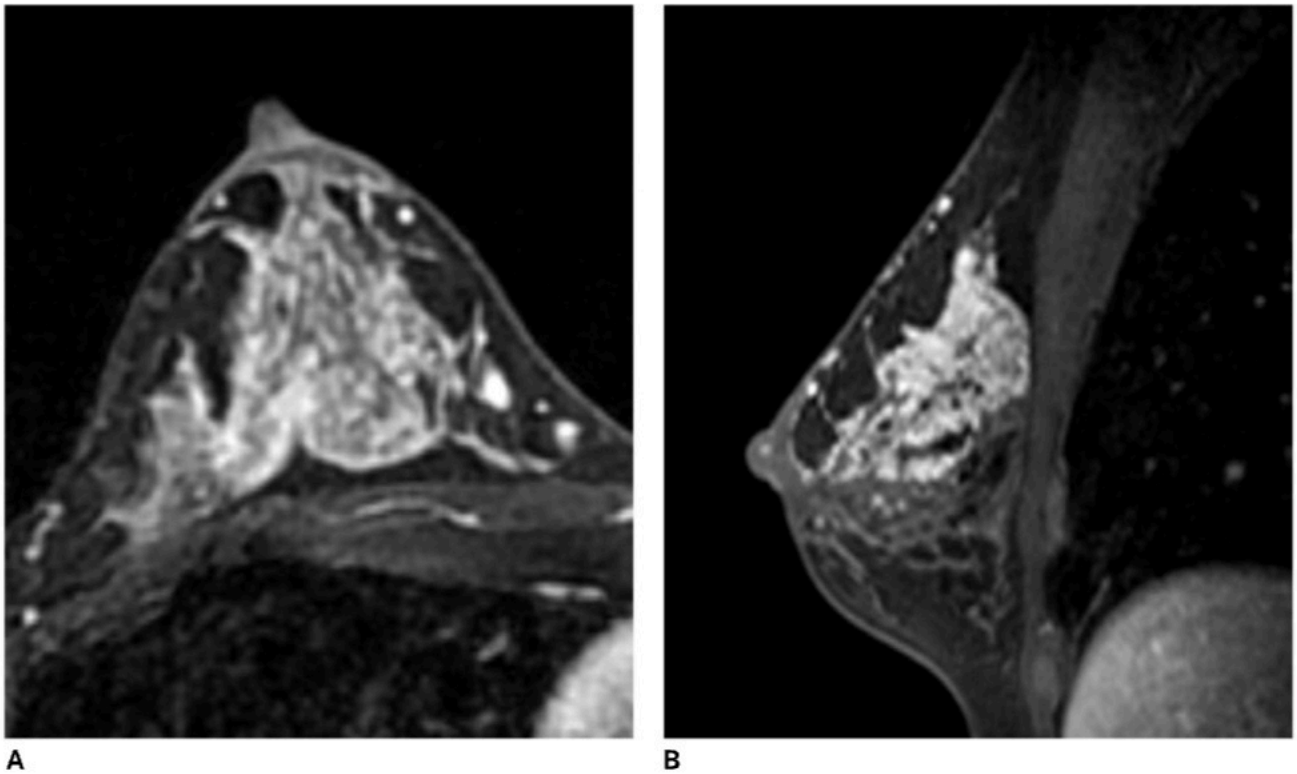

A B

Figure 3 – REGIONAL, heterogeneous NME. Fat-suppressed early post-contrast T1W (A) axial and (B) sagittal images. Pathology: DCIS.

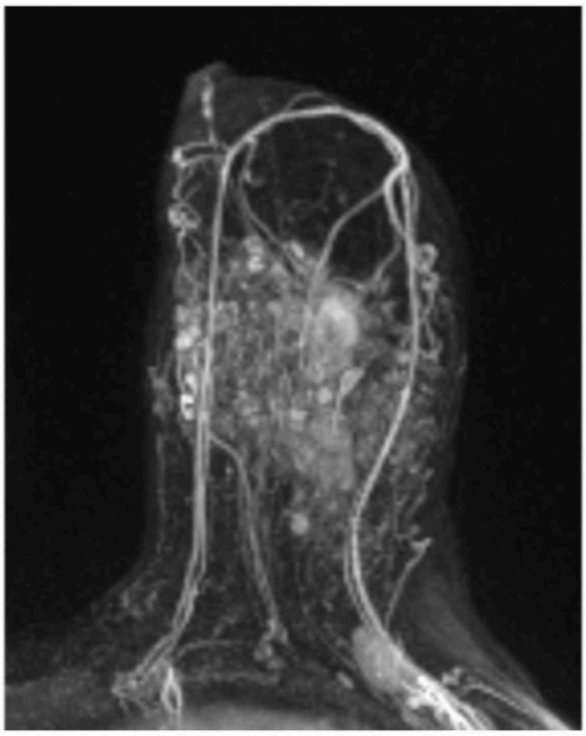

A

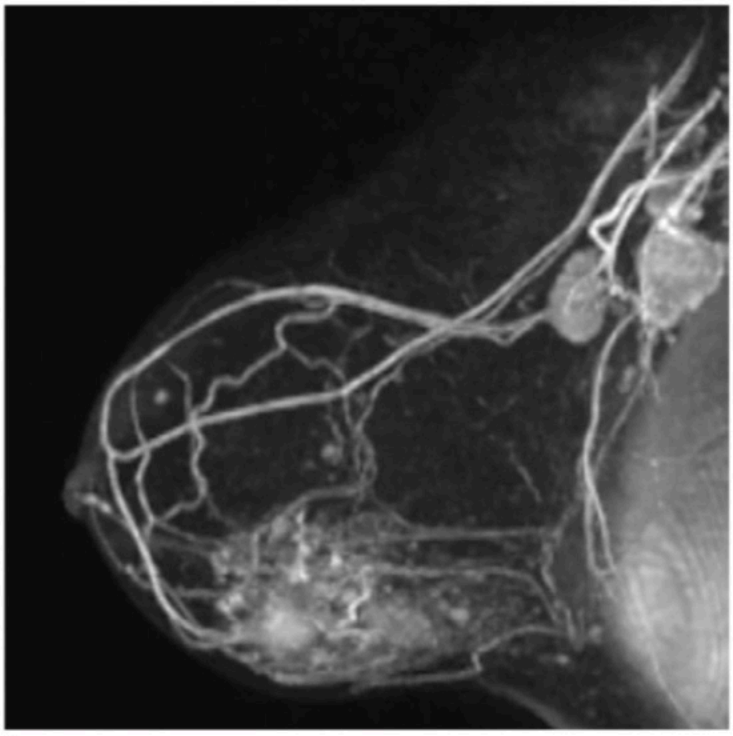

B

Figure 4 – REGIONAL, clumped NME. Note also left axillary lymphadenopathy consistent with metastatic disease. (A) Axial and (B) sagittal early post-contrast T1W maximum intensity projection images. Pathology: DCIS with microinvasion.

D. NON-MASS ENHANCEMENT (NME)

1. DISTRIBUTION

   c. Focal

   Focal describes enhancement that is localized and occupies less than one quadrant but does not follow a segmental or linear distribution. It is the appropriate NME distribution descriptor when the pattern of enhancement does not fall into one of the other categories.

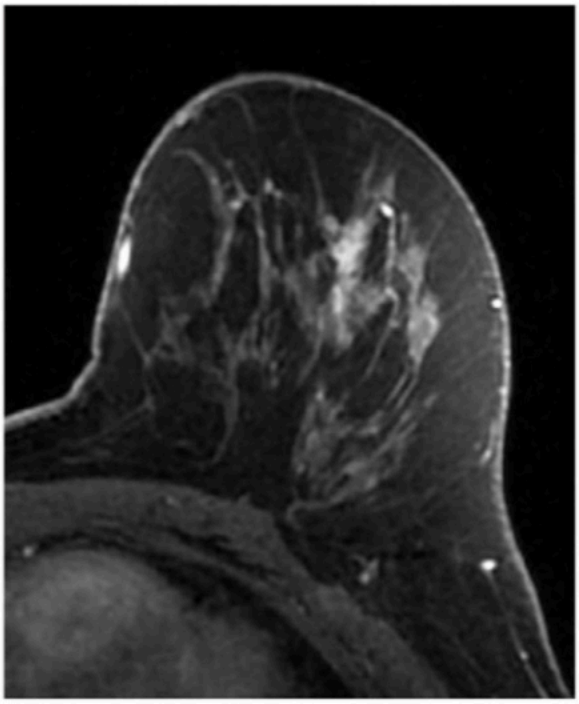

Figure 1 – FOCAL, heterogeneous NME. Fat-suppressed early post-contrast T1W image. Pathology: Pseudoangiomatous stromal hyperplasia (PASH).

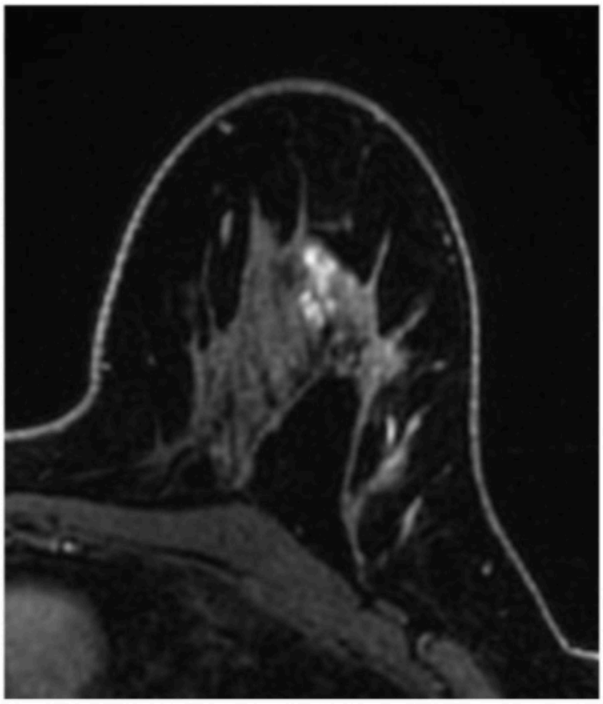

Figure 2 – FOCAL, clumped NME. Fat-suppressed early post-contrast T1W image. Pathology: Fibrocystic change.

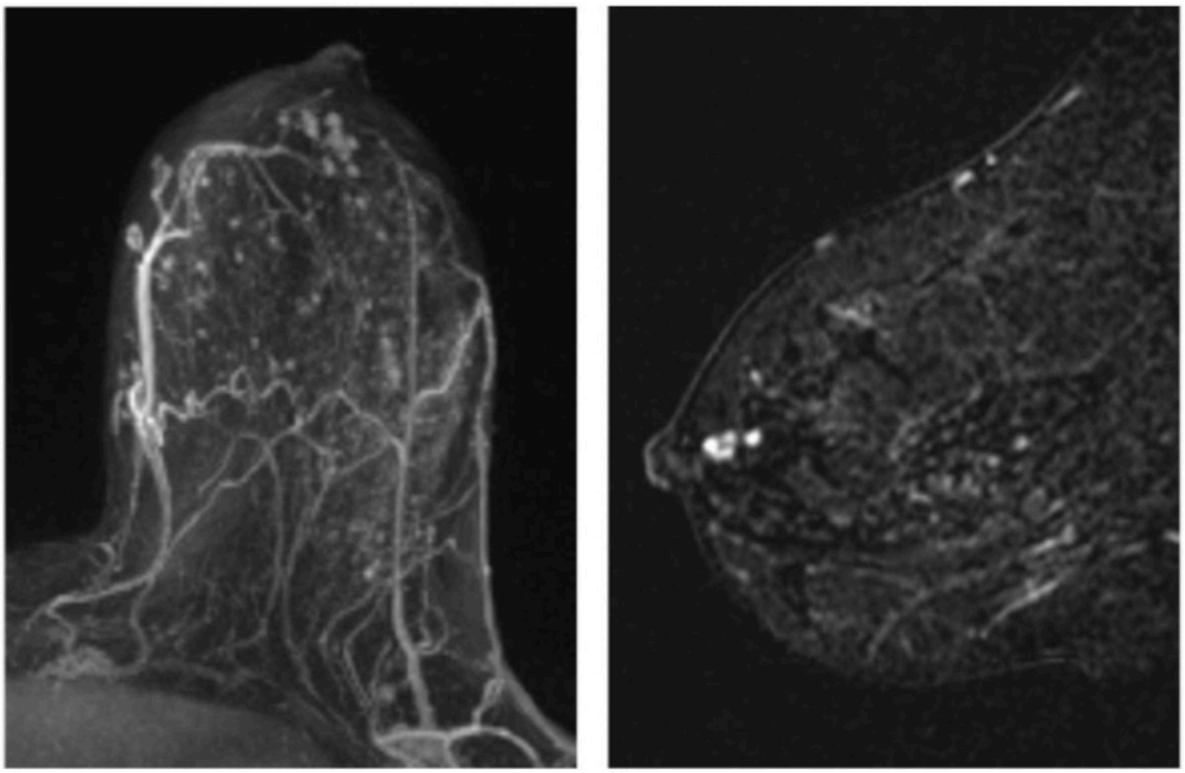

A B

Figure 3 – FOCAL, clumped NME. (A) Early post-contrast T1W maximum intensity projection image. (B) Early post-contrast T1W subtracted image. Pathology: DCIS.

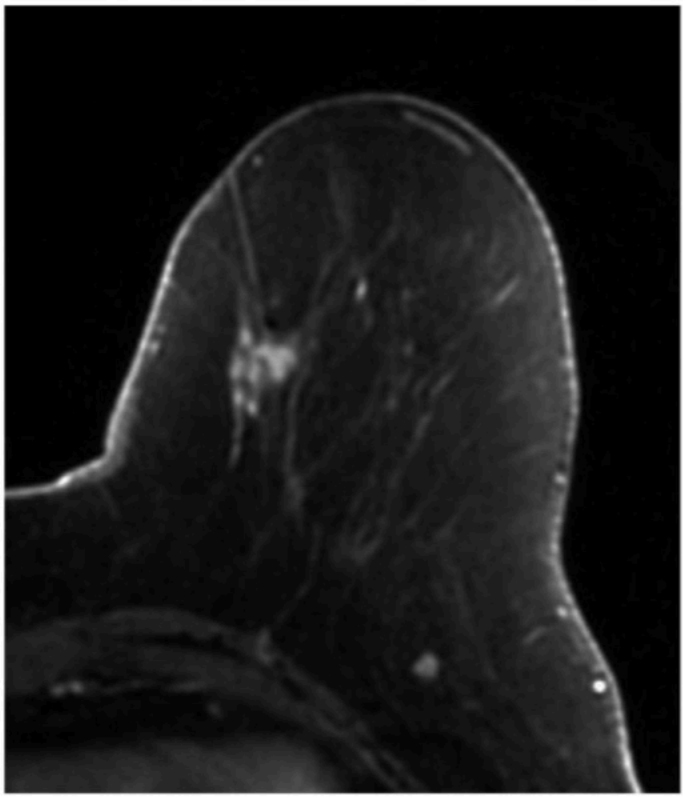

Figure 4 – FOCAL, clumped NME. Fat-suppressed early post-contrast T1W image. Pathology: Invasive ductal carcinoma and DCIS.

D. NON-MASS ENHANCEMENT (NME)

1. DISTRIBUTION

   d. Linear

   Linear describes enhancement arrayed in a line (may curve or be angled) or a line that branches. Linear distribution is a typically a suspicious feature because it suggests enhancement within or around a duct.

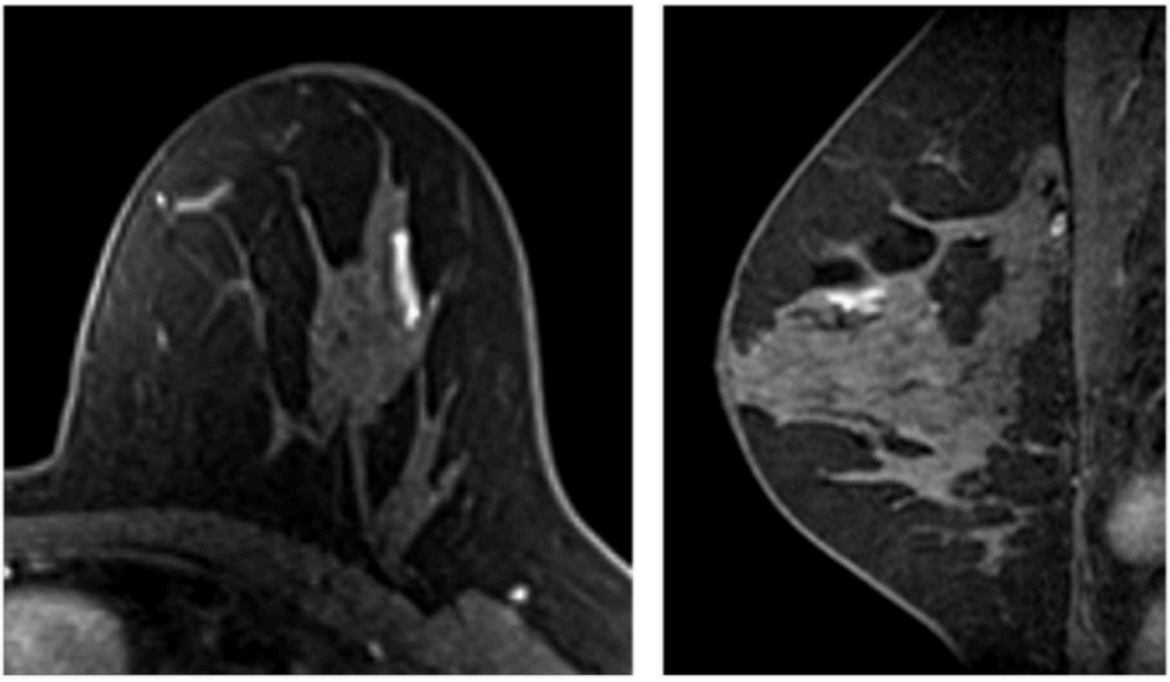

A B

Figure 1 – LINEAR, homogeneous NME. Fat-suppressed early post-contrast T1W (A) axial and (B) sagittal images. Pathology: DCIS.

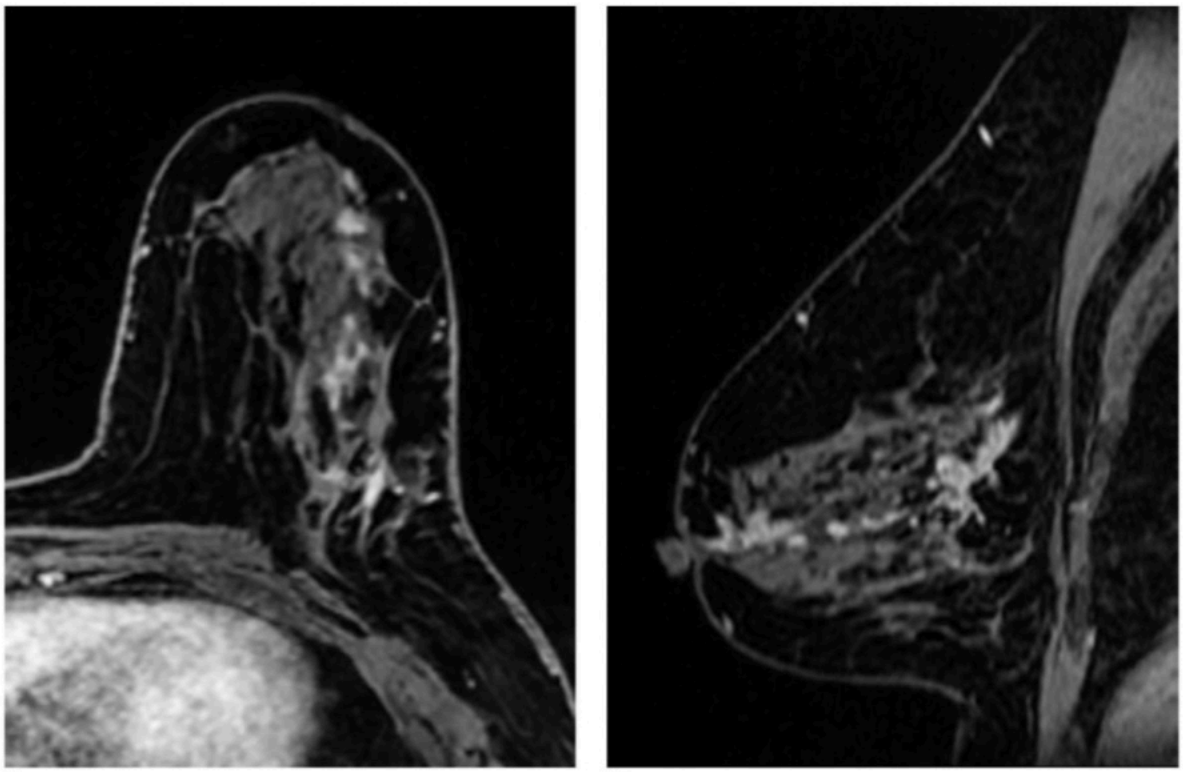

A B

Figure 2 – LINEAR, clumped NME. Fat-suppressed early post-contrast T1W (A) axial and (B) sagittal images. Pathology: DCIS.

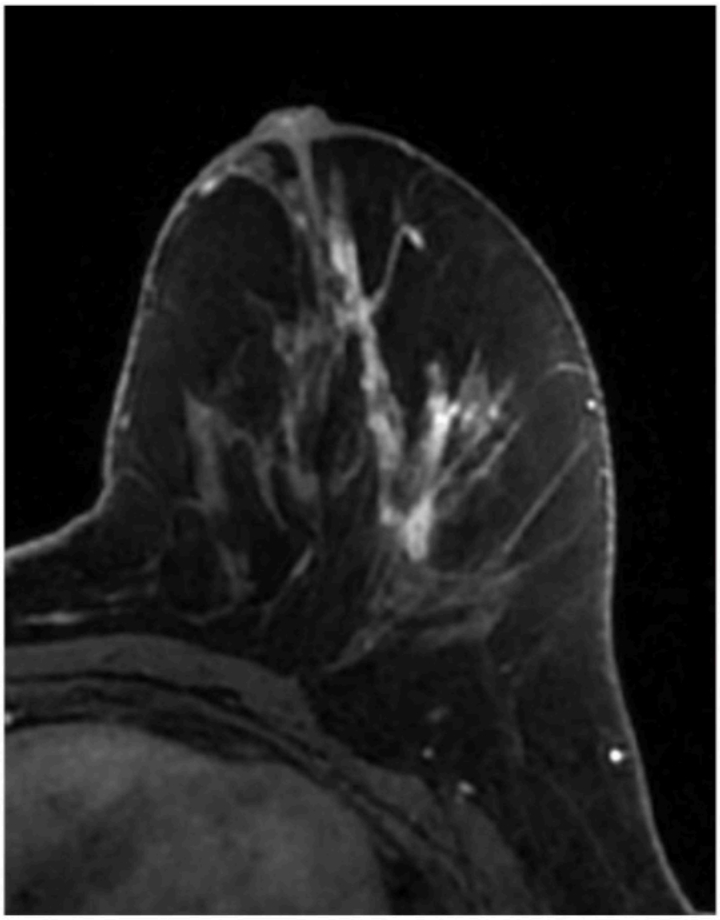

Figure 3 – LINEAR, clumped NME. Fat-suppressed early post-contrast T1W image. Pathology: Lobular carcinoma in situ (LCIS).

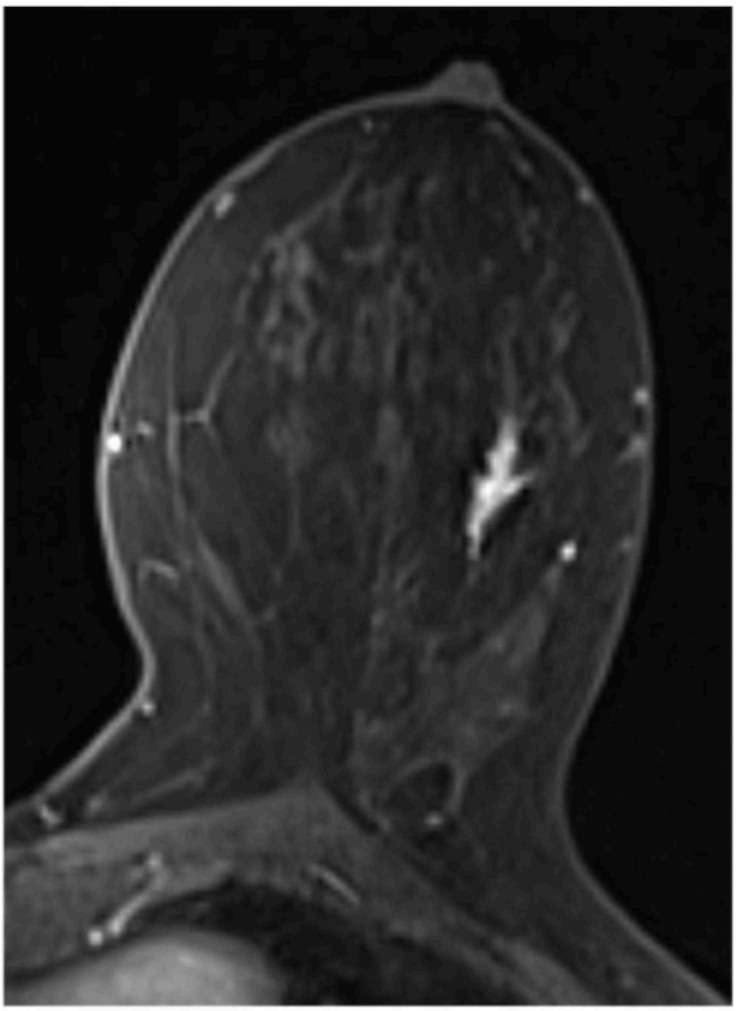

Figure 4 – LINEAR, heterogeneous NME. Fat-suppressed early post-contrast T1W image. Pathology: Stromal fibrosis.

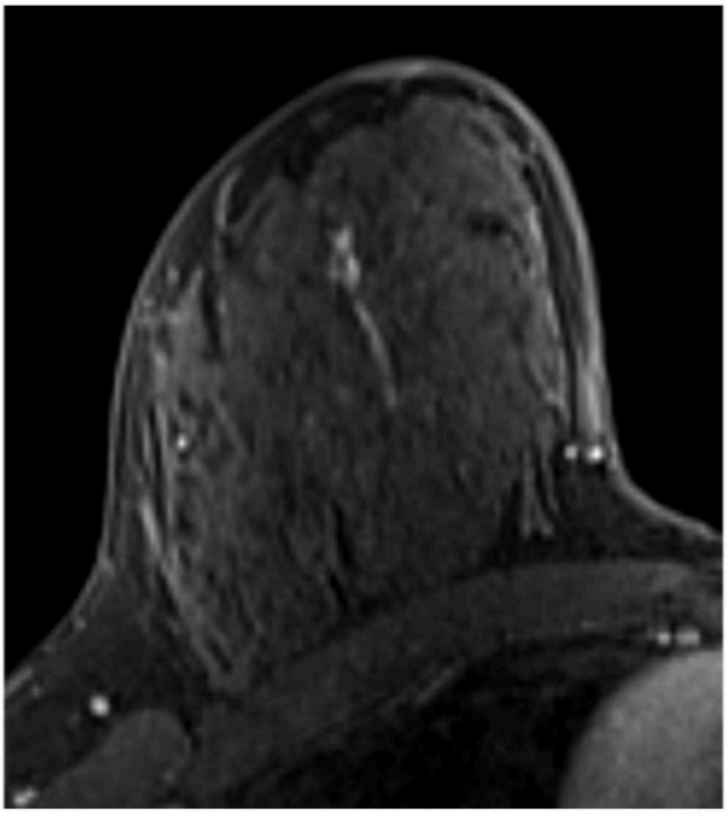

Figure 5 – LINEAR, heterogeneous NME. Fat-suppressed early post-contrast T1W image. Pathology: Nodular sclerosing adenosis.

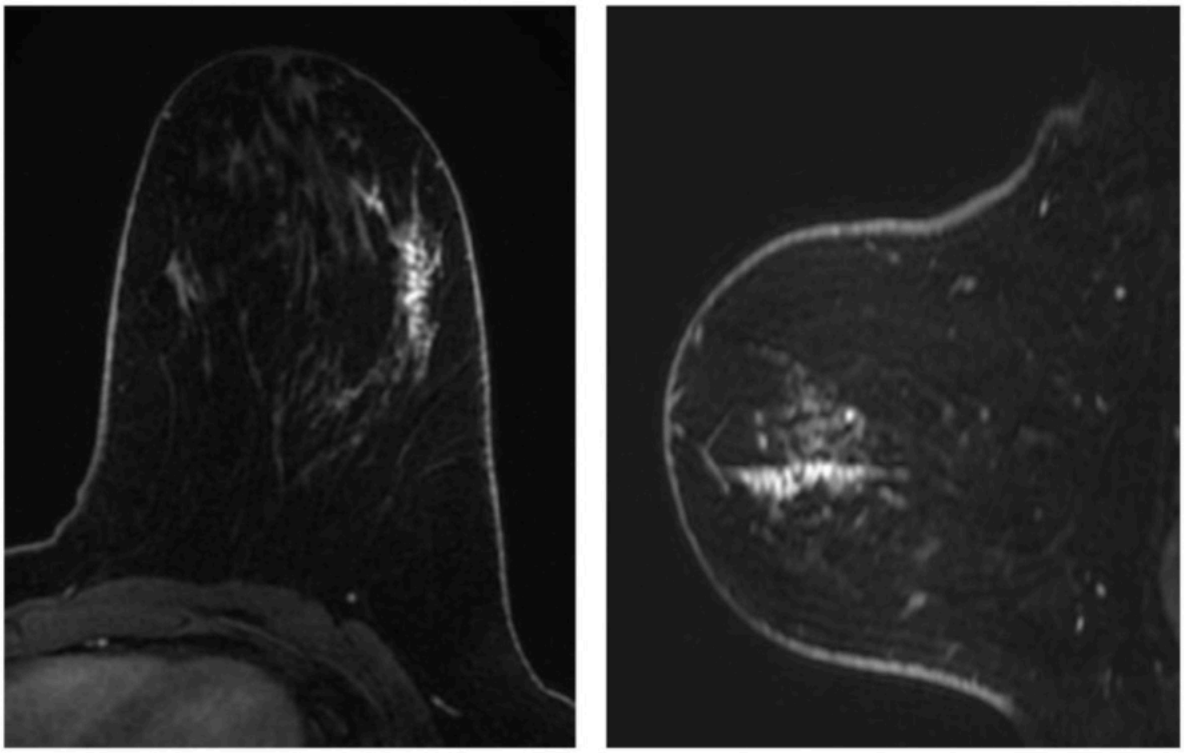

A B

Figure 6 – LINEAR, heterogeneous NME. Fat-suppressed early post-contrast T1W image. Pathology: Apocrine metaplasia.

D. NON-MASS ENHANCEMENT (NME)

1. DISTRIBUTION

   e. Segmental

   Segmental describes enhancement that is triangular or cone shaped with the apex pointing toward the nipple. Segmental distribution is typically a suspicious feature because it suggests enhancement within or around a segment of ducts or ducts and their branches.

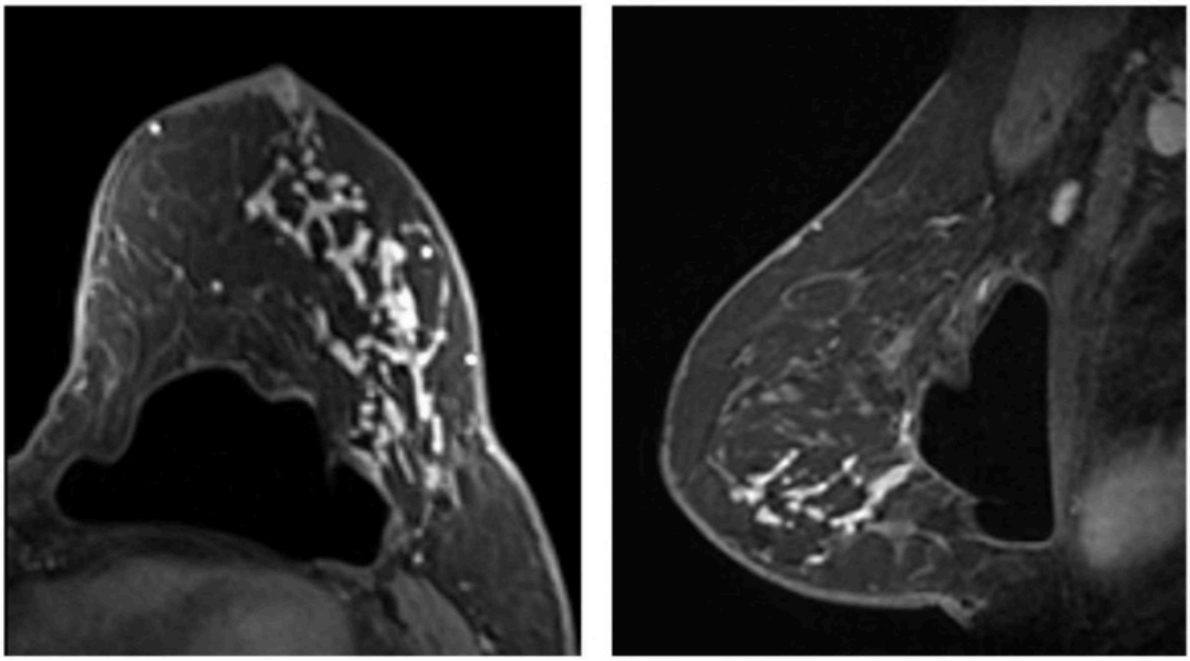

A B

Figure 1 – SEGMENTAL, clumped NME. The patient incidentally has a breast implant. Fat-suppressed early post-contrast T1W (A) axial and (B) sagittal images. Pathology: DCIS.

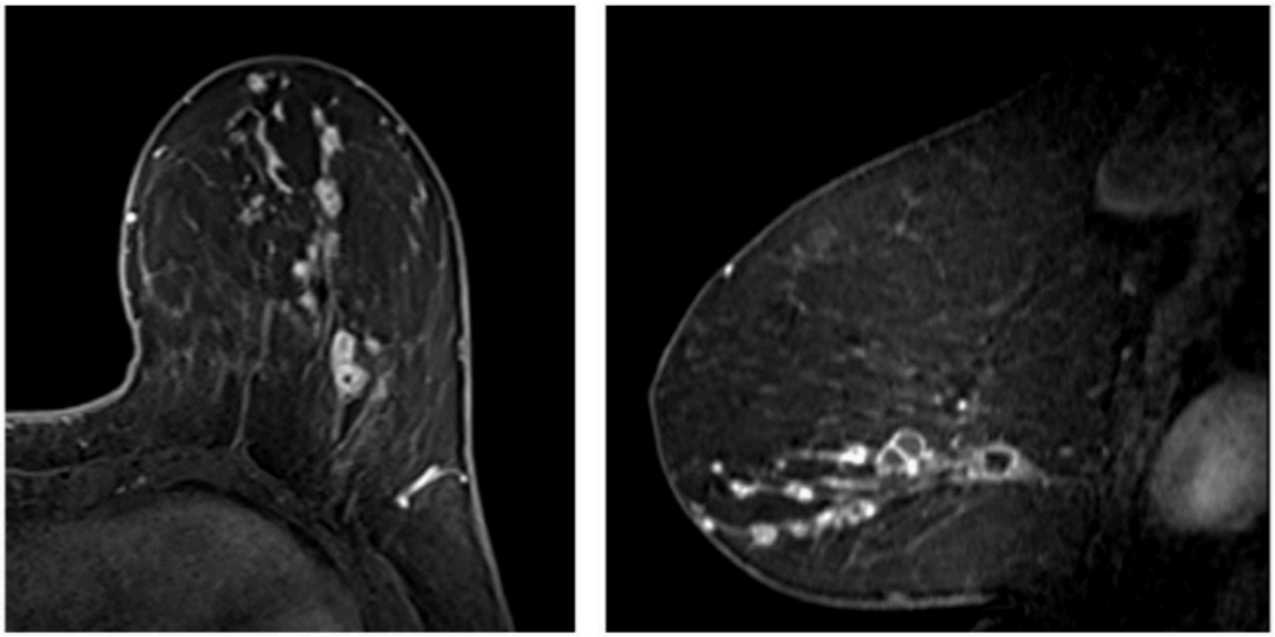

A B

Figure 2 – SEGMENTAL, clustered ring NME. Fat-suppressed early post-contrast T1W (A) axial and (B) sagittal images. Pathology: DCIS.

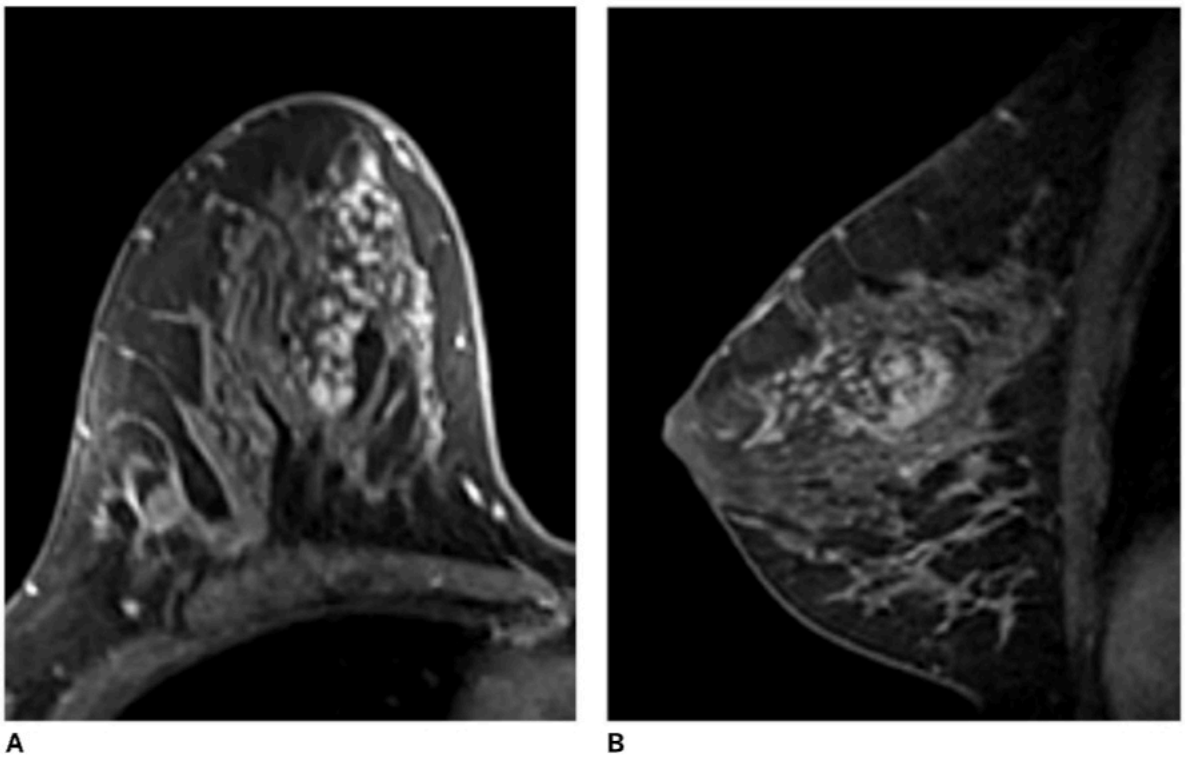

A B

Figure 3 – SEGMENTAL, heterogeneous NME. Fat-suppressed early post-contrast T1W (A) axial and (B) sagittal images. Pathology: DCIS.

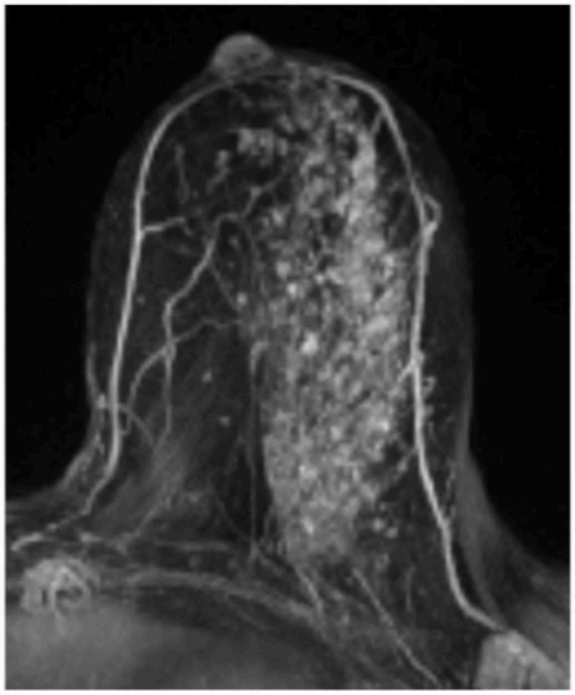

A

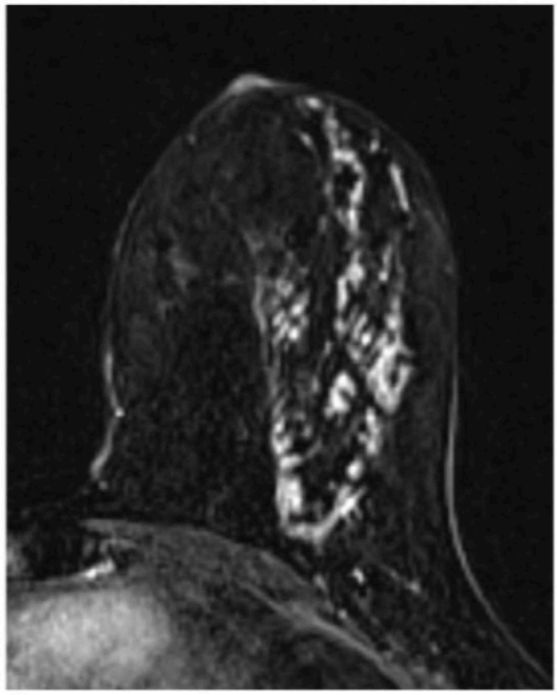

B

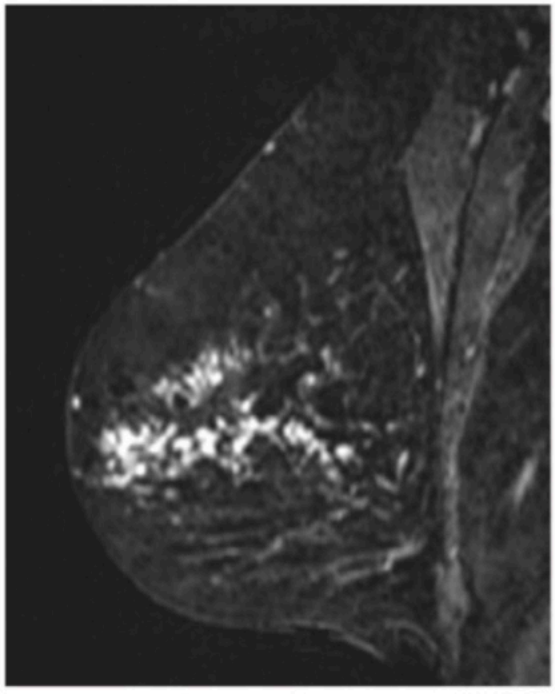

C

Figure 4 – SEGMENTAL, clumped NME. (A) Early post-contrast T1W maximum intensity projection image. Early post-contrast T1W subtracted (B) axial and (C) sagittal images. Pathology: DCIS.

D. NON-MASS ENHANCEMENT (NME)

2. INTERNAL ENHANCEMENT PATTERN

a. Homogeneous

Homogeneous describes confluent, uniform enhancement.

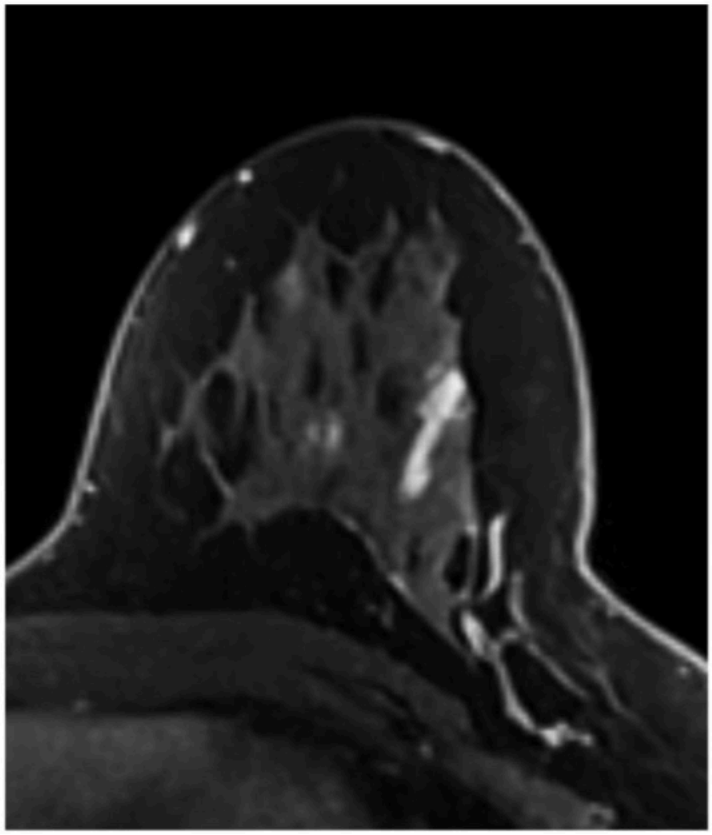

Figure 1 – Linear HOMOGENEOUS NME. Fat-suppressed early post-contrast T1W image. Pathology: DCIS.

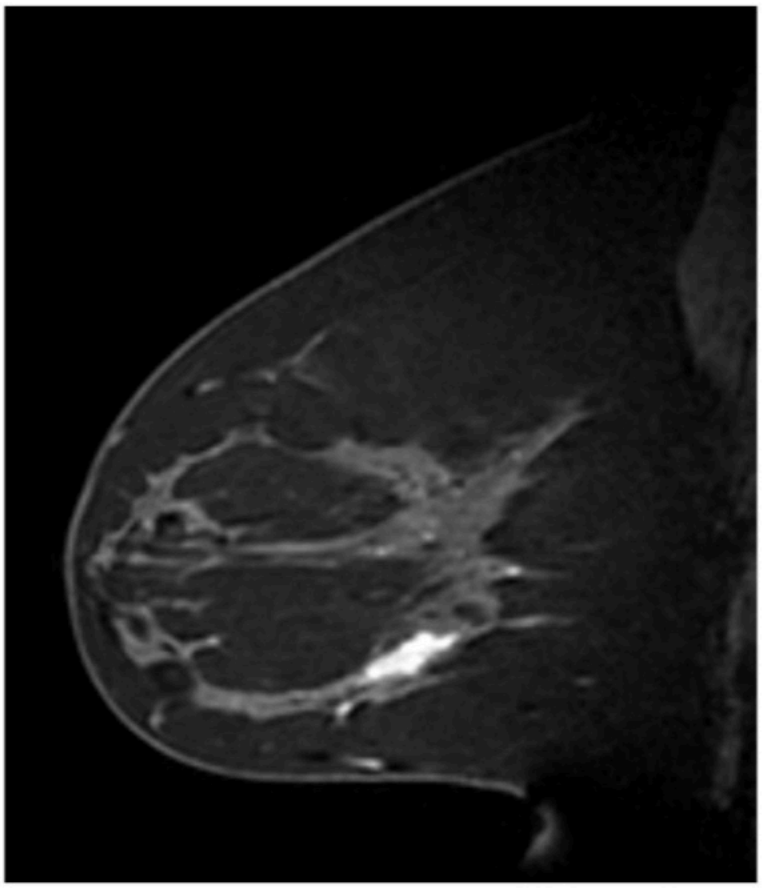

Figure 2 – Linear HOMOGENEOUS NME. Fat-suppressed early post-contrast T1W image. Pathology: Invasive ductal carcinoma and DCIS.

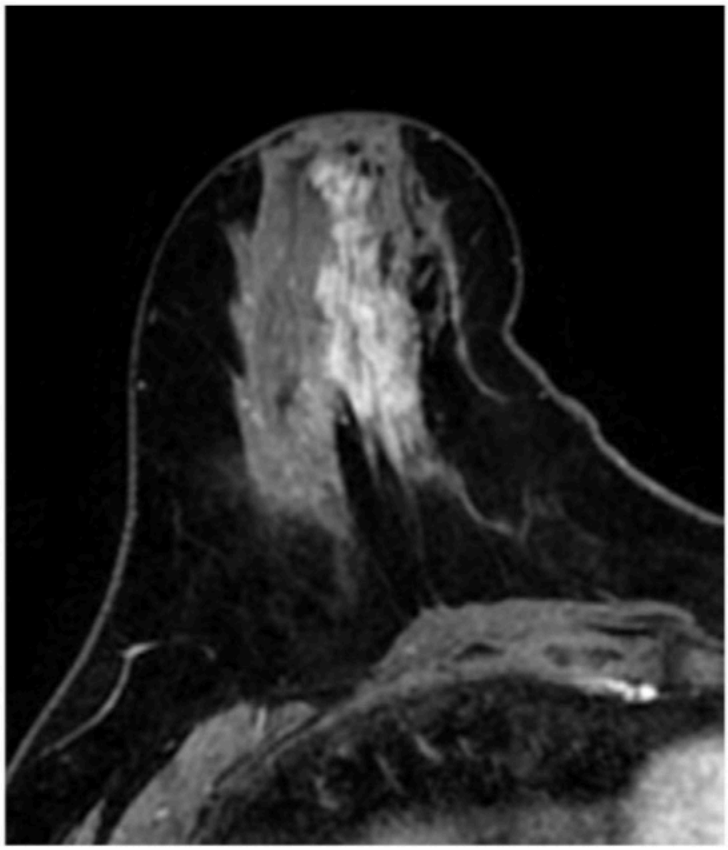

Figure 3 – Segmental, HOMOGENEOUS NME. Fat-suppressed early post-contrast T1W image. Pathology: DCIS.

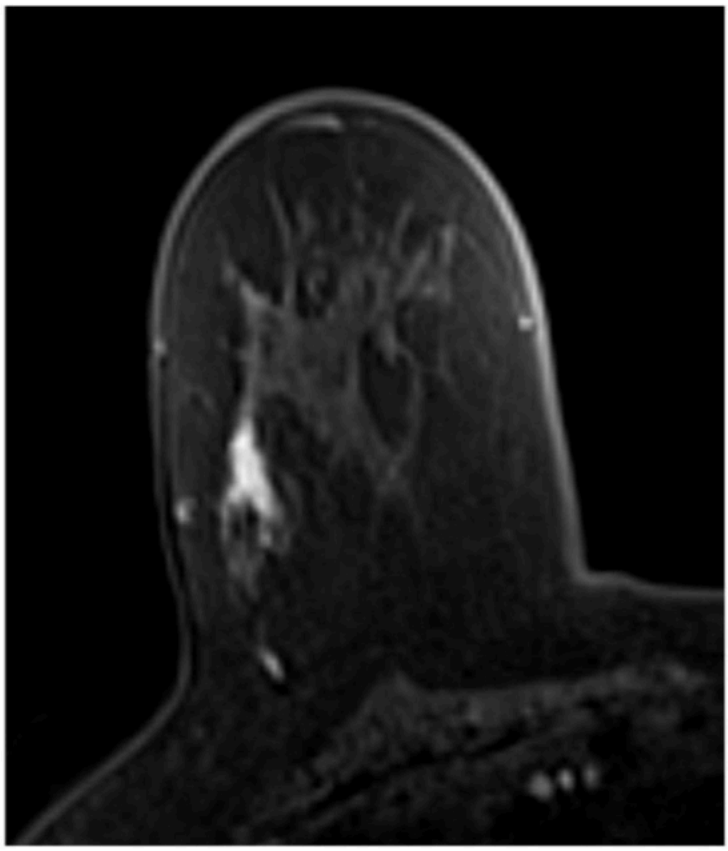

Figure 4 – Linear, HOMOGENEOUS NME. Fat-suppressed early post-contrast T1W image. Pathology: Invasive lobular carcinoma (ILC).

D. NON-MASS ENHANCEMENT (NME)

2. INTERNAL ENHANCEMENT PATTERN

b. Heterogeneous

Heterogeneous describes a nonuniform enhancement pattern, separated by areas of breast parenchyma or fat.

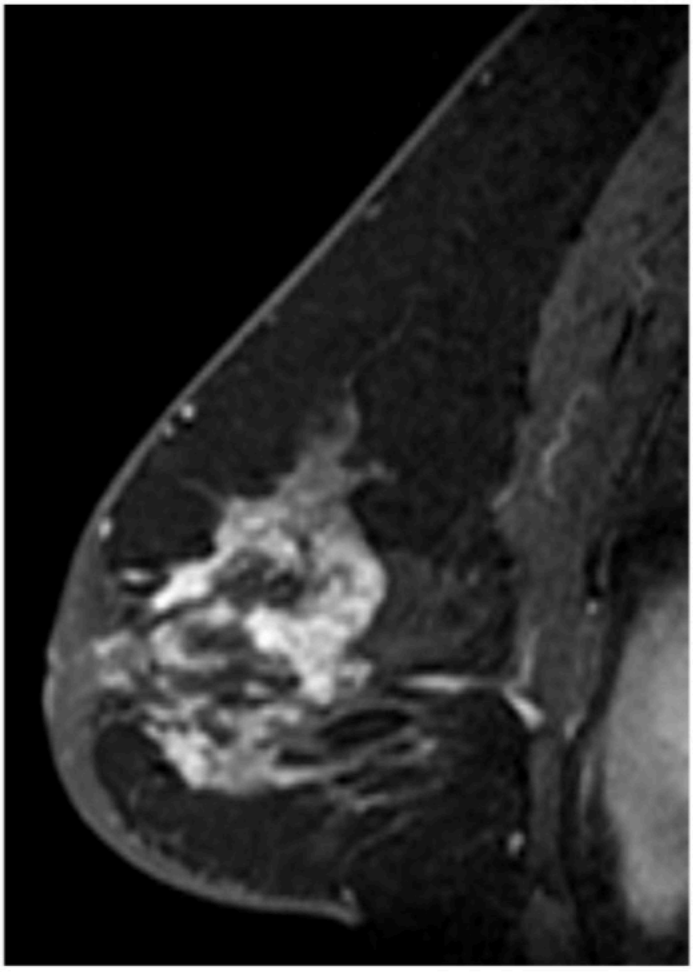

Figure 1 – Diffuse, HETEROGENEOUS NME. Fat-suppressed early post-contrast T1W image. Pathology: Invasive ductal carcinoma.

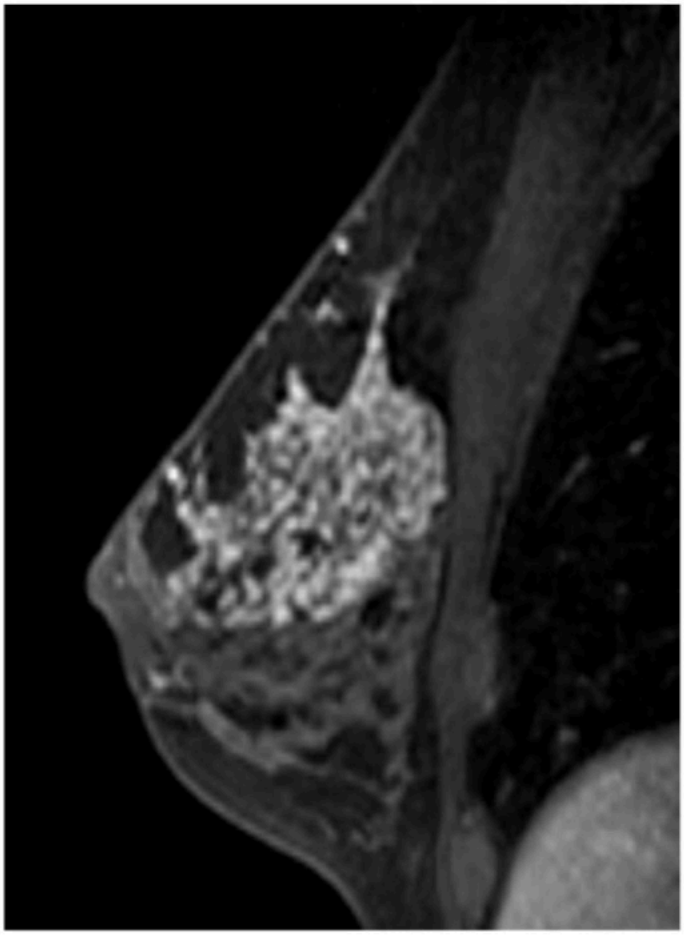

Figure 2 – Segmental, HETEROGENEOUS NME. Fat-suppressed early post-contrast T1W image. Pathology: DCIS.

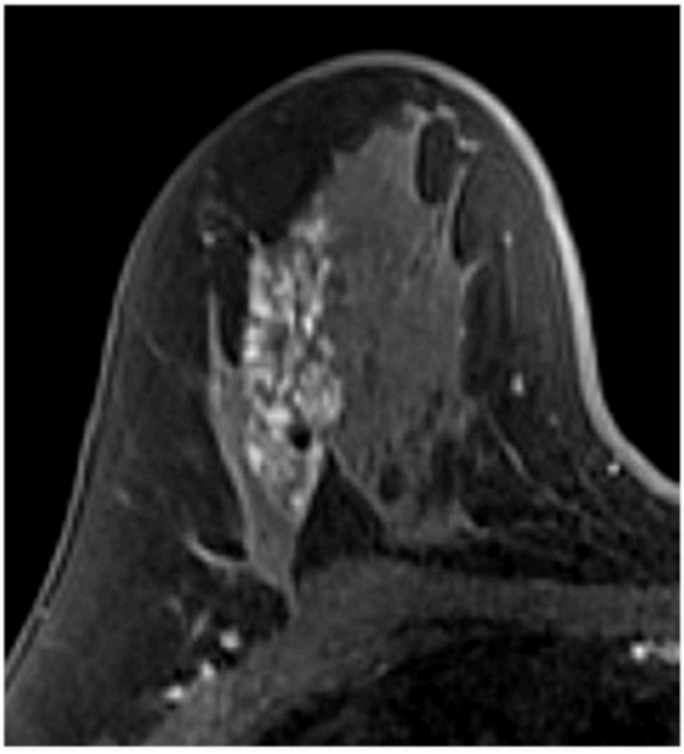

Figure 3 – Segmental, HETEROGENEOUS NME. Fat-suppressed early post-contrast T1W image. Pathology: Pseudoangiomatous stromal hyperplasia (PASH).

D. NON-MASS ENHANCEMENT (NME)

2. INTERNAL ENHANCEMENT PATTERN

c. Clumped

Clumped describes enhancement of varying shapes and sizes with a cobblestone or beaded appearance. Use of this descriptor typically implies a suspicious finding.

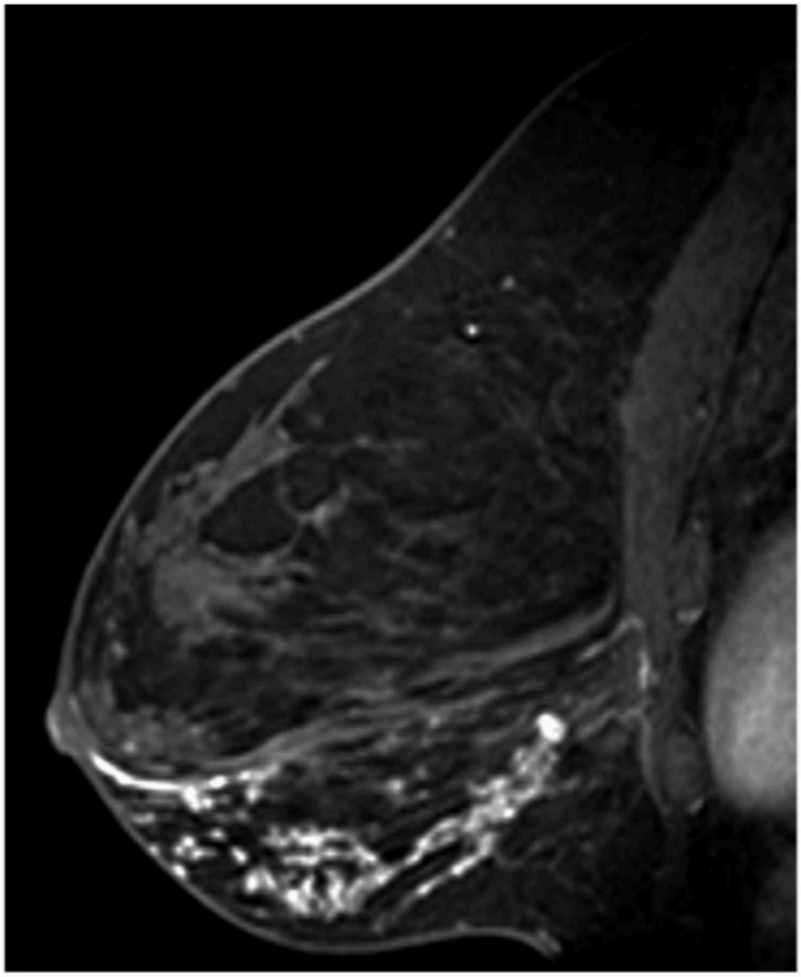

Figure 1 – Segmental, CLUMPED NME. Fat-suppressed early post-contrast T1W image. Pathology: DCIS.

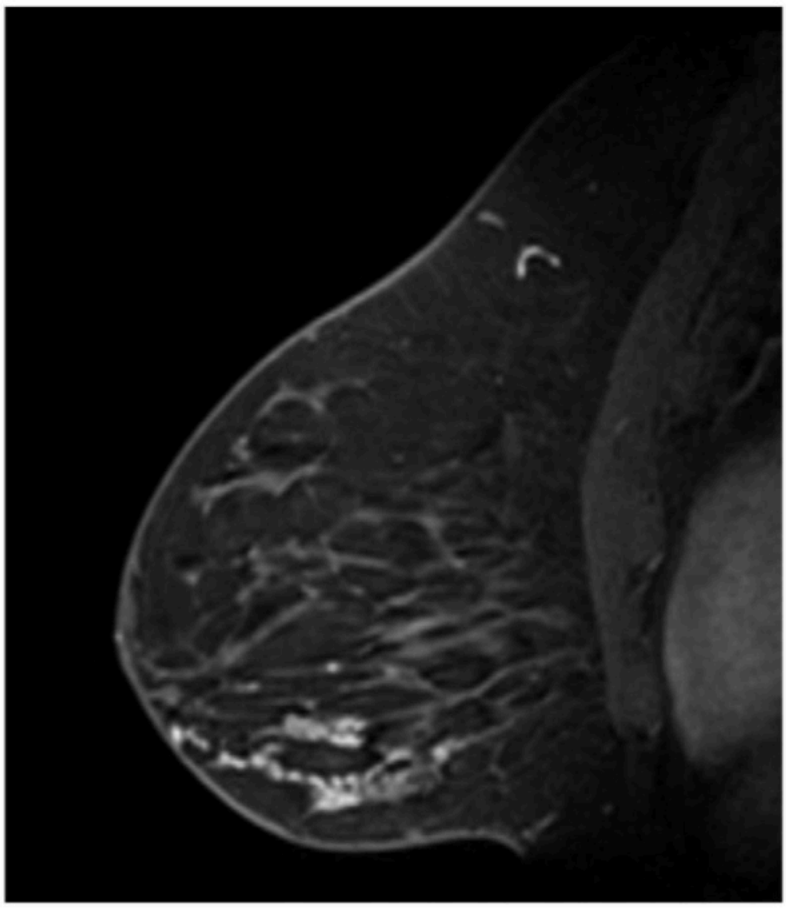

Figure 2 – Segmental, CLUMPED NME. Fat-suppressed early post-contrast T1W image. Pathology: DCIS.

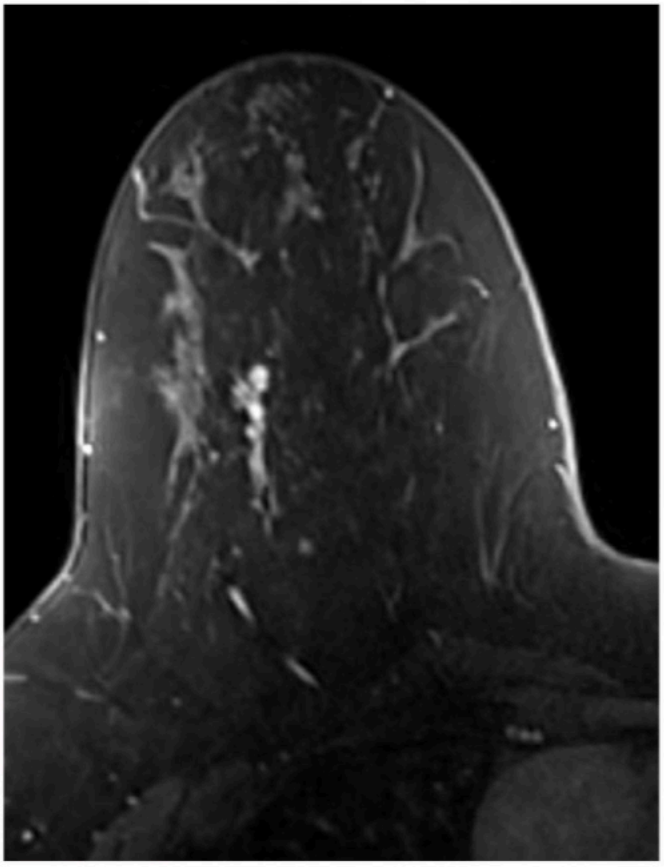

Figure 3 – Linear, CLUMPED NME. Fat-suppressed early post-contrast T1W image. Pathology: DCIS.

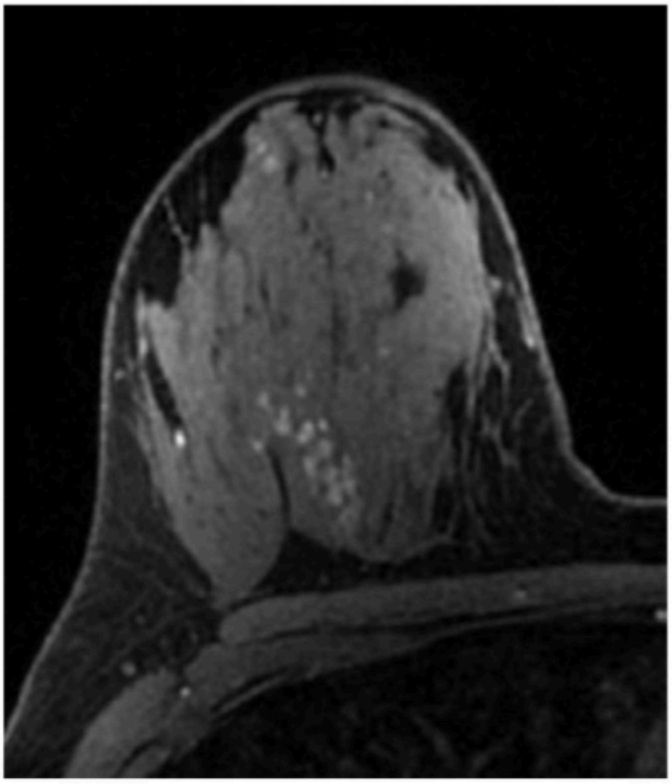

Figure 4 – Focal CLUMPED NME. Fat-suppressed early post-contrast T1W image. Pathology: DCIS.

D. NON-MASS ENHANCEMENT (NME)

2. INTERNAL ENHANCEMENT PATTERN

d. Clustered Ring

Clustered ring describes thin rings of enhancement clustered together around the ducts. Use of this descriptor typically implies a suspicious finding. In some studies, clustered ring is the NME internal enhancement pattern most predictive for malignancy [7].

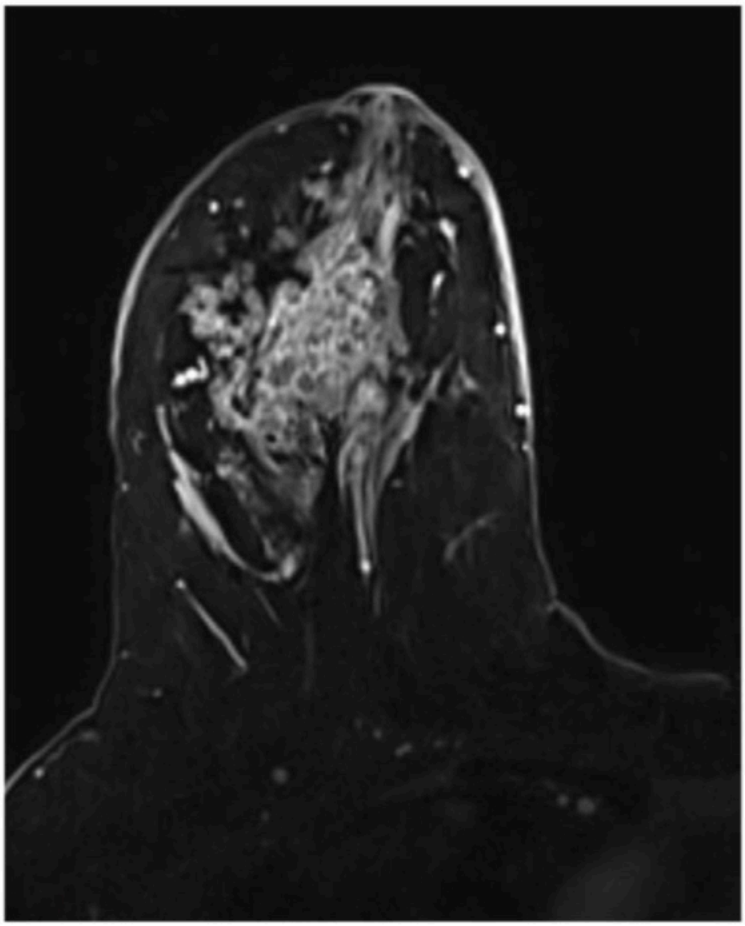

Figure 1 – Segmental CLUSTERED RING NME. Fat-suppressed early post-contrast T1W image. Pathology: Invasive ductal carcinoma.

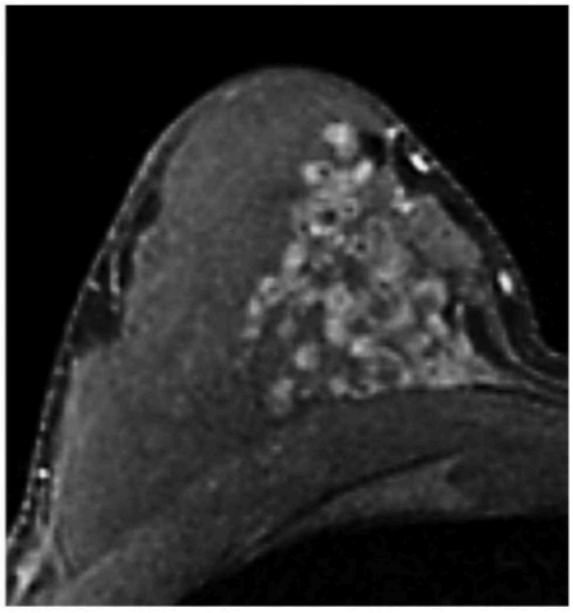

Figure 2 – Segmental CLUSTERED RING NME. Fat-suppressed early post-contrast T1W image. Pathology: Invasive ductal carcinoma and DCIS.

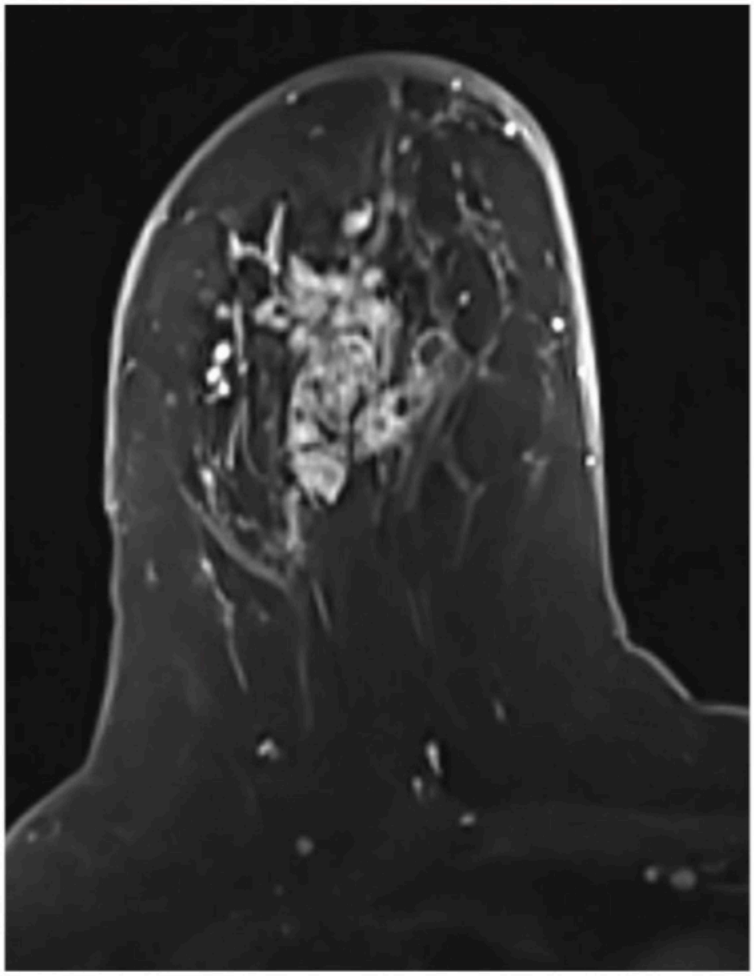

Figure 3 – Focal CLUSTERED RING NME. Fat-suppressed early post-contrast T1W image. Pathology: DCIS.

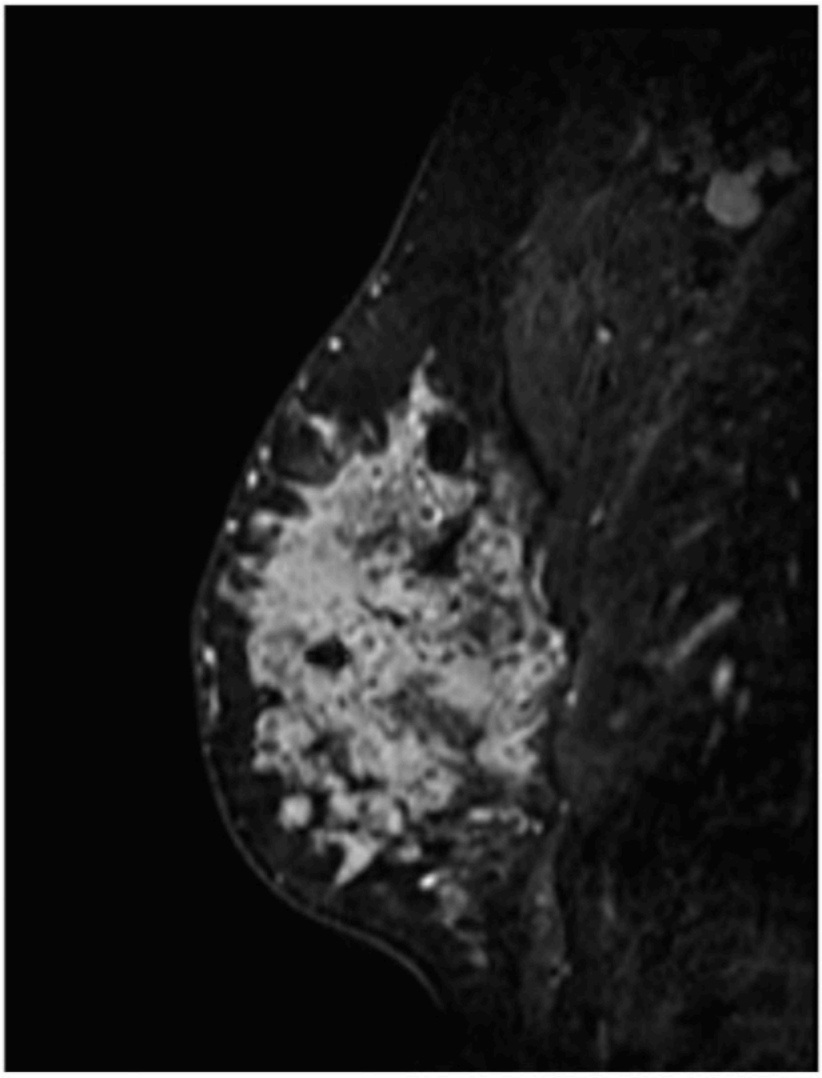

Figure 4 – Diffuse CLUSTERED RING NME. Fat-suppressed early post-contrast T1W image. Pathology: DCIS.

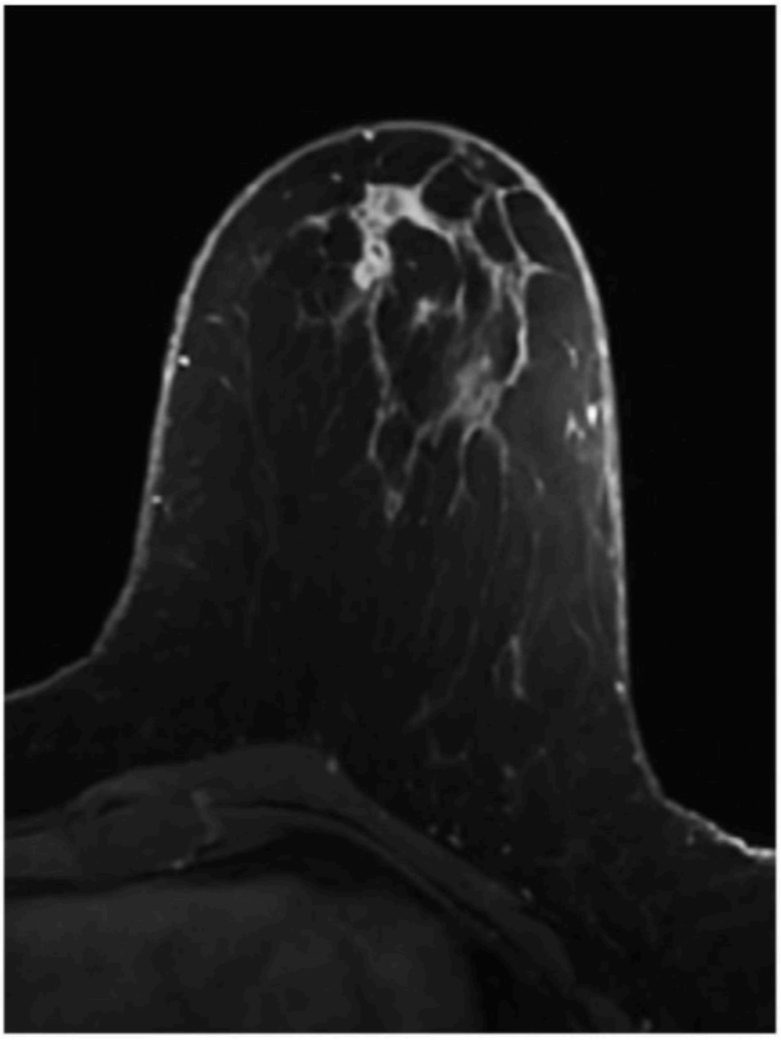

Figure 5 – Focal CLUSTERED RING NME. Fat-suppressed early post-contrast T1W image. Pathology: Granulomatous mastitis.

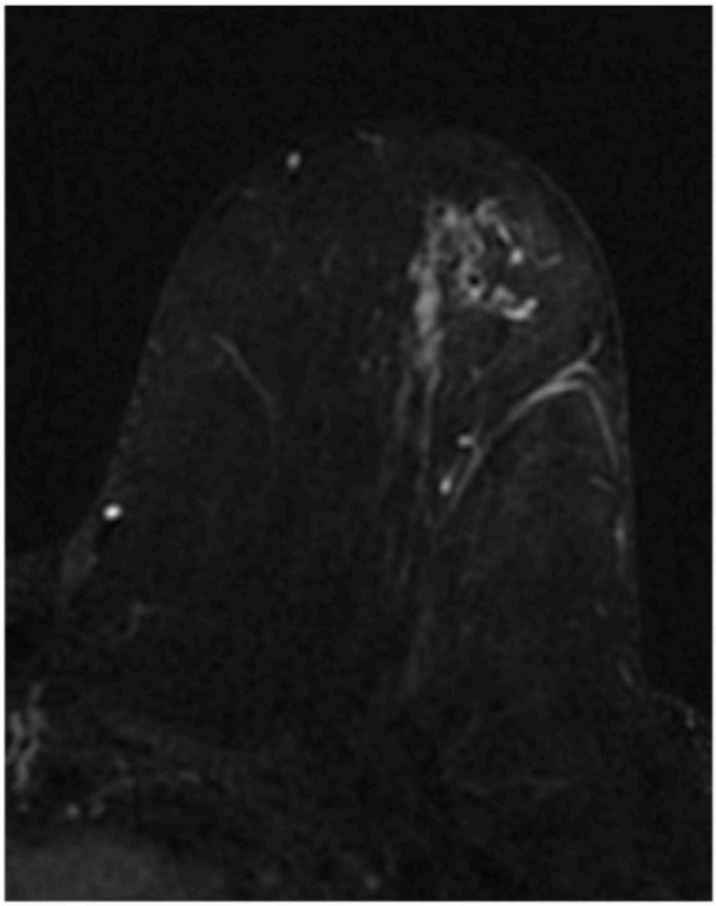

Figure 6 – Focal CLUSTERED RING NME. Early post-contrast T1W subtracted image. Pathology: Usual ductal hyperplasia.

E. ENHANCEMENT KINETICS

Enhancement kinetics may be helpful in assessment of MRI findings for which the morphology is not definitively benign or suspicious, and should be reported when the kinetic pattern influences assessment. Kinetic features should not be used as the primary criteria for identification or characterization of MRI findings. When no unique enhancing MRI finding is present, no kinetic assessment is needed.

For clinical breast MRI, semi-quantitative kinetic assessments describing early (previously "initial") and delayed phases are reported. Early phase contrast enhancement describes the enhancement-related signal intensity that occurs in the first 60–120 seconds after contrast injection, and in particular the change in intensity comparing the early time point to the pre-contrast time point. Delayed phase contrast enhancement describes the enhancement-related signal intensity that occurs after the first 60–120 seconds after contrast injection or when the curve begins to change, and in particular the change in intensity comparing the delayed time point to the early post-contrast time point. The term "initial" was replaced in this version of the Manual because newer "faster" sequences are now available which image at initial timepoints prior to the early phases used in standard imaging.

Many findings have mixed enhancement kinetics. The most suspicious (not most predominant) enhancement types in the early and delayed phase should be reported, because the most suspicious enhancement has been shown to be the most predictive of malignancy [8]. For example, for a finding with early phase fast and medium enhancement, the early phase kinetics should be reported as fast because it is the most suspicious of the early phase enhancement types.

Kinetics are assessed visually and/or using signal time intensity curves generated manually and/or by computer aided evaluation (CAE) systems. CAE system-generated color maps better demonstrate heterogeneity than manually generated signal time intensity curves but are not required for kinetics analysis. CAE generated color maps are not consistent across vendors, and familiarity with the individual colorization for a particular vendor is important for use.

Chart 1. Kinetic Analysis - Signal Intensity (SI)/Time Curve Description

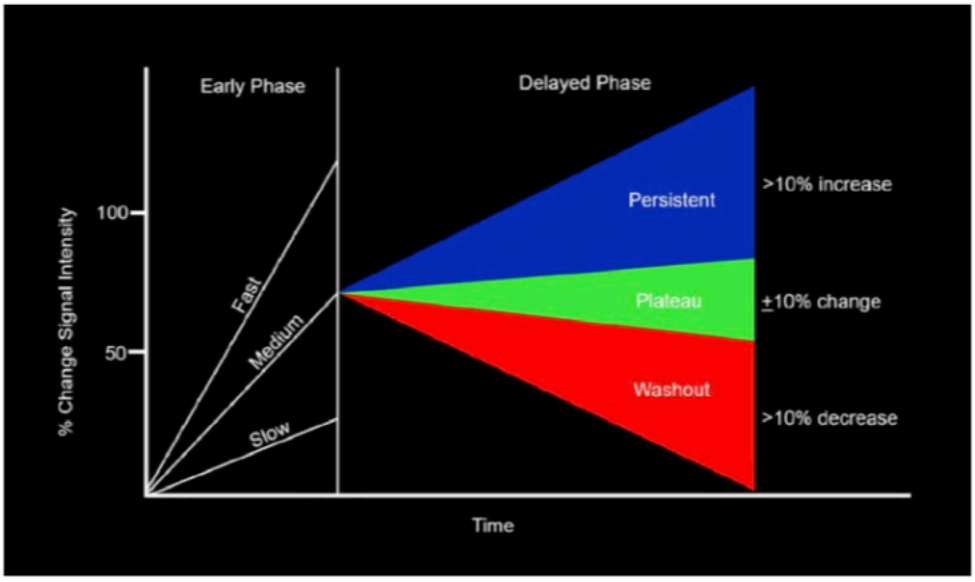

Color coding is performed of the delayed phase on a pixel-by-pixel analysis. If a pixel's signal intensity increases (persistent) or decreases (washout) by > 10%, different colors are assigned to the pixels. If the signal intensity does not change more than 10% (plateau) in either direction, then it is coded a different color. Delayed phase in this example has been coded as blue for persistent, green for plateau, and red for washout.

E. ENHANCEMENT KINETICS

1. EARLY PHASE

   The enhancement-related signal intensity that occurs in the first 60–120 seconds after contrast injection, and in particular the change in intensity comparing the early time point to the pre-contrast time point.

   a. Slow — < 50% increase in signal intensity

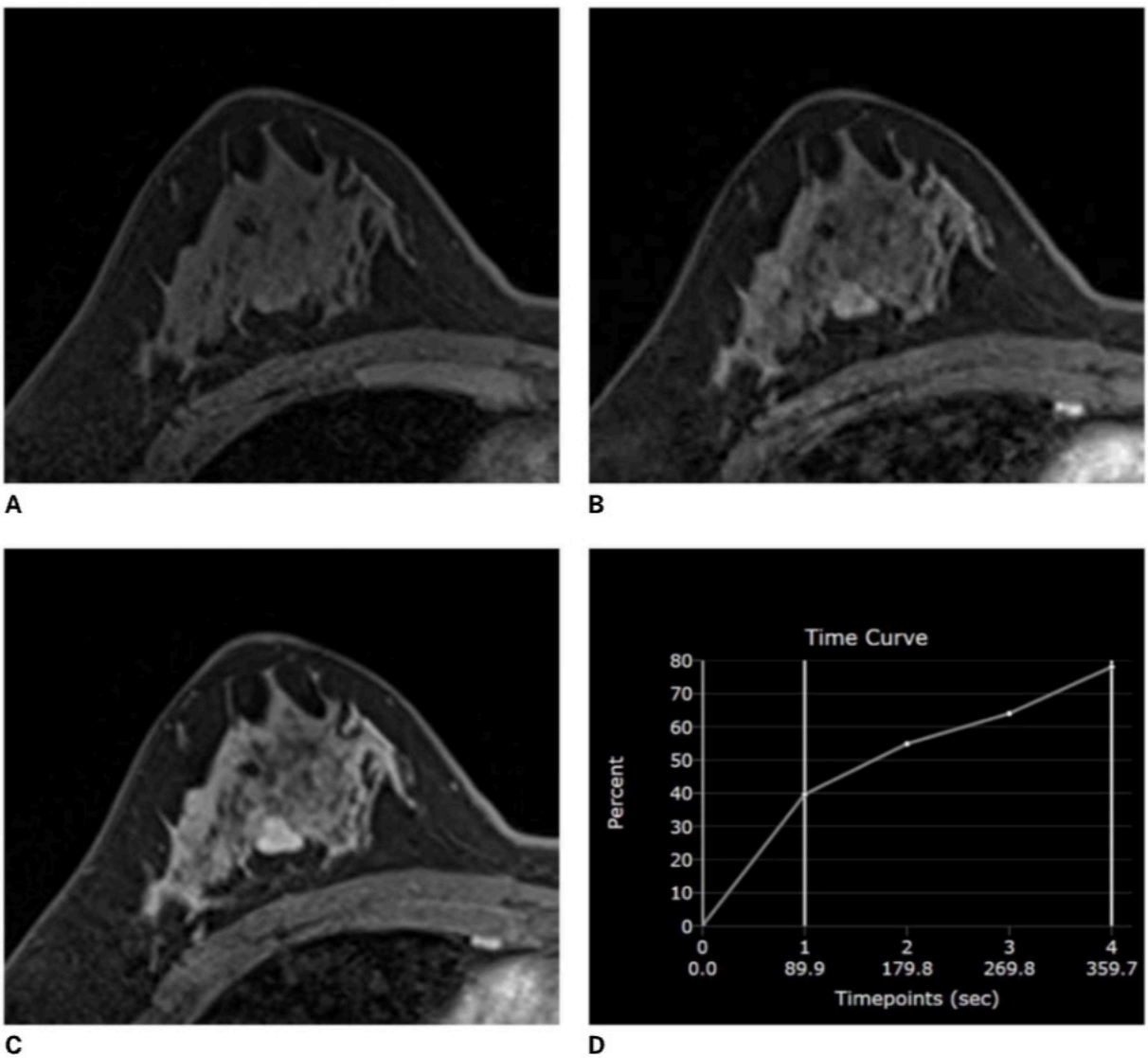

Figure 1 – EARLY PHASE: SLOW. Slow early and persistent delayed phase kinetics. (A) Fat-suppressed non-contrast T1W image. (B) Fat-suppressed early post-contrast T1W image. (C) Fat-suppressed delayed post-contrast T1W image. (D) Graph of the kinetic curve. Etiology: Stable, presumed fibroadenoma.

E. ENHANCEMENT KINETICS

1. EARLY PHASE

   b. Medium — 50%–100% increase in signal intensity

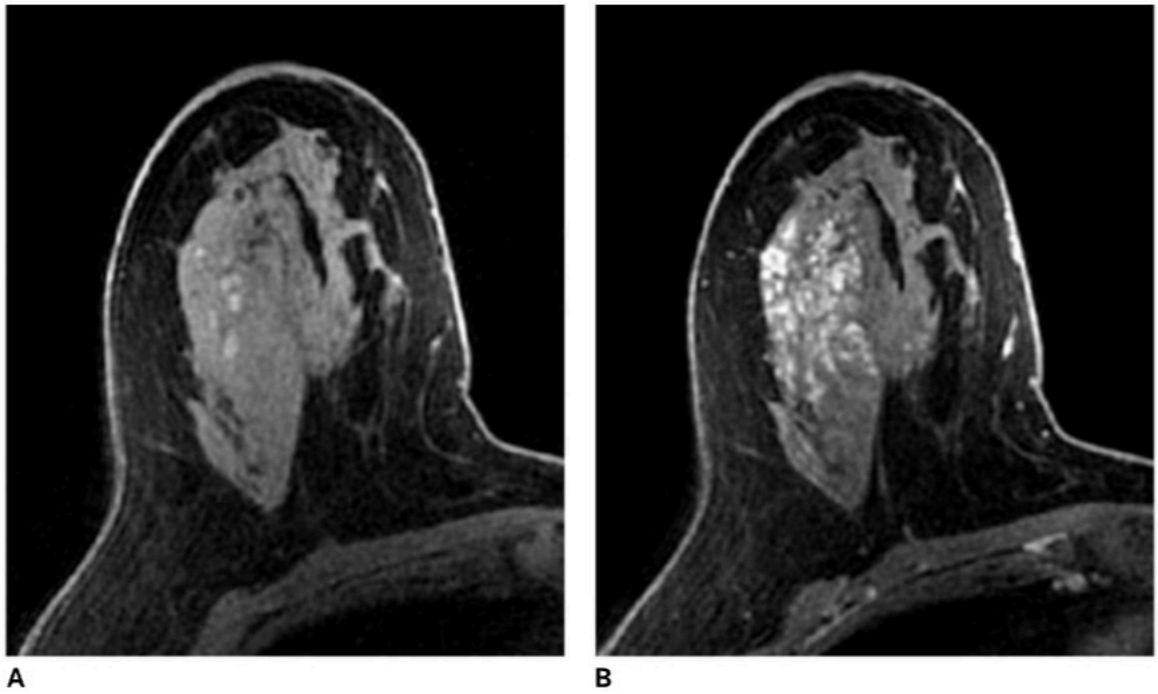

A B

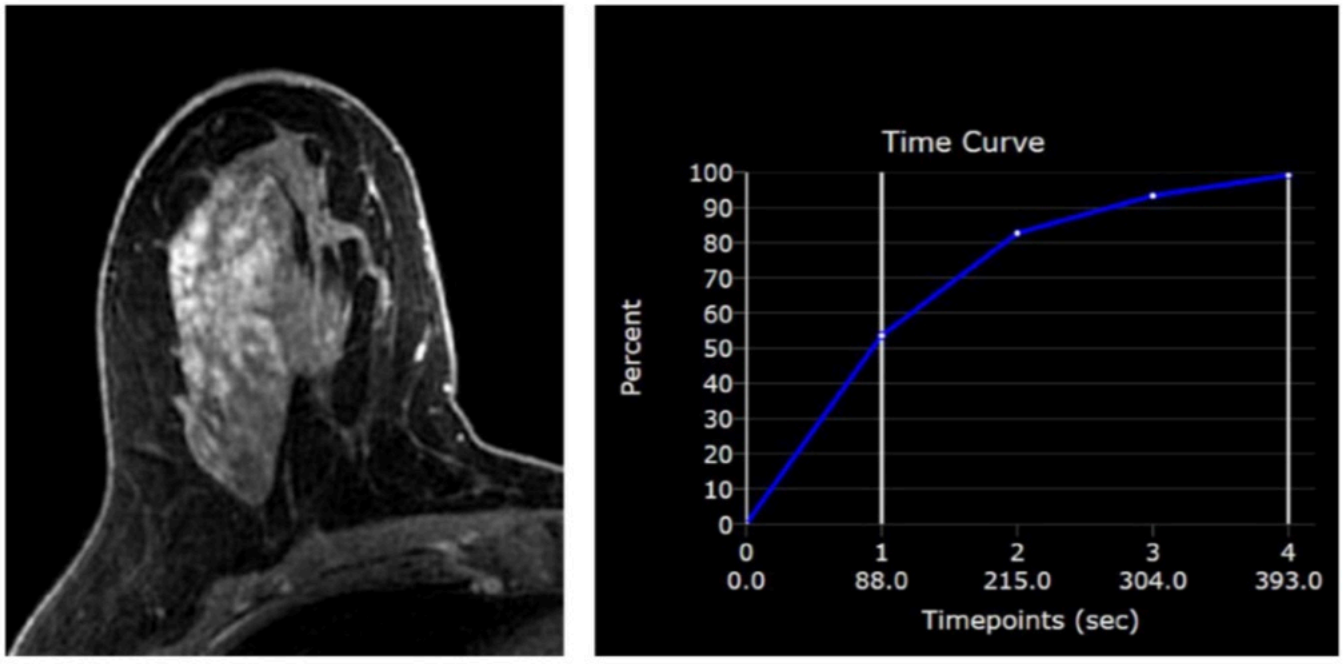

C D

Figure 2 – EARLY PHASE: MEDIUM. Medium early and persistent delayed phase kinetics. (A) Fat-suppressed non-contrast T1W image. (B) Fat-suppressed early post-contrast T1W image. (C) Fat-suppressed delayed post-contrast T1W image. (D) Graph of the kinetic curve. Pathology: Pseudoangiomatous stromal hyperplasia (PASH).

E. ENHANCEMENT KINETICS

1. EARLY PHASE

   c. Fast — > 100% increase in signal intensity

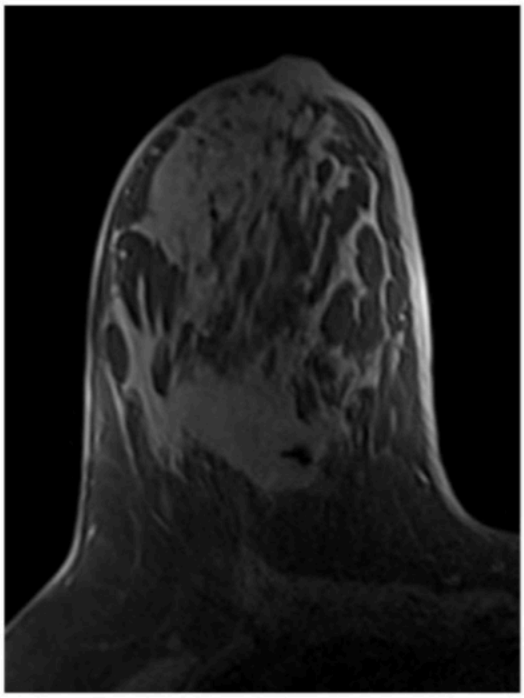

A

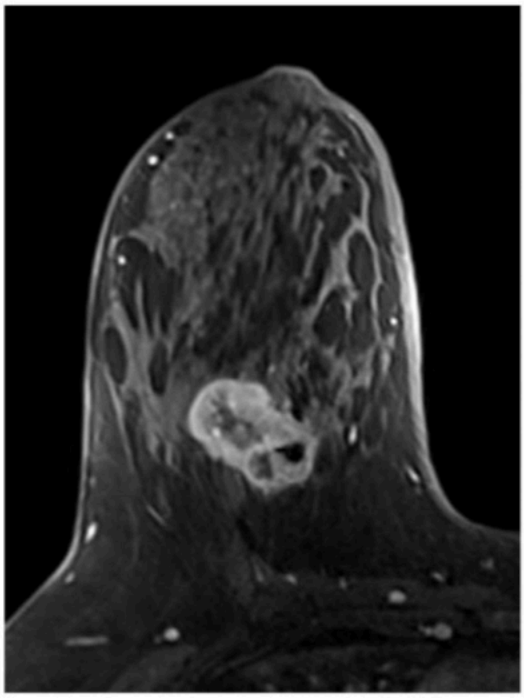

B

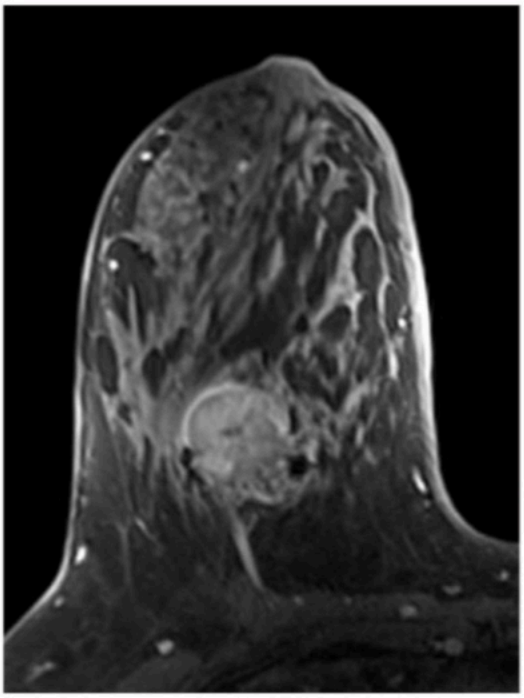

C

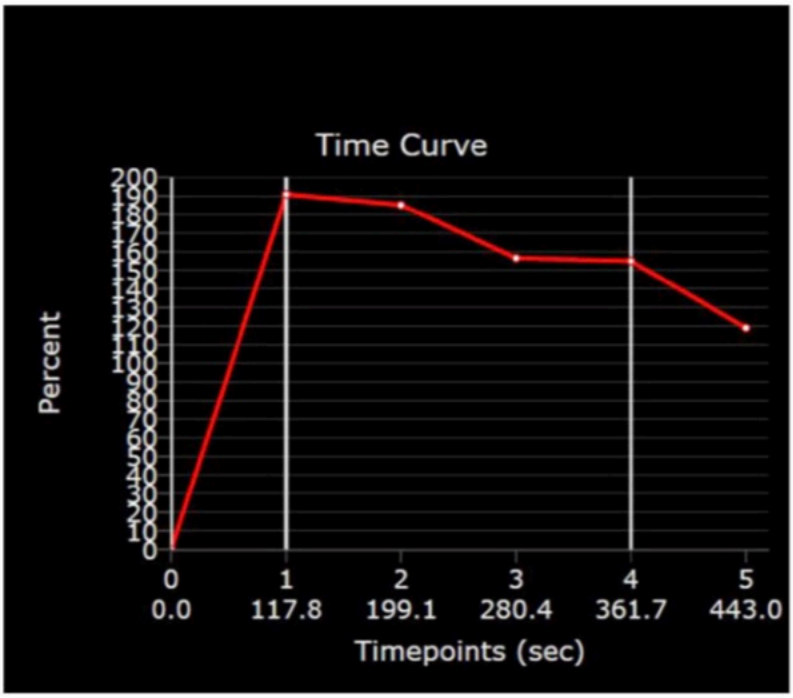

D

Figure 3 – EARLY PHASE: FAST. Fast early and washout delayed phase enhancement. (A) Fat-suppressed non-contrast T1W image. (B) Fat-suppressed early post-contrast T1W image. (C) Fat-suppressed delayed post-contrast T1W image. (D) Graph of the kinetic curve. Pathology: Invasive ductal carcinoma.

E. ENHANCEMENT KINETICS

2. DELAYED PHASE

Delayed phase color coding is performed using a pixel-by-pixel analysis of the signal intensity change from the early phase to the delayed phase. Pixels are color coded according to persistent (> 10% increase in signal intensity), washout (> 10% decrease in signal intensity) and plateau (increase or decrease not > 10%) categories.

a. Persistent

Signal intensity increases > 10% compared to early phase signal intensity. Although "Type 1 curve" has been used historically by some for this pattern, it is not a BI-RADS term and its use is discouraged for clinical reporting.

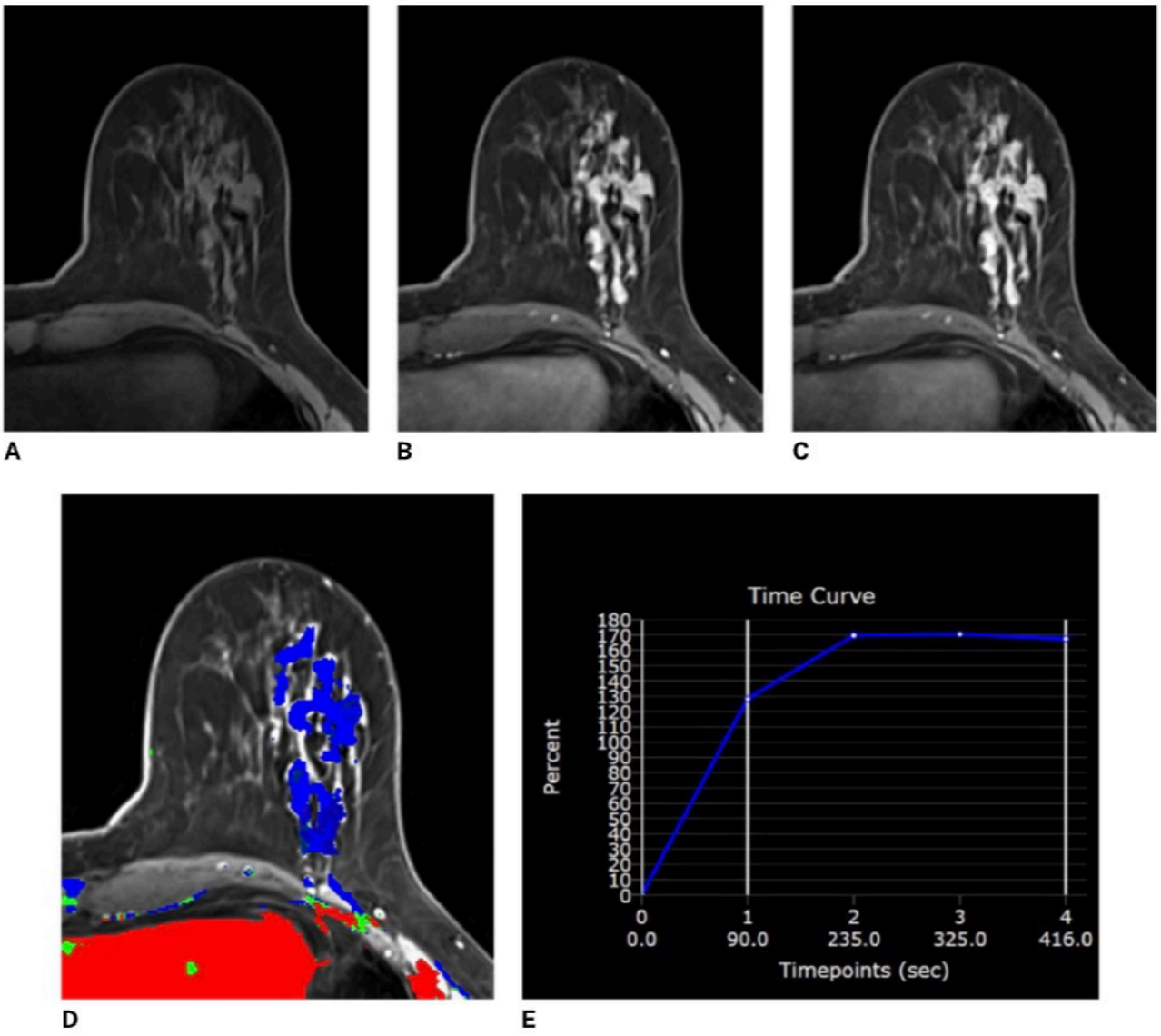

Figure 1 – DELAYED PHASE: PERSISTENT. Fast early and PERSISTENT delayed phase enhancement. (A) Fat-suppressed non-contrast T1W image. (B) Fat-suppressed early post-contrast T1W image. (C) Fat-suppressed delayed post-contrast T1W image. (D) Color map with blue overlay indicating PERSISTENT delayed phase kinetics. (E) Graph of the kinetic curve. Pathology: DCIS.

E. ENHANCEMENT KINETICS

2. DELAYED PHASE

b. Plateau —

Signal intensity increases or decreases ≤ 10% from early phase signal intensity. Although "Type 2 curve" has been used historically by some for this pattern it is not a BI-RADS term and its use is discouraged for clinical reporting.

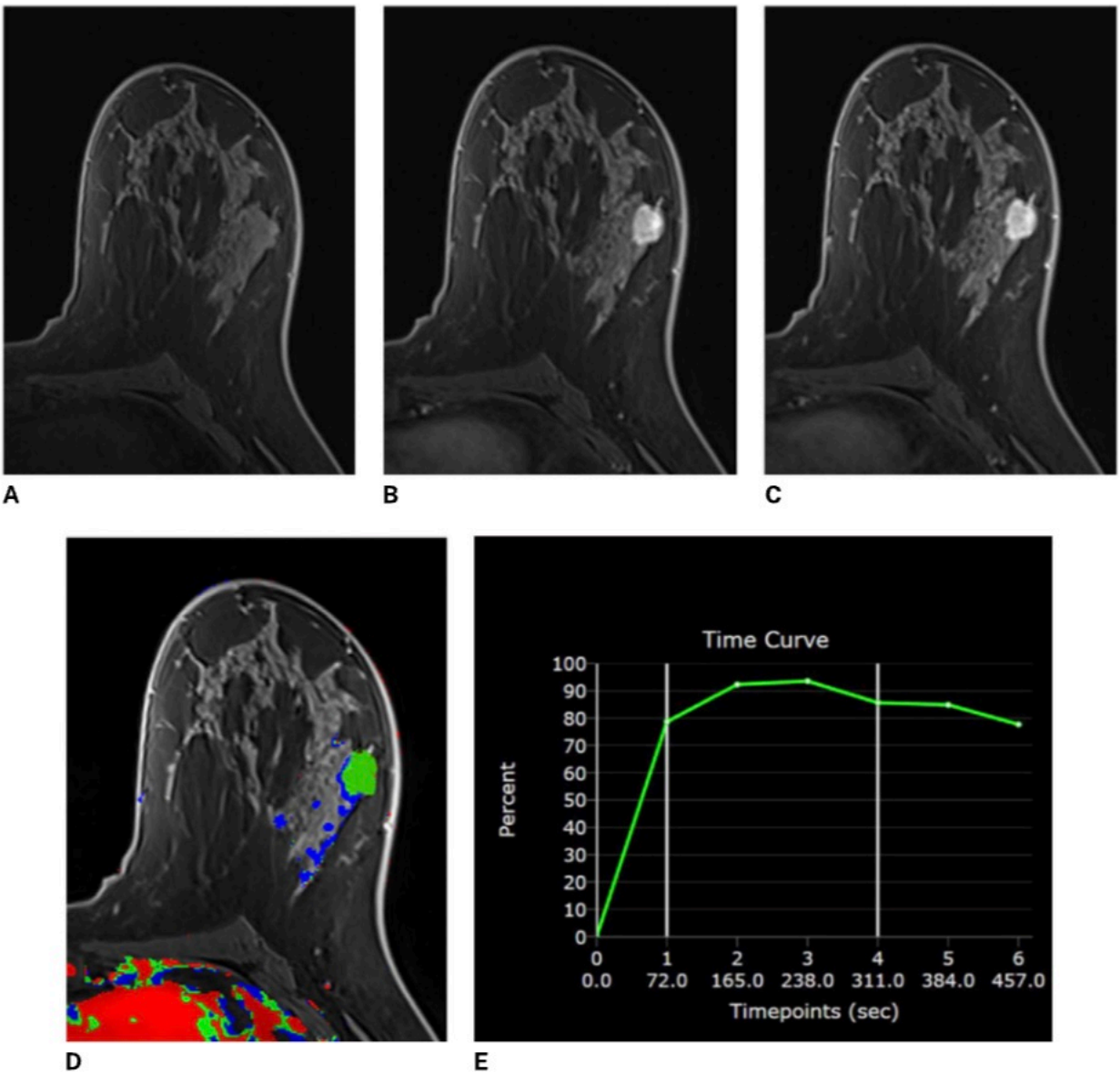

Figure 2 – DELAYED PHASE: PLATEAU. Medium early and PLATEAU delayed phase enhancement. (A) Fat-suppressed non-contrast T1W image. (B) Fat-suppressed early post-contrast T1W image. (C) Fat-suppressed delayed post-contrast T1W image. (D) Color map with green overlay indicating PLATEAU delayed phase kinetics. (E) Graph of the kinetic curve. Pathology: Invasive ductal carcinoma.

E. ENHANCEMENT KINETICS

2. DELAYED PHASE

c. Washout

Signal intensity decreases > 10% after the early enhancement. This is the most suspicious delayed phase kinetics category. Although "Type 3 curve" has been used historically by some for this pattern it is not a BI-RADS term and its use is discouraged for clinical reporting.

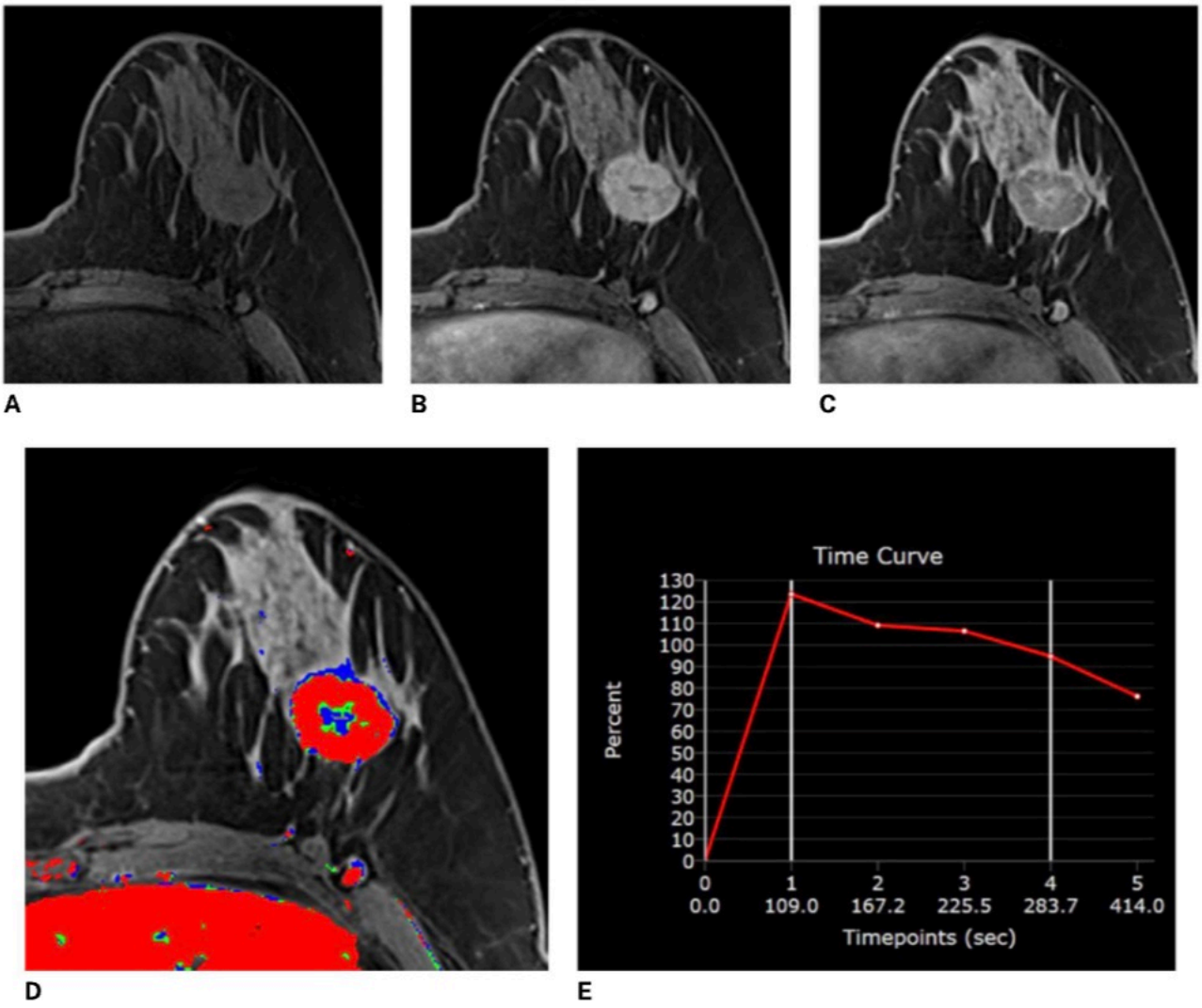

Figure 3 – DELAYED PHASE: WASHOUT. Fast early and WASHOUT delayed phase enhancement. (A) Fat-suppressed non-contrast T1W image. (B) Fat-suppressed early post-contrast T1W image. (C) Fat-suppressed delayed post-contrast T1W image. (D) Color map with red overlay, indicating WASHOUT delayed phase kinetics. (E) Graph of the kinetic curve. Pathology: Invasive ductal carcinoma.

F. LYMPH NODES

1. INTRAMAMMARY LYMPH NODES

Intramammary lymph nodes frequently occur in the lateral and usually upper portions of the breast, although they may occur anywhere in the breast. They are usually adjacent to a vein because the lymphatic drainage of the breast parallels the venous drainage.

a. Normal

Normal intramammary lymph nodes are circumscribed, reniform, homogeneously enhancing and typically T2 hyperintense. Because they are often small it may be difficult to discern fat within their hila.

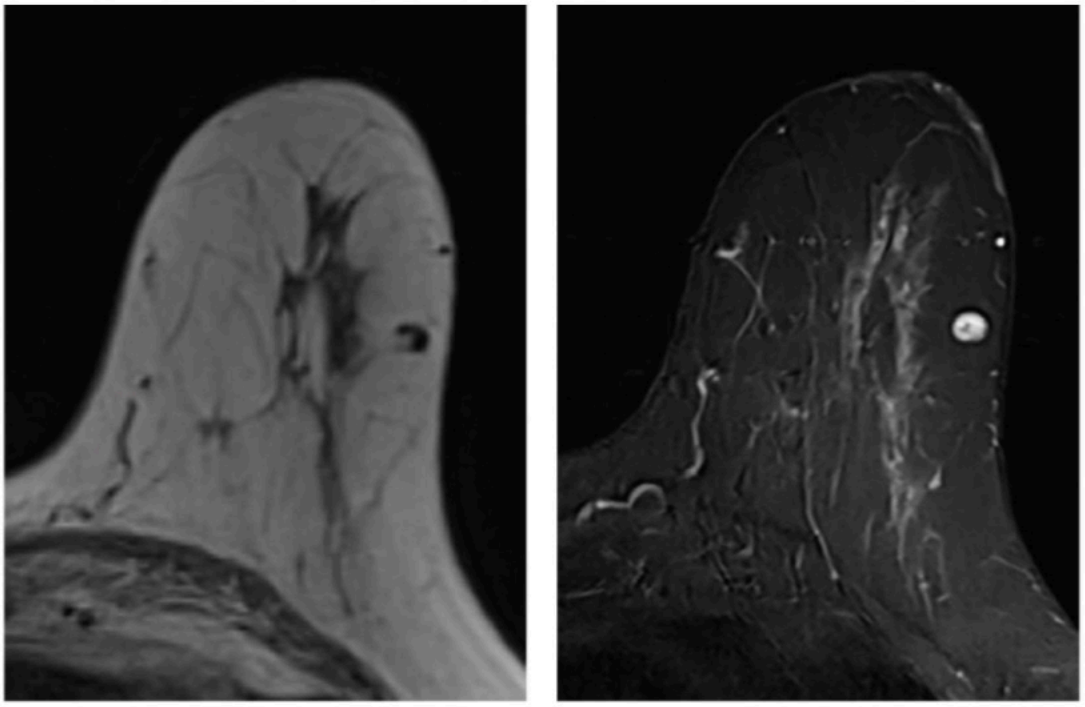

A B

Figure 1 – INTRAMAMMARY LYMPH NODE: NORMAL. Normal left intramammary lymph node. (A) Non-fat-suppressed non-contrast T1W image. (B) Fat-suppressed T2W image.

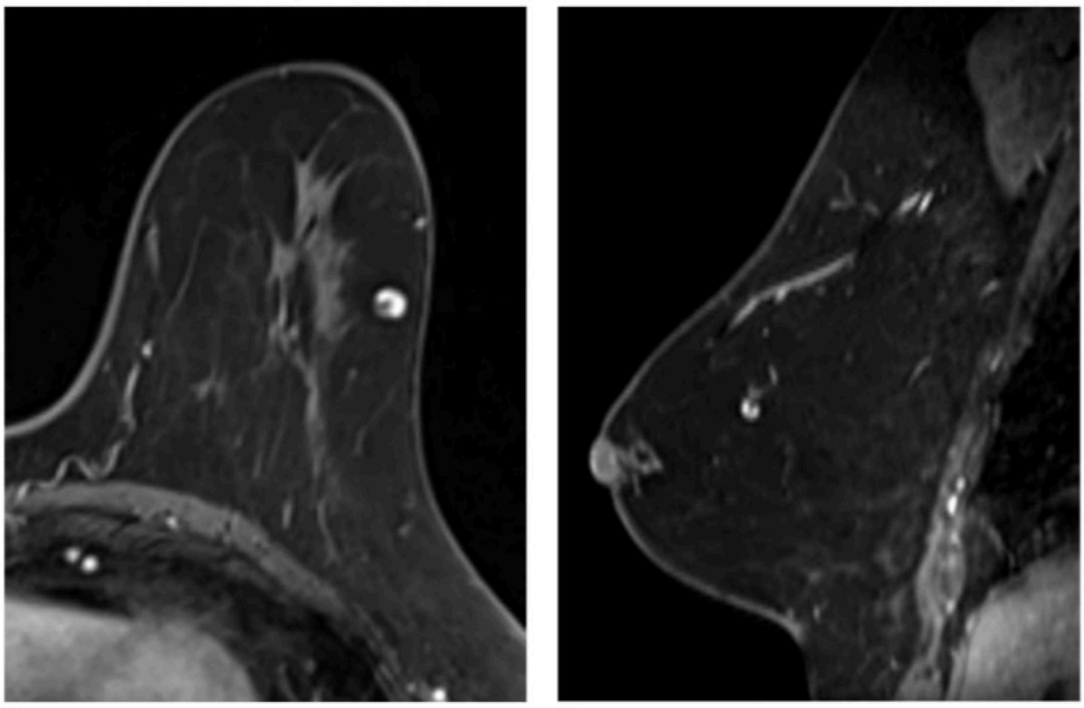

C D

Figure 1 – *(Continued)* INTRAMAMMARY LYMPH NODE: NORMAL. Normal left intramammary lymph node. Fat-suppressed early post-contrast T1W (C) axial and (D) sagittal images.

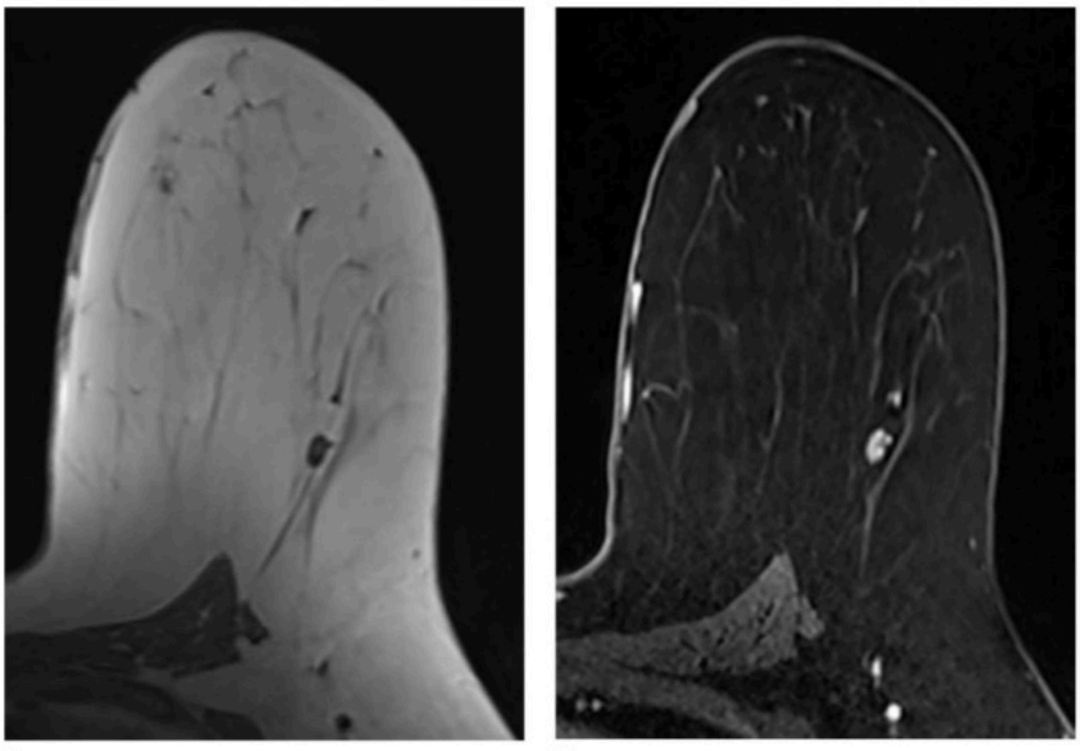

A B

Figure 2 – INTRAMAMMARY LYMPH NODE: NORMAL. Normal left intramammary lymph node. (A) Non-fat-suppressed non-contrast T1W image. (B) Fat-suppressed early post-contrast T1W image.

F. LYMPH NODES

1. INTRAMAMMARY LYMPH NODES

b. Abnormal

Abnormal intramammary lymph nodes are subjectively enlarged compared to expected size. However, there is no established breast MRI size or cortical thickness threshold to distinguish benign from suspicious intramammary lymph nodes. Suspicious features include an increase in size compared to older examinations and a non-circumscribed margin. For larger lymph nodes the absence of a fatty hila may signal that they are abnormal. When deciding if a lymph node is abnormal, using older mammogram and/or ultrasound examinations to assess stability can be helpful.

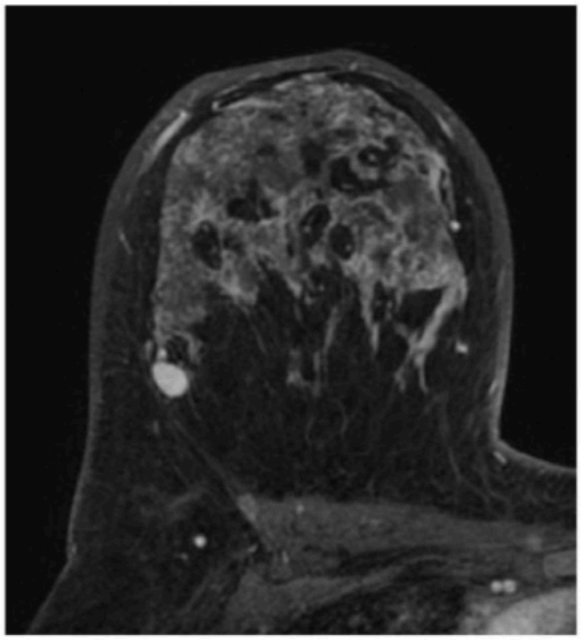

Figure 1 – INTRAMAMMARY LYMPH NODE: ABNORMAL. Abnormal right intramammary lymph node. The node has lost its reniform shape. Fat-suppressed early post-contrast T1W image.

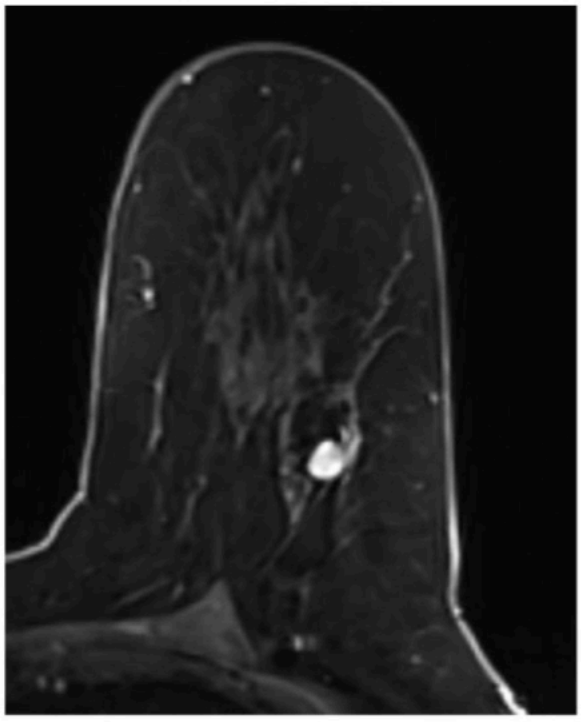

Figure 2 – INTRAMAMMARY LYMPH NODE: ABNORMAL. Abnormal left intramammary lymph node. Fat-suppressed early post-contrast T1W image.

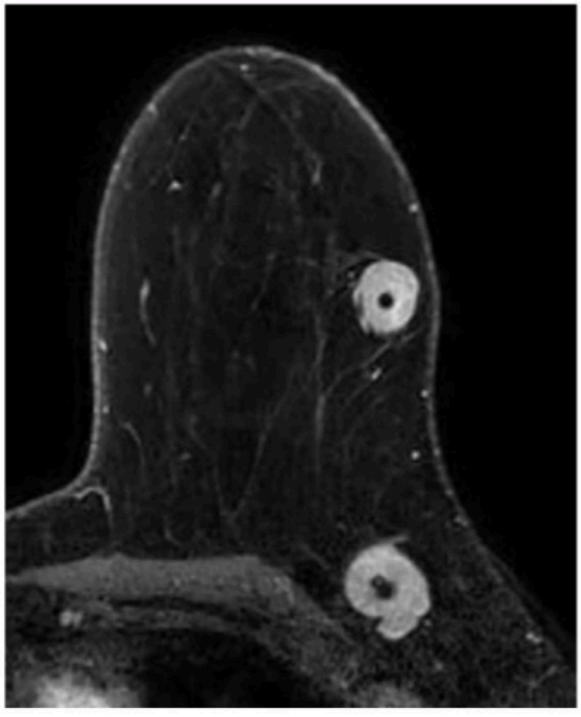

Figure 3 – INTRAMAMMARY LYMPH NODE: ABNORMAL. Abnormal left intramammary (anterior) and level I axillary (posterior) lymph nodes with biopsy markers (causing signal voids). Fat-suppressed early post-contrast T1W image. Pathology: Metastatic lymph nodes.

F. LYMPH NODES

2. AXILLARY LYMPH NODES

Axillary lymph nodes are categorized into anatomic levels based on their relationship to the pectoralis minor muscle. Lymph nodes that are lateral to the lateral margin of the pectoralis minor muscle are level I, lymph nodes that are anterior or posterior to the pectoralis minor muscle are level II, and lymph nodes that are medial to the pectoralis minor muscle are level III (sometimes referred to as infraclavicular). Level II lymph nodes are typically posterior to the pectoralis minor muscle but may lie between pectoralis major and minor muscles, referred to as interpectoral or Rotter's lymph nodes. Most frequently, metastatic disease progresses sequentially from level I to level II to level III, although there are exceptions. Surgical staging procedures typically include level I (sentinel lymph node biopsy and axillary lymph node dissection) and level II lymph nodes (axillary lymph node dissection) but do not usually include level III lymph nodes unless there is a clinical reason.

a. Normal

Normal axillary lymph nodes are circumscribed, reniform, homogeneously enhancing and typically T2 hyperintense. They are subjectively symmetric in size and cortical thickness compared to other ipsilateral or contralateral axillary lymph nodes. Lobulation of a thin cortex is a normal finding. Fatty hila are typically visible but may not be perceptible in smaller lymph nodes. Enhancement kinetics of early fast and delayed washout are typical in normal lymph nodes and are not suspicious features. There are no validated quantitative lymph node features to distinguish benign from suspicious axillary lymph nodes on breast MRI. In particular, a cortical thickness > 3 mm (as may be used as a threshold on ultrasound) is not applicable to breast MRI, as many normal lymph nodes have this appearance on MRI including due to partial volume averaging.

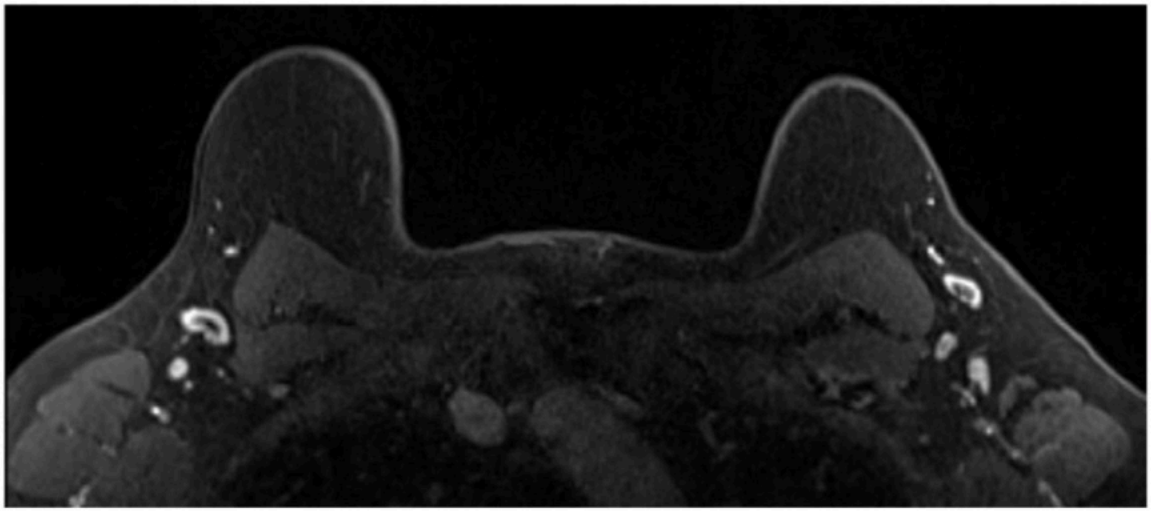

Figure 1 – AXILLARY LYMPH NODES: NORMAL. Normal bilateral axillary lymph nodes with reniform shapes and symmetric size and cortical thickness. Fat-suppressed early post-contrast T1W image.

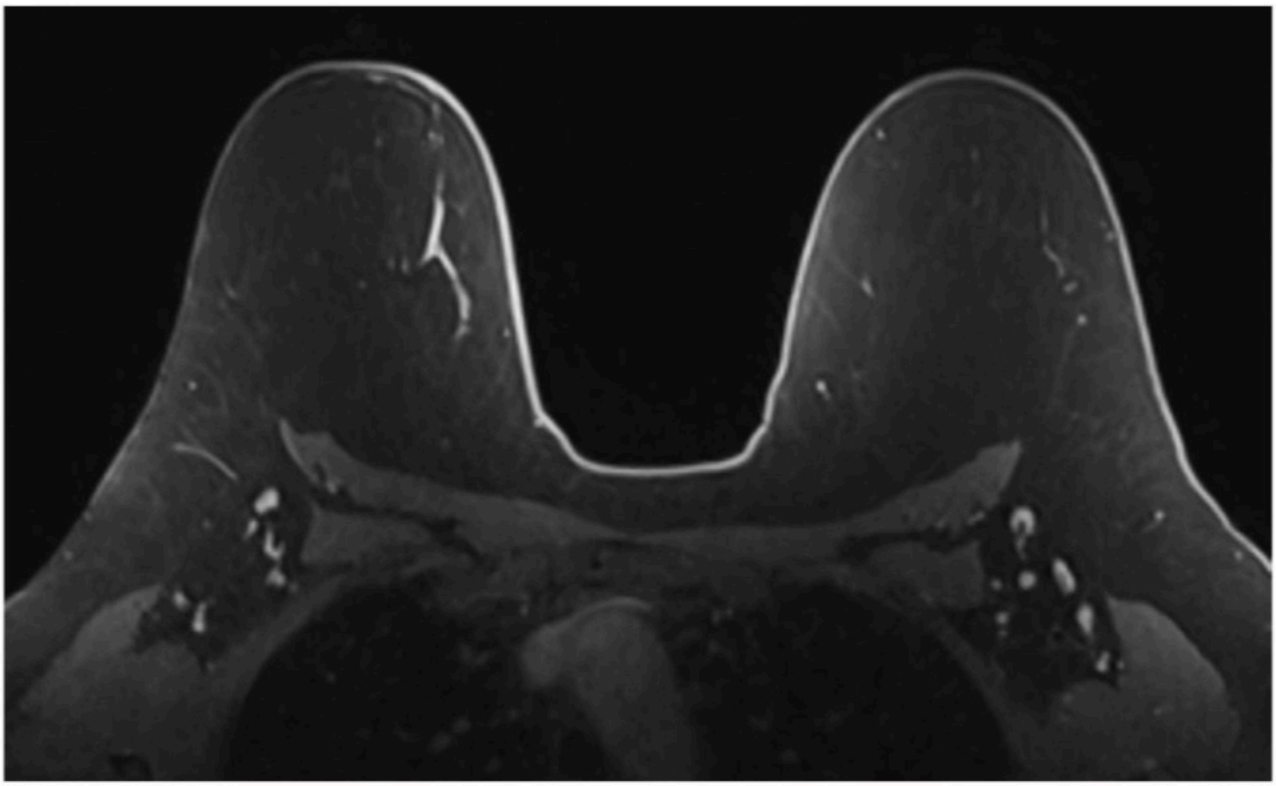

Figure 2 – AXILLARY LYMPH NODES: NORMAL. Fat-suppressed early post-contrast T1W image.

F. LYMPH NODES

2. AXILLARY LYMPH NODES

b. Abnormal

Abnormal axillary lymph nodes are subjectively asymmetric in cortical thickness compared to other ipsilateral or contralateral axillary lymph nodes, or have significantly increased in size or cortical thickness compared to a prior exam. Abnormal cortical thickening may be focal or diffuse. Other potentially abnormal features include loss of reniform shape (rounding) and absence of fatty hila, but these may be present in normal smaller lymph nodes and in general should not be used as the only criteria for describing lymph nodes as abnormal. There are no validated quantitative lymph node features to distinguish benign from suspicious axillary lymph nodes on breast MRI. In particular, a cortical thickness > 3 mm (as may be used as a threshold on ultrasound) is not applicable to breast MRI, as many normal lymph nodes have this appearance on MRI including due to partial volume averaging.

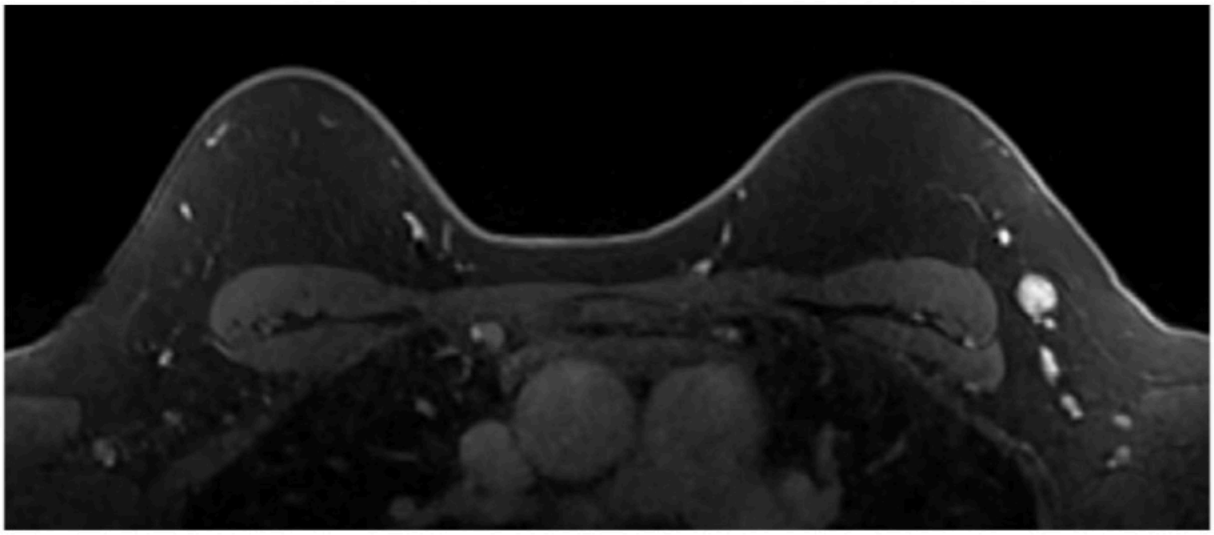

Figure 1 – AXILLARY LYMPH NODES: ABNORMAL. Abnormal left level I axillary lymph node. The node size and cortical thickness are larger than for other axillary lymph nodes. Fat-suppressed early post-contrast T1W image. Pathology: Metastatic breast carcinoma.

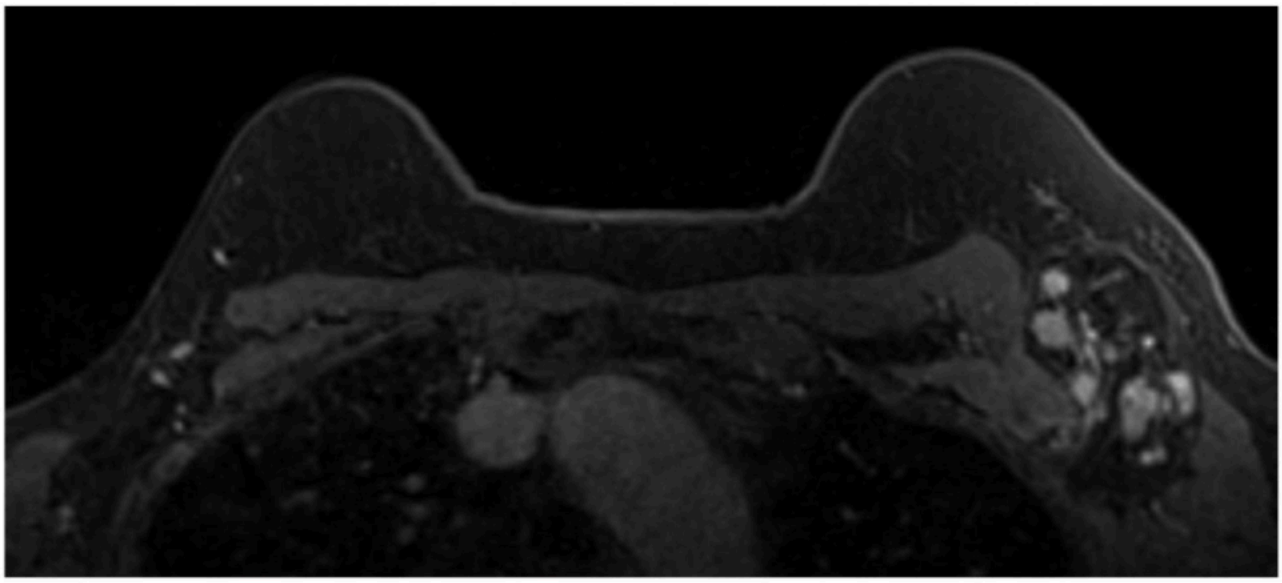

Figure 2 – AXILLARY LYMPH NODES: ABNORMAL. Abnormal left level 1 axillary lymph nodes. The node sizes and cortical thicknesses are larger than for other axillary lymph nodes. Fat-suppressed early post-contrast T1W image. Pathology: Benign, reactive after recent vaccination in left arm.

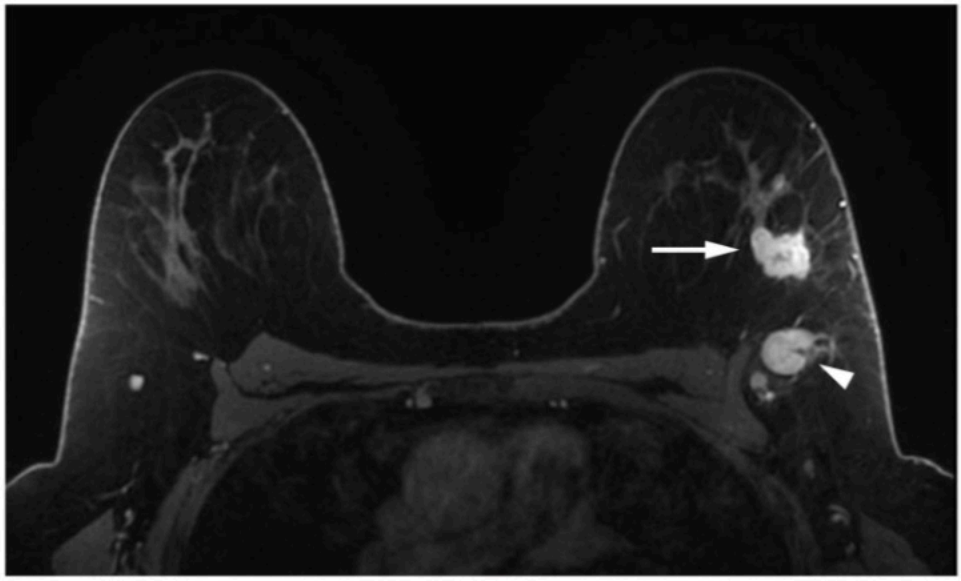

Figure 3 – AXILLARY LYMPH NODES: ABNORMAL. Abnormal left level I axillary lymph node (arrowhead) and ipsilateral invasive ductal carcinoma (arrow). Fat-suppressed early post-contrast T1W image. Pathology: Metastatic breast carcinoma.

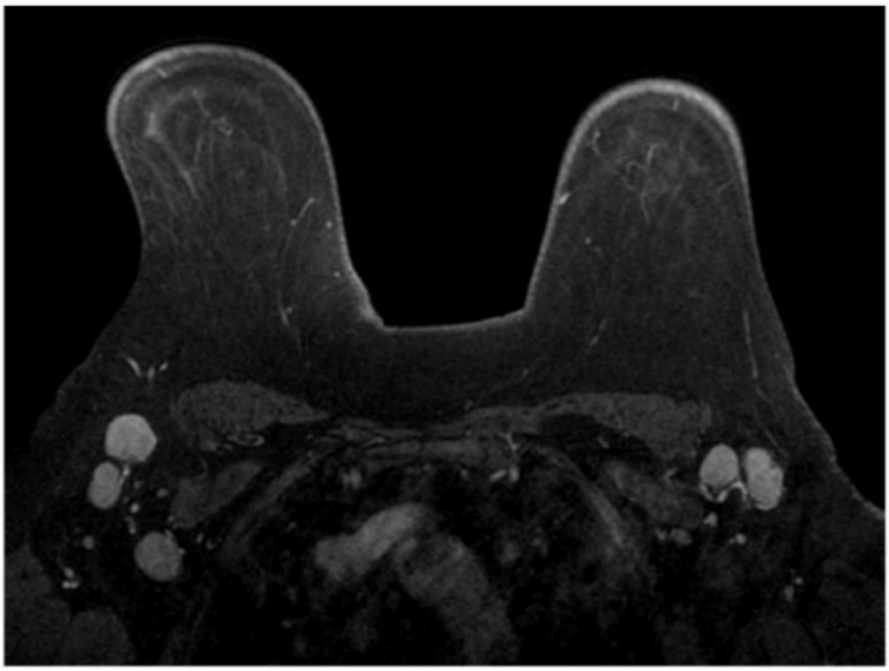

Figure 4 – AXILLARY LYMPH NODES: ABNORMAL. Abnormal bilateral level I axillary lymph nodes. The node sizes and cortical thicknesses are larger than usual for axillary lymph nodes. Fat-suppressed early post-contrast T1W image. Pathology: Benign, reactive.

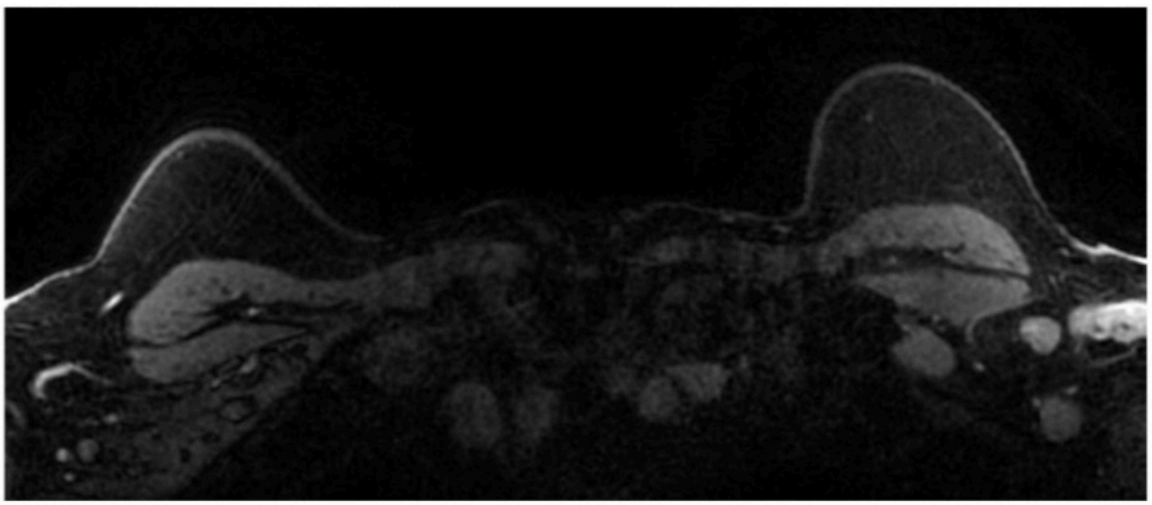

Figure 5 – AXILLARY LYMPH NODES: ABNORMAL. Abnormal left level I and II axillary lymph nodes. The node sizes and cortical thicknesses are larger than for other axillary lymph nodes. Fat-suppressed early post-contrast T1W image.

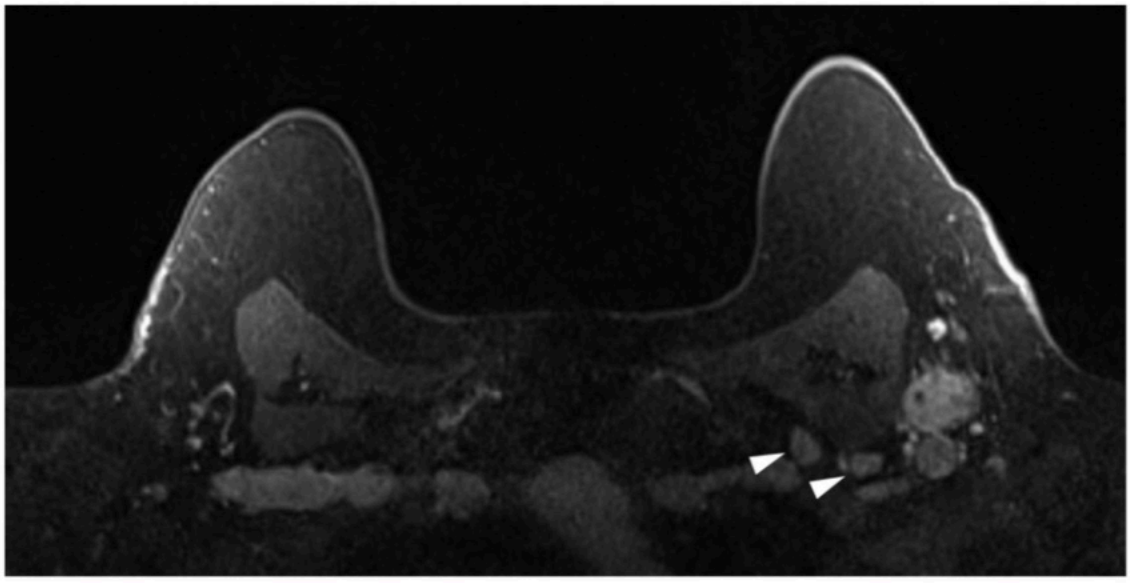

Figure 6 – AXILLARY LYMPH NODES: ABNORMAL. Abnormal left level I and II (arrowheads) axillary lymph nodes. Fat-suppressed early post-contrast T1W image.

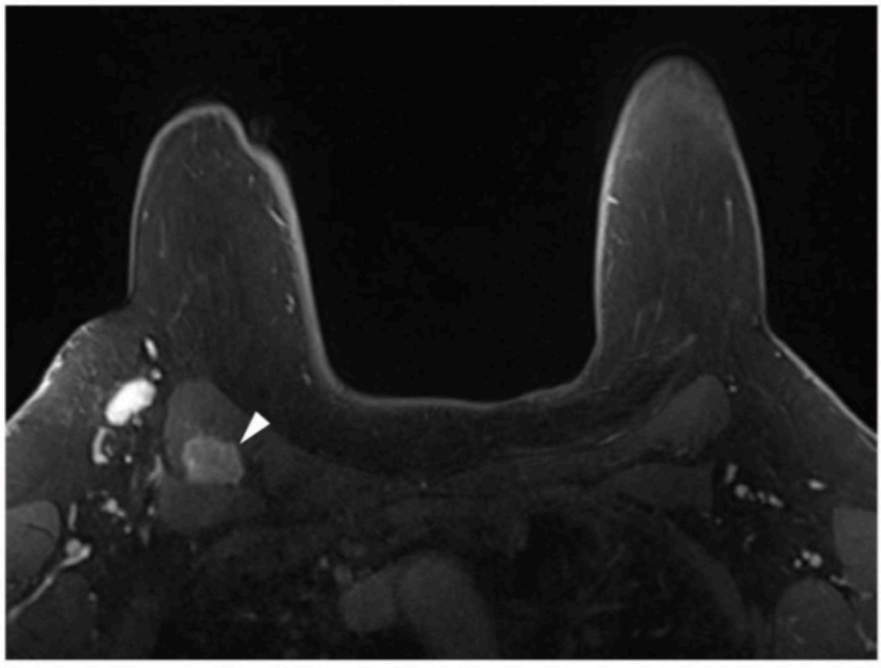

Figure 7 – AXILLARY LYMPH NODES: ABNORMAL. Abnormal right level I and II axillary lymph nodes. Note the right interpectoral or Rotter's node (level II) (arrowhead). Fat-suppressed early post-contrast T1W image.

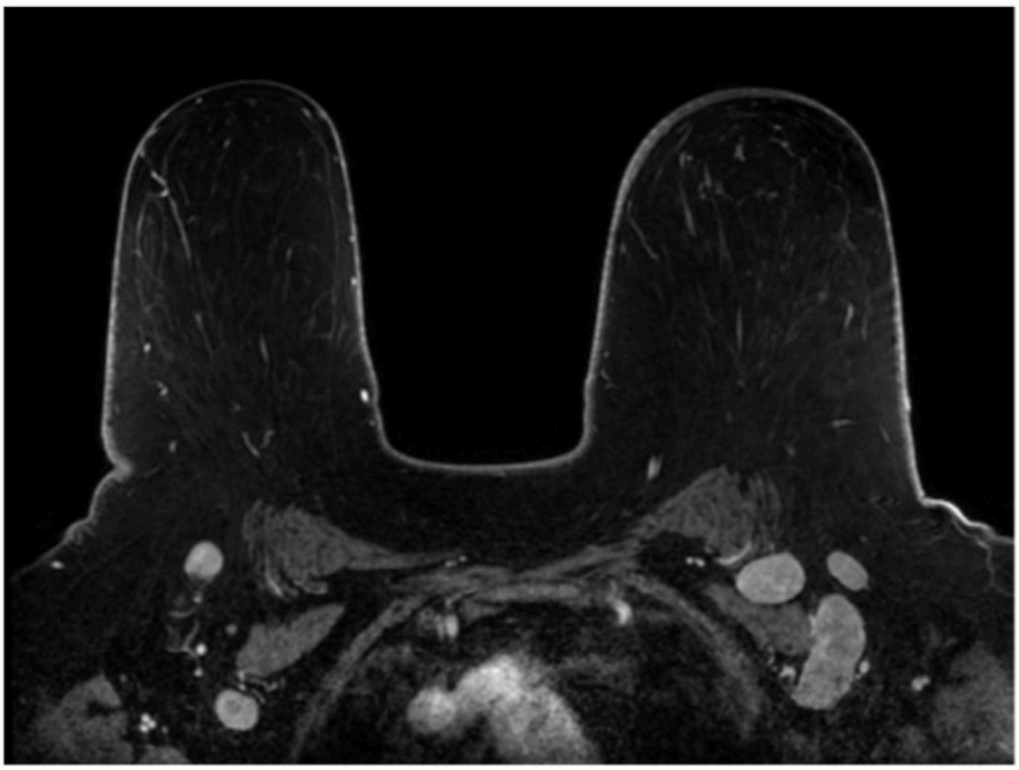

Figure 8 – AXILLARY LYMPH NODES: ABNORMAL. Abnormal bilateral level I and level II axillary lymph nodes. Note the left level II interpectoral or Rotter's lymph node. Fat-suppressed early post-contrast T1W image.

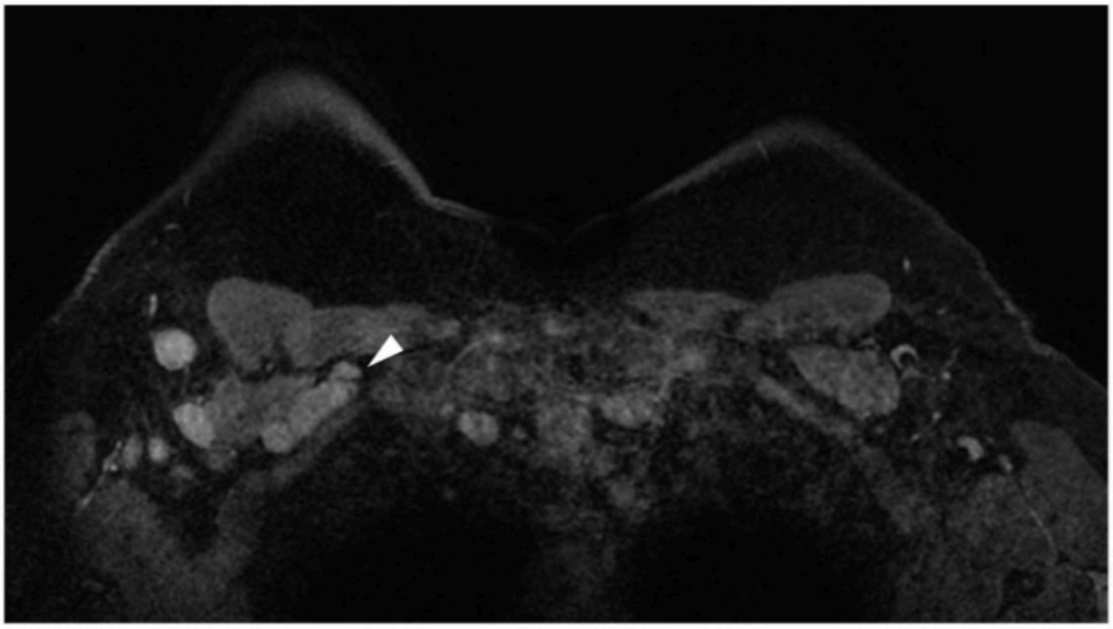

Figure 9 – AXILLARY LYMPH NODES: ABNORMAL. Abnormal level I, II, and III (arrowhead) right axillary lymph nodes. Fat-suppressed early post-contrast T1W image.

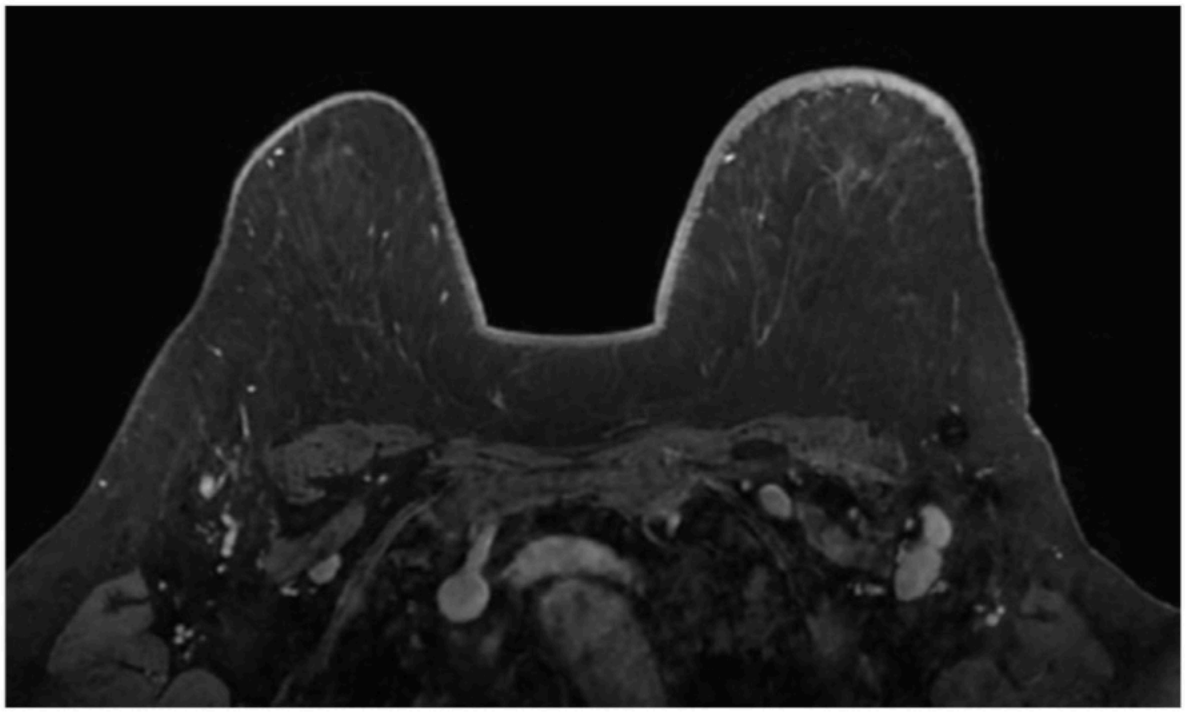

Figure 10 – AXILLARY LYMPH NODES: ABNORMAL. Abnormal left levels I and III axillary lymph nodes. Fat-suppressed early post-contrast T1W image. Pathology: Benign.

Axillary and Intramammary Lymph Node Reporting Details and Use of BI-RADS assessments:

For abnormal-appearing axillary and intramammary lymph nodes, the location or axillary level(s) involved should be described, and the approximate number of nodes involved.

For abnormal-appearing ipsilateral intramammary and axillary lymph nodes in the setting of known breast malignancy or findings suspicious for breast malignancy, the lymph nodes should be fully described but they should not be given a separate BI-RADS assessment. If not biopsy-proven metastatic, management often depends on multiple clinical factors and preferences. For abnormal-appearing axillary or intramammary lymph nodes that are an isolated finding because there is no ipsilateral known breast malignancy or findings suspicious for breast malignancy, the lymph nodes should be given a BI-RADS assessment based on the level of suspicion for lymph node malignancy.

Example wording which could be used for abnormal axillary lymph nodes in these different settings includes:

Lymph nodes known to be biopsy-proven malignant/metastatic from breast primary:

"Four abnormal-appearing lymph nodes in the level I axilla. One node confirmed malignant/metastatic disease"

Lymph nodes associated with known ipsilateral breast malignancy or suspicious breast findings but not biopsied:

"Two abnormal-appearing lymph nodes in the level I axilla. If it would change clinical management, recommend targeted ultrasound and ultrasound-guided tissue sampling."

Lymph nodes as an isolated finding:

"Four abnormal-appearing lymph nodes in the level I axilla. BI-RADS 4B — moderate suspicion for malignancy. Recommend targeted ultrasound and ultrasound-guided tissue sampling."

Lymph nodes associated with known lymphoma/CLL:

"Enlarged axillary lymph nodes bilaterally consistent with patients' history of lymphoma." BI-RADS 2.

F. LYMPH NODES

3. INTERNAL MAMMARY LYMPH NODES

a. Normal

Normal internal mammary lymph nodes are frequently seen with current MRI techniques [9], and the fact that a lymph node is visible does not make it abnormal or suspicious. In MRI screening of asymptomatic women with no history of breast cancer, normal internal mammary lymph nodes may measure up to 9–10 mm in long axis [9, 10].

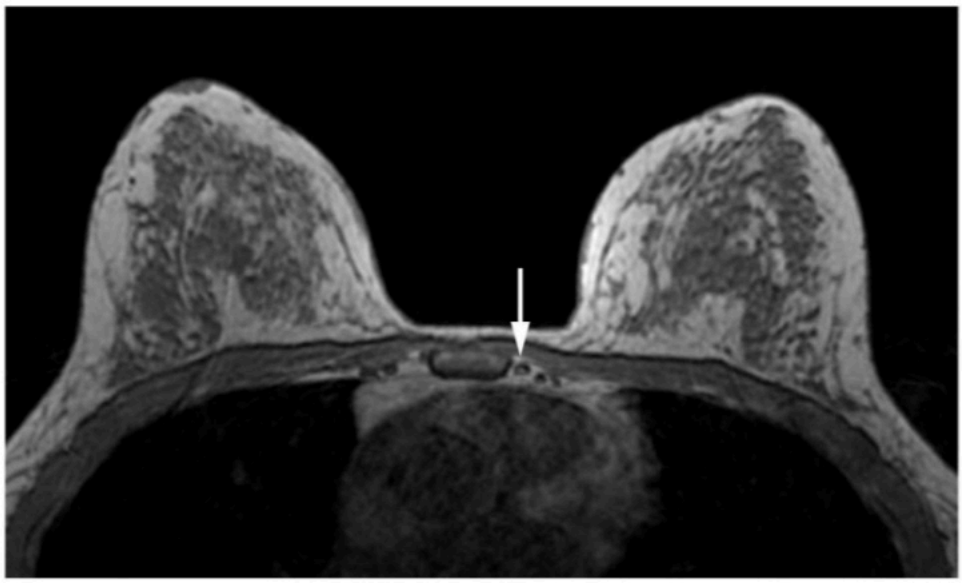

A

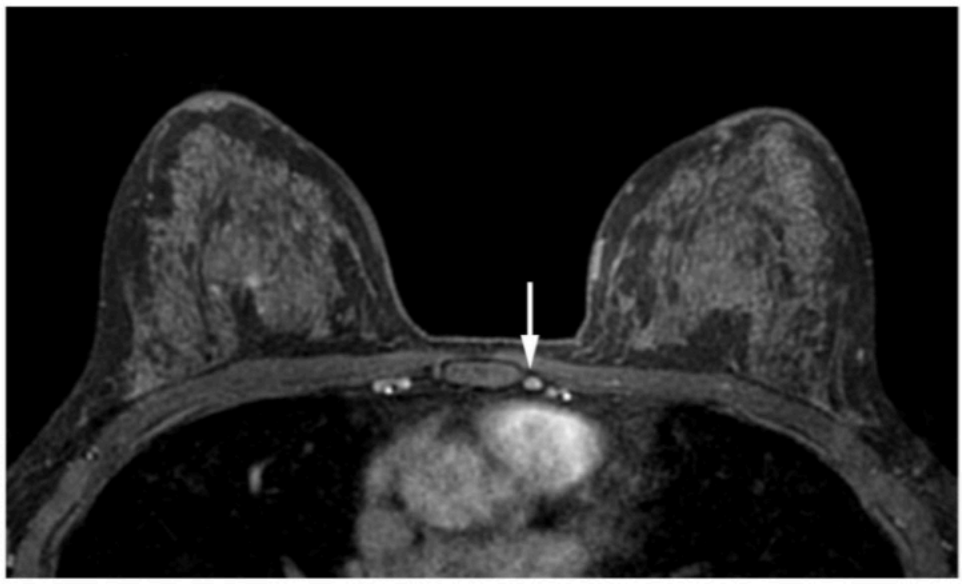

B

Figure 1 – INTERNAL MAMMARY LYMPH NODE: NORMAL. Normal left internal mammary lymph node (arrows). (A) Non-fat-suppressed non-contrast T1W image. (B) Fat-suppressed early post-contrast T1W image.

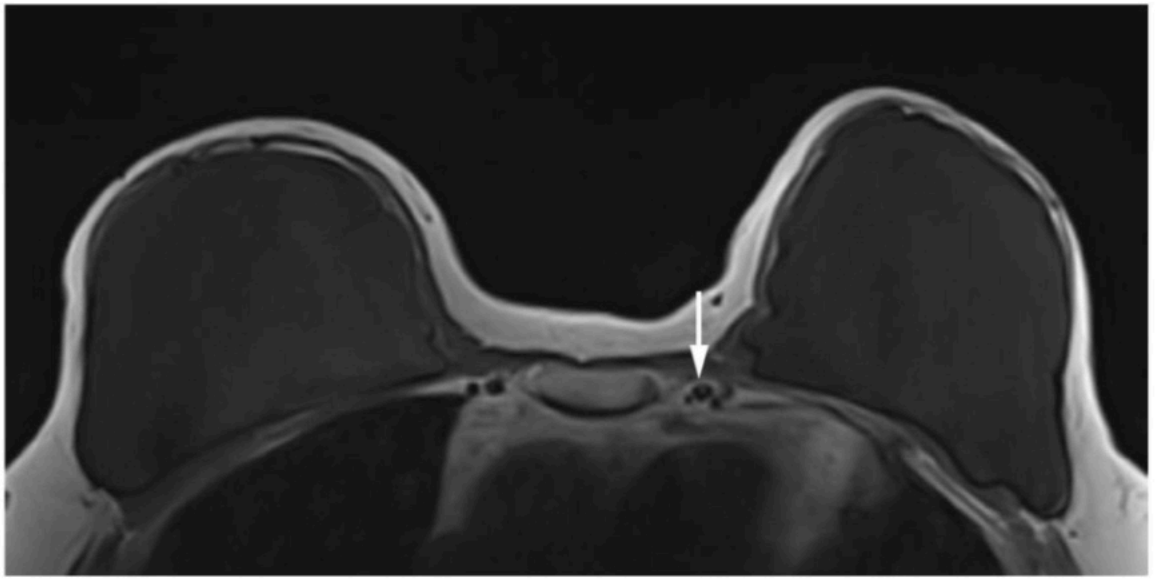

A

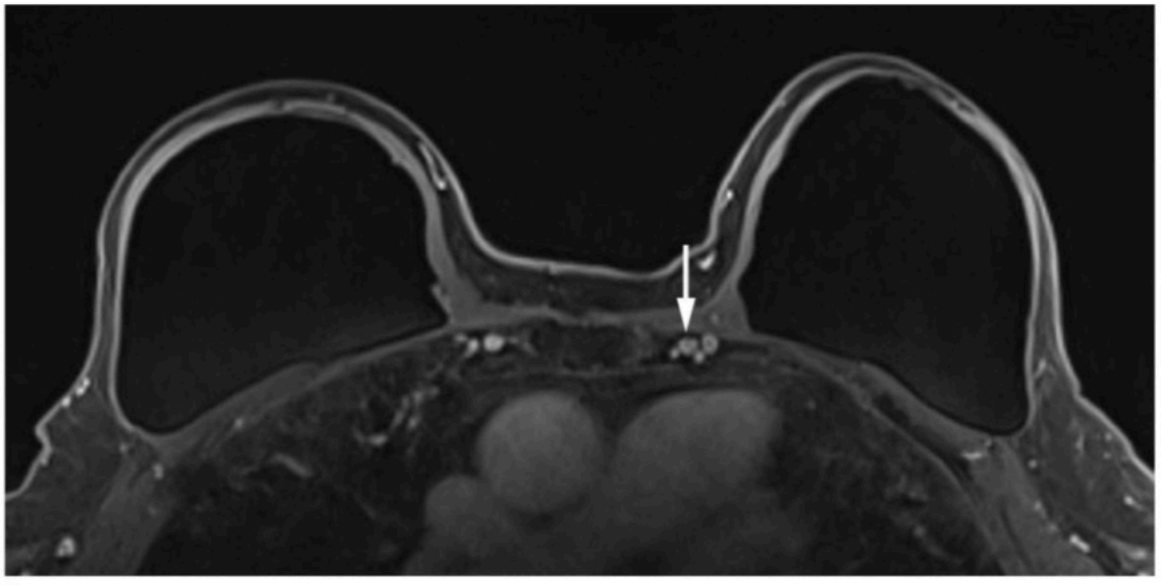

B

Figure 2 – INTERNAL MAMMARY LYMPH NODE: NORMAL. Normal left internal mammary lymph node (arrows). (A) Non-fat-suppressed non-contrast T1W image. (B) Fat-suppressed early post-contrast T1W image.

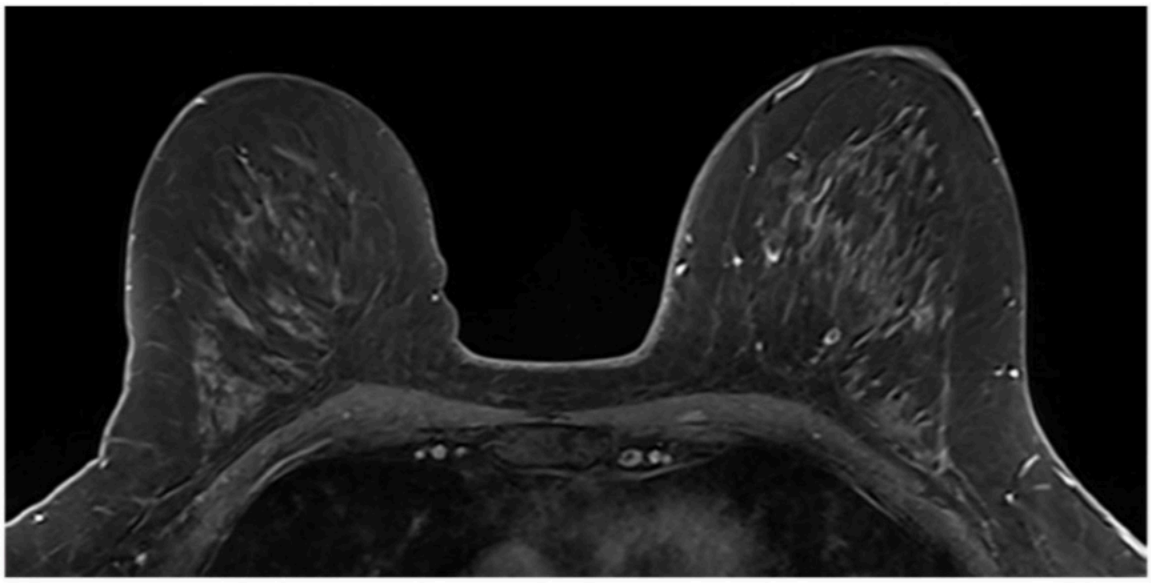

Figure 3 – INTERNAL MAMMARY LYMPH NODE: NORMAL. Normal left internal mammary lymph node. Fat-suppressed early post-contrast T1W image.

F. LYMPH NODES

3. INTERNAL MAMMARY LYMPH NODES

b. Abnormal

Abnormal internal mammary lymph nodes are subjectively asymmetric in size compared to other ipsilateral or contralateral internal mammary lymph nodes. Location ipsilateral to a current or prior breast cancer makes an asymmetric lymph node more suspicious.

There are limited data regarding quantitative size features predictive of malignant involvement. In MRI screening of asymptomatic women with no history of breast cancer, normal internal mammary lymph nodes may measure up to 9–10 mm in long axis [9, 10]. In MRI of patients with current breast cancer, a small study showed that size ≥ 5 mm was most helpful in predicting malignancy [11].

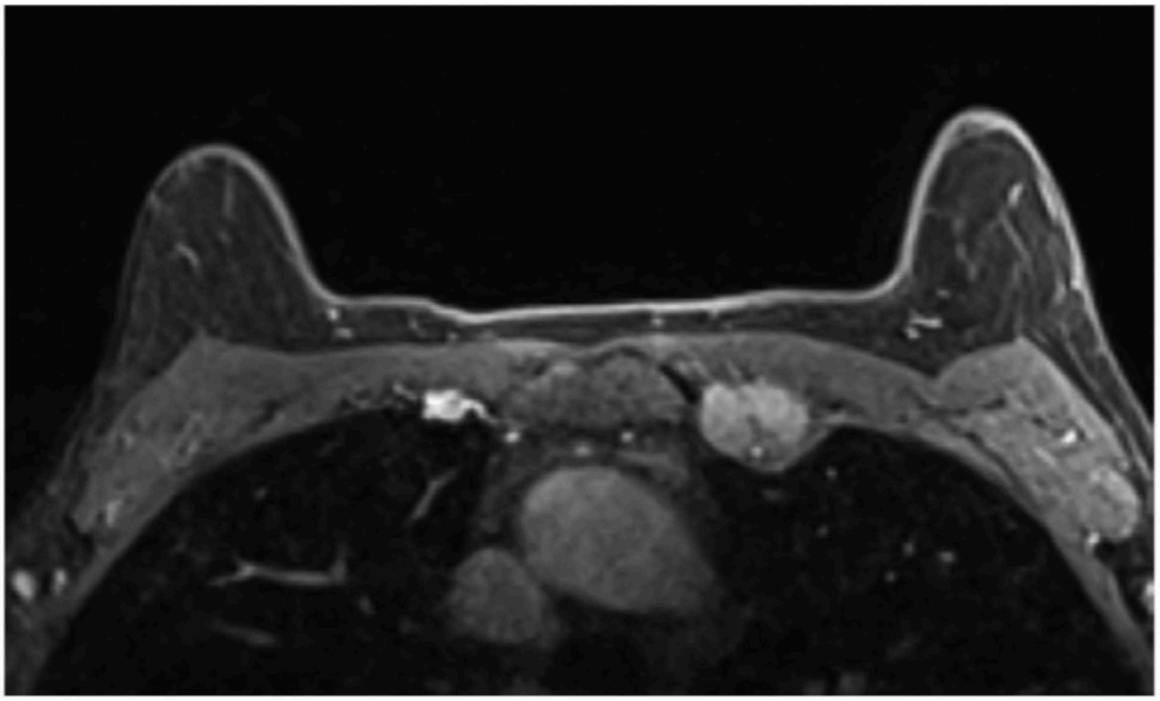

Figure 1 – INTERNAL MAMMARY LYMPH NODE: ABNORMAL. Abnormal left internal mammary lymph node in a patient with current left invasive ductal carcinoma. Fat-suppressed early post-contrast T1W image.

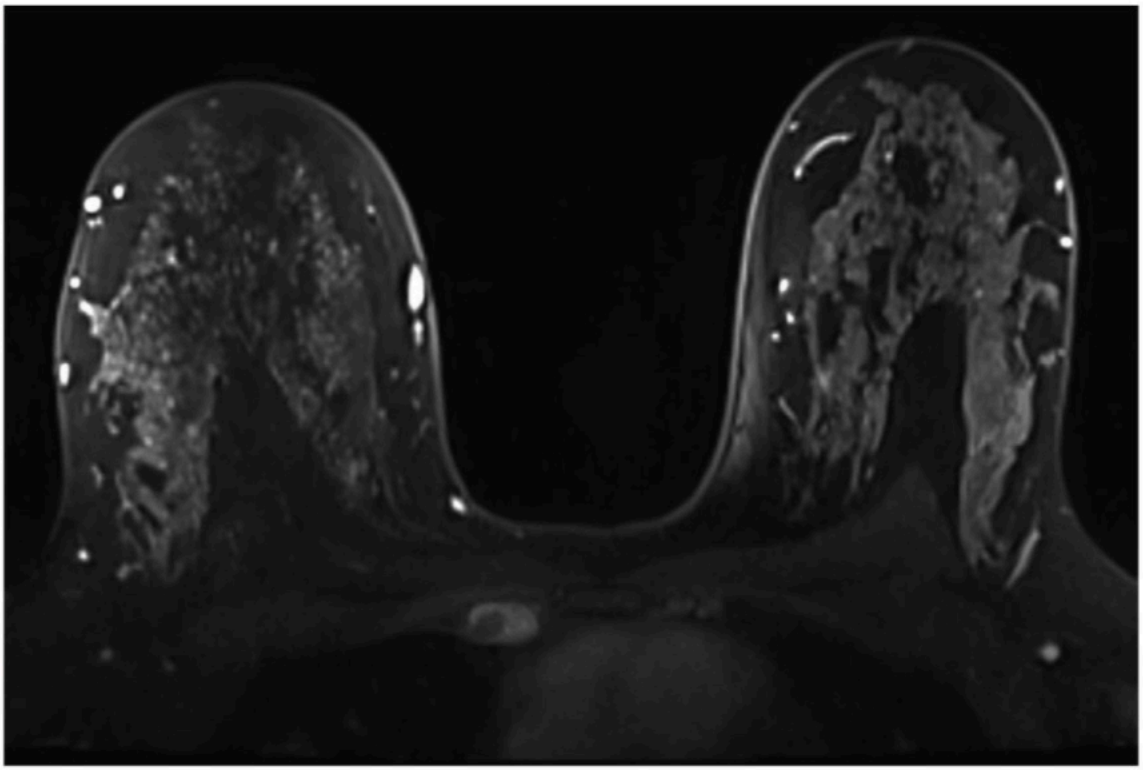

Figure 2 – INTERNAL MAMMARY LYMPH NODE: ABNORMAL. Abnormal right internal mammary lymph node in patient with current right invasive ductal carcinoma. Fat-suppressed early post-contrast T1W image.

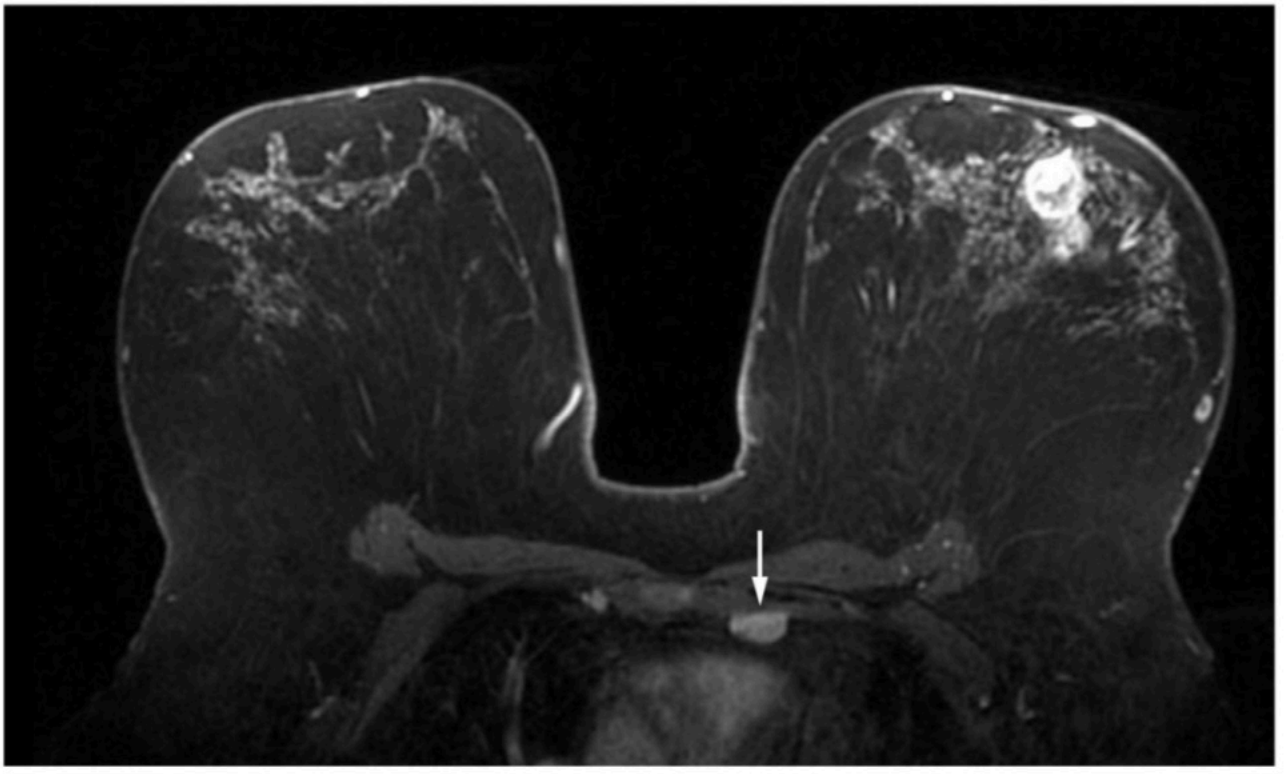

A



B

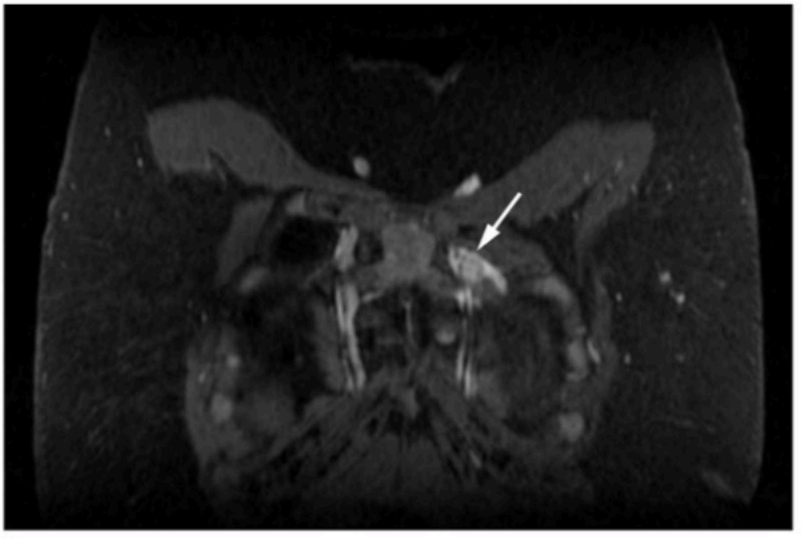

C

Figure 3 – INTERNAL MAMMARY LYMPH NODES: ABNORMAL. Abnormal left internal mammary lymph nodes (arrows) in patient with current left invasive ductal carcinoma (anterior left breast on axial image). A second abnormal node is noted more inferiorly on sagittal image (arrowhead). (A) Axial, (B) sagittal, and (C) coronal fat-suppressed early post-contrast T1W images.

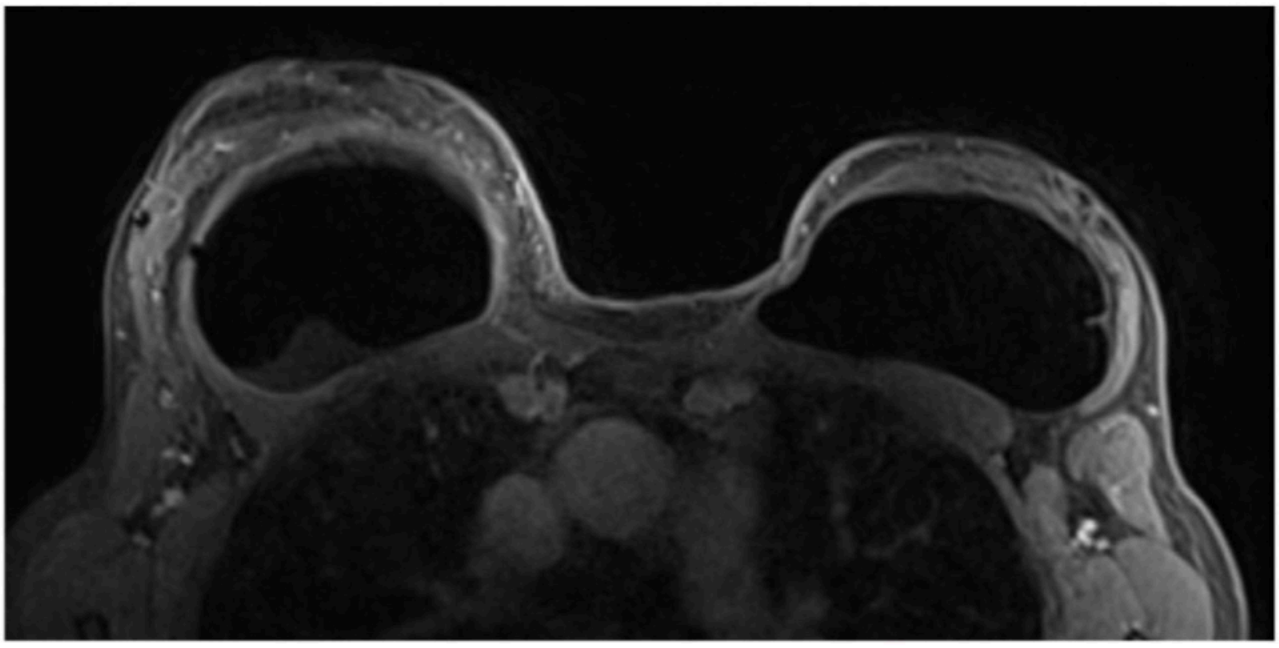

A

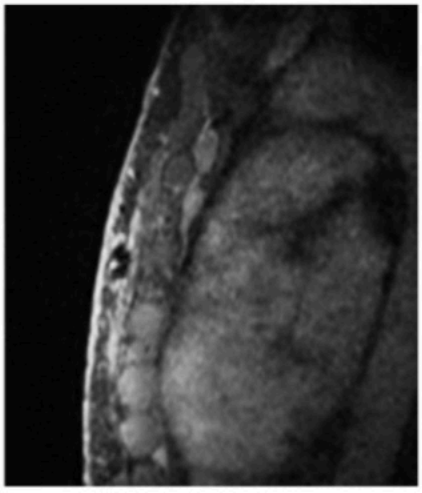

B

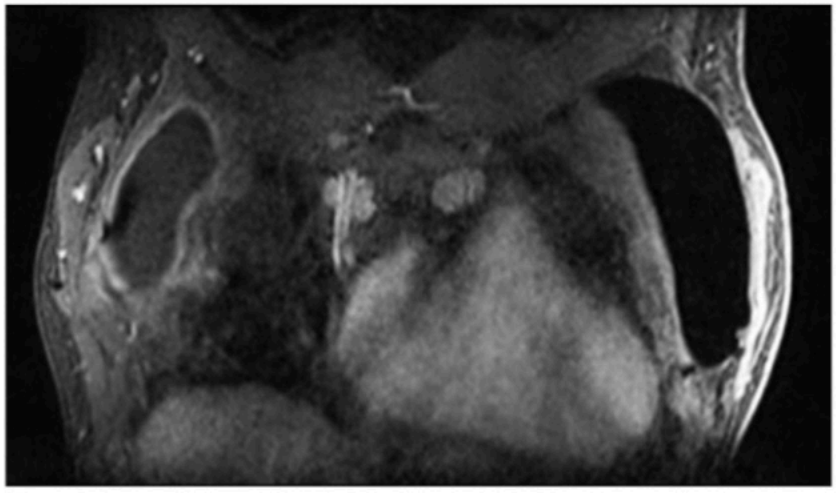

C

Figure 4 – INTERNAL MAMMARY LYMPH NODES: ABNORMAL. Bilateral abnormal internal mammary lymph nodes in a patient with silicone implants and right peri-implant fluid collection. (A) Axial, (B) sagittal, and (C) coronal fat-suppressed early post-contrast T1W images. Etiology: Benign, reactive.

Internal Mammary Reporting Details and Use of BI-RADS Assessments:

When describing abnormal-appearing internal mammary lymph nodes it is helpful to provide the side and intercostal space number by defining the ribs above and below the lymph node (e.g., intercostal space between ribs 1 and 2). This may facilitate correlation with other imaging or aid in targeted radiation therapy.

For abnormal-appearing internal mammary lymph nodes in the setting of known breast malignancy or findings suspicious for breast malignancy, the lymph nodes should be fully described but they should not be given a separate BI-RADS assessment. If not biopsy-proven metastatic, management often depends on multiple clinical factors and preferences.

For abnormal-appearing internal mammary lymph nodes that are an isolated finding, they should be given a BI-RADS assessment based on the level of suspicion for lymph node malignancy.

Example wording which could be used for abnormal-appearing internal mammary lymph nodes in the different settings includes:

<u>Lymph nodes known to be biopsy-proven malignant/metastatic breast cancer:</u>

"Abnormal-appearing internal mammary lymph node in the right 4th intercostal space. Biopsy of one node confirmed malignant/metastatic disease."

<u>Lymph nodes associated with known ipsilateral breast malignancy or suspicious breast findings:</u>

"Abnormal-appearing lymph node in the right 4th intercostal space. If it would change clinical management, any further work-up should be based on multidisciplinary shared decision making and/or institutional practices."

<u>Lymph nodes as an isolated finding:</u>

"Abnormal-appearing lymph node in the right 4th intercostal space. BI-RADS 4A, low suspicion for malignancy. If it would change clinical management, any further work-up should be based on multidisciplinary shared decision making and/or institutional practices."

G. ASSOCIATED FEATURES

Associated features are usually seen and described with other significant primary findings but may be stand-alone entities when no other abnormality is present. Associated features are often associated with or suspicious for breast cancer. They are particularly important if they influence surgical management and/or breast cancer staging.

1. NIPPLE RETRACTION

   The nipple is pulled in. This should not be confused with nipple inversion, which is often bilateral. Nipple retraction can be caused by benign etiologies such as prior surgery or be associated with malignancy. In the absence of suspicious findings and particularly when stable, nipple retraction alone is not suspicious.

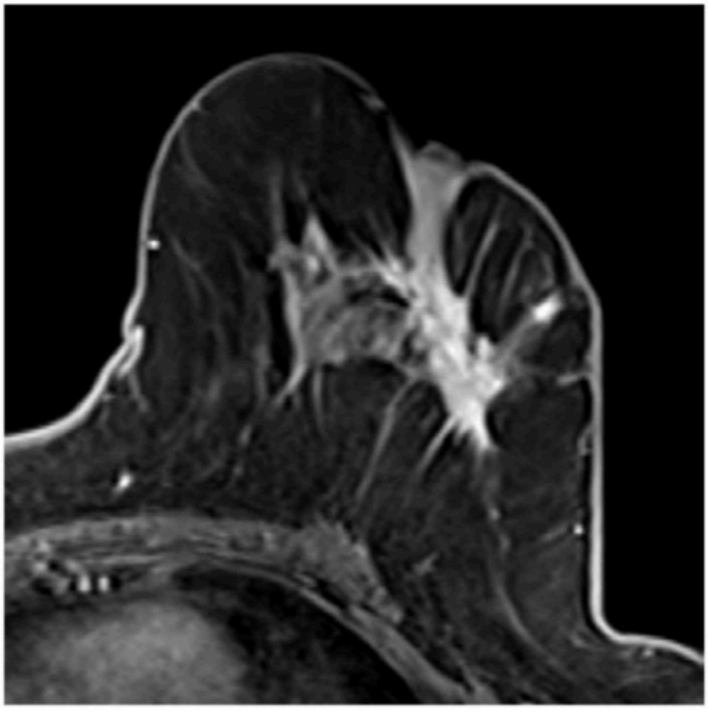

Figure 1 – NIPPLE RETRACTION caused by an irregular, spiculated, heterogeneous mass. Fat-suppressed early post-contrast T1W image. Pathology: Invasive ductal carcinoma.

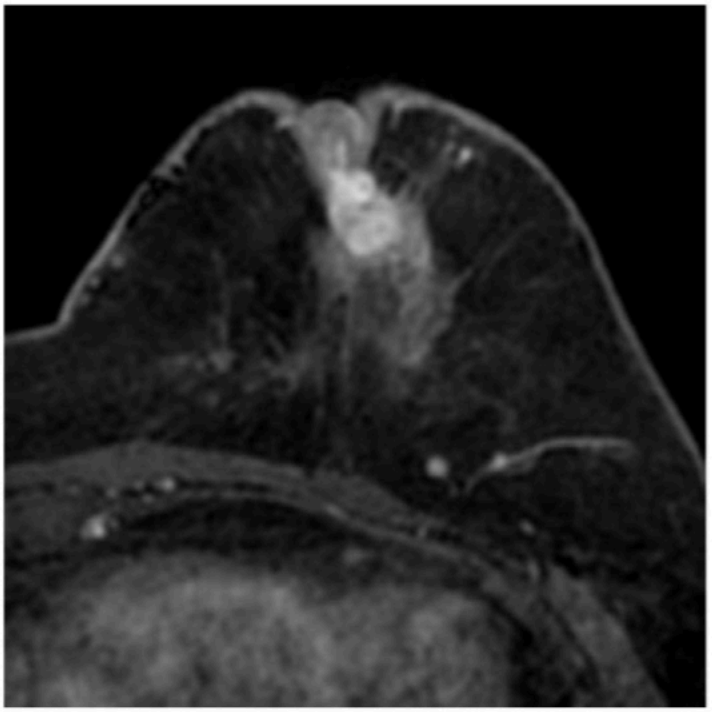

Figure 2 – NIPPLE RETRACTION caused by an oval, indistinct, heterogeneous mass. Fat-suppressed early post-contrast T1W image. Pathology: Invasive ductal carcinoma.

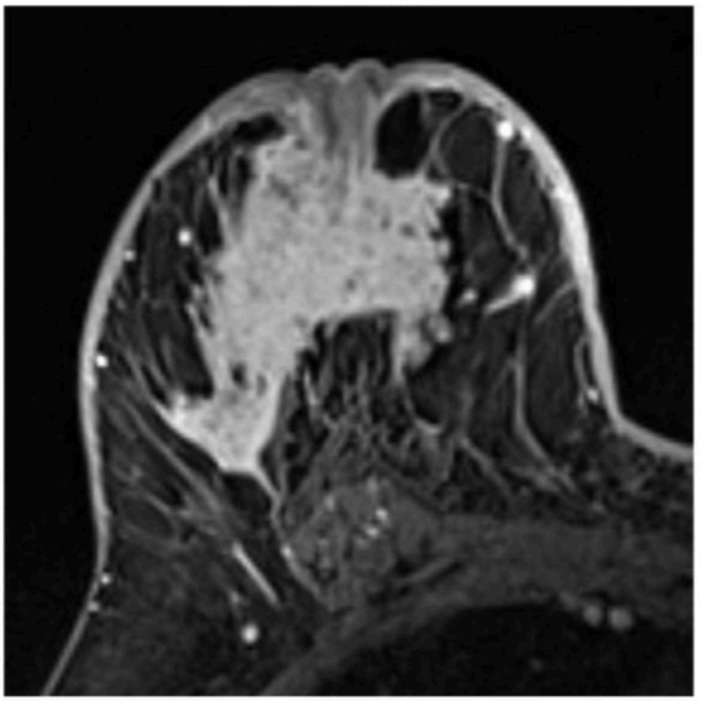

Figure 3 – NIPPLE RETRACTION caused by an irregular, spiculated, heterogeneous mass. Fat-suppressed early post-contrast T1W image. Pathology: Invasive ductal carcinoma.

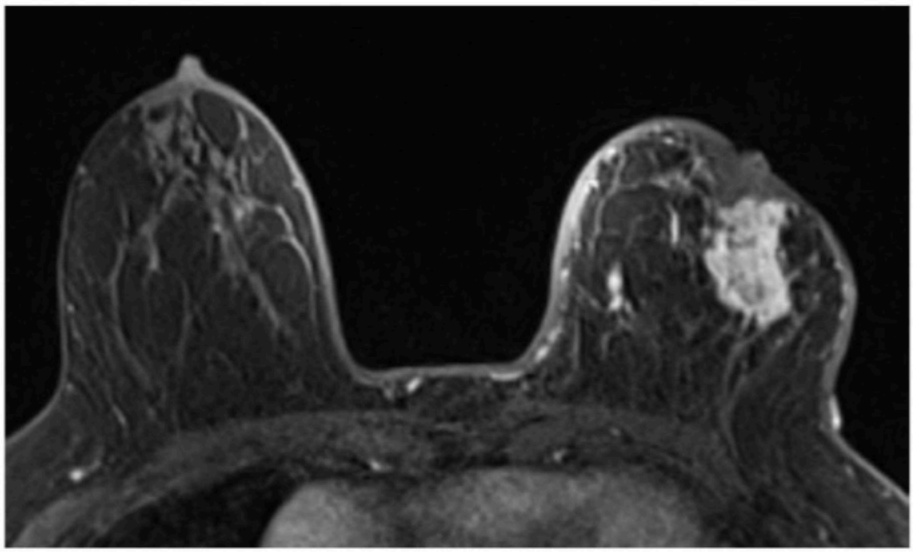

Figure 4 – NIPPLE RETRACTION caused by an irregular, spiculated, heterogeneous mass. Fat-suppressed early post-contrast T1W image. Pathology: Invasive lobular carcinoma.

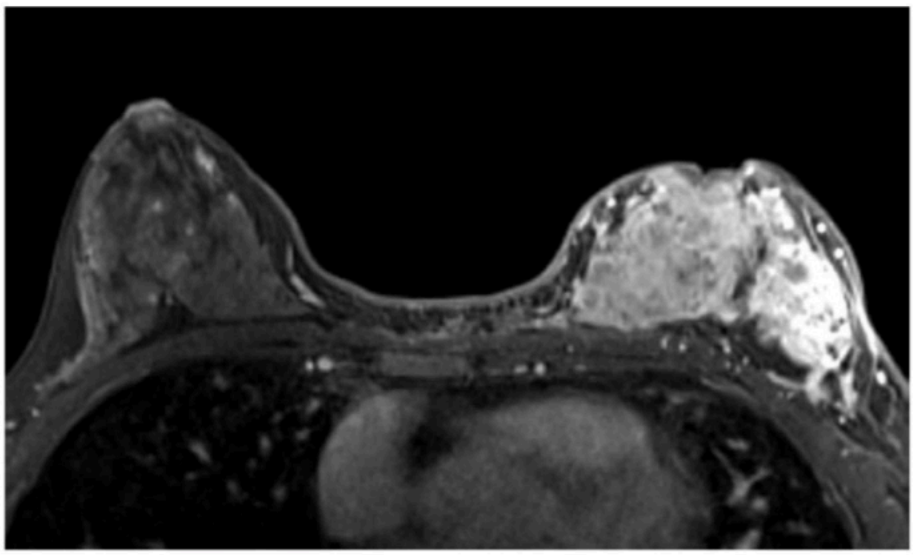

Figure 5 – NIPPLE RETRACTION caused by a large irregular, indistinct, heterogeneous mass. Fat-suppressed early post-contrast T1W image. Pathology: Invasive ductal carcinoma.

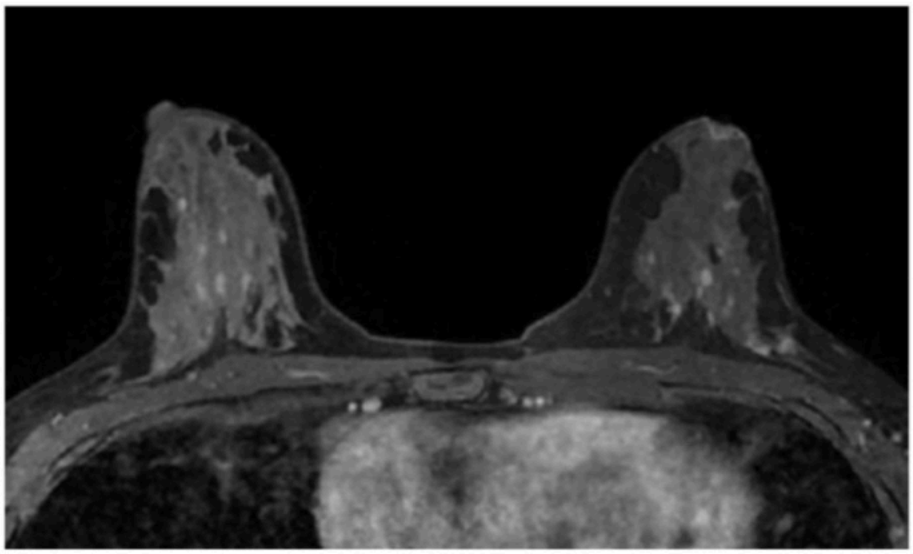

Figure 6 – Incidental nipple inversion (not nipple retraction). Benign inversion of the left nipple. Fat-suppressed early post-contrast T1W image.

G. ASSOCIATED FEATURES

2. NIPPLE INVOLVEMENT

Known malignancy or suspicious enhancement directly involves and is contiguous with the nipple. Normal nipples typically enhance symmetrically, but normal nipple enhancement may be asymmetric, sometimes related to nipple inversion. To qualify as nipple involvement, there should be definitive abnormal enhancement of the nipple and/or nipple areolar complex.

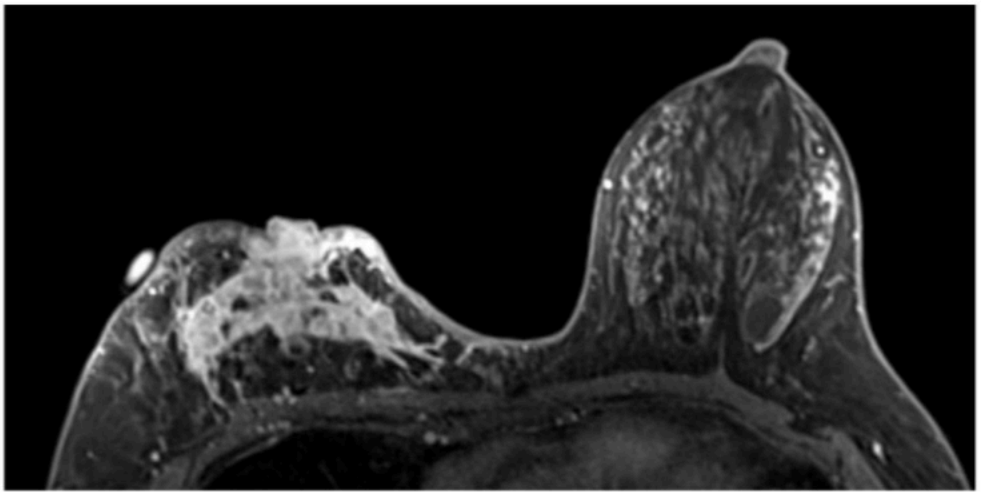

Figure 1 – NIPPLE INVOLVEMENT. Nipple and peri-areolar skin enhancement is contiguous with the malignant NME. Fat-suppressed early post-contrast T1W image. Pathology: Invasive ductal carcinoma and DCIS.

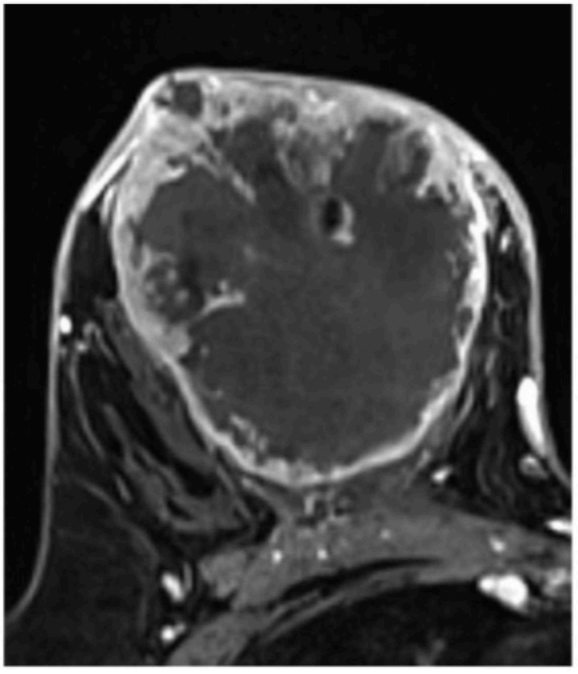

Figure 2 – NIPPLE INVOLVEMENT. Nipple and skin enhancement is contiguous with the malignant thick rim enhancing mass. Fat-suppressed early post-contrast T1W image. Pathology: Invasive ductal carcinoma.

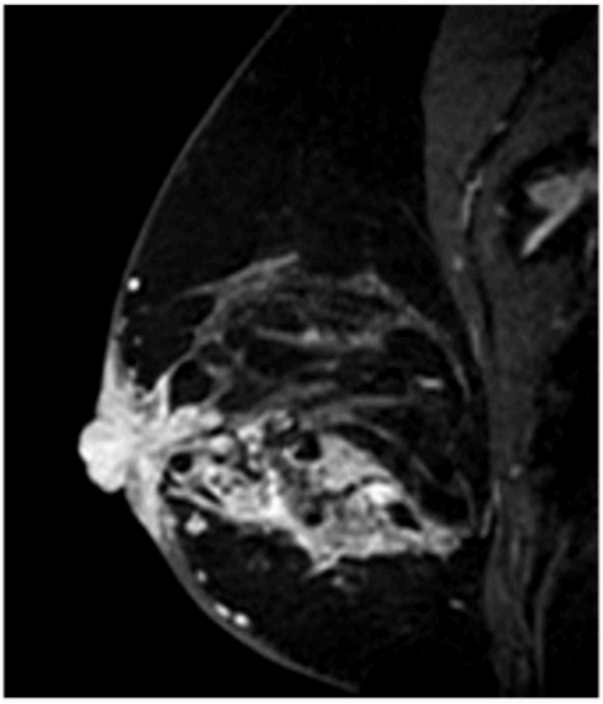

Figure 3 – NIPPLE INVOLVEMENT. Nipple and peri-areolar skin enhancement is contiguous with the malignant NME. Fat-suppressed early post-contrast T1W image. Pathology: Invasive ductal carcinoma.

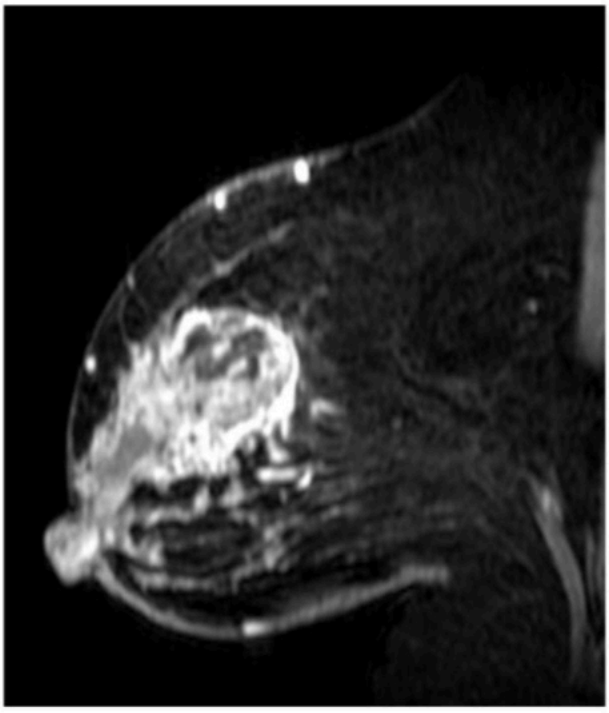

Figure 4 – NIPPLE INVOLVEMENT. Nipple enhancement is contiguous with the malignant NME. Fat-suppressed early post-contrast T1W image. Pathology: Invasive ductal carcinoma.

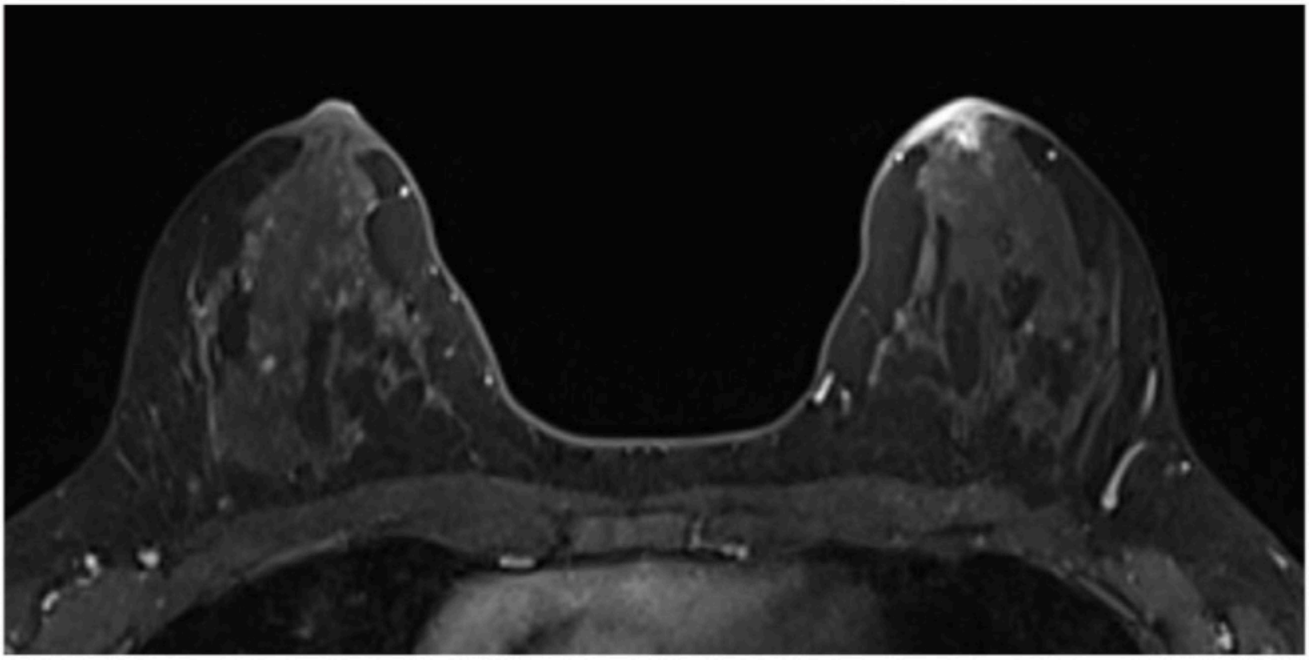

Figure 5 – NIPPLE INVOLVEMENT. Nipple and peri-areolar skin enhancement associated with a retroareolar mass. Fat-suppressed early post-contrast T1W image. Pathology: Paget's disease.

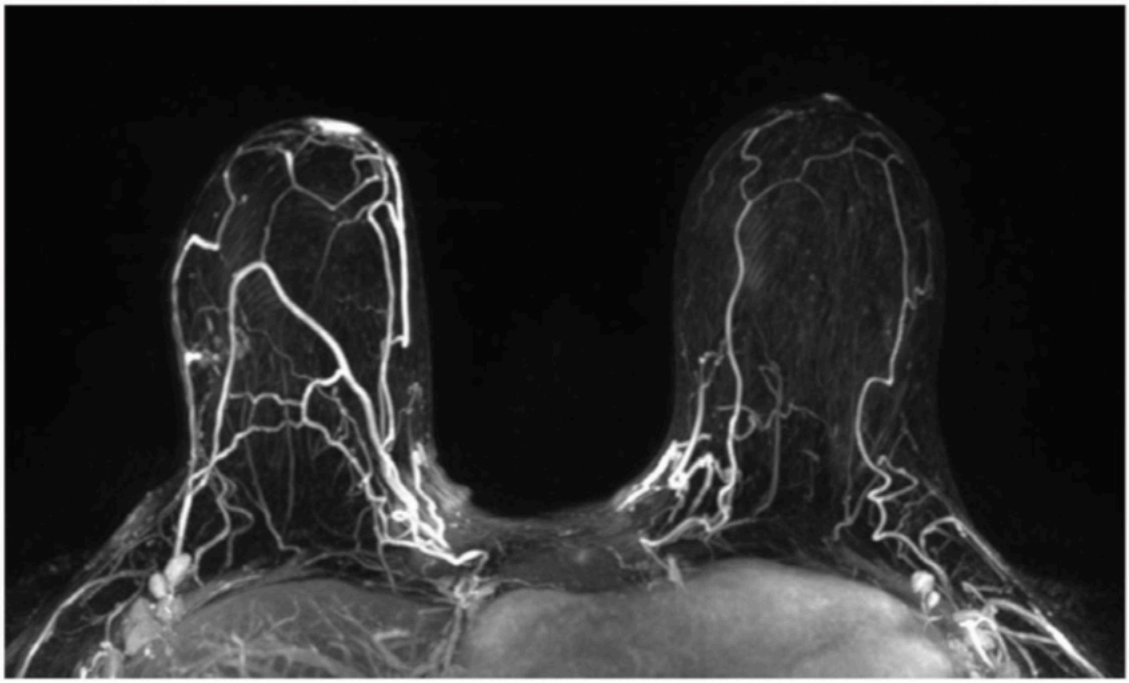

Figure 6 – NIPPLE INVOLVEMENT. Nipple enhancement with no associated primary breast findings. Early post-contrast T1W maximum intensity projection image. Pathology: Paget disease.

G. ASSOCIATED FEATURES

3. SKIN RETRACTION

The skin is pulled in. Skin retraction can be caused by benign etiologies such as prior surgery, or may be associated with malignancy. In the absence of suspicious findings and particularly when stable, skin retraction alone is not suspicious.

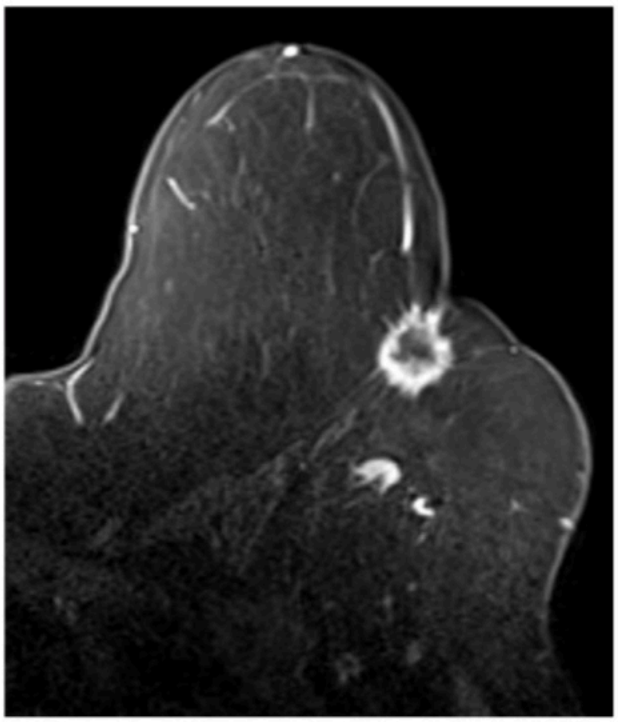

Figure 1 – SKIN RETRACTION caused by a round, spiculated thick rim enhancing mass, but there is no skin enhancement. Fat-suppressed early post-contrast T1W image. Pathology: Invasive ductal carcinoma.

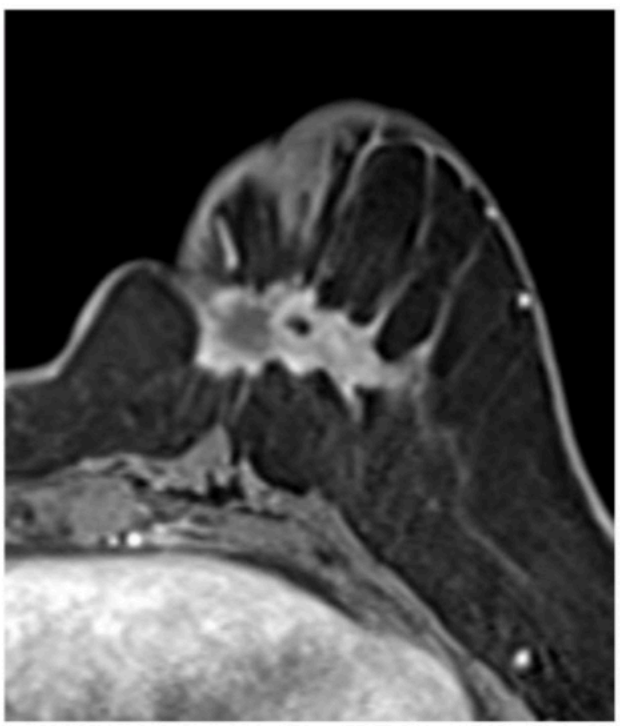

Figure 2 – SKIN RETRACTION. Fat-suppressed early post-contrast T1W image. Pathology: Invasive ductal carcinoma.

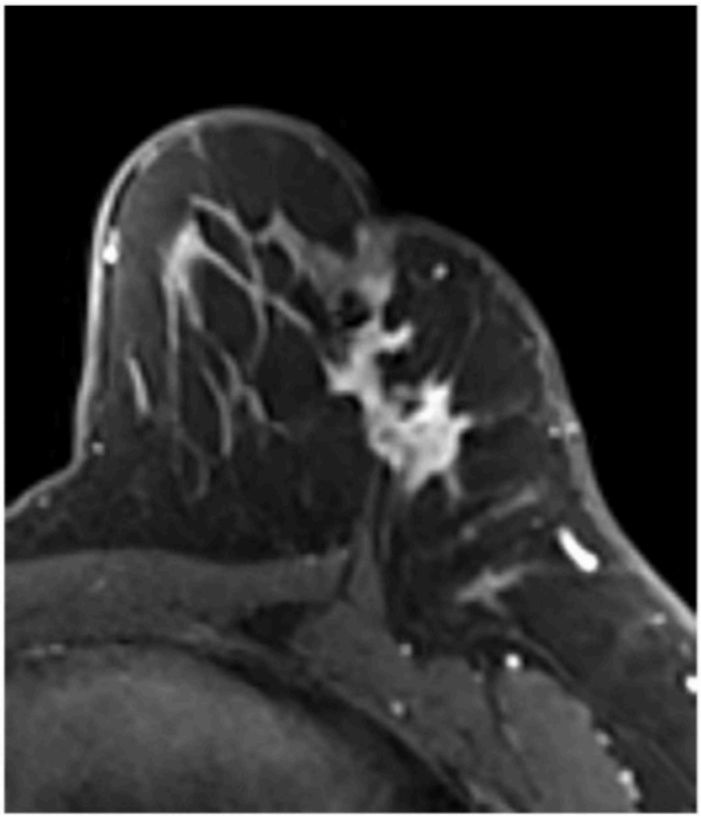

Figure 3 – SKIN RETRACTION. Fat-suppressed early post-contrast T1W image. Pathology: Invasive lobular carcinoma.

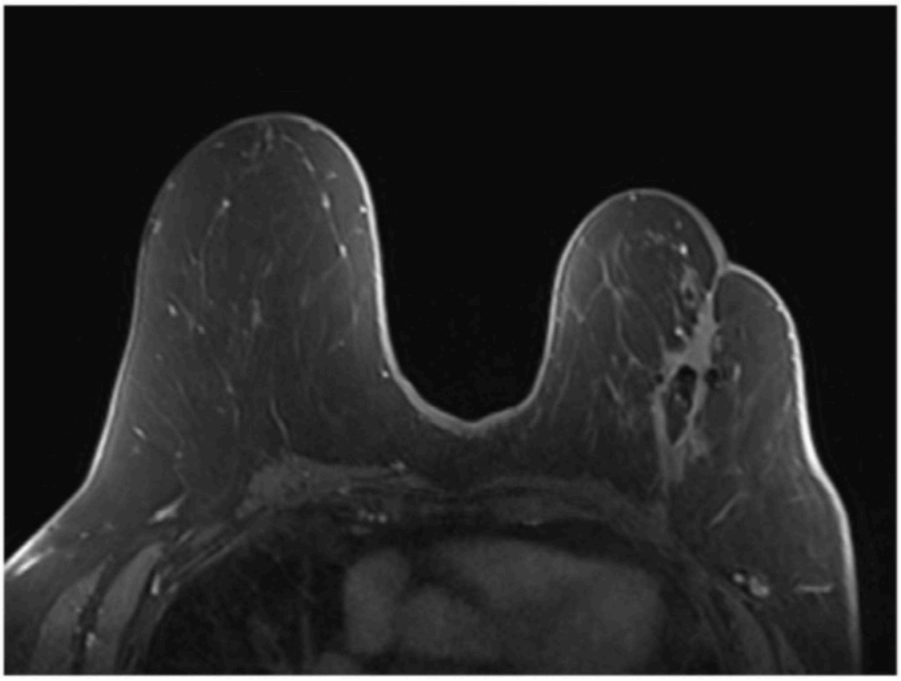

Figure 4 – SKIN RETRACTION. Benign skin retraction from prior left breast surgery (scarring and seroma formation are seen at the prior surgical site but there is no abnormal enhancement). Fat-suppressed early post-contrast T1W image. Etiology: Benign postsurgical change.

G. ASSOCIATED FEATURES

4. SKIN THICKENING

Skin thickening may be focal or diffuse and is defined as thickness > 2 mm. Skin thickening can be caused by benign etiologies such as prior surgery or radiation therapy or edema including systemic edema or can be associated with malignancy. In the absence of enhancement and particularly when stable, skin thickening alone is not suspicious.

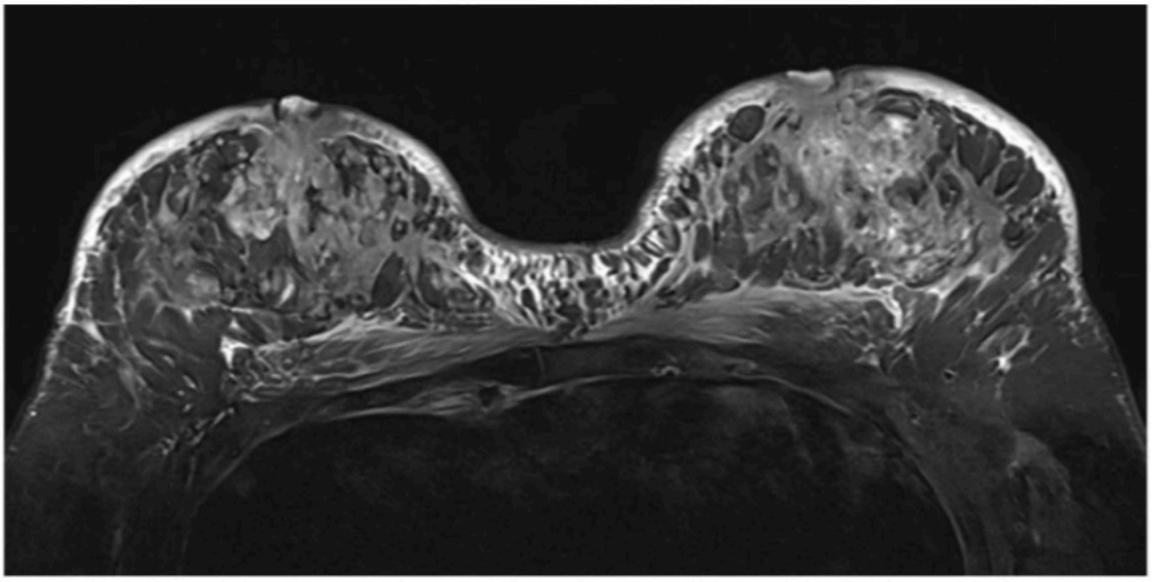

A

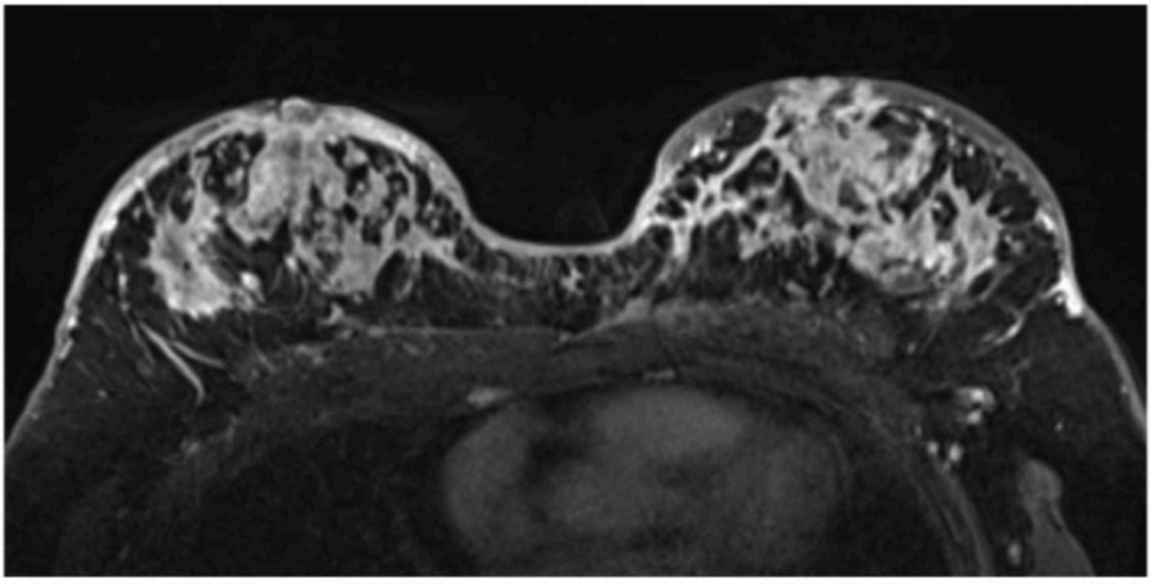

B

Figure 1 – SKIN THICKENING. Bilateral diffuse SKIN THICKENING with patchy skin involvement (enhancement) due to inflammatory carcinoma. (A) Fat-suppressed T2W image. (B) Fat-suppressed early post-contrast T1W image. Pathology: Bilateral invasive ductal carcinoma.

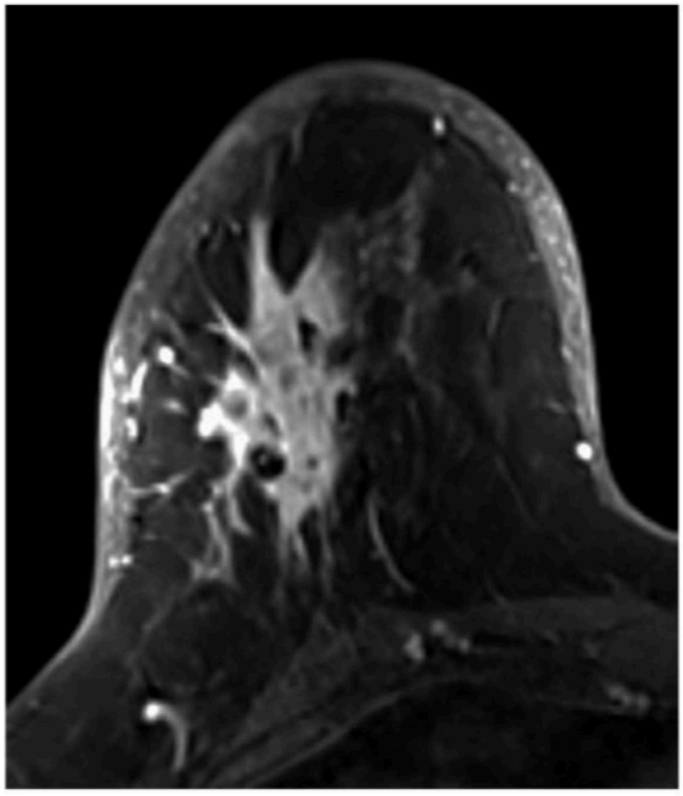

Figure 2 – SKIN THICKENING. Diffuse skin thickening with focal skin involvement (enhancement) in the lateral right breast. There is also malignant NME in the lateral breast. Fat-suppressed early post-contrast T1W image. Pathology: Invasive lobular carcinoma.

G. ASSOCIATED FEATURES

5. SKIN INVOLVEMENT

The enhancement of the malignancy or suspicious finding extends directly into the skin, and the involved skin is enhancing. Also, skin involvement without direct extension from a breast finding may be seen, particularly with inflammatory breast cancer. To qualify as skin involvement, there should be definitive enhancement of the skin, not just skin thickening or edema. Skin involvement can be focal or more diffuse.

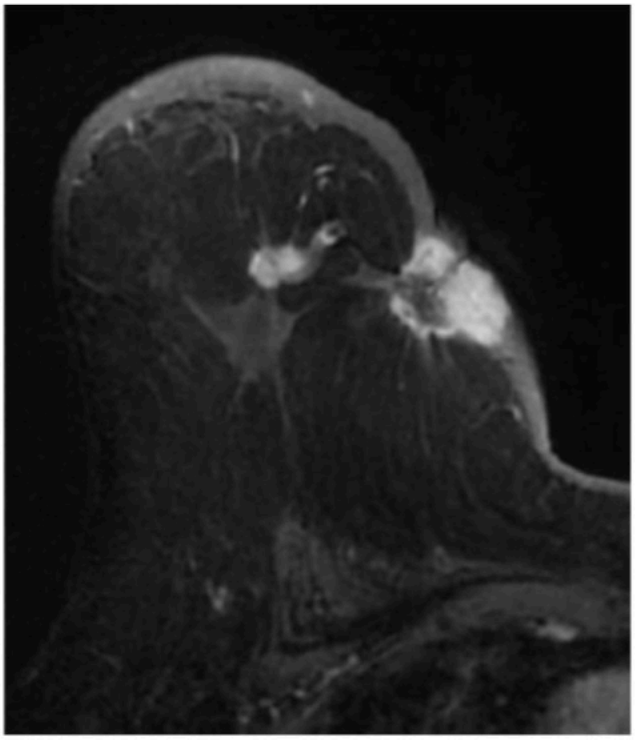

Figure 1 – SKIN INVOLVEMENT. Localized skin enhancement in the medial right breast, due to direct invasion from an underlying spiculated mass. A second mass is also present approximately 2 cm lateral to the mass showing skin involvement. Fat-suppressed early post-contrast T1W image. Pathology: Invasive ductal carcinoma.

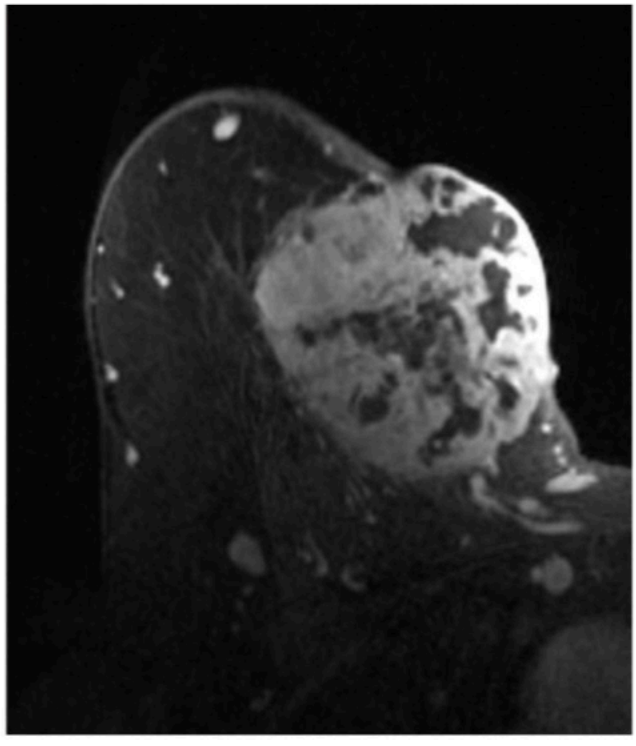

Figure 2 – SKIN INVOLVEMENT. Localized skin enhancement in the medial right breast, due to direct invasion from an underlying heterogeneous mass. Fat-suppressed early post-contrast T1W image. Pathology: Invasive ductal carcinoma.

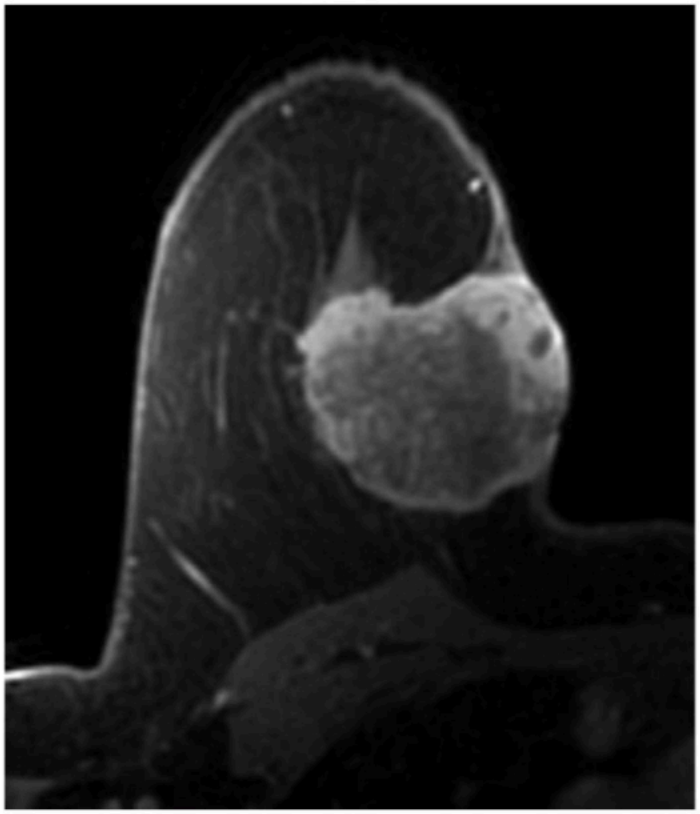

Figure 3 – SKIN INVOLVEMENT. Localized skin enhancement in the medial right breast, due to direct invasion from an underlying heterogeneous mass. Fat-suppressed early post-contrast T1W image. Pathology: Invasive ductal carcinoma.

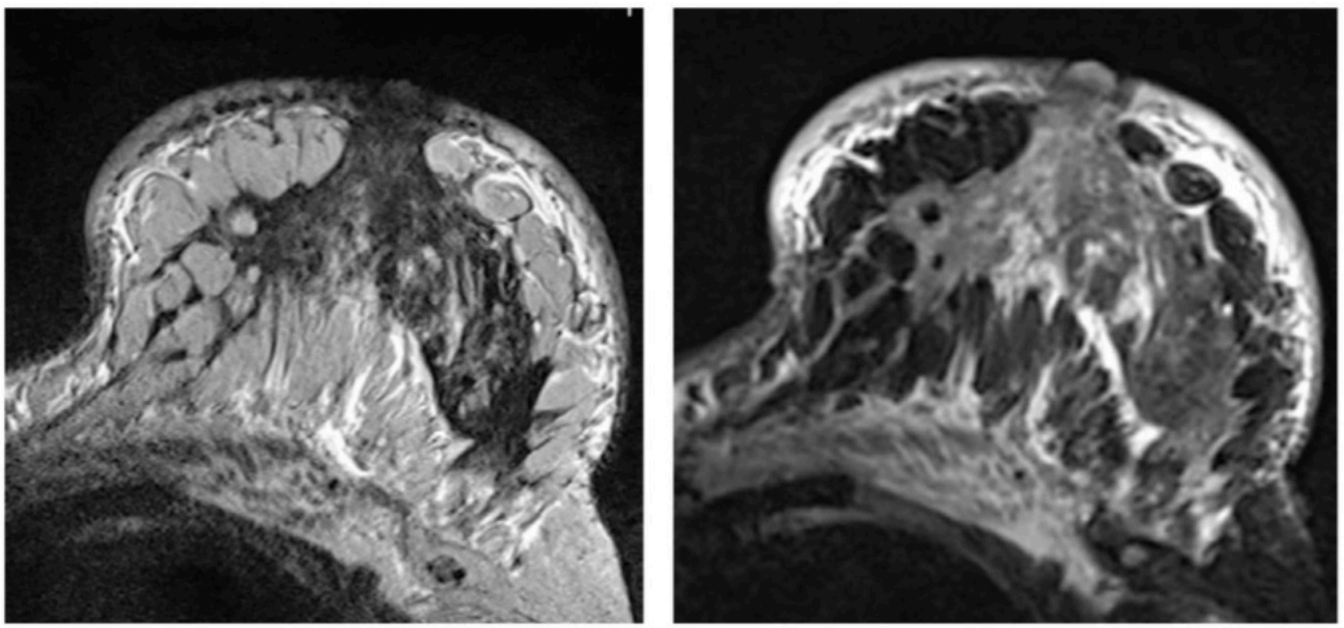

A B

Figure 4 – SKIN INVOLVEMENT. Diffuse skin thickening and enhancement due to inflammatory carcinoma. (A) Non-fat-suppressed T2W image. (B) Fat-suppressed early post-contrast T1W image. Pathology: Invasive ductal carcinoma.

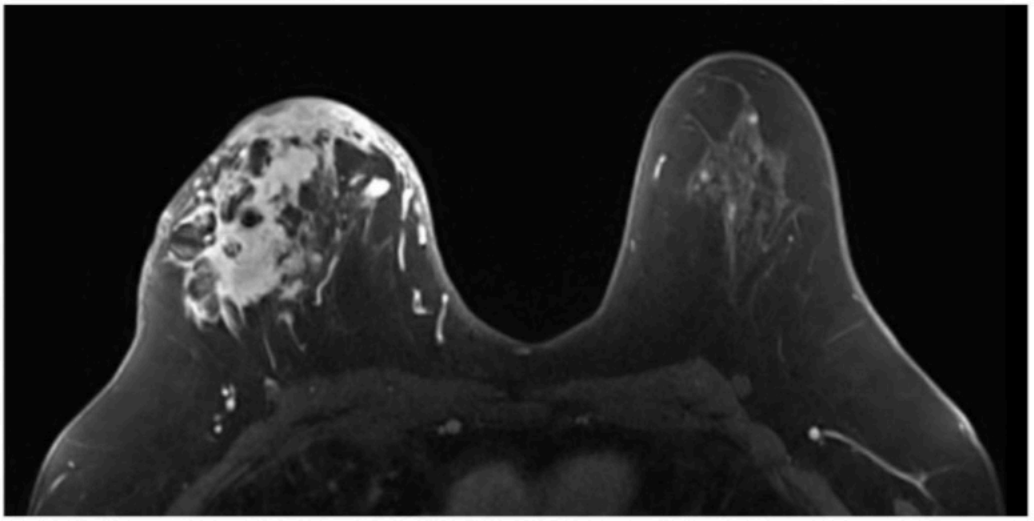

A

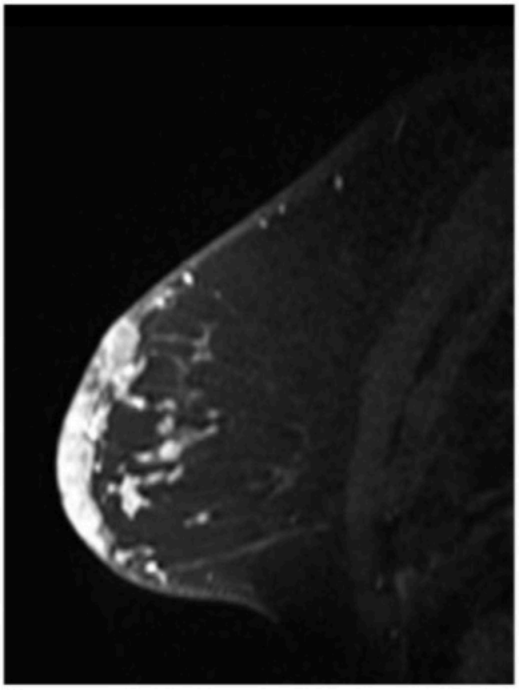

B

Figure 5 – SKIN INVOLVEMENT. Skin thickening and enhancement due to inflammatory carcinoma. (A) Axial and (B) sagittal fat-suppressed early post-contrast T1W images. Pathology: Invasive ductal carcinoma.

G. ASSOCIATED FEATURES

6. PECTORALIS MUSCLE INVOLVEMENT

The enhancement of the malignancy or suspicious finding extends into or otherwise involves the pectoralis major and/or minor muscles. To qualify as pectoralis muscle involvement, there should be definitive extension of enhancement into the muscle(s). Enhancement that abuts but does not extend into the pectoralis muscle(s) should be described as abutting but not invading the structure(s).

The pectoralis muscles are separate from the chest wall in breast cancer staging. This is an important distinction with staging and management implications. The chest wall consists of the intercostal and serratus anterior muscles and the chest osseous structures. Pectoralis muscle involvement is not chest wall involvement, and chest wall involvement should be reported separately if present.

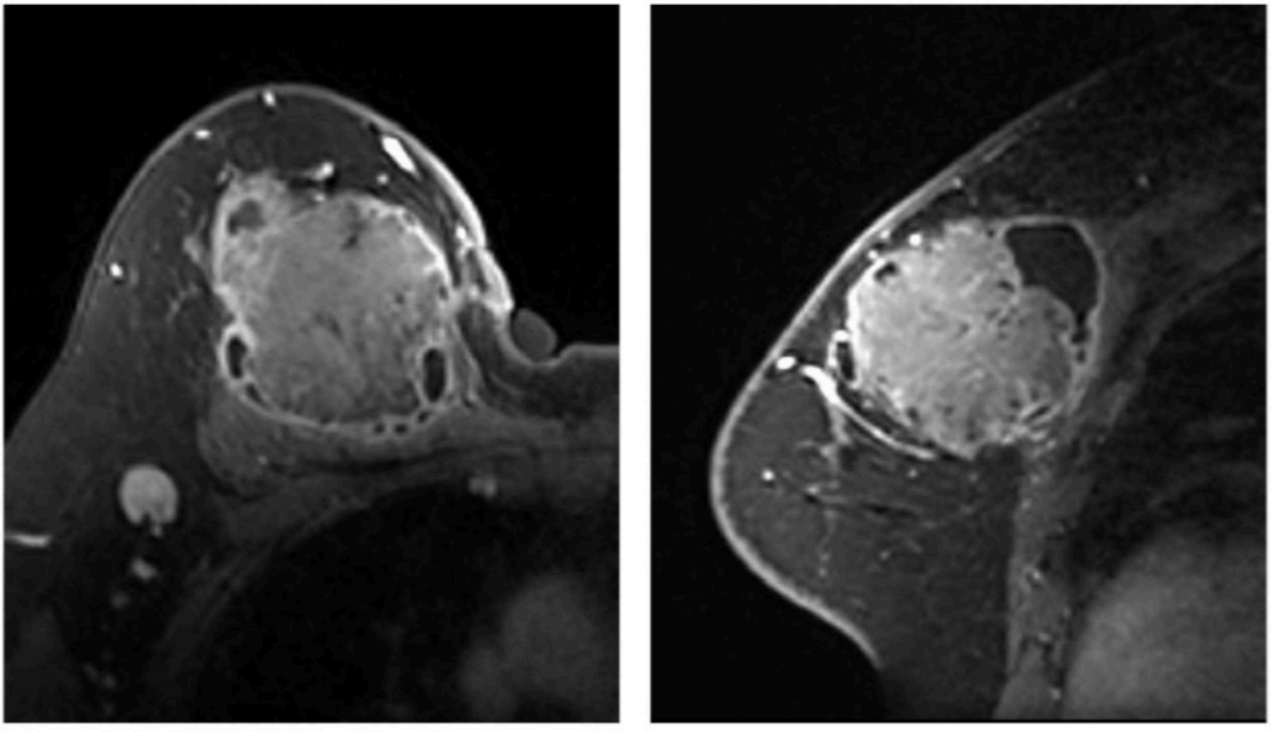

A B

Figure 1 – PECTORALIS MUSCLE INVOLVEMENT. Enhancement extends into the pectoralis major muscle. (A) Axial and (B) sagittal fat-suppressed early post-contrast T1W images. Pathology: Invasive ductal carcinoma.

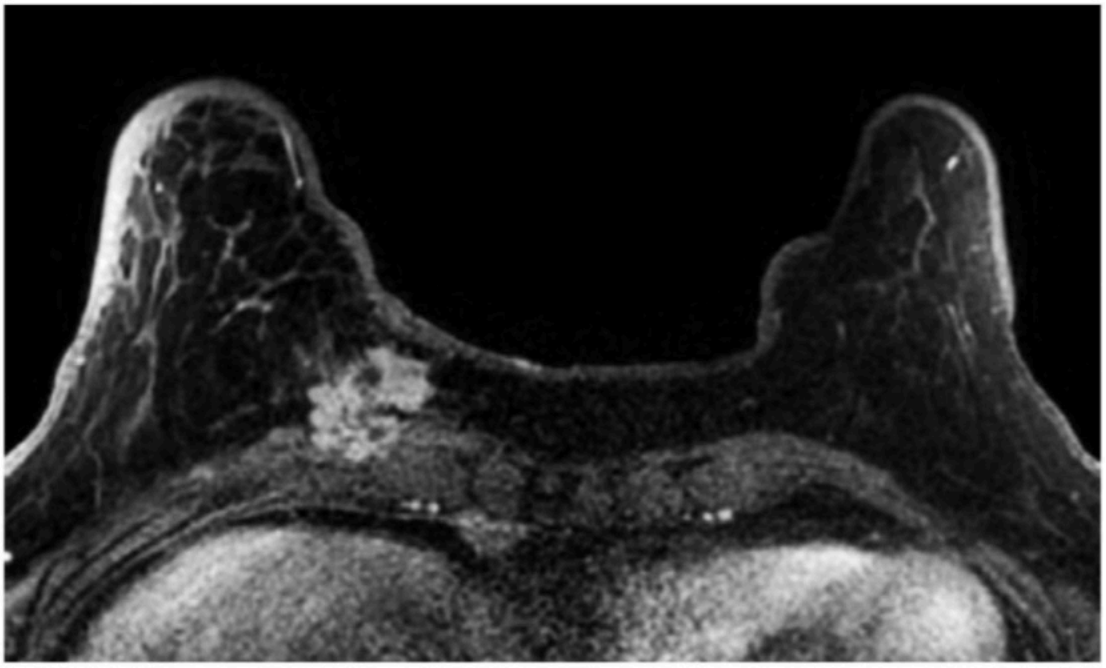

Figure 2 – PECTORALIS MUSCLE INVOLVEMENT. Enhancement extends into the pectoralis major muscle. Fat-suppressed early post-contrast T1W image. Pathology: Invasive ductal carcinoma.

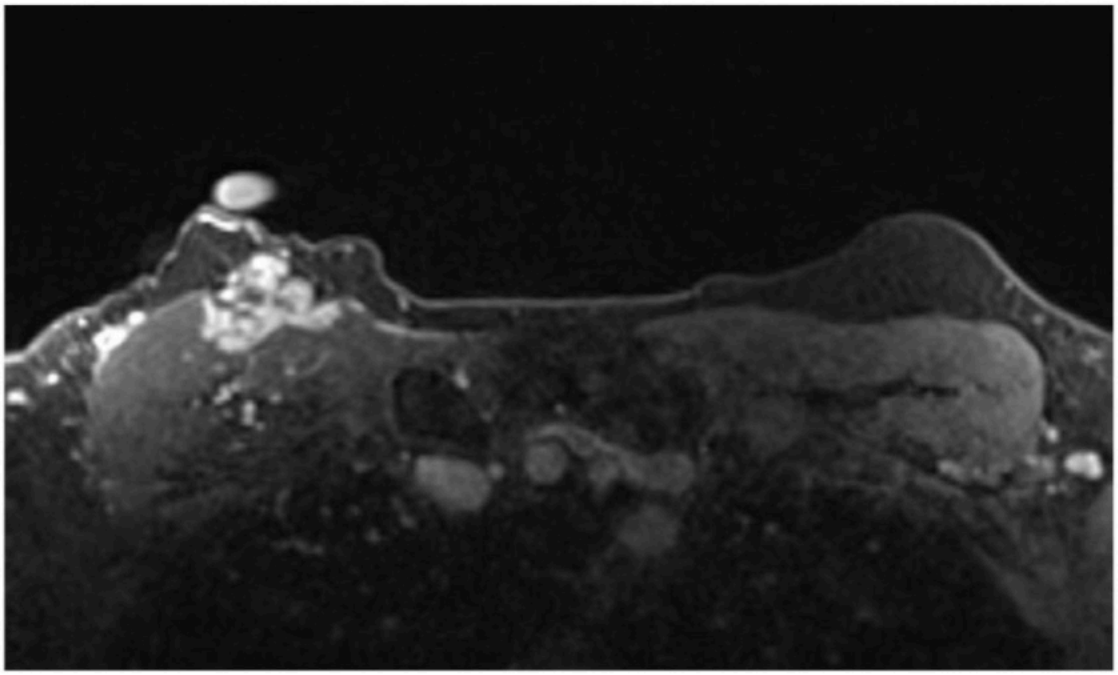

Figure 3 – PECTORALIS MUSCLE INVOLVEMENT. Enhancement extends into the pectoralis major muscle. Fat-suppressed early post-contrast T1W image. Pathology: Invasive lobular carcinoma.

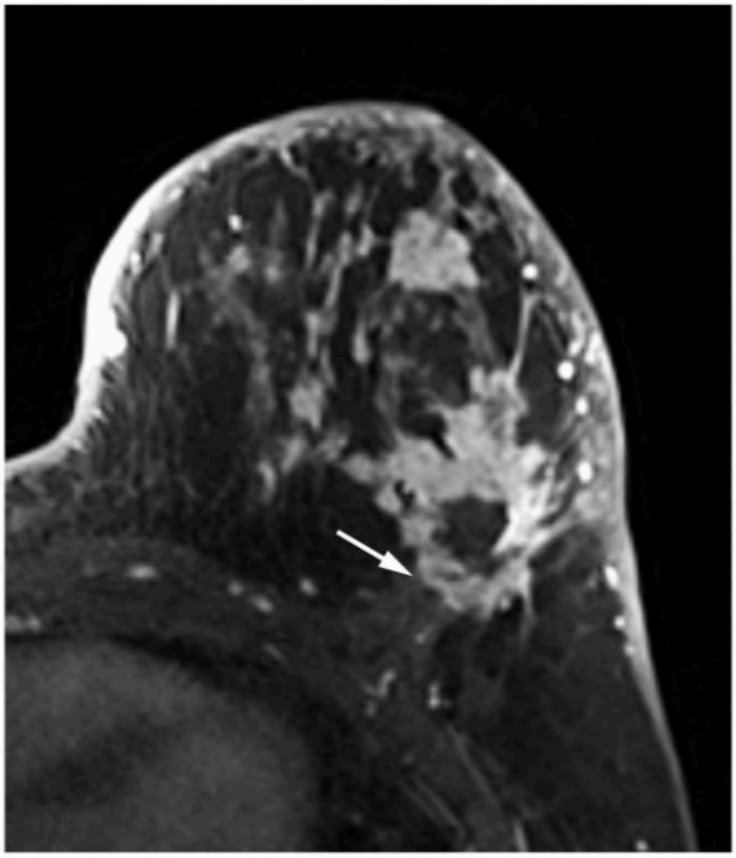

Figure 4 – PECTORALIS MUSCLE INVOLVEMENT. Enhancement extends into the retracted pectoralis major muscle (arrow). Fat-suppressed early post-contrast T1W image. Pathology: Invasive ductal carcinoma.

G. ASSOCIATED FEATURES

7. CHEST WALL INVOLVEMENT

The enhancement of the malignancy or suspicious finding extends into or otherwise involves the chest wall. The chest wall is defined as the intercostal muscles, serratus anterior muscles and osseous structures in breast cancer staging. To qualify as chest wall involvement, there should be definitive extension of enhancement into the chest wall structure(s). Enhancement that abuts but does not extend into the structure(s) should be described as abutting but not invading the structure(s).

The pectoralis muscles are separate from the chest wall in breast cancer staging. Pectoralis muscle involvement is not chest wall involvement, and pectoralis muscle involvement should be reported separately if present.

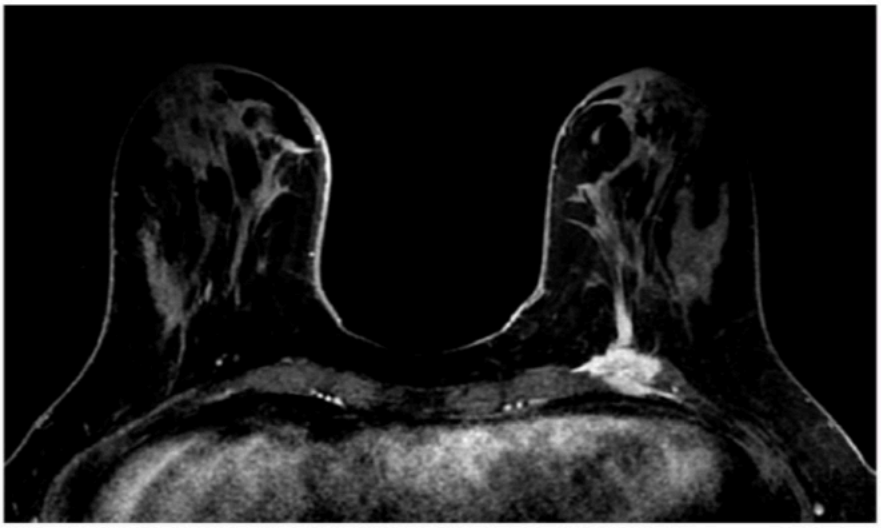

A

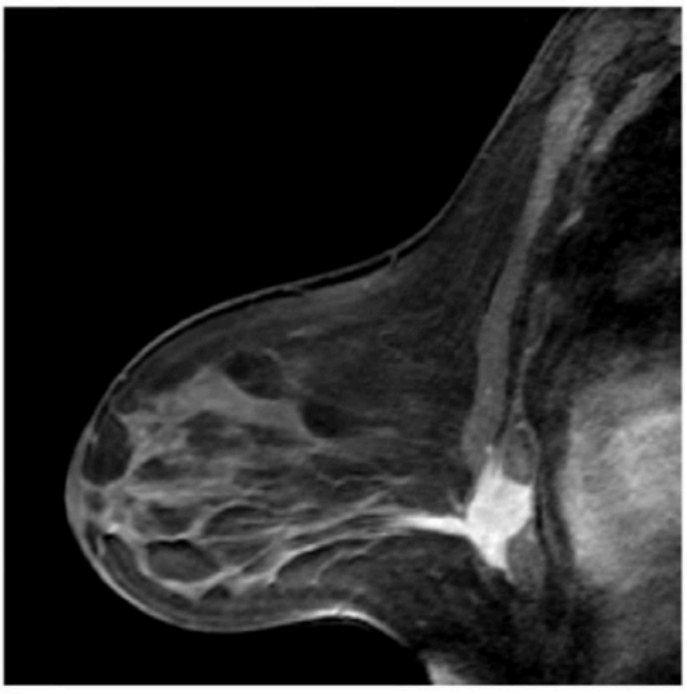

B

Figure 1 – CHEST WALL INVOLVEMENT. Enhancement involving the chest wall (intercostal muscles) and pectoralis major muscle. The involvement of the intercostal muscles constitutes the chest wall involvement in this case, not the pectoralis muscle involvement. (A) Axial and (B) sagittal fat-suppressed early post-contrast T1W images. Pathology: Invasive ductal carcinoma.

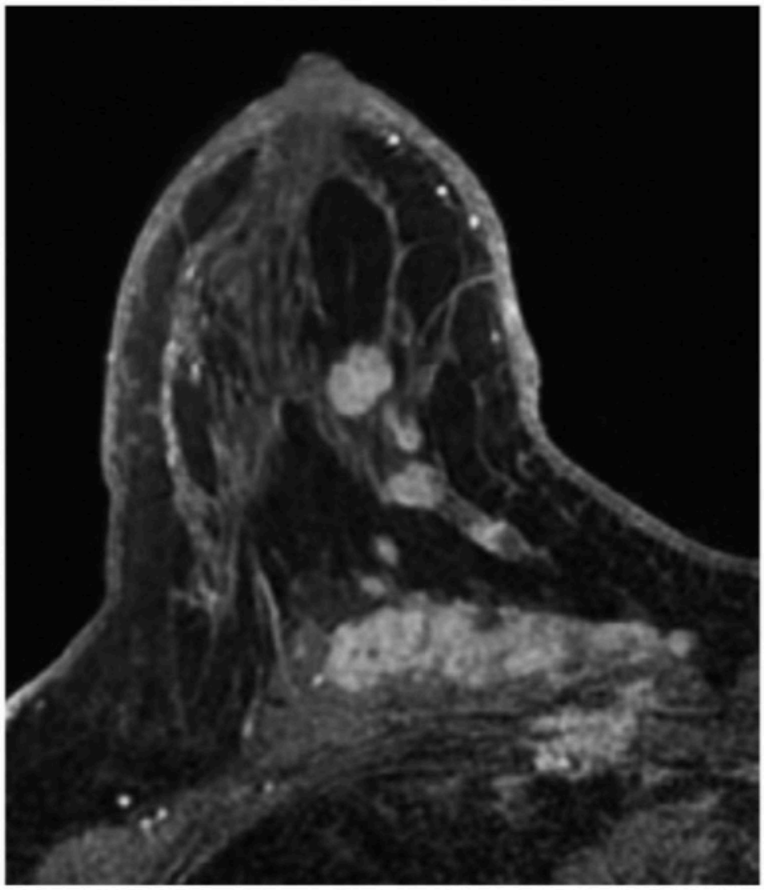

Figure 2 – CHEST WALL INVOLVEMENT. Enhancement involving the chest wall (intercostal muscles) and pectoralis major muscle. The involvement of the intercostal muscles constitutes the chest wall involvement in this case, not the pectoralis muscle involvement. Fat-suppressed early post-contrast T1W image. Pathology: Invasive ductal carcinoma.

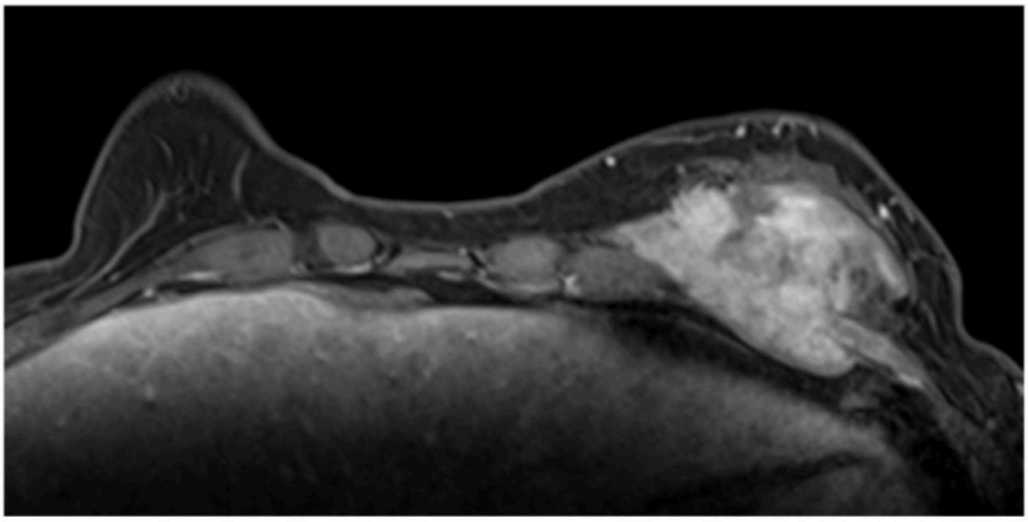

A

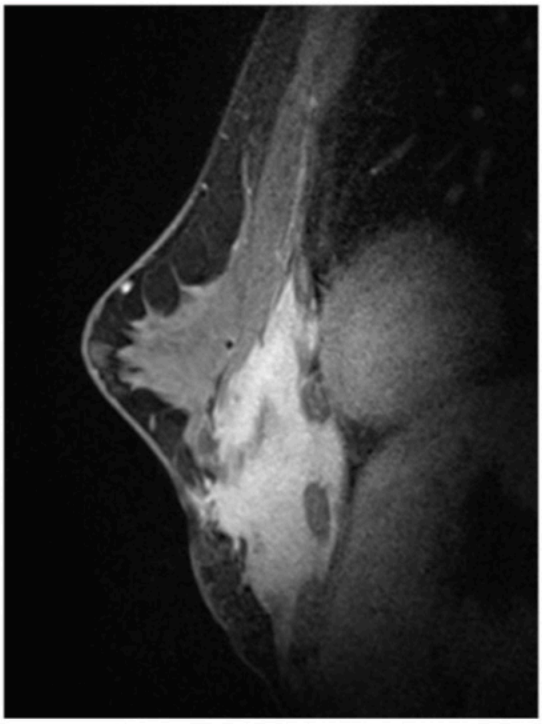

B

Figure 3 – CHEST WALL INVOLVEMENT. Enhancement involving the chest wall (intercostal muscles) and pectoralis major muscle. The involvement of the intercostal muscles constitutes the chest wall involvement in this case. (A) Axial and (B) sagittal fat-suppressed early post-contrast T1W images. Pathology: Desmoid tumor.

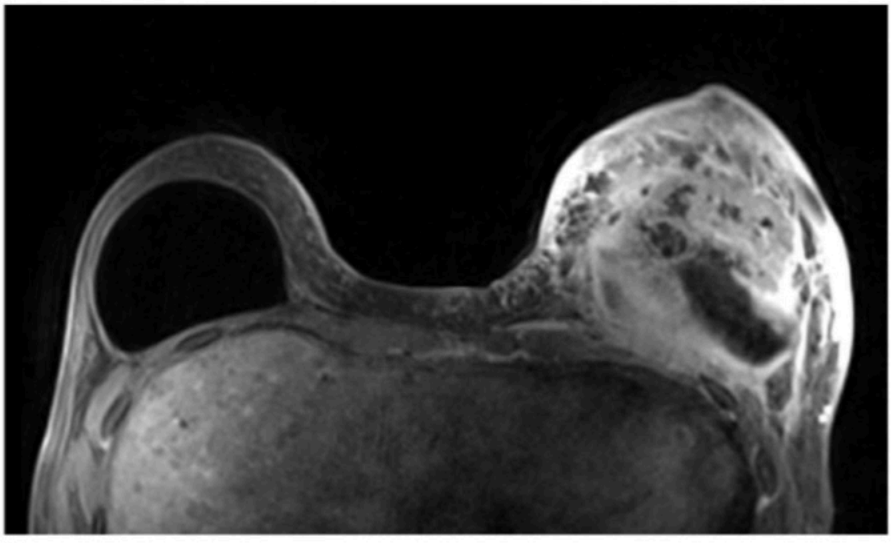

A

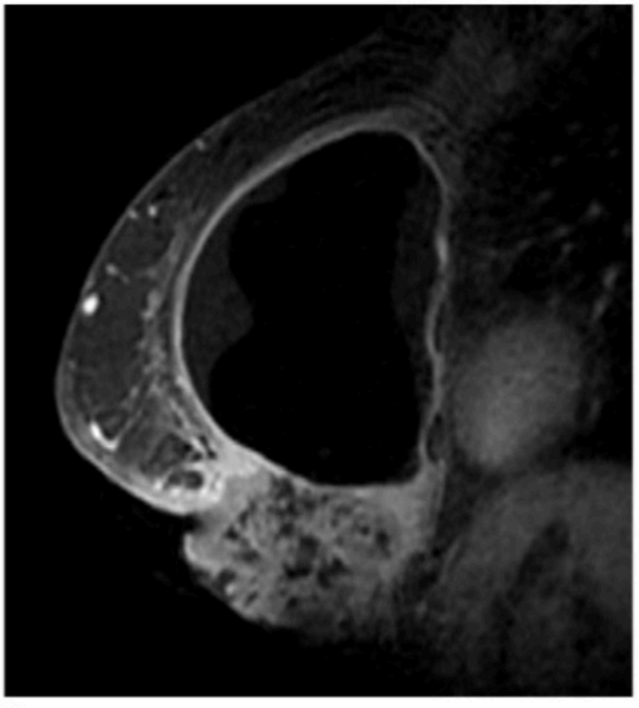

B

Figure 4 – CHEST WALL INVOLVEMENT. Enhancement involving the chest wall (intercostal muscles) and pectoralis major muscle. The involvement of the intercostal muscles constitutes the chest wall involvement in this case. There is also skin involvement. (A) Axial and (B) sagittal fat-suppressed early post-contrast T1W images. Pathology: Invasive ductal carcinoma.

G. ASSOCIATED FEATURES

8. PERITUMORAL EDEMA

Hyperintense T2 signal is present in the tissue surrounding a malignant or suspicious finding. It may suggest a malignant etiology of the finding, and for extensive malignancies is associated with an increased risk of lymph node metastases [12]. However, this feature can also be present due to benign etiologies such as post-biopsy change.

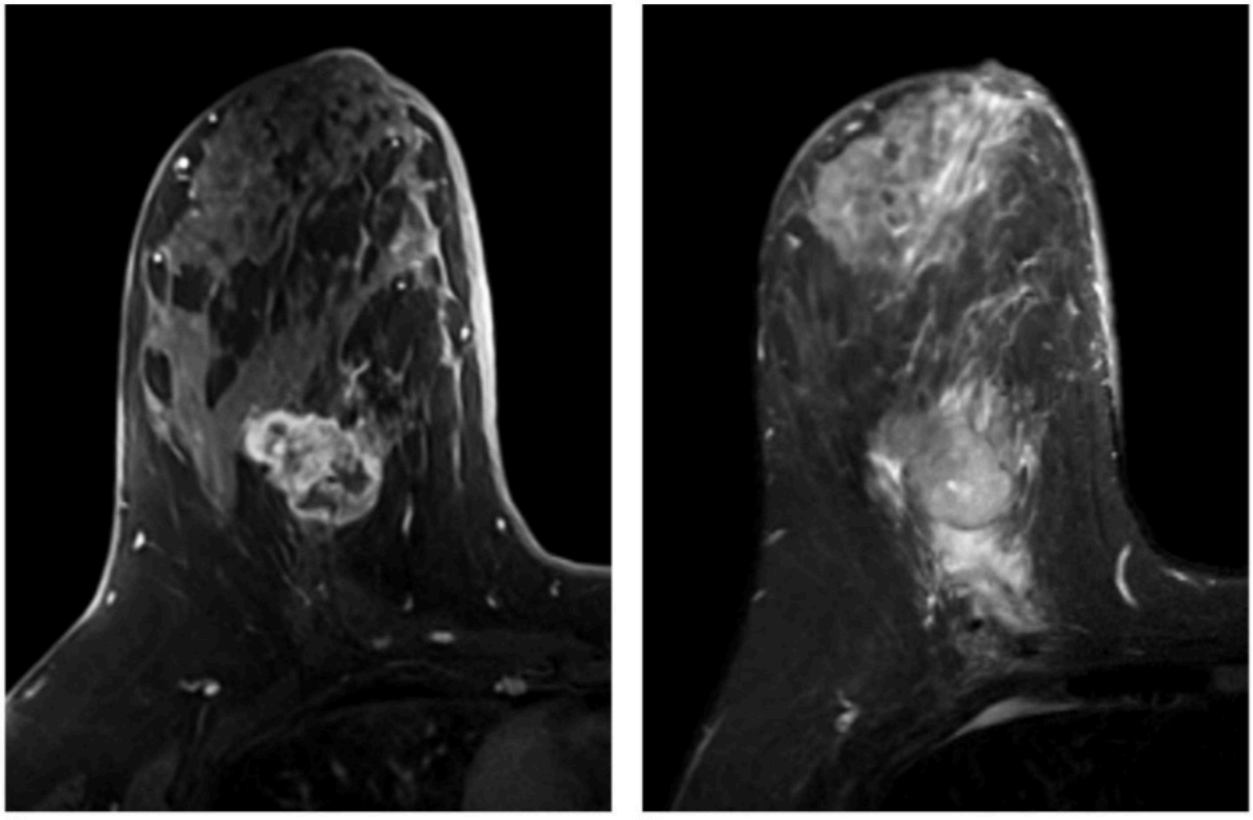

A B

Figure 1 – PERITUMORAL EDEMA. Edema, seen on the T2W image, surrounds an irregular, indistinct, heterogeneous mass. (A) Fat-suppressed early post-contrast T1W image. (B) Fat-suppressed T2W image. Pathology: Invasive ductal carcinoma.

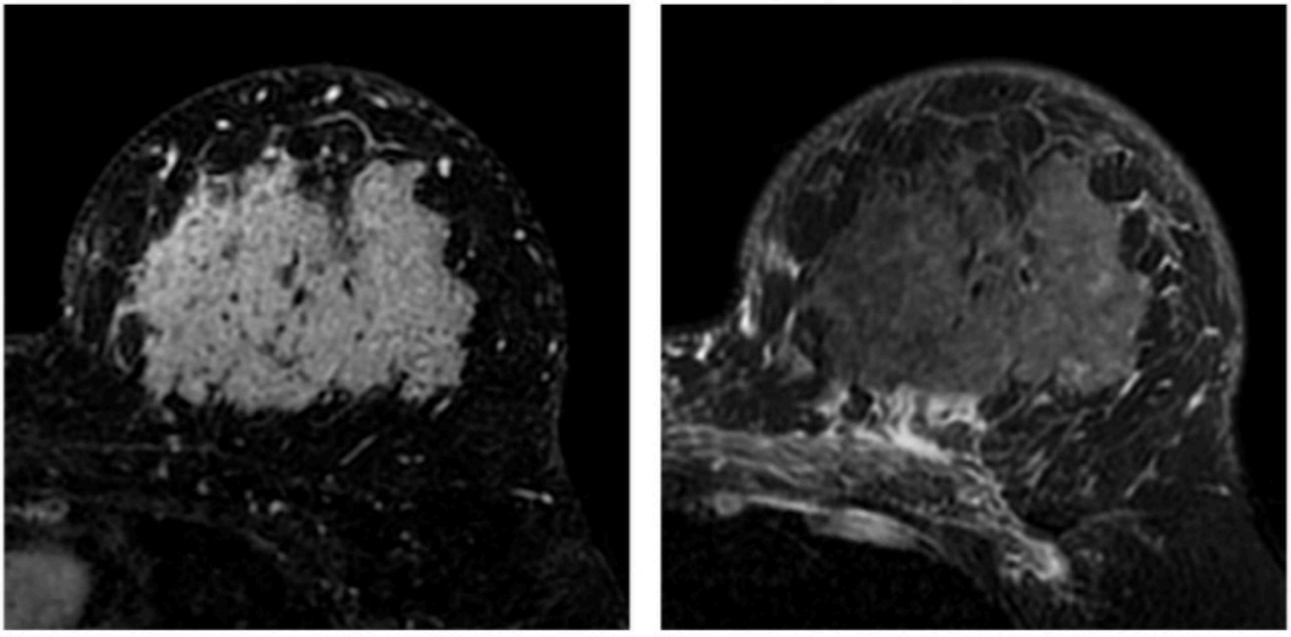

A B

Figure 2 – PERITUMORAL EDEMA. Skin thickening and peritumoral edema due to inflammatory breast cancer. (A) Early post-contrast T1W subtracted image. (B) Fat-suppressed T2W image. Pathology: Invasive ductal carcinoma.

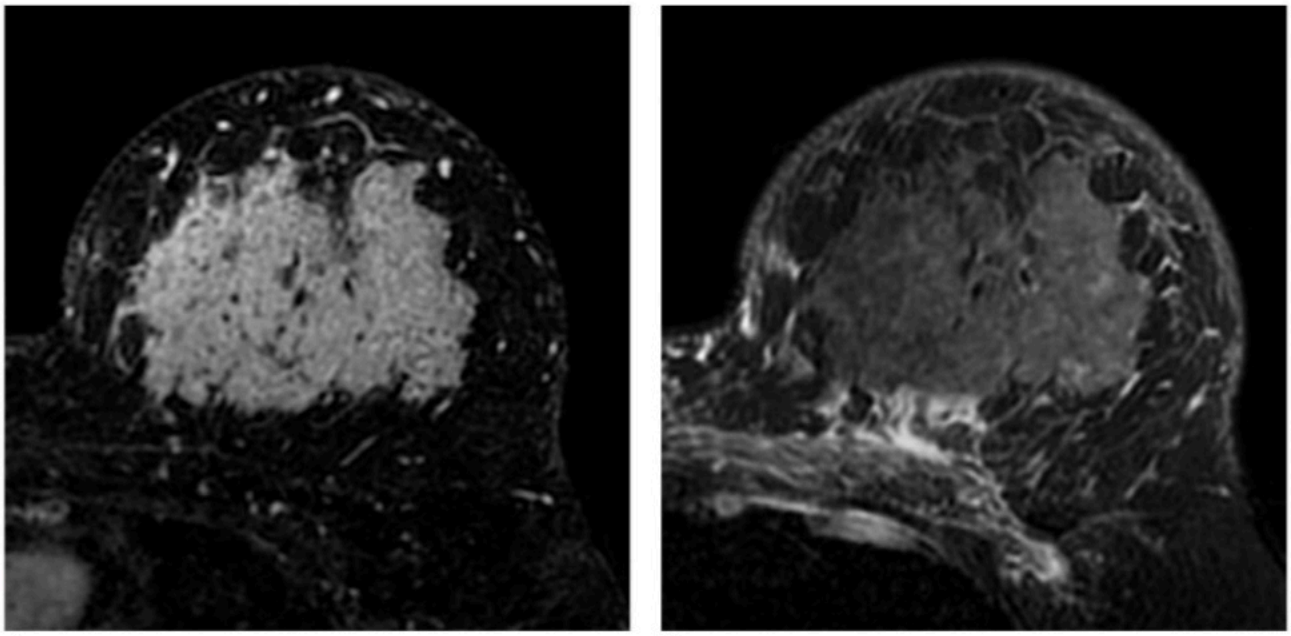

A B

Figure 2 – PERITUMORAL EDEMA. Skin thickening and peritumoral edema due to inflammatory breast cancer. (A) Early post-contrast T1W subtracted image. (B) Fat-suppressed T2W image. Pathology: Invasive ductal carcinoma.

H. OTHER FINDINGS — TYPICALLY BENIGN

1. HIGH T1 DUCT SIGNAL

   Hyperintense signal is present in ducts on T1-weighted images before contrast administration. When there is no associated suspicious enhancement, this finding is benign. The high T1 duct signal is due to blood or protein in the fluid within the ducts. However, if there is coexisting ductal enhancement after contrast administration, other etiologies (e.g., papilloma, DCIS) should be considered.

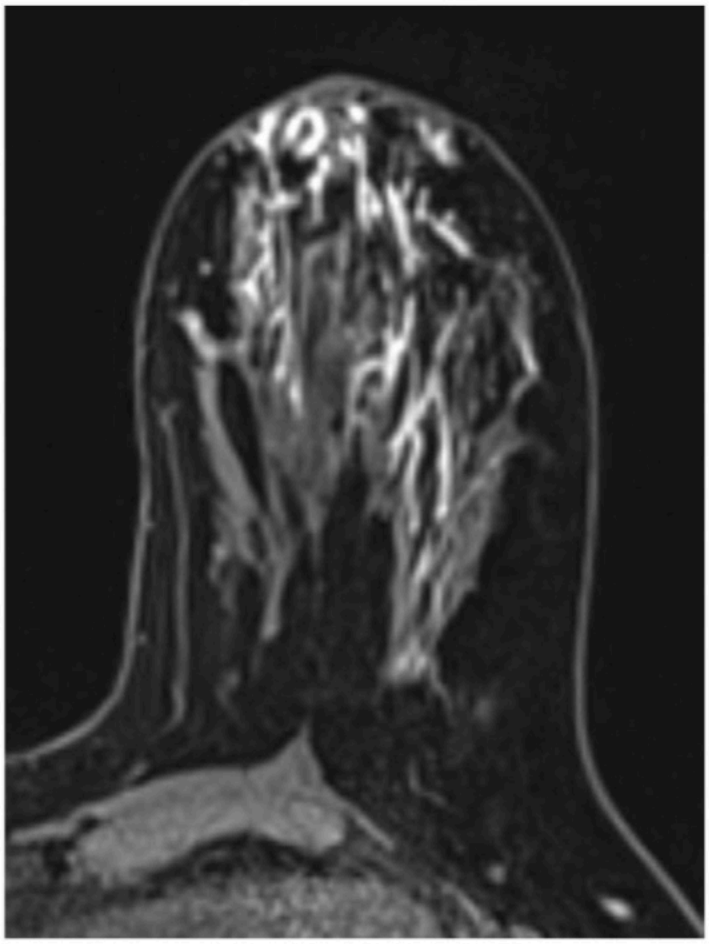

Figure 1 – HIGH T1 DUCT SIGNAL. Fat-suppressed non-contrast T1W image.

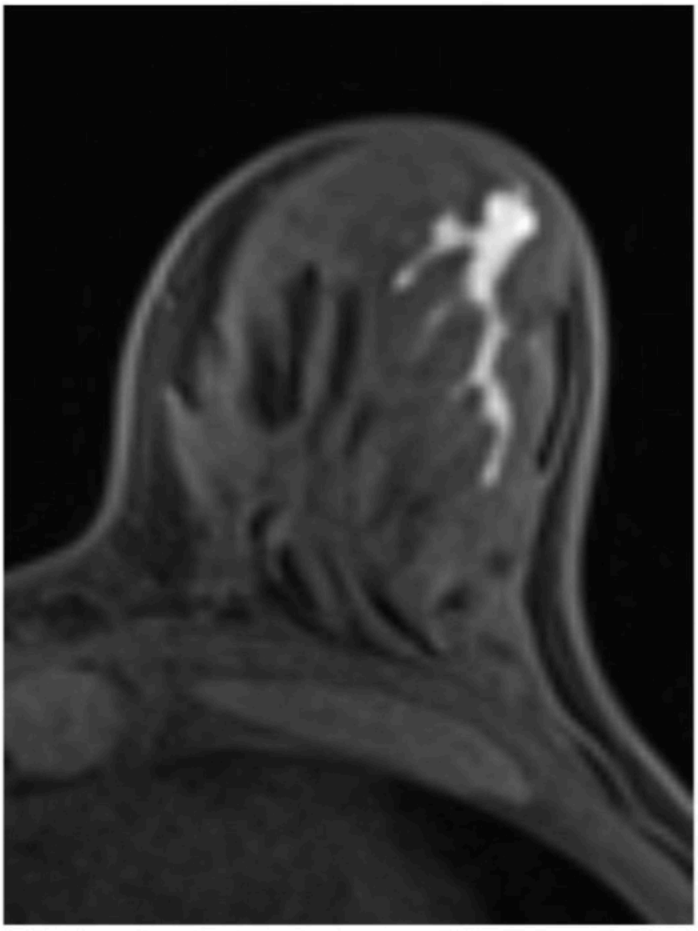

Figure 2 – HIGH T1 DUCT SIGNAL. Fat-suppressed non-contrast T1W image.

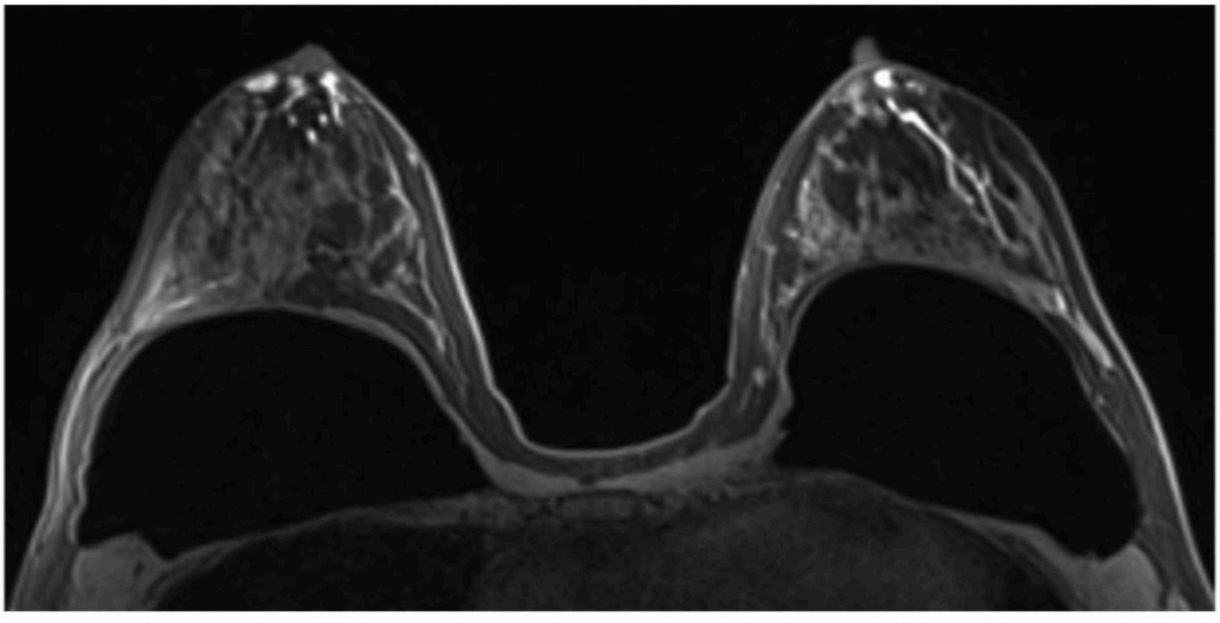

Figure 3 – HIGH T1 DUCT SIGNAL. Fat-suppressed non-contrast T1W image.

H. OTHER FINDINGS — TYPICALLY BENIGN

2. CYSTS

A cyst is a circumscribed, round or oval, fluid-filled mass with a thin wall. Cysts are usually hyperintense on T2 images but may also be hypointense on T2 images and hyperintense on T1 images when their contents are proteinaceous or hemorrhagic. A cyst may have thin peripheral peri-cystic enhancement of the adjacent parenchymal tissue (which should be distinguished from the thick rim enhancement that can be associated with suspicious masses.)

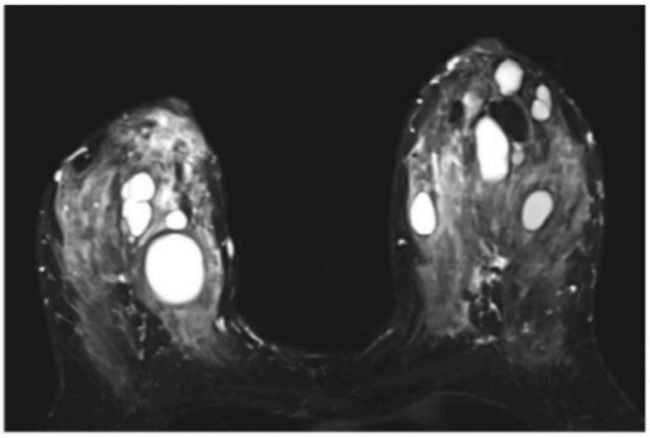

A

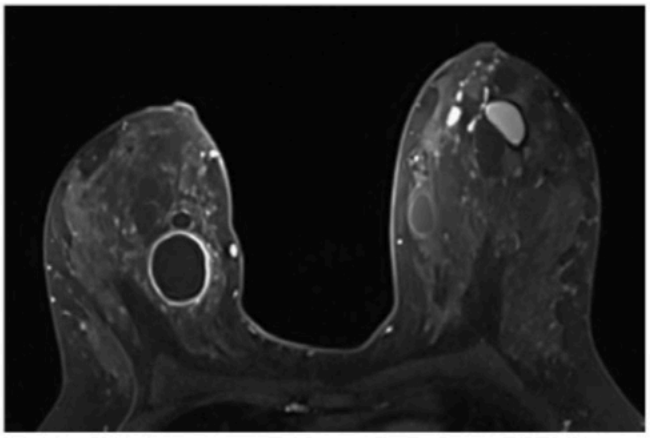

B

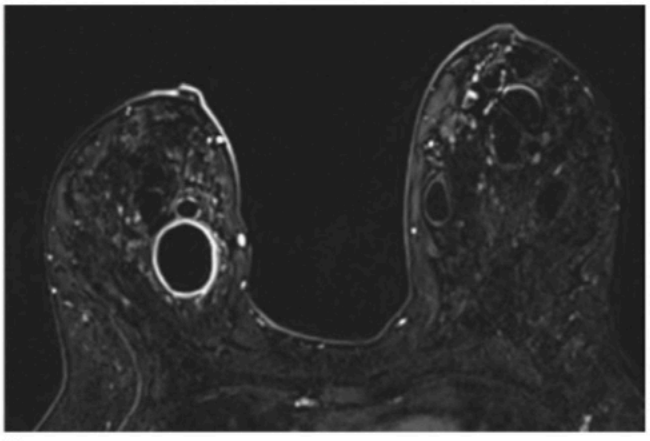

C

Figure 1 – CYSTS. A few of the cysts show thin peripheral peri-cystic enhancement, which is different from thick rim enhancement that can be seen in suspicious masses. (A) Fat-suppressed T2W image. (B) Fat-suppressed early post-contrast T1W image. (C) Early post-contrast T1W subtracted image.

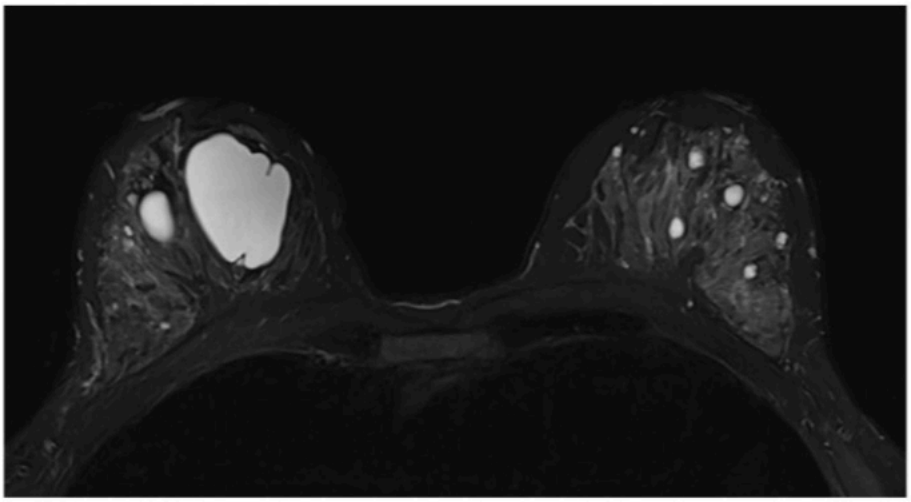

A

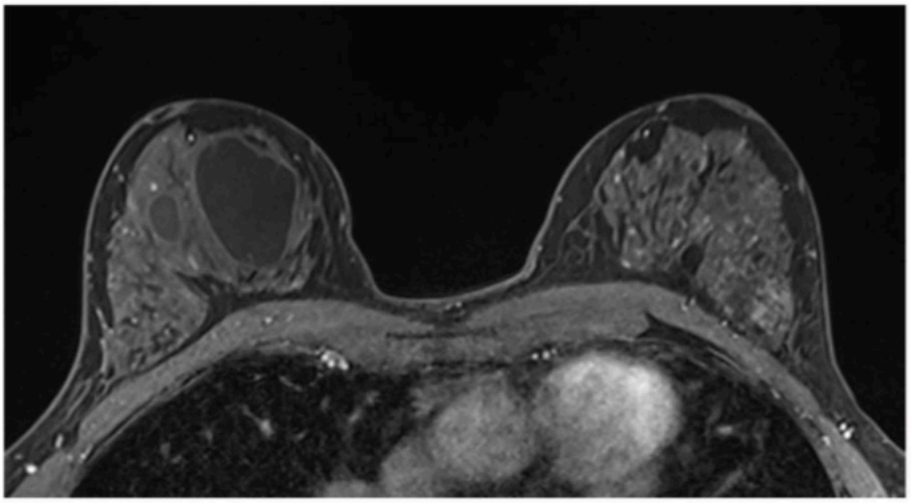

B

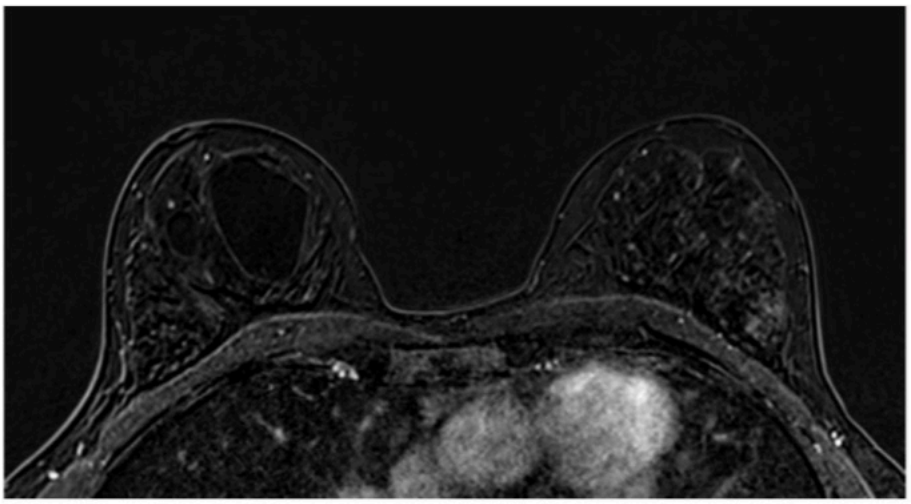

C

Figure 2 – CYSTS. (A) Fat-suppressed T2W image. (B) Fat-suppressed early post-contrast T1W image. (C) Early post-contrast T1W subtracted image.

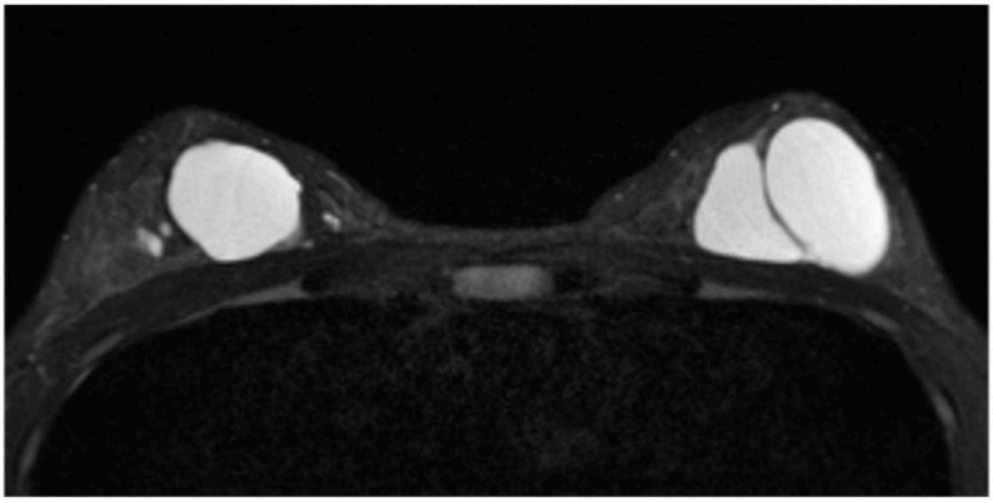

A

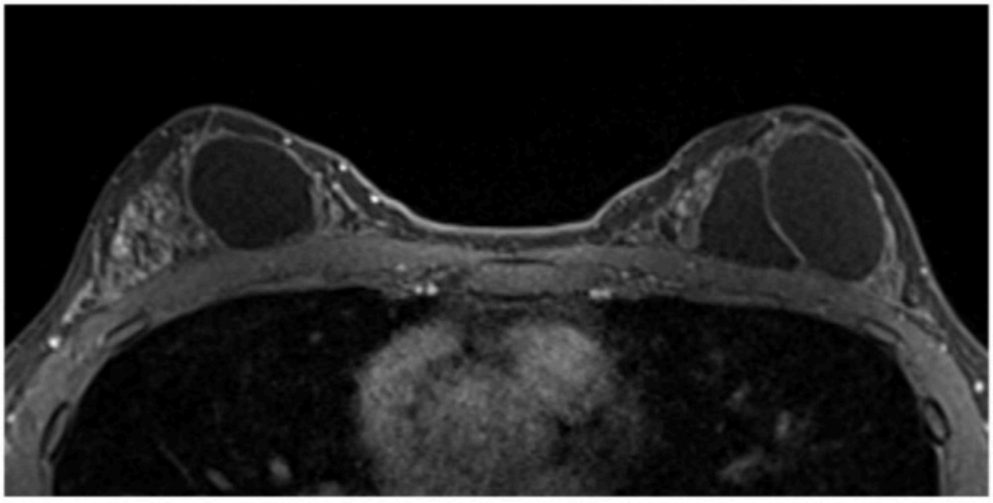

B

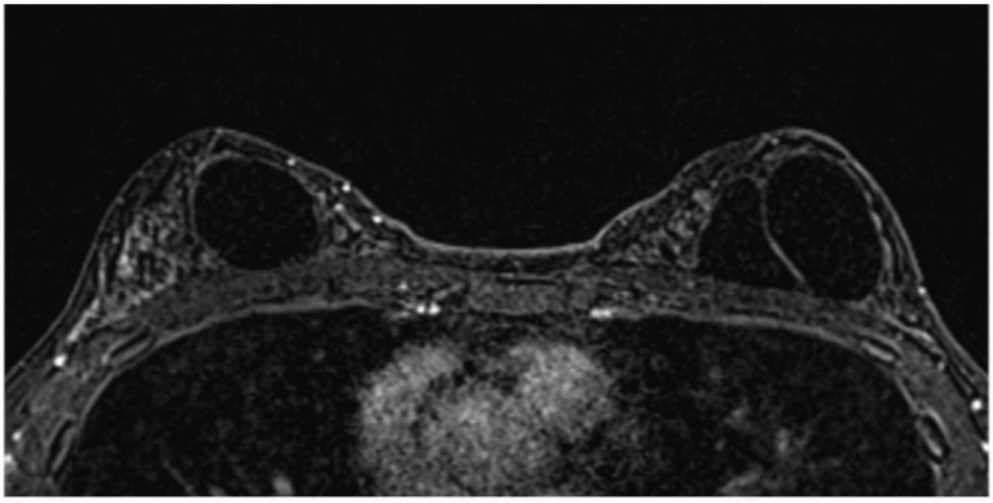

C

Figure 3 – CYSTS. (A) Fat-suppressed T2W image. (B) Fat-suppressed early post-contrast T1W image. (C) Early post-contrast T1W subtracted image.

H. OTHER FINDINGS — TYPICALLY BENIGN

3. POSTOPERATIVE COLLECTIONS (HEMATOMA/SEROMA)

Postoperative collections are often T2 hyperintense and may also have bright signal on T1 weighted imaging due to blood or protein and a fluid-fluid level, in an area of tissue with marked BPE. A fat-fluid layer may be present. Postoperative collections may demonstrate thin peripheral enhancement, a benign pattern.

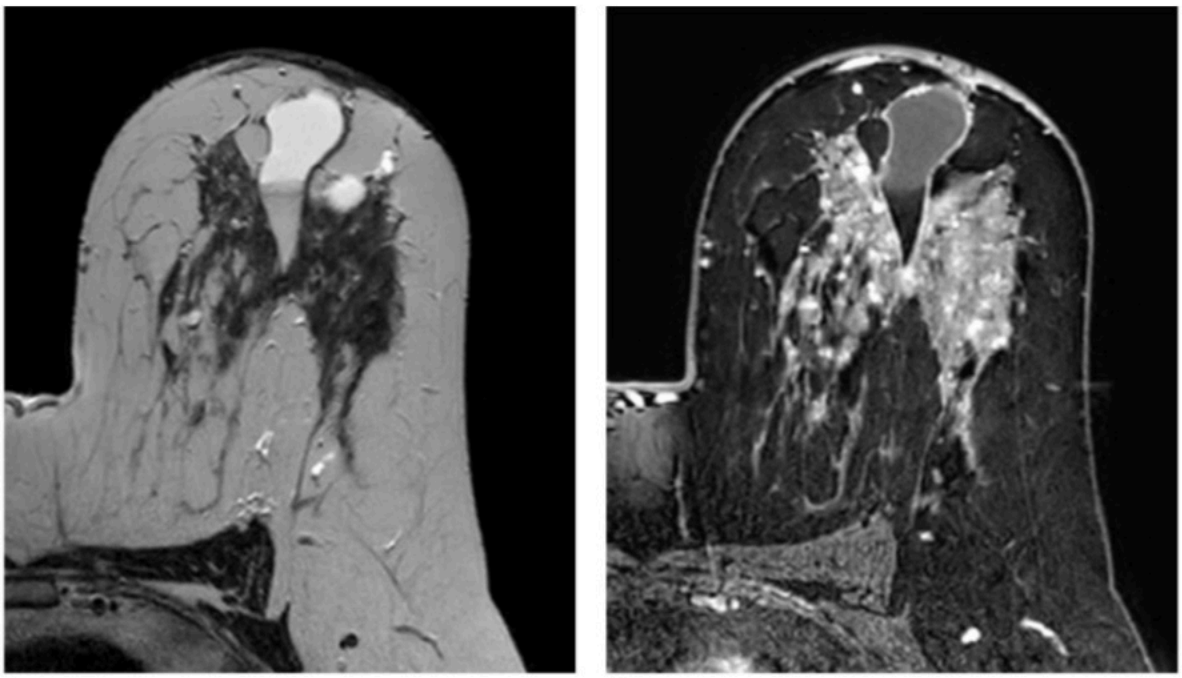

A B

Figure 1 – POSTOPERATIVE COLLECTIONS. Postoperative collection with benign thin peripheral enhancement and fluid-fluid level. (A) Non-fat-suppressed T2W image. (B) Fat-suppressed early post-contrast T1W image.

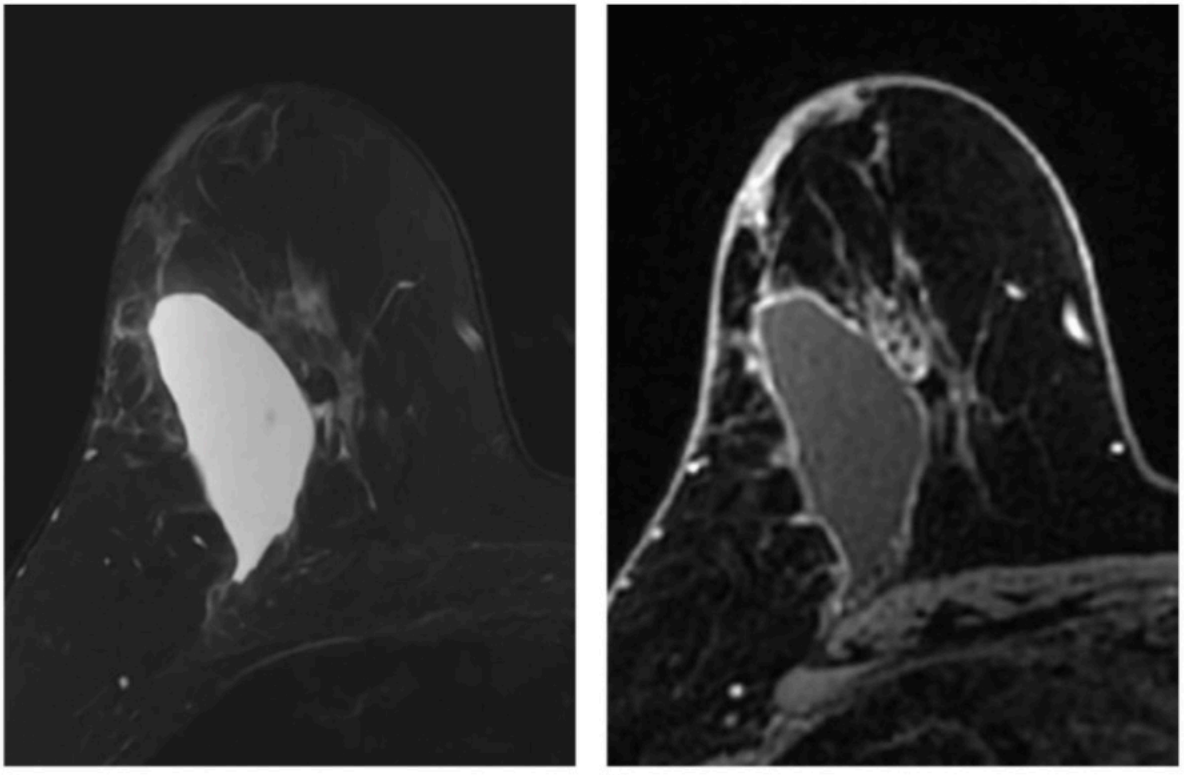

A B

Figure 2 – POSTOPERATIVE COLLECTIONS. Postoperative collection with benign thin peripheral enhancement. (A) Fat-suppressed T2W image. (B) Fat-suppressed early post-contrast T1W image.

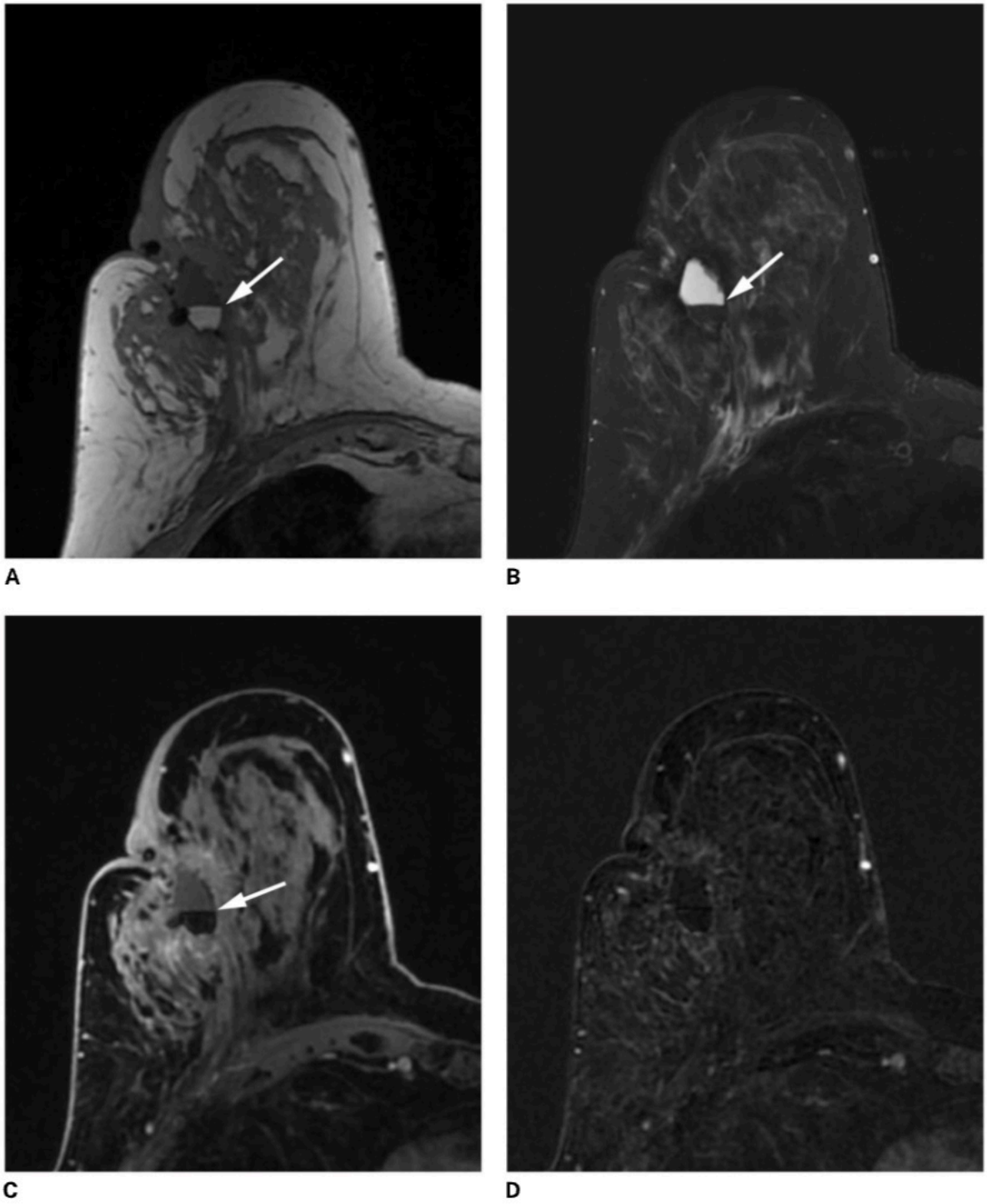

Figure 3 – POSTOPERATIVE COLLECTIONS. Postoperative collection with fluid-fluid level (arrows). (A) Non-fat-suppressed non-contrast T1W image. (B) Fat-suppressed T2W image. (C) Fat-suppressed early post-contrast T1W image. (D) Early post-contrast T1W subtracted image.

H. OTHER FINDINGS — TYPICALLY BENIGN

4. POST-THERAPY SKIN THICKENING AND TRABECULAR THICKENING

   Trabecular thickening with associated skin thickening may be seen following surgery and/or radiation therapy.

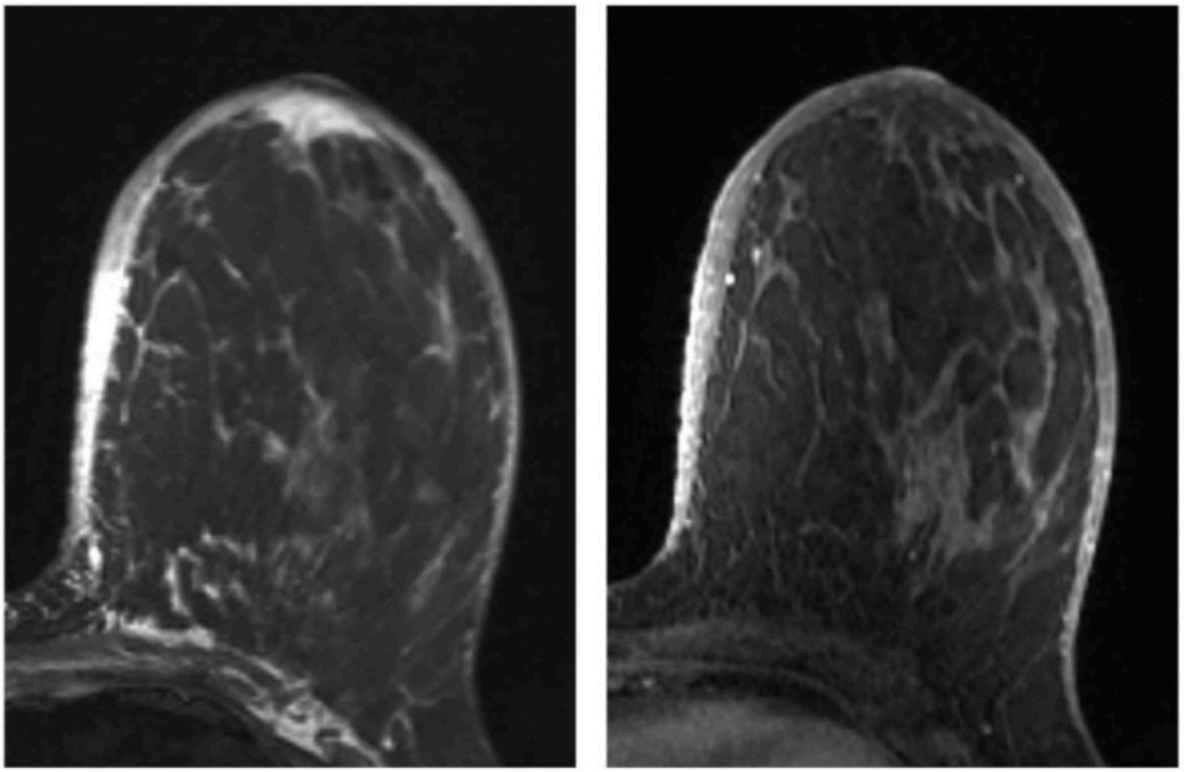

A B

Figure 1 – POST-THERAPY SKIN THICKENING AND TRABECULAR THICKENING due to previous lumpectomy and radiation, with edema also affecting the chest wall. (A) Fat-suppressed T2W image. (B) Fat-suppressed early post-contrast T1W image.

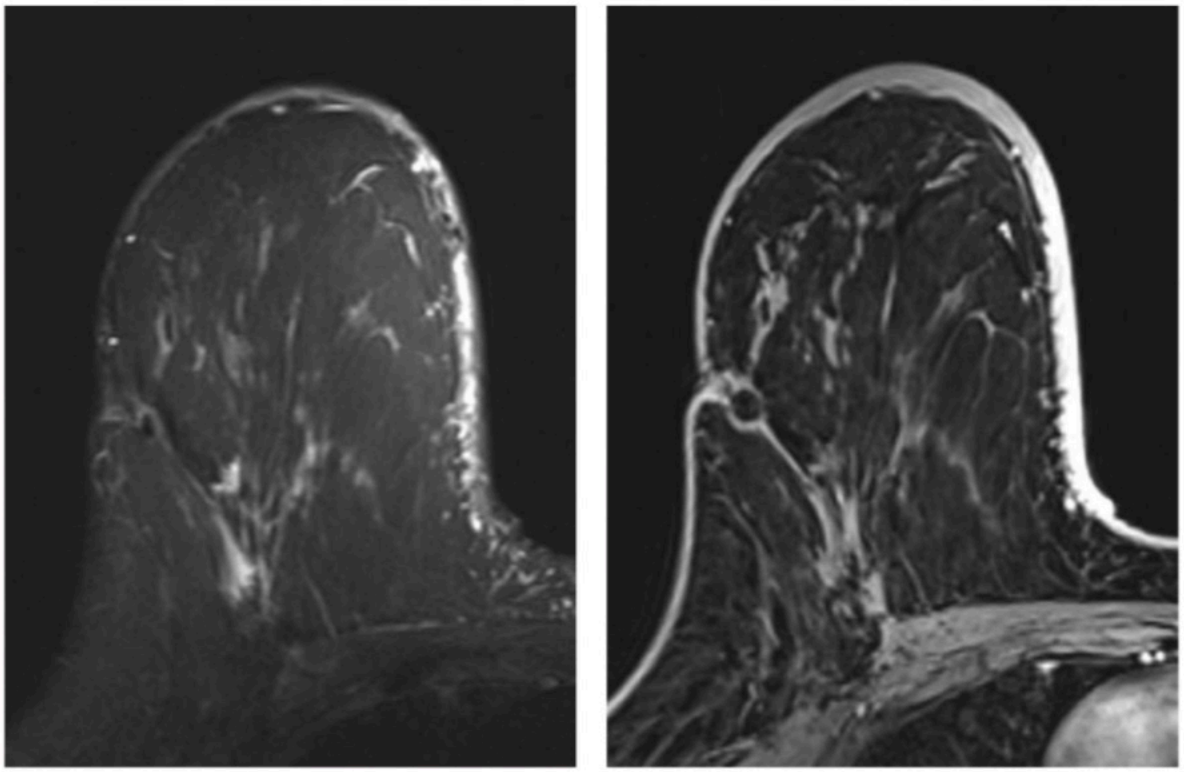

A B

Figure 2 – POST-THERAPY SKIN THICKENING AND TRABECULAR THICKENING due to prior lumpectomy and radiation therapy. (A) Fat-suppressed T2W image. (B) Fat-suppressed early post-contrast T1W image.

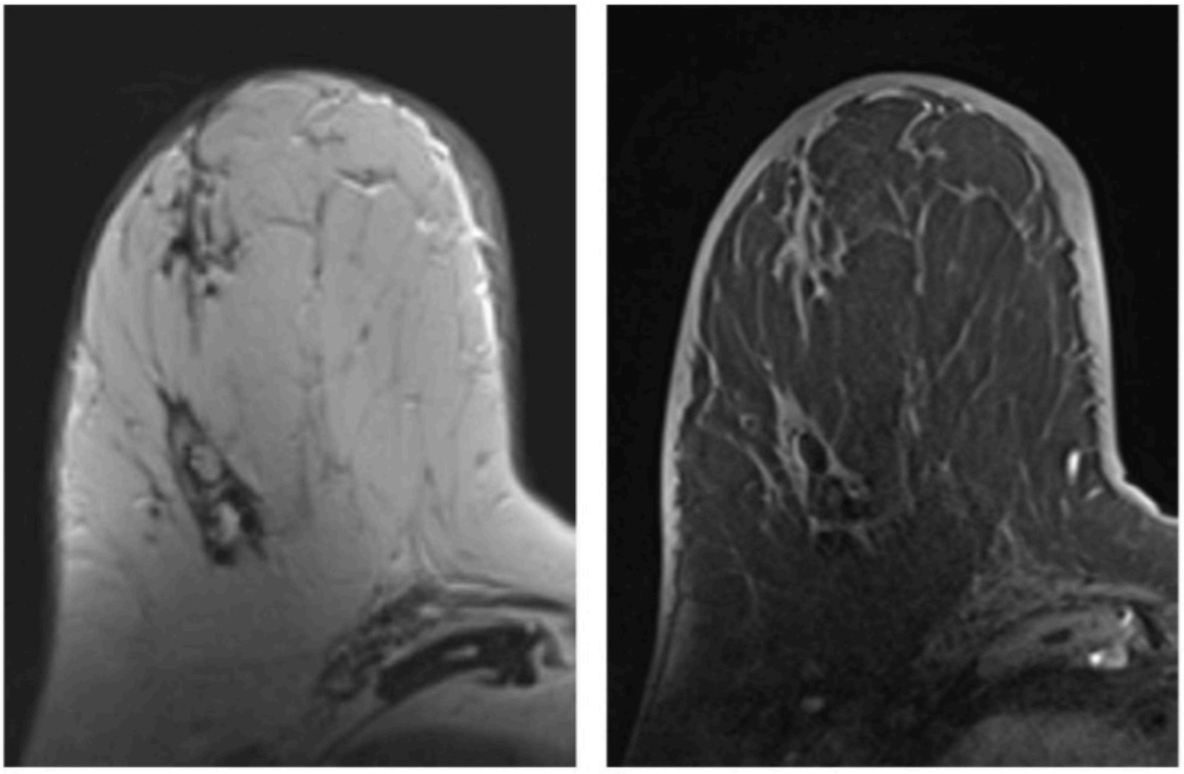

A B

Figure 3 – POST-THERAPY SKIN THICKENING AND TRABECULAR THICKENING due to prior lumpectomy and radiation therapy. (A) Non-fat-suppressed T2W image. (B) Fat-suppressed early post-contrast T1W image.

H. OTHER FINDINGS — TYPICALLY BENIGN

5. NON-ENHANCING MASS

Non-enhancing solid masses do not exhibit enhancement. Subtraction imaging may be useful in confirming absence of enhancement. Other sequences such as T2-weighted images may demonstrate the mass, due to signal characteristics that differentiate it from the surrounding tissue. These non-enhancing solid masses are distinguished from cysts as they do not contain fluid. Non-enhancing masses are benign, other than in specific circumstances such as a known biopsy-proven malignancy after neoadjuvant systemic therapy that persists as a mass but does not enhance after treatment.

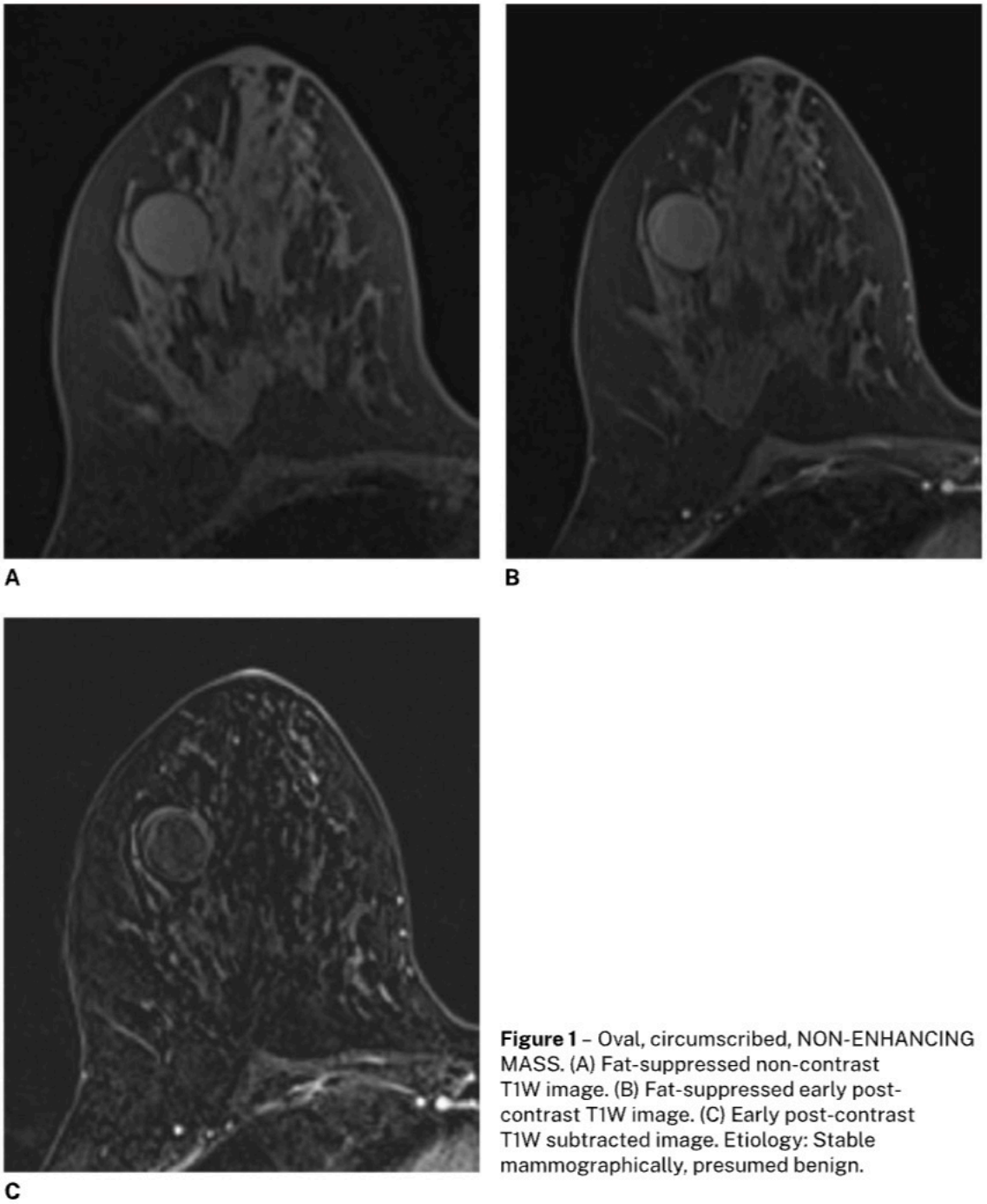

A B C

Figure 1 – Oval, circumscribed, NON-ENHANCING MASS. (A) Fat-suppressed non-contrast T1W image. (B) Fat-suppressed early post-contrast T1W image. (C) Early post-contrast T1W subtracted image. Etiology: Stable mammographically, presumed benign.

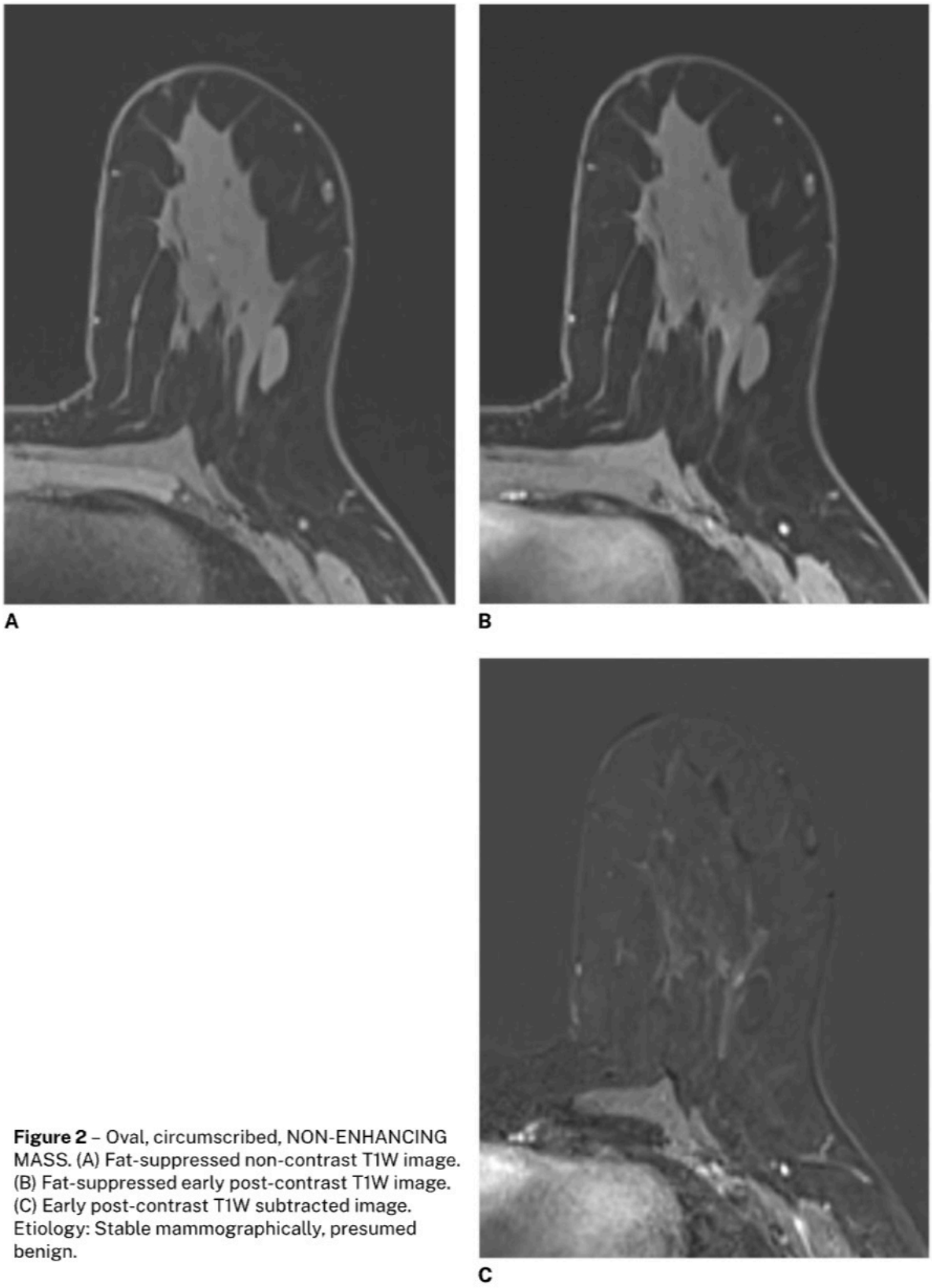

Figure 2 – Oval, circumscribed, NON-ENHANCING MASS. (A) Fat-suppressed non-contrast T1W image. (B) Fat-suppressed early post-contrast T1W image. (C) Early post-contrast T1W subtracted image. Etiology: Stable mammographically, presumed benign.

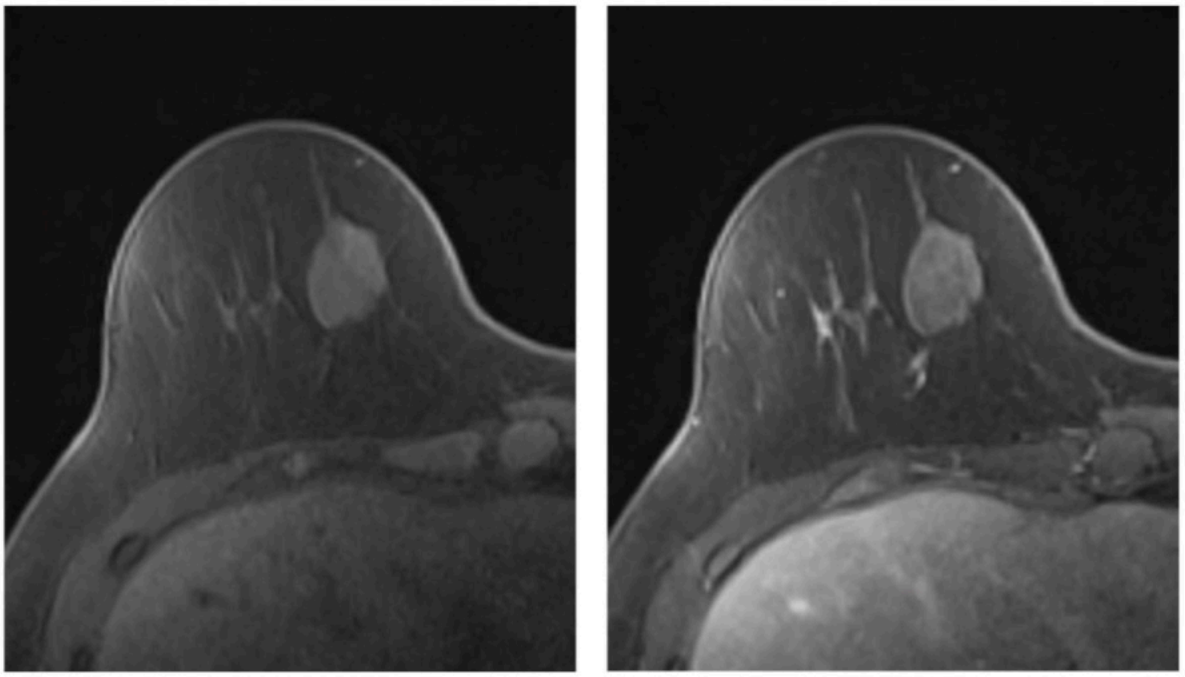

A B

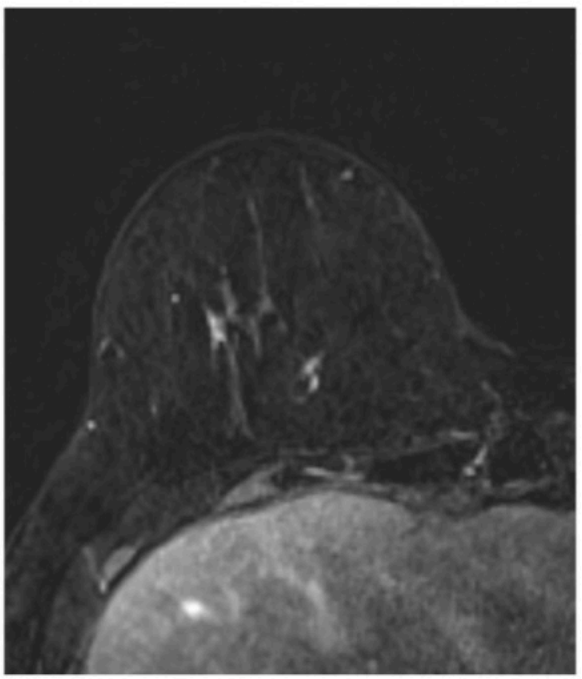

C

Figure 3 – Oval, indistinct, NON-ENHANCING MASS. (A) Fat-suppressed non-contrast T1W image. (B) Fat-suppressed early post-contrast T1W image. (C) Early post-contrast T1W subtracted image. Pathology: Stable mammographically, presumed benign.

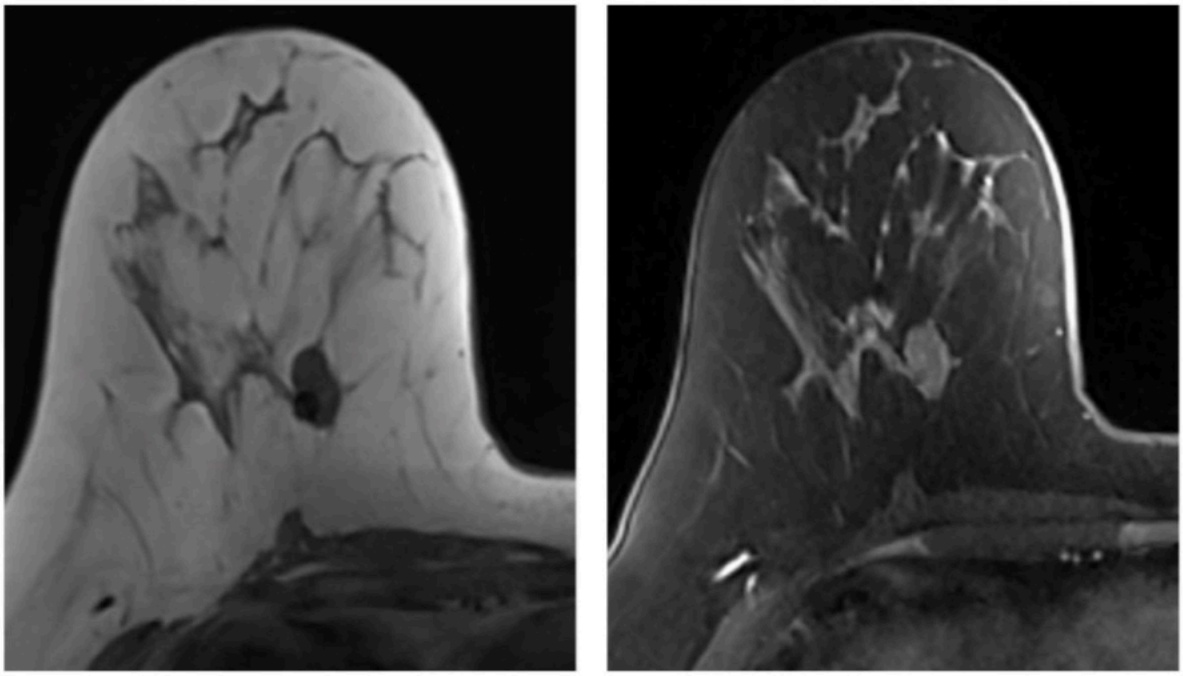

A B

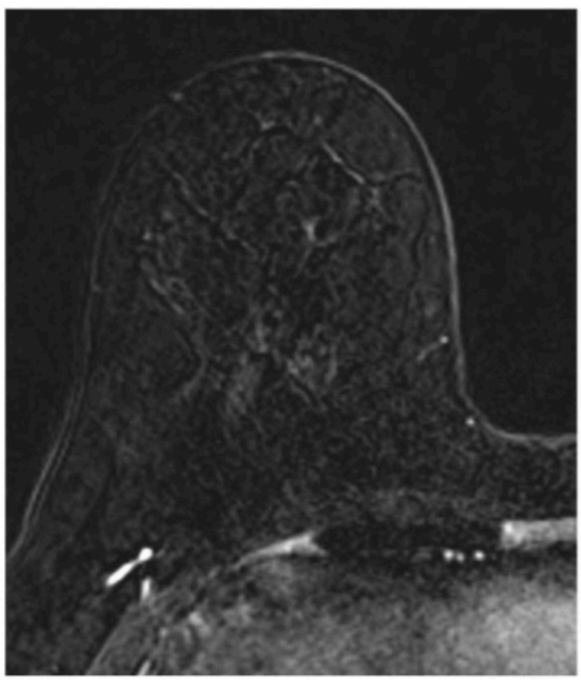

C

Figure 4 – Oval, circumscribed, NON-ENHANCING MASS. (A) Non-fat-suppressed non-contrast T1W image. (B) Fat-suppressed early post-contrast T1W image. (C) Early post-contrast T1W subtracted image. Pathology: Fibroadenoma.

H. OTHER FINDINGS — TYPICALLY BENIGN

6. SIGNAL VOID

   There is an absence of signal due to susceptibility artifact, typically from a metallic clip or other foreign body.

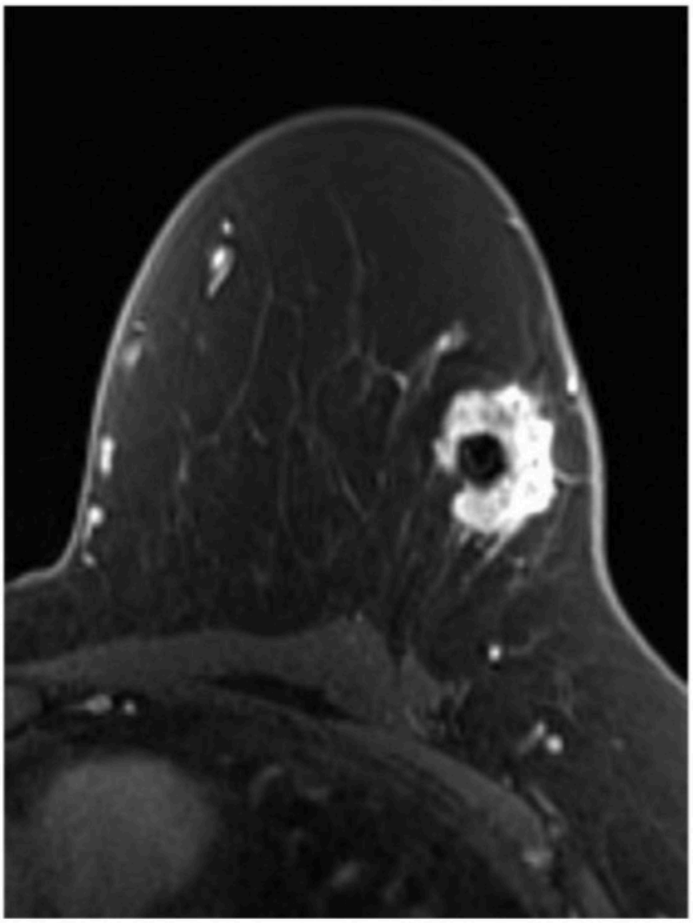

Figure 1 – SIGNAL VOID from a wireless localizer within an irregular, spiculated, heterogeneous mass. Fat-suppressed early post-contrast T1W image. Pathology: Invasive ductal carcinoma.

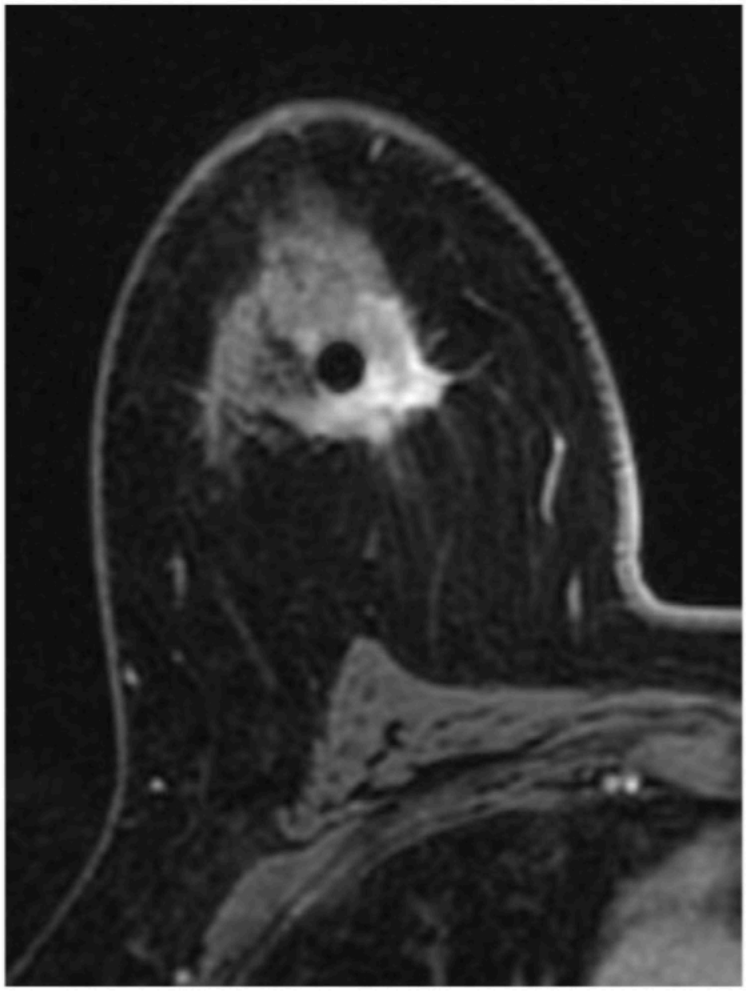

Figure 2 – SIGNAL VOID from a biopsy clip within an irregular, spiculated, heterogeneous mass. Fat-suppressed early post-contrast T1W image. Pathology: Invasive ductal carcinoma.

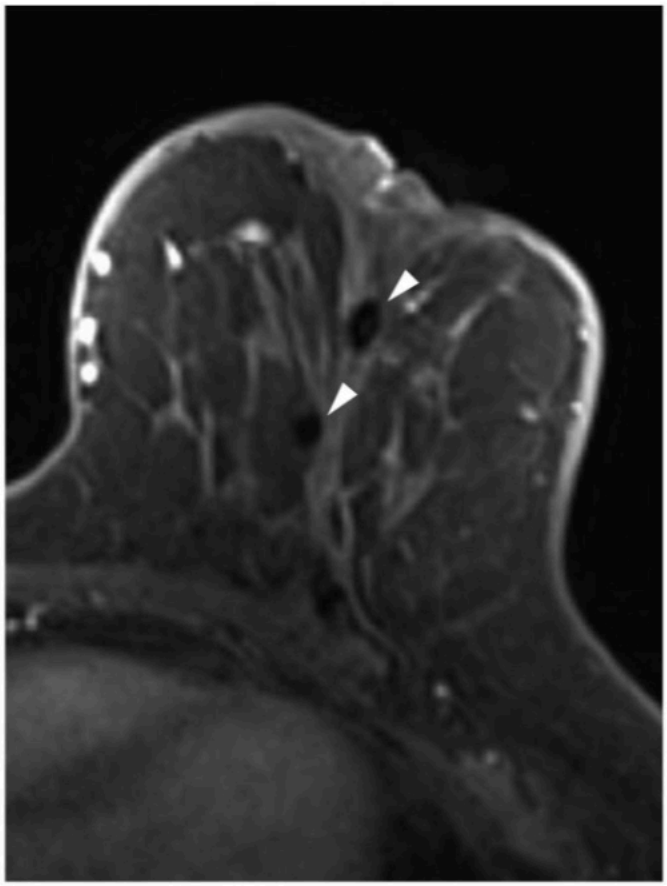

Figure 3 – SIGNAL VOID from multiple surgical clips (arrowheads) at the lumpectomy site. Fat-suppressed early post-contrast T1W image.

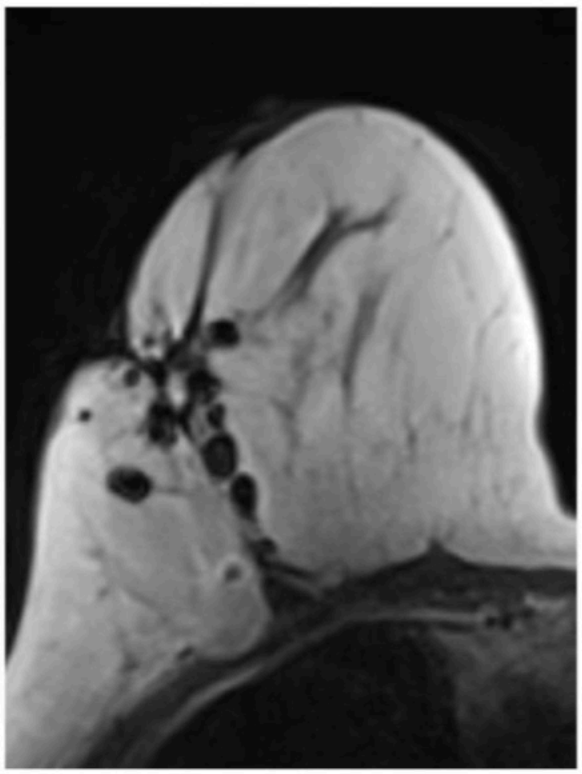

Figure 4 – SIGNAL VOID from multiple surgical clips at the lumpectomy site. Non-fat-suppressed non-contrast T1W image.

H. OTHER FINDINGS — TYPICALLY BENIGN

7. FAT NECROSIS

Focal collections of fat can be present at sites of prior trauma including surgery. Fat necrosis is not uncommon and is benign when confirmed to be localized areas of fat that follow fat signal intensity across sequences. Fat necrosis can have variable enhancement ranging from minimal to pronounced, and enhancement can be present or appear several years after trauma including surgery.

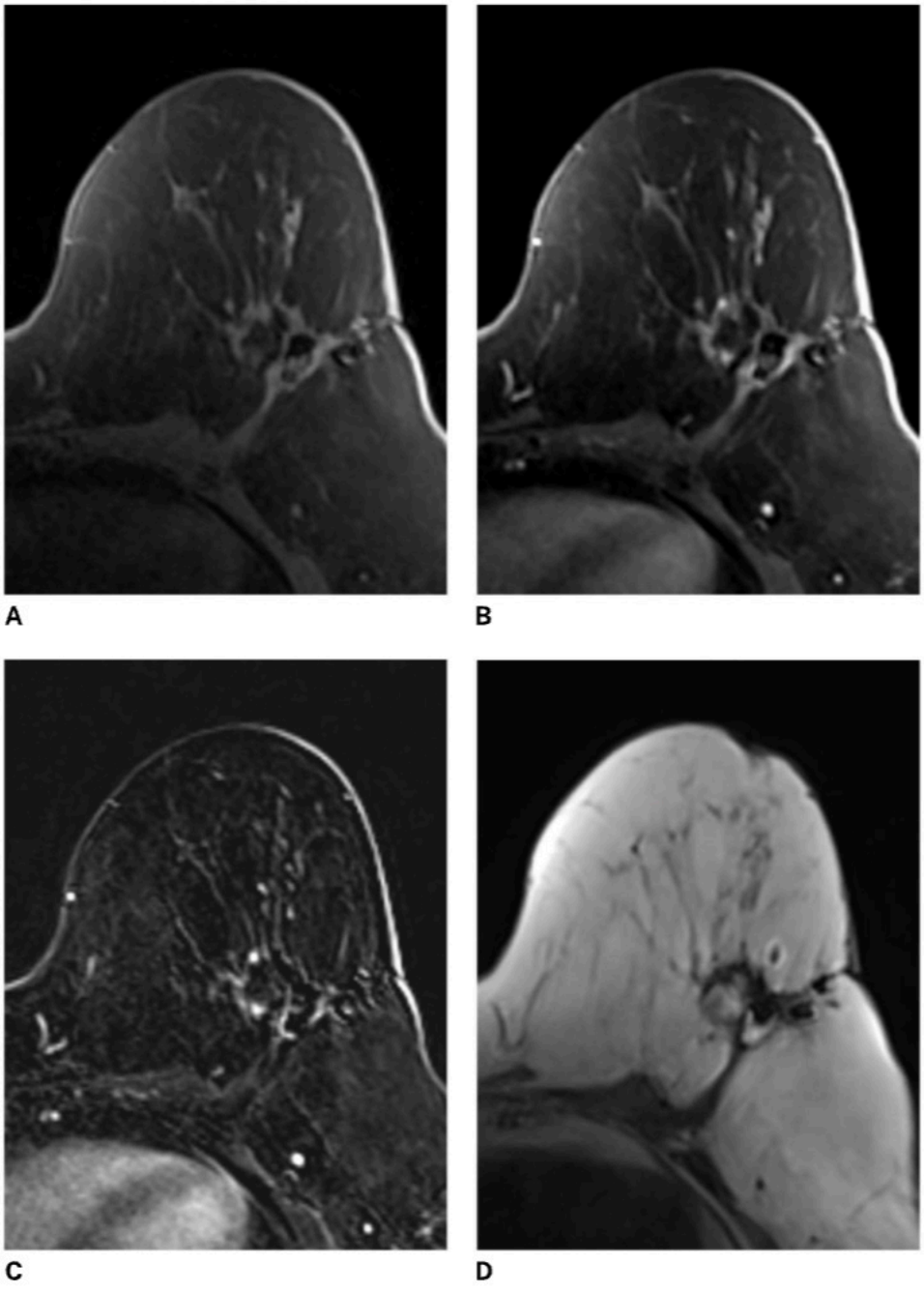

Figure 1 – FAT NECROSIS. Peripheral enhancement with internal fat intensity at site of prior surgery. (A) Fat-suppressed non-contrast T1W image. (B) Fat-suppressed early post-contrast T1W image. (C) Early post-contrast T1W subtracted image. (D) Non-fat-suppressed non-contrast T1W image. Pathology: Postsurgical change.

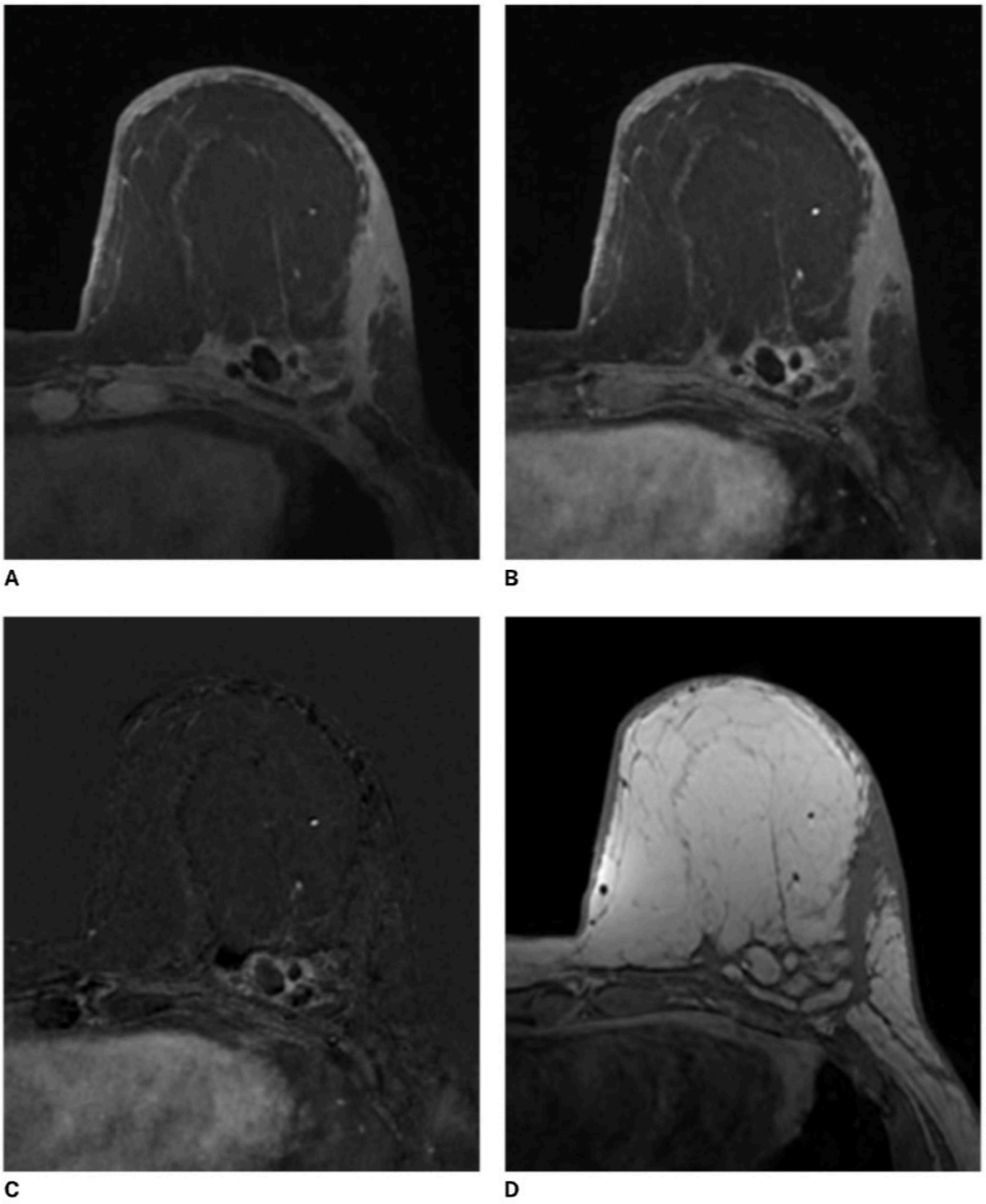

Figure 2 – FAT NECROSIS. Peripheral enhancement with internal fat intensity at site of prior surgery (posterior aspect of mastectomy with TRAM reconstruction.) (A) Fat-suppressed non-contrast T1W image. (B) Fat-suppressed early post-contrast T1W image. (C) Early post-contrast T1W subtracted image. (D) Non-fat-suppressed non-contrast T1W image. Pathology: Postsurgical change.

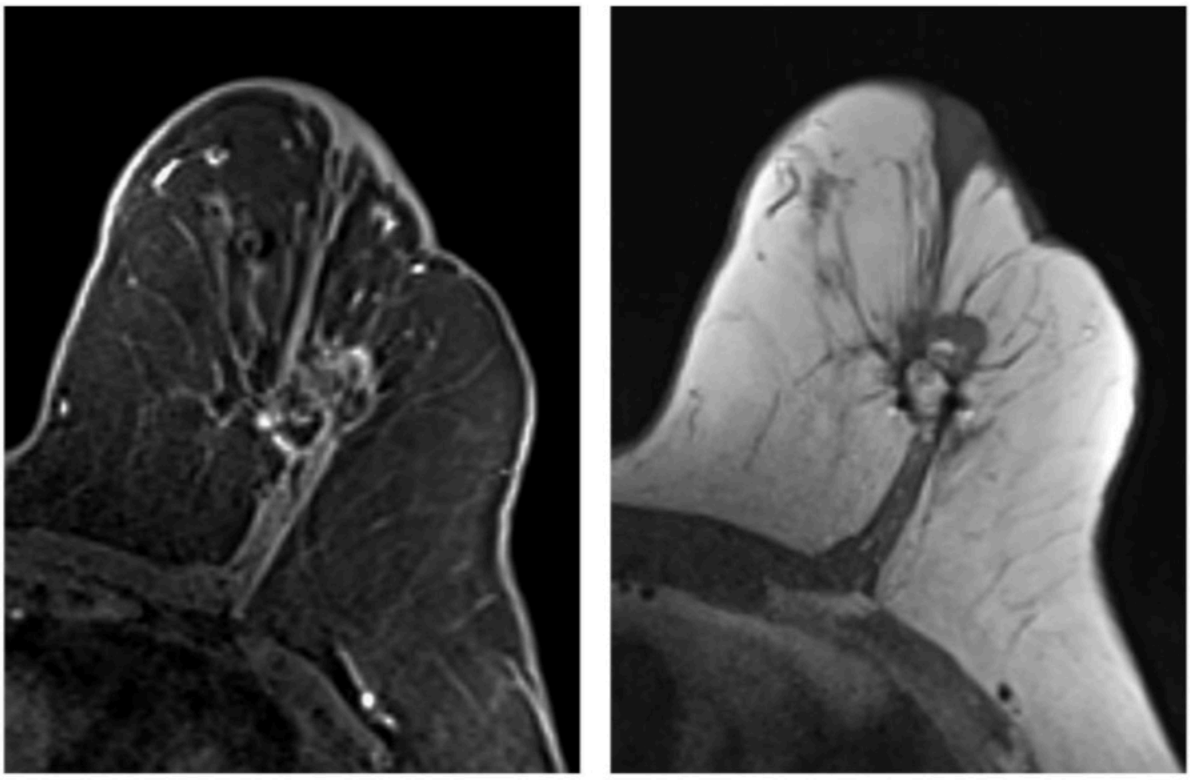

A B

Figure 3 – FAT NECROSIS. Peripheral enhancement with internal fat intensity at site of prior surgery. There is associated skin retraction. (A) Fat-suppressed early post-contrast T1W image. (B) Non-fat-suppressed non-contrast T1W image.

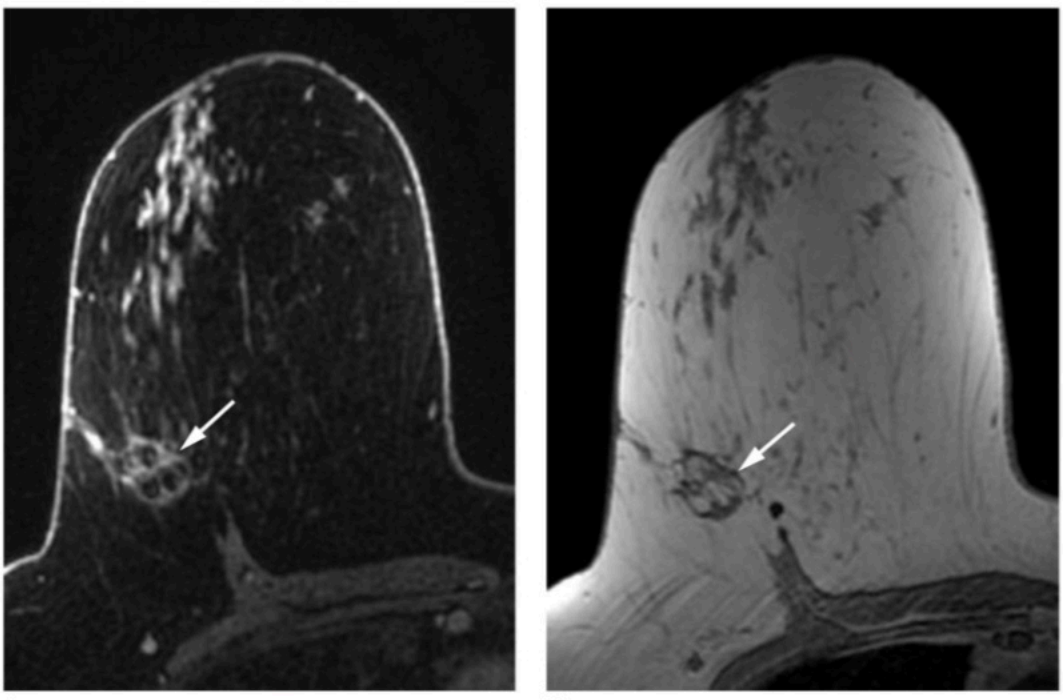

A B

Figure 4 – FAT NECROSIS. Peripheral enhancement with internal fat intensity (arrows). (A) Fat-suppressed early post-contrast T1W image. (B) Non-fat-suppressed non-contrast T1W image.

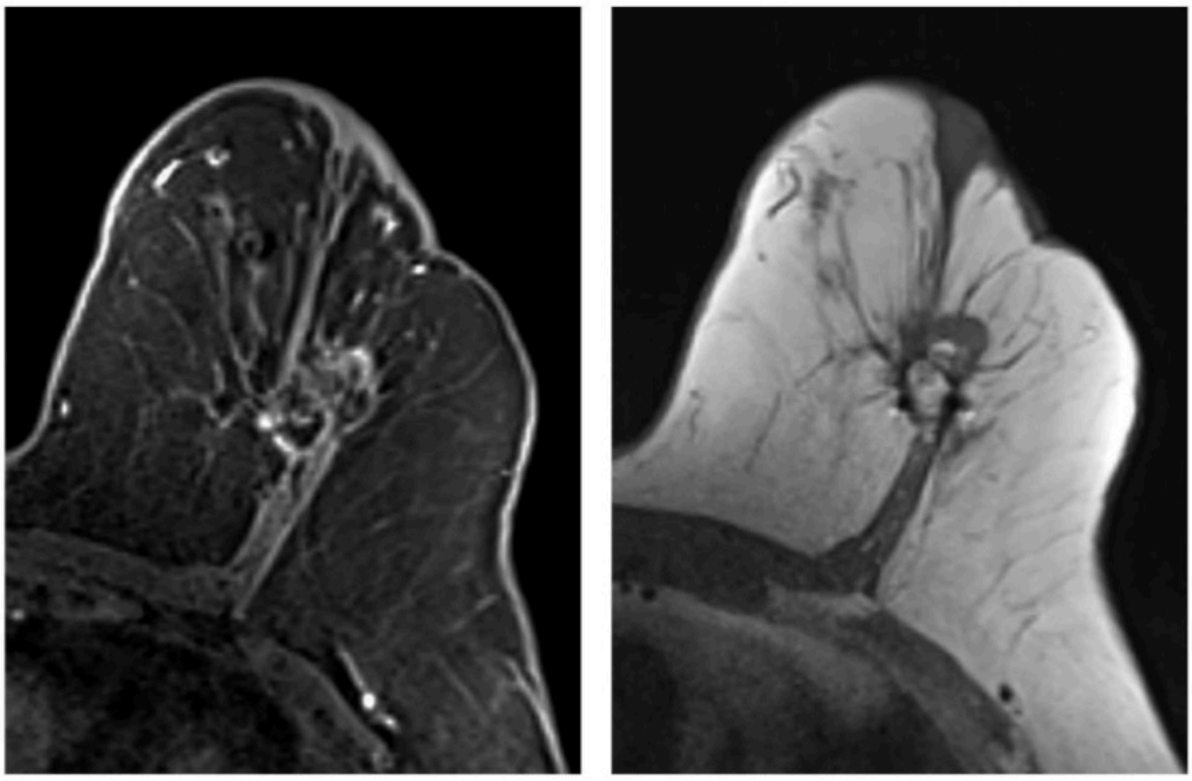

A B

Figure 3 – FAT NECROSIS. Peripheral enhancement with internal fat intensity at site of prior surgery. There is associated skin retraction. (A) Fat-suppressed early post-contrast T1W image. (B) Non-fat-suppressed non-contrast T1W image.

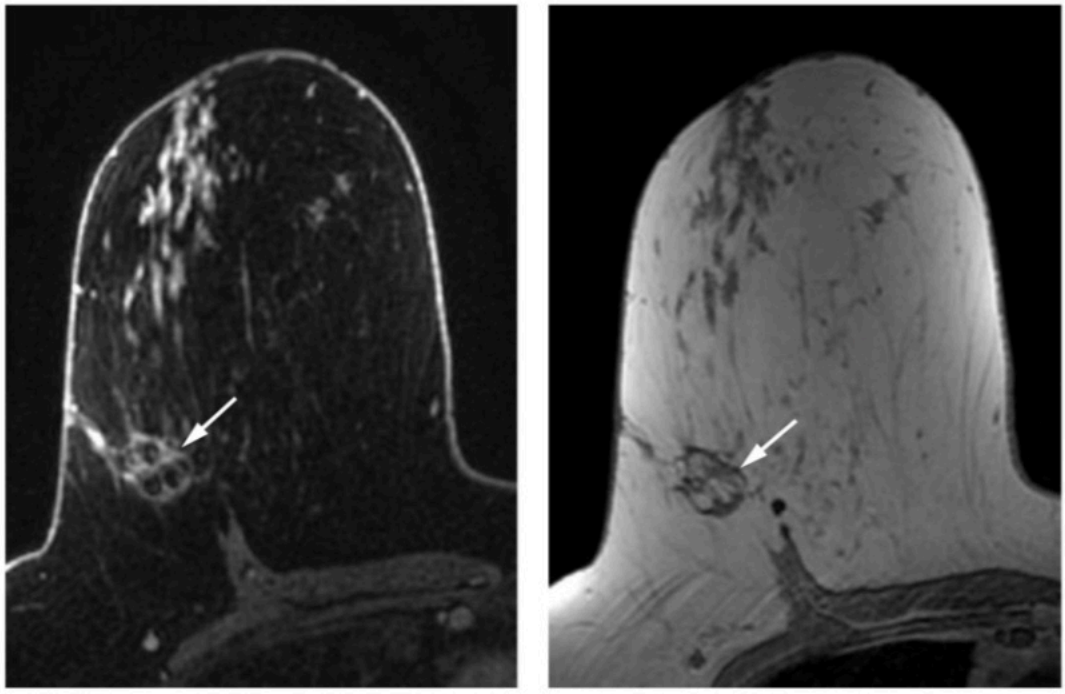

A B

Figure 4 – FAT NECROSIS. Peripheral enhancement with internal fat intensity (arrows). (A) Fat-suppressed early post-contrast T1W image. (B) Non-fat-suppressed non-contrast T1W image.

H. OTHER FINDINGS — TYPICALLY BENIGN

8. HAMARTOMA

A focal area of fat and FGT is contained within a pseudocapsule. The FGT within a hamartoma may have enhancement that is different (including more pronounced) from the other breast FGT. This enhancement pattern within the hamartoma is benign if there is no unique mass or non-mass enhancement component.

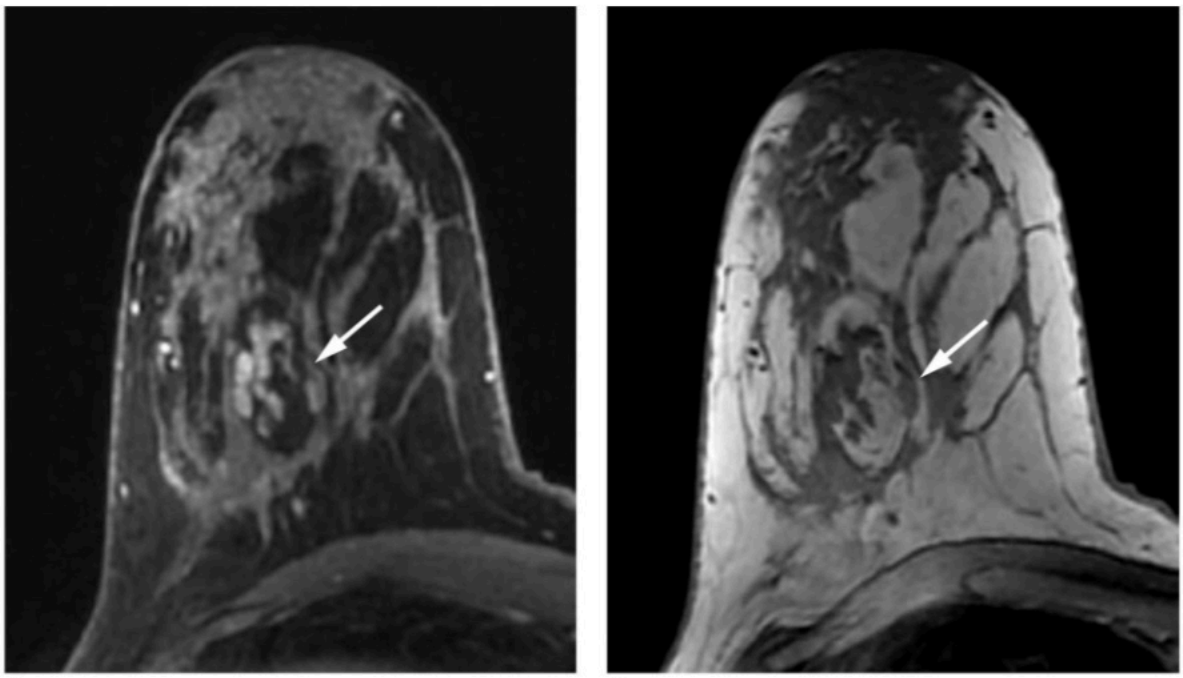

A B

Figure 1 – HAMARTOMA (arrows). (A) Fat-suppressed early post-contrast T1W image. (B) Non-fat-suppressed non-contrast T1W image.

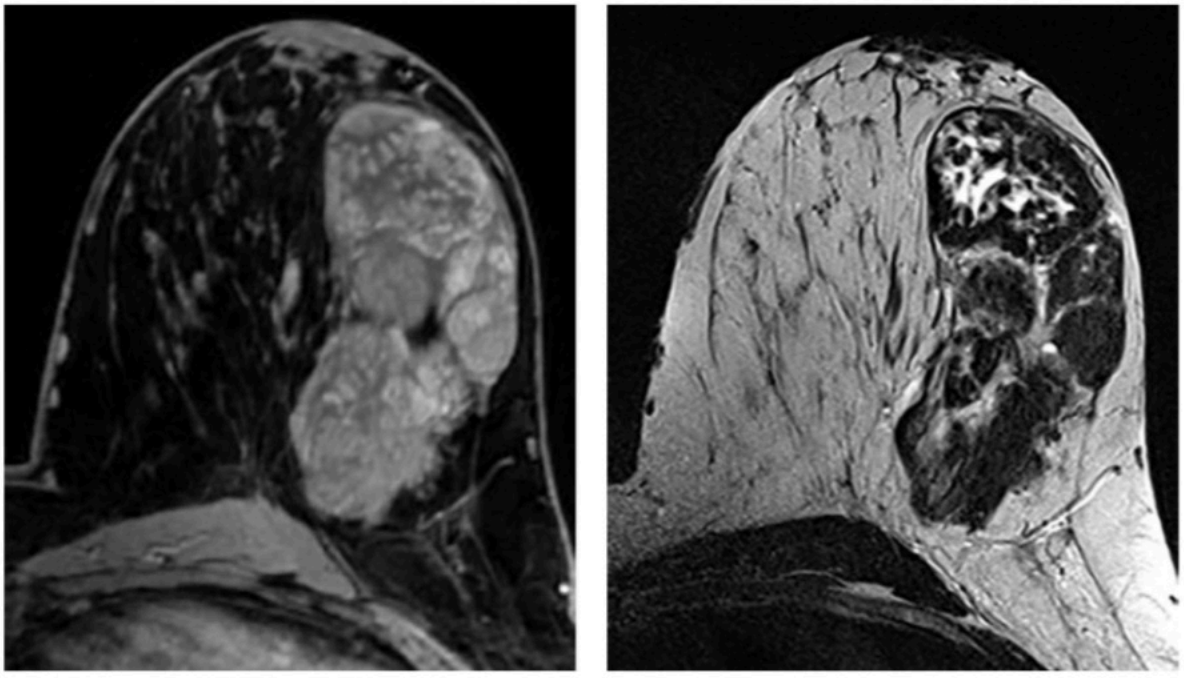

A B

Figure 2 – HAMARTOMA. (A) Fat-suppressed early post-contrast T1W image. (B) Non-fat-suppressed non-contrast T2W image.

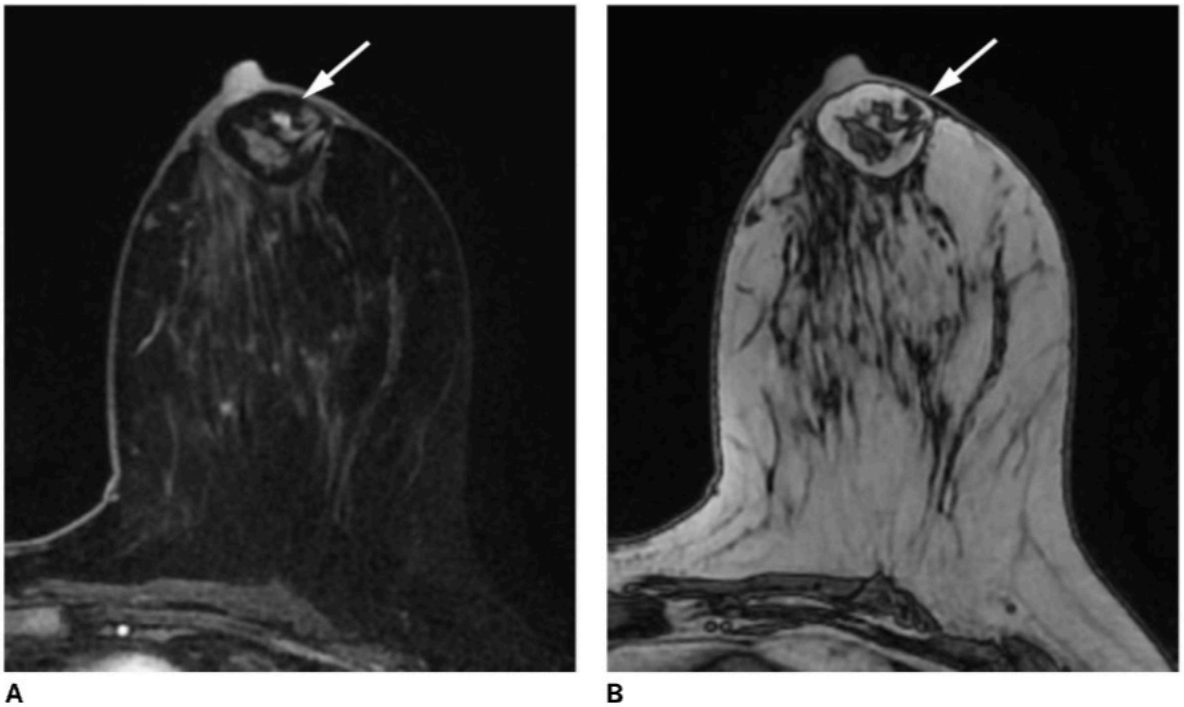

A B

Figure 3 – HAMARTOMA (arrows). (A) Fat-suppressed early post-contrast T1W image. (B) Non-fat-suppressed non-contrast T1W image.

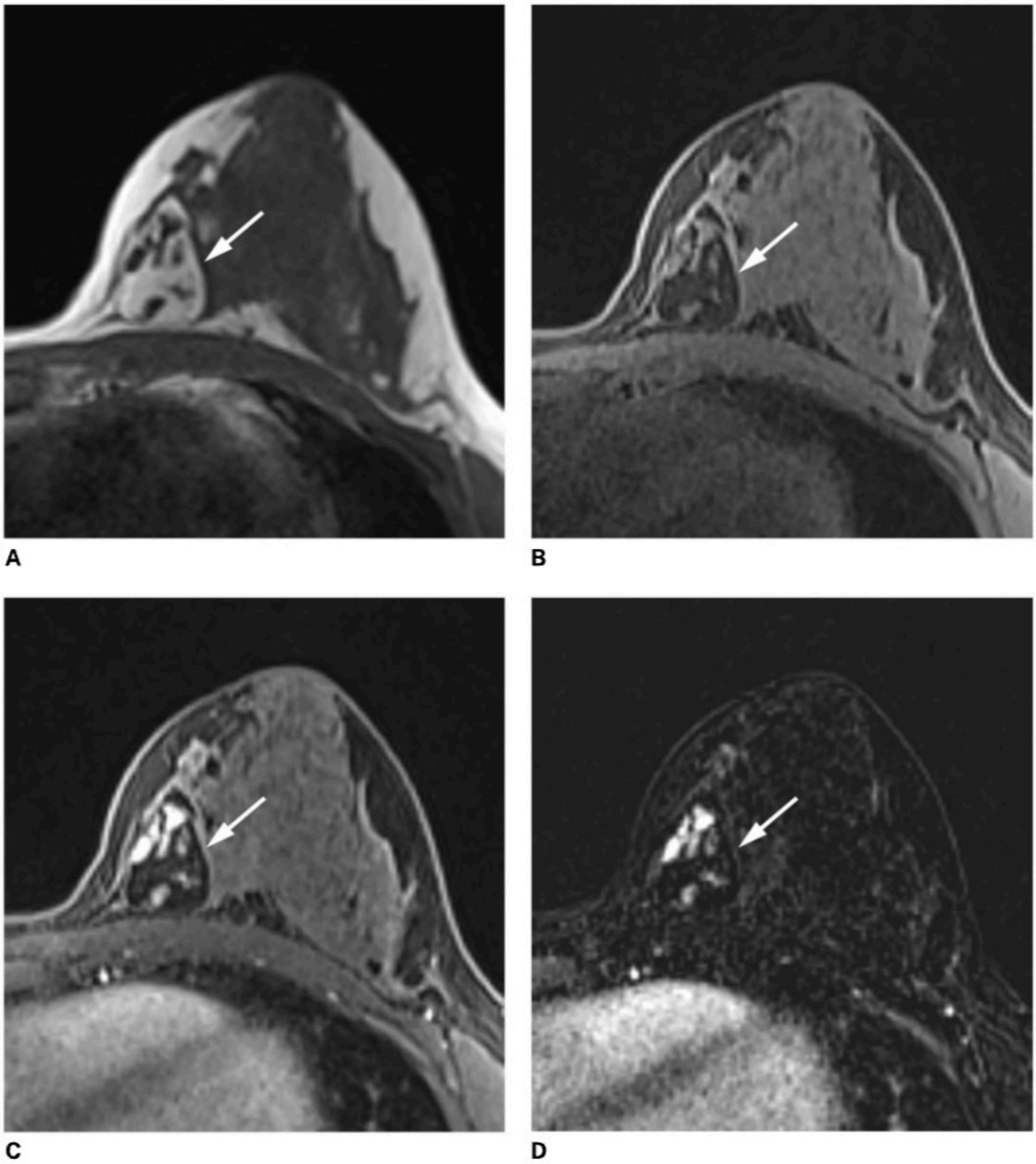

Figure 4 – HAMARTOMA (arrows). (A) Non-fat-suppressed non-contrast T1W image. (B) Fat-suppressed non-contrast T1W image. (C) Fat-suppressed early post-contrast T1W image. (D) Early post-contrast T1W subtracted image.

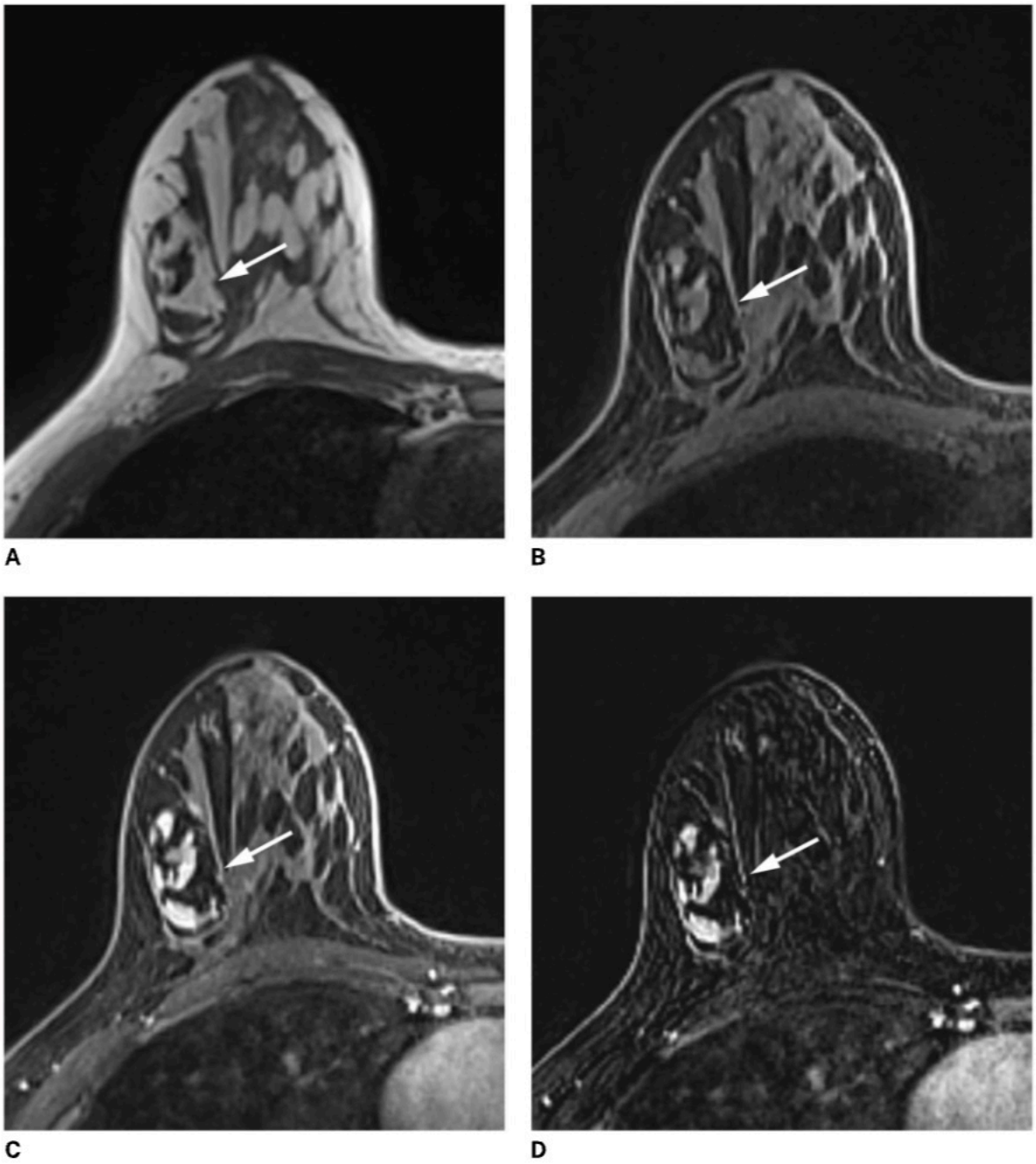

Figure 5 – HAMARTOMA (arrows). (A) Non-fat-suppressed non-contrast T1W image. (B) Fat-suppressed non-contrast T1W image. (C) Fat-suppressed early post-contrast T1W image. (D) Early post-contrast T1W subtracted image.

H. OTHER FINDINGS — TYPICALLY BENIGN

9. ENHANCING SKIN LESIONS

These are enhancing lesions of the skin unrelated to a current or suspected breast cancer. Moles, keloids, skin-related cysts (epidermal inclusion or sebaceous) and areas of focal inflammation may normally enhance. Enhancing skin lesions are common, and in general need not be reported unless there are suspicious MRI morphology features such as a spiculated margin or if there are known suspicious clinical features. When reported due to suspicious clinical features, a recommendation would typically be for clinical assessment and correlation.

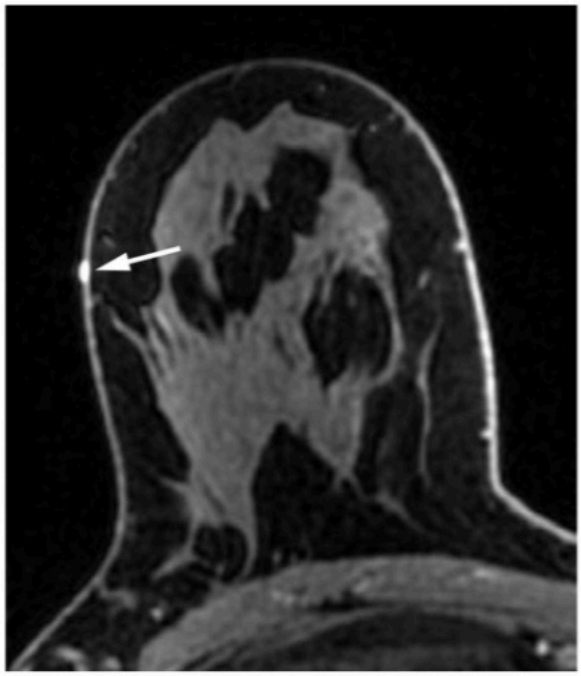

Figure 1 – ENHANCING SKIN LESION (arrow).
Fat-suppressed early post-contrast T1W image.
Etiology: Skin mole.

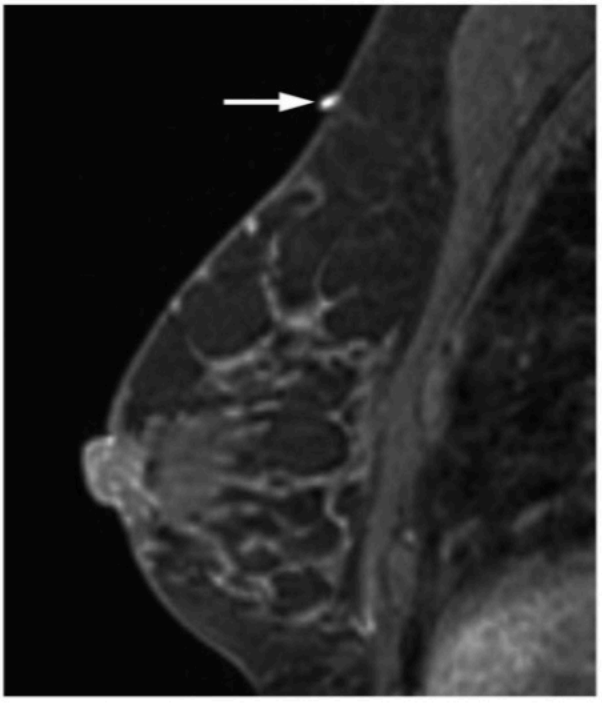

Figure 2 – ENHANCING SKIN LESION (arrow). Fat-suppressed early post-contrast T1W image. Etiology: Skin tag.

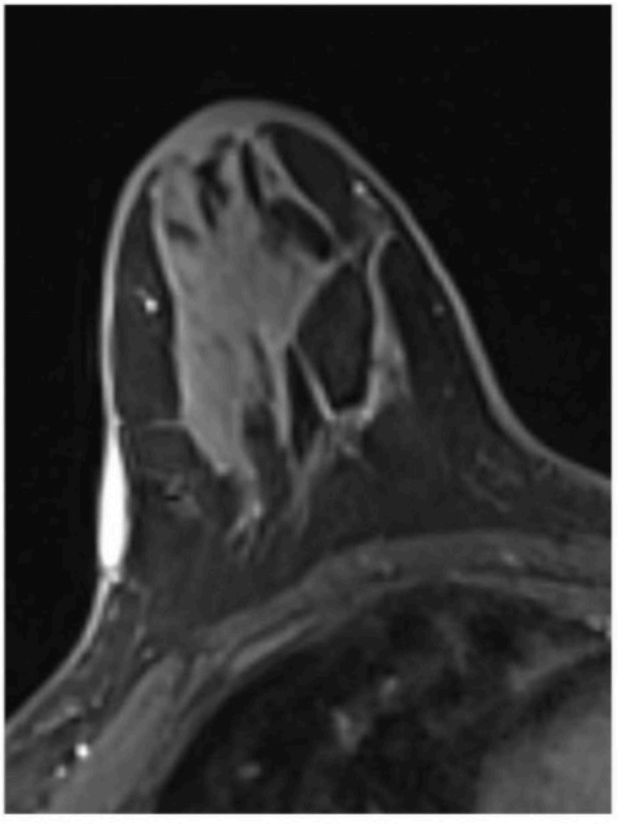

Figure 3 – ENHANCING SKIN LESION. Fat-suppressed early post-contrast T1W image. Etiology: Keloid.

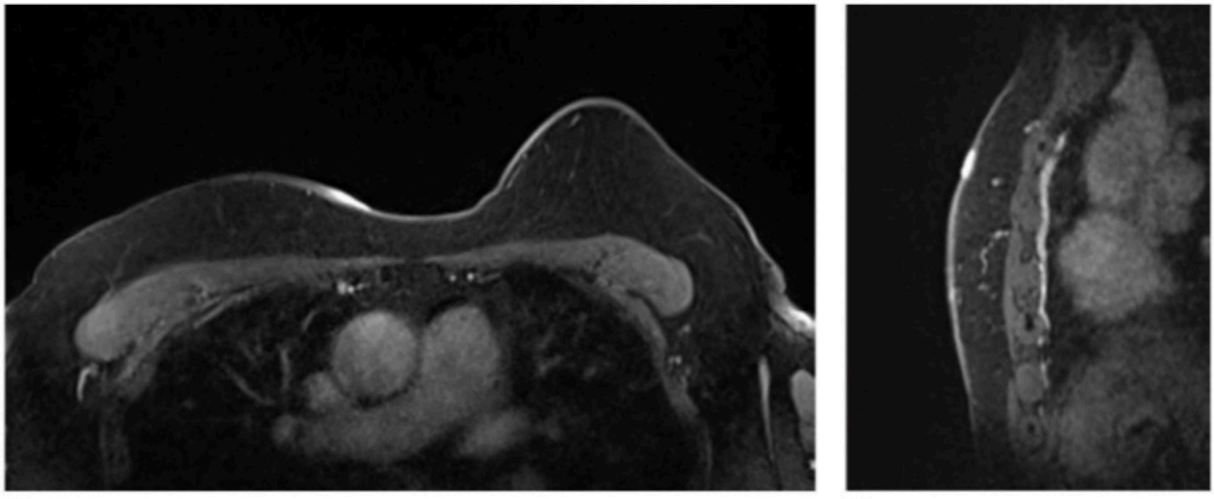

A B

Figure 4 – ENHANCING SKIN LESION. Fat-suppressed early post-contrast T1W (A) axial and (B) sagittal images.

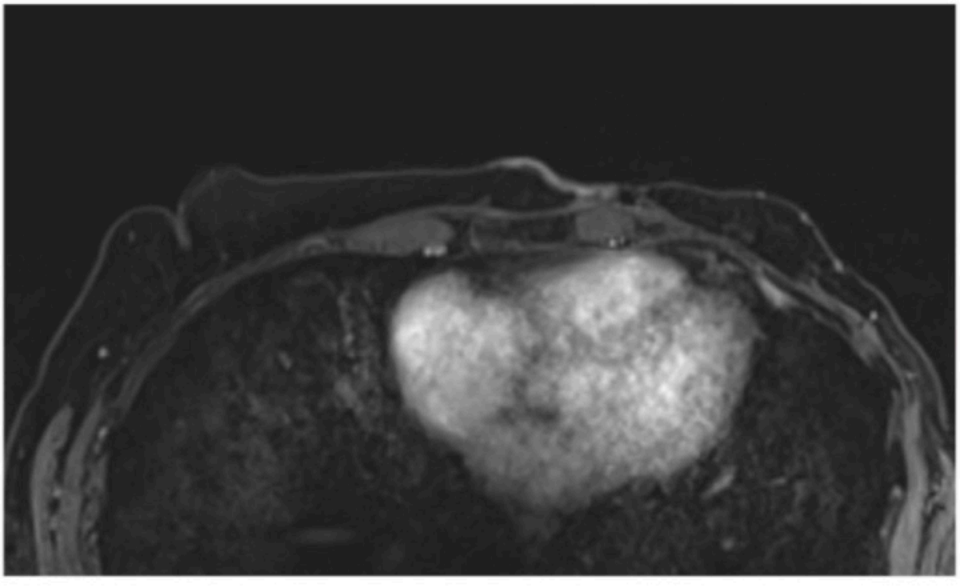

Figure 5 – ENHANCING SKIN LESION. Fat-suppressed early post-contrast T1W image. Pathology: Recurrent ILC.

I. LOCATION OF FINDING

The location of breast MRI findings should be described in the following order:

Laterality

Location in breast as clock face (preferred) in whole number, or quadrant or other anatomic location

Depth in breast as anterior, middle or posterior third

Distance from the nipple in whole centimeters

Example: right breast, 10:00, anterior depth, 3 cm from nipple

1. LATERALITY

   Describe right, left or bilateral

2. LOCATION IN BREAST

   CLOCK FACE (Preferred) or Quadrant or Other Anatomic Location

   Describe the specific location of the finding

   Clock face is preferred as it is the most specific. Clock face should be described in whole hour numbers (e.g., 2 o'clock not 2:30 o'clock). Using smaller "half hour" increments implies a higher level of location precision than is possible across readers and modalities. If findings are between whole hour numbers locations, the closest whole number location should be used. Clock face is oriented based on the patient facing the observer. For example, 3:00 is in the lateral left breast and the medial right breast.

   Quadrant can be used instead of clock face when most appropriate, such as for larger findings spanning multiple clock face locations.

   Other anatomic locations should be used when they are most appropriate. These are retroareolar (behind the nipple at anterior depth), central (behind the nipple at middle or posterior depth), axillary tail (breast upper outer quadrant adjacent to the axilla), and axilla.

   It may be helpful to describe the tissue zone (premammary, mammary, post-mammary) where the finding lies to facilitate lesion identification when correlating among modalities. For example, noting that a mass lies at the subcutaneous pre-mammary zone or at the junction with the mammary tissue zone may allow for more efficient search and more confident identification when ultrasound evaluation is undertaken.

3. DEPTH

   Describe the depth in the breast using anterior, middle, posterior third.

4. DISTANCE FROM THE NIPPLE

   Describe the distance from the nipple in whole centimeters (e.g., 2 cm from the nipple, not 2.3 cm from the nipple). Using smaller subcentimeter distance increments implies a higher level of precision than is possible across readers and modalities. If findings are between whole cm locations, the closest whole cm location should be used. Measure the distance from the nipple from the base of the nipple to the center of the finding, on the same 2-dimensional (2D) image if both are visible or using a maximum intensity projection if both are not visible on the same 2D image. If the finding is close to the nipple, it is important to also describe the distance from its anterior extent to the nipple, to assist with surgical planning. If the finding is large, distance to its anterior and posterior extents can also be included. If the findings are close to the skin, pectoralis muscle or chest wall, describe the distance of the findings to these structures. Due to differences in patient positioning and other technique factors, distance from the nipple, skin, pectoralis muscle and chest wall may vary across modalities.

J. IMPLANTS AND OTHER TYPES OF AUGMENTATION

Breast MRI for implant assessment is typically performed in patients with silicone implants who have signs or symptoms, to evaluate for rupture or other complication. In the U.S. the FDA also recommends that asymptomatic patients with silicone implants undergo imaging to detect "silent rupture," using ultrasound or MRI, 5–6 years after placement, then every 2–3 years [13]. The ACR Appropriateness Criteria now has similar recommendations for imaging asymptomatic patients with silicone implants for "silent rupture". However, a study of U.S. plastic surgeons in 2020 found that most did not recommend imaging in this scenario [14].

Breast MRI performed only for assessment of implants does not require contrast. If only a non-contrast examination intentionally is performed, no BI-RADS assessment is given. This is because BI-RADS assessments reflect probabilities of breast cancer, and at this time detection of breast cancer requires contrast.

The MRI technique for silicone implants should include both T2-weighted images to assess for peri-implant fluid and silicone-specific sequences to assess for implant integrity. Silicone-specific sequences suppress both water and fat (both appear dark) so that only silicone appears hyper-intense, allowing evaluation of the silicone implant without bright signal from water or fat.

1. LOCATION

   Implants are usually placed either anterior to the pectoralis major muscle behind the breast glandular tissue (prepectoral), or posterior to the pectoralis major muscle (retropectoral).

   a. Prepectoral

      The implant is located anterior to the pectoralis major muscle.

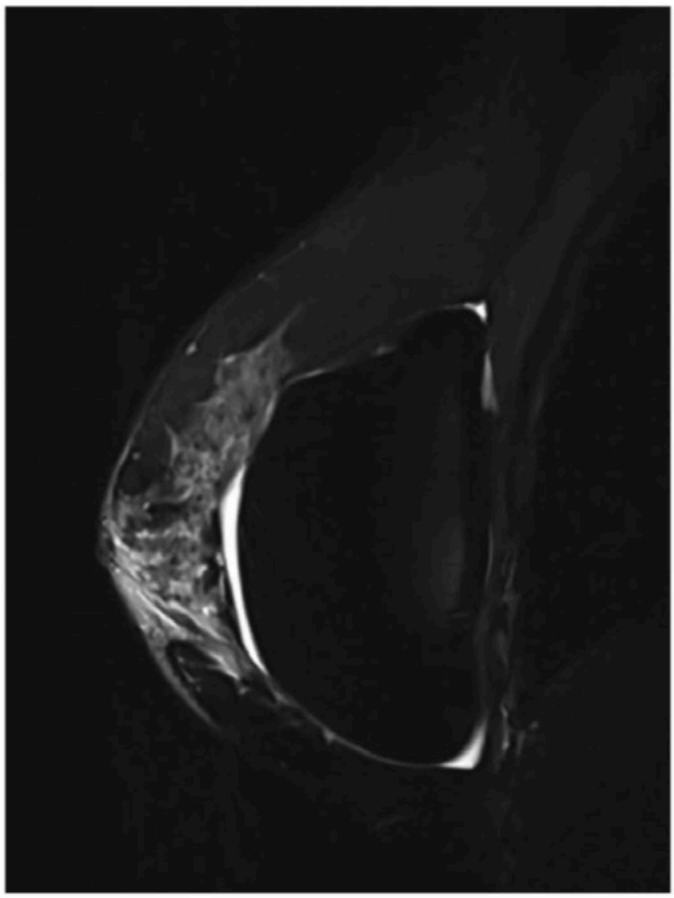

Figure 1 – IMPLANT LOCATION: PREPECTORAL. Intact, single lumen silicone implant with incidental trace peri-implant fluid. Fat- and silicone-suppressed T2W image.

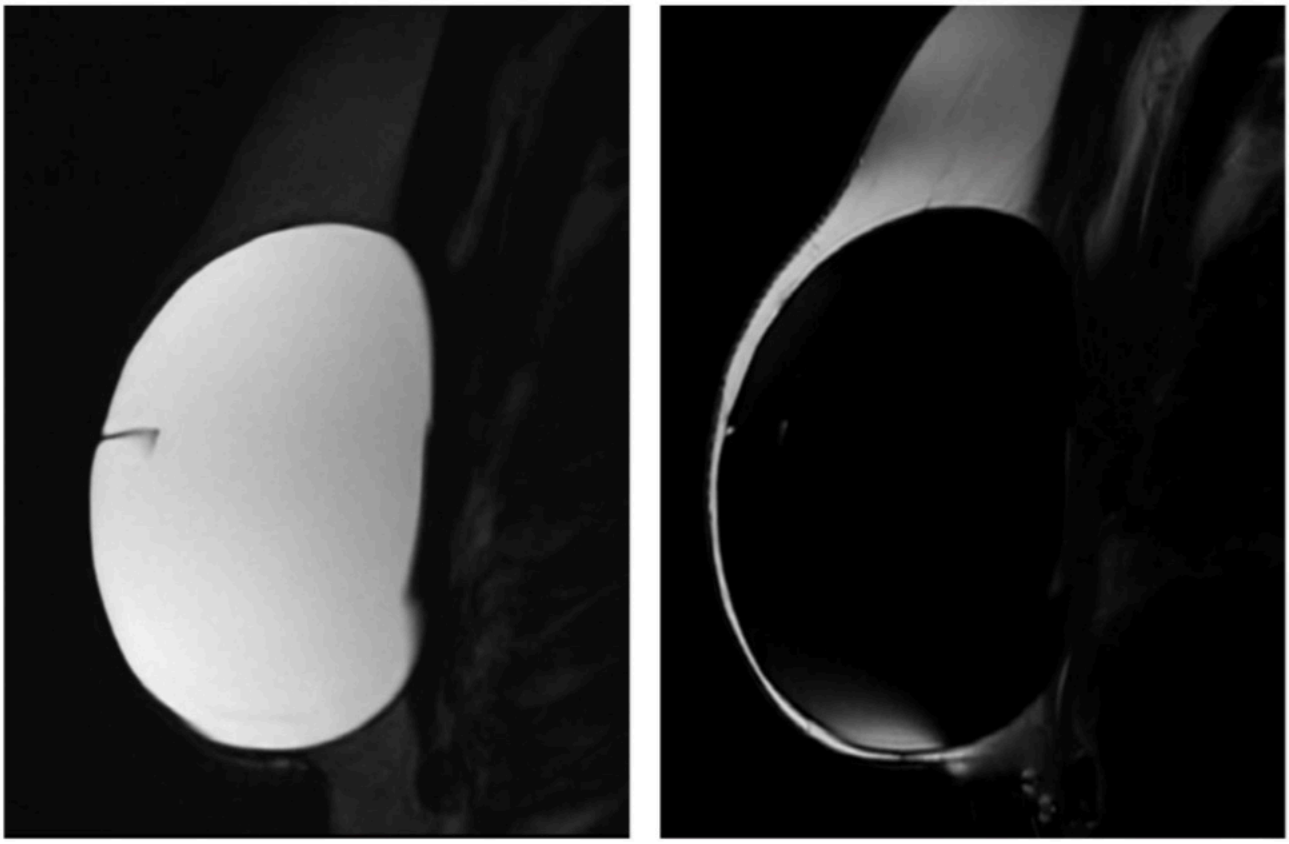

A B

Figure 2 – IMPLANT LOCATION: PREPECTORAL. Intact, single lumen silicone implant with incidental radial fold. (A) Fat- and water-suppressed silicone-specific image. (B) Non-fat-suppressed silicone-suppressed T2W image.



Figure 3 – IMPLANT LOCATION: PREPECTORAL. Intact, single lumen saline implant. The presence of a filling valve (arrow) is characteristic of saline implants. Fat-suppressed T2W image.

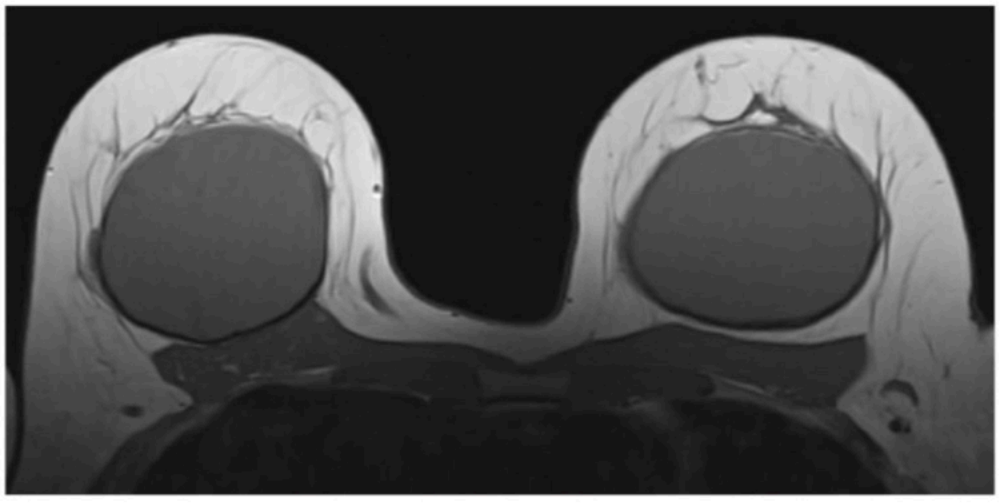

Figure 4 – IMPLANT LOCATION: PREPECTORAL. Intact, single lumen silicone implants. Non-fat-suppressed non-contrast T1W image.

J. IMPLANTS AND OTHER TYPES OF AUGMENTATION

1. LOCATION

b. Retropectoral

The implant is located deep to portions of the pectoralis major muscle.

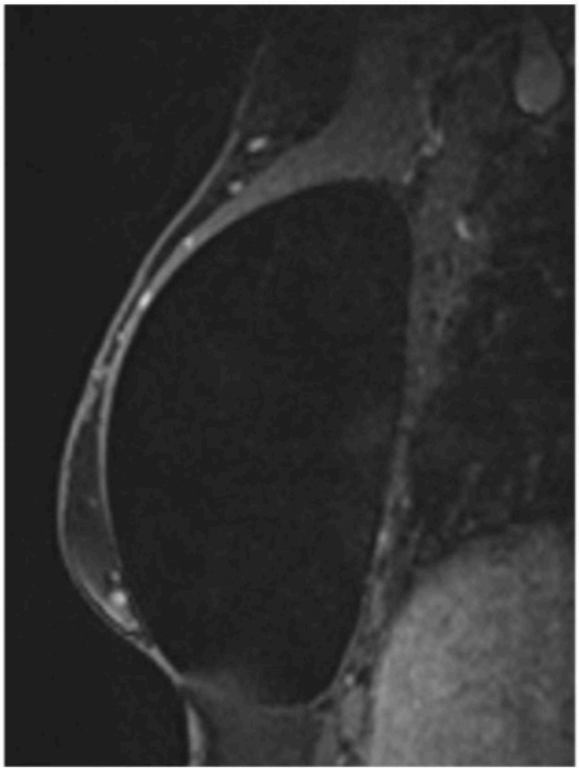

Figure 1 – IMPLANT LOCATION: RETROPECTORAL. Intact, single lumen silicone implant. Fat-suppressed early post-contrast T1W image.

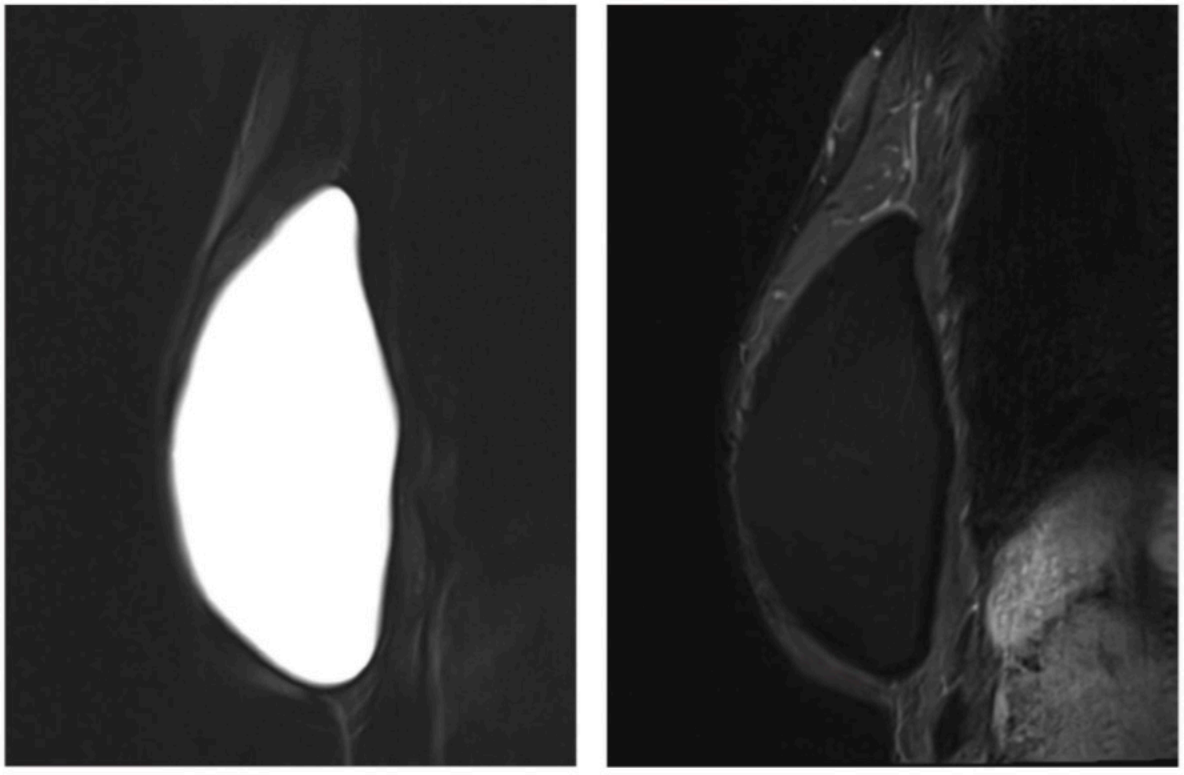

A B

Figure 2 – IMPLANT LOCATION: RETROPECTORAL. Intact, single lumen silicone implant.
(A) Fat- and water-suppressed silicone-specific image. (B) Fat- and silicone-suppressed T2W image.

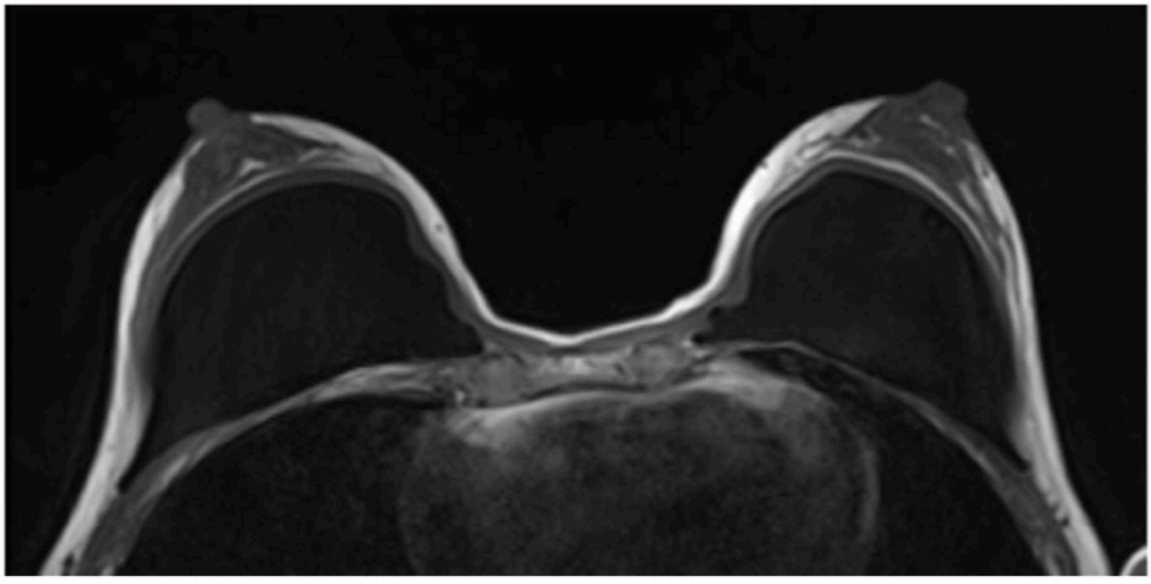

Figure 3 – IMPLANT LOCATION: RETROPECTORAL. Intact, single lumen saline implants.
Non-fat-suppressed T1W image.

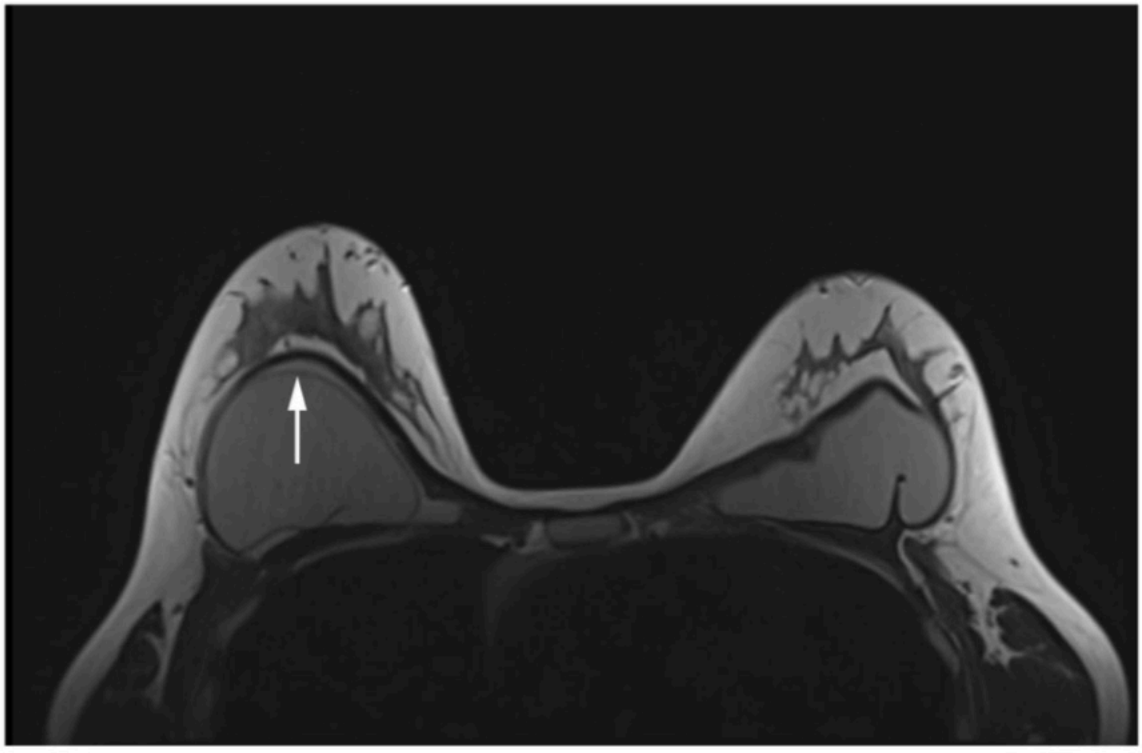

Figure 4 – IMPLANT LOCATION: RETROPECTORAL. Single lumen silicone implants; intracapsular rupture on the right with subcapsular line sign (arrow), intact on the left. Non-fat-suppressed T2W image.

J. IMPLANTS AND OTHER TYPES OF AUGMENTATION

2. IMPLANT MATERIAL AND INTEGRITY

A breast implant is comprised of a silicone elastomer shell which contains the implant material. The body forms a fibrous capsule around breast implants. Typically, the fibrous capsule is not seen on breast MRI around an intact implant. Breast implant materials are usually silicone or saline, although other implant materials exist.

a. Saline

Saline implants follow water signal on all MRI sequences. The presence of a filling valve is also characteristic of saline implants.

i. Intact

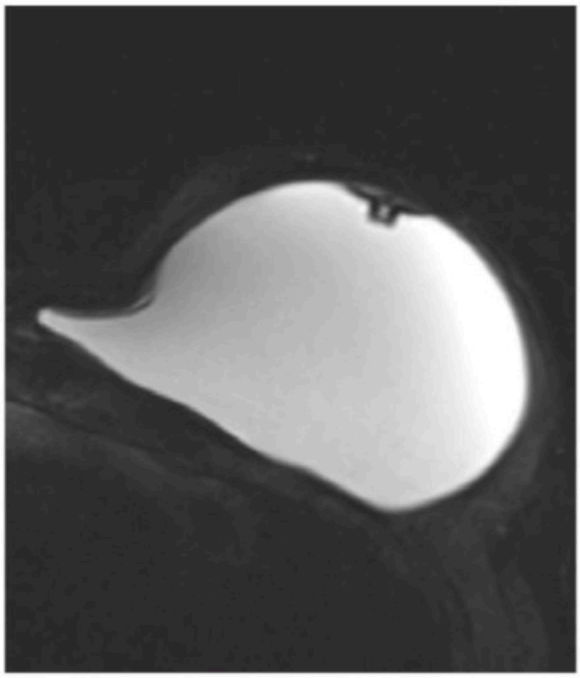

Figure 1 – IMPLANT MATERIAL: SALINE, INTACT. Intact, retropectoral, single lumen saline implant. Fat-suppressed T2W image.

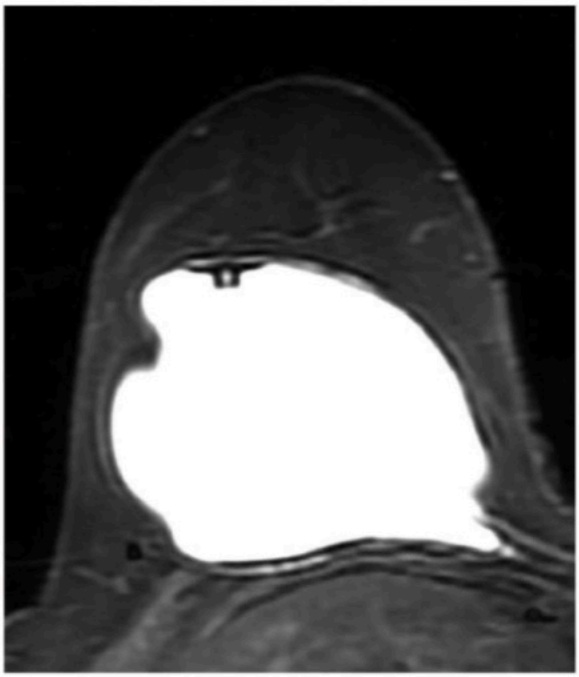

Figure 2 – IMPLANT MATERIAL: SALINE, INTACT. Intact, retropectoral, single lumen saline implant. Fat-suppressed T2W image.

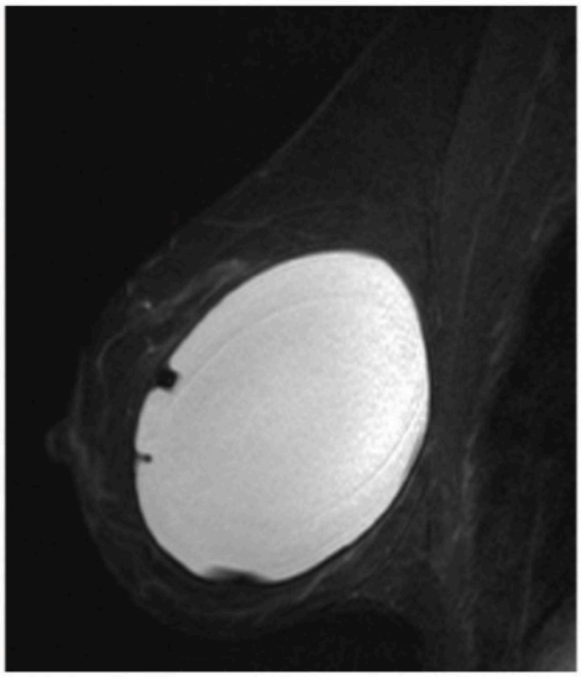

Figure 3 – IMPLANT MATERIAL: SALINE, INTACT. Intact, prerepectoral, single lumen saline implant. Fat-suppressed T2W image.

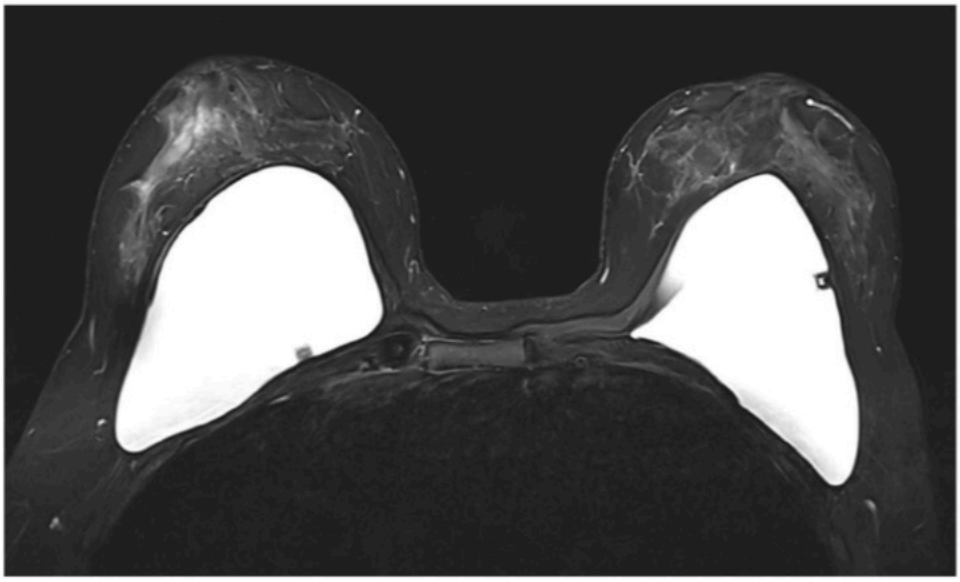

Figure 4 – IMPLANT MATERIAL: SALINE, INTACT. Intact, retropectoral, single lumen saline implants. Fat-suppressed T2W image.

J. IMPLANTS AND OTHER TYPES OF AUGMENTATION

2. IMPLANT MATERIAL AND INTEGRITY

a. Saline

ii. Ruptured

When a saline implant ruptures, it is clinically evident because the breast becomes smaller as the saline is absorbed by the body. Therefore, breast MRI for saline implant rupture is not typically needed or performed.

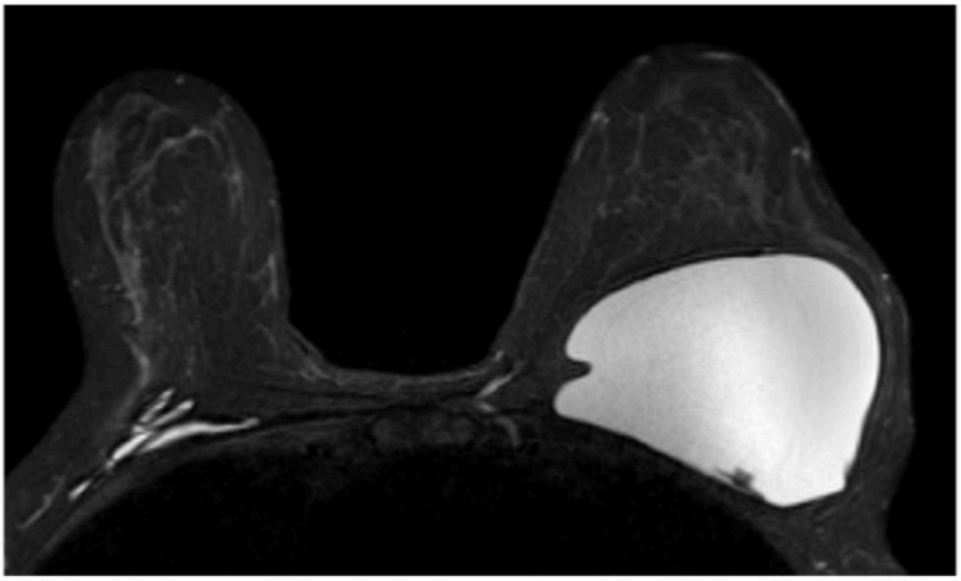

Figure 1 – IMPLANT MATERIAL: SALINE, RUPTURED (RIGHT) AND INTACT (LEFT). Retropectoral, single lumen, saline implants, ruptured on the right, intact on the left. A small amount of residual saline is seen in the collapsed right implant. Fat-suppressed T2W image.

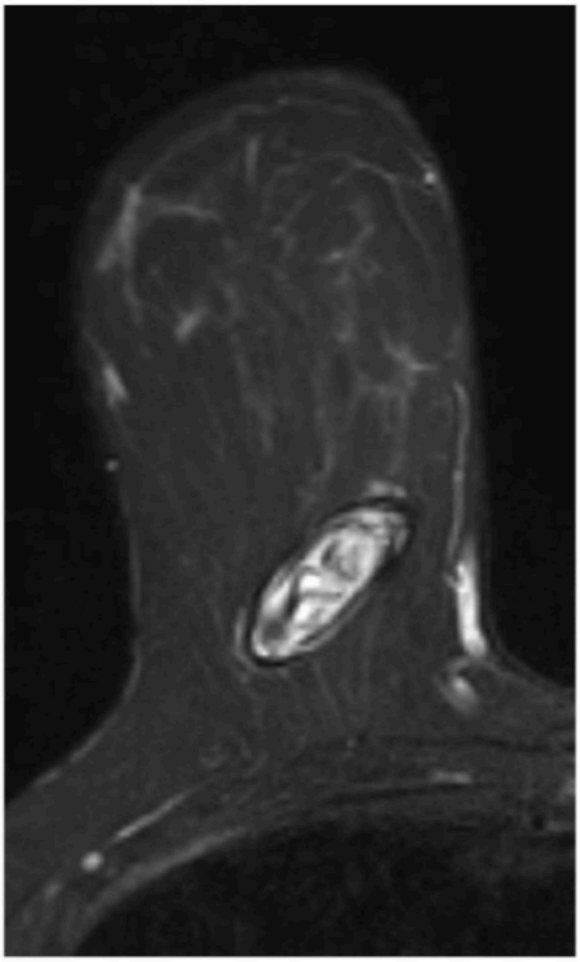

Figure 2 – IMPLANT MATERIAL: SALINE, RUPTURED. Ruptured prepectoral, single lumen saline implant. Fat-suppressed T2W image.

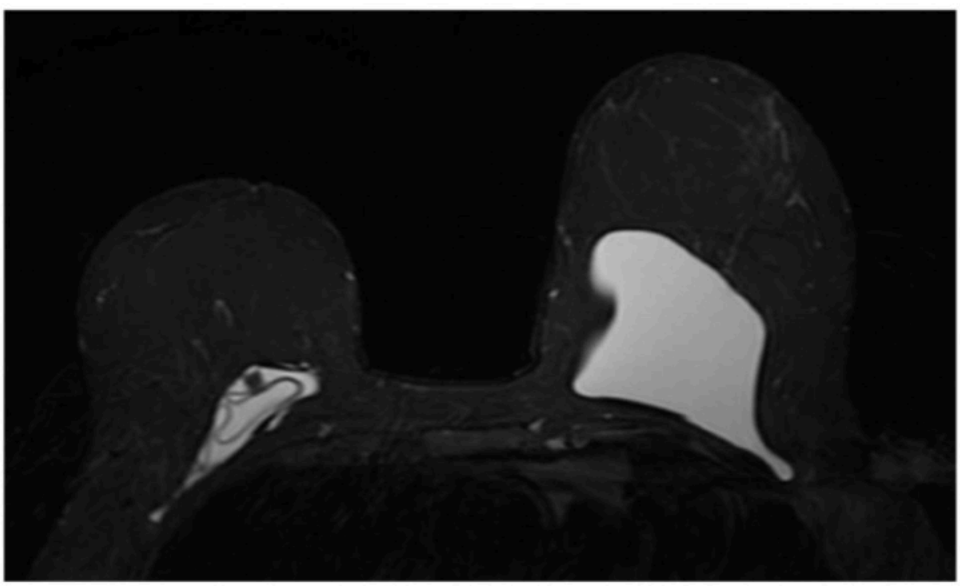

Figure 3 – IMPLANT MATERIAL: SALINE, RUPTURED (RIGHT) AND INTACT (LEFT). Prepectoral, single lumen, saline implants, ruptured on the right, intact on the left. Fat-suppressed T2W image.

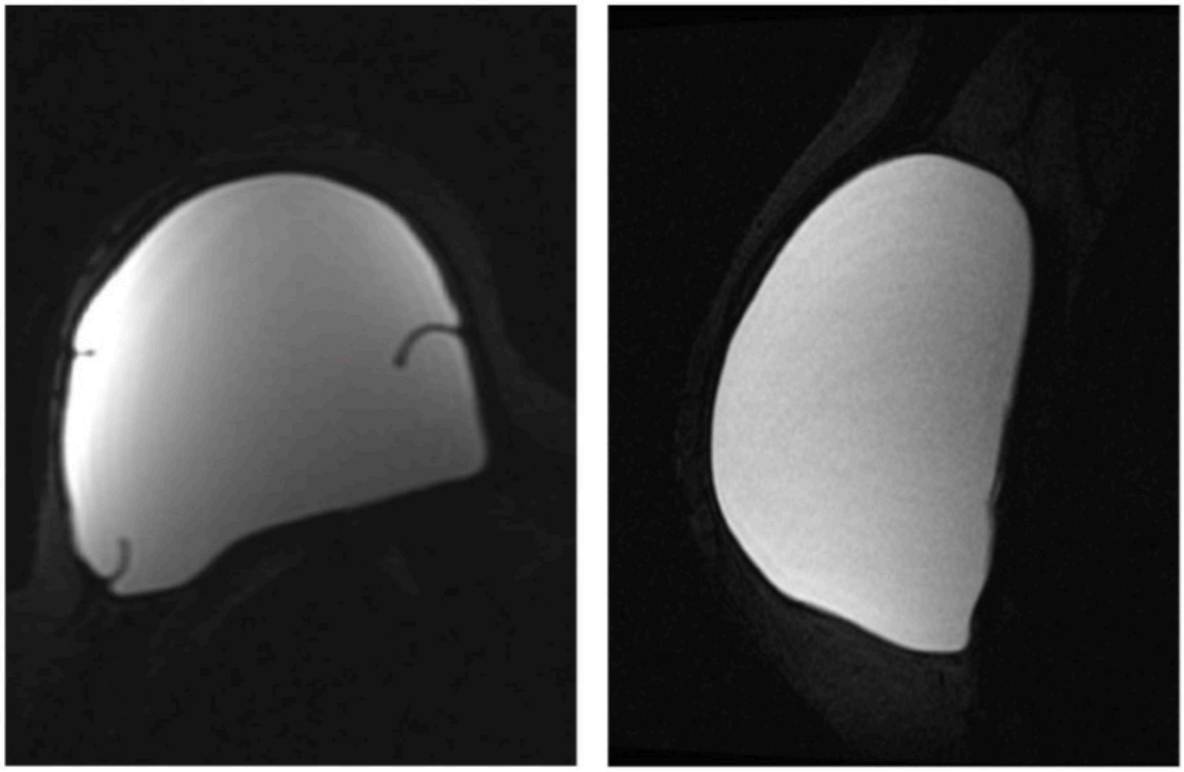

A B

Figure 3 – IMPLANT MATERIAL: SILICONE, INTACT. Intact, retropectoral, single lumen silicone implant. Normal radial folds are present. (A) Axial and (B) sagittal fat- and water-suppressed silicone-specific images.

J. IMPLANTS AND OTHER TYPES OF AUGMENTATION

2. IMPLANT MATERIAL AND INTEGRITY

b. Silicone

ii. Ruptured

When a silicone implant ruptures, the silicone may remain contained within the fibrous capsule (intracapsular rupture) or may extrude outside of the fibrous capsule into the breast tissue (extracapsular rupture). For in-depth discussion about and image examples of silicone implant rupture, please refer to "Intracapsular silicone findings" and "Extracapsular silicone findings" below.

2. IMPLANT MATERIAL AND INTEGRITY

c. Other Implant/Augmentation Materials

Other methods of augmentation include implantation of autologous (such as TRAM, DIEP and other tissue flaps) tissue and non-autologous tissue and direct injection of materials such as silicone, paraffin, soy oil, polypropylene and polyurethane.

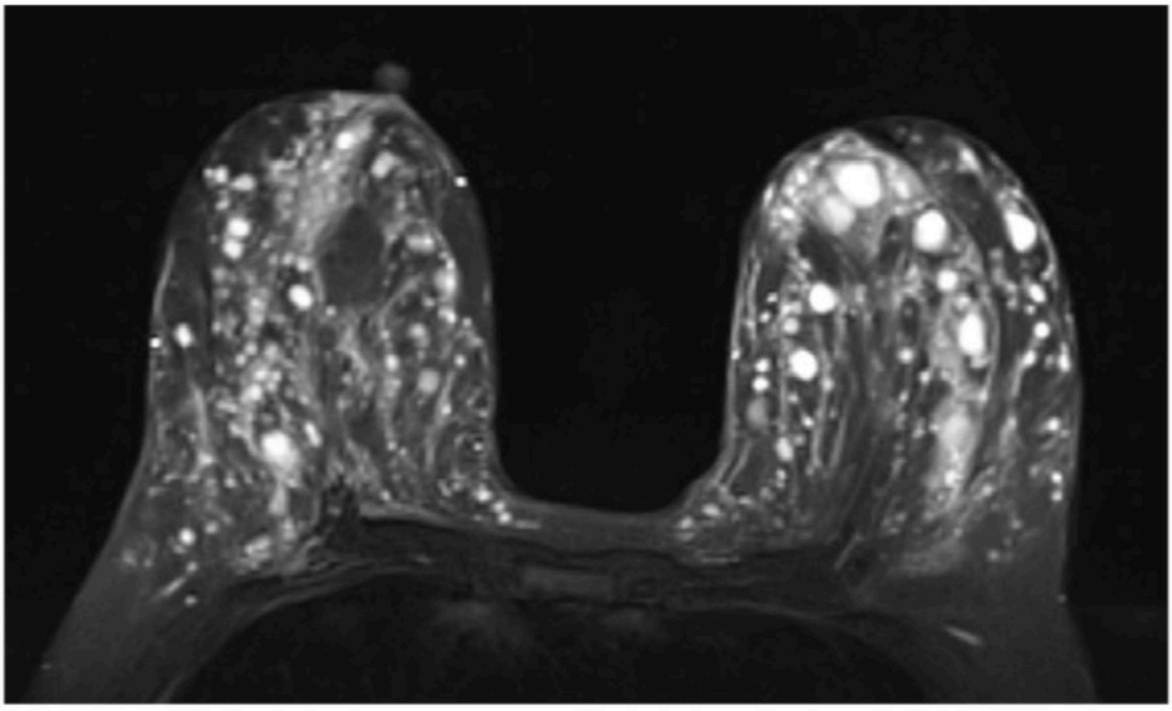

A

Figure 1 – OTHER IMPLANT/AUGMENTATION MATERIALS: DIRECT SILICONE INJECTION. (A) Fat-suppressed STIR (silicone and water hyperintense) image.

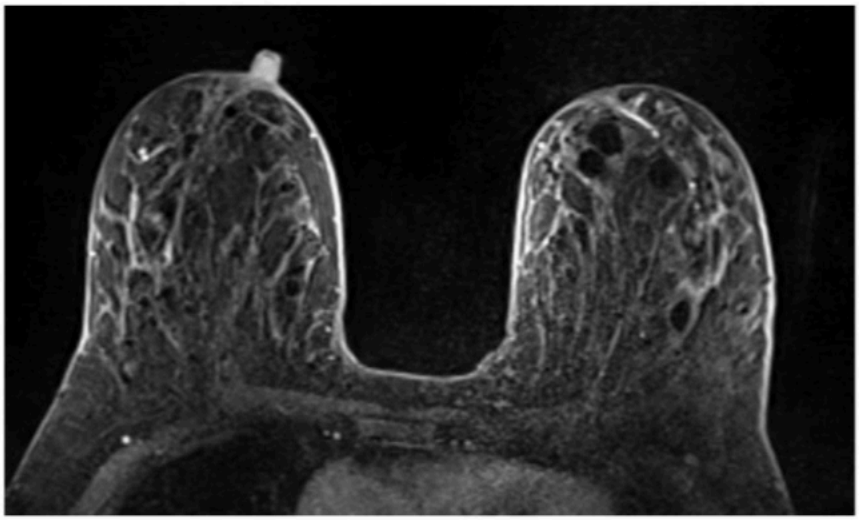

B

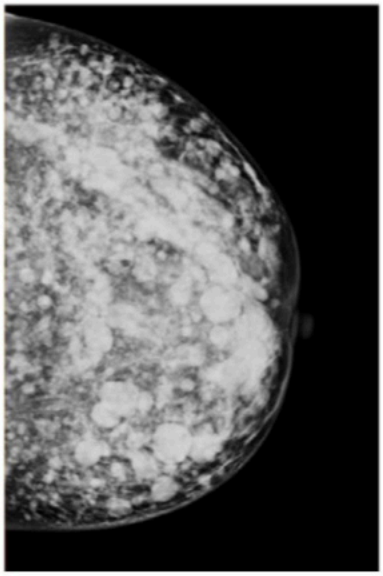

C

Figure 1 – *(Continued)* OTHER IMPLANT/AUGMENTATION MATERIALS: DIRECT SILICONE INJECTION. (B) Fat-suppressed early post-contrast T1W image. (C) Left CC digital mammogram.

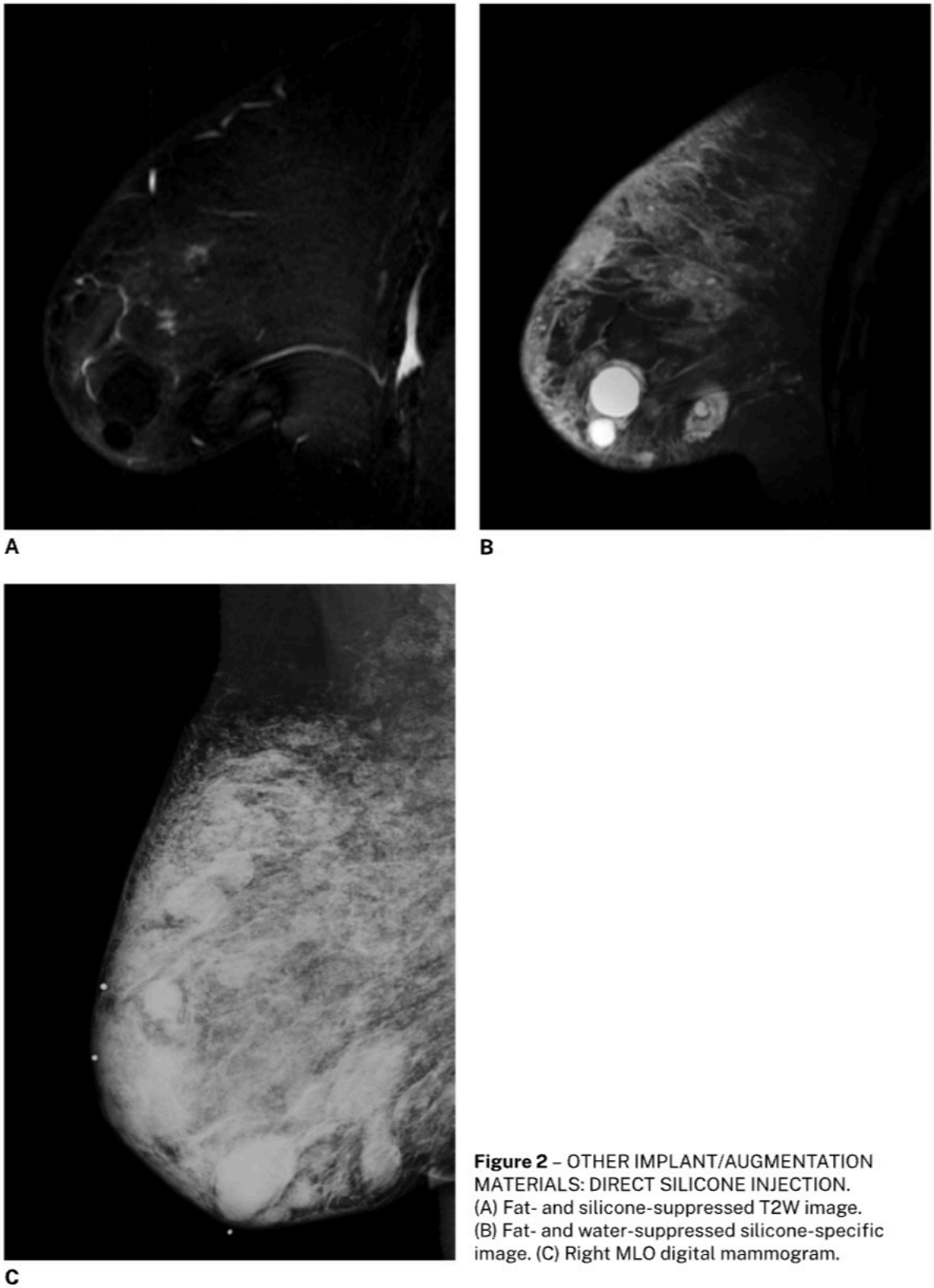

Figure 2 – OTHER IMPLANT/AUGMENTATION MATERIALS: DIRECT SILICONE INJECTION. (A) Fat- and silicone-suppressed T2W image. (B) Fat- and water-suppressed silicone-specific image. (C) Right MLO digital mammogram.

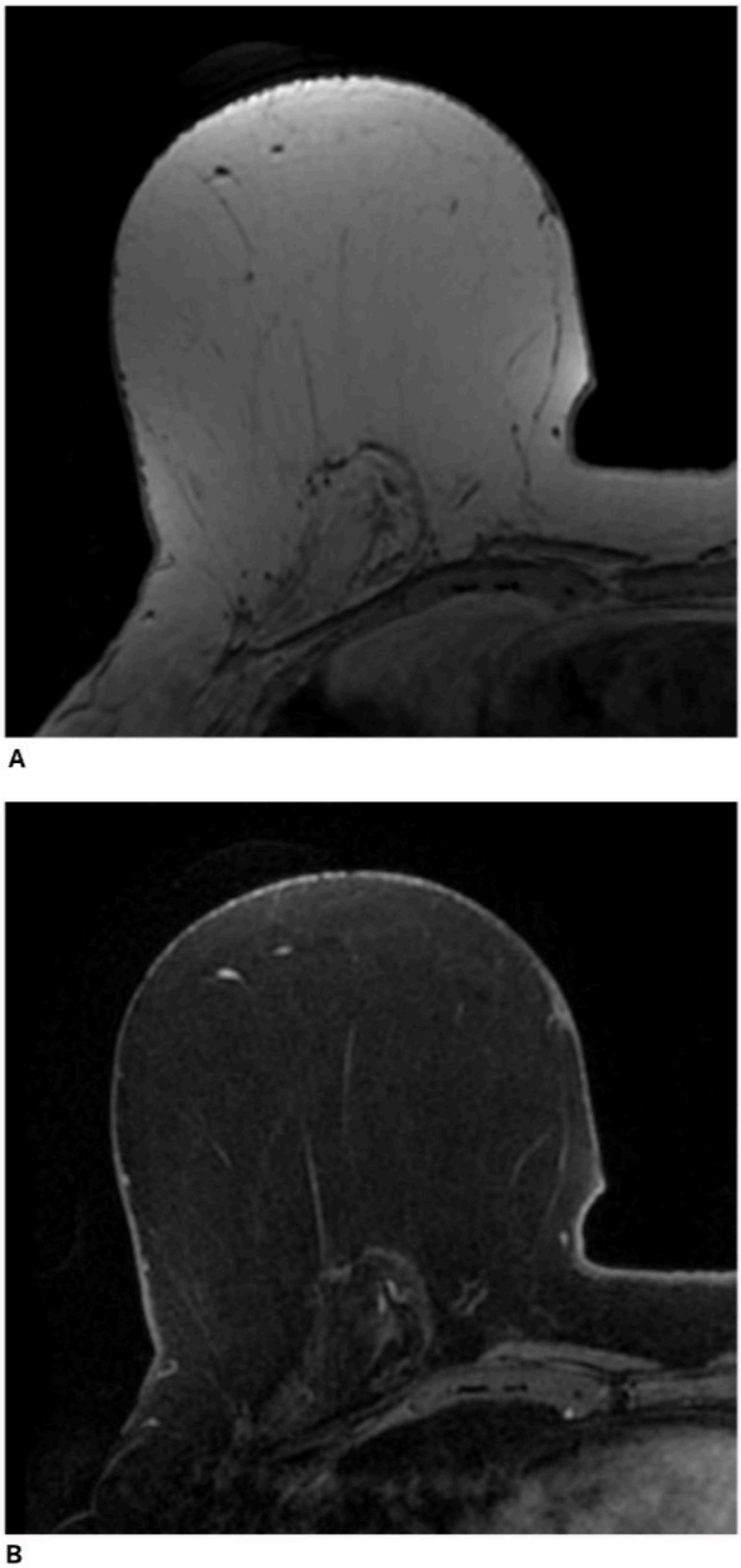

Figure 3 – OTHER IMPLANT/ AUGMENTATION MATERIALS: AUTOLOGOUS FLAP RECONSTRUCTION. Right mastectomy with transverse rectus abdominus myocutaneous (TRAM) flap reconstruction. (A) Non-fat-suppressed non-contrast T1W image. (B) Fat-suppressed early post-contrast T1W image.

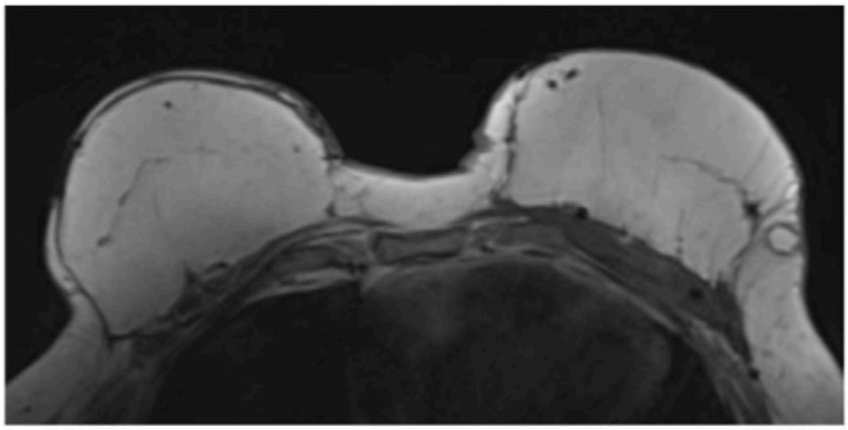

A

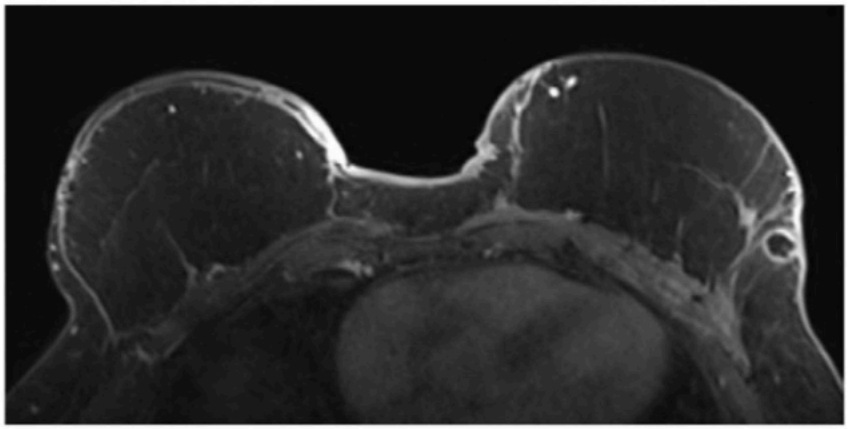

B

Figure 4 – OTHER IMPLANT/AUGMENTATION MATERIALS: AUTOLOGOUS FLAP RECONSTRUCTION. Bilateral mastectomies with autologous deep inferior epigastric perforator (DIEP) flap reconstructions, with fat injection in the lateral left reconstructed breast. (A) Non-fat-suppressed non-contrast T1W image. (B) Fat-suppressed early post-contrast T1W image.

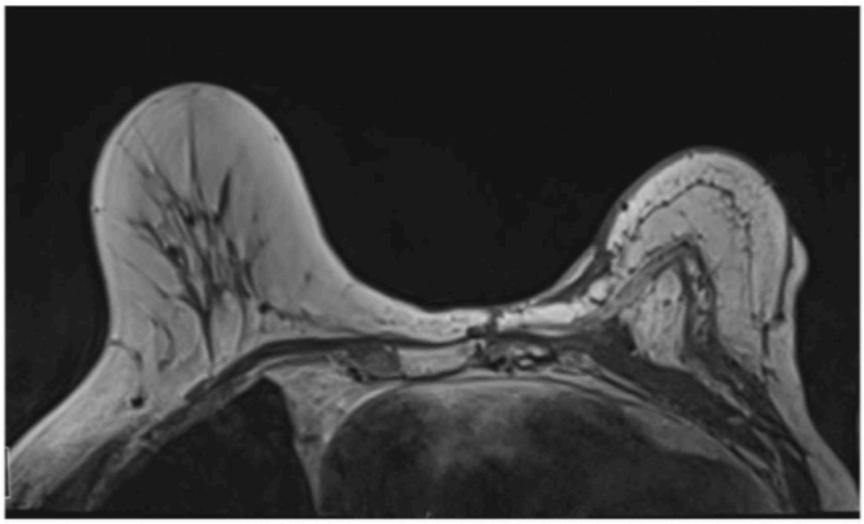

Figure 5 – OTHER IMPLANT/AUGMENTATION MATERIALS: AUTOLOGOUS FLAP RECONSTRUCTION. Left mastectomy with autologous latissimus flap reconstruction. Non-fat-suppressed non-contrast T1W image.

J. IMPLANTS AND OTHER TYPES OF AUGMENTATION

3. LUMEN TYPE

Implants most commonly have a single lumen, but they may contain multiple lumens.

a. Single

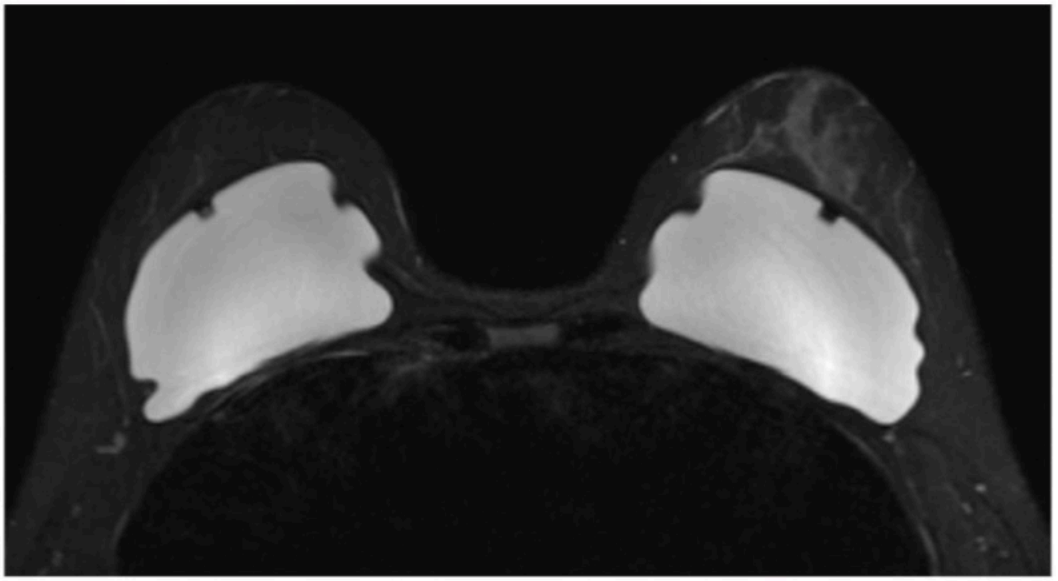

Figure 1 – LUMEN TYPE: SINGLE. Intact, retropectoral, saline implants. Fat-suppressed T2W image.

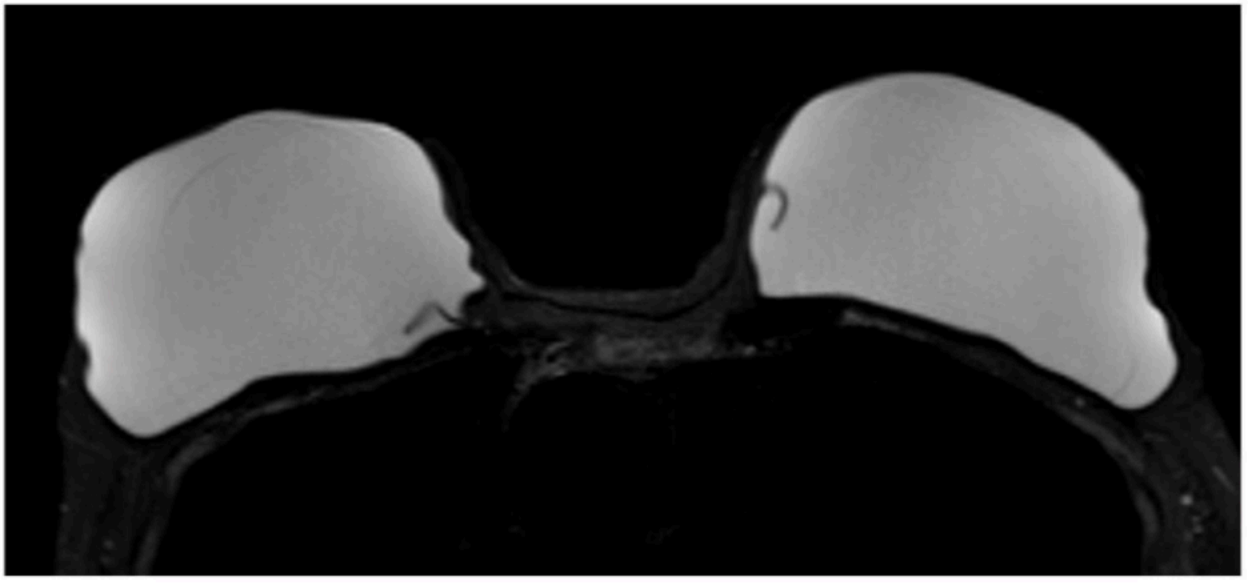

Figure 2 – LUMEN TYPE: SINGLE. Intact, retropectoral, silicone implants. Fat- and water-suppressed silicone-specific image.

J. IMPLANTS AND OTHER TYPES OF AUGMENTATION

3. LUMEN TYPE

   b. Double

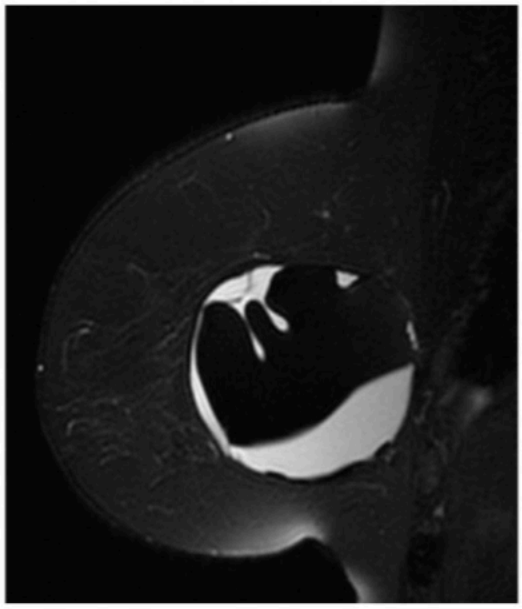

Figure 1 – LUMEN TYPE: DOUBLE. Intact, prepectoral implant: inner silicone and outer saline lumens. Fat- and silicone-suppressed T2W image.

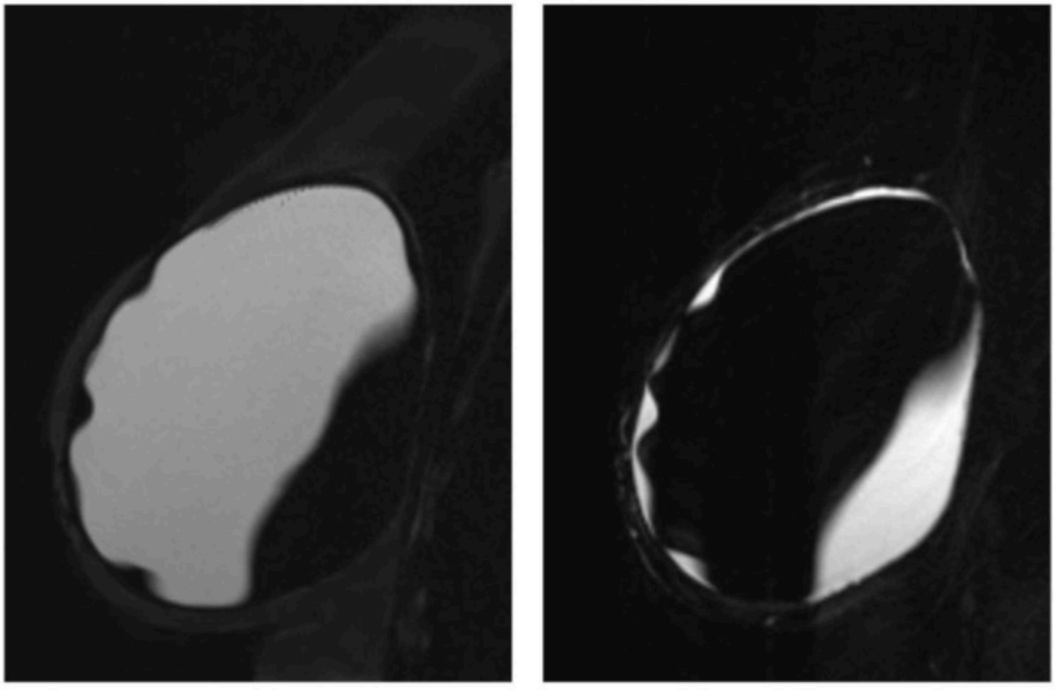

A **B**

Figure 2 – LUMEN TYPE: DOUBLE. Intact, prepectoral implant: inner silicone and outer saline lumens. (A) Sagittal fat- and water-suppressed silicone-specific image and (B) Sagittal fat- and silicone-suppressed T2W image.

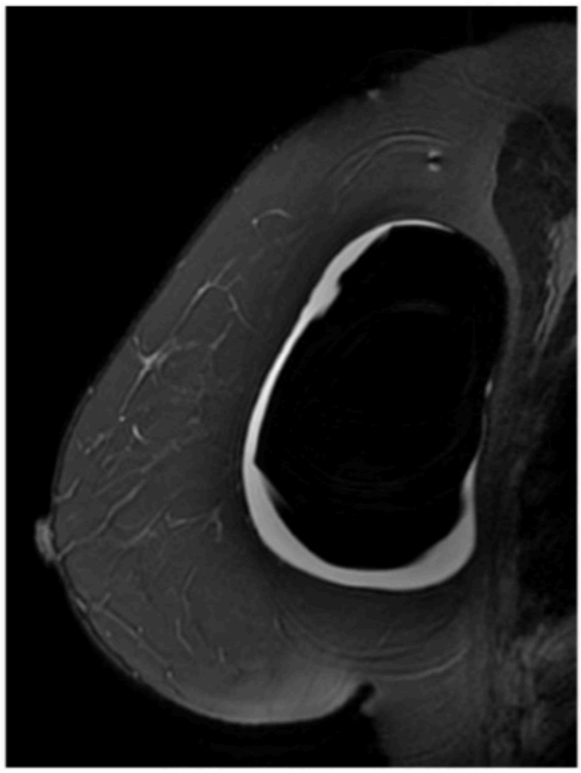

Figure 3 – LUMEN TYPE: DOUBLE. Intact, prepectoral implant: inner silicone and outer saline lumens. Sagittal fat- and silicone-suppressed T2W image.

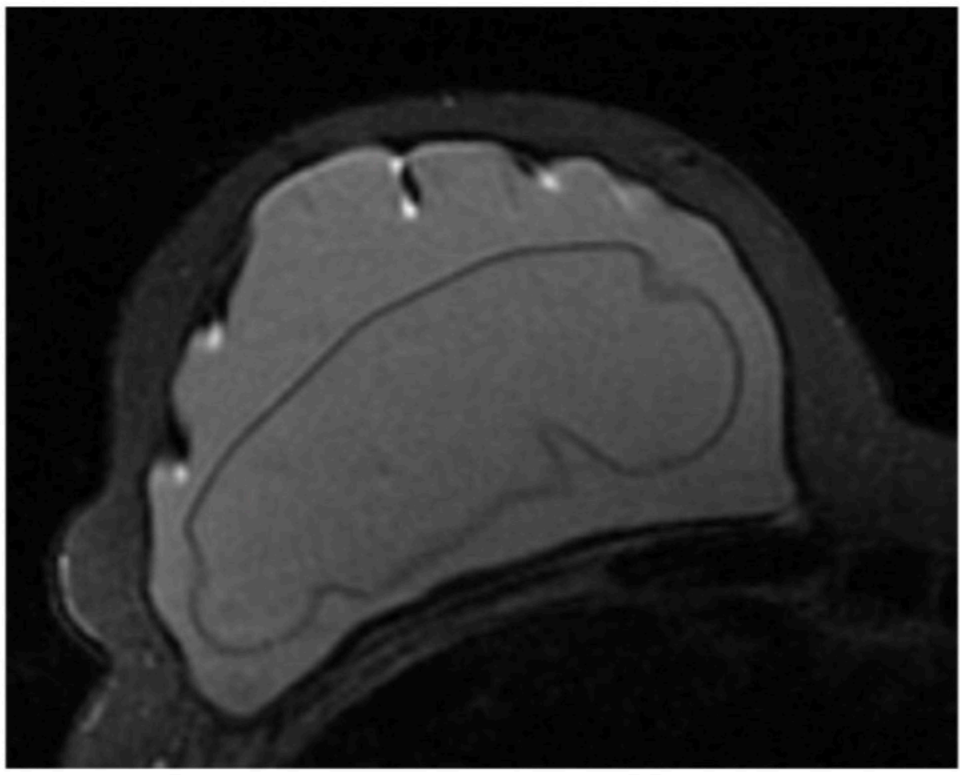

Figure 4 – LUMEN TYPE: DOUBLE. Intact, prepectoral implant: inner and outer silicone lumens. Knowledge of implant type can prevent misinterpreting a case such as this as an intracapsular rupture. Fat- and water-suppressed silicone-specific image.

J. IMPLANTS AND OTHER TYPES OF AUGMENTATION

4. INTRACAPSULAR SILICONE IMPLANT FINDINGS

a. Radial Folds

A radial fold is an infolding of the intact elastomer shell. There is no silicone present interposed between the directly apposed infolded layers of the shell. This is a normal finding which does not indicate intracapsular rupture. Radial folds may also be present in saline implants.

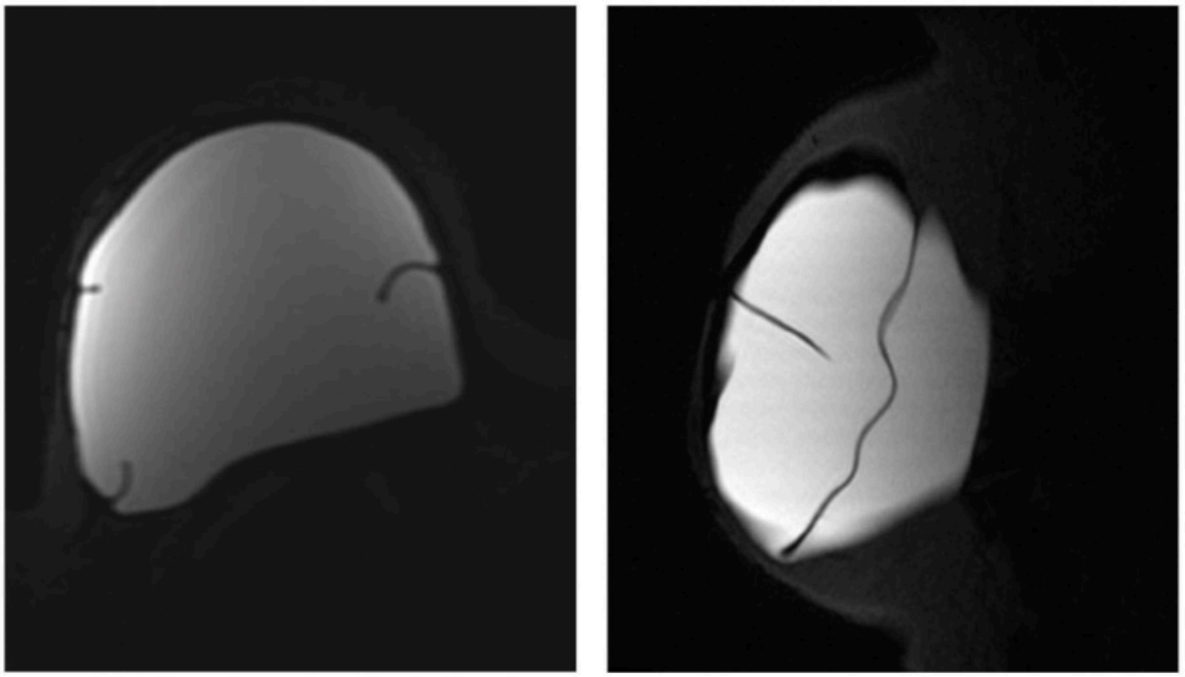

A B

Figure 1 – INTRACAPSULAR FINDINGS: RADIAL FOLDS (normal finding). (A) Axial and (B) sagittal fat- and water-suppressed silicone-specific images.

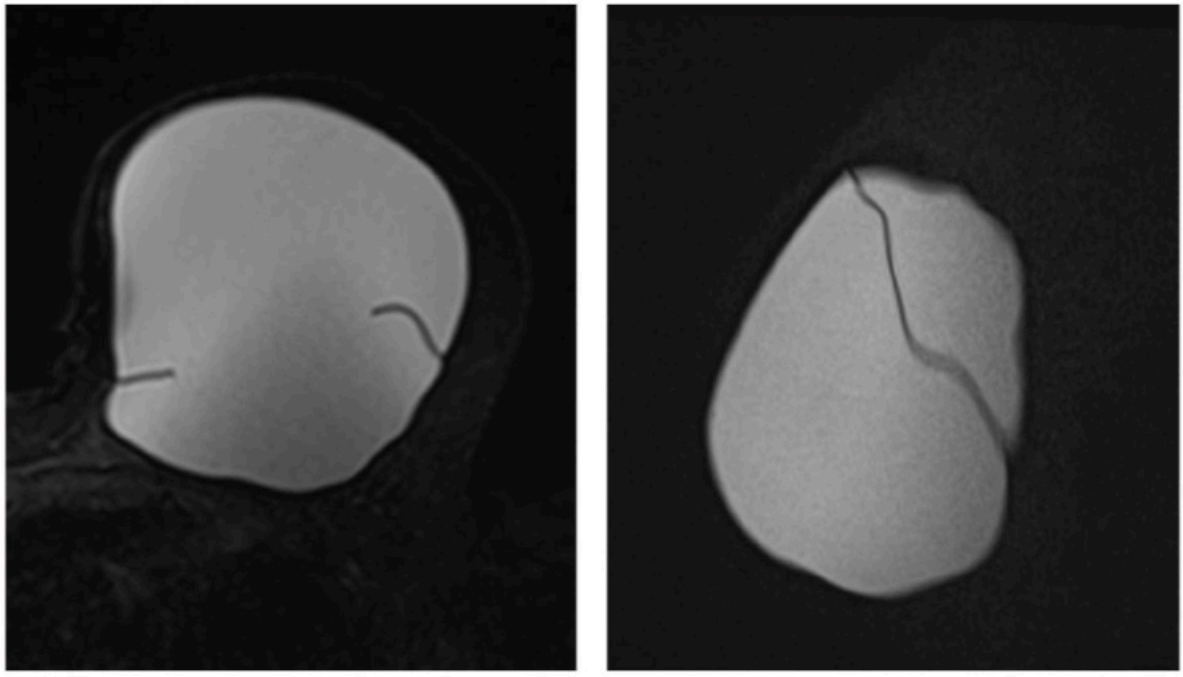

A B

Figure 2 – INTRACAPSULAR FINDINGS: RADIAL FOLD (normal finding). (A) Axial and (B) sagittal fat- and water-suppressed silicone-specific images.

J. IMPLANTS AND OTHER TYPES OF AUGMENTATION

4. INTRACAPSULAR SILICONE IMPLANT FINDINGS

b. Signs of Intracapsular Rupture

MRI signs of intracapsular rupture reflect silicone outside of the non-intact implant shell but within the fibrous capsule. One sign is the subcapsular line sign, with silicone between the hypointense line of the implant shell and the edge of the capsule. Another sign of rupture is the keyhole or teardrop sign, with silicone present in the potential space created by the apposed shell walls of a radial fold. With greater collapse, there are multiple adjacent curvilinear or wavy hypointense lines of the collapsed implant shell floating within the silicone, the linguine sign.

i. Subcapsular line

This finding indicates intracapsular rupture. Silicone is present between the fibrous capsule and collapsed implant envelope, seen as a hypointense line paralleling the fibrous capsule.

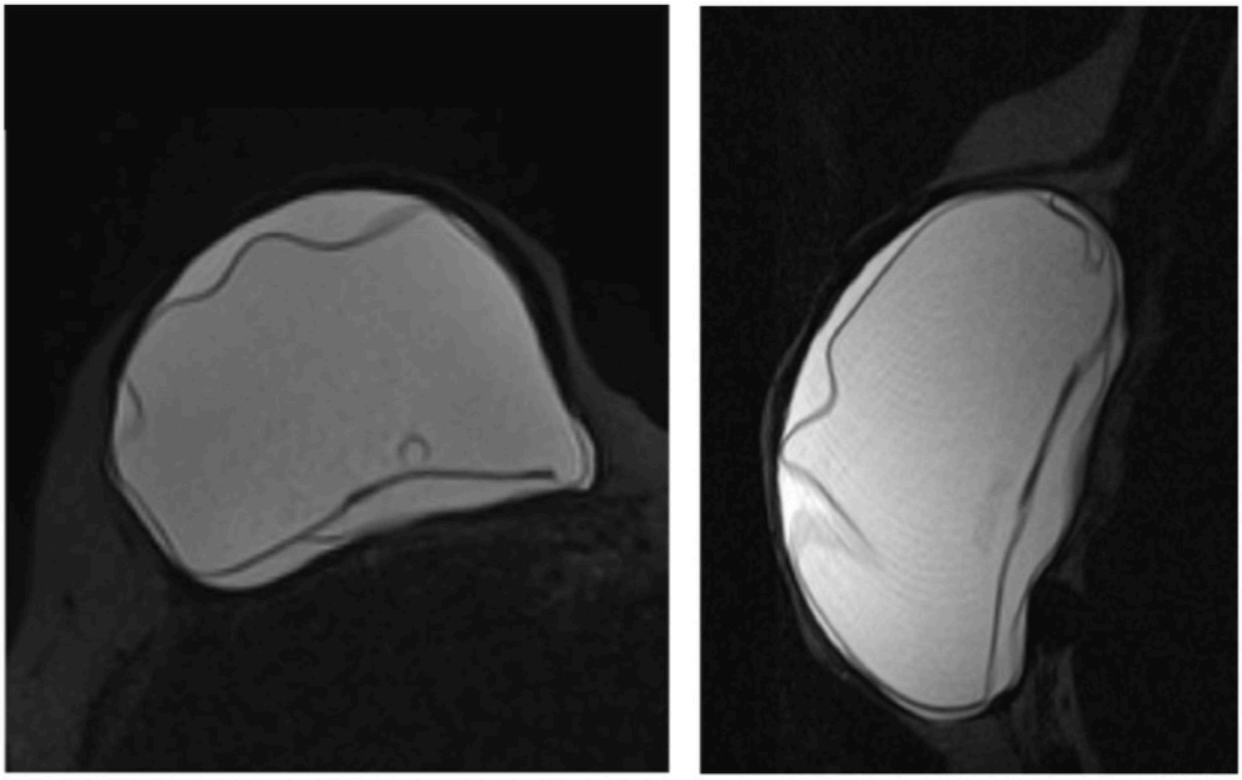

A B

Figure 1 – INTRACAPSULAR FINDINGS: SUBCAPSULAR LINE. There is intracapsular rupture. (A) Axial and (B) sagittal fat- and water-suppressed silicone-specific images.

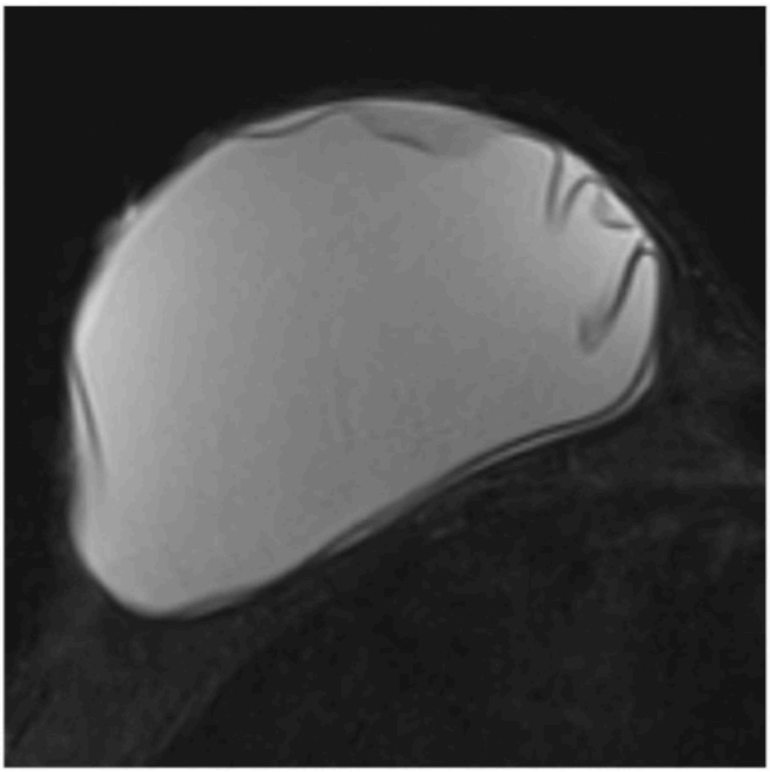

Figure 2 – INTRACAPSULAR FINDINGS: SUBCAPSULAR LINE. There is intracapsular rupture. Fat- and water-suppressed silicone-specific image.

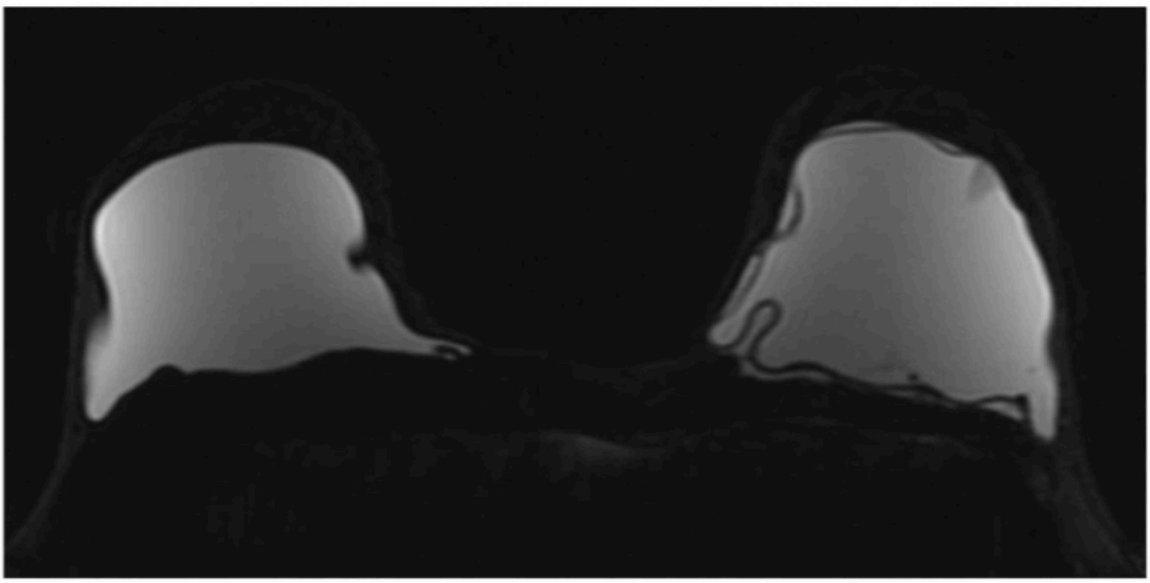

Figure 3 – INTRACAPSULAR FINDINGS: SUBCAPSULAR LINE (left). There is left silicone implant intracapsular rupture. The right silicone implant appears intact. Fat- and water-suppressed silicone-specific image.

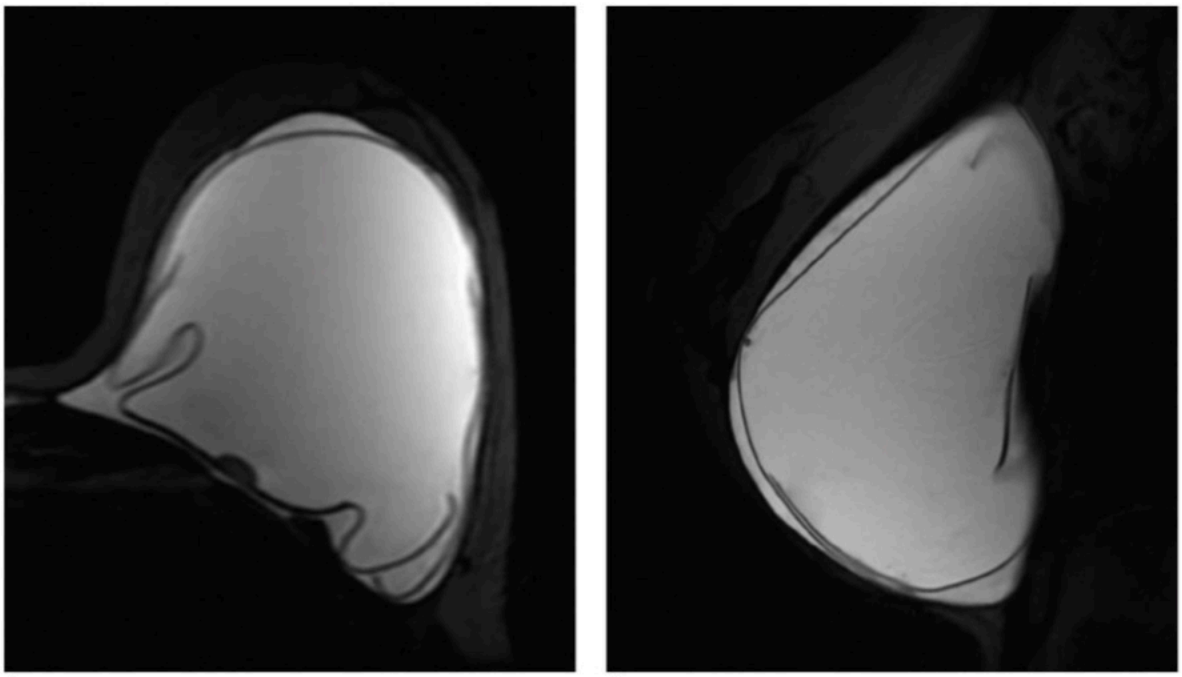

A B

Figure 4 – INTRACAPSULAR FINDINGS: SUBCAPSULAR LINE. There is intracapsular rupture. (A) Axial and (B) sagittal fat- and water-suppressed silicone-specific images.

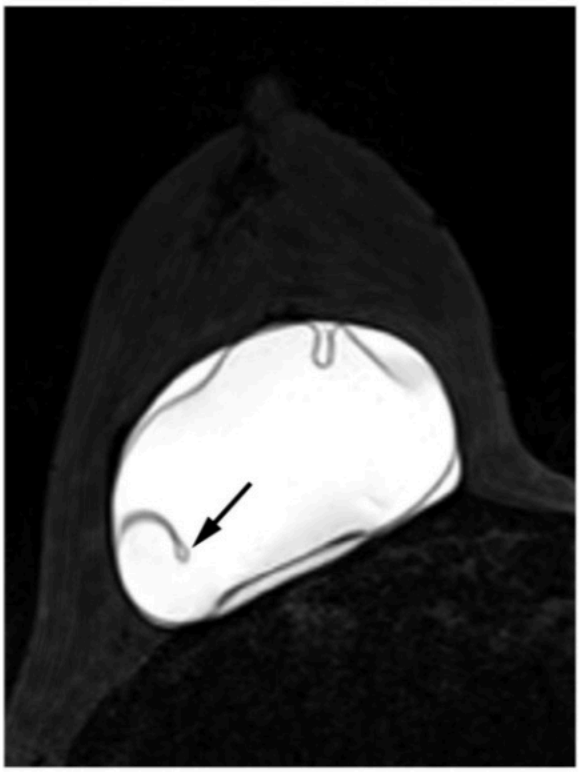

Figure 5 – INTRACAPSULAR FINDINGS: SUBCAPSULAR LINE. The keyhole sign is also present (arrow). There is intracapsular rupture. Fat- and water-suppressed silicone-specific image.

J. IMPLANTS AND OTHER TYPES OF AUGMENTATION

4. INTRACAPSULAR SILICONE IMPLANT FINDINGS

b. Signs of Intracapsular Rupture

ii. Keyhole sign

This finding indicates intracapsular rupture. Silicone is present within the potential space created by the apposed walls of the implant shell or envelope. Silicone signal intensity is seen inside and outside of the hypointense loop representing the collapsed implant envelope.

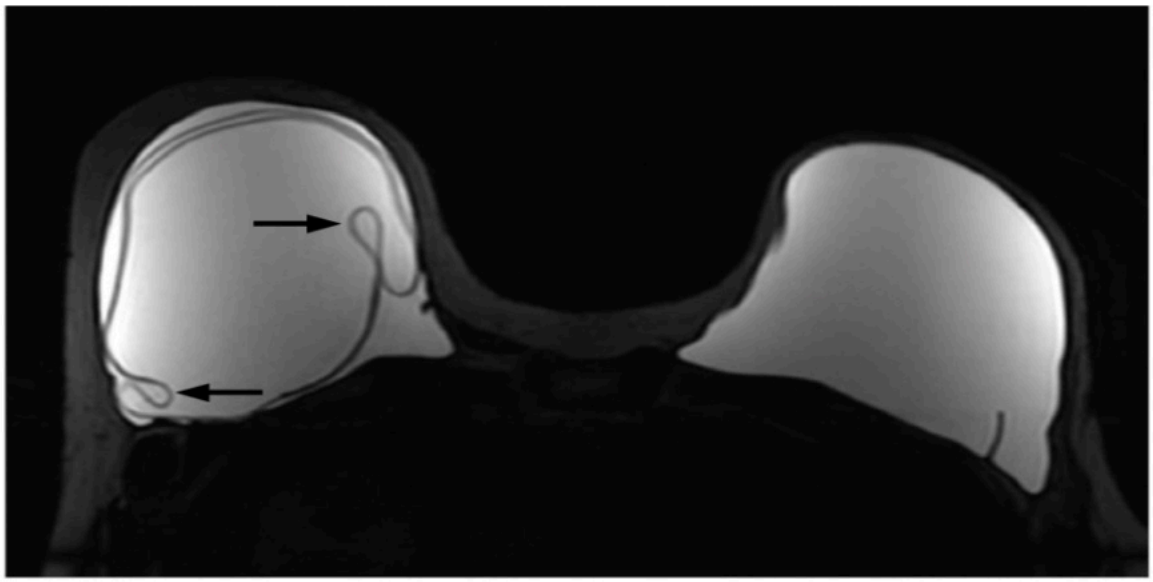

Figure 1 – INTRACAPSULAR FINDINGS: KEYHOLE SIGN (arrows) involving right silicone implant. The subcapsular line sign is also present. There is right intracapsular rupture. The left implant has a radial fold but is intact. Fat- and water-suppressed silicone-specific image.

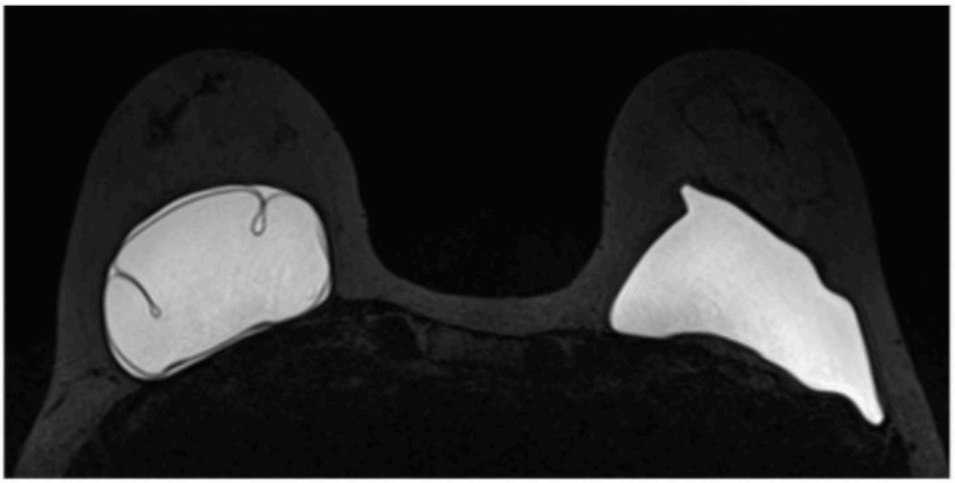

A

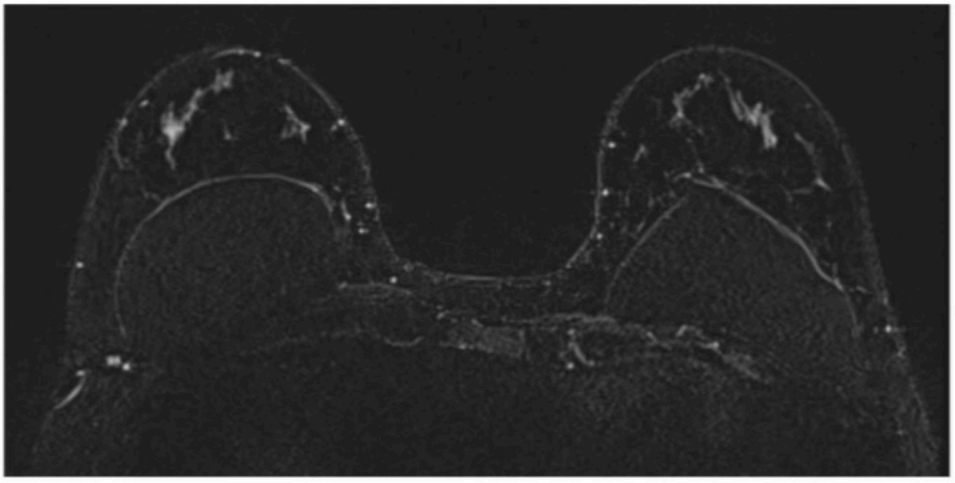

B

Figure 2 – INTRACAPSULAR FINDINGS: KEYHOLE SIGN. The subcapsular line sign is also present. There is right intracapsular rupture. The left implant is intact. (A) Fat- and water-suppressed silicone-specific image. (B) Fat- and silicone-suppressed T2W image.

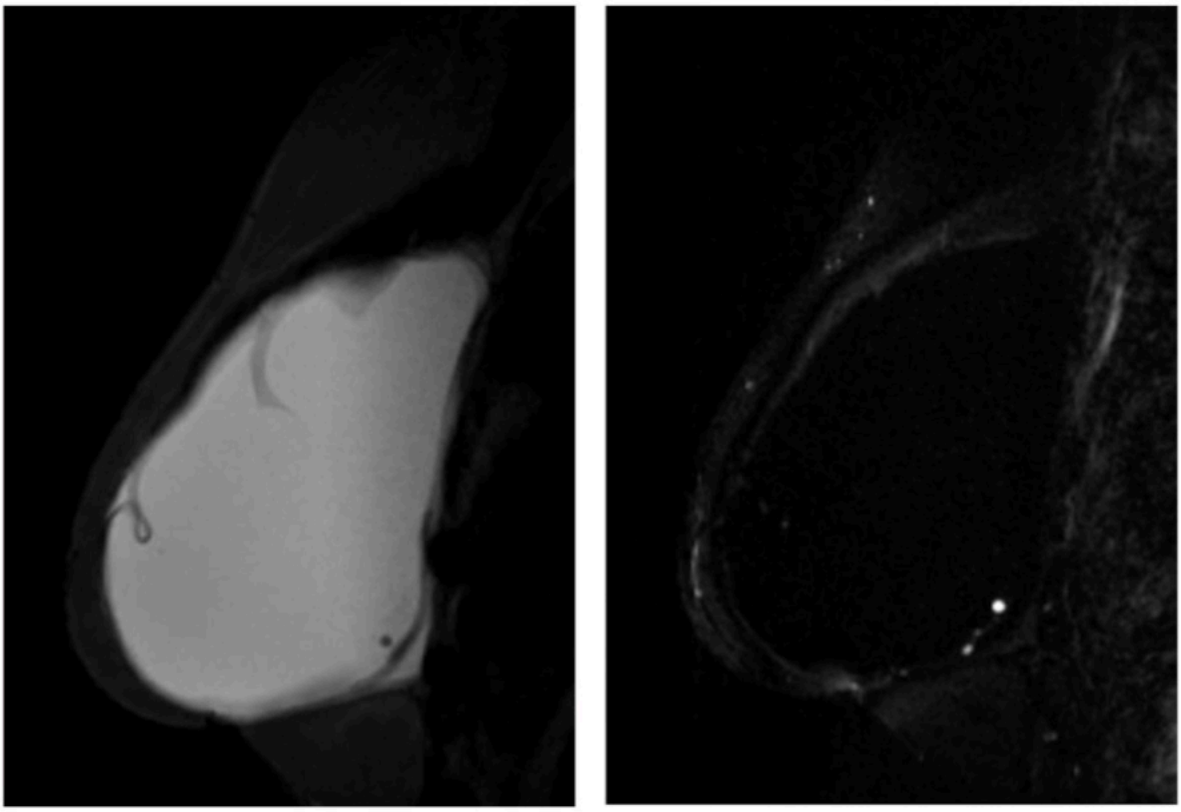

A B

Figure 3 – INTRACAPSULAR FINDINGS: KEYHOLE SIGN. There is intracapsular rupture. There are also water droplets in the posterior inferior aspect of the implant, which can be seen in both intact and ruptured implants. (A) Fat- and water-suppressed silicone-specific image. (B) Fat- and silicone-suppressed T2W image.

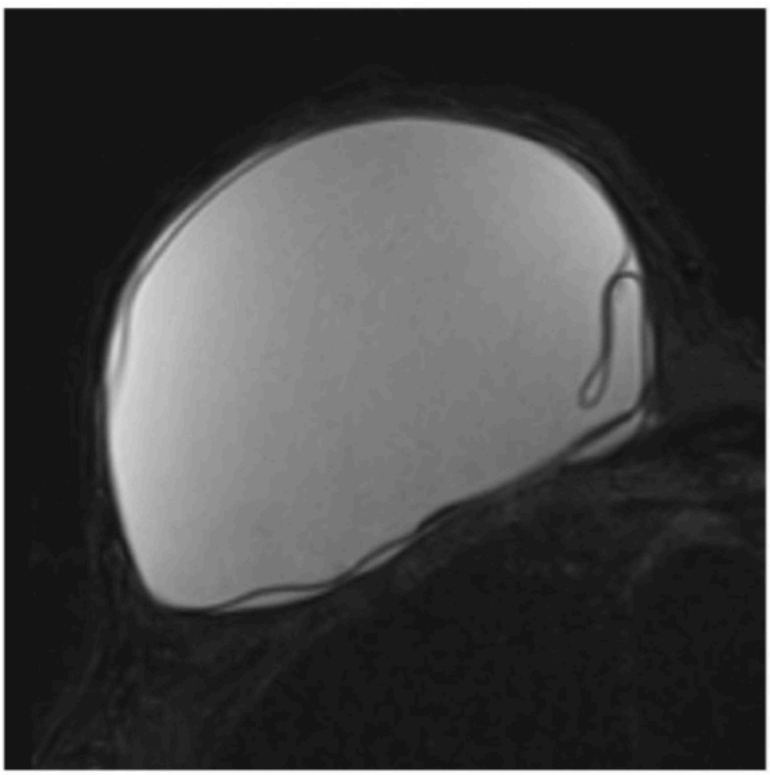

Figure 4 – INTRACAPSULAR FINDINGS: KEYHOLE SIGN. Subcapsular line sign is also present. There is intracapsular rupture. Fat- and water-suppressed silicone-specific image.

J. IMPLANTS AND OTHER TYPES OF AUGMENTATION

4. INTRACAPSULAR SILICONE IMPLANT FINDINGS

b. Signs of Intracapsular Rupture

iii. Linguine sign

This finding indicates intracapsular rupture. Multiple adjacent hypointense curvilinear lines surrounded by silicone signal intensity within the fibrous capsule are the collapsed implant envelope.

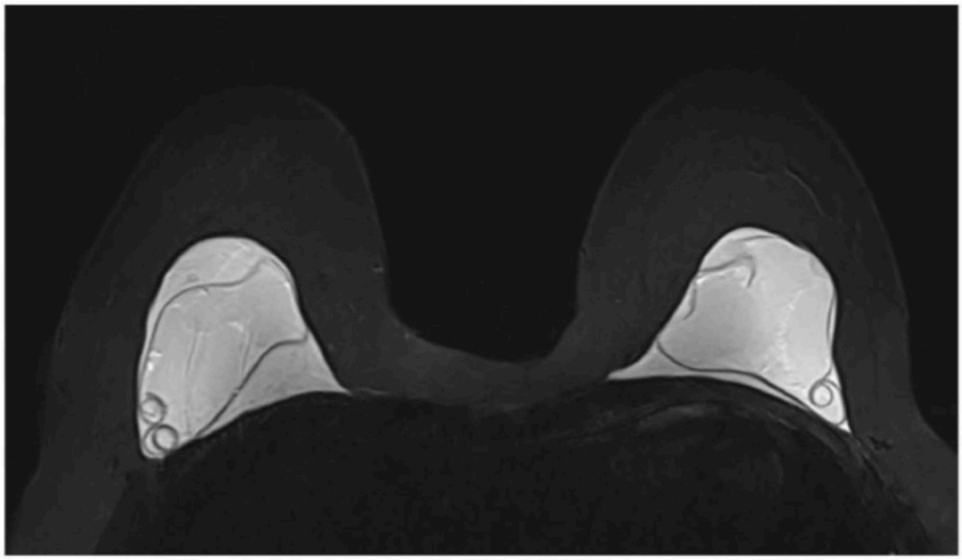

Figure 1 – INTRACAPSULAR FINDINGS: LINGUINE SIGN. Bilateral linguine signs consistent with bilateral intracapsular rupture. Fat- and water-suppressed silicone-specific image.

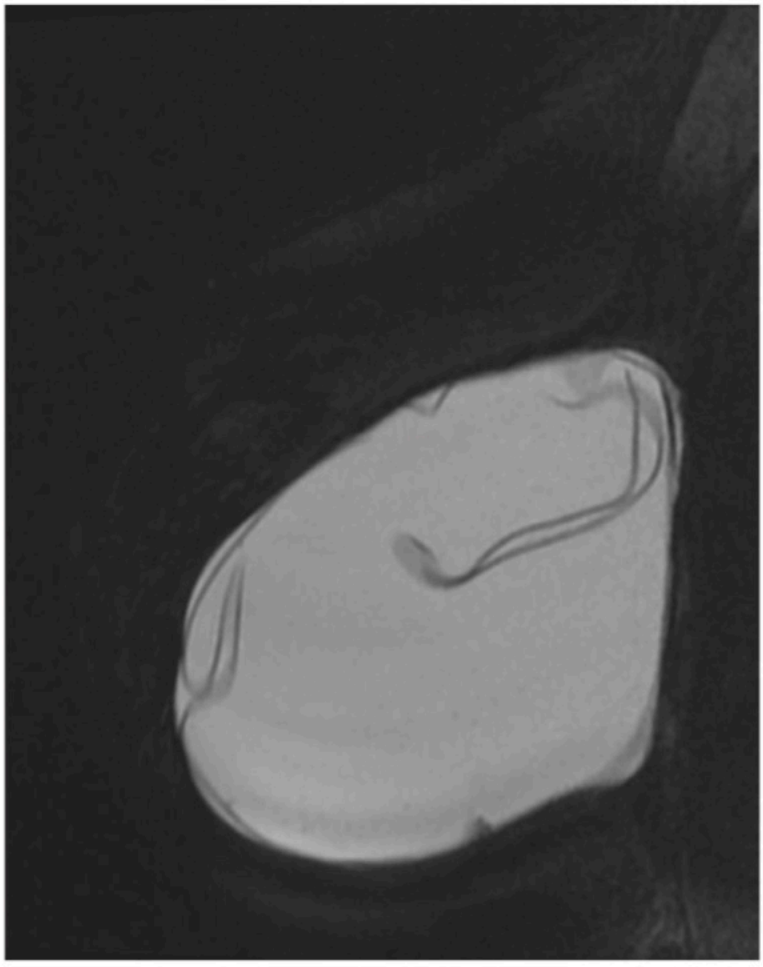

Figure 2 – INTRACAPSULAR FINDINGS: LINGUINE SIGN. There is intracapsular rupture. Fat- and water-suppressed silicone-specific image.

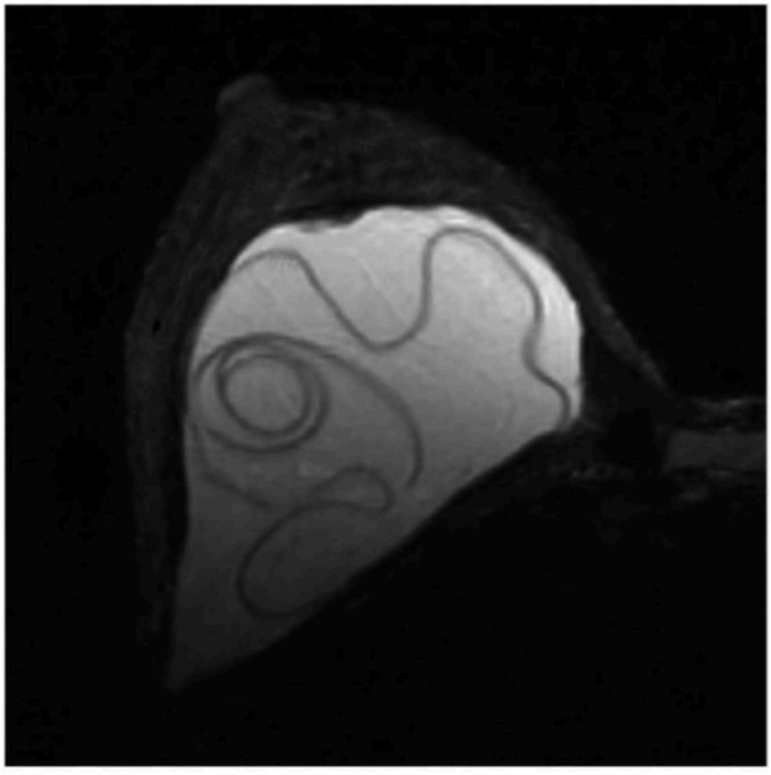

Figure 3 – INTRACAPSULAR FINDINGS: LINGUINE SIGN. There is intracapsular rupture. Fat- and water-suppressed silicone-specific image.

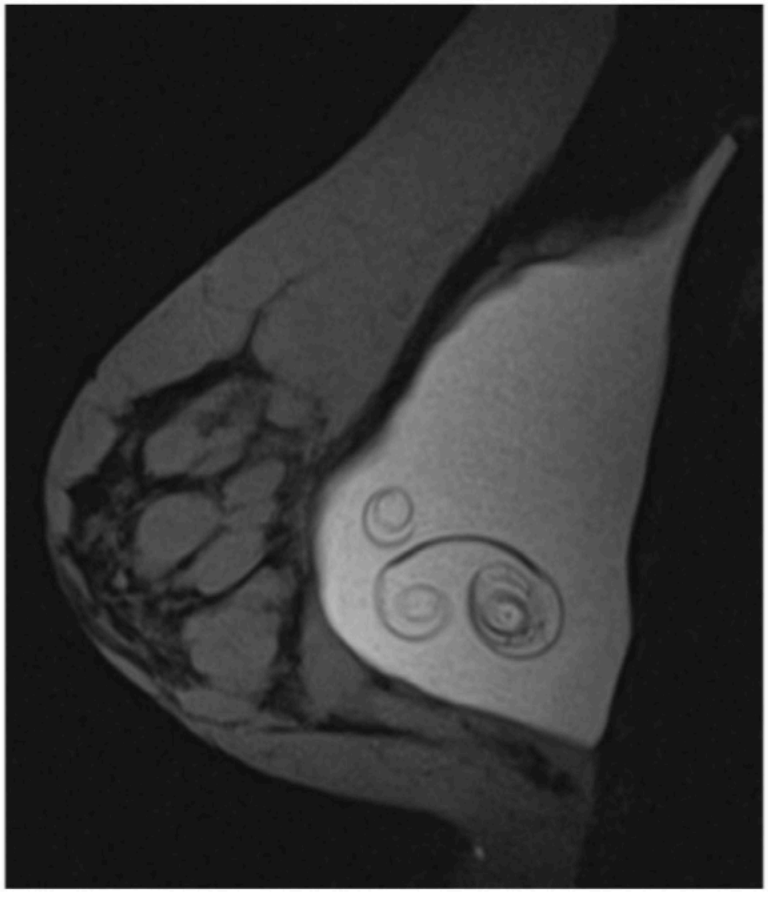

Figure 4 – INTRACAPSULAR FINDINGS: LINGUINE SIGN. There is intracapsular rupture. Fat- and water-suppressed silicone-specific image.

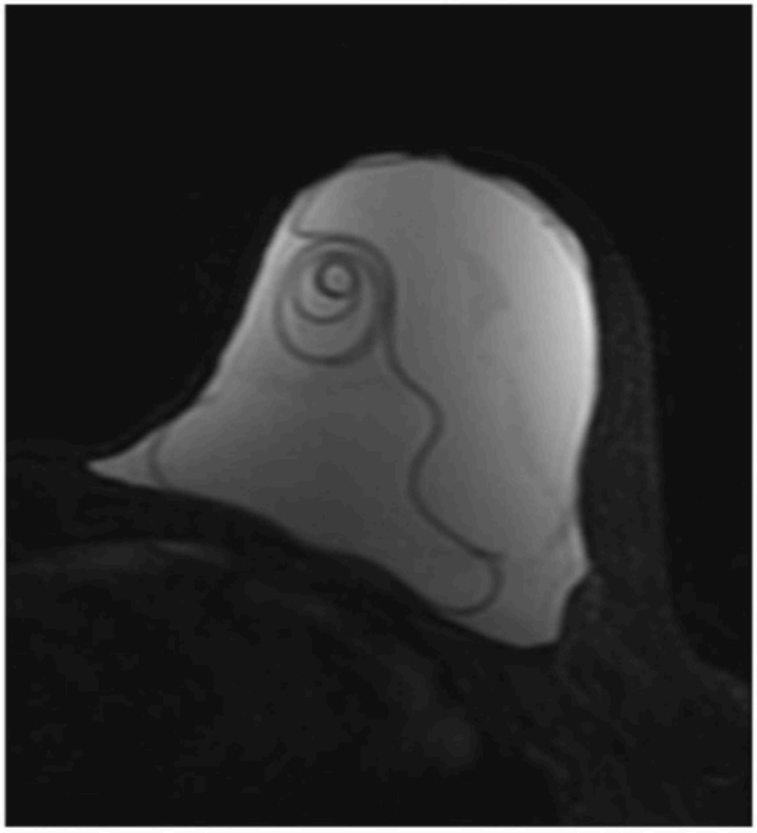

Figure 5 – INTRACAPSULAR FINDINGS: LINGUINE SIGN. There is intracapsular rupture. Fat- and water-suppressed silicone-specific image.

J. IMPLANTS AND OTHER TYPES OF AUGMENTATION

4. INTRACAPSULAR SILICONE IMPLANT FINDINGS

c. Water Droplets

This finding can be seen in intact and in ruptured silicone implants. Water droplets within silicone breast implants are seen as small drops with water signal intensity on water-specific sequences.

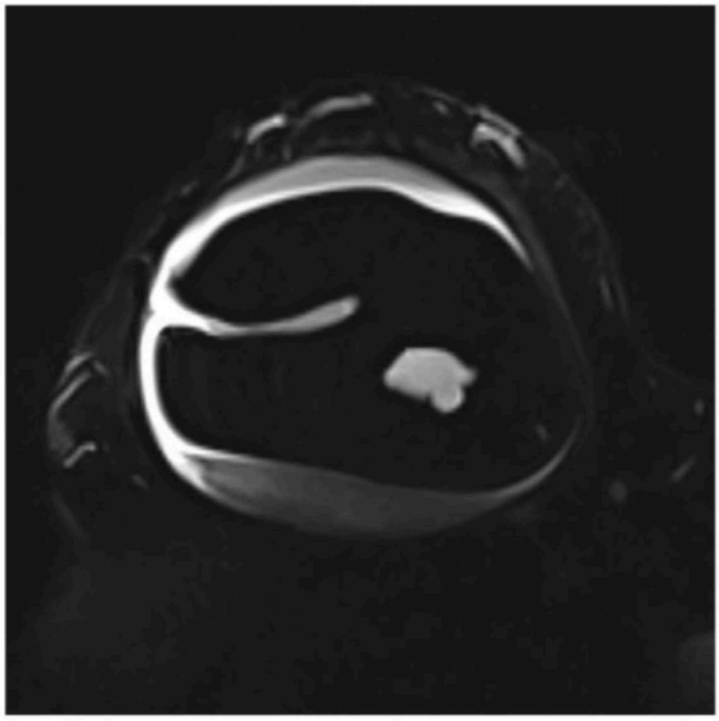

Figure 1 – INTRACAPSULAR FINDINGS: WATER DROPLETS. Water droplet within a ruptured silicone implant. Fat- and silicone-suppressed T2W image.

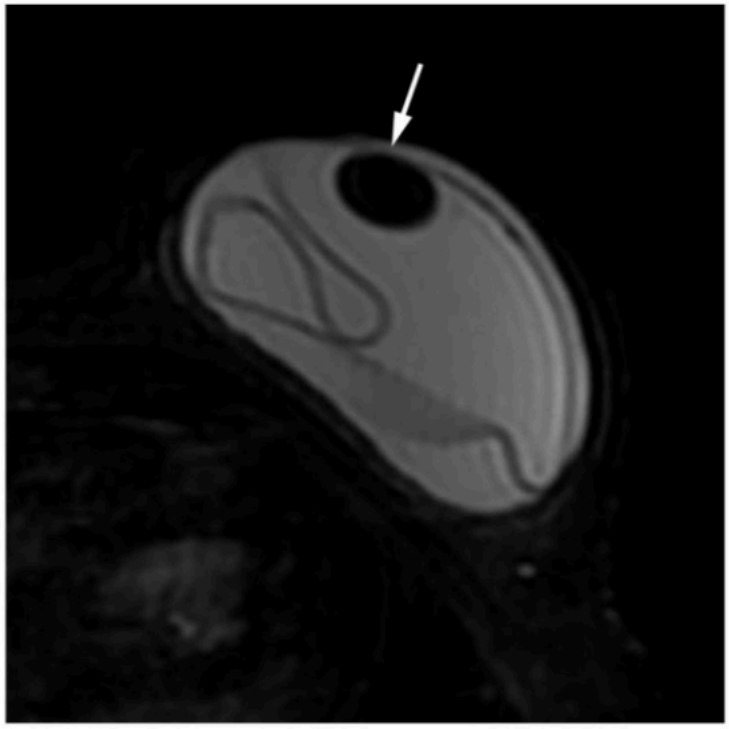

Figure 2 – INTRACAPSULAR FINDINGS: WATER DROPLETS. Water droplet (arrow) within a ruptured silicone implant with subcapsular line. Fat- and water-suppressed silicone-specific image.

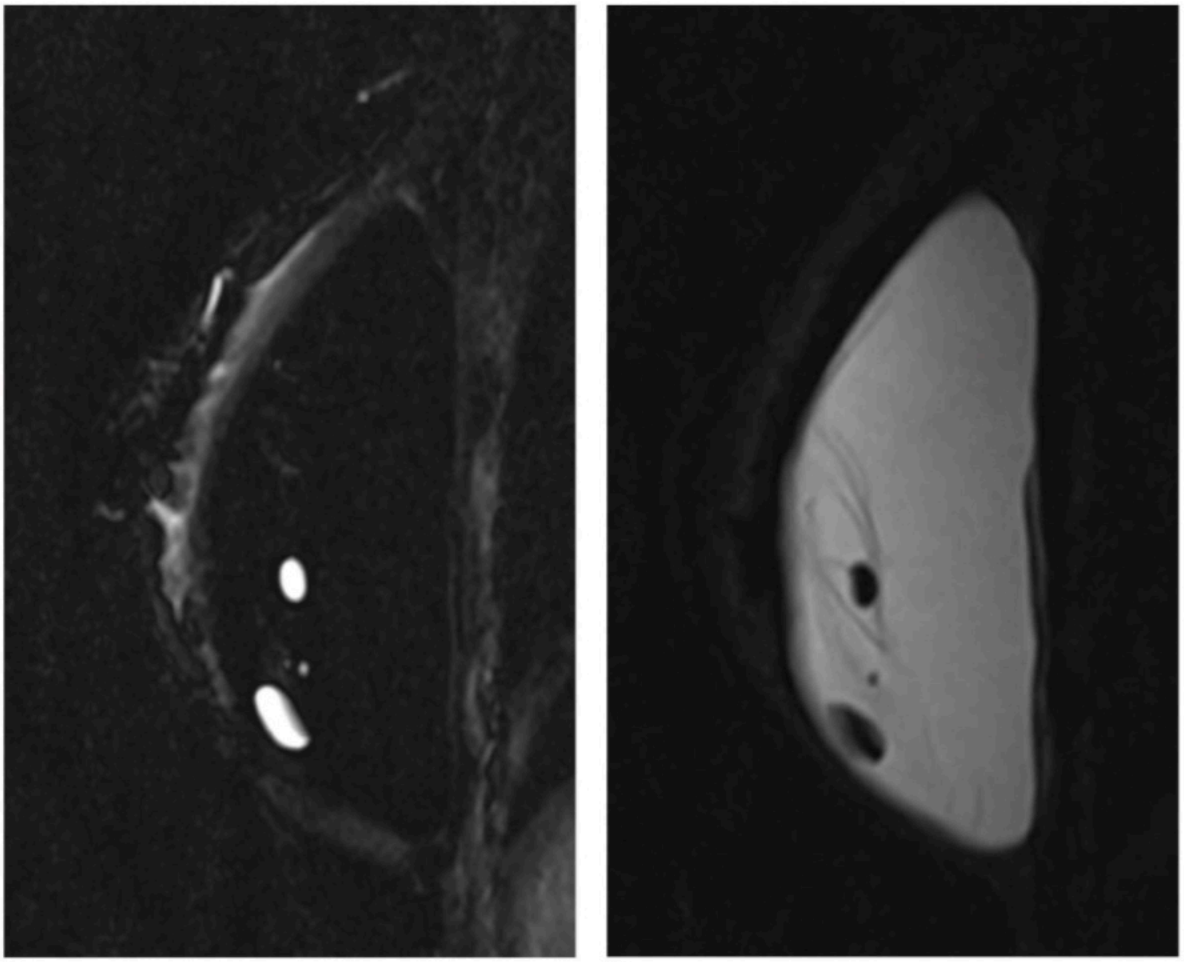

A B

Figure 3 – INTRACAPSULAR FINDINGS: WATER DROPLETS. Water droplets within a ruptured silicone implant with linguine sign. (A) Fat- and silicone-suppressed T2W image. (B) Fat- and water-suppressed silicone-specific image.

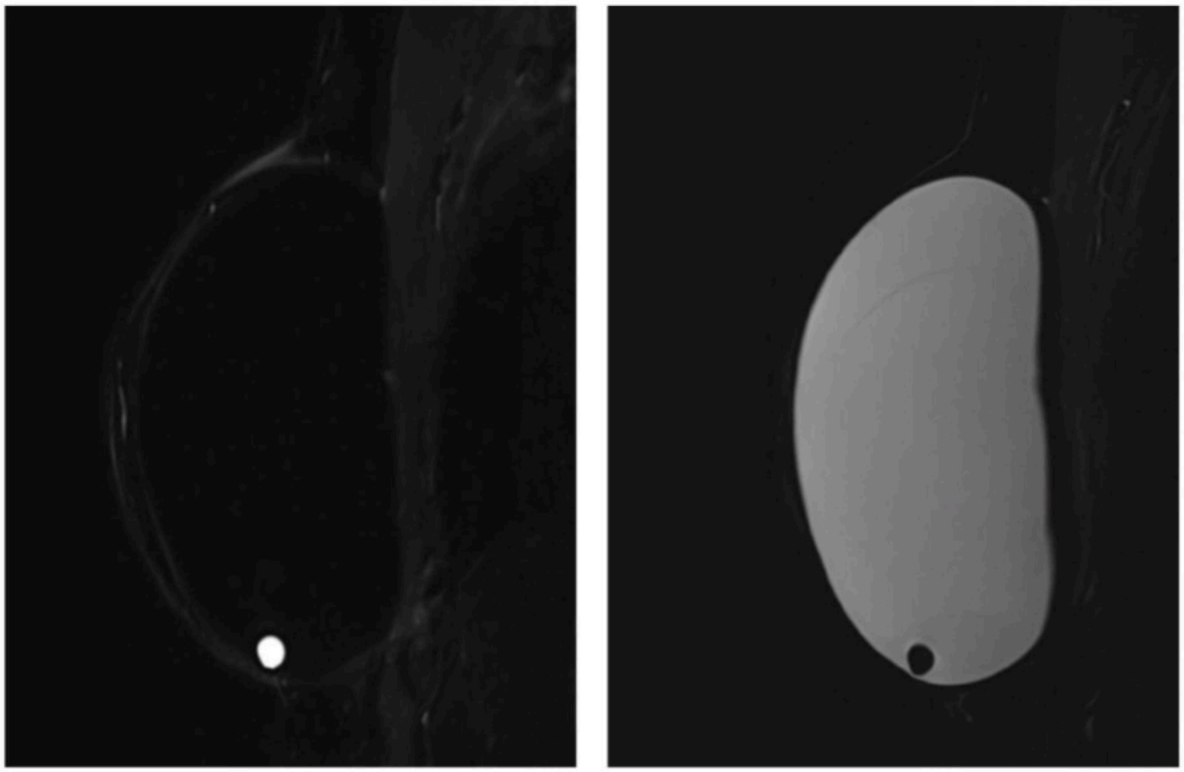

A B

Figure 4 – INTRACAPSULAR FINDINGS: WATER DROPLETS. Water droplet within an intact silicone implant. (A) Fat- and silicone-suppressed T2W image. (B) Fat- and water-suppressed silicone-specific image.

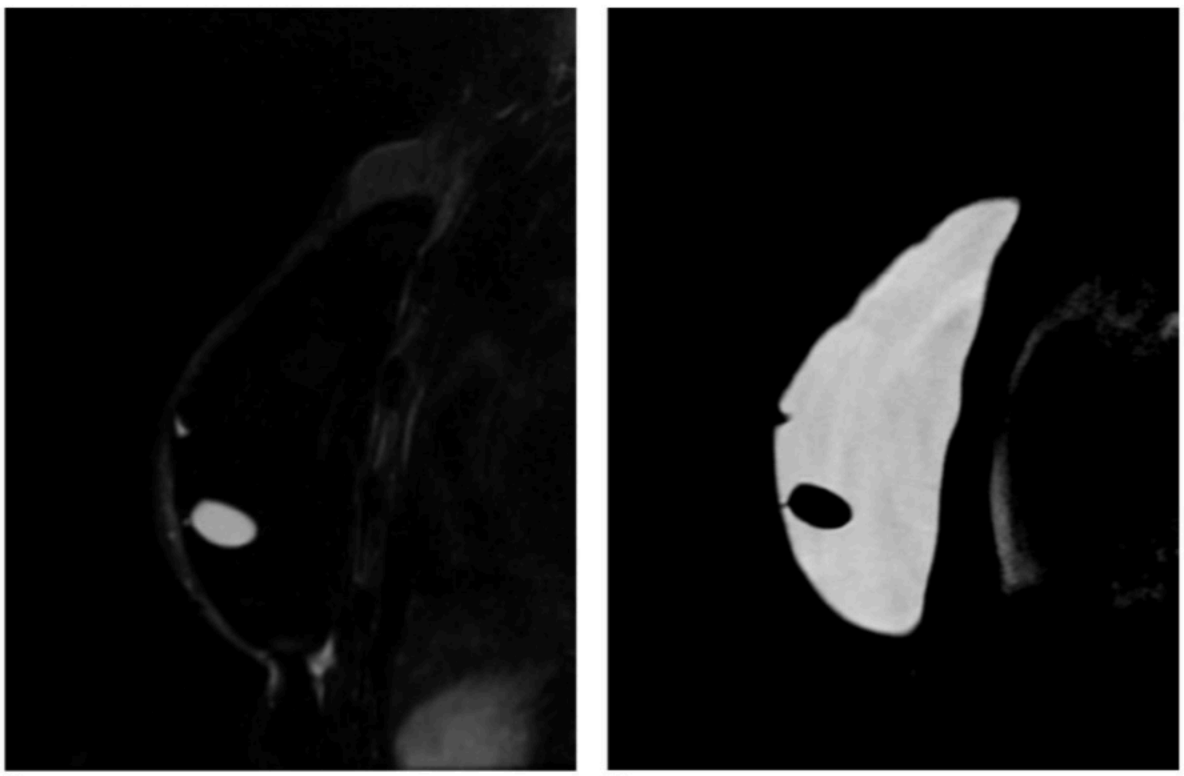

A B

Figure 5 – INTRACAPSULAR FINDINGS: WATER DROPLETS. Water droplet within an intact silicone implant. (A) Fat- and silicone-suppressed T2W image. (B) Fat- and water-suppressed silicone-specific image.

J. IMPLANTS AND OTHER TYPES OF AUGMENTATION

5. EXTRACAPSULAR SILICONE FINDINGS

a. Breast

Free silicone outside the fibrous capsule and within the breast indicates either a current or prior extracapsular (and, by definition, an accompanying intracapsular) rupture. Note that it is possible to see extracapsular silicone in the setting of a current intact implant (if a previously ruptured implant was replaced), or in the absence of an implant (prior explanation of a ruptured implant).

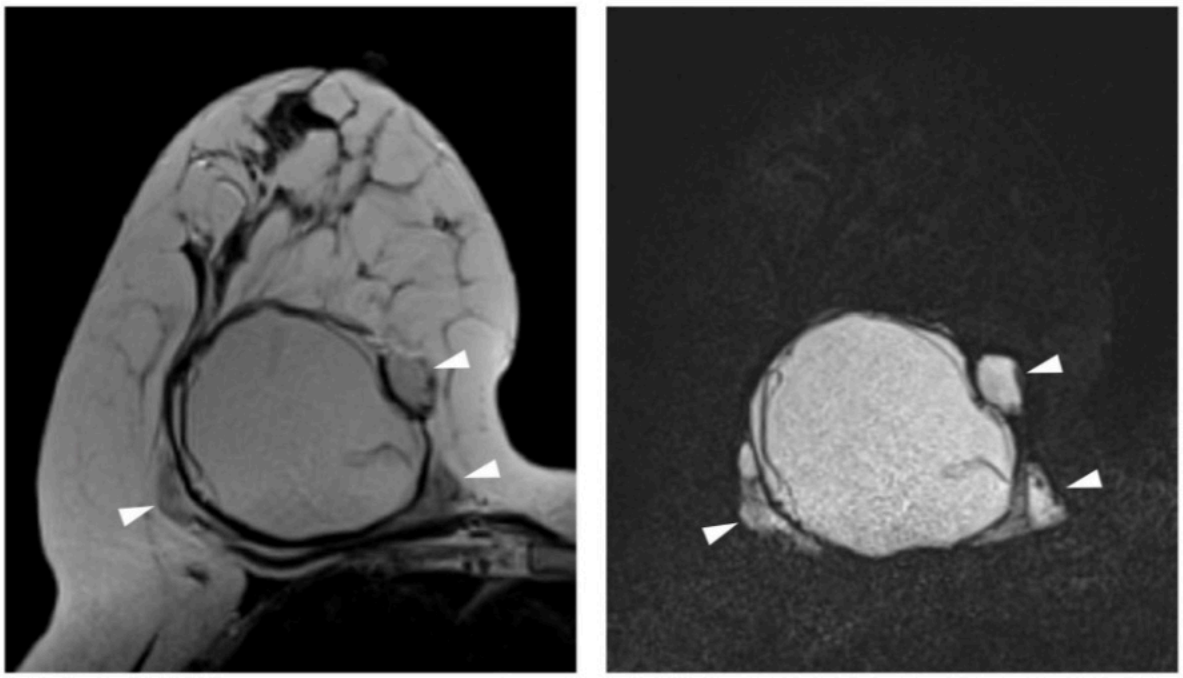

A B

Figure 1 – EXTRACAPSULAR SILICONE: BREAST (arrowheads). (A) Non-fat-suppressed T2W image. (B) Fat- and water-suppressed silicone-specific image.

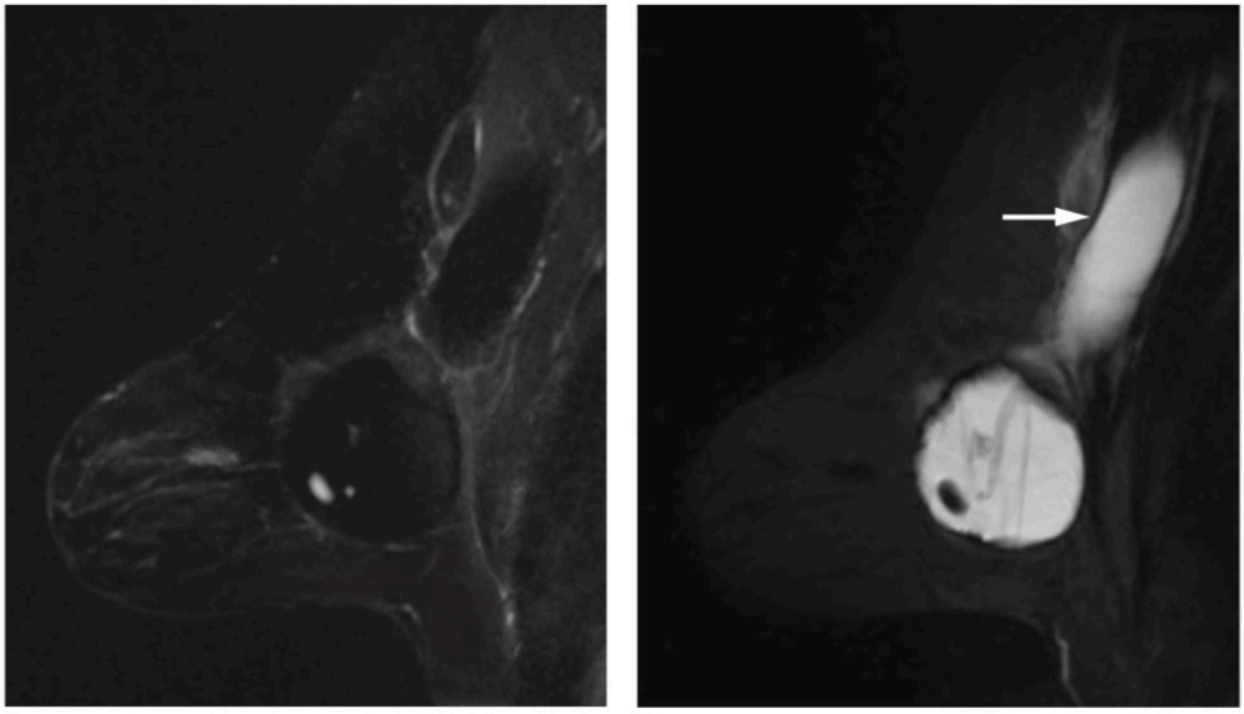

A B

Figure 2 – EXTRACAPSULAR SILICONE: BREAST. Extracapsular silicone (arrow) and water droplet within the ruptured silicone implant. (A) Fat- and silicone-suppressed T2W image. (B) Fat- and water-suppressed silicone-specific image.

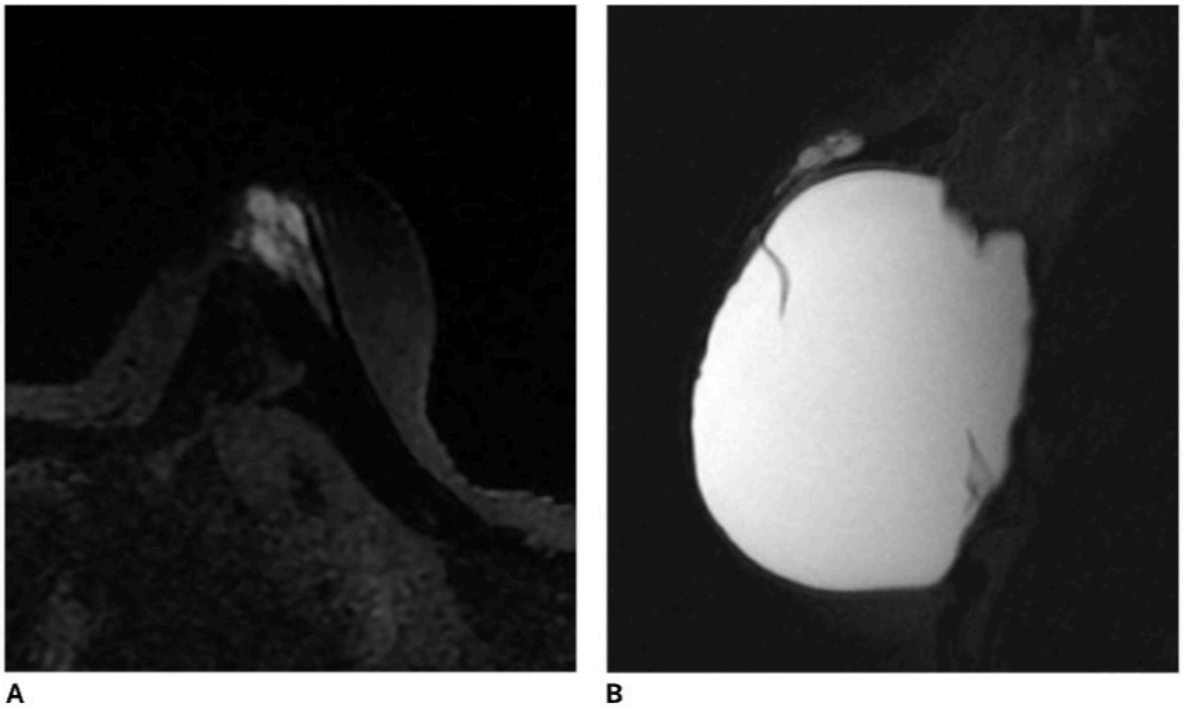

A B

Figure 3 – EXTRACAPSULAR SILICONE: BREAST. Extracapsular silicone along the superior aspect of the left silicone implant. (A) Axial and (B) sagittal fat- and water-suppressed silicone-specific images.

J. IMPLANTS AND OTHER TYPES OF AUGMENTATION

5. EXTRACAPSULAR FINDINGS

b. Lymph Nodes

Silicone in lymph nodes can follow silicone signal on MRI. Silicone may be present in lymph nodes due to implant rupture (related to a current implant or one previously explanted), but also with intact silicone implants due to "silicone bleed."

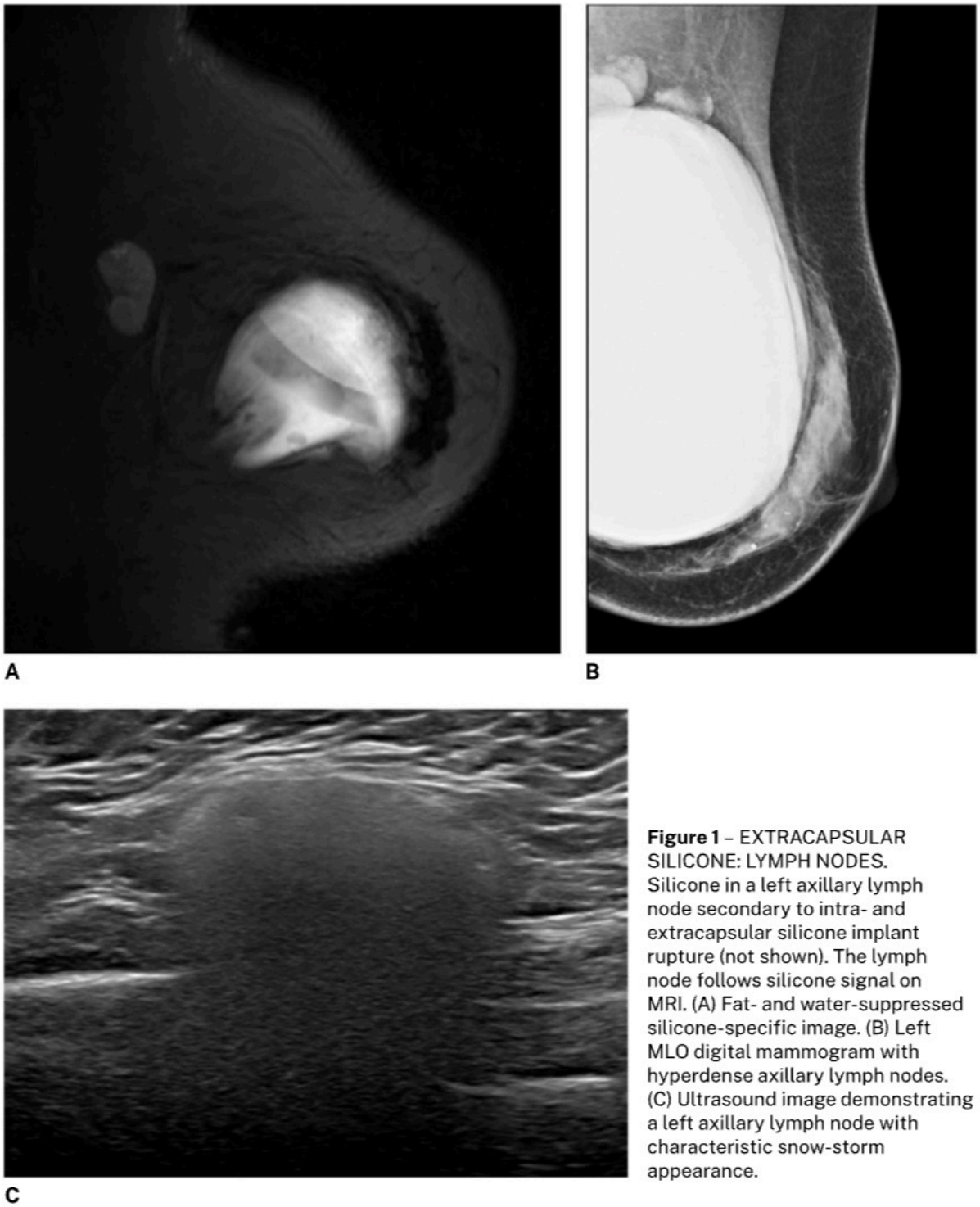

A B C

Figure 1 – EXTRACAPSULAR SILICONE: LYMPH NODES. Silicone in a left axillary lymph node secondary to intra- and extracapsular silicone implant rupture (not shown). The lymph node follows silicone signal on MRI. (A) Fat- and water-suppressed silicone-specific image. (B) Left MLO digital mammogram with hyperdense axillary lymph nodes. (C) Ultrasound image demonstrating a left axillary lymph node with characteristic snow-storm appearance.

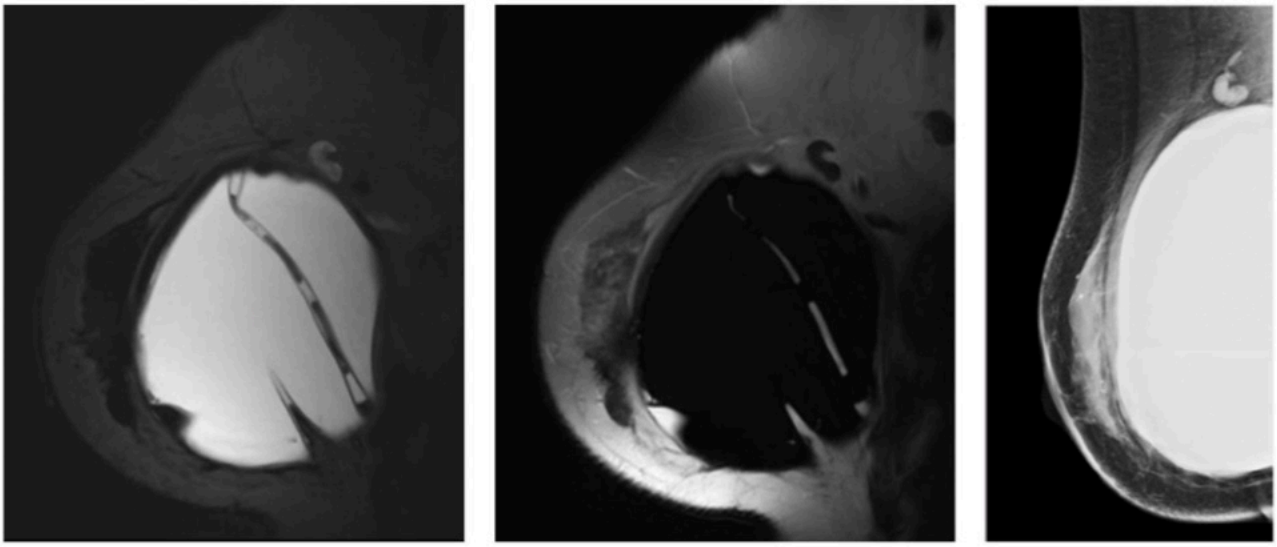

A B C

Figure 2 – EXTRACAPSULAR SILICONE: LYMPH NODES. Silicone in a right axillary lymph node. The lymph node follows silicone signal on MRI. (A) Fat- and water-suppressed silicone-specific image. (B) Fat- and silicone-suppressed T2W image. Note: Fat suppression is incomplete. (C) Right MLO digital mammogram image demonstrating a hyperdense axillary lymph node.

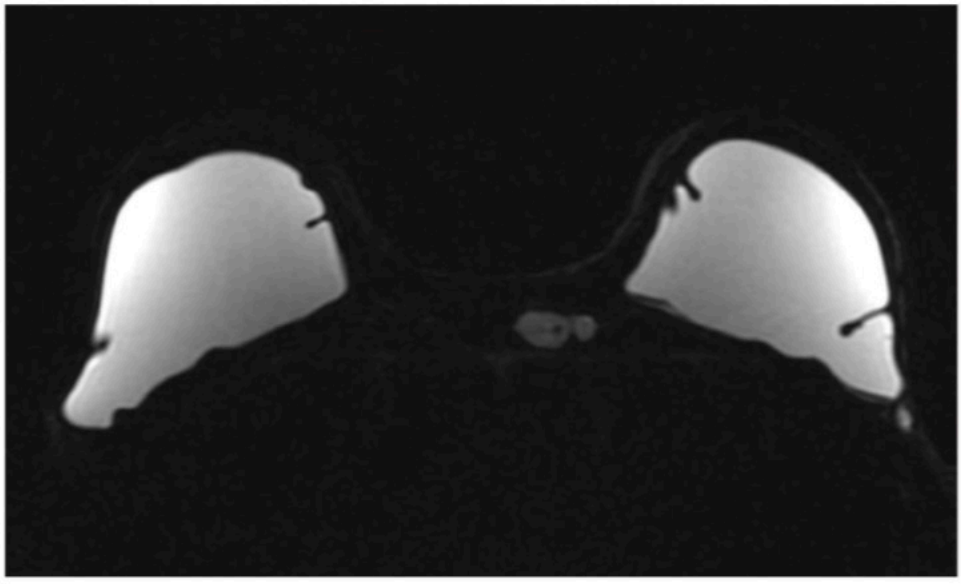

Figure 3 – EXTRACAPSULAR SILICONE: LYMPH NODES. Silicone in left internal mammary lymph nodes. The lymph nodes follows silicone signal on MRI. Fat- and water-suppressed silicone-specific image.

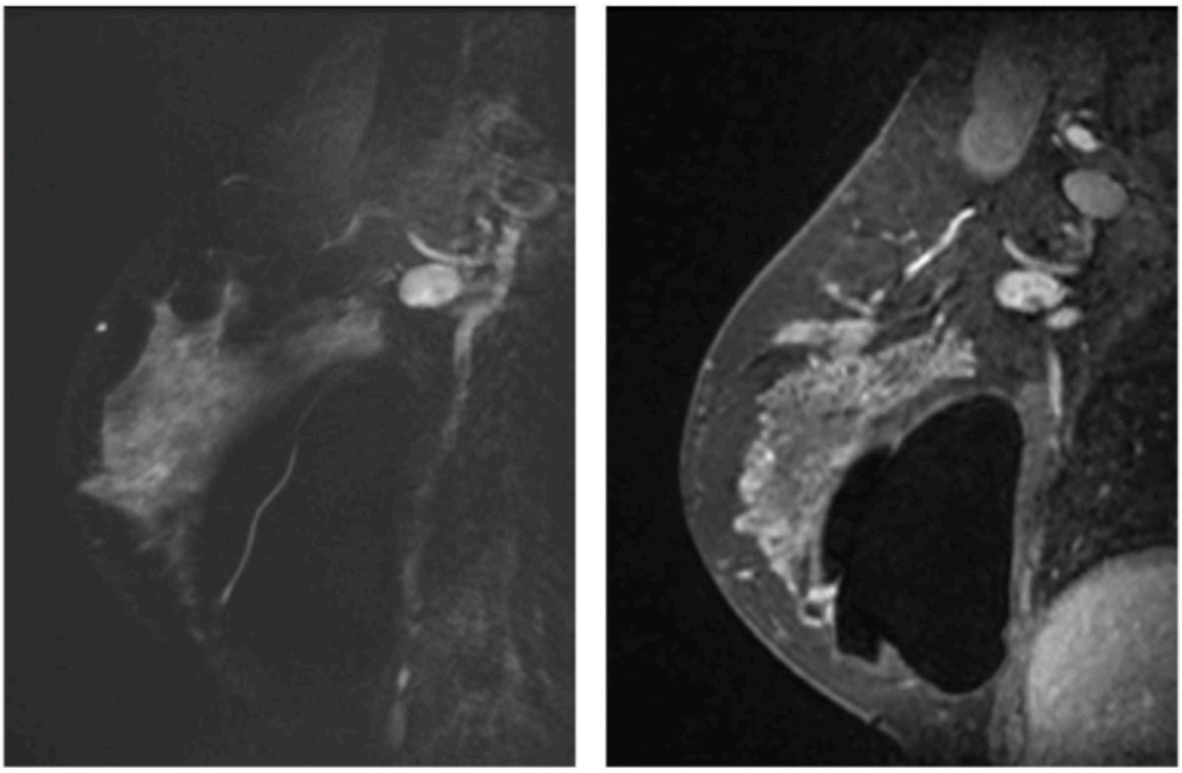

A B

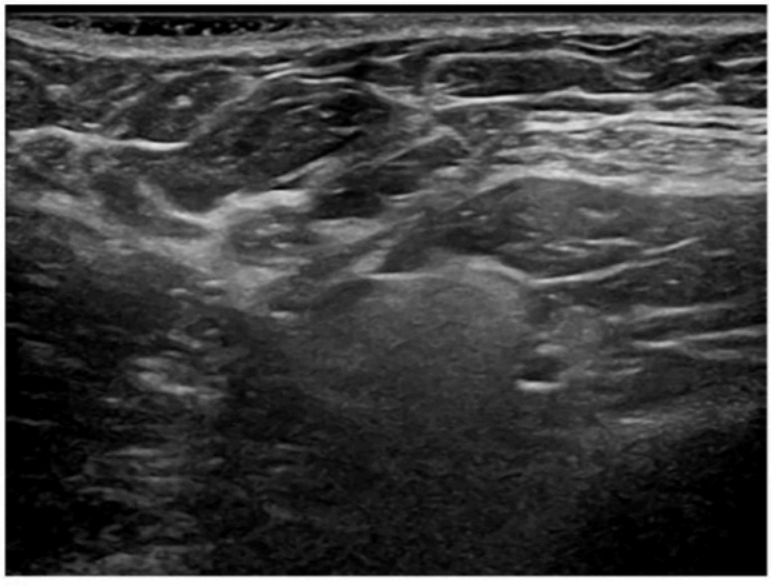

C

Figure 4 – EXTRACAPSULAR SILICONE: LYMPH NODES. Silicone in a right axillary lymph node secondary to intra- and extracapsular silicone implant rupture. The lymph node does not follow silicone signal on MRI in this case. (A) Fat- and silicone-suppressed T2W image. (B) Fat-suppressed early post-contrast T1W image. (C) Ultrasound image demonstrating a right axillary lymph node with snow-storm appearance.

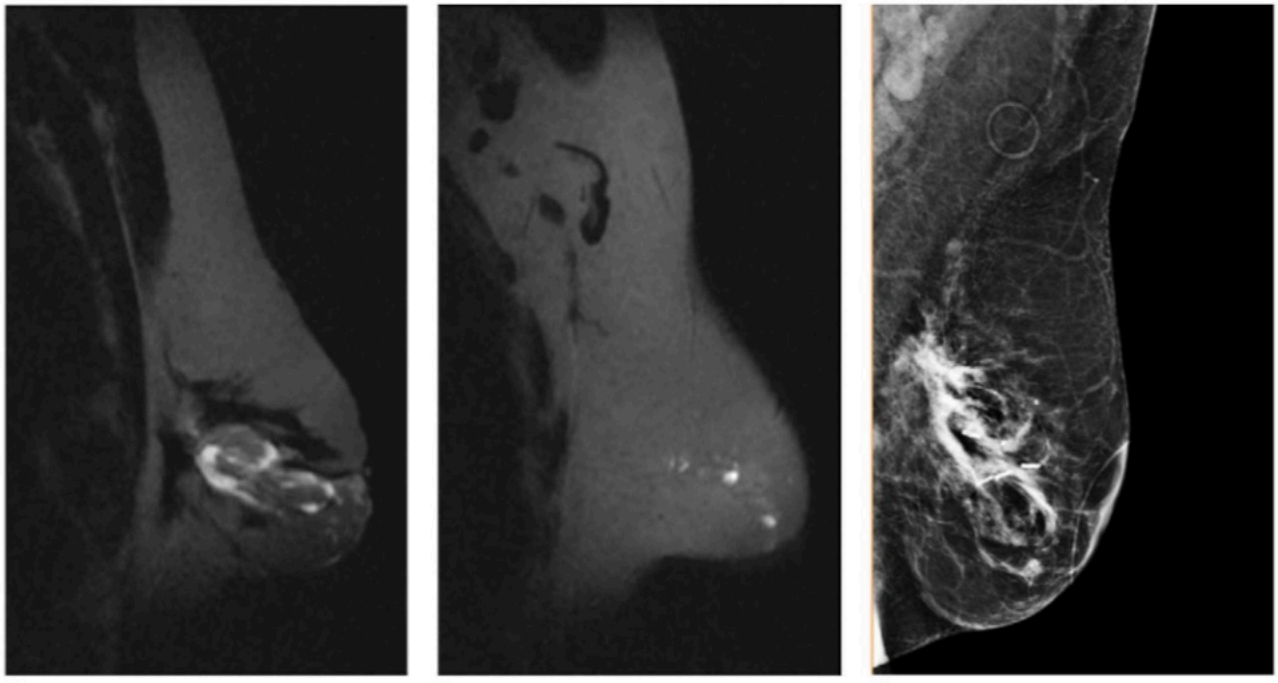

A B C

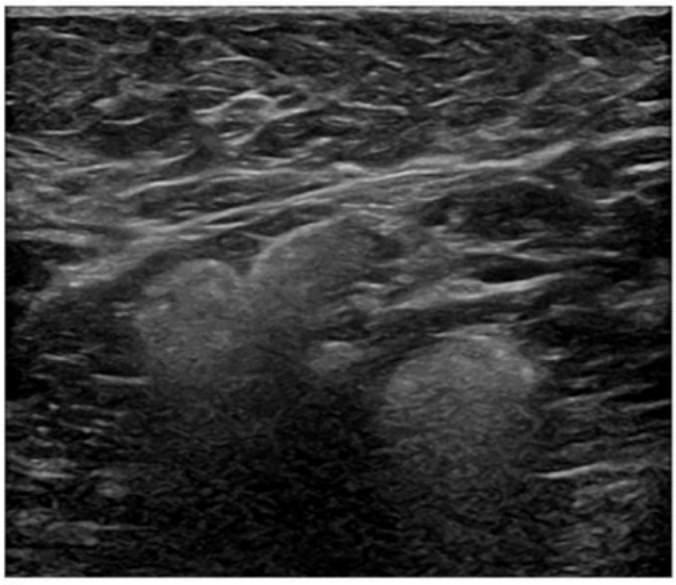

D

Figure 5 – EXTRACAPSULAR SILICONE: LYMPH NODES. Silicone in left axillary lymph nodes status post removal of a ruptured silicone implant. Lymph nodes do not follow silicone signal on MRI in this case. (A) Fat- and water-suppressed silicone-specific image demonstrates retained silicone in the breast parenchyma. (B) Fat- and water-suppressed silicone-specific image demonstrates lymph nodes that do not follow silicone signal. *Note:* fat suppression is incomplete in (A) and (B). (C) Left MLO digital mammogram view with retained silicone within the breast and hyperdense axillary lymph nodes. (D) Ultrasound image demonstrating left axillary lymph nodes with snow-storm appearance.

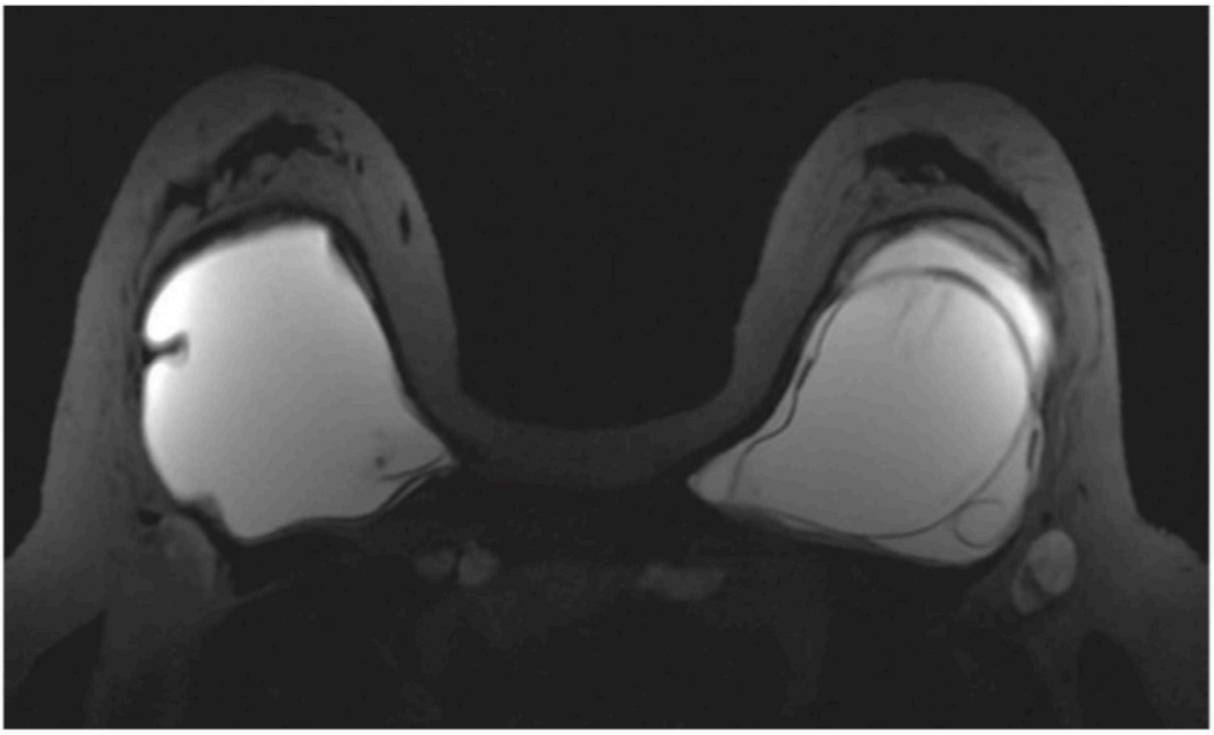

Figure 6 – EXTRACAPSULAR SILICONE: LYMPH NODES. Silicone in bilateral axillary and internal mammary lymph nodes. The left implant shows signs of intracapsular rupture. There is a subtle subcapsular line sign on the right, posteriorly. Fat- and water-suppressed silicone-specific image. *Note:* Fat suppression is incomplete.

J. IMPLANTS AND OTHER TYPES OF AUGMENTATION

6. FOCAL CONTOUR BULGE

The contour of an intact implant is usually smooth or has gentle undulations. However, intact implants may be distorted due to capsular contraction, which can cause a focal bulge in the implant contour.

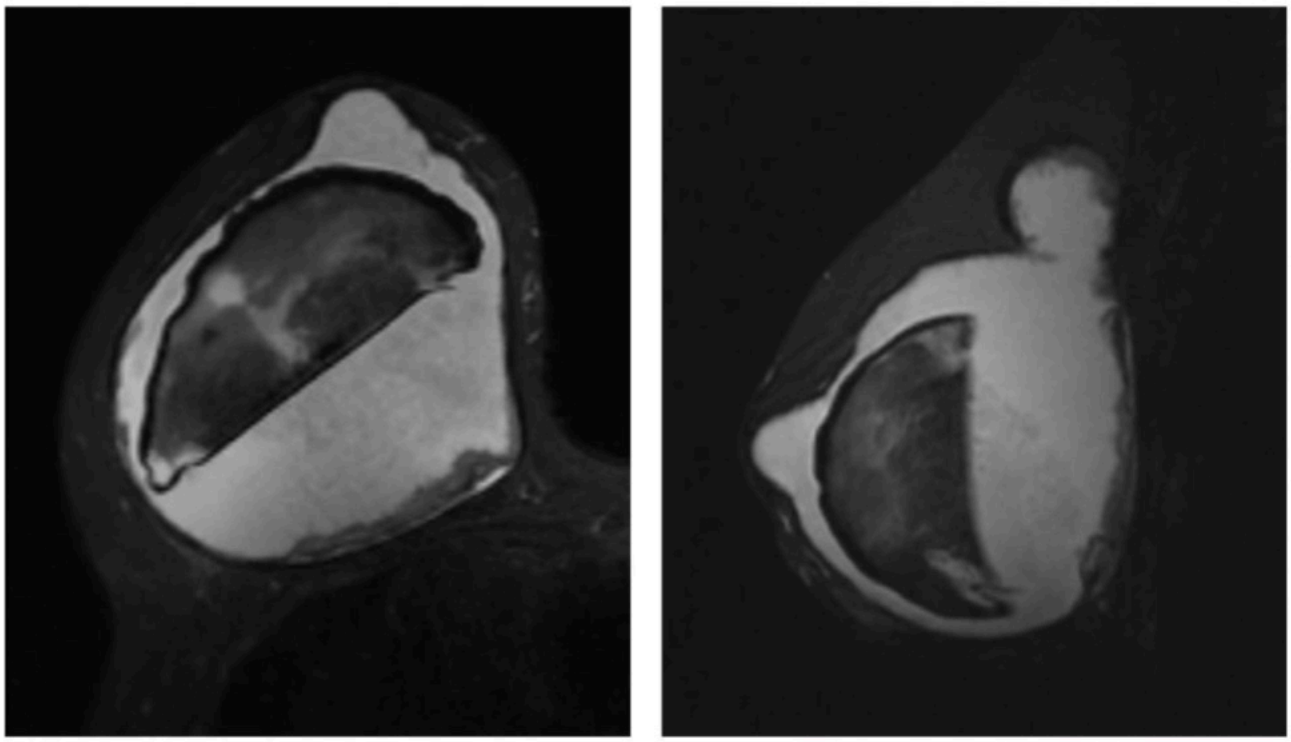

A B

Figure 1 – FOCAL CONTOUR BULGE. Focal bulge along the anterior and superior aspect of a double lumen implant with evidence of admixture. (A) Axial and (B) sagittal fat-suppressed T2W images.

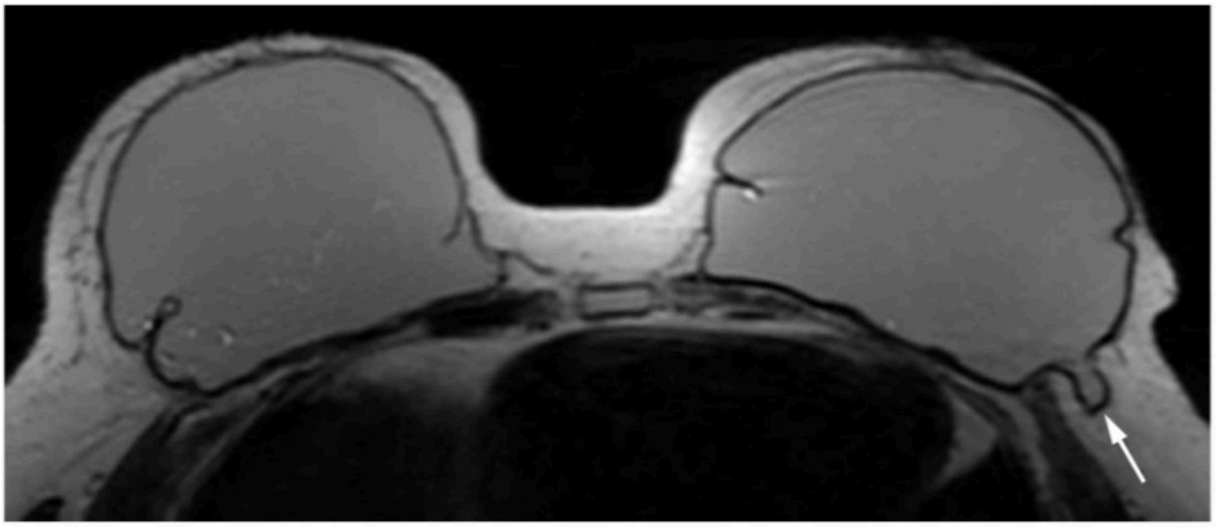

Figure 2 – FOCAL CONTOUR BULGE. Focal bulge along the lateral aspect of the left single lumen intact silicone implant (arrow). Non-fat-suppressed T2W image.

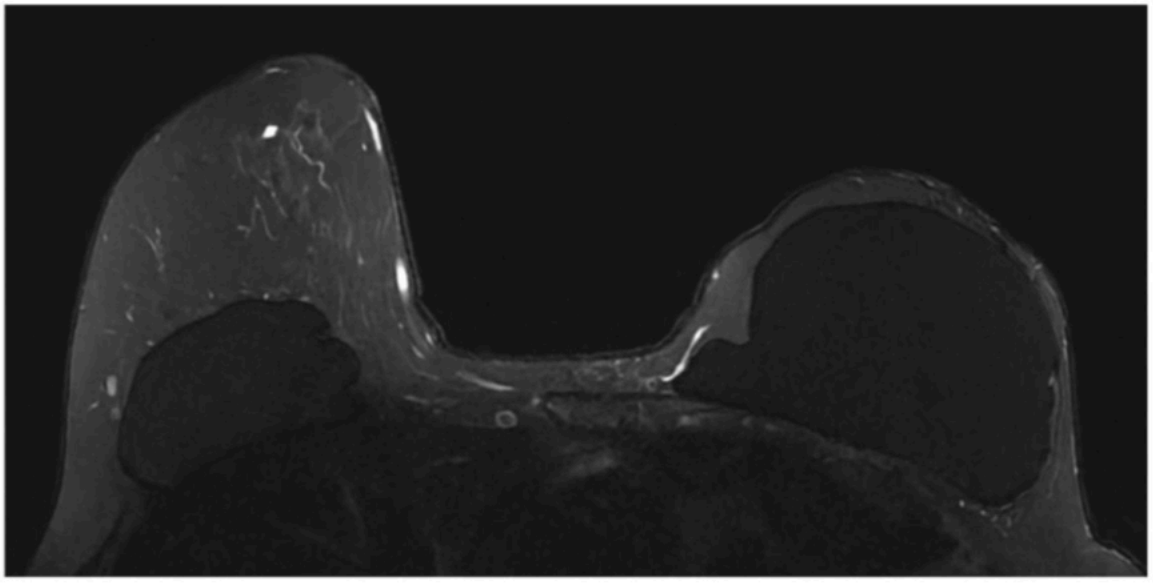

Figure 3 – FOCAL CONTOUR BULGE. Focal bulge along the medial aspect of the left single lumen intact silicone implant. Fat-and-silicone-suppressed T2W image.

J. IMPLANTS AND OTHER TYPES OF AUGMENTATION

7. PERI-IMPLANT FLUID

Peri-implant fluid is seen in the space between the implant shell and the capsule on water-specific sequences. A trace amount of peri-implant fluid or effusion around an implant is normal. More than a trace amount of peri-implant fluid can be due to infection, a benign effusion/seroma, or more rarely breast implant-associated anaplastic large cell lymphoma (BIA-ALCL), a non-Hodgkin lymphoma of T-cell origin. The factors that contribute to the development of BIA-ALCL are not fully elucidated but are felt to include chronic inflammation with subsequent malignant transformation of activated T cells. With the increasing use of breast implants, BIA-ALCL has emerged as a rare yet important diagnosis. BIA-ALCL most often presents with a delayed peri-implant effusion on imaging (considered suspicious if > 1 year after placement) but may also present with masses. In the absence of clinical signs and symptoms of infection or trauma, a delayed (> 1 year after placement) persistent peri-implant effusion should be regarded with suspicion and fine-needle aspiration or biopsy of peri-implant fluid collections and/or masses should be performed to evaluate for BIA-ALCL. Ultrasound is the primary imaging modality to further assess and sample suspicious peri-implant fluid detected on MRI.

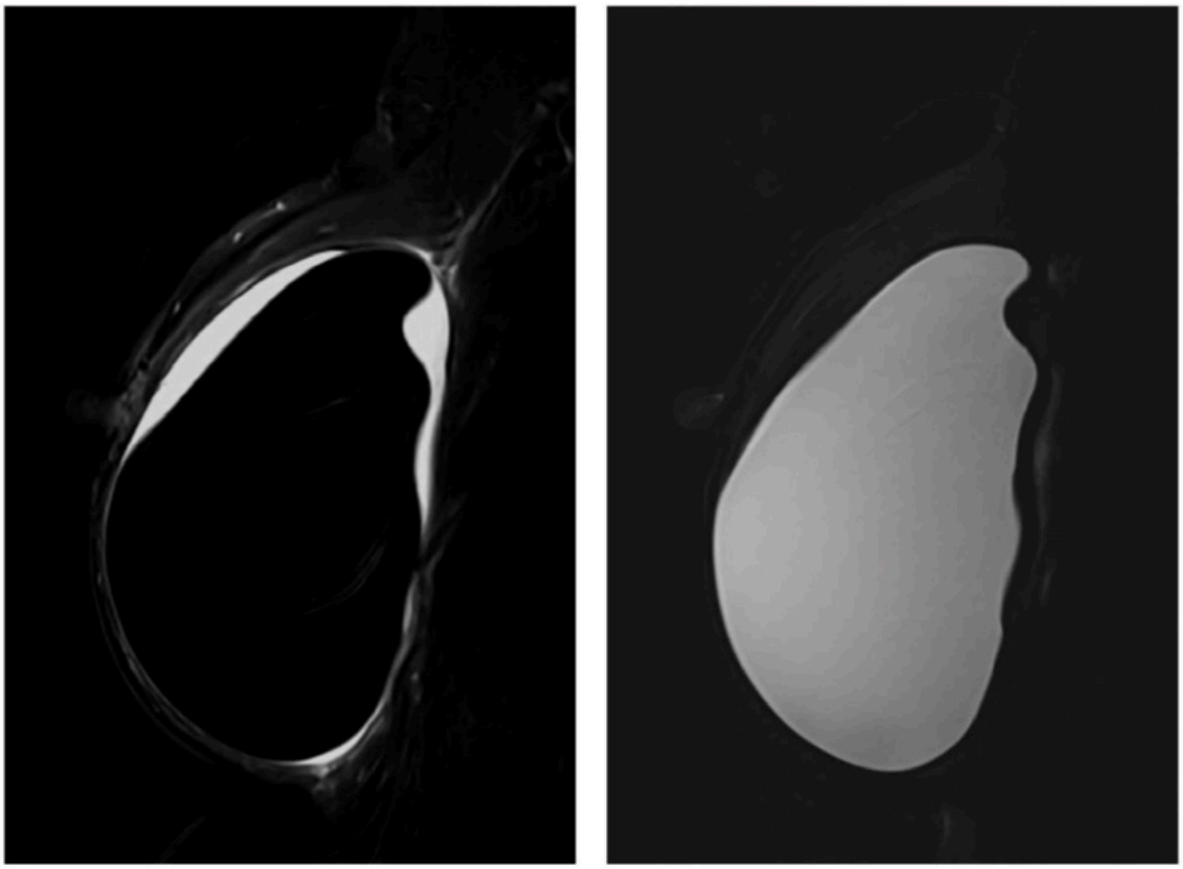

A B

Figure 1 – PERI-IMPLANT FLUID. (A) Fat- and silicone-suppressed T2W image. (B) Fat- and water-suppressed silicone-specific image. Pathology: Benign effusion.

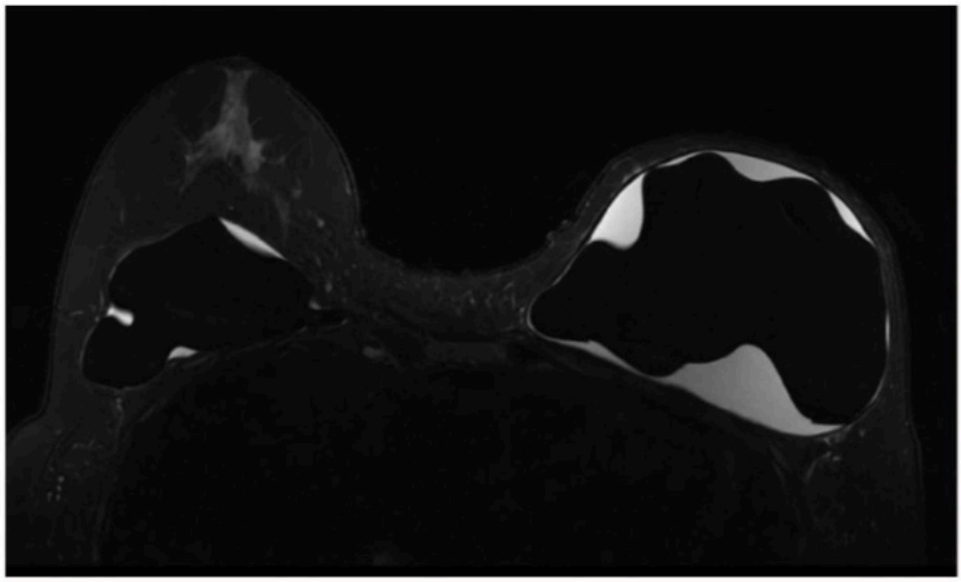

Figure 2 – PERI-IMPLANT FLUID. Bilateral peri-implant fluid, left greater than right, surrounding the silicone implants. Fat- and silicone-suppressed T2W image. Pathology: Benign on aspiration and subsequent capsulectomy.

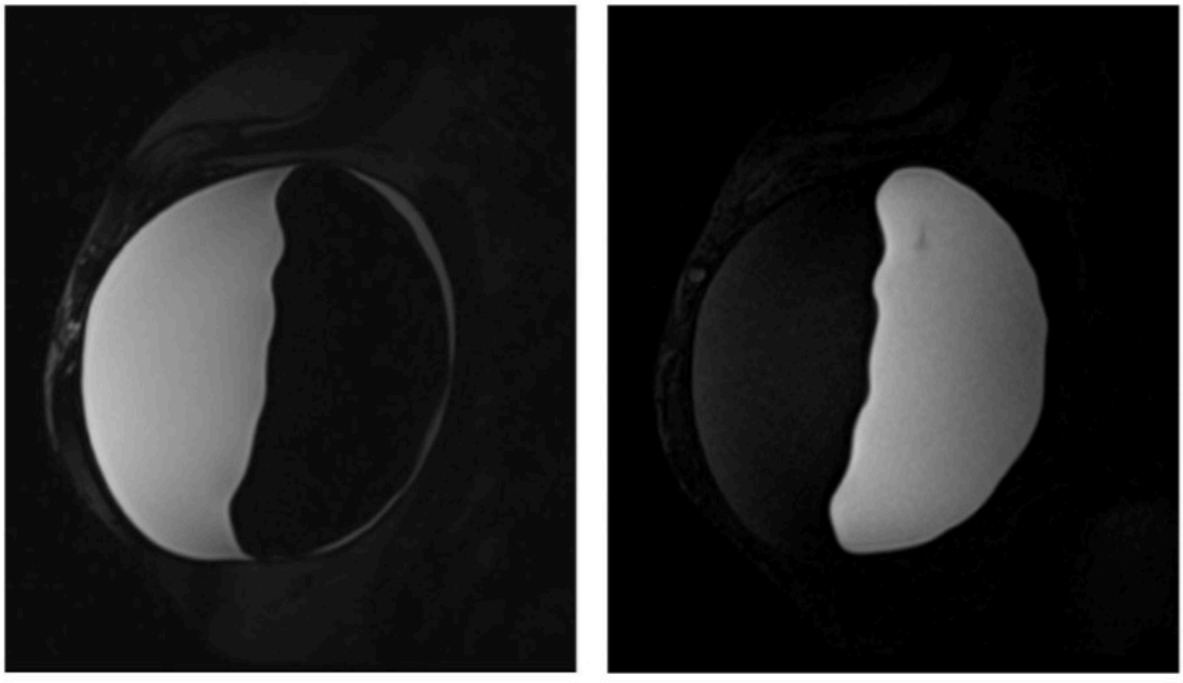

A B

Figure 3 – PERI-IMPLANT FLUID. (A) Fat- and silicone-suppressed T2W image. (B) Fat- and water-suppressed silicone-specific image. Pathology: Benign effusion.

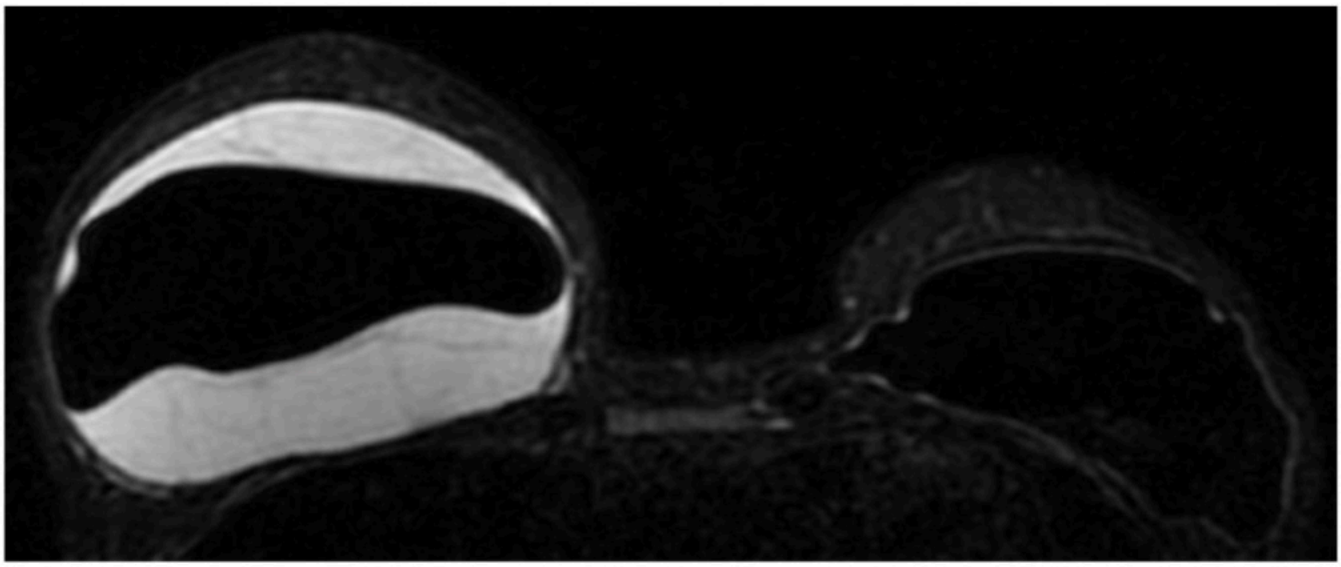

Figure 4 – PERI-IMPLANT FLUID. Large peri-implant fluid surrounding the right silicone implant. Fat-and-silicone-suppressed T2W image. Pathology: BIA-ALCL.

III. REPORTING SYSTEM

A. ASSESSMENT CATEGORIES

Table 2. BI-RADS® Assessment Categories and Concordant Management Recommendations

Assessment	Management	Likelihood of Cancer
Category 0: Incomplete: Need Additional Imaging Evaluation OR Category 0: Incomplete: Need Prior Imaging for Comparison	Recall for additional imaging Need comparison to prior examination(s)	N/A
Category 1: Negative	Routine breast screening, including MRI if appropriate according to major guidelines	Essentially 0% likelihood of malignancy
Category 2: Benign	Routine breast screening, including MRI if appropriate according to major guidelines	Essentially 0% likelihood of malignancy
Category 3: Probably Benign	Short-interval (6-month) follow-up or continued surveillance (12-month)	> 0% but ≤ 2% likelihood of malignancy
Category 4: Suspicious Category 4A: Low suspicion for malignancy Category 4B: Moderate suspicion for malignancy Category 4C: High suspicion for malignancy	Tissue diagnosis	> 2% but < 95% likelihood of malignancy > 2 to ≤ 10 > 10 to ≤ 50 > 50 to < 95
Category 5: Highly Suggestive of Malignancy	Tissue diagnosis	≥ 95% likelihood of malignancy
Category 6: Known Biopsy-Proven Malignancy	Clinical follow-up with surgeon and/or oncologist, and definitive local therapy (usually surgery) when clinically appropriate	N/A

At minimum, a single BI-RADS assessment category should be given for each breast MRI examination according to the highest order actionable assessment category, using the hierarchy of assessments 5 > 4 > 0 > 6 > 3 > 2/1. For example, an examination with a right breast biopsy-proven malignancy BI-RADS category 6 finding and also a left breast BI-RADS category 4 suspicious finding should be assigned an examination-level BI-RADS assessment category 4, since the suspicious category 4 finding is an immediately actionable item which supersedes the action for the biopsy-proven malignancy.

It is not required but can be very helpful to assign a separate BI-RADS assessment category for each breast, to more clearly distinguish between multiple findings and their assessments and management recommendations. When breast-level assessment categories are assigned, the same highest order actionable assessment category hierarchy of 5 > 4 > 0 > 6 > 3 > 2/1 should be used for each breast. For example, for an examination with a right breast biopsy-proven malignancy BI-RADS category 6 finding and also a right breast BI-RADS category 4 suspicious finding, and no left breast findings, the breast-level assessments are right breast assessment category 4 and left breast assessment category 1.

Further, it is not required but can be helpful to assign a separate BI-RADS assessment for each finding that is BI-RADS category 3 or higher, to even more clearly distinguish between multiple findings and their assessments and management recommendations.

Overall, including for auditing at the examination level, the breast MRI examination is coded according to the highest order BI-RADS assessment category across both breasts.

ASSESSMENT IS INCOMPLETE

Category 0: Need Additional Imaging Evaluation or Category 0: Need Prior Imaging for Comparison

Recent amendments to MQSA regulations, which took effect on Sept. 10, 2024, resulted in the creation of two new assessment categories for mammography under category 0 (replacing the previous combined descriptive verbiage of "Category 0: Incomplete: Need additional imaging evaluation and/or Prior for comparison"). The two new MQSA-required categories are: **Category 0: Incomplete: Need additional imaging evaluation**, used to indicate that the examination is incompletely evaluated, and the recommendation is for additional imaging evaluation (e.g., supplementary mammographic views and/or US); and **Category 0: Incomplete: Need prior mammograms for comparison**, to be used if retrieval of previous examinations for comparison is indicated before a final assessment can be rendered. For consistency, this updated verbiage has been generalized across the Manual for the other modalities. However, since prior studies desired for comparison may not be limited to mammograms, the terminology in the sections other than the Mammography chapter has been modified to say **Category 0: Incomplete: Need prior imaging for comparison.**

Category 0 is used to indicate that the breast is incompletely evaluated. The use of category 0 should be rare for breast MRI, because there is typically enough information from the MRI examination alone for appropriate interpretation including characterization and assessment of findings.

The infrequent use of category 0 should be limited to the following three scenarios:

1) *Additional imaging is needed for further characterization of breast MRI findings, typically with mammography and/or ultrasound.*

   This application should be reserved for particular MRI findings which appear highly likely but not definitively specific benign entities, for which further imaging is needed for characterization to confirm suspected benign etiology. One example is an MRI mass that appears likely but not definitively a lymph node for which ultrasound is needed for complete characterization

(although most lymph nodes will be fully characterized by the MRI alone and not warrant additional imaging). Another example is an area of MRI enhancement which appears likely but not definitively fat necrosis for which mammography is needed for complete characterization (although most fat necrosis will be fully characterized by the MRI alone and not warrant additional imaging).

When category 0 is used for this scenario, the recommendation should be **Need additional imaging evaluation**. The report should also include the type of recommended imaging, and contingency assessment and management recommendations for if the MRI findings cannot be found or better characterized by additional imaging. For example, a report describing an MRI mass that is likely but not definitively a lymph node with assessment category 0 and recommendation for ultrasound should include a contingency assessment and recommendation based on the MRI appearance and level of suspicion for if the finding cannot be found or better characterized with ultrasound.

Category 0 should not be used when findings are sufficiently characterized by MRI and additional imaging is being recommended for detection to guide follow-up or biopsy. For example, a finding that has probably benign MRI features should be assessed as category 3, even if additional imaging with ultrasound is recommended to detect the findings to facilitate ultrasound rather than MRI follow-up. A finding that has suspicious or highly suggestive MRI features should be assessed as category 4 or 5, even if additional imaging with ultrasound is recommended to detect the findings to facilitate ultrasound biopsy.

2) *Comparison with prior imaging studies is needed to interpret the breast MRI examination.*

Correlation with prior breast imaging studies can be important for interpretation. However, comparison to prior breast imaging studies is not required for all breast MRI examinations, since the MRI examinations alone are most often sufficient for interpretation including characterization and assessment of findings. Comparison to priors is warranted when the radiologist believes that evaluating features or stability on prior studies is necessary to fully characterize MRI findings. Importantly, for the clinical indication of current breast cancer, the MRI should be interpreted with direct correlation to the prior imaging related to the cancer diagnosis whenever possible, and the MRI report should specifically include the location and size of the current cancer on prior imaging. When category 0 is used for this scenario, the recommendation should be **Need prior imaging for comparison.**

3) *Additional imaging is needed due to a technically inadequate breast MRI.*

For example, an intended contrast-enhanced MRI for contrast was not successfully administered should be designated category 0, and the recommendation should be for repeat breast MRI for technical reasons.

ASSESSMENT IS COMPLETE — FINAL ASSESSMENT CATEGORIES

Category 1: Negative

There are no significant findings to report. This is a normal examination. There is no evidence of malignancy.

Category 2: Benign

There are benign findings felt sufficiently significant to report. There is no evidence of malignancy.

Benign reported findings may include evidence of prior surgeries, biopsy markers, enhancing findings assessed as benign, and breast implants. Not all benign findings need to be reported. For example, high T1 duct signal and cysts do not need to be routinely described.

Category 3: Probably Benign

Category 3 findings have a > 0 to ≤ 2% likelihood of cancer. As for mammography and ultrasound, the goal of use of category 3 is to decrease the number of false positive recommendations for biopsy made for findings with very low probabilities of cancer, using imaging follow-up to identify the small subset of those findings that are malignant while at an early stage.

Unlike mammography, there are no large prospective studies of breast MRI category 3 malignancy rates, findings types and frequencies of use. Multiple predominantly single site retrospective studies of breast MRI category 3 have been published, as has a systematic review and metanalysis of studies through June, 2016 [15]. Due to methods including mostly single site retrospective designs, heterogeneous populations and clinical indications, and evaluation of imaging findings limited to individual lesion types and features, data to guide appropriate use of breast MRI category 3 remain limited. However, overall there is evidence that category 3 can be employed in breast MRI practice with malignancy rates in the appropriate ≤ 2% range.

Given the current heterogeneity of use and outcomes of breast MRI category 3, it is particularly important that category 3 performance audit metrics be regularly reviewed to ensure that practices are within acceptable parameters.

Category 3 Malignancy Rates

While an early study from nearly 20 years ago showed a category 3 malignancy rate of approximately 24% [16], multiple subsequent studies demonstrated category 3 malignancy rates ranging from 0% to 6% [4, 17–30], with frequencies in most studies ≤ 2% and a metanalysis pooled frequency of 1.6% [15]. These studies indicate that despite heterogeneity of use across patients, clinical indications and findings, category 3 can be employed in practice with malignancy rates in the appropriate ≤ 2% range.

Caution should be used when considering category 3 for findings on non-baseline examinations, since one study showed that the category 3 malignancy rate was 2% in baseline examinations but 9% in the non-baseline setting [19].

Also, there are sparse data regarding the stage of diagnosis for the subset of category 3 findings that prove to be malignant, with some evidence confirming that early stage at diagnosis is still achievable [19]. Further studies are needed to confirm the early-stage diagnoses for BI-RADS category 3 findings that are found to be malignant.

Category 3 Imaging Findings Types and Features

Studies have typically evaluated category 3 findings' individual features, and no individual feature such as finding type or other descriptor has been shown to confer a likelihood of malignancy ≤ 2% [4, 6, 15, 21, 31, 32]. In practice, combinations of features are used in assessment. In the absence of robust data for combinations of features, guidance regarding the specific imaging findings appropriate to place in category 3 remains limited.

In general, mass individual features most frequently associated with benignity include oval shape, circumscribed margin, homogeneous or dark internal septations, T2 hyperintensity, and persistent delayed-phase kinetics. None of these features alone is sufficient to assign category 3 [6], as cancers can present with these individual features, including T2 hyperintensity [33].

In general, non-mass individual features most frequently associated with benignity include focal or regional distribution and homogeneous internal enhancement. None of these features alone is sufficient to assign category 3, as cancers can present with these individual features.

Of note, non-mass enhancement which is slightly unique but associated with adjacent cysts is typically benign [34].

Based on the existing data [6] and expert practice, a mass that is oval and circumscribed and has homogeneous internal enhancement or dark internal septations and is T2 hyperintense has a likelihood of cancer ≤ 2% and could be assessed as at most category 3. The use of category 3 for other MRI findings types should be infrequent and remains based on individual and practice experience.

BPE is present on many breast MRI examinations and is normal finding. Radiologists should be familiar with the variety of patterns that are normal including asymmetric BPE. Rarely, there may be enhancement that is almost certainly but not definitely asymmetric BPE, for which a category 3 assessment could be considered.

Category 3 Frequency of Use

The desirable goal for the frequency of use of breast MRI category 3 is ≤ 5% of examinations. Use of category 3 in ≤ 5% of examinations has been shown to be achievable in practice [17–19, 22, 35]. While some studies, particularly from 15–20 years ago, showed category 3 use rates as high as 20–24% [16, 27, 36], multiple more recent studies across patient populations and clinical indications have demonstrated lower category 3 frequencies ranging from 3% to 14%, with most in the 5% to10% range [19, 37, 38] [4, 17–19, 21, 22, 24–26, 28–30, 35, 37–40]. The more recent lower use rates are likely due to multiple factors such as improved techniques, greater radiologist experience including recognition of BPE patterns, and presence of comparison MRI examinations [36].

Category 3 Timing of Follow-Up

As for mammography and ultrasound, follow-up should be recommended to occur at 6, 12 and 24 months. Findings that decrease or resolve or are interpreted as benign by a more experienced reader at 6 or 12 months should be assessed as category 2 with no additional recommended follow-up. Findings that remain present and stable with probably benign appearance should be assessed at 6 and 12 months as category 3 and at 24 months as category 2. An increase, progression or otherwise more suspicious appearance of category 3 findings at follow-up should prompt a category 4 or 5 assessment based on the imaging findings and a recommendation for tissue sampling. Follow-up at each interval is important, as malignancies have been demonstrated as early as 6 months [4, 15, 18, 19] and as late as 24 months [15].

Category 3 Use in Current Breast Cancer

Overall, category 3 should be avoided for findings in the ipsilateral or contralateral breast on MRI examinations in the setting of current breast cancer. Breast MRI findings which might be assessed as category 3 in other clinical scenarios should be assigned category 4A in the setting of current breast cancer. This is because the goal of breast MRI for current cancer is to establish the extent of malignancy in the near-term to guide management decisions. A category 3 assessment with a short interval follow-up recommendation does not result in near-term tissue diagnosis to establish the extent of disease. Only very rarely, category 3 could be used in the current cancer setting based on particular patient or imaging considerations.

Category 4: Suspicious

Category 4 findings are suspicious but not highly suggestive of breast cancer and have a > 2 to < 95% chance of malignancy. A category 4 assessment is used for the vast majority of findings for which tissue diagnosis is recommended.

Use of category 4 subdivisions of 4A, 4B and 4C which has been optional for mammography and ultrasound is now also optional for breast MRI. Use of the subdivisions for MRI has been shown to result in probabilities of malignancy in the established cut-point ranges [41]. Placement of findings into subdivisions allows for a more meaningful practice audit, is useful in research, and aids patients, referring providers and pathologists in understanding the relative degree of suspicion. Future research to clarify which types of MRI findings may be appropriately placed in each subdivision will be important. Currently, the types of MRI findings to place in each category 4 subdivision are based on individual and practice experience.

- Category 4A should be used for findings with a low suspicion for malignancy, estimated to be > 2 to $\leq 10\%$.
- Category 4B should be used for findings with a moderate suspicion for malignancy, estimated to be > 10 to $\leq 50\%$.
- Category 4C should be used for findings with a high suspicion for malignancy, estimated to be > 50 to $< 95\%$. A finding in this category is very suspicious but not classic for breast cancer.

The concordant management recommendation for category 4 findings is tissue diagnosis.

The method of recommended tissue diagnosis and contingencies should be included in the report. For example, if the radiologist believes that ultrasound should be used to attempt to detect the findings for biopsy, appropriate recommendation wording could be: "Recommend tissue diagnosis. Specifically, recommend targeted ultrasound and ultrasound-guided biopsy. If there is no ultrasound correlate, recommend MRI-guided biopsy." If it is felt that the findings should go directly to MRI biopsy, appropriate wording could be: "Recommend tissue diagnosis. Specifically, recommend MRI-guided biopsy, as ultrasound is unlikely to demonstrate a correlate."

Category 5: Highly Suggestive of Malignancy

Category 5 findings are highly suggestive of breast cancer and have a $\geq 95\%$ chance of malignancy. Almost all nonmalignant percutaneous sampling diagnoses are considered discordant for category 5, resulting in recommendations for repeat (often surgical) biopsies.

No individual features such as finding type or other descriptor confer likelihoods of malignancy $\geq 95\%$. The features with the highest likelihoods of cancer include mass spiculated margin and non-mass linear or segmental enhancement [32]. As for mammography and ultrasound, combinations of suspicious imaging findings are required to justify a category 5 assessment. Caution should be taken using category 5 for non-mass enhancement as a variety of non-malignant entities can present with suspicious non-mass features.

The concordant management recommendation for category 5 findings is tissue diagnosis. Percutaneous tissue diagnosis remains the standard of care for suspicious including for category 5 findings, as establishing a malignant diagnosis prior to surgery has important treatment planning benefits.

The method of recommended tissue diagnosis and contingencies should be included in the report. For example, if the radiologist believes that ultrasound should be used to attempt to detect the findings for biopsy, appropriate recommendation wording could be: "Recommend tissue diagnosis. Specifically, recommend targeted ultrasound and ultrasound-guided biopsy. If there is no ultrasound correlate, recommend MRI-guided biopsy." If it is felt that the findings should go directly to MRI biopsy, appropriate wording could be: "Recommend tissue diagnosis. Specifically, recommend MRI-guided biopsy, as ultrasound is unlikely to demonstrate a correlate."

Category 6: Known Biopsy-Proven Malignancy

Category 6 is used for known biopsy-proven malignancy prior to definitive local therapy (usually surgery but could include other local treatments considered to be definitive by the multidisciplinary team), including when there is no enhancement at the known malignancy site.

Category 6 should be used prior to definitive therapy for enhancing findings that are biopsy-proven malignancy, particularly when correlated with the comparison imaging. It should also be used for more extensive than expected enhancing findings for which there is a high certainty of malignancy, typically because the findings are the same morphology and potentially contiguous with the index cancer. Category 6 may also be used for separate additional close findings (ACFs) that are suspicious but not definitively malignancy. Further guidance for what to categorize as category 6 vs. separately as category 4 or 5 is discussed below.

Category 6 should also be used prior to surgery to describe the site of biopsy-proven malignancy when there are no enhancing findings or only benign-appearing findings. For example, after biopsy prior to surgery there may be only a marker at the malignancy site, because the findings were completely removed at biopsy or because the malignancy is not detectible by MRI. After neoadjuvant systemic therapy prior to surgery, if there has been a complete MRI response, there may be only a marker at the malignancy site, because there is no residual malignancy or because the residual malignancy is not detectible by MRI. Category 6 should be used in all of these circumstances since the clinical standard of care for local therapy remains surgical removal and the negative predictive value of MRI for each of these circumstances is insufficient to avoid surgery.

When breast MRI is performed in the immediate postoperative period after surgery including with positive margins, the assessment category should be based on the imaging appearance. If there are enhancing findings that are definitively residual biopsy-proven malignancy the appropriate assessment is category 6. If there are enhancing findings that are suspicious but not definitively malignancy particularly when not at the surgical site the appropriate assessment is category 4 or 5. If there are enhancing findings that are benign including thin enhancement of a seroma or otherwise minimal enhancement at the surgical site the appropriate assessment is category 2.

Category 6 and Additional Findings

Category 6 should be used for enhancing findings that are definitively the biopsy-proven malignancy based on correlation with the comparison imaging. It should also be used for more extensive enhancing findings for which there is a high certainty of malignancy, typically because they have the same morphology as the biopsy-proven malignancy.

Category 6 may also be used for separate additional close findings (ACFs) that are suspicious but not definitively malignancy when all of the following criteria are met: 1) They are within 2 cm of the biopsy-proven malignancy, 2) They do not increase the total extent by more than 2 cm, and 3) It is felt they would not change clinical management such as prompting a significantly larger surgery. Whether such findings would impact management will be influenced by multiple factors including extent of the known breast cancer and preferences and patterns in a particular practice. The ACFs should be fully reported including sizes and relationships relative to the biopsy-proven malignancy. The term "satellite" should not be used for such findings, as it is not sufficiently defined including the level of concern for malignancy and proximity to the primary malignancy.

Other separate suspicious breast findings that do not meet the criteria (high certainty of malignancy or ACF) in the two paragraphs above should typically be given a separate assessment of category 0, 4 or 5, as appropriate based on their appearances.

Reporting Category 6 and Additional Findings

The biopsy-proven malignancy findings should be fully described.

Additional significant actionable findings should be clearly described as separate from the current cancer and be given appropriate assessments and management recommendations. For category 4 or 5 findings, the management recommendation is tissue diagnosis. Practices may wish to add "if it would impact clinical management" to the tissue diagnosis recommendation, because in patients with breast cancer the need for additional biopsies will depend on the treatment plan. For example, if mastectomy is planned, additional ipsilateral biopsies are not typically warranted.

At minimum, a separate assessment category should be given for each breast MRI examination, according to the highest order actionable BI-RADS assessment category, using the hierarchy of assessments 5 > 4 > 0 > 6 > 3 > 2/1.

Therefore, in patients with current breast cancer, higher order additional actionable findings with assessments of category 0, 4 and 5 supersede category 6 findings, because they warrant immediate action.

It is not required but can be helpful to assign a separate BI-RADS assessment for each finding that is BI-RADS category 3 or higher, to clearly distinguish between multiple findings and their assessment and management.

Abnormal-appearing ipsilateral axillary lymph nodes in the setting of known malignancy should be fully described, but they should not be given a separate BI-RADS assessment. Management of lymphadenopathy often depends on multiple clinical factors and preferences. Abnormal-appearing axillary lymph nodes that are contralateral to a known malignancy with no findings suspicious for malignancy in that breast should be given a BI-RADS assessment based on the level of suspicion for lymph node malignancy.

Example Reporting

For a patient with biopsy-proven malignancy in the right breast with an additional ipsilateral suspicious breast finding that is category 4B, and no contralateral findings, the finding-level descriptions, assessments and recommendations would be:

Right breast:

1) In the right breast at 12 o'clock middle depth, 7 cm from the nipple, there is an irregular mass with a spiculated margin and thick rim internal enhancement. The size is 3.4 cm AP × 1.0 cm RL × 2.6 cm SI. BI-RADS category 6: Known biopsy-proven malignancy. Recommend clinical follow-up with surgeon and/or oncologist, and definitive local therapy when clinically appropriate.

2) In the right breast at 4 o'clock anterior depth, 2 cm from the nipple, there is an oval mass with an indistinct margin and heterogeneous internal enhancement. The size is 1.2 cm AP × 1.0 cm RL × 0.9 cm SI. This mass is 5 cm inferior to the biopsy-proven malignancy. BI-RADS category 4, suspicious. 4B: Intermediate suspicion for malignancy. Recommend tissue diagnosis. Specifically, recommend targeted ultrasound and ultrasound-guided biopsy. If there is no ultrasound correlate, recommend MRI-guided biopsy.

Left breast:

Category 1: No evidence of malignancy. Recommend routine breast screening, including MRI if appropriate according to guidelines.

Overall, each breast is coded according to the highest order actionable BI-RADS assessment category for that breast. In this example, the overall right breast assessment is category 4B, and the overall left breast assessment is category 1. Overall, the examination is coded according to the highest order BI-RADS assessment category across both breasts. In this example, the overall examination is coded category 4B.

As described in the Auditing and Outcomes Monitoring section, examinations with a category 6 as highest order actionable assessment should not be counted as additional cancers in breast imaging audits. Because the diagnosis of malignancy already has been established, inclusion of these cases would skew the data for many performance parameters.

Ultrasound For Suspicious Breast MRI Findings

When additional imaging with ultrasound is recommended for breast MRI findings, the term "second-look" ultrasound should be avoided, as it implies that a "first-look" ultrasound has been performed. The terms "targeted," "MRI-targeted," "directed," or "MRI-directed" ultrasound should be used.

For suspicious MRI findings, the decision to initially recommend ultrasound and ultrasound-guided tissue sampling rather than immediately recommending MRI-guided tissue sampling should be based on the published likelihoods of ultrasound detection for particular MRI findings, the potential challenges to MRI-guided sampling, and practice considerations such as access time for MRI-guided procedures.

A systematic review and metanalysis showed that the overall rate of ultrasound detection of MRI findings was heterogeneous across studies, ranging from 23% to 82%, with a pooled rate of 58% [42]. Detection was more frequent for masses with a pooled detection rate of 66% than for NME with a pooled rate of 29%. Study results regarding the impact of findings sizes on detection rates have been mixed. Based on the relatively low NME detection rate it is particularly reasonable to immediately recommend MRI-guided tissue sampling for NME.

For findings that would be challenging to sample using MRI due to location or the presence of breast implants, there should be a lower threshold for initially recommending ultrasound and ultrasound-guided tissue sampling.

Ultrasound findings should definitively correlate to the MRI findings in order to undergo ultrasound-guided tissue sampling, unless there are no or limited options for MRI sampling. This is important to avoid a falsely reassuring negative ultrasound biopsy of the incorrect location.

B. REPORT ORGANIZATION

The report should be concise and organized using the following wording and organization:

Table 3. Report Organization

1.	Indication for examination
2.	Comparison to previous examination(s)
3.	Acquisition parameters
4.	Amount of fibroglandular tissue (FGT)
5.	Level of background parenchymal enhancement (BPE)
6.	Clear description of any important findings
7.	Assessment
8.	Management recommendations

1. INDICATION FOR EXAMINATION

As for mammography and ultrasound, the goal of breast MRI interpretation is to answer the primary clinical question raised by the indication or reason for the examination. The clinical indication for the breast MRI should be understood and reported when interpreting the examination.

New to this version of BI-RADS are structured categories for the major clinical indications for breast imaging, with associated optional subcategories and relevant clinical histories. These structured categories should be used for breast MRI reporting and also for mammography, CEM, and ultrasound reporting. Use of these structured indications has many benefits, including to facilitate auditing of outcomes according to the different major indication categories of screening versus non-screening examinations, which have different diagnostic performance outcomes.

The breast MRI report history or indication section should specify the major clinical indication in one of the three new categorical indications of 1) Asymptomatic Screening, 2) Diagnostic: Work-Up, or 3) Diagnostic: Current Breast Cancer. The indication of Asymptomatic Screening should only be used in patients who are asymptomatic with no current clinical or imaging findings or current breast cancer.

When possible, the breast MRI report history or indication section should also include the optional subcategory indication, such as for Asymptomatic Screening the subcategory Gene Mutation, or for Diagnostic: Current Breast Cancer the subcategory Extent of Disease Before Definitive Surgery.

In addition, the relevant clinical history that could significantly influence MRI interpretation should be reported. Depending upon the indication, relevant history may include estimated breast cancer risk and/or specific risk factors, the current clinical or imaging findings. For the indication of Diagnostic: Current Breast Cancer, it is very important to understand the location and size of the current cancer on prior imaging, and it is helpful to include this history or indication section of the MRI report. Hormone-related or -influencing scenarios such as a recent pregnancy, lactation, menstrual cycle phase, and/or use of hormone replacement or antiestrogen therapy should in general be reported when they are important in explaining the MRI findings on a particular examination, such as "rebound" background parenchymal enhancement after cessation of antiestrogen therapy.

Table 4. Structured Exam Indications

Major Indication	Optional Subcategory Indication	Relevant History to Report, if known
Asymptomatic Screening	• Elevated risk • Dense breasts • Prior breast cancer, treatment completed • Other	• Gene mutation • Estimated cancer risk • Prior breast cancer history
Diagnostic Work-up	• Clinical findings • Imaging findings • Follow-up category 3 • Follow-up after biopsy • Implant assessment • Other	• Clinical finding type • Imaging finding type
Diagnostic: Current Breast Cancer	• Extent of disease before treatment/therapy • Response during or after neoadjuvant therapy • Other	• Location and size of cancer on prior imaging evaluation

2. COMPARISON TO PREVIOUS EXAMINATION(S)

   Across breast imaging modalities, comparison and correlation with prior breast imaging studies can be important for interpretation. For breast MRI, comparison and correlation to prior beast imaging studies may not be needed for all examinations since the MRI features on the current examination alone are often sufficient for appropriate assessments and recommendations. Comparison is warranted when the radiologist believes evaluating stability or features on other imaging is necessary to fully assess the MRI findings. In particular, for the clinical indication of Diagnostic: Current Breast Cancer, comparison should be made to the prior imaging studies that lead to the cancer diagnosis and/or that last assessed the current cancer whenever possible. It is recommended that the dates of the comparison imaging studies be reported.

3. ACQUISITION PARAMETERS

   Breast MRI reports should describe the key acquisition techniques, including the field strength and pulse sequences utilized. Contrast enhanced exams should include the dose and type of gadolinium contrast agent and the details of contrast injection. Temporal resolution (including any delay after contrast administration, number and length of post-contrast sequences) should be reported for dynamic contrast enhanced (DCE) series. When utilized, CAE of kinetics or other post-processing techniques should also be described. Since most parameters will remain constant, standardized language for MRI techniques can be used in the reports. Finally, significant imaging artifacts such as from patient motion, susceptibility artifacts, fat suppression failure/inhomogeneity, and suboptimal contrast injection should be described.

4. AMOUNT OF FIBROGLANDULAR TISSUE (FGT)

   The amount of FGT should be reported in one of four categories:

   A. Almost entirely fatty

   B. Scattered fibroglandular tissue

   C. Heterogeneous fibroglandular tissue

   D. Extreme fibroglandular tissue

5. LEVEL OF BACKGROUND PARENCHYMAL ENHANCEMENT (BPE)

   The BPE level should be reported in one of four categories:

   a) minimal (includes no enhancement)

   b) mild

   c) moderate

   d) marked

6. CLEAR DESCRIPTION OF ANY IMPORTANT FINDINGS

   The report should be succinct, using terminology from the latest approved lexicon without embellishment. Definitions of lexicon terms for findings should not appear in the report narrative.

7. ASSESSMENT (ALSO REFER TO SECTION IIIA)

   Within or following the impression section of the report, the BI-RADS assessment category number(s) and wording should be stated (example: Assessment category 4B, Suspicious. Intermediate Suspicion for Malignancy).

8. MANAGEMENT RECOMMENDATIONS

BI-RADS assessment categories are designed to be paired with concordant specific management recommendations. The linking of assessment categories with concordant management recommendations further enhances sound medical practice. In some settings, a discordant management recommendation may be appropriate, related to unique clinical circumstances. An explanation of the discordant recommendation added to the report can provide nuanced guidance in these situations.

C. WORDING OF REPORT

The structured clinical indication for the examination should be stated. Comparison to prior examination(s) should be reported including the dates of the prior studies.

The report should be organized with a brief description of the breast MRI tissue properties and any pertinent findings, followed by the assessment and management recommendations.

The report should be succinct, using terminology from the latest approved lexicon without embellishment. Definitions of lexicon terms for findings should not appear in the report narrative. Within or following the impression section of the report, the BI-RADS assessment category number(s) and wording should be stated (example: Assessment category 4B, Suspicious. Intermediate Suspicion for Malignancy). Any discussions between the interpreting physician and the referring clinician or patient should be documented in the original report or in an addendum to the report.

IV. GUIDANCE

MAJOR UPDATES COMPARED TO THE PRIOR EDITION

ACQUISITION PARAMETERS:

The name of post-contrast series obtained at approximately 60–120 seconds after administration of contrast was changed from "initial" to "early", because newer protocols may include "initial" ultrafast post-contrast series before the early timepoint.

LEXICON:

The Lexicon structure was updated, and there are multiple updated descriptors and sections.

The term focus has been removed from the lexicon for multiple reasons. Most small dots of enhancement are benign and should appropriately be dismissed as benign. Further, for a truly unique enhancing finding ≤ 5 mm in size, modern MRI techniques should allow characterization as a small mass (meets criteria/features of a mass) or focal NME (does not meet criteria/features of a mass). There has also been inconsistent understanding and use of the term focus in clinical practice and in the literature. Future research should investigate the predictive morphologic and kinetic features of such small masses and NME, optimally in multi-site prospective studies.

The mass margin previously "irregular" was changed to indistinct for better harmonization with the mammography and ultrasound mass margin descriptors and to avoid confusion with its use as a shape descriptor as well.

The new mass descriptor of T2 signal intensity was added. Based on expert opinion and existing data, a T2 hyperintense mass that is also oval and circumscribed and demonstrates homogeneous internal enhancement or dark internal septations has a low probability of malignancy of ≤ 2% [6]. Therefore, T2 signal intensity should be assessed and specifically reported when it influences assessments and recommendations.

The new associated feature of peritumoral edema was added. This is hyperintense T2 signal in the tissue surrounding a malignant or suspicious finding. It may suggest a malignant etiology of the finding, and for extensive malignancies is associated with an increased risk of lymph node metastases [12]. However, this finding can also be present as post-biopsy change or due to other benign etiologies.

Regional lymph nodes when abnormal were previously categorized as an associated feature ("lymphadenopathy). Due to the importance of detailed description of abnormal lymph nodes, "lymph nodes" was added as separate category across modalities. For breast MRI, the nodes to be assessed are those which are routinely seen on breast MRI, which are the intramammary, axillary, and internal mammary lymph nodes.

REPORTING SYSTEM

A thorough review was made of the literature related to category 3. Based on the literature, despite heterogeneity of use across patients, clinical indications and findings, category 3 can be employed in practice with malignancy rates in the appropriate ≤ 2% range. However, caution should be used when considering category 3 for findings on non-baseline examinations, since one study showed that the category 3 malignancy rate was 2% in baseline examinations but 9% in the non-baseline setting [19]. Based on the existing data and expert practice, a mass that is oval and circumscribed and has

homogeneous internal enhancement or dark internal septations and is T2 hyperintense has a likelihood of cancer ≤ 2% and could be assessed as at most category 3. The use of category 3 for other MRI findings types should be infrequent and remains based on individual and practice experience. In addition, it is now specified across modalities that in the setting of examinations obtained for current breast cancer, imaging findings which might be assessed as category 3 in other clinical scenarios should be assigned category 4A. This is because the goal of breast MRI for current cancer is to establish the extent of malignancy in the near-term to guide management decisions.

General concepts were included to provide guidance and consistency distinguishing category 6 from additional suspicious findings. Category 6 should be used for enhancing findings that are definitively the biopsy-proven malignancy based on correlation with the comparison imaging. It should also be used for enhancing findings that are more extensive than expected on correlative studies but for which there is a high certainty of malignancy, typically because they are contiguous with or the same morphology as the biopsy-proven malignancy. Category 6 may also be used for separate additional close findings (ACFs) that are suspicious but not definitively malignancy when all of the following criteria are met: 1) They are within 2 cm of the biopsy-proven malignancy, 2) They do not increase the total extent by more than 2 cm, and 3) It is felt they would not change clinical management such as prompting a significantly larger surgery. Whether such findings would impact management will be influenced by multiple factors including extent of the known breast cancer and preferences and patterns in a particular practice. The ACFs should be fully reported including sizes and relationships relative to the biopsy-proven malignancy. The term “satellite” should not be used for such findings, as it is not sufficiently defined including level of concern for malignancy and proximity to the primary malignancy. Other separate suspicious breast findings that do not meet the criteria (high certainty of malignancy or ACF) above should typically be given a separate assessment of category 0, 4 or 5, as appropriate based on their appearances.

V. FREQUENTLY ASKED QUESTIONS

1. ***Do the FDA mammography regulations require that BI-RADS categories be assigned to MRI examinations?***

   No, the FDA mammography regulations do not apply to breast MRI. However, the ACR recommends using BI-RADS assessment categories for breast MRI examinations.

2. ***What assessment category should be used for a non-contrast breast MRI examination for implant assessment? Should such exams be audited as TP, FP, TN, or FN?***

   BI-RADS assessment categories are used to reflect likelihoods of breast cancer. At this time, detection of breast cancer required the use of contrast. Therefore, an examination intentionally performed with no contrast for implant assessment is not assigned assessment categories and is not included in the outcomes audit. Occasionally, a breast MRI for cancer detection will not have contrast administered due to patient or technical issues. For this scenario, the appropriate assessment would be Category 0: Incomplete: Need additional imaging evaluation for a technically inadequate examination.

APPENDIX A — MRI LEXICON SUMMARY FORM

ACR BI-RADS® — MRI LEXICON SUMMARY FORM

For each of the following categories, select the term that best describes the dominant lesion feature.

BREAST TISSUE		
A. Amount of fibroglandular tissue (FGT)		
A. Almost entirely fatty		
B. Scattered fibroglandular tissue		
C. Heterogeneous fibroglandular tissue		
D. Extreme fibroglandular tissue		
B. Background parenchymal enhancement (BPE): Primarily assessed on the first post-contrast image; subtraction and MIP imaging may give additional information		
1. Level *(select one)*	a. Minimal	Includes no enhancement
	b. Mild	
	c. Moderate	
	d. Marked	
2. Symmetry	a. Symmetric	
	b. Asymmetric	
FINDINGS		
C. Masses: 3-dimensional space-occupying lesions		
1. Shape *(select one)*	a. Oval	Elliptical or egg-shaped
	b. Lobulated	One or more indentations resulting in an undulating contour
	c. Round	Spherical, ball-shaped, similar in diameter in all three axes
	d. Irregular	Neither oval, lobulated nor round, with acute angle protruding portions
2. Margin *(select one)*	a. Circumscribed	Entire margin is sharply demarcated with abrupt transition between the finding and surrounding tissue
	b. Non-circumscribed	
	i. Indistinct	Uneven edges (but not spiculated)
	ii. Spiculated	Characterized by lines radiating from the mass
3. Internal enhancement pattern *(select one)*	a. Homogeneous	Confluent uniform enhancement
	b. Dark internal septations	Dark non-enhancing lines within a mass
	c. Heterogeneous	Varied, non-uniform enhancement signal intensity
	d. Thick rim enhancement	Thick enhancement at the periphery of mass
4. T2 signal intensity	a. Hyperintense	Mass is uniformly bright; "lymph node bright"
	b. Not hyperintense	Not uniformly bright or "lymph node bright"

D. Non-mass enhancement (NME): A unique area of enhancement that is not a mass and is distinct from BPE		
1. Distribution *(select one)*	a. Diffuse	Enhancement distributed randomly through a large portion of the breast
	b. Regional	Enhancement in a large volume of tissue (typically more than one quadrant) but not diffuse and does not follow a segmental or linear distribution
	c. Focal	Localized and occupies less that one quadrant and does not follow a segmental or linear distribution
	d. Linear	Enhancement arrayed in a line or a line that branches (not necessarily a straight line)
	e. Segmental	Triangular or cone shaped region of enhancement, apex pointing to nipple, suggesting a duct or its branches
2. Internal enhancement pattern *(select one)*	a. Homogeneous	Confluent uniform enhancement
	b. Heterogeneous	Non-uniform enhancement in a random pattern, separated by normal tissue or fat
	c. Clumped	Enhancement of varying shapes and sizes with cobblestone or beaded enhancement, with occasional confluent areas
	d. Clustered ring	Rings of enhancement around ducts
E. Enhancement kinetics: Description of enhancement characteristics during injection of contrast medium		
1. Early phase	Enhancement-related signal intensity within the first 60–120 seconds after contrast injection	
	a. Slow	< 50% increase in signal intensity
	b. Medium	50–100% increase in signal intensity
	c. Fast	> 100% increase in signal intensity
2. Delayed phase	Enhancement-related signal intensity after the first 60–120 seconds after contrast injection or when the curve begins to change	
	a. Persistent	Signal intensity increases > 10% compared to early phase
	b. Plateau	Signal intensity increases or decreases ≤ 10% compared to early phase
	c. Washout	Signal intensity decreases > 10% compared to early phase
F. Lymph nodes		
1. Intramammary	a. Normal	Circumscribed, reniform, T2 hyperintense, homogeneously enhancing
	b. Abnormal	Subjectively enlarged, possibly non-circumscribed margin
2. Axillary	a. Normal	Circumscribed, reniform, homogeneously enhancing and typically T2 hyperintense
	b. Abnormal	Subjectively asymmetric in cortical thickness compared to other ipsilateral or contralateral axillary lymph nodes, lack of fatty hilum in larger lymph nodes, or have significantly increased in size or cortical thickness compared to a prior exam
3. Internal mammary	a. Normal	May measure up to 9 –10 mm if morphologically normal in screening populations
	b. Abnormal	Subjectively asymmetric in size compared to other ipsilateral or contralateral internal mammary lymph nodes; suspicious if ≥ 5mm in size in patients with current breast cancer

G. Associated Features *(select all that apply)*		
1. Nipple retraction	Nipple is pulled in; do not confuse with nipple inversion	
2. Nipple involvement	Abnormal enhancement involving the nipple when the tumor involves/directly extends into the nipple	
3. Skin retraction	The skin is pulled in abnormally	
4. Skin thickening	May be focal or diffuse; defined as being greater than 2 mm in thickness	
5. Skin involvement	Abnormal enhancement within the skin, either when tumor directly invades or without direct extension (often due to inflammatory breast cancer) via the invasion of the dermal lymphatics	
6. Pectoralis muscle involvement	Abnormal enhancement involving the underlying pectoralis major and/or minor muscle(s)	
7. Chest wall involvement	Abnormal enhancement extending into the ribs or intercostal spaces (behind the pectoralis muscle)	
8. Peritumoral edema	Hyperintense T2 signal is present in the tissue surrounding a malignant or suspicious finding	
H. Other findings, typically benign		
1. High T1 duct signal	Hyperintense signal is present in ducts on T1-weighted images before contrast administration	
2. Cysts	Circumscribed, round or oval, fluid-filled mass with a thin wall. Usually hyperintense on T2 images but may also be hypointense on T2 images and hyperintense on T1 images when their contents are proteinaceous or hemorrhagic. A cyst may have thin peripheral peri-cystic enhancement of the adjacent parenchymal tissue	
3. Postoperative fluid collections (hematoma/seroma)	Often T2 hyperintense and may also have bright signal on T1 weighted imaging due to blood or protein. A fat-fluid layer may be present. May demonstrate thin peripheral enhancement, a benign pattern	
4. Post-therapy skin thickening and trabecular thickening	May be seen following surgery and/or radiation therapy	
5. Non-enhancing mass	Solid masses that do not exhibit enhancement, distinguished from cysts as they do not contain fluid. Subtraction imaging may be useful in confirming absence of enhancement	
6. Signal void	Absence of signal due to susceptibility artifact, typically from a metallic clip or other foreign body	
7. Fat necrosis	Focal collections of fat can be present at sites of prior trauma including surgery	
8. Hamartoma	A focal area of fat and fibroglandular tissue is contained within a pseudocapsule	
9. Enhancing skin lesions	Enhancing lesions of the skin unrelated to a current or suspected breast cancer such as moles, keloids, skin-related cysts (epidermal inclusion or sebaceous) and areas of focal inflammation, all of which may normally enhance	
I. Location of finding		
1. Laterality	Describe right, left or bilateral	
2. Location in breast	Describe clock face (preferred) in whole number, or quadrant or other anatomic location	
3. Depth	Indicate depth (anterior, middle, posterior third)	
4. Distance from nipple	From base of nipple to center of finding in whole cm; include centimeters from the skin, or chest wall as appropriate	
J. Implants and other types of augmentation		
1. Implant location	a. Prepectoral	The implant is located anterior to the pectoralis muscle
	b. Retropectoral	The implant is located deep to portions of the pectoralis major muscle
2. Material	a. Saline	Indicate intact vs ruptured status
	b. Silicone	Indicate intact vs ruptured status
	c. Other implant/augmentation material	Might include autologous (such as TRAM, DIEP and other tissue flaps) tissue, non-autologous tissue (such as fat) and direct injection of materials such as silicone, paraffin, soy oil, polypropylene and polyurethane

3. Lumen type	a. Single	
	b. Double	
4. Intracapsular silicone findings *(select all that apply)*	a. Radial folds	Infolding of the intact elastomer shell. Normal finding
	b. Intracapsular silicone findings	
	i. Subcapsular line sign	Silicone is present between the fibrous capsule and collapsed implant envelope
	ii. Keyhole sign	Silicone is present within the potential space created by the apposed walls of the implant shell or envelope
	iii. Linguine sign	Multiple adjacent hypointense curvilinear lines surrounded by silicone signal
	c. Water droplets	Small drops with water signal intensity on water-specific sequences
5. Extracapsular silicone findings	a. Breast	Free silicone outside the fibrous capsule and within the breast indicates either a current or prior extracapsular (and, by definition, an accompanying intracapsular) rupture
	b. Lymph nodes	Silicone may be present in lymph nodes due to implant rupture (related to a current implant or one previously explanted), but also with intact silicone implants due to "silicone bleed"
6. Focal contour bulge		Focal bulge in the implant contour perhaps due to capsular contraction
7. Peri-implant fluid		Fluid is seen in the space between the implant shell and the capsule on water-specific sequences. A trace amount of peri-implant fluid or effusion around an implant is normal

ASSESSMENT CATEGORIES (select one)

Incomplete Assessment	Management	Likelihood of Cancer
Category 0: Incomplete: Need Additional Imaging Evaluation OR Category 0: Incomplete: Need Prior Imaging for Comparison	Recall for additional imaging Need comparison to prior examination(s)	N/A
Final Assessment	**Management**	**Likelihood of Cancer**
Category 1: Negative	Routine breast screening, including MRI if appropriate according to major guidelines	Essentially 0% likelihood of malignancy
Category 2: Benign	Routine breast screening, including MRI if appropriate according to major guidelines	Essentially 0% likelihood of malignancy
Category 3: Probably Benign	Short-interval (6-month) follow-up or continued surveillance (12-month)	≥ 0% but ≤ 2% likelihood of malignancy
Category 4: Suspicious	Tissue diagnosis	> 2% but < 95% likelihood of malignancy
Category 5: Highly Suggestive of Malignancy	Tissue diagnosis	≥ 95% likelihood of malignancy
Category 6: Known Biopsy-Proven Malignancy	Clinical follow-up with surgeon and/or oncologist, and definitive local therapy (usually surgery) when clinically appropriate	N/A

REFERENCES

1. ACR Practice Parameter For The Performance Of Contrast-Enhanced Magnetic Resonance Imaging (MRI) Of The Breast. Available at: https://gravitas.acr.org/PPTS/GetDocumentView?docId=6. Accessed September 30, 2025.
2. American College of Radiology. MRI and Breast MRI Accreditation. Available at: https://accreditationsupport.acr.org/support/solutions/11000003458. Accessed September 30, 2025.
3. Jansen SA, Shimauchi A, Zak L, et al. Kinetic curves of malignant lesions are not consistent across MRI systems: need for improved standardization of breast dynamic contrast-enhanced MRI acquisition. AJR Am J Roentgenol 2009;193:832–9.
4. Grimm LJ, Anderson AL, Baker JA, et al. Frequency of malignancy and imaging characteristics of probably benign lesions seen at breast MRI. AJR Am J Roentgenol 2015;205:442–47.
5. Baltzer P, Mann RM, Iima M, et al. Diffusion-weighted imaging of the breast-a consensus and mission statement from the EUSOBI International Breast Diffusion-Weighted Imaging working group. Eur Radiol 2020;30:1436–50.
6. Grimm LJ, Enslow M, Ghate SV. Solitary, well-circumscribed, T2 hyperintense masses on MRI have very low malignancy rates. Journal of Breast Imaging 2019;1:37–42.
7. Chikarmane SA, Michaels AY, Giess CS. Revisiting Nonmass Enhancement in Breast MRI: Analysis of Outcomes and Follow-Up Using the Updated BI-RADS Atlas. AJR Am J Roentgenol 2017; 209:1178–84.
8. Wang LC, DeMartini WB, Partridge SC, Peacock S, Lehman CD. MRI-detected suspicious breast lesions: predictive values of kinetic features measured by computer-aided evaluation. AJR Am J Roentgenol 2009;193:826–31.
9. Mack M, Chetlen A, Liao J. Incidental Internal Mammary Lymph Nodes Visualized on Screening Breast MRI. AJR Am J Roentgenol 2015;205:209–14.
10. Ray KM, Munir R, Wisner DJ, et al. Internal mammary lymph nodes as incidental findings at screening breast MRI. Clin Imaging 2015;39:791–3.
11. Kinoshita T, Odagiri K, Andoh K, et al. Evaluation of small internal mammary lymph node metastases in breast cancer by MRI. Radiat Med 1999;17:189–93.
12. Zhao S, Li Y, Ning N, et al. Association of peritumoral region features assessed on breast MRI and prognosis of breast cancer: a systematic review and meta-analysis. Eur Radiol 2024;34:6108–20.
13. U.S. Department of Health and Human Services. Food and Drug Administration. Breast Implants - Certain Labeling Recommendations to Improve Patient Communication. Available at: https://www.fda.gov/media/131885/download. Accessed September 30, 2025.
14. Carr LW, Roberts J, Mericli AF, Liu J, Arribas EM, Clemens MW. Breast Implant Imaging Surveillance among U.S. Plastic Surgeons: U.S. Food and Drug Administration Recommendations versus Clinical Reality. Plast Reconstr Surg 2020;145:1381–87.
15. Spick C, Bickel H, Polanec SH, Baltzer PA. Breast lesions classified as probably benign (BI-RADS 3) on magnetic resonance imaging: a systematic review and meta-analysis. Eur Radiol 2018;28:1919–28.
16. Liberman L, Morris EA, Benton CL, Abramson AF, Dershaw DD. Probably benign lesions at breast magnetic resonance imaging: preliminary experience in high-risk women. Cancer 2003;98:377–88.

17. Strigel RM, Rollenhagen J, Burnside ES, et al. Screening Breast MRI Outcomes in Routine Clinical Practice: Comparison to BI-RADS Benchmarks. Acad Radiol 2017;24:411–17.

18. Panigrahi B, Harvey SC, Mullen LA, et al. Characteristics and Outcomes of BI-RADS 3 Lesions on Breast MRI. Clin Breast Cancer 2019;19:e152-e59.

19. Edmonds CE, Lamb LR, Mercaldo SF, Sippo DA, Burk KS, Lehman CD. Frequency and cancer yield of BI-RADS category 3 lesions detected at high-risk screening breast MRI. AJR Am J Roentgenol 2020;214:240–48.

20. Mosier A, Gupta E, Ataya D, Bhatt K, Rim A. Low Compliance in a Health-Conscience Spending Era Likely Helps Obviates the Need for 6 month BI-RADS 3 Breast MRI Follow-up After 1 year. Breast J 2017;23:504–08.

21. Chikarmane SA, Tai R, Meyer JE, Giess CS. Prevalence and Predictive Value of BI-RADS 3, 4, and 5 Lesions Detected on Breast MRI: Correlation with Study Indication. Acad Radiol 2017;24:435–41.

22. Giess CS, Poole PS, Chikarmane SA, Sippo DA, Birdwell RL. Screening Breast MRI in Patients Previously Treated for Breast Cancer: Diagnostic Yield for Cancer and Abnormal Interpretation Rate. Acad Radiol 2015;22:1331–7.

23. Bahrs SD, Baur A, Hattermann V, et al. BI-RADS® 3 lesions at contrast-enhanced breast MRI: is an initial short-interval follow-up necessary? Acta Radiologica 2014;55:260–65.

24. Weinstein SP, Hanna LG, Gatsonis C, Schnall MD, Rosen MA, Lehman CD. Frequency of malignancy seen in probably benign lesions at contrast-enhanced breast MR imaging: findings from ACRIN 6667. Radiology 2010;255:731.

25. Hauth E, Umutlu L, Kummel S, Kimmig R, Forsting M. Follow-up of probably benign lesions (BI-RADS 3 category) in breast MR imaging. Breast J 2010;16:297–304.

26. Eby PR, DeMartini WB, Gutierrez RL, Saini MH, Peacock S, Lehman CD. Characteristics of probably benign breast MRI lesions. AJR Am J Roentgenol 2009;193:861–7.

27. Eby PR, Demartini WB, Peacock S, Rosen EL, Lauro B, Lehman CD. Cancer yield of probably benign breast MR examinations. J Magn Reson Imaging 2007;26:950–5.

28. Chikarmane SA, Birdwell RL, Poole PS, Sippo DA, Giess CS. Characteristics, malignancy rate, and follow-up of BI-RADS category 3 lesions identified at breast MR imaging: implications for MR image interpretation and management. Radiology 2016;280:707–15.

29. Lourenco AP, Chung MT, Mainiero MB. Probably benign breast MRI lesions: frequency, lesion type, and rate of malignancy. J Magn Reson Imaging 2014;39:789–94.

30. Spick C, Szolar DH, Baltzer PA, et al. Rate of malignancy in MRI-detected probably benign (BI-RADS 3) lesions. AJR Am J Roentgenol 2014;202:684–9.

31. Price ER, Sickles EA, Yitta S, et al. Use of the probably benign (BI-RADS category 3) assessment for masses on breast MRI: Is it transferable to general clinical practice? Breast J 2018;24:109–14.

32. Mahoney MC, Gatsonis C, Hanna L, DeMartini WB, Lehman C. Positive predictive value of BI-RADS MR imaging. Radiology 2012;264:51–8.

33. Igarashi T, Ashida H, Morikawa K, Motohashi K, Fukuda K. Use of BI-RADS-MRI descriptors for differentiation between mucinous carcinoma and fibroadenoma. European Journal of Radiology 2016;85:1092–98.

34. Baltzer PA, Dietzel M, Kaiser WA. Nonmass lesions in magnetic resonance imaging of the breast: additional T2-weighted images improve diagnostic accuracy. J Comput Assist Tomogr 2011;35:361–6.

35. Sedora Roman NI, Mehta TS, Sharpe RE, et al. Proposed biopsy performance benchmarks for MRI based on an audit of a large academic center. Breast J 2018;24:319–24.

36. Niell BL, Gavenonis SC, Motazedi T, et al. Auditing a breast MRI practice: performance measures for screening and diagnostic breast MRI. J Am Coll Radiol 2014;11:883–9.

37. Lee CH, Bryce Y, Zheng J, et al. Outcome of screening MRI in premenopausal women as a function of the week of the menstrual cycle. AJR Am J Roentgenol 2020;214:1175–81.

38. Ambinder EB, Myers K, Panigrahi B, et al. Breast MRI BI-RADS 3: Impact of Patient-Level Factors on Compliance With Short-Term Follow-Up. J Am Coll Radiol 2020;17:377–83.

39. Lee CI, Ichikawa L, Rochelle MC, et al. Breast MRI BI-RADS assessments and abnormal interpretation rates by clinical indication in US community practices. Acad Radiol 2014;21:1370–6.

40. Lee AY, Ichikawa L, Lee JM, et al. Concordance of BI-RADS Assessments and Management Recommendations for Breast MRI in Community Practice. AJR Am J Roentgenol 2016;206:211–6.

41. Strigel RM, Burnside ES, Elezaby M, et al. Utility of BI-RADS Assessment Category 4 Subdivisions for Screening Breast MRI. AJR Am J Roentgenol 2017;208:1392–99.

42. Spick C, Baltzer PA. Diagnostic utility of second-look US for breast lesions identified at MR imaging: systematic review and meta-analysis. Radiology 2014;273:401–09.



ACR BI-RADS® v2025

Contrast Enhanced Mammography

Carol H. Lee, MD, Chair

Jordana Phillips, MD
Janice S. Sung, MD
John M. Lewin, MD
Mary S. Newell, MD



American College of Radiology™

TABLE OF CONTENTS

PREFACE 728

INTRODUCTION 729

I. GENERAL CONSIDERATIONS 731

II. BREAST IMAGING LEXICON — CEM 733

III. IMAGE EXAMPLES. 738

IV. REPORTING SYSTEM 780

A. ASSESSMENT CATEGORIES 780

B. REPORT ORGANIZATION 783

C. WORDING OF REPORT 787

V. GUIDANCE 788

VI. FREQUENTLY ASKED QUESTIONS 792

APPENDIX A — LEXICON SUMMARY FORM FOR RECOMBINED IMAGES 795

PREFACE

The introduction of the American College of Radiology Breast Imaging Reporting and Data System (BI-RADS®) has revolutionized breast imaging interpretation and reporting and serves as the model for optimal reporting of radiologic studies.

As the field of breast imaging has evolved to include newer technologies, so too has the BI-RADS Atlas evolved. When first introduced in 1992, BI-RADS was little more than a pamphlet dealing only with mammography. As experience with mammography grew and terms were validated by evidence, subsequent editions were released refining terms. The 4th Edition of BI-RADS, which was published in 2003, included sections on ultrasound and magnetic resonance imaging (MRI) in addition to mammography. The 5th Edition, released in December 2013, continued to refine terms and expand on areas such as auditing and reporting. The newest version, now referred to as the BIRADS v2025 Manual, contains some changes in lexicon terminology.

Contrast enhanced mammography (CEM) was first approved by the Food and Drug Administration (FDA) in 2011 and its use is increasing. CEM has been shown to be more sensitive than mammography or ultrasound for the detection of malignancy. Given that utilization is increasing, it is important that a lexicon be available to allow for consistency in reporting and also to allow for validation of standardized terms through studies looking at the performance of CEM in a variety of clinical settings.

Each figure legend describes several features of the imaging finding, with those capitalized signifying the dominant feature being illustrated. Additional descriptors in the legend will be included in lower case (e.g., "ROUND, circumscribed, high density mass."). Where possible, the biopsy-proven pathology of the finding will be included. Occasionally, multiple finding types are depicted in the illustration and will be additionally described in the legend. For example, a group of calcifications may include both "round" and "amorphous" morphologies. While more than one type may be described, a single management recommendation should be made based on the most suspicious finding(s) present. In this new version of the Manual, the lexicon descriptors within a given category that cross the BI-RADS modalities, are arranged from least to most suspicious, where appropriate.

This is the first version of the BI-RADS lexicon for CEM to be embedded within the Manual instead of as a supplement. It will continue to undergo revisions and alterations as more experience is gained with this modality and as studies to validate terms are performed. Until then, as with other sections of BI-RADS, we encourage consistent usage of the lexicon to promote increased clarity and precision in reporting and accuracy in reaching final assessments.

ACR Committee on BI-RADS®
American College of Radiology
E-mail: RADS@acr.org

Carol H. Lee, MD, FACR, FSBI
Chair, Subcommittee on BI-RADS® Contrast Enhanced Mammography

INTRODUCTION

To perform CEM, intravenous (IV) iodinated contrast is administered and two exposures (low and high energy) are made using the standard mammography projections of craniocaudal (CC) and mediolateral oblique (MLO) with kVp settings that straddle the k-edge of iodine.

The low-and high- energy images are then recombined and processed to indicate tissue that enhances with iodine. The low energy (LE) image serves as the standard digital mammogram and reporting for this portion of the CEM examination should be no different from reporting for a standard mammogram. The mammography lexicon should be used for reporting the LE images. For the recombined (RC) image, the lexicon is similar but not identical to that used for MRI as outlined in this document.

A significant finding on a CEM examination might be seen on the LE images only, on the RC images only, or on both. Therefore, separate descriptions of the LE and RC images as well as an overall description should be included.

CEM is a relatively new technology and revisions to the lexicon will occur. If you would like to propose a substantive change, please submit it by e-mail (RADS@acr.org) to the ACR for review by the BI-RADS committee. However, please first visit the ACR BI-RADS web page at: https://www.acr.org/Clinical-Resources/Clinical-Tools-and-Reference/Reporting-and-Data-Systems/BI-RADS, which displays committee-approved responses to suggestions already submitted.

The ACR BI-RADS – CEM is divided into six sections:

SECTION I: General Considerations

SECTION II: Breast Imaging Lexicon — CEM

SECTION III: Image Examples

SECTION IV: Reporting System

SECTION V: Guidance

SECTION VI: Frequently Asked Questions

APPENDIX A — CEM Lexicon Summary form for Recombined Images

The following are brief summaries of each section

I. General Considerations and Image Acquisition Parameters

The potential indications for the examination, workflow considerations, and acquisition parameters are discussed.

II. Breast Imaging Lexicon — CEM

The lexicon for the low energy (LE) image portion of the CEM is the same as the mammography lexicon. For the RC images, terms are adopted from the MRI section but modified to cover situations unique to CEM. Each descriptor is illustrated by images.

III. Image Examples

Image examples of lexicon terms specific to CEM are presented. The display order will not match the outlined version of the lexicon presented in Section II, as examples of findings seen on low energy (LE) images are not included.

IV. Reporting System

The reporting system is designed to provide an organized approach to image interpretation and reporting. Not only is the use of approved terminology critical to produce an understandable breast imaging report, but the order in which the information is conveyed is also important. In addition to the usual organization of the breast imaging report, the LE and the RC images should be described separately, and the final assessment should be based on the most suspicious findings on each of these components. Standardized reporting facilitates clear and concise communication across disciplines and permits simultaneous data collection for future outcomes review (i.e., medical audit, tumor registry). Although not required, a structured reporting system will allow individual interpreting physicians and mammography facilities to monitor their own results and appraise the accuracy of image interpretation so that they can adjust interpretive thresholds appropriately. Note that use of ACR-approved computer-based reporting software is required for participation in the ACR National Mammography Database (NMD) (https://nrdr.acr.org/Portal/NMD/Main/page.aspx).

V. Guidance

Because CEM is a relatively new modality, many unanswered questions may arise in its performance. This section will discuss some questions that are commonly encountered in performing and interpreting these examinations.

VI. Frequently Asked Questions

Frequently asked questions are addressed.

APPENDIX A

The appendix contains a form for easy notation of findings on the RC images of a CEM examination with the appropriate BI-RADS terminology in a simple summary. This form also contains the BI-RADS assessment categories. For findings on the LE images, whether or not they are seen on the RC images, please refer to the appendix in the BI-RADS mammography section.

I. GENERAL CONSIDERATIONS

Contrast enhanced mammography is referred to by several different names including contrast enhanced digital mammography and contrast enhanced spectral mammography. The preferred term which avoids overlap with proprietary names is contrast enhanced mammography (CEM).

The post-processed combination of low and high energy images should be referred to as the recombined images (RC images).

When starting to utilize this technique, it is prudent to decide for which indications and clinical settings the study will be used. There is evidence that CEM may be useful for a variety of indications including determination of extent of disease in newly diagnosed breast cancer, response to neoadjuvant chemotherapy, problem solving, and intermediate and high-risk screening. It should be noted that as of the release of the BI-RADS v2025 Manual, the use of CEM for screening is not yet FDA approved, therefore the use of this modality for screening purposes is considered an off-label indication. CEM has also been proposed as an alternative to MRI when the patient is not a candidate for MRI. For any proposed indication, it is worthwhile to have a predetermined workflow for evaluation of (RC) imaging findings that have no correlate on conventional mammography or ultrasound. Although CEM–guided biopsy devices are FDA approved, these findings are commonly pursued with MRI and MRI-guided biopsy as there is currently limited availability of CEM-guided biopsy although it is in gaining clinical penetrance. If MRI or MRI-guided biopsy is not available or cannot be tolerated by the patient, an alternative approach for these findings will be needed and this should be recognized before CEM is performed. If neither CEM-guided nor MRI-guided biopsy are available, possible options, depending on the level of suspicion of the finding, could include short interval follow-up CEM, stereotactic biopsy using landmarks, or in rare circumstances image guided localization using landmarks followed by surgical excision.

CEM requires the use of IV iodinated contrast and patients should be evaluated for risks for contrast reaction. In addition, personnel at facilities that offer CEM should be fully trained and equipped to deal with contrast reactions. For patients who report prior contrast reactions, pre-medication can be considered to reduce the possibility of subsequent reaction. However, the data on reducing severe reactions has not been consistently demonstrated. Overall, the potential benefit of performing CEM in these patients should be weighed against the possibility of a serious contrast reaction or side effects of the pre-medication.

Many facilities choose to screen patients for impaired renal function or other relative contraindications to IV contrast. If this is elected by a facility, criteria for who should be screened prior to the CEM examination should be the same as those used prior to CT studies that require contrast. Also, any screening to determine suitability for contrast administration should happen at the time of scheduling so that lab work assessing renal function, if required, can be obtained before the patient's CEM visit. For patients with compromised renal function, the benefit of CEM should be weighed against the risk of contrast induced nephropathy prior to scheduling the exam. For a full discussion of the use of IV contrast please refer to the ACR Manual on Contrast Media available on the ACR website (https://www.acr.org/Clinical-Resources/Clinical-Tools-and-Reference/Contrast-Manual).

WORKFLOW AND IMAGE ACQUISITION

There is little data that supports timing of CEM during any particular phase of the menstrual cycle. For MRI, the recommendation has previously been to schedule during week 2, but several studies have shown that outcomes may not be affected by the stage of the menstrual cycle, and this may also be true for CEM.

Ready availability of personnel to start an IV line is critical to ensure timely performance of the study. To allow this, facilities should consider setting aside dedicated CEM time slots.

The usual dose of contrast for CEM will depend on the patient's body weight and the concentration of iodine in the agent used. Contrast is generally delivered with a power injector at a rate of 3 ml/sec. After a delay of approximately 2 minutes, the patient is positioned in the standard four mammography projections and two exposures are taken for each projection, one right after the other. The LE image is obtained at a kVp in the range of standard mammography, generally 28 to 32 kVp, and the high energy image typically between 45 and 49 kVp. A post-processed RC image is generated from the LE and high-energy images.

The order of the projections obtained varies with the facility. In general, for a bilateral study, the same view is alternated between the breasts so at least one view of each breast is obtained while contrast is maximally present. If there is one breast that requires particular attention, for example a case of newly diagnosed breast cancer, both views of that breast can be obtained first. Also, if it is known that an additional non-standard view of one breast is needed, for example an exaggerated CC view, it can be obtained before imaging of the contralateral breast. The total time available to obtain images before contrast washes out is between 7 to 10 minutes, so ideally the entire CEM should be performed within that time frame.

II. BREAST IMAGING LEXICON — CEM

Table 1. BI-RADS® CEM Lexicon Overview

Breast Tissue	Terms	
A. Breast density[1]	(A) The breasts are almost entirely fatty	
	(B) There are scattered areas of fibroglandular density	
	(C) The breasts are heterogeneously dense, which may obscure small masses	
	(D) The breasts are extremely dense, which lowers the sensitivity of mammography	
B Background parenchymal enhancement (BPE)	1. Level	a. Minimal
		b. Mild
		c. Moderate
		d. Marked
	2. Symmetric or Asymmetric	a. Symmetric
		b. Asymmetric
C. Findings on low energy images only: **Refer to BI-RADS Mammography Lexicon**		
D. Findings on recombined images only		
Finding	**Terms**	
1. Masses	a. Shape	i. Oval
		ii. Lobulated
		iii. Round
		iv. Irregular
	b. Margin	i. Circumscribed
		ii. Non-circumscribed
		1) Indistinct
		2) Spiculated
	c. Internal enhancement pattern	i. Homogeneous
		ii. Heterogeneous
		iii. Rim enhancement
2. Non-mass enhancement (NME)	a. Distribution	i. Diffuse
		ii. Regional
		iii. Focal
		iv. Linear
		v. Segmental
	b. Internal enhancement pattern	i. Homogeneous
		ii. Heterogeneous
		iii. Clumped
3. Enhancing asymmetry	Internal enhancement pattern	a. Homogeneous
		b. Heterogeneous
E. Findings on low energy images with associated enhancement on recombined images		
1. Morphology	Refer to mammography lexicon	
2. Internal enhancement pattern	a. Homogeneous	
	b. Heterogeneous	
	c. Rim	

3. Extent of enhancement	a. Mammographic lesion partially enhances b. Mammographic lesion completely enhances c. Enhancement extends beyond mammographic lesion d. No enhancement of the mammographic lesion but enhancement in the adjacent tissue
F. Lesion conspicuity	a. Low b. Moderate c. High
G. Associated features	a. Nipple retraction b. Nipple involvement c. Skin retraction d. Skin thickening e. Skin involvement f. Axillary adenopathy
H. Location of finding	

[1] In July 2025, the FDA approved an alternative standard that would allow the interpreting physician to provide an overall assessment of breast density that is phrased in the singular phrasing. The singular phrasing is intended to be used in reports of unilateral mammograms. Please see Mammography Guidance section item #10 for more information.

A. Breast density: Breast composition should be assessed on the LE images and characterized using categories similar to conventional mammography. The report should include a description of the breast composition using one of the following terms:

Breast Density Categories

(A) The breasts are almost entirely fatty

(B) There are scattered areas of fibroglandular density

(C) The breasts are heterogeneously dense, which may obscure small masses

(D) The breasts are extremely dense, which lowers the sensitivity of mammography

In July 2025, the FDA approved an alternative standard that would allow the interpreting physician to provide an overall assessment of breast density that is phrased in the singular phrasing. The singular phrasing is intended to be used in reports of unilateral mammograms. Please see Mammography Guidance section item #10 for more information.

B. Background Parenchymal Enhancement (BPE): The presence of background parenchymal enhancement of the normal breast tissue should be described. As CEM is performed with IV contrast, fibroglandular breast parenchyma may demonstrate normal enhancement. BPE is not necessarily directly related to the amount of fibroglandular tissue and should be described as:

1. Level
    a. Minimal
    b. Mild
    c. Moderate
    d. Marked

As is the case with MRI, BPE should be described relative to the amount of the fibroglandular tissue and not the entire volume of the breast.

2. Symmetric vs Asymmetric:
    a. Symmetric BPE denotes similar levels and distribution of BPE between the two breasts.
    b. Asymmetric BPE denotes a greater level of broad distribution of enhancement in one breast than in the other. This may be seen after radiation therapy, with the radiated breast showing less BPE. If asymmetric BPE is seen without a known cause, it should be evaluated as it may represent a pathologic process such as diffuse inflammation or diffuse malignancy in the breast with the asymmetrically higher BPE.

FINDINGS OVERVIEW

Findings seen on CEM are divided into three broad categories: Those seen on the LE images only, those presenting as areas of enhancement only seen on the RC images, and those seen on the LE images with associated enhancement on the RC images. It should be clearly stated in the report whether a finding is seen on the LE images only, on the recombined images only, or on both. If there are separate findings on the LE and RC images, this should be clearly stated.

C. Finding on LE images only: A finding apparent on the LE images only should be described using the BI-RADS mammography lexicon. For example, masses that demonstrate no enhancement may be described by their shape, margin, and density. Calcifications should be described as benign or if not classically benign, by their morphology and distribution.

D. Findings on RC images only: A finding visualized only on the RC images may be described as a mass, non-mass enhancement, or an enhancing asymmetry. The descriptors for areas of enhancement on CEM are in general the same as those used for MRI. However, the CEM lexicon includes fewer descriptors than the MRI lexicon due to the lower resolution of CEM. In addition, unlike MRI, there are cases in which abnormal enhancement is seen on one view only. This should be called an "enhancing asymmetry." The conspicuity of the lesion, reflecting the degree of enhancement relative to background parenchymal enhancement may also be described.

1. Masses on RC images only: A mass is a 3D space-occupying lesion with a convex-outward contour. There may or may not be an identifiable correlate on the LE images. If there is no LE correlate, the mass shape/margin and internal pattern of enhancement should be characterized on the recombined images.
    a. Shape: Descriptors for mass shape are the same as for MRI, and include oval, lobulated, round, or irregular shape. Lobulated has been added to the shape descriptors to match the updated mammography lexicon.
    b. Margin: Descriptors for mass margin are the same as for MRI, and include circumscribed or non-circumscribed (indistinct, spiculated) margin. Note that the term indistinct is new to this version, replacing "irregular" to match the MRI lexicon change.
    c. Internal pattern of enhancement: A mass may demonstrate homogeneous, heterogeneous, or rim enhancement. Note that while the MRI lexicon has been updated to describe suspicious peripheral mass enhancement as "thick rim enhancement" rather than "rim enhancement," the lexicon term is not being changed in CEM, as the lower resolution of CEM precludes differentiation between thick and thin rim enhancement.
2. Non-mass enhancement (NME) on RC images only: Enhancement that is neither a mass nor an enhancing asymmetry is classified as non-mass enhancement. NME should be classified according to its distribution and described as diffuse, regional, focal, linear, or segmental. "Multiple regions" has been removed as a descriptor to match the MRI lexicon

change, where it was found to be of limited value as a descriptor (diffuse may be more appropriate in many of those situations). Unlike with MRI, the internal enhancement pattern of NME may not be clearly discernible due to the lower resolution of CEM compared to MRI. If visible, internal enhancement pattern may be described as homogeneous, heterogeneous, or clumped.

3. Enhancing asymmetry: This term should be used for a finding seen on only one view on the RC images. If desired, the internal enhancement pattern of an asymmetry can be described as homogeneous or heterogeneous. If a one-view asymmetry is seen on the LE image and exhibits enhancement, it can also be described as an enhancing asymmetry.

E. Findings seen on LE images with associated enhancement on recombined images: For enhancing lesions with a correlate on LE images (mass, asymmetry, focal asymmetry, architectural distortion, or calcifications); the LE finding should be described using the BI-RADS mammography lexicon. If the LE finding that enhances is not a mass (asymmetry, architectural distortion, or calcifications), the characteristics of the enhancement should be described using the CEM lexicon. For masses seen on the LE images that also enhance, it is not always necessary to further describe the mass shape and margin as seen on the RC images. Other descriptors besides shape and margin for enhancement seen on RC images include:

1. Morphology-refer to mammography lexicon
2. Internal pattern of enhancement: homogeneous, heterogeneous, rim
3. Extent of enhancement
    a. The mammographic lesion partially enhances
    b. The mammographic lesion completely enhances
    c. The enhancement extends beyond the mammographic lesion
    d. There is no enhancement of the mammographic lesion but there is surrounding enhancement in the tissue adjacent to the lesion. This commonly occurs with inflamed cysts or fat necrosis.

F. Lesion conspicuity: Lesion conspicuity (relative to background): Degree of enhancement relative to background may be described as low, moderate, or high. These are subjective qualitative descriptors relative to the degree of background parenchymal enhancement. Low refers to enhancement equal to or slightly greater than BPE, high if the enhancement is much greater than BPE, and moderate if the enhancement is in between low and high. For CEM, there is no data yet to correlate lesion conspicuity with likelihood of malignancy. Terms for conspicuity are included in the lexicon to allow for future research.

1. Low
2. Moderate
3. High

G. Associated Features: These are generally seen on the LE images and can also sometimes be appreciated on the RC images.

1. Nipple retraction: Nipple retraction is when the nipple is pulled in. New nipple retraction is associated with increased suspicion of underlying pathology.
2. Nipple involvement: Tumor is contiguous and invades the nipple.
3. Skin retraction: Skin is pulled in abnormally.

4. Skin thickening: Skin thickening is defined as being > 2 mm in thickness. Skin thickening without enhancement may represent post-treatment related changes (such as surgery and/or radiation) or a systemic process if bilateral and diffuse. However, diffuse skin thickening, with or without areas of enhancement, may also be secondary to lymphatic obstruction from malignancy or locally advanced breast cancer.
5. Skin involvement: Skin involvement may be seen with direct tumor invasion or with inflammatory cancer and is confirmed by enhancement (as opposed to isolated thickening).
6. Axillary adenopathy: Enlarged axillary lymph nodes may warrant comment, clinical correlation and additional evaluation, especially if they are new or considerably larger or rounder when compared to prior studies. Refer to Mammography section IV.E. for more in-depth discussion on lymph node morphology.

H. Location of finding: The location of a suspicious finding should be described using standard clock-face (preferred) and/or quadrant descriptor. Similar to mammography, the side is given first, followed by the clock-face and/or quadrant location, and the depth of the lesion (anterior, middle, or posterior third and/or distance from nipple in cm). See additional detail about reporting finding location below in Report Organization section in IV.B.5.b.

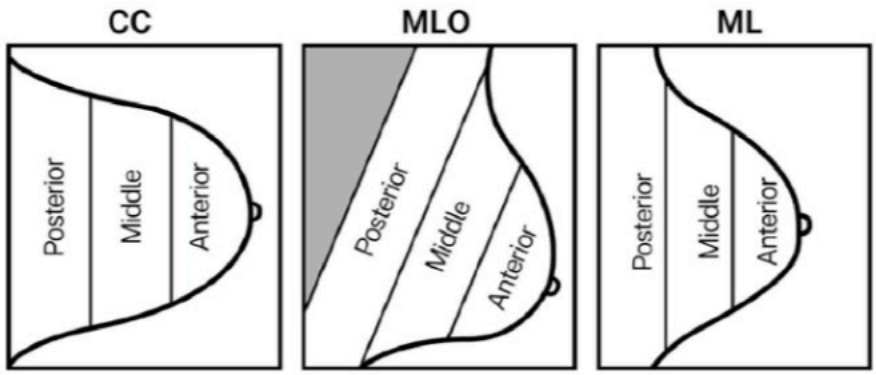

Figure 1 – Depth diagrams.

III. IMAGE EXAMPLES

The display order of these image examples order will **not** match the outlined version of the lexicon as presented in Section II, as examples of findings seen on low energy (LE) images are not included.

A. BACKGROUND PARENCHYMAL ENHANCEMENT

1. LEVEL
    a. Minimal



Figure 1 – BACKGROUND PARENCHYMAL ENHANCEMENT: MINIMAL. Recombined image.

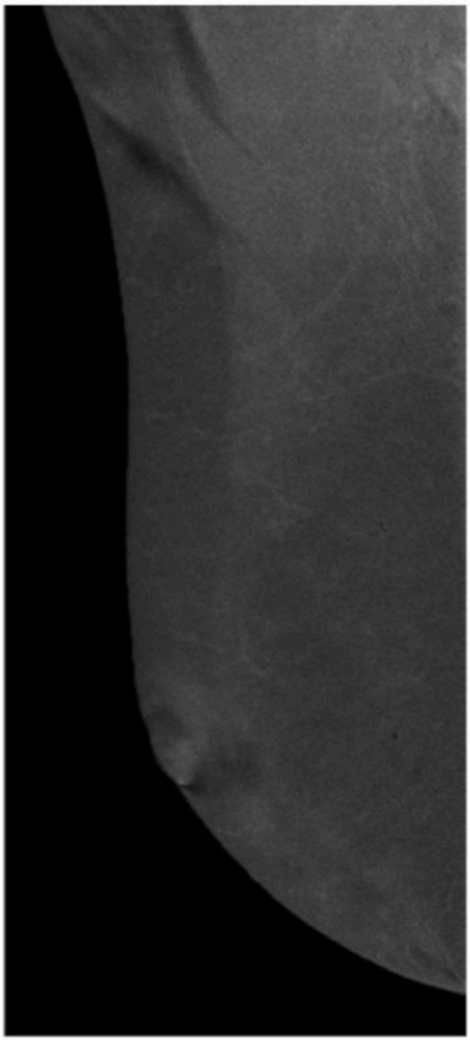

Figure 2 – BACKGROUND PARENCHYMAL ENHANCEMENT: MINIMAL. Recombined image.

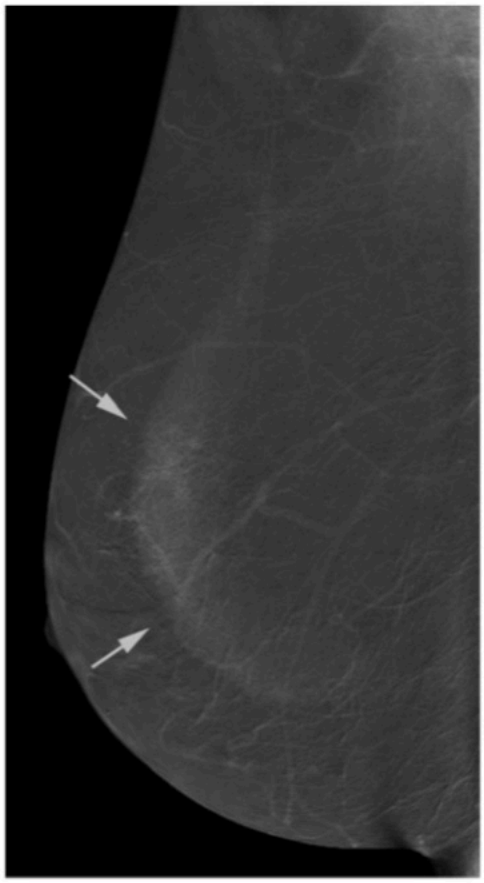

Figure 3 – BACKGROUND PARENCHYMAL ENHANCEMENT: MINIMAL. Note the rim artifact (arrows) caused by scattered radiation within the breast during image acquisition. Recombined image.

A. BACKGROUND PARENCHYMAL ENHANCEMENT

1. LEVEL

   b. Mild



Figure 4 – BACKGROUND PARENCHYMAL ENHANCMENT: MILD. Recombined image.

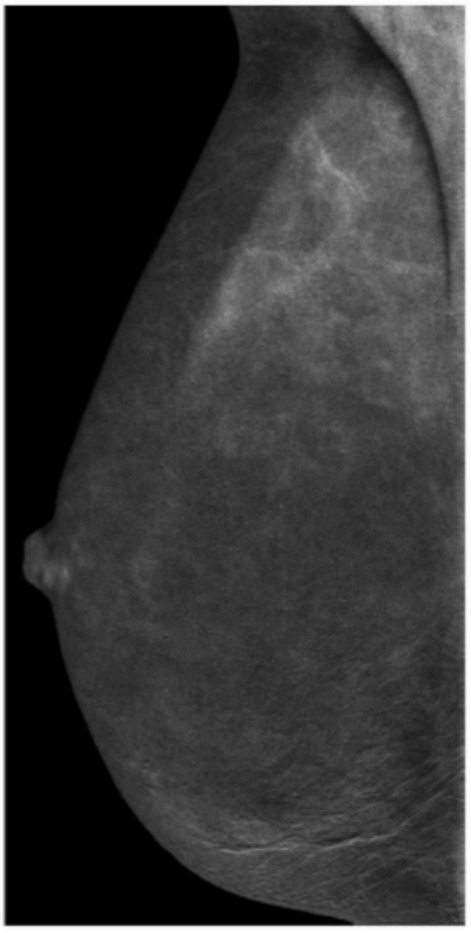

Figure 5 – BACKGROUND PARENCHYMAL ENHANCEMENT: MILD. Recombined image.

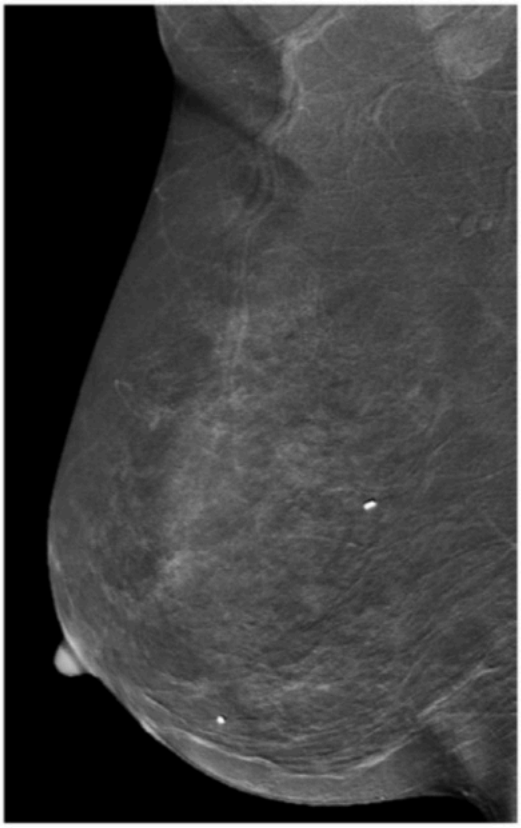

Figure 6 – BACKGROUND PARENCHYMAL ENHANCEMENT: MILD. Recombined image.

A. BACKGROUND PARENCHYMAL ENHANCEMENT

1. LEVEL

    c. Moderate

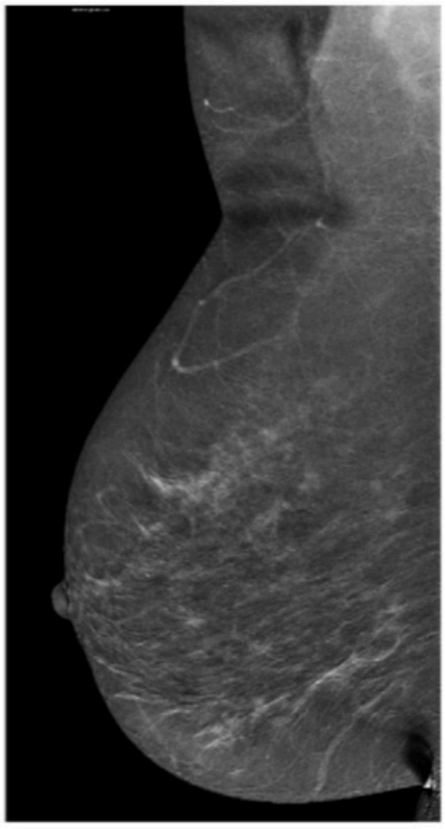

Figure 7 – BACKGROUND PARENCHYMAL ENHANCEMENT: MODERATE. Recombined image.

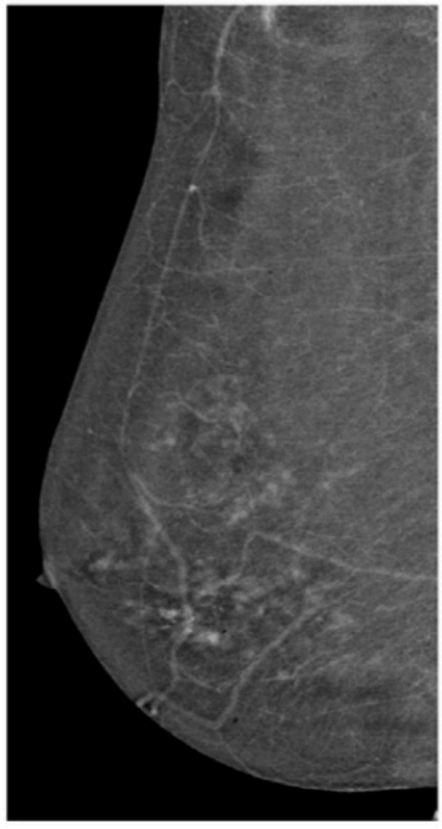

Figure 8 – BACKGROUND PARENCHYMAL ENHANCEMENT: MODERATE. Recombined image.

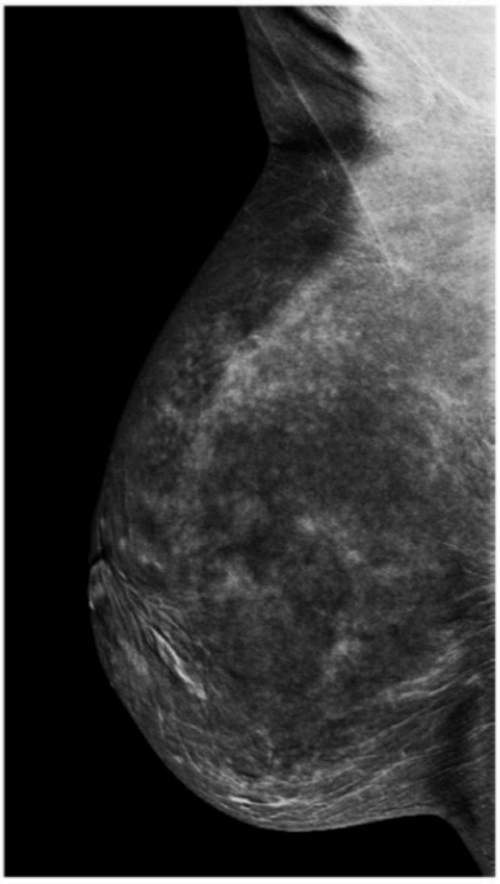

Figure 9 – BACKGROUND PARENHCHYMAL ENHANCEMENT: MODERATE. Recombined image.



Figure 10 – BACKGROUND PARENHCHYMAL ENHANCEMENT: MODERATE. The multiple bilateral dots of enhancement should not be called multiple foci. Bilateral recombined images.

A. BACKGROUND PARENCHYMAL ENHANCEMENT

1. LEVEL

   d. Marked

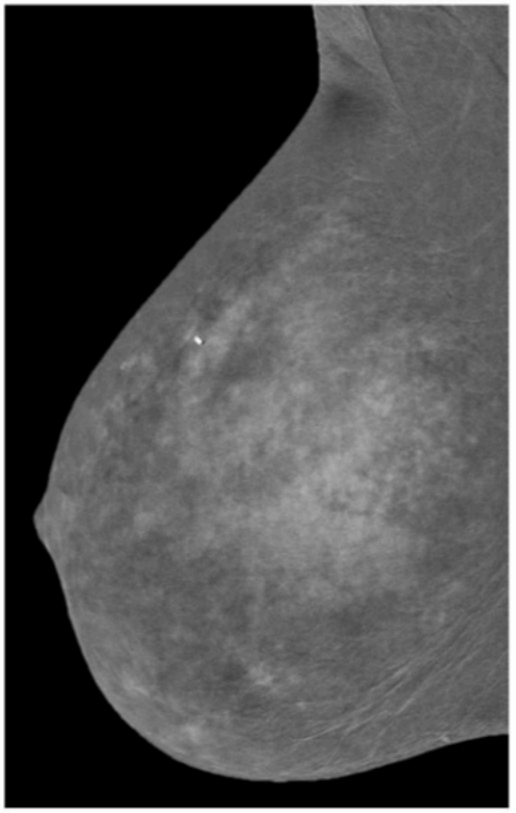

Figure 11 – BACKGROUND PARENCHYMAL ENHANCEMENT: MARKED. Recombined image.

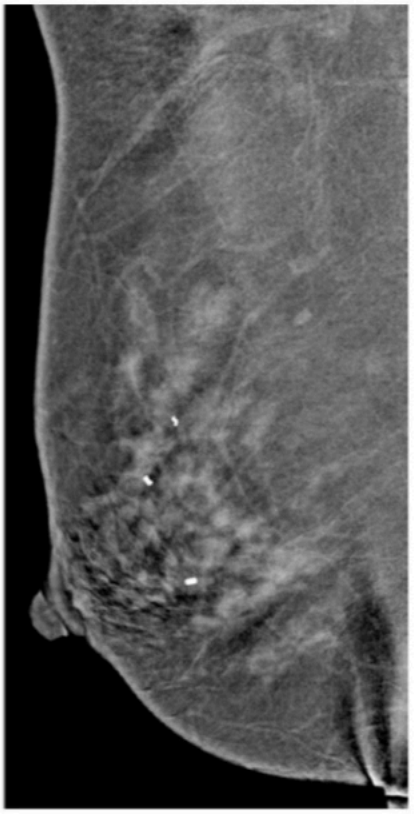

Figure 12 – BACKGROUND PARENCHYMAL ENHANCEMENT: MARKED. Recombined image.

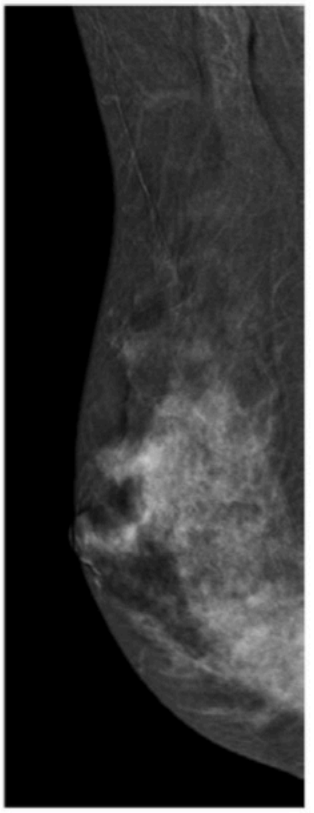

Figure 13 – BACKGROUND PARENCHYMAL ENHANCEMENT: MARKED. Recombined image.

A. BACKGROUND PARENCHYMAL ENHANCEMENT

2. SYMMETRIC OR ASYMMETRIC

   a. Symmetric



Figure 14 – BACKGROUND PARENCHYMAL ENHANCEMENT: SYMMETRIC. BPE is moderate and symmetric in both breasts. Recombined image.

A. BACKGROUND PARENCHYMAL ENHANCEMENT

2. SYMMETRIC OR ASYMMETRIC

   b. Asymmetric

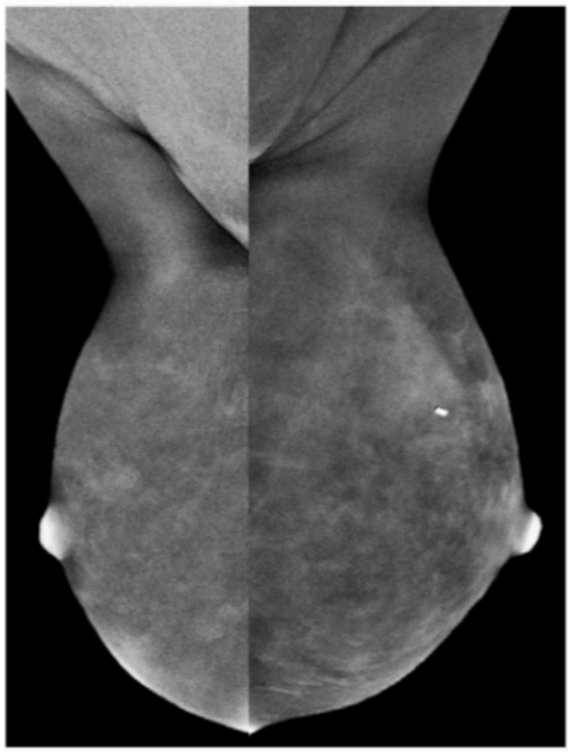

Figure 15 – BACKGROUND PARENCHYMAL ENHANCEMENT: ASYMMETRIC. Minimal BPE in right breast (left image); moderate BPE in left breast (right image) in a patient with a history of right breast cancer status post breast conservation surgery and radiation therapy. Marker clip on the left from remote ultrasound-guided biopsy of a 7 mm mass yielding fibroadenoma. Recombined images.

B. LESION CONSPICUITY (relative to background)

1. LOW

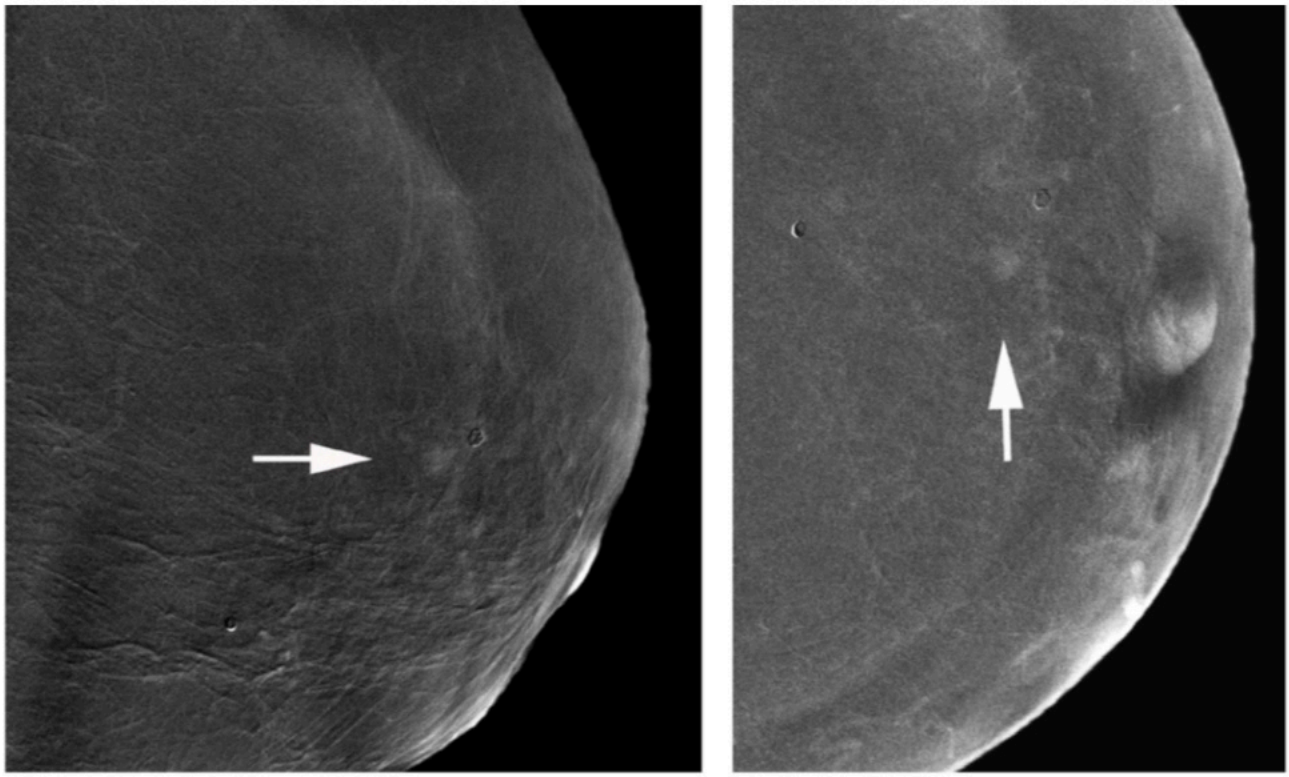

A B

Figure 16 – LESION CONSPICUITY: LOW. Small round mass with indistinct margin (arrows). (A) Left MLO recombined image (B) Left CC recombined image. Pathology: Invasive ductal carcinoma (despite low conspicuity).

B. LESION CONSPICUITY (relative to background)

2. MODERATE



Figure 17 – LESION CONSPICUITY: MODERATE. Focal non-mass with homogeneous internal enhancement (arrow). Second lesion (arrowhead) has low conspicuity. Recombined image. Pathology: Invasive ductal carcinoma for both.

B. LESION CONSPICUITY (relative to background)

3. HIGH

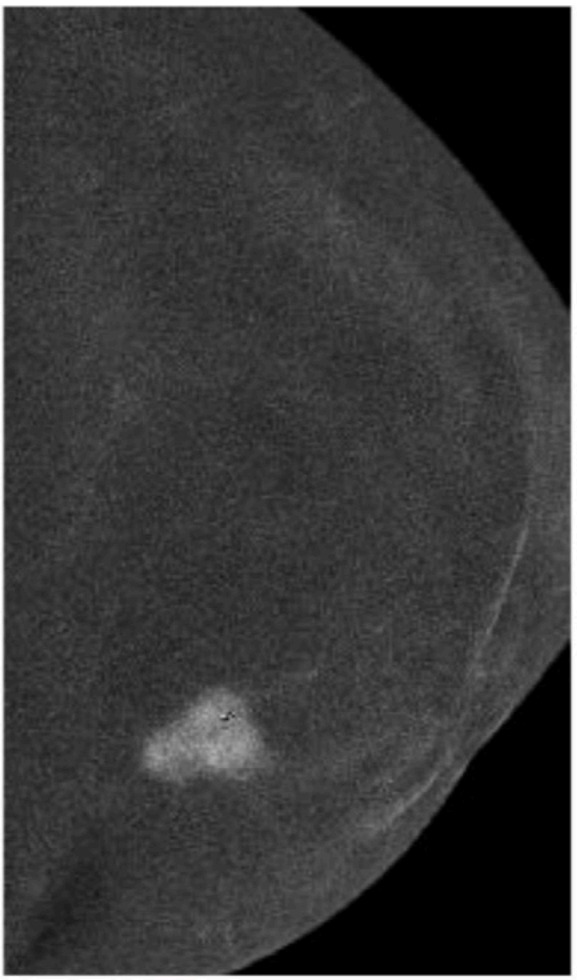

Figure 18 – LESION CONSPICUITY: HIGH. Lobulated mass with circumscribed margin, heterogeneous internal enhancement. Recombined image. Pathology: Fibroadenoma.

C. MASSES ON RECOMBINED IMAGES

1. SHAPE
    a. Oval

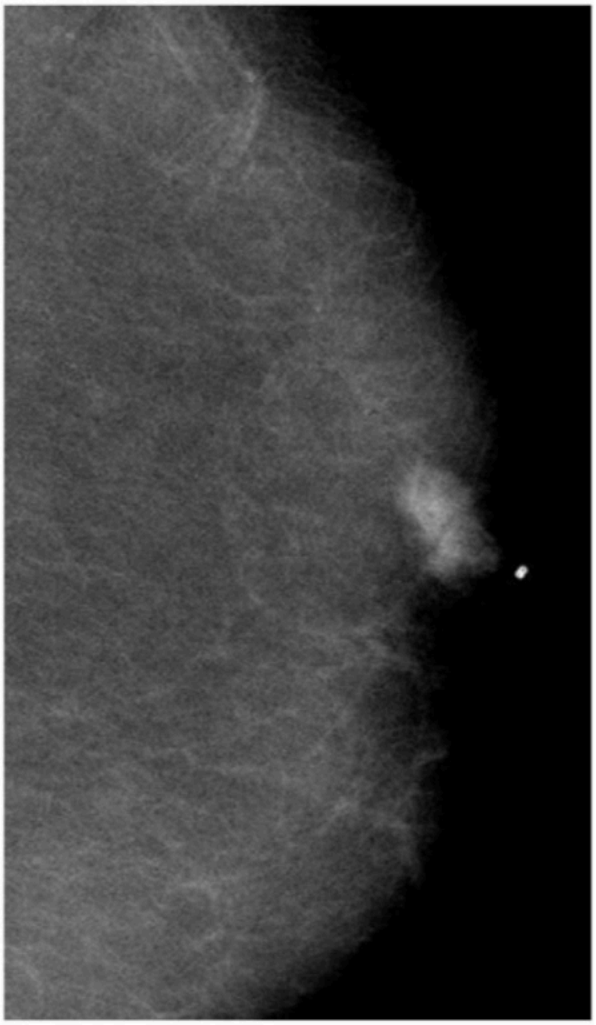

Figure 19 – SHAPE: OVAL. Indistinct OVAL mass heterogeneous internal enhancement. The mass was palpable. Recombined image. Pathology: Invasive ductal carcinoma.

C. MASSES ON RECOMBINED IMAGES

1. SHAPE

   b. Lobulated



Figure 20 – SHAPE: LOBULATED. LOBULATED, circumscribed mass with heterogeneous internal enhancement. Recombined image. Pathology: Invasive ductal carcinoma.

C. MASSES ON RECOMBINED IMAGES

1. SHAPE

   c. Round



Figure 21 – SHAPE: ROUND. Circumscribed ROUND mass with homogeneous internal enhancement (arrow). Recombined image. Pathology: Benign intramammary lymph node.

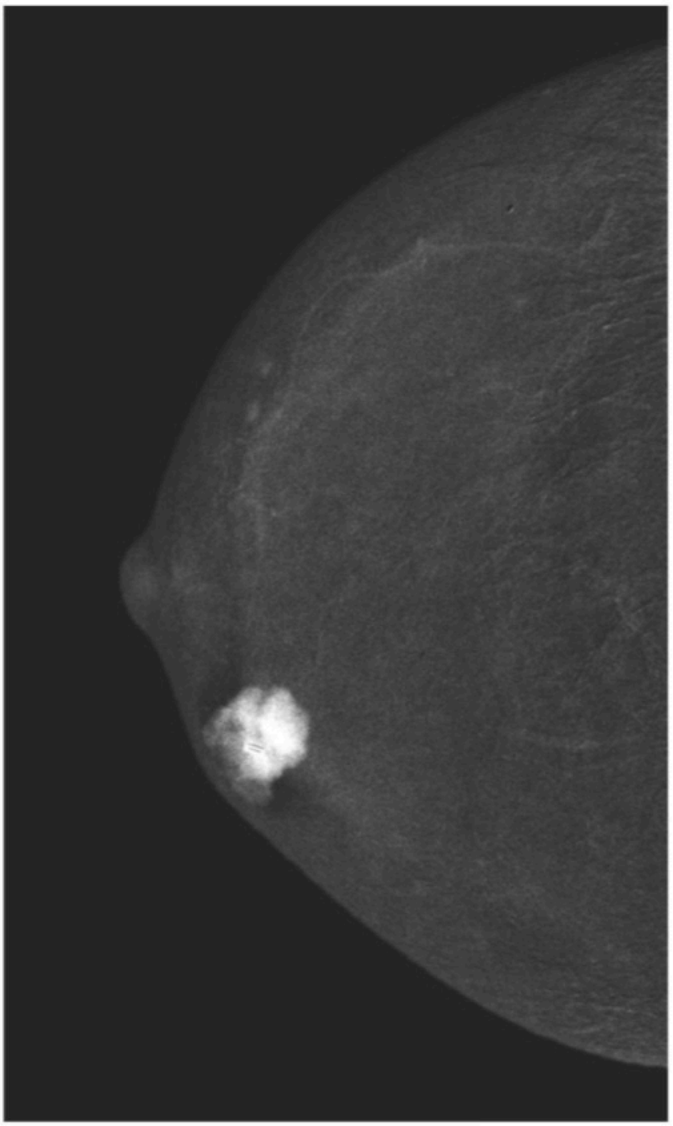

Figure 22 – SHAPE: ROUND. Indistinct ROUND mass with heterogeneous internal enhancement. Recombined image. Pathology: Fibroadenoma.

C. MASSES ON RECOMBINED IMAGES

1. SHAPE

   d. Irregular

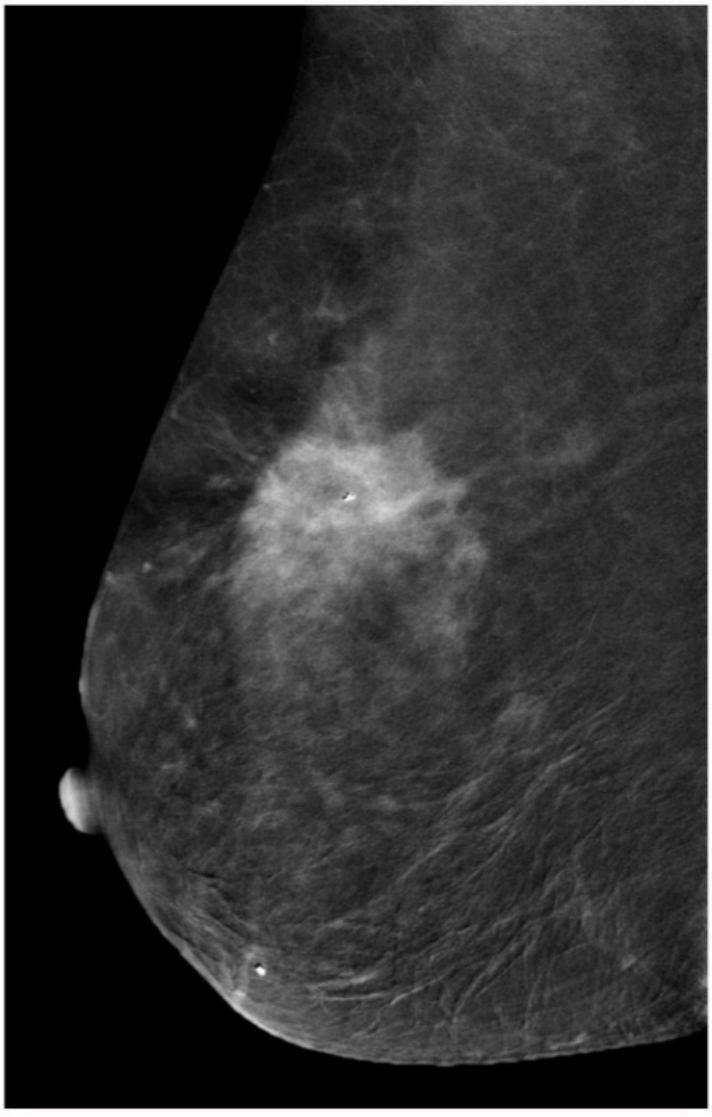

Figure 23 – SHAPE: IRREGULAR. IRREGULAR mass with indistinct margin and heterogeneous internal enhancement. Recombined image. Pathology: Invasive ductal carcinoma.

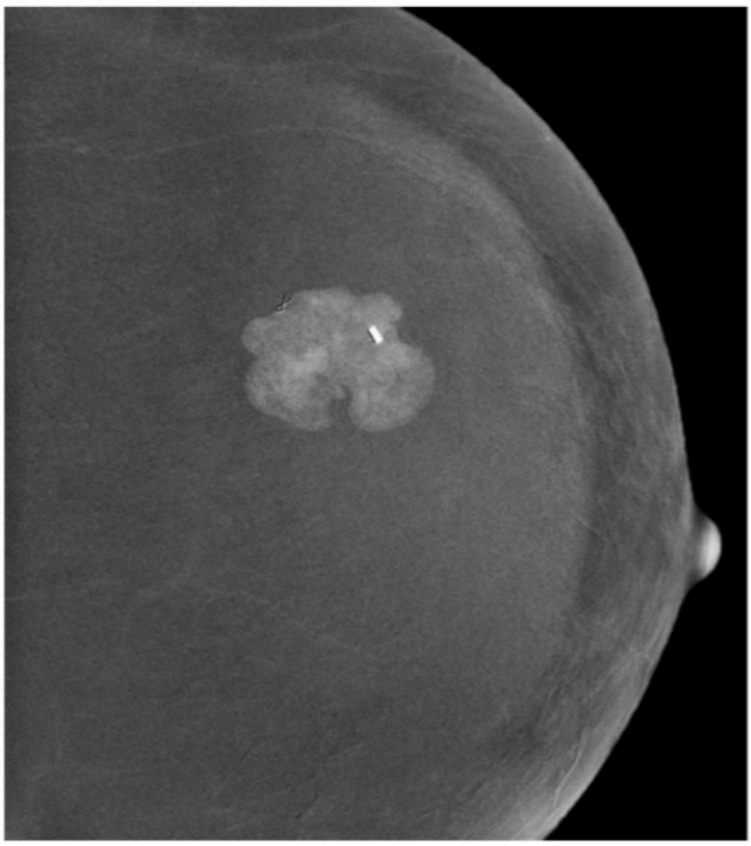

Figure 24 – SHAPE: IRREGULAR. IRREGULAR, indistinct mass with heterogeneous internal enhancement. Recombined image. Pathology: Invasive ductal carcinoma.

C. MASSES ON RECOMBINED IMAGES

2. MARGIN

   a. Circumscribed

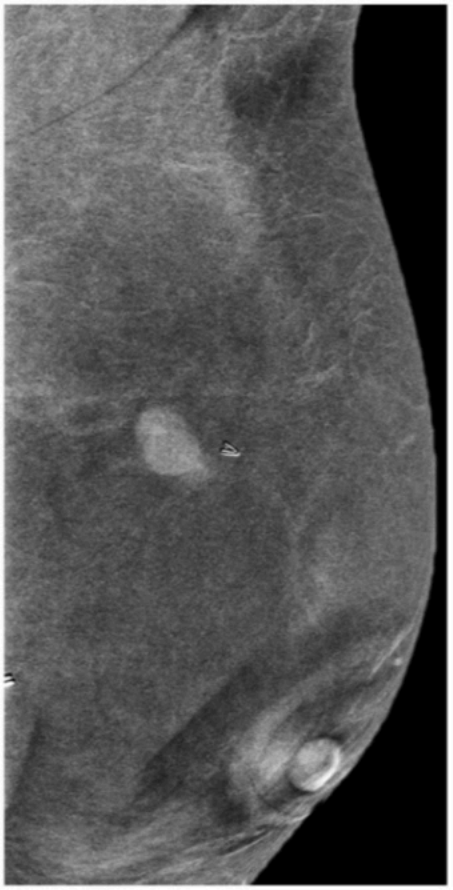

Figure 25 – MARGIN: CIRCUMSCRIBED. Oval CIRCUMSCRIBED mass with homogeneous internal enhancement. Recombined image. Pathology: Fibroadenoma.

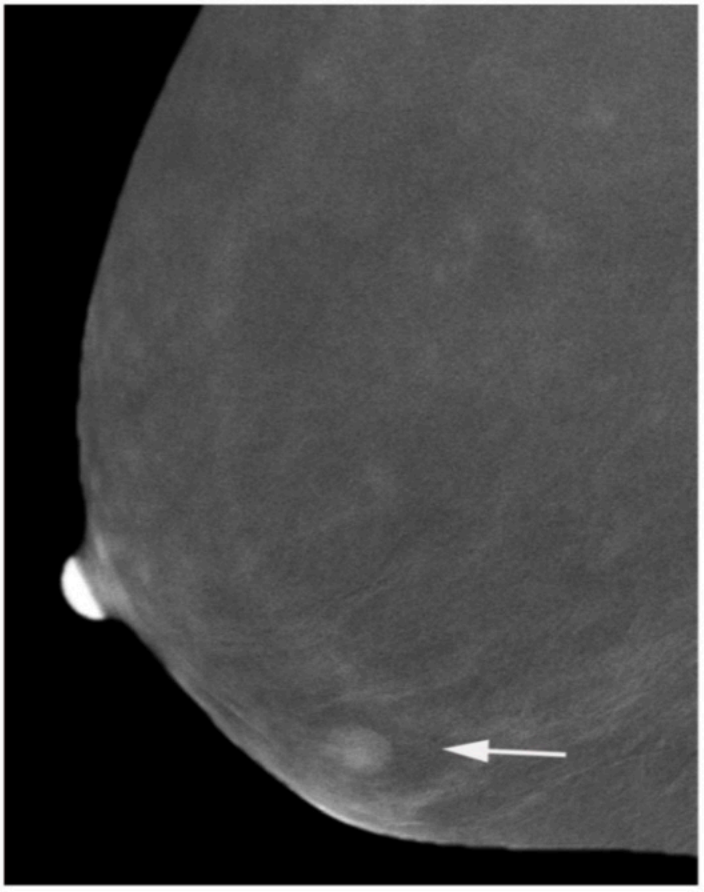

Figure 26 – MARGIN: CIRCUMSCRIBED. Oval CIRCUMSCRIBED mass with homogeneous internal enhancement (arrow). Recombined image. Presumed benign, long-term stability.

C. MASSES ON RECOMBINED IMAGES

2. MARGIN

   a. Non-circumscribed

      i. Indistinct (previously irregular, changed to align with MRI lexicon update)

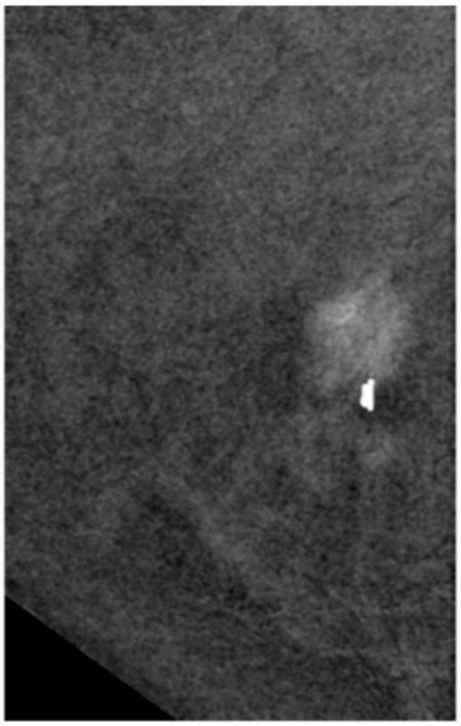

Figure 27 – MARGIN: NON-CIRCUMSCRIBED, INDISTINCT. Irregular, INDISTINCT mass with homogeneous internal enhancement. Recombined image. Pathology: Invasive ductal carcinoma.

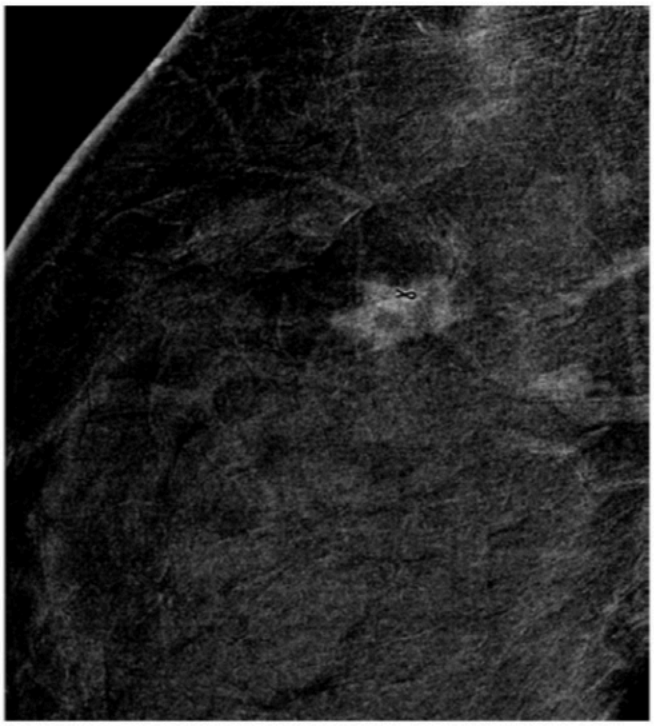

Figure 28 – MARGIN: NON-CIRCUMSCRIBED: INDISTINCT. Irregular, INDISTINCT mass with heterogeneous internal enhancement. Recombined image. Pathology: Invasive ductal carcinoma.

C. MASSES ON RECOMBINED IMAGES

2. MARGIN

b. Non-circumscribed

ii. Spiculated

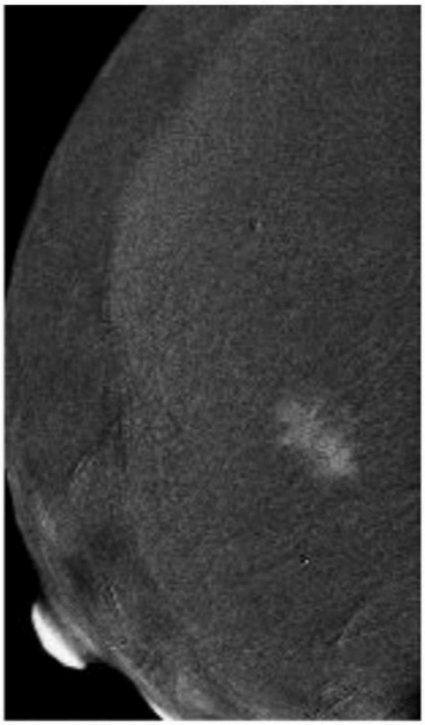

Figure 29 – MASS MARGIN: NON-CIRCUMSCRIBED: SPICULATED. Irregular shape, homogeneous internal enhancement. Recombined image. Pathology: Invasive ductal carcinoma.

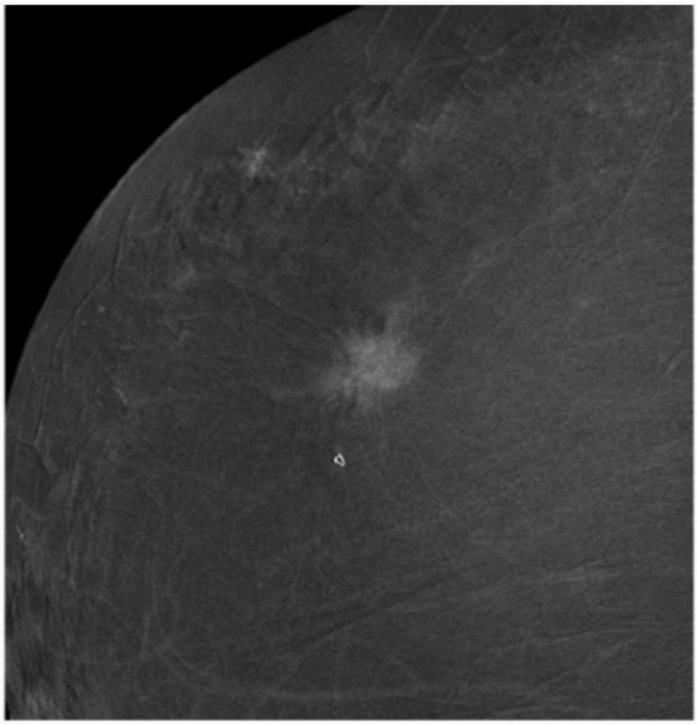

Figure 30 – MASS MARGIN: NON-CIRCUMSCRIBED: SPICULATED. Irregular shape, homogeneous internal enhancement. Recombined image. Pathology: Invasive ductal carcinoma.

C. MASSES ON RECOMBINED IMAGES

3. INTERNAL ENHANCEMENT CHARACTERISTICS

a. Homogeneous



Figure 31 – MASS INTERNAL ENHANCEMENT: HOMOGENEOUS. Oval, circumscribed mass with HOMOGENEOUS internal enhancement. Recombined image. Pathology: Benign papilloma.

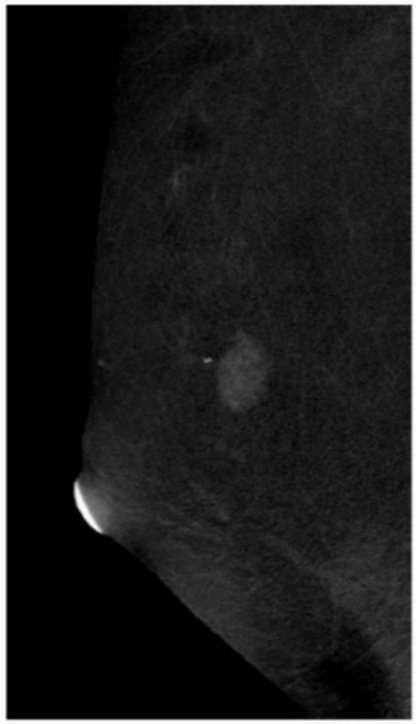

Figure 32 – MASS INTERNAL ENHANCEMENT: HOMOGENEOUS. Oval, circumscribed mass with HOMOGENEOUS internal enhancement. Recombined image. Pathology: Fibroadenoma.

C. MASSES ON RECOMBINED IMAGES

3. INTERNAL ENHANCEMENT CHARACTERISTICS

b. Heterogeneous

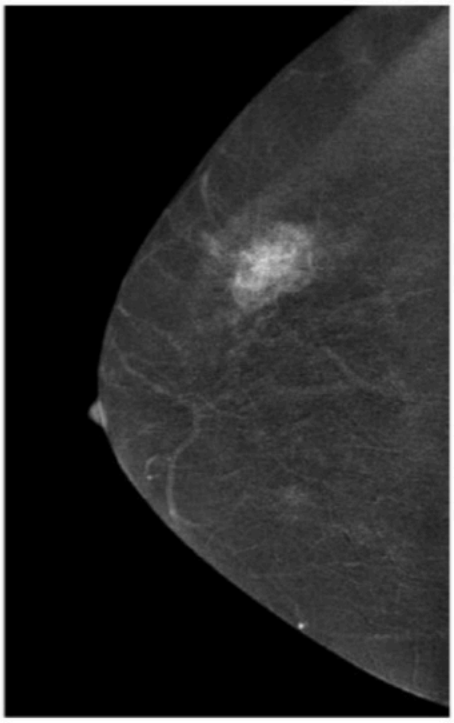

Figure 33 – MASS INTERNAL ENHANCEMENT: HETEROGENEOUS. Oval, indistinct mass with HETEROGENEOUS internal enhancement. Recombined image. Pathology: Invasive ductal carcinoma.

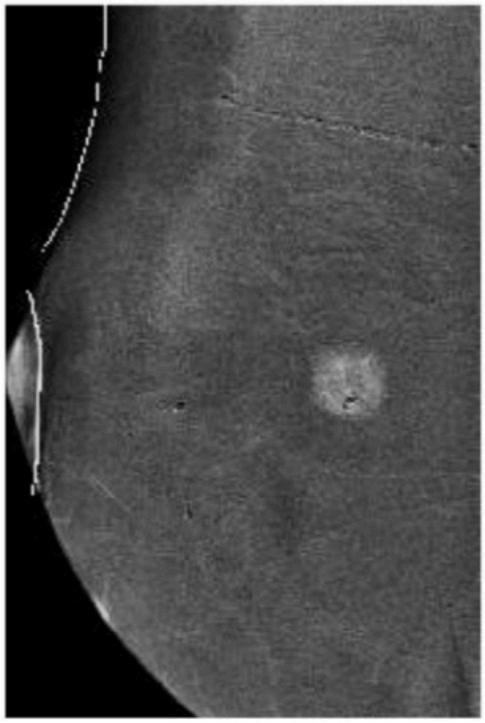

Figure 34 – MASS INTERNAL ENHANCEMENT: HETEROGENEOUS. Round, indistinct mass with HETEROGENEOUS internal enhancement. Recombined image. Pathology: Invasive ductal carcinoma.

C. MASSES ON RECOMBINED IMAGES

3. INTERNAL ENHANCEMENT CHARACTERISTICS

c. Rim Enhancement

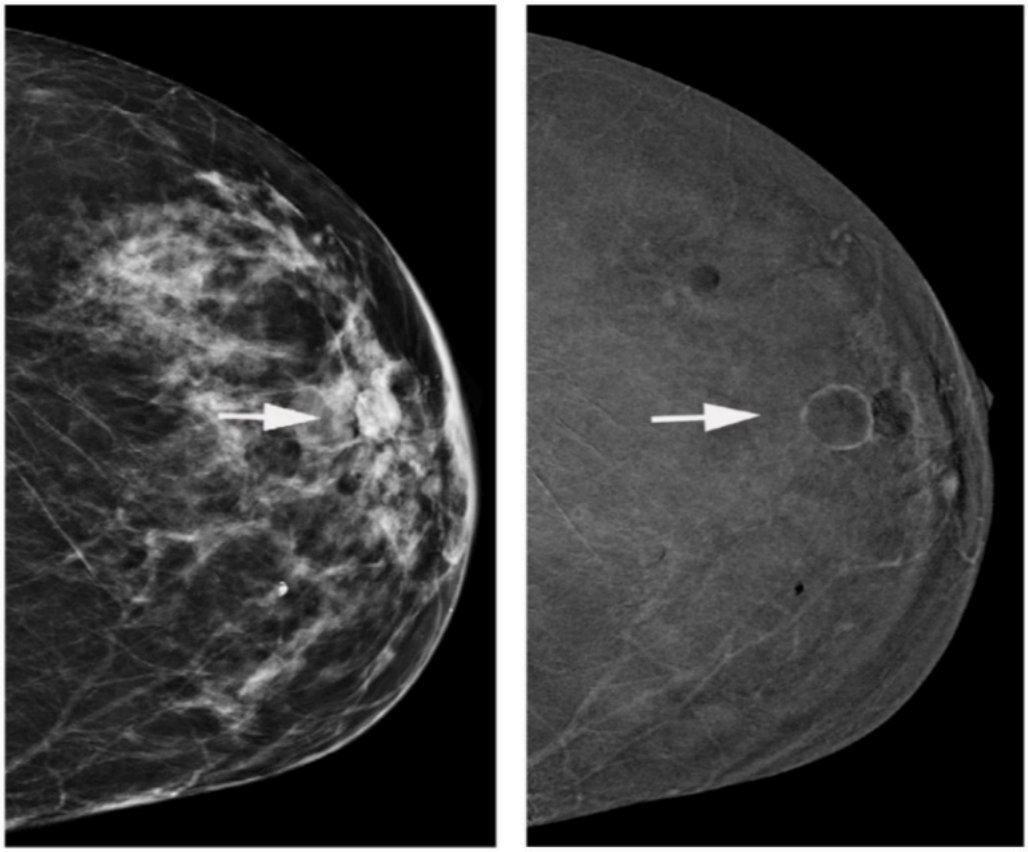

A B

Figure 35 – MASS INTERNAL ENHANCEMENT: RIM ENHANCEMENT. Round, circumscribed mass on (A) LE image and (B) RC image, displaying rim enhancement (arrows). Simple cyst by ultrasound.

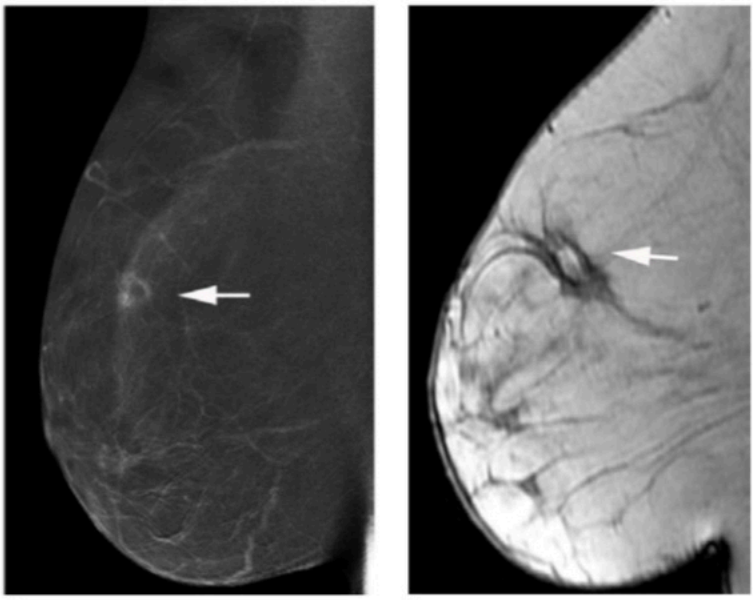

A B

Figure 36 – MASS INTERNAL ENHANCEMENT: RIM ENHANCEMENT. Rim enhancing mass at prior lumpectomy site on recombined image (A) (arrow). Surgery was 18 months earlier. (B) T1 weighted image without fat suppression on MRI shows fat in the mass (arrow). This is a typical benign finding at a lumpectomy site with fat necrosis.

D. NON-MASS ENHANCEMENT (NME)

1. DISTRIBUTION

   a. Diffuse

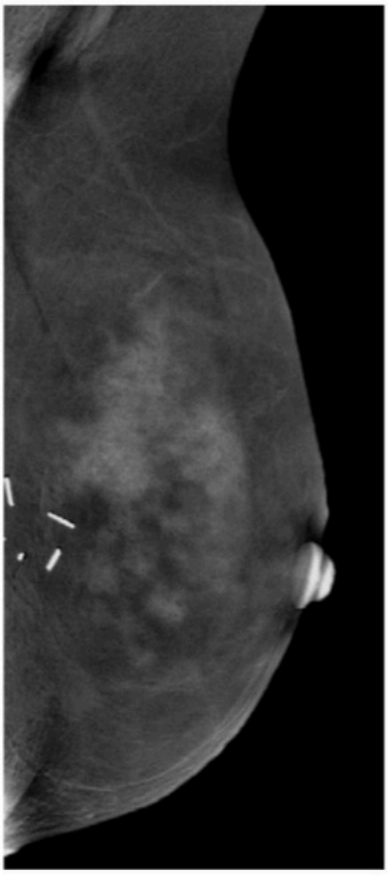

Figure 37 – NON-MASS DISTRIBUTION: DIFFUSE. Patient with prior history of breast cancer and previous lumpectomy and radiation on the left. Recombined image. Pathology: Invasive mammary carcinoma (recurrent).



Figure 38 – NON-MASS DISTRIBUTION: DIFFUSE. No history of surgery or radiation. Minimal enhancement in the right breast (left image). Diffuse non-mass enhancement on the left (right image). This should not be confused with asymmetric background enhancement. Bilateral MLO recombined images. Pathology: Extensive invasive lobular cancer.

D. NON-MASS ENHANCEMENT (NME)

1. DISTRIBUTION

   b. Regional



Figure 39 – NON-MASS DISTRIBUTION: REGIONAL (arrows). Low conspicuity regional non-mass enhancement. This would previously have been described as "multiple regions," but that term was removed from the MRI lexicon as it did not prove useful. Recombined image. Pathology: Multicentric invasive ductal carcinoma and DCIS.

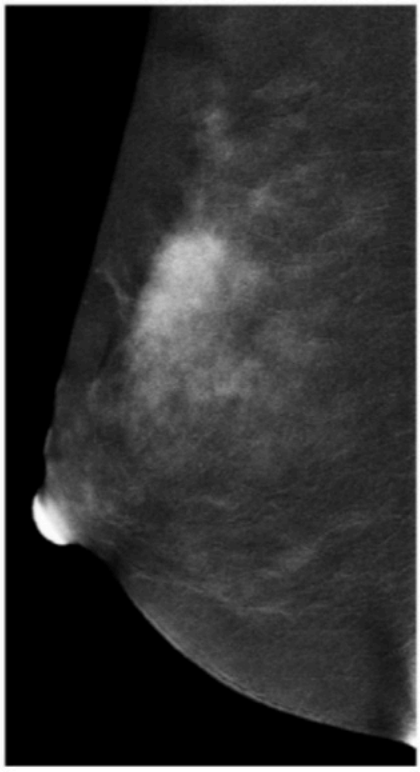

Figure 40 – NON-MASS DISTRIBUTION: REGIONAL. Homogeneous moderate and high conspicuity REGIONAL non-mass enhancement. Recombined image. Pathology: Pseudoangiomatous stromal hyperplasia (PASH).

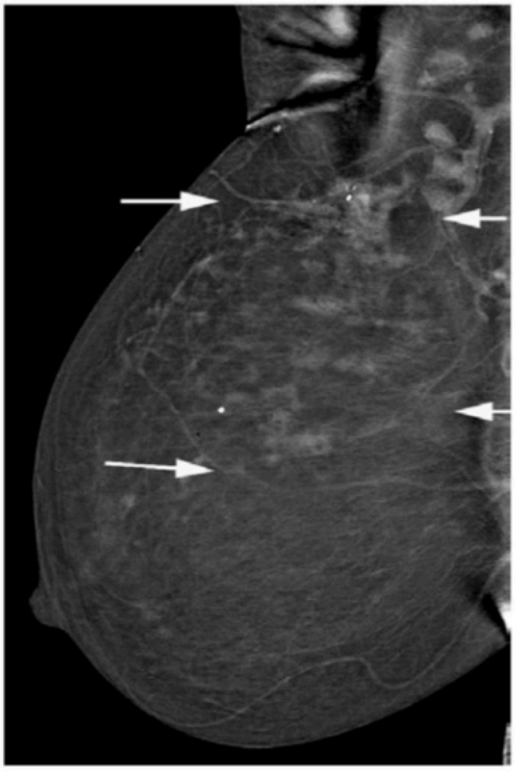

Figure 41 – NON-MASS DISTRIBUTION: REGIONAL (arrows). Clumped REGIONAL non-mass enhancement. Recombined image. Pathology: Invasive ductal carcinoma and DCIS.

D. NON-MASS ENHANCEMENT (NME)

1. DISTRIBUTION

   c. Focal

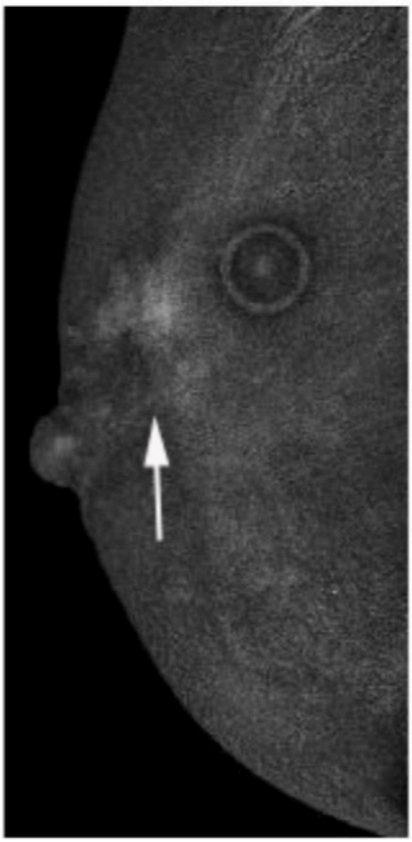

Figure 42 – NON-MASS DISTRIBUTION: FOCAL. FOCAL non-mass enhancement with heterogeneous internal enhancement. Recombined image. Pathology: Invasive ductal carcinoma and DCIS.



Figure 43 – NON-MASS DISTRIBUTION: FOCAL. FOCAL non-mass enhancement with heterogeneous internal enhancement. Recombined image. Pathology: Invasive ductal carcinoma.

D. NON-MASS ENHANCEMENT (NME)

1. DISTRIBUTION

   d. Linear

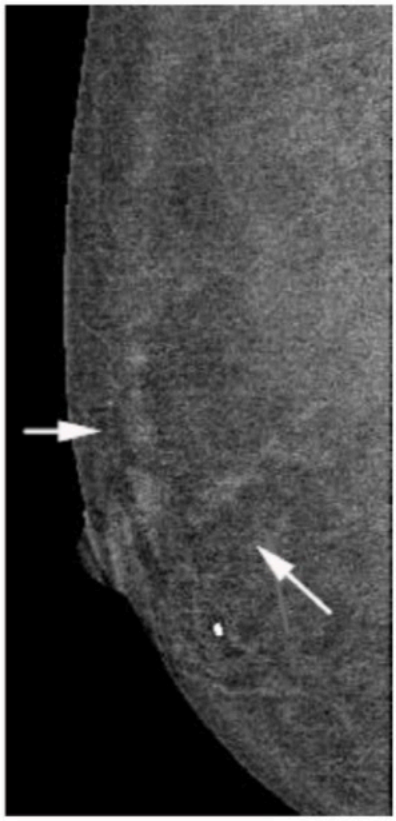

Figure 44 – NON-MASS DISTRIBUTION: LINEAR (arrows). Low conspicuity LINEAR non-mass enhancement. Recombined image. Pathology: DCIS.

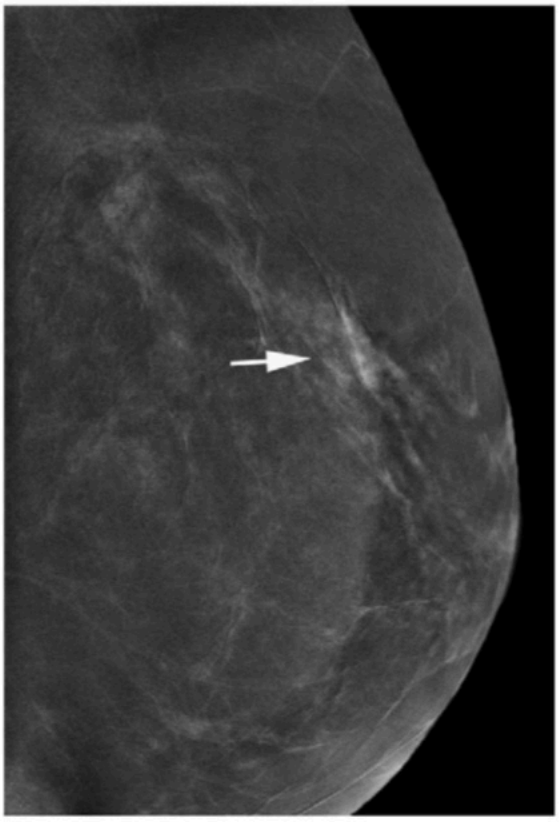

Figure 45 – NON-MASS DISTRIBUTION: LINEAR (arrow). Recombined image. Pathology: DCIS with microinvasion.

D. NON-MASS ENHANCEMENT (NME)

1. DISTRIBUTION

   e. Segmental

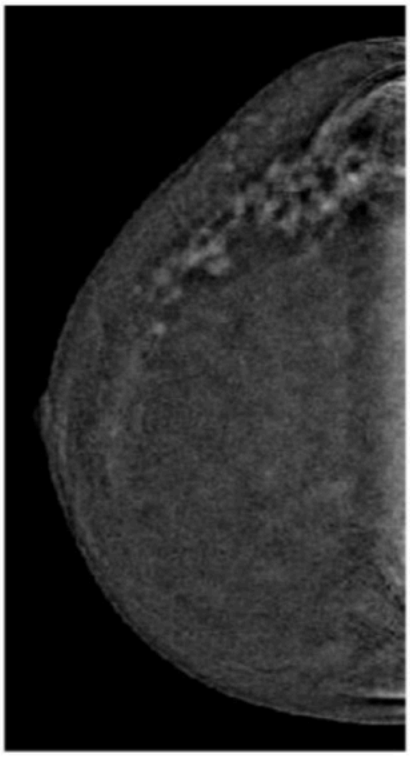

Figure 46 – NON-MASS DISTRIBUTION: SEGMENTAL. Clumped SEGMENTAL non-mass enhancement. Recombined image. Pathology: Invasive lobular carcinoma.

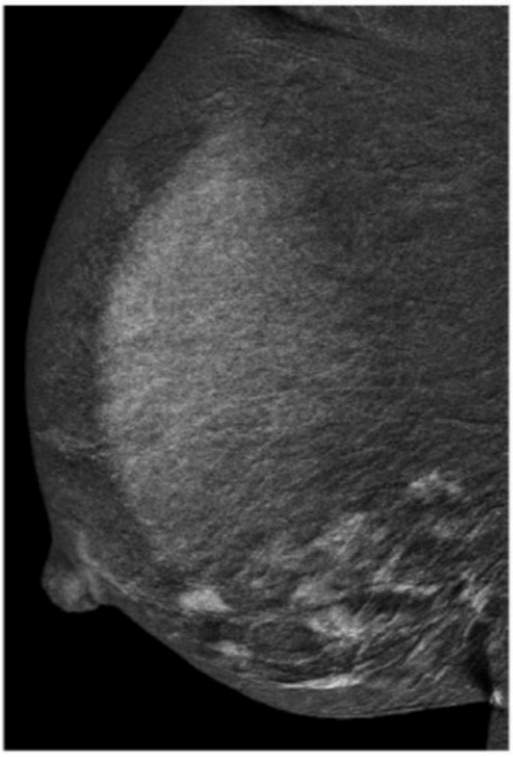

Figure 47 – NON-MASS DISTRIBUTION: SEGMENTAL: Clumped SEGMENTAL non-mass enhancement. Recombined image. Pathology: Invasive lobular carcinoma.

D. NON-MASS ENHANCEMENT (NME)

2. INTERNAL ENHANCEMENT CHARACTERITICS

a. Homogeneous

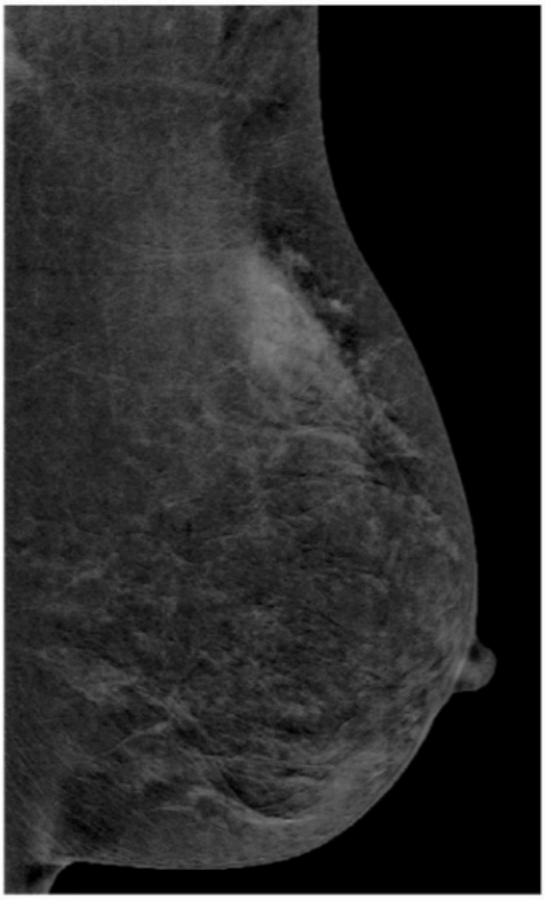

Figure 48 – NON-MASS INTERNAL ENHANCEMENT: HOMOGENEOUS. HOMOGENEOUS regional non-mass enhancement. Recombined image. Benign based on long term stability.

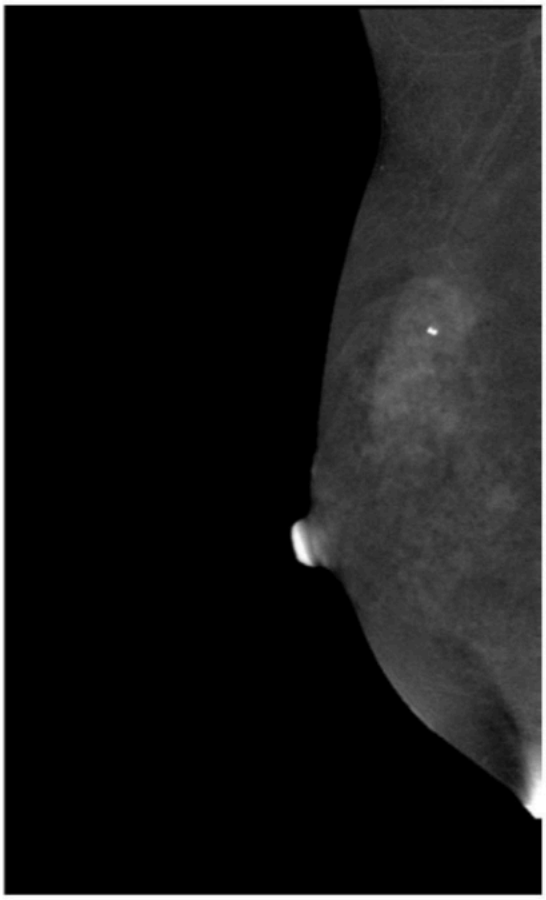

Figure 49 – NON-MASS INTERNAL ENHANCEMENT PATTERN: HOMOGENEOUS. HOMOGENEOUS segmental moderate conspicuity non-mass enhancement. Recombined image. Pathology: Invasive ductal carcinoma.

D. NON-MASS ENHANCEMENT (NME)

2. INTERNAL ENHANCEMENT CHARACTERITICS

   b. Heterogeneous

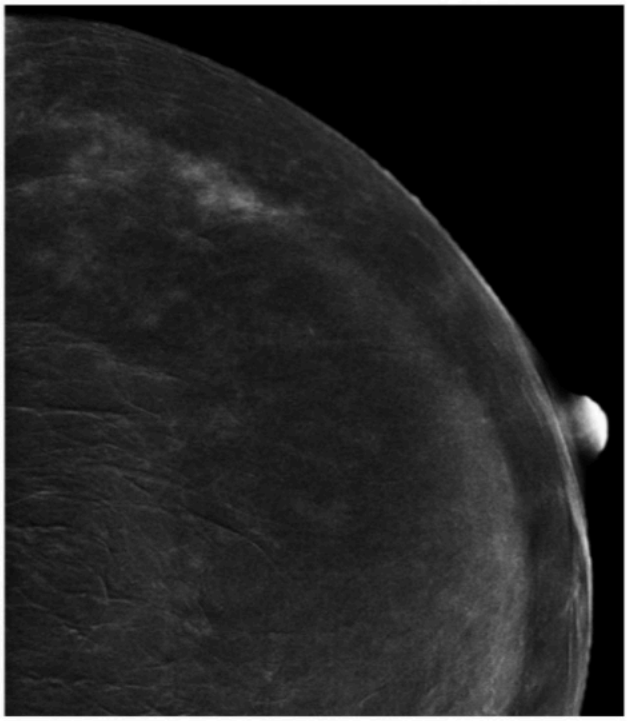

Figure 50 – NON-MASS INTERNAL ENHANCEMENT PATTERN: HETEROGENEOUS. HETEROGENEOUS segmental non-mass enhancement. Recombined image. Pathology: DCIS with microinvasion.

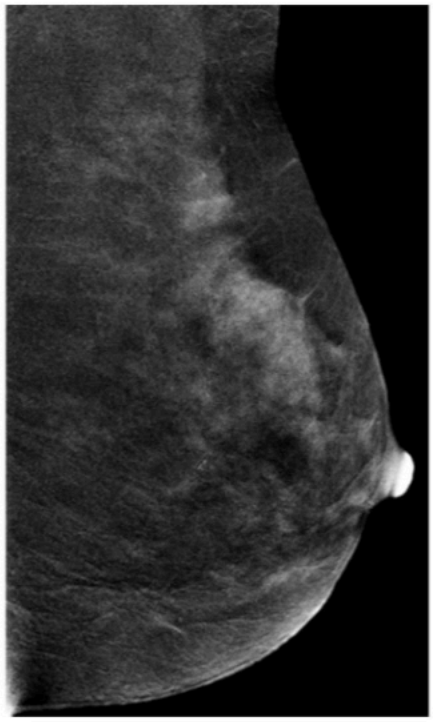

Figure 51 – NON-MASS INTERNAL ENHANCEMENT PATTERN: HETEROGENEOUS. HETEREGENEOUS segmental non-mass enhancement. Recombined image. Pathology: Invasive ductal carcinoma.

D. NON-MASS ENHANCEMENT (NME)

2. INTERNAL ENHANCEMENT CHARACTERITICS

c. Clumped

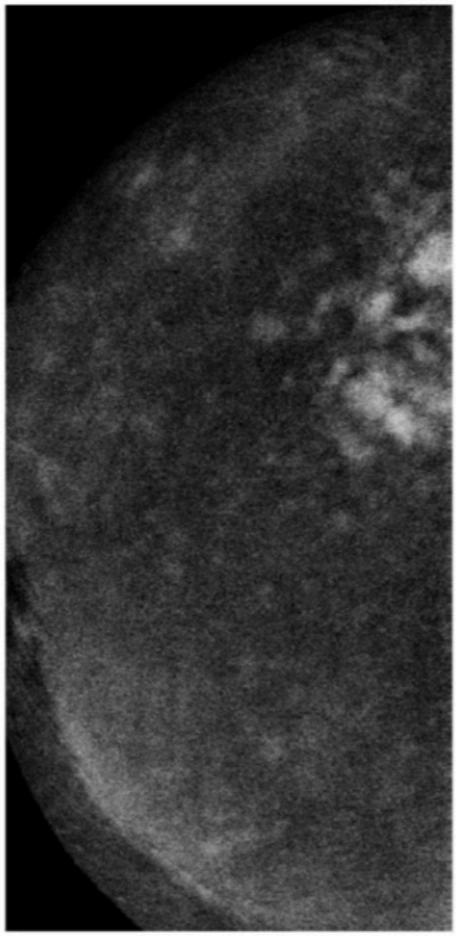

Figure 52 – NON-MASS INTERNAL ENHANCEMENT PATTERN: CLUMPED. CLUMPED, regional, high conspicuity non-mass enhancement. Recombined image. Pathology: Invasive ductal carcinoma.



Figure 53 – NON-MASS INTERNAL ENHANCEMENT PATTERN: CLUMPED. CLUMPED segmental non-mass enhancement. Recombined image. Pathology: Invasive lobular carcinoma.

E. ENHANCING ASYMMETRY

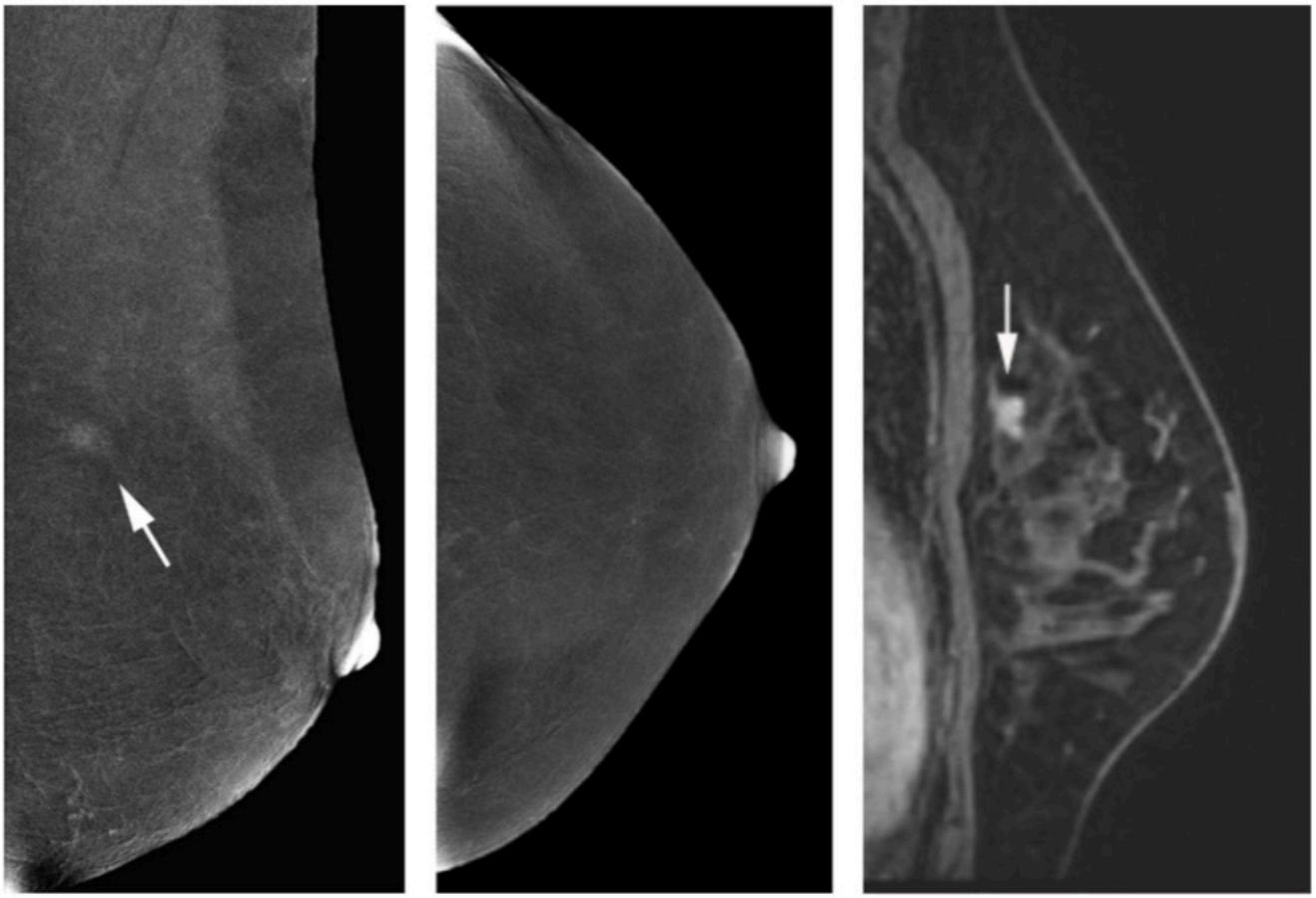

A B C

Figure 54 – ENHANCING ASYMMETRY – Seen only on left MLO recombined image (A) (arrow), not seen on the left CC (B). The finding is confirmed as an enhancing mass on post-contrast T1-weighted MRI sagittal image (C) (arrow). Pathology: Invasive ductal carcinoma.

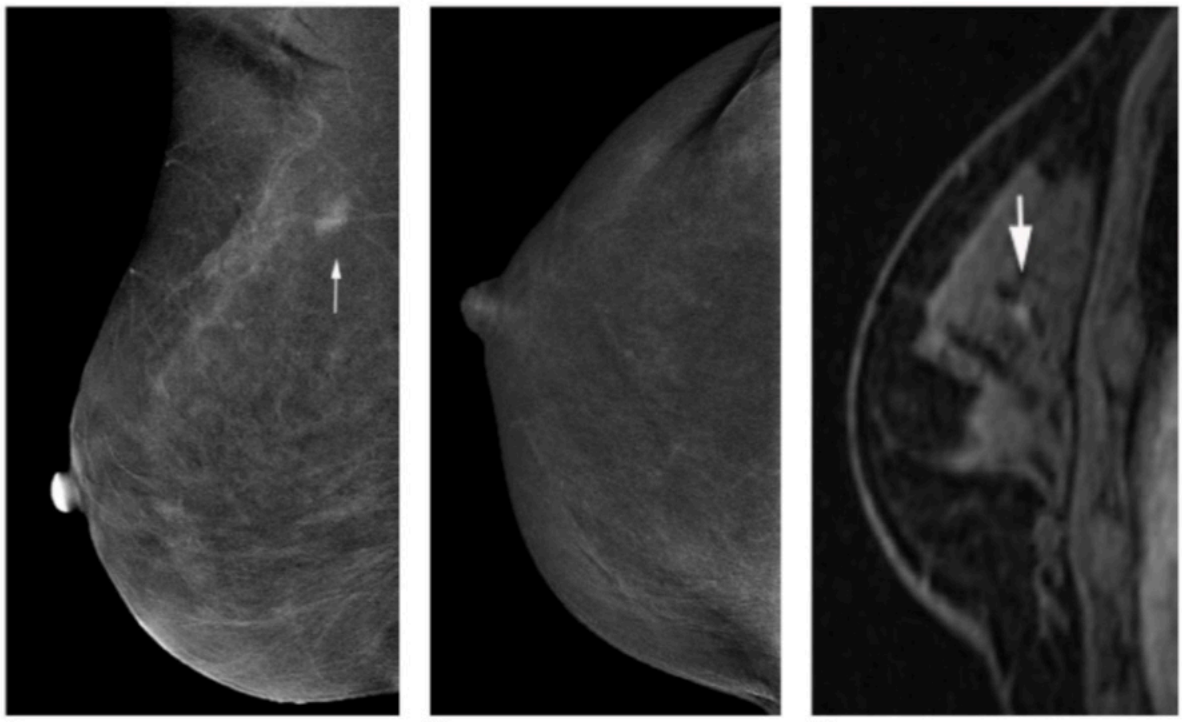

A B C

Figure 55 – ENHANCING ASYMMETRY. This is seen only on right MLO recombined image (A) (arrow) and not on the corresponding CC recombined image (B), perhaps because of posterior location. The finding is subtly seen as enhancing mass on post-contrast T1 weighted MRI sagittal image (C) (arrow). Pathology: Invasive ductal carcinoma.

F. ABNORMALITY SEEN ON BOTH LOW ENERGY AND RECOMBINED IMAGES

1. MASS

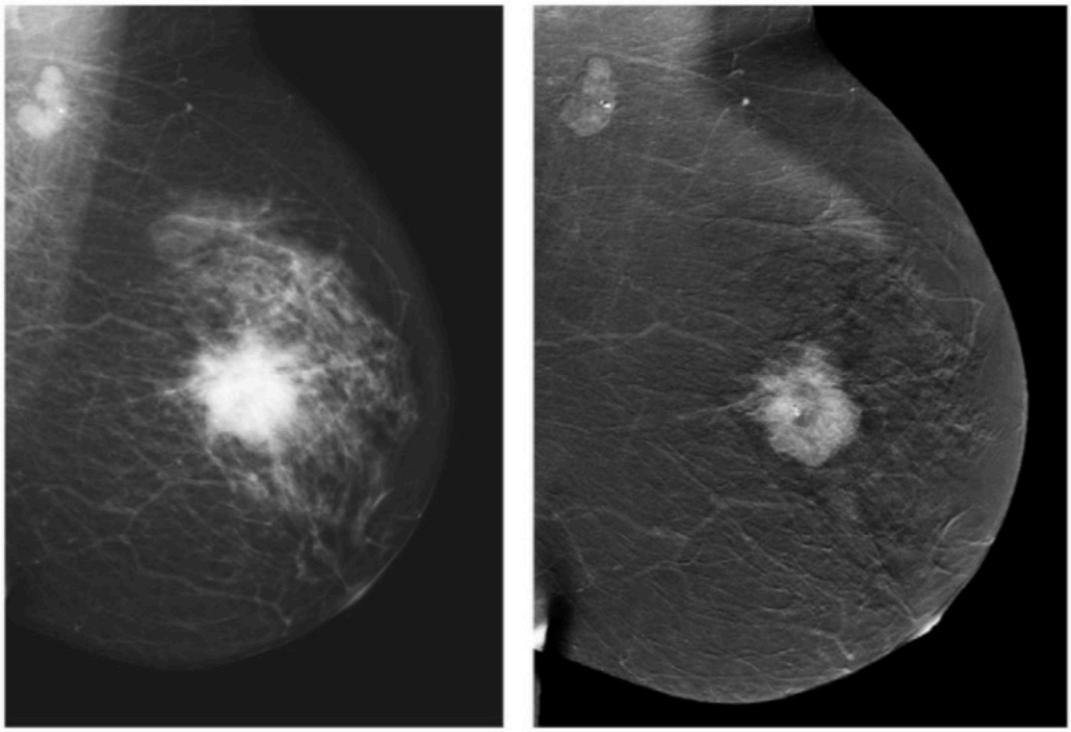

A B

Figure 56 – ABNORMALITY SEEN ON BOTH LOW ENERGY AND RECOMBINED IMAGES: MASS. The low energy (LE) image (A) shows a round, high density, spiculated mass. On the recombined image (RC) (B), the mass shows heterogeneous internal enhancement. When a mass is seen on both the LE and RC images, shape and margin should be described according to the mammography lexicon. It is not necessary to separately describe the shape and margin on the RC image. Internal enhancement and, if desired, conspicuity can be described. Pathology: Invasive ductal carcinoma.

F. ABNORMALITY SEEN ON BOTH LOW ENERGY AND RECOMBINED IMAGES

2. ARCHITECTURAL DISTORTION

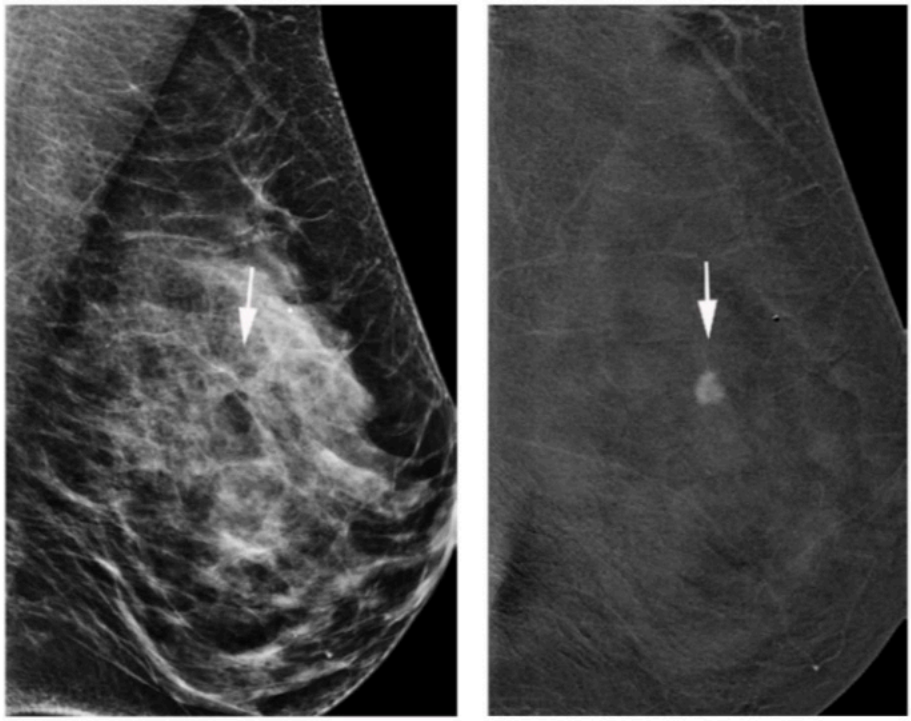

A B

Figure 57 – ABNORMALITY SEEN ON BOTH LOW ENERGY AND RECOMBINED IMAGES: ARCHITECTURAL DISTORTION. On LE image (A) there is an architectural distortion (arrow). Recombined LMLO image (B) shows focal non-mass enhancement with heterogeneous enhancement (arrow). If the finding on the LE image is anything other than a mass, terms from the mammography lexicon should be used to describe the LE finding and terms from the CEM lexicon should be used to describe the enhancement on RC image. Pathology: Invasive ductal carcinoma.

F. ABNORMALITY SEEN ON BOTH LOW ENERGY AND RECOMBINED IMAGES

3. CALCIFICATIONS

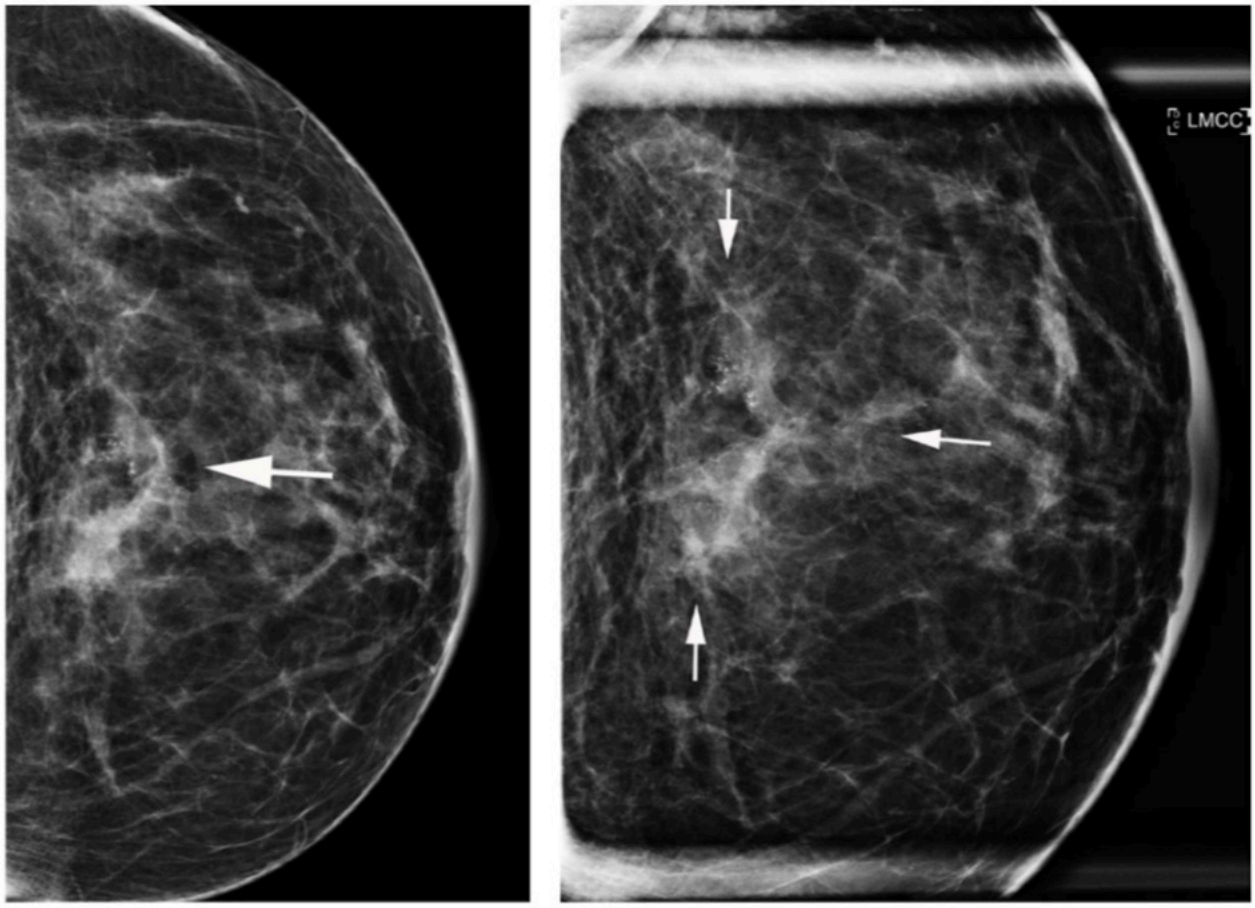

A B

Figure 58 – ABNORMALITY SEEN ON BOTH LOW ENERGY AND RECOMBINED IMAGES: CALCIFICATIONS. On low energy CC magnification view (A), regional fine pleomorphic calcifications with an associated asymmetry seen (arrow). On recombined image (B) the finding manifests as regional non-mass enhancement (arrows).

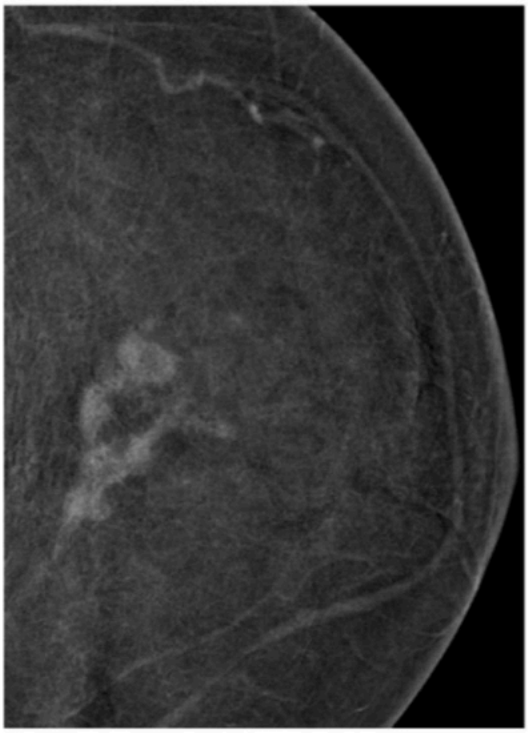

C

Figure 58 – *(Continued)* ABNORMALITY SEEN ON BOTH LOW ENERGY AND RECOMBINED IMAGES: CALCIFICATIONS. On recombined image (C) regional non-mass enhancement is demonstrated. Pathology: DCIS.

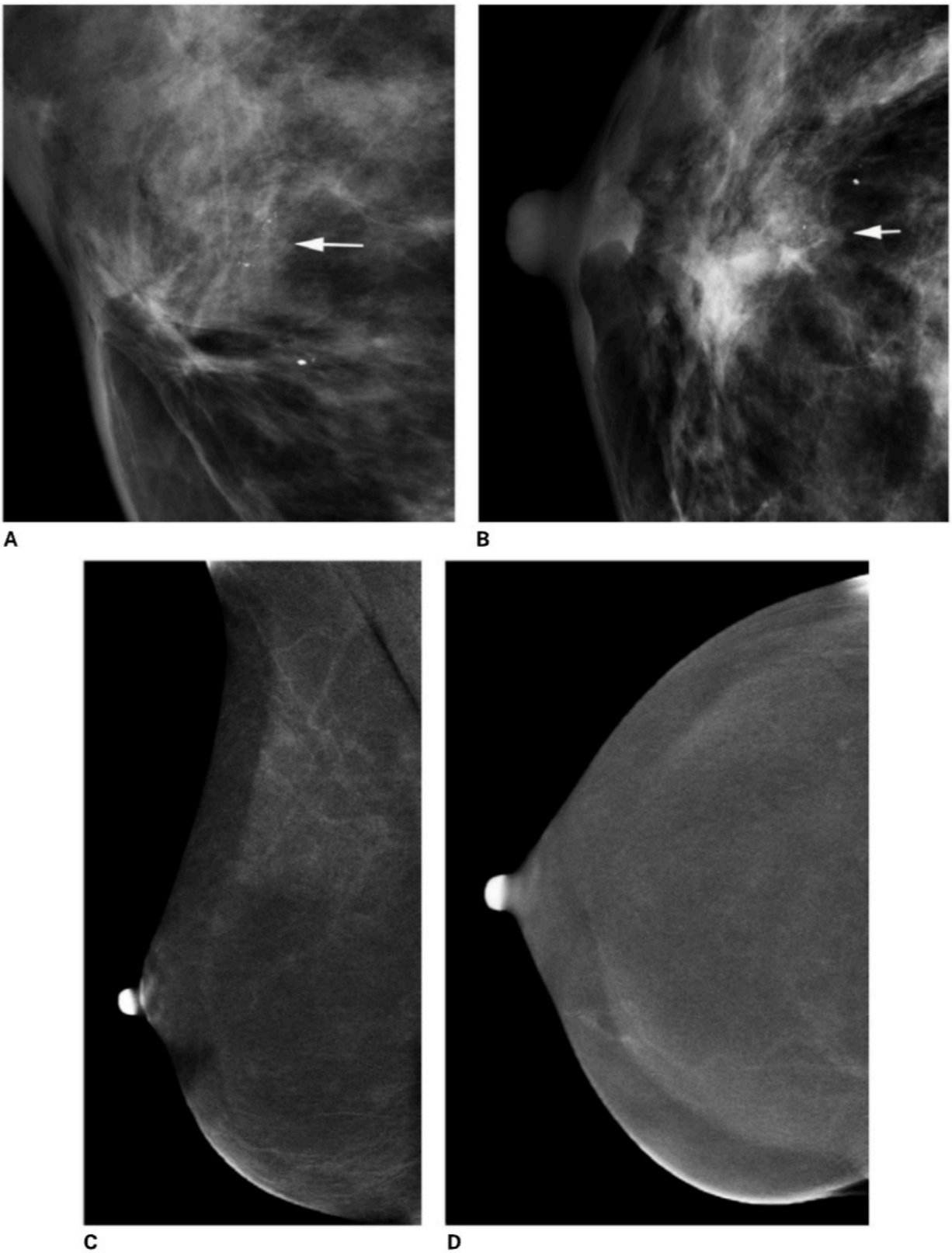

Figure 59 – ABNORMALITY ON LOW ENERGY BUT NOT RECOMBINED IMAGE: CALCIFICATIONS. Magnification ML (A) and CC (B) views show grouped amorphous calcifications (arrows). No abnormal enhancement seen on recombined MLO (C) or CC (D) images. Pathology: DCIS with microinvasion.

IV. REPORTING SYSTEM

A. ASSESSMENT CATEGORIES

1. ASSESSMENT IS INCOMPLETE

Category 0: Incomplete

Amendments to the MQSA regulations, which took effect on Sept. 10, 2024, resulted in the creation of two new assessment categories under category 0 (replacing the previous combined descriptive verbiage of "Category 0: Incomplete: Need Additional Imaging Evaluation and/or Prior Imaging for Comparison"). The two new categories are: **Category 0: Incomplete: Need additional imaging evaluation**, used to indicate that the examination is incompletely evaluated, and the recommendation is for additional imaging evaluation (i.e., supplementary mammographic views and/or US); and **Category 0: Incomplete: Need prior mammograms for comparison**, to be used if retrieval of previous examinations for comparison is indicated before a final assessment can be rendered.

A Category 0: Incomplete: Need additional imaging evaluation assessment is almost always used in a screening situation to indicate an abnormal screening examination that is not definitively negative (category 1) or benign (category 2). This reflects the binary nature of screening assessments (positive versus negative) and management recommendations (routine screening versus prompt action). Even when a suspicious abnormality is clearly demonstrated on a screening examination, a category 0 assessment should be used, indicating the need for a complete diagnostic examination to more accurately evaluate the extent of potential disease prior to biopsy. The use of category 0 assessments for all abnormal screening examinations emphasizes that the abnormal interpretation rate should reflect even those screening examinations with findings sufficiently abnormal to justify tissue diagnosis. Once the diagnostic imaging is completed, a final assessment is rendered for the diagnostic examination, but the screening mammography examination remains assessed as category 0.

The use of category 0 for CEM in the diagnostic setting is discouraged, particularly if the finding is seen on the LE images, unless the examination is read off-line, and the patient needs to be recalled for the additional imaging. For these cases, the CEM is analogous to a screening mammogram and the use of BI-RADS 0 is appropriate. Under rare circumstances, this assessment category may be used in a diagnostic mammography report if the diagnostic evaluation was not fully completed (e.g., a patient electively leaves a facility prior to completing the mammographic views or diagnostic ultrasound). A recommendation for additional imaging evaluation may include the use of spot compression or magnification or other special mammographic views, and/or US.

Additionally, unlike MRI, where most of the information needed to make a final assessment is included in the standard protocol for the exam, this is not necessarily true for CEM, and there will be cases for which additional imaging with MRI will be necessary to make a final assessment. This generally pertains to findings seen on the recombined images only and not seen on the LE images or ultrasound which cannot be fully characterized based on the RC images alone. For these cases, a category 0 assessment may be most appropriate.

Keep in mind that there are problems associated with the use of category 0. If category 0 is assigned and the patient does not have the recommended additional imaging, or if the additional imaging is not correlated with the CEM findings, a significant abnormality may be missed.

If category 0 is assigned, the type of recommended additional imaging should be clearly stated in the report. Subsequent management should also be included in the report, should the additional imaging prove to be negative. For example, if there is an enhancing mass on the RC images with negative LE images and ultrasound or MRI is recommended, the report should state what should be done if the subsequent imaging is negative. If a suspicious enhancing lesion is seen on CEM but CEM-biopsy capability is not available and MRI is needed to direct the biopsy, the case should be assigned a BI-RADS category 4 or 5, not BI-RADS category 0. This situation is analogous to a suspicious finding on MRI for which biopsy is warranted but for which targeted ultrasound is recommended to attempt to identify a correlate. If the abnormality is not seen on MRI, further management can then be decided based on the findings on both the CEM and MRI. Giving these cases an assessment of 4 or 5 decreases the possibility of a suspicious finding on CEM falling through the cracks.

Facilities utilizing a Category 0: Incomplete: Need prior mammograms for comparison assessment when awaiting prior mammograms should have a tracking procedure in place guaranteeing 100% reliability that a final assessment will be made within 30 days (preferably sooner), even if prior examinations do not become available. Some practices may reasonably choose never to use category 0 in the context of awaiting prior examinations if they do not have a 100% reliable tracking procedure and rather elect to hold the case for reporting until it is determined if prior exams can be made available. If an "Incomplete — Need prior breast examinations for comparison" report is issued while awaiting prior examinations, an addendum to the initial mammography report should be released once prior examinations become available, and the incomplete assessment replaced by a final assessment once the comparison is made.

Proper procedures for the auditing of category 0 assessments are described in detail in the Auditing and Outcomes Monitoring section of the Manual. As with other imaging modalities, there should be a mechanism in place to resolve cases assigned a BI-RADS category 0.

2. ASSESSMENT IS COMPLETE – FINAL ASSESSMENT CATEGORIES

Category 1: Negative

There is nothing to comment on. This is a normal examination. Category 1 includes a normal description of breast composition and the degree of BPE. It should be emphasized that BPE is a normal finding, and short-term follow-up is not necessary to assess BPE for stability.

Category 2: Benign

Like category 1, this is a normal assessment, but in these cases the interpreter chooses to describe a benign finding such as intramammary lymph node, implants, metallic foreign bodies (such as core biopsy and surgical clips), enhancing and non-enhancing fibroadenomas, cysts, old non-enhancing scars, or recent scars; postoperative collections, fat-containing lesions (such as oil cysts, lipomas, galactoceles, and hamartomas). The interpreter may choose not to describe such findings, in which case the examination should be assessed as negative (category 1). Both category 1 and 2 assessments indicate that there is no evidence of malignancy. The difference is that category 2 should be used when describing one or more specific benign findings in the report, whereas category 1 would be used when such findings are not described (even if they are present).

Category 3: Probably Benign

A finding assessed using this category should have a ≤ 2% likelihood of malignancy but greater than the essentially 0% likelihood of malignancy of a characteristically benign finding. Typical findings on mammography that are appropriately assigned a probably benign

assessment are well established. For findings seen only on the recombined images, however, there is no data to guide which lesions fall into this category. In the absence of data, the use of category 3 for RC image findings remains intuitive.

BPE, a benign finding on nearly all CEM examinations, should not be the reason for a probably benign assessment.

In general, a BI-RADS category 3 assessment should not be given directly from a screening CEM study, as is the case for standard screening mammography. Ideally, any finding or questionable finding should be fully worked up before a category 3 assessment is assigned. However, given the lack of data concerning BI-RADS category 3 assessments on CEM, there may be instances where it is used without the addition of further imaging evaluation.

Recommendations will likely undergo future modifications as more data accrue regarding the validity of using category 3 assessments for CEM, the follow-up interval required, and the type of findings that warrant this assessment.

Careful auditing of the use of category 3 assessments should be performed and publication of outcomes data is strongly recommended.

Category 4: Suspicious

This category is used for findings that have > 2% but < 95% chance of malignancy and for which biopsy is recommended. Thus, almost all recommendations for breast interventional procedures will come from assessments made using this assessment category. In CEM, assessment category 4 is not currently divided into subcategories 4A, 4B, and 4C.

Category 4 is used for the majority of findings for which tissue diagnosis is desired. These biopsies can usually be performed percutaneously, by CEM, US, MRI or stereotactic guidance.

In many patients with a suspicious finding on the RC image only, targeted US will identify a corresponding abnormality so that US-guided biopsy can be performed. US-guided biopsies are faster, more comfortable for the patient, and more cost effective than CEM- or MRI-guided biopsies so should be the chosen method when possible. If CEM-directed biopsy is not available and the RC-only finding is not visible on US, then an MRI-guided biopsy may be required. If the finding that was deemed suspicious on CEM is not visible by MRI, follow-up CEM may be reasonable, similar to suspicious MRI findings that are not visible on MRI at the time of attempted MRI-guided biopsy. If the interpreter feels that the CEM finding is sufficiently suspicious to warrant an attempt at biopsy despite a negative MRI, and if CEM-guided biopsy is not available, biopsy using landmarks on the LE images could be attempted.

Category 5: Highly Suggestive of Malignancy

These assessments carry a very high probability (≥ 95%) of malignancy. This category initially was established to include lesions for which 1-stage surgical treatment was considered without preliminary biopsy. Given the widespread acceptance of imaging-guided percutaneous biopsy, 1-stage surgery is rarely performed. Therefore, the current rationale for using a category 5 assessment is to identify lesions for which any non-malignant percutaneous tissue diagnosis is considered discordant, resulting in a recommendation for repeat (usually surgical) biopsy.

No single CEM descriptor is sufficiently predictive of malignancy to produce the ≥ 95% probability required for a category 5 assessment. Just as in mammography and US, an appropriate combination of suspicious findings is needed to justify a category 5 assessment at CEM. It is recommended that category 5 assessments be audited separately to verify a ≥ 95% PPV, thereby validating that the assessment is not being overused.

Category 6: Known Biopsy-Proven Malignancy

This category is reserved for examinations performed after biopsy proof of malignancy (imaging performed after percutaneous biopsy) but prior to definitive local therapy (usually surgical removal) in which there are no abnormalities other than the known cancer present that might need additional evaluation. That is, a cancer diagnosis has already been established, a lesion is depicted at CEM, and this lesion corresponds to the previously biopsied cancer.

In the setting of CEM after neoadjuvant chemotherapy, if no abnormal enhancement is seen, the case should still be assigned a BI-RADS category 6 because surgery (or other definitive local therapy) is still the standard of care despite an apparent imaging response as determined by imaging.

Post-Procedure Mammogram for Marker Placement

The 2023 Amendments to the MQSA Regulations added another assessment category: "Post-Procedure Mammogram for Marker Placement." This assessment was derived from the prior 2003 alternate standard and is to be used on mammograms whose specific purpose is to delineate the presence of a tissue marker, exempting it from requirements for auditing, as with the "Known Biopsy-Proven Malignancy" category. An accompanying numerical code has not been assigned by ACR to this assessment category.

B. REPORT ORGANIZATION

The reporting system should be concise and organized and include any pertinent clinical history that may affect interpretation of the examination. The report should include a description of the amount of fibroglandular tissue and the degree of background parenchymal enhancement (BPE). Significant findings on the LE and on the RC images should be described and an assessment rendered based on the most suspicious finding. For any given finding, it is important to state clearly whether it is seen on the LE images only, the RC images only, or both.

Table 2. Report Organization

1.	Indication for examination
2.	Comparison to previous examination(s)
3.	CEM technique
4.	Breast density and BPE
5.	Clear description of any important findings
6.	Assessment
7.	Management recommendations

1. INDICATION FOR EXAMINATION

New to this version of BI-RADS are structured categories for the major clinical indications for breast imaging, with associated optional subcategories and relevant clinical histories. These structured categories should be used when creating reports for all modalities. Use of structured indications (outlined below) is recommended to aid in achieving report clarity and outcomes monitoring, including method of cancer detection.

A brief but specific description of the indication for examination is provided. If the exam is being done for screening of a patient who is at higher than average risk for breast cancer, the specific attribute that increases her risk should be stated (i.e. personal history, family history, previous ADH etc.). CEM has been reported to be superior to 2D mammography for detecting

cancers in women at intermediate increased risk of breast cancer, including women with a personal history, previous biopsy-proven atypia or LCIS, family history, or extremely dense breasts. For diagnostic exams, indications may include those for which MRI is used, including determination of extent of newly diagnosed breast cancer or response to neoadjuvant chemotherapy. In general, however, MRI is recognized as being superior to CEM for detecting unsuspected breast cancer and in very high risk patients such as those who are known BRCA mutation carriers, MRI is still the modality of choice. CEM can be considered for these patients when there is a contraindication to MRI.

Table 3. Structured Exam Indications

Major Indication	Optional Subcategory Indication	Relevant History to Report, if known
Asymptomatic Screening	• Elevated risk • Dense breasts • Prior breast cancer, treatment completed • Other	• Gene mutation • Estimated cancer risk • Prior breast cancer history
Diagnostic Work-up	• Clinical findings • Imaging findings • Follow-up category 3 • Follow-up after biopsy • Implant assessment • Other	• Clinical finding type • Imaging finding type
Diagnostic: Current Breast Cancer	• Extent of disease before treatment/ therapy • Response during or after neoadjuvant therapy • Other	• Location and size of cancer on prior imaging evaluation

2. COMPARISON TO PREVIOUS EXAMINATION(S)

   A statement indicating that the current examination has been compared to previous examination(s) and the dates of previous exams reviewed is recommended. “Baseline exam” can be specified when it is the patient’s first mammogram. It should also be stated if the comparison is to prior CEM or standard mammography. If the patient has undergone prior imaging but the images are not available for comparison, it is recommended to indicate that in the report.

3. CEM TECHNIQUE

   Give a brief description of the protocol:

   a. Laterality (right, left, bilateral) and views.

   b. Name of contrast agent

   c. Dosage (mmol/kg) and volume (in cc)

   d. Presence or absence of complications/contrast reaction; if there is a reaction, include a description of the reaction, management and disposition of the patient. Contrast reactions and recommendations for further management should also be detailed in the final recommendation section to be certain it is noted by the referring clinician.

4. BREAST DENSITY AND BPE

This should include an overall description of the breast composition as determined by the LE images.

Table 4. Breast Density Categories[1]

(A) The breasts are almost entirely fatty
(B) There are scattered areas of fibroglandular density
(C) The breasts are heterogeneously dense, which may obscure small masses
(D) The breasts are extremely dense, which lowers the sensitivity of mammography

[1] In July 2025, the FDA approved an alternative standard that would allow the interpreting physician to provide an overall assessment of breast density that is phrased in the singular phrasing. The singular phrasing is intended to be used in reports of unilateral mammograms. Please see the Mammography Guidance section #10 for more information.

The amount of background parenchymal enhancement on the recombined images should be reported:

a. Minimal

b. Mild

c. Moderate

d. Marked

On bilateral examinations, describe whether the pattern is asymmetric or symmetric, if appropriate.

If an implant is present, it should be stated in the report. Note that CEM has not been studied in patients with implants and like standard mammography is not accurate for assessment of silicone implant integrity.

5. CLEAR DESCRIPTION OF ANY IMPORTANT FINDINGS

Significant findings on the LE and RC images should be reported and correlated. If there is an abnormality on the LE images, a statement as to whether it is seen on the RC images and vice versa should be included. When there is a finding on the LE images, descriptors using the mammography lexicon should be used. When there is a finding on the RC images descriptors as outlined in the CEM lexicon section should be used. If the finding is present on both the LE and RC images, descriptors of both using the lexicon should be reported.

Abnormal enhancement is unique and separate from BPE. Its description should indicate the breast in which the abnormal enhancement occurs, the lesion type, and modifiers.

The report of any significant finding should include:

a. Size of finding

b. Location

   i. Laterality should be indicated.

   ii. Location- Quadrant and/or clock face should be reported. Quadrants refer to smaller sub-divisions of the breast, including upper outer, upper inner, lower outer, and lower inner portions of the breast. Some additional location descriptors that do not conform to a quadrant include central (deep to the nipple on all views, middle to posterior depth), retroareolar (deep to the nipple on all views, anterior depth), axillary tail

(upper outer quadrant adjacent to axilla), and axilla. Clock face is oriented based on the patient facing the observer and should be specified using a whole number. For example, 3:00 is in the lateral left breast and the medial right breast. For some large one-view findings, it may not be possible to specify a quadrant or clock face. In these situations, a hemisphere descriptor should be used: upper, lower, inner, or outer.

iii. Depth or distance from the nipple - Describe the location based on depth (anterior, middle, posterior) or distance from the nipple in whole centimeters (e.g., 2 cm from the nipple, not 2.3 cm from the nipple). Using smaller distance increments implies a higher level of precision than is possible across readers and modalities. If findings are between whole cm locations, the closest whole cm location should be selected and used.

Measure the distance from the nipple from the base of the nipple to the center of the finding, on the same image if both are visible. If the finding is close to the nipple, it is important to describe how far the anterior extent of the imaging finding is from the nipple to assist with surgical planning. If the finding is large, distance to its anterior and posterior extents can also be included, to assist with surgical planning.

If the findings are close to the skin, pectoralis muscle or chest wall, describe the distance of the findings to these structures. Due to differences in patient positioning and other technique factors, distance from the nipple, skin, pectoralis muscle and chest wall may vary across modalities. It may be helpful to describe the anatomic zone where the finding lies to facilitate lesion identification when correlating among modalities. For example, noting that a mass lies at the subcutaneous fat-fibroglandular zone junction may allow easier search and more confident identification when ultrasound evaluation is undertaken.

c. Descriptors for abnormal enhancement. If a mass is seen on both the LE and RC images, the shape and margin should be described using the mammography lexicon. Repeating the descriptors for the findings on the RC image is not necessary.

i. Mass

- Shape (if seen on RC image only)
- Margin if evaluable (if seen on RC image only)
- Internal characteristics, if evaluable
- Lesion conspicuity

ii. Non-mass

- Distribution
- Internal characteristics, if evaluable
- Lesion conspicuity

iii. Enhancing asymmetry

- Lesion conspicuity

d. Artifacts if severe enough to potentially affect interpretation

6. ASSESSMENT

All reports should include an assessment category, as described above in the *Assessment Categories* section, page 780. If there is an abnormal finding, the assessment category should reflect the most abnormal finding whether on LE images, RC images or both.

7. MANAGEMENT RECOMMENDATIONS

All CEM examinations should include a management recommendation. If the assessment is incomplete (category 0), a specific suggestion for the next course of action should be rendered. This could include obtaining prior mammograms or performing additional imaging such as ultrasound or MRI. If additional imaging is recommended, the current report should proactively and clearly specify the recommended course of action in the scenario where the additional imaging proves to be negative or equivocal. With few exceptions, the management recommendations should be linked to the assessment category as described below.

Table 5. Concordance Between BI-RADS® Assessment Categories and Management Recommendations

Assessment	Management	Likelihood of Cancer
Category 0: Incomplete: Need Additional Imaging Evaluation OR Category 0: Incomplete: Need Prior Mammograms for Comparison	Recall for additional imaging Need comparison to prior examination(s)	N/A
Category 1: Negative	Routine annual mammography (with or without contrast as appropriate)	Essentially 0% likelihood of malignancy
Category 2: Benign	Routine annual mammography (with or without contrast as appropriate)	Essentially 0% likelihood of malignancy
Category 3: Probably Benign	Short-interval (6-month) follow-up or continued surveillance (12-month)	≥ 0% but ≤ 2% likelihood of malignancy
Category 4: Suspicious	Tissue diagnosis	> 2% but < 95% likelihood of malignancy
Category 5: Highly Suggestive of Malignancy	Tissue diagnosis	≥ 95% likelihood of malignancy
Category 6: Known Biopsy- Proven Malignancy	Clinical follow-up with surgeon and/or oncologist, and definitive local therapy (usually surgery) when clinically appropriate	N/A

C. WORDING OF REPORT

The current examination should be compared to prior examinations when appropriate. The indication for examination, such as screening or diagnostic, should be stated. The report should be organized with a brief description of the composition of the breast and any pertinent findings, followed by the assessment and management recommendations. All discussions between the interpreting physician and the referring clinician or patient should be documented in the original report or in an addendum to the report.

If a contrast reaction has occurred, a full description of the type of reaction, treatment if any, and management of the patient should be clearly stated in the body of the report and referred to in the report conclusion to be certain the referring physician is aware. In addition, recommendations for possible need for pre-treatment if intravenous contrast needs to give in the future should be made.

The report should be succinct, using terminology from the approved lexicon without embellishment. Do not use definitions of the lexicon terms in the report narrative; use only the descriptors themselves. Following the impression section and the (concordant) management recommendations section of the report, the terminology for the assessment category should be stated, as well as its category number. Other aspects of the report data should comply with the ACR PRACTICE PARAMETER FOR COMMUNICATION OF DIAGNOSTIC IMAGING FINDINGS.

V. GUIDANCE

SUMMARY

This section provides additional guidance for how to use the new CEM BI-RADS lexicon and reporting system in a variety of different clinical scenarios.

LEXICON

As of this publication, the lexicon used to report findings appreciated on the low energy (LE) and recombined (RC) images of CEM exams are adapted from conventional mammography and breast MRI descriptors. It is important to characterize any abnormality based on both its LE and RC imaging appearance. However, if a mass seen on LE images also enhances, the primary descriptors should be those of the mammography lexicon. It is not necessary to repeat descriptors for the shape and margin of the same mass on the RC images. If appropriate, descriptors for internal enhancement characteristics (homogeneous, heterogeneous, rim) and degree of conspicuity of the enhancement may be described.

If an abnormality has suspicious features on LE but has no RC correlate, it should still be pursued as a suspicious imaging finding. This is particularly true for suspicious calcifications seen on the LE im ages without corresponding enhancement [1,2]. Similarly, if there is enhancement on recombined images only, without LE correlate, it should be pursued as an indeterminate finding.

Interpreting CEM can be very straightforward when there is a solitary finding seen on both LE and RC images in the setting of minimal background parenchymal enhancement. However, there are circumstances when interpreting the RC images can be challenging. We have outlined some methods for navigating these circumstances below.

TECHNICAL CONSIDERATIONS

As with all imaging, it is important to first ensure the CEM images are technically adequate for interpretation. This includes (1) confirming contrast was appropriately administered, (2) ensuring your hanging protocol has LE images superimposed with RC images, and (3) appropriately setting window and level to reveal contrast enhancement.

To start, it is important to confirm that all of the contrast agent was safely and completely administered to the patient. Unlike breast MRI which employs a relatively small volume of gadolinium- based contrast material, CEM uses a larger quantity of an iodinated contrast agent that is administered at a dose of 1.5cc/kg with variable institutional maximums. As a result, the technologist performing the CEM should be able to visibly appreciate if contrast agent leaks from the tubing or if the patient is experiencing discomfort from contrast extravasation into their soft tissues. Any contrast event should be communicated to the responsible radiologist who will determine next steps including whether the study is interpretable. Otherwise, it is reasonable to assume that contrast has been appropriately administered to the patient and abnormal enhancement, if present, should be seen. While it is true that variations in hemodynamic blood flow could impact contrast visibility, the technical parameters of the CEM have been determined to allow for this.

The acquired CEM images could be impacted should contrast material get on a patient's skin or on the imaging equipment. Contrast contamination has the appearance of punctate hyperdensities overlying the breasts, similar to calcifications, but are often only seen on the recombined images [3,4,5]

To minimize this artifact, personnel should wash hands after handling contrast material. Alternatively, personnel can consider wearing gloves when handling the contrast material and changing or removing the gloves when performing the imaging portion of the CEM exam.

Hanging protocols for CEM can vary from institution to institution. One key element that should be maintained across sites is the superimposition of LE and RC images during viewing. This allows direct correlation of LE imaging findings with enhancement on RC images. Similarly, it allows readers to identify a LE correlate should an unexpected abnormality be seen on the RC images. Some vendor equipment has improved functionality that allows for the phasing in and out of the LE and RC images; however, this is not critical for exam review.

Lastly, a common challenge is adjusting the window and level to maximize contrast visibility. The internal contrast and brightness of the CEM images are determined at the time of acquisition. They are impacted by different conditions, such as breast tissue thickness and breast composition. Viewing workstations typically maintain the same technical parameters from acquisition and may not be optimized for interpretation. Manual adjustment of image brightness (level) and contrast (window) should be performed to improve visibility of any abnormal enhancement. A series of window and level settings may also be established so manual adjustment is less necessary.

BACKGROUND PARENCHYMAL ENHANCEMENT (BPE)

BPE is defined as the normal enhancement of glandular elements of the breast. The literature suggests that a majority of women imaged with CEM have minimal or mild background parenchymal enhancement [6,7]. It has yet to be determined whether timing CEM with the stage of the menstrual cycle will affect the accuracy of interpretation. The MRI literature suggests that for MRI, performing the study during a specific stage of the menstrual cycle does not affect sensitivity [8,9].

It can be difficult to differentiate BPE from artifacts that are seen on recombined images. The most common artifact that is appreciated is called rim artifact, also known as breast-within-a-breast, halo artifact, or matrix artifact. This artifact is due to scattered radiation that occurs within the breast during image acquisition. The result is an apparent enhancing halo just deep to the skin surface and can often be seen in the upper breast.

The literature suggests that moderate or marked BPE may be associated with increased risk for malignancy [6]; however, this needs to be studied further before formal associations are made. Studies are also examining whether BPE is related to false negative CEM exams (cancer not identified on CEM) and false positive CEM exams. Until results are available, it is important to remember that CEM is a planar imaging exam, and consequently small benign or malignant abnormalities may blend with BPE when it is moderate or marked. Along these lines, any enhancement that stands out above BPE on CEM should not be dismissed.

The approach for maximizing detection of abnormal enhancement in the setting of increased BPE is similar to that for MRI interpretation. The RC image can be viewed as you might a maximum intensity projection. Look for areas of asymmetric enhancement between the two breasts with special attention to areas separate from the BPE. Correlation with the LE images is critical to determine if an associated morphologic abnormality is present. If none, additional evaluation with targeted ultrasound and possibly MRI would be recommended.

MASSES

Masses on LE images may have associated enhancement on RC images. It is important to recognize that the presence of enhancement does not necessarily mean that the mass is malignant. Several benign entities can be associated with an enhancing mass including fibroadenoma, papilloma, and

radial scar. When determining management strategies for these enhancing masses, it is important to use information from both the LE and RC images. If the mass has suspicious features on LE images, such as having irregular margin or increased density, or having developed over time, the finding should be viewed with suspicion. On the other hand, should the mass be stable over time with circumscribed margin, further evaluation may not be necessary.

Masses on LE images may also be absent of enhancement. Similar to MRI, non-enhancing masses are usually benign. Masses that have a thin rim of enhancement but are otherwise associated with decreased enhancement relative to surrounding breast tissue are typically benign. This imaging appearance is termed the 'eclipse sign' or negative contrast enhancement and is classic for benign cysts [10].

However, it may not be possible to definitively say that a mass is non-enhancing in the setting of moderate or marked BPE. Remember that CEM is a planar exam, and the RC images reflect enhancement occurring throughout the breast. While the mass itself may not be enhancing, it may appear to have enhancing portions due to superimposed enhancing breast parenchyma. In this circumstance, the RC images are not helpful in classifying the mass as benign or malignant and ultrasound or possibly MRI may be necessary for further characterization.

ARCHITECTURAL DISTORTION

Similar to masses, architectural distortion on LE images may or may not be associated with enhancement. Although preliminary results for CEM and MRI suggest it may be possible to differentiate benign from malignant distortion based on enhancement [11], there is insufficient published data to confidently make this distinction. As a result, the LE assessment becomes crucial for interpretation. Should unexplained distortion persist on LE and conventional mammographic and tomosynthesis images, it should be pursued with percutaneous biopsy regardless of its enhancement pattern.

CALCIFICATIONS

The published literature suggests that the presence or absence of enhancement on RC imaging cannot be used to classify calcifications as benign or malignant [1,2]. Studies have shown that DCIS and invasive carcinoma can present as calcifications on LE images without abnormal enhancement on RC images. For this reason, any suspicious calcifications should be worked up according to their appearance on LE, conventional mammographic and tomosynthesis views.

ASYMMETRY

As with standard mammography, a one-view only finding should be called an asymmetry until its 3D nature can be confirmed with additional imaging. Also, in keeping with standard mammography, a 2-view finding that does not fulfill the criteria for a mass on LE images should be termed a focal asymmetry. All asymmetry types seen on the LE images should be evaluated and managed as on any mammogram whether or not they enhance.

RECOMBINED (RC) IMAGE-ONLY FINDINGS

A primary benefit of CEM is the ability to detect lesions based on vascularity that would otherwise not be seen on conventional mammography or tomosynthesis. However, managing RC image-only enhancement on CEM can be challenging. Unlike MRI that has multiple sequences that help characterize abnormalities as benign or malignant, RC images often only provide binary information as to

whether enhancement is present or not. As of this publication, additional features of RC image-only enhancement such as margin, distribution, and internal enhancement characteristics are often not specific enough to differentiate benign from malignant. As a result, it can be difficult to determine which RC image-only enhancement requires additional imaging work-up. In addition, RC image-only enhancement may be difficult to localize on two views. This can further complicate the diagnostic evaluation. The suggestions below can be used to help navigate some of these circumstances.

To start, the CEM lexicon should be used to describe the RC image-only enhancement as a mass, non-mass enhancement, or enhancing asymmetry. This enhancement should then be directly correlated with the LE images to see whether there is any associated abnormality. If there is a LE correlate, then it can be used to help determine the probability of malignancy. If the LE correlate is new, then the enhancement remains indeterminate. On the other hand, if the LE correlate has been present over many years and the LE appearance is morphologically benign, then the enhancement can be classified as benign. If a LE correlate is not clearly noted, it may also be useful to correlate with additional mammographic views and ultrasound.

In addition, it is worth evaluating how the RC image-only enhancement compares with background parenchymal enhancement. As mentioned earlier, it should be determined whether the enhancement is asymmetric between breasts or whether it is more conspicuous or discrete than the BPE. If this is the case, then the enhancement should be viewed as suspicious and further evaluated. A first step in further evaluation of an enhancing finding could be ultrasound. If, however, there is continued uncertainty with how to manage RC image-only enhancement, the best approach is to analogize to breast MRI. Published data have shown that findings on MRI and CEM have a similar appearance [12,13,14]. For this reason, when unsure how to handle incidental enhancement, consider how a similar finding might be handled on breast MRI and follow that plan.

ENHANCING ASYMMETRY

Unlike MRI where abnormal enhancement can generally be localized within the breast, it is not uncommon to see potentially abnormal enhancement on only one RC image without LE correlate. These should be termed “enhancing asymmetries” and managed as one would manage an asymmetry seen on a standard mammogram. As with conventional mammography, a one-view-only enhancing finding cannot be dismissed simply because it is seen on only one view.

REPORTING ORGANIZATION

It is important to remember that CEM is made up of LE and RC images. The report, management plan, and BI-RADS assessment should include an interpretation of both. If a suspicious abnormality is seen on either the LE or the RC images, it should be pursued with additional diagnostic evaluation. For example, if there is a suspicious morphologic finding noted on LE images (mass, distortion, calcifications) this should be further evaluated, even in the absence of enhancement. Similarly, RC image-only enhancement without a LE correlate should be pursued.

VI. FREQUENTLY ASKED QUESTIONS

1. ***When US is needed after diagnostic CEM does US get incorporated into the report? If US is not incorporated into the report – how do you code?***

   As with standard mammography, it is preferable to report both the CEM and the US together if done on same day. If US is reported separately, it should be given a BI-RADS assessment based on the sonographic findings with an added statement referring to the CEM findings.

   For example, if there is a mass on the CEM study and ultrasound is done at a later time and is negative, the US can be assigned a BI-RADS 1 with additional recommendation of how to manage the finding on the CEM. If ultrasound is recommended based on CEM findings and done at a later time, the CEM report should always include a management recommendation if the ultrasound is negative. In the case where a single report is issued, each exam should still be audited separately.

2. ***I don't have access to MRI. How should I handle RC image only findings?***

   Targeted ultrasound could be performed to see if there is a sonographic correlate. If US is negative and the RC image finding is low suspicion, a short interval follow-up CEM may be appropriate. CEM-guided biopsy capability is available and is an option if MRI is not available. If neither CEM nor MR-guided biopsy is available and the RC image finding is very suspicious, biopsy using stereotactic guidance and landmarks could be attempted. Alternatively, pre-operative localization, again using landmarks, followed by surgical excision could be undertaken for very suspicious findings.

3. ***Can we use dynamics of enhancement to help determine probability of malignancy?***

   Although there has been some work on using kinetics in CEM, the protocol at most facilities does not allow for sequential post-contrast imaging so dynamics cannot be used.

4. ***When does the exam become non-diagnostic? How much time do I have?***

   Ideally, imaging should be completed within 8-9 minutes after injection. After that time, contrast may have washed out sufficiently to render RC images unreliable.

5. ***What should I do if the full contrast dose doesn't get administered?***

   In these circumstances, it depends on how much contrast was actually delivered. If only a small amount of contrast was given, the study can be rescheduled. Alternatively, the exam could be done with the understanding that the RC images may not be reliable and only the LE images are read as a regular mammogram. In general, if there is any doubt as to the adequacy of contrast administration, the examination should be read as a standard LE examination.

6. ***If I have a choice between CEM and MRI, when is each imaging exam better?***

   It has been shown that MRI has a higher sensitivity for detection of breast cancer but lower or comparable specificity than CEM. MRI also offers better visualization of areas typically not well seen on mammography including far posterior locations or axilla. MRI is more expensive than CEM, not always covered by insurance, and not as easily tolerated for most women. MRI is recommended for very high-risk patients (such as BRCA mutation carriers, lifetime risk of ≥ 20%). CEM may be used as supplemental screening for women at intermediate risk for breast cancer (lifetime risk of 15–20%). Currently, CEM is not approved by the FDA for screening so using this examination for this indication would be considered an off-label use. Facilities that choose to

use CEM for screening are encouraged to have strict criteria for who will be screened and carefully audit their results.

7. ***I want to tell the tech to do extra images (XCC, cleavage view, etc.) because a suspected finding is in the outer or inner portion of the breast. When should I do these extra images?***

   These can be done along with the standard images of the breast in question, followed by imaging of the contralateral breast. All imaging should be accomplished within the 8–9-minute time frame following contrast injection.

8. ***Should I be timing CEM with menstrual cycle?***

   There is no data that outcomes of CEM are influenced by the stage of the menstrual cycle in which the study is done. For MRI, there is evidence that important outcomes are unrelated to the stage of the menstrual cycle in which the study was performed.

9. ***The RC image-only finding barely enhances. Do I have to work this up?***

   In general, any enhancement that is not considered to be background should be fully evaluated, even if the level of enhancement is low. As more experience is gained with CEM and more data becomes available, better guidance on findings that can be safely ignored may become evident.

10. ***I see an RC image-only finding on only one view. What do I do next?***

    First, it should be determined whether the enhancing asymmetry is a true lesion or simply part of background. If it is felt to be a real finding, targeted ultrasound can be attempted. If that is unrevealing, MRI may be the best option for further evaluation. MRI can often characterize the finding as benign, probably benign (such as a likely fibroadenoma), or suspicious. If suspicious, an MRI-guided biopsy can be performed. If the enhancement seen on CEM is not seen on MR, a 6-month follow-up CEM can be the management strategy.

11. ***Should we place radiopaque markers on the breast to indicate scars, skin lesions, or clinical abnormalities?***

    Markers that are usually placed for standard mammograms should also be placed for CEM studies.

12. ***What should I call a finding seen only on one view and only on the RC image? If it has the shape of a mass, can I call it a mass? Do these one-view findings with no LE correlate always have to be evaluated?***

    Enhancement without a corresponding finding on LE images and seen on only one RC view is not an uncommon occurrence in CEM. This should be termed an "enhancing asymmetry" even if it has a geometric shape on the single view, similar to standard mammography. It should not be called a mass unless seen on orthogonal views. These one view RC image findings are often simply asymmetric BPE but can sometimes represent a true finding and even malignancy so should not be dismissed simply because they are seen on only one view.

13. ***If an asymmetry is seen on only one LE view but shows enhancement on the corresponding RC image, would it also be called an "enhancing asymmetry?"***

    Yes, such a finding could be called an enhancing asymmetry. It can also be described as an asymmetry with corresponding enhancement.

14. ***Why is the term "focus" not included in the CEM lexicon as it was for MRI?***

    "Focus" was included in the prior MRI lexicon to describe dots of enhancement too small to characterize further in terms of margins or kinetics, but has been discontinued with this new version. The term was never included in the mammography lexicon. The resolution of enhancing findings

on CEM is lower than for standard mammography or MRI and kinetics are not used with CEM. Therefore, these small areas of enhancement are more analogous to small masses seen on standard mammography rather than dots previously described with MRI and the term "mass" should be used regardless of size.

15. The descriptors for a mass's margin are different for LE findings and RC only findings. If a mass is seen on both the LE and RC images, is it necessary to give separate descriptors for the margin?

No. If a mass is seen on the LE images, the mammography lexicon should be used to describe shape and margin regardless of whether or not it enhances. If appropriate, additional descriptors for the enhancement such as internal characteristics (homogeneous, heterogeneous, rim) and lesion conspicuity can be used.

16. What are appropriate uses for BI-RADS category 0 for CEM? When should BI-RADS category 0 not be used?

If additional imaging is needed to evaluate a definite or questioned CEM finding, the use of BI-RADS category 0 is appropriate.

If BI-RADS category 0 is used, the type of additional imaging and the management should the additional imaging prove to be negative should be stated in the report. Additionally, there should be a mechanism in place to resolve all cases assigned a category 0.

BI-RADS category 0 should not be used if there is a suspicious finding on CEM but for which CEM-guided biopsy is not available and for which MRI is needed to guide intervention. In this case, a BI-RADS category 4 or 5 assessment is correct, with recommendation made for MRI-guided biopsy.

APPENDIX A — LEXICON SUMMARY FORM FOR RECOMBINED IMAGES

ACR BI-RADS® — CEM LEXICON SUMMARY FORM FOR RECOMBINED IMAGES

For each of the following categories, select the term that best describes the dominate lesion feature. Whenever possible, definitions used in BI-RADS for mammography (low energy image findings) and/or MRI should be used. The outline format presented below does not match that used in Table 1, as only recombined lexicon terminology is included here.

BREAST TISSUE		
A. Background parenchymal enhancement (BPE): Refers to the normal enhancement of fibroglandular tissue seen on the recombined images		
1. Level	a. Minimal	
	b. Mild	
	c. Moderate	
	d. Marked	
2. Symmetric or asymmetric (report for bilateral studies)	a. Symmetric	Similar enhancement in both breasts
	b. Asymmetric	More enhancement in one breast than the other
FINDINGS		
B. Seen on low energy images	1. Yes (refer to Mammography lexicon)	
	2. No	
C. Lesion conspicuity (relative to background)	1. Low	Enhancement equal to or slightly greater than background
	2. Moderate	Enhancement is between low and high
	3. High	Enhancement is much greater than background
D. Masses: 3D, space-occupying lesion, convex-outward contour		
1. Shape *(select one)*	a. Oval	Elliptical or egg-shaped
	b. Lobulated	Generally oval with one or more indentations resulting in an undulating surface
	c. Round	Spherical, ball-shaped, circular, or globular
	d. Irregular	Neither oval, lobulated nor round. Has acute angle protruding portions.
2. Margin *(select one)*	a. Circumscribed	Entire margin is sharply demarcated with abrupt transition between the lesion and surrounding tissue
	b. Non-circumscribed	
	i. Indistinct (historically irregular)	Uneven edges (but not spiculated)
	ii. Spiculated	Characterized by lines radiating from the mass
3. Internal enhancement characteristics *(select one)*	a. Homogeneous	Confluent uniform enhancement
	b. Heterogeneous	Nonuniform enhancement with variable density
	c. Rim enhancement	Enhancement more pronounced at periphery of mass

E. Non-mass enhancement (NME): Enhancement that is neither a mass nor an enhancing asymmetry		
1. Distribution *(select one)*	a. Diffuse	Enhancement distributed randomly throughout the breast
	b. Regional	Enhancement in a large volume of tissue (may be more than one quadrant) but not diffuse and does not follow a segmental or linear distribution
	c. Focal	In a confined area, less than a breast quadrant volume with fat or normal glandular tissue interspersed between the abnormally enhancing components (exception: focal homogeneous enhancement)
	d. Linear	Enhancement arrayed in a line (not necessarily a straight line) implying involvement of a duct
	e. Segmental	Triangular or cone-shaped region of enhancement. Apex generally oriented toward the nipple
2. Internal enhancement characteristics (when discernible) *(select one)*	a. Homogeneous	Confluent uniform enhancement
	b. Heterogeneous	Nonuniform enhancement in a random pattern separated by normal breast parenchyma or fat
	c. Clumped	Cobblestone enhancement of varying shapes and sizes with occasional confluent areas
F. Enhancing asymmetry		
1. Internal enhancement pattern *(select one)*	a. Homogeneous	Confluent uniform enhancement
	b. Heterogeneous	Nonuniform enhancement in a random pattern separated by normal breast parenchyma or fat
G. Intramammary lymph node: Circumscribed, homogeneously enhancing masses, reniform, often < 1 cm when normal. Mention if abnormal.		
H. Skin lesion: Benign enhancing lesions of skin		
I. Associated features		
1. Nipple retraction		Nipple is pulled in. Do not confuse with nipple inversion
2. Nipple involvement		Tumor directly invades and is contiguous with the nipple
3. Skin retraction		The skin is pulled in abnormally
4. Skin thickening		May be focal or diffuse, > 2mm in thickness
5. Skin involvement		Abnormal enhancement within the skin, which is thickened
	a. Direct invasion	The skin enhances where the tumor directly invades
	b. Without direct invasion (usually inflammatory breast cancer)	The enhancement may be diffuse or focal depending on the extent of invasion of dermal lymphatics
6. Axillary adenopathy		Enlarged lymph nodes may warrant comment, clinical correlation, and additional evaluation especially if new or considerably larger or rounder compared to previous examination
J. Location of finding: An important finding (assessed as anything other than benign) must always be triangulated so that its 3D location within the breast is known		
1. Laterality - describe right, left, or both breasts		
2. Location in breast (clock-face (preferred) in whole number, quadrant or other anatomic location)		
3. Depth (anterior, middle, posterior)		
4. Distance from nipple (in whole cm) - base of nipple to center of finding		

ASSESSMENT CATEGORIES (select one)		
Incomplete Assessment	**Management**	**Likelihood of Cancer**
Category 0: Incomplete: Need Additional Imaging Evaluation OR Category 0: Incomplete: Need Prior Mammograms for Comparison	Recall for additional imaging Need comparison to prior examination(s)	N/A
Final Assessment	**Management**	**Likelihood of Cancer**
Category 1: Negative	Routine annual mammography (with or without contrast as appropriate)	Essentially 0% likelihood of malignancy
Category 2: Benign	Routine annual mammography (with or without contrast as appropriate)	Essentially 0% likelihood of malignancy
Category 3: Probably Benign	Short-interval (6-month) follow-up or continued surveillance mammography	> 0% but ≤ 2%
Category 4: Suspicious	Tissue diagnosis	> 2 but < 95% likelihood of malignancy
Category 5: Highly Suggestive of Malignancy	Tissue diagnosis	≥ 95% malignancy
Category 6: Known Biopsy-Proven Malignancy	Clinical follow-up with surgeon and/or oncologist, and definitive local therapy (usually surgery) when clinically appropriate	N/A

REFERENCES

1. Cheung YC, Tsai HP, Lo YF, Ueng SH, Huang PC, Chen SC. Clinical utility of dual-energy contrast-enhanced spectral mammography for breast microcalcifications without associated mass: a preliminary analysis. Eur Radiol.
2. Houben IP, Vanwetswinkel S, Kalia V, Thywissen T, Nelemans PJ, Heuts EM, Smidt ML, Meyer-Baese A, Wildberger JE, Lobbes M. Contrast-enhanced spectral mammography in the evaluation of breast suspicious calcifications: diagnostic accuracy and impact on surgical management. Acta Radiol. 2019 Sep;60(9):1110–1117.
3. Gluskin J, Click M, Fleischman R, Dromain O, Morris EA, Jochelson MS. Contamination artifact that mimics in-situ carcinoma on contrast-enhanced digital mammography. Eur J Radiol 2017; 95; 147–154.
4. Bhimani C, Li L, Liao L, Roth RG, Tinney E, Germaine P. Contrast-enhanced Spectral Mammography: Modality-Specific Artifacts and Other Factors Which May Interfere with Image Quality. Acad Radiol. 2017 Jan;24(1):89–94.
5. Yagil Y, Shalmon A, Rundstein A, Servadio Y, Halshtok O, Gotlieb M, Sklair-Levy M. Challenges in contrast-enhanced spectral mammography interpretation: artefacts lexicon. Clin Radiol. 2016 May;71(5):450–7.
6. Sorin V, Yagil Y, Shalmon A, Gotlieb M, Faermann R, Halshtok-Neiman O, et al. Background Parenchymal Enhancement at Contrast-Enhanced Spectral Mammography (CESM) as a Breast Cancer Risk Factor. Acad Radiol. 2019.
7. Sogani J, Morris EA, Kaplan JB, D'Alessio D, Goldman D, Moskowitz CS, et al. Comparison of Background Parenchymal Enhancement at Contrast-enhanced Spectral Mammography and Breast MR Imaging. Radiology. 2017;282(1):63–73.
8. DeMartini WB, Liu F, Peacock S, Eby PR, Gutierrez RL, Lehman CD. Background Parenchymal Enhancement on Breast MRI: Impact on Diagnostic Performance. AJR 2012 198:W373–W380.
9. Lee CH, Bryce Y, Zheng J, Sung JS, Comstock CE, Moskowitz C, Morris EA. Outcome of screening MRI in premenopausal women as a function of the week of the menstrual cycle. AJR 2020; 214:1175–1181.
10. Lobbees MBI, Lalji U, Houwers J, Nijssen EC, Nelemans PJ, van Roozendaal L, Smidt ML et al. Contrast-enhanced spectral mammography in patients referred from the breast cancer screening programme. Eur Radiol 2014:24;1668–1676.
11. Patel BK, Naylor ME, Kosiorek HE, Lopez-Alvarez YM, Miller AM, Pizzitola VJ, Pockaj BA. Clinical utility of contrast-enhanced spectral mammography as an adjunct for tomosynthesis-detected architectural distortion. Clin Imaging. 2017 Nov-Dec;46:44–52.
12. Chou C-P, Lewin JM, Chiang C-L, Hung B-H, Yang T-L, Huang J-S, et al. Clinical evaluation of contrast-enhanced digital mammography andcontrast enhanced tomosynthesis — Comparison to contrast-enhancedbreast MRI. Eur J Radiol 2015: 84; 2501–2508.
13. Fallenberg EM, Schmitzberger FF, Amer H, Ingold-Heppner B, Balleyguier C, Diekmann F, Engelken F, Mann RM, Renz DM, Bick U, Hamm B, Dromain C. Contrast-enhanced spectral mammography vs. mammography and MRI - clinical performance in a multi-reader evaluation. Eur Radiol. 2017 Jul;27(7):2752–2764.
14. Lewin J. Comparison of contrast-enhanced mammography and contrast-enhanced breast MR imaging. Magn Reson Imaging Clin N Am 2018: 26; 259–263.

SUGGESTED READING FOR PREFACE

Lewin JM, Isaacs PK, Vance V, Larke FJ. Dual-energy contrast-enhanced digital subtraction mammography: feasibility. Radiology. 2003;229:261–268.

Diekmann F, Diekmann S, Taupitz M, Bick U, Winzer KJ, Hüttner C, et al. Use of iodine-based contrast media in digital full-field mammography — initial experience. Rofo. 2003;175:342–345.

SUGGESTED READING FOR SECTION I: GENERAL CONSIDERATIONS

Dromain C, Thibault F, Muller S, Rimareix F, Delaloge S, Tardivon A, et al. Dual-energy contrast-enhanced digital mammography: initial clinical results. Eur Radiol. 2011:21; 565–74.

Badr S, Laurent N, Régis C, Boulanger L, Lemaille S, Poncelet E. Dual-energy contrast-enhanced digital mammography in routine clinical practice in 2013. Diagn Interv Imaging. 2014:95;245–58.

Sognani J, Mango VL, Keating D, Sung JS, Jochelson MS. Contrast-enhanced mammography: past, present, and future. Clin Imaging 2021: 69; 269–279.

Ghaderi KF, Phillips J, Perry H, Lotfi P, Mehta TS. Contrast-enhanced mammography: Applications and future directions. RadioGraphics 2019; 39:1907–1920.

Polat DS, Evans WP, Dogan BE. Contrast-enhanced digital mammography: Technique, clinical applications, and pitfalls. AJR 2020; 215:1267–1278.

Sumkin JH, Berg WA, Carter GJ, Bandos AI, Chough DM, Ganott MA, Hakim CM, Kelly AE, Zuley ML, Houshmand G, Anello MI, Gur D. Diagnostic Performance of MRI, Molecular Breast Imaging, and Contrast-enhanced Mammography in Women with Newly Diagnosed Breast Cancer. Radiology. 2019:293; 531–540.

Covington MF. Contrast-enhanced mammography implementation, performance, and use for supplemental breast cancer screening. Radiol Clin N Am 2021: 59; 113–128.

SUGGESTED READING FOR SECTION III: REPORT ORGANIZATION

KnoglerT, Homolka P, Hoernig M, Leithnern R, Langs G, Martin Waitzbauer M, et al. Application of BI-RADS Descriptors in Contrast-Enhanced Dual-Energy Mammography: Comparison with MRI. Breast Care 2017;12:212–216.

Perry H, Phillips J, Dialani V, Slanetz PJ, Fein-Zachary VJ, Karimova EJ. Contrast-enhanced mammography: A systematic guide to interpretation and reporting. AJR 2019; 212:222–231.

Berg WA, Bandos AI, Zuley ML, Waheed UX. Training radiologists to interpret contrast-enhanced mammography:Toward a standardized lexicon. J Breast Imaging 2021: 3; 176–189.

Yagil Y, Shalmon A, Rundstein A, Servadio Y, Halshtok O, Gotlieb M, Sklair-Levy M. Challenges in contrast-enhanced spectral mammography interpretation: artefacts lexicon. Clin Radiol. 2016 May;71:450–457.

ACR BI-RADS® v2025

Auditing and Outcomes Monitoring

Peter R. Eby, MD

Debbie L. Bennett, MD
Ethan O. Cohen, MD
Donna M. Plecha, MD
Edward A. Sickles, MD

American College of Radiology™

TABLE OF CONTENTS

PREFACE 804

INTRODUCTION 806

I. GLOSSARY 808

II. THE BASIC CLINICALLY RELEVANT AUDIT 816

A. BI-RADS CATEGORY 3 AUDITING 822

B. BENCHMARKS AND ACCEPTABLE RANGES 826

C. IMPORTANT CONSIDERATIONS 830

III. THE MORE COMPLETE AUDIT 833

IV. EXAMPLES OF HOW TO CLASSIFY EXAMINATIONS AS TRUE-POSITIVE, TRUE-NEGATIVE, FALSE-POSITIVE, AND FALSE-NEGATIVE 840

A. BI-RADS ASSESSMENT CONCORDANT WITH MANAGEMENT RECOMMENDATION 840

B. BI-RADS ASSESSMENT DOES NOT MATCH MANAGEMENT RECOMMENDATION 845

C. AUDITING OF INITIAL BI-RADS CATEGORY 3 ASSESSMENT 846

V. AREAS OF CONFUSION IN THE DATA COLLECTION PROCESS 849

A. WHAT NOT TO AUDIT 849

B. DOUBLE READING 850

C. THE "SCREENING" VERSUS THE "DIAGNOSTIC WORK-UP" RADIOLOGIST 851

D. CANCER IDENTIFIED AT SCREENING EXAMINATION LESS THAN 1 YEAR AFTER THE PREVIOUS NEGATIVE SCREENING EXAMINATION 851

E. THE GROUP OF EXAMINATIONS ASSESSED AS PROBABLY BENIGN (BI-RADS CATEGORY 3) WITH A RECOMMENDATION FOR SHORT-INTERVAL FOLLOW-UP AND SURVEILLANCE IMAGING 852

VI. FREQUENTLY ASKED QUESTIONS AND GUIDANCE CONCERNING BREAST IMAGING AUDITS 853

A. ALL BREAST IMAGING MODALITIES 853

B. MAMMOGRAPHY 855

C. ULTRASOUND 855

D. MRI 856

VII. INITIAL METHOD OF DETECTION 858

PREFACE

The Food and Drug Administration (FDA) [1] requires an audit of all facilities engaged in mammography to promote quality examinations for patients throughout the United States. The American College of Radiology (ACR) endorses this requirement. The ACR also asserts that more thorough auditing of mammography, breast ultrasound (US) and breast MRI supports breast imaging practices and their individual interpreting physicians to continuously improve their clinical performance and patient care. The section on auditing and outcomes monitoring provides detailed instructions for conducting a clinically relevant audit including which data to collect, which metrics to calculate, and how to analyze the results. Regular audits help breast imaging teams identify deficiencies, facilitate research, reduce adverse medicolegal consequences and, most importantly, improve outcomes for patients.

In the 4th Edition of the BI-RADS® Atlas, published in 2003, the material regarding follow-up and outcomes monitoring was part of the Mammography section because established benchmarks and outcomes existed only for that modality. Subsequent substantial and widespread increases in breast US and breast MRI for screening and diagnostic applications in the ensuing decade triggered creation of the distinct Follow-up and Outcomes Monitoring section, by Drs. Sickles and D'Orsi, in the 5th Edition of BI-RADS published in 2013. The new section presented auditing procedures for all three breast imaging modalities so that any breast imaging facility (or individual interpreting physician) might compare observed outcomes with new benchmarks.

This illustrated BI-RADS v2025 Manual, like its Atlas predecessors, is designed to help breast imaging facilities and individual interpreting physicians conduct clinically relevant audits and improve patient care in daily clinical practice. In this version, the Follow-up and Outcomes Monitoring section has been renamed Auditing and Outcomes Monitoring to better reflect its content.

In addition to a new name, there are several other substantial changes in the Auditing and Outcomes Monitoring section of this version. The definitions of screening and diagnostic examinations are now modality-neutral to account for current and future advances in technology and addition of new modalities. Benchmarks for mammography, ultrasound and MRI have been updated with the latest published data. The basic audit has been expanded to include category 3 assessments and outcomes to encourage review by individual practices and publication of updated contemporary benchmarks. The *More Complete Audit* now includes guidance for breast MRI examinations performed to assess the extent of disease. The concept and categories of initial method of detection (MOD) are introduced and, finally, a specific section has been created to describe *What Not to Audit* (section V. A.).

Collection and calculation of all the data in the *Basic Clinically Relevant Audit* (section II) requires proper coding of the data elements for efficient retrieval, often requiring considerable effort. However, once collected and calculated, these data allow clinically relevant measurement of one's practice outcomes by providing quantifiable evidence in pursuit of the three major goals of breast cancer screening:

1. Find a high percentage of breast cancers that exist in a screening population (measurement: cancer detection rate).

2. Find these breast cancers within an acceptable range of recommendations for additional imaging and recommendation for tissue diagnosis, to minimize cost and morbidity (measurement: recall rate, abnormal interpretation rate, positive predictive values).

3. Find a high percentage of small, node-negative, early-stage breast cancers, which are more likely to be curable (measurement: percentages of node-negative, minimal, and stage 0 + I cancers).

BI-RADS was always intended to be a dynamic and evolving document that would adapt to changes in the practice of breast imaging and be of practical use to interpreting physicians. Therefore, the Committee on BI-RADS welcomes any comments and/or suggestions from users and requests that these be submitted by e-mail to the ACR. However, prior to submitting comments or suggestions, please first visit the ACR BI-RADS web site at https://www.acr.org/Clinical-Resources/Clinical-Tools-and-Reference/Reporting-and-Data-Systems/BI-RADS, which displays committee-approved responses to Frequently Asked Questions.

ACR Committee on BI-RADS®
American College of Radiology
E-mail: RADS@acr.org

Peter R. Eby, MD, FACR, FSBI
Chair, Subcommittee on BI-RADS® Auditing and Outcomes Monitoring

INTRODUCTION

This chapter of the BI-RADS® v2025 Manual provides detailed instructions and guidance for the process of routinely auditing breast imaging practices. The chapter defines primary data to collect and how to calculate performance metrics for each group and interpreting physician to assess their overall performance in breast imaging interpretation. The basic principles described in this chapter apply similarly to mammography, breast ultrasound (US), and breast MRI and other future modalities employed for screening and diagnostic breast imaging. The aspirational goal of the ACR and its Committee on BI-RADS is to support continuous improvement in quality and outcomes for patients and encourage research and publication of performance benchmarks.

Audits must be based on a set of consistent, objective, and reproducible rules, so that results and outcomes can be compared to national benchmarks and past performance for individuals and all breast imaging practices. Furthermore, audits of different breast imaging modalities should utilize the same rules to facilitate cross-modality comparisons, except when the unique aspects of a given modality justify a different approach. In addition to the *Basic Clinically Relevant Audit*, collection of *More Complete Audit* data to derive other metrics regarding breast imaging performance is highly encouraged. Audits of screening and diagnostic examinations should be performed separately because they address different clinical questions in different patient populations and presuppose different clinical outcomes. Practical examples of everyday situations are presented and then characterized using the definitions and mathematical formulas included in this section.

For auditing purposes, positive "truth" for cancer outcome is defined as tissue diagnosis of breast cancer within the timespan of the standard ascertainment interval. For definitions provided within this section, the standard ascertainment interval is 1 year (365 days), as recommended by the ACR, and the basis for existing performance benchmarks. There are two exceptions to the 1-year standard ascertainment interval used to define truth. First, breast imaging facilities with an alternate accepted local standard screening interval, such as 2 years, whether in the United States or elsewhere, should consistently replace the 1-year ascertainment interval with their definition. Second, the newly recommended audit of BI-RADS category 3 findings, outlined in this version of the Manual, uses 2 years of observation as the standard ascertainment interval to determine truth.

Regardless of modality, screening exams are performed to detect clinically unsuspected breast cancer in patients without any reported symptoms, clinical signs, or imaging findings. The sole binary decision of the radiologist interpreting a screening examination is to either recommend action (most commonly the production and permanent archival of additional images) before the next screening or recommend no action until the next screening. Recommending no further action within the standard screening interval defines the "negative" screening examination. The recommendation for, or acquisition of, additional images beyond those prescribed by the standard screening protocol, to further evaluate a finding before conclusion of the standard interval, constitutes action and provides an objective and reproducible rule that defines the "positive" screening examination. This accomplishes objectivity and reproducibility by basing the auditing rule on something that does not rely upon subjective review.

Regardless of modality, diagnostic imaging is any examination applied to patients to further characterize any reported symptoms, clinical signs, or imaging findings that may or may not be malignant. The practice of screening patients, either in person or remotely, and performing diagnostic, multi-modality examinations and delivering results within a single visit has evolved substantially in the past decade. The committee recognizes the potential benefits of accelerating care and immediate diagnostic feedback for patients. When multiple examinations are performed in a single visit,

radiologists must recognize and adhere to the definitions of screening and diagnostic examinations and track assessments separately to 1) provide clear communication to patients and providers and 2) produce audits that are comparable to existing and future benchmarks and other practices.

When a screening mammography, MRI or US examination is interpreted while the patient waits for results, the acquisition of additional images beyond those prescribed by the standard screening protocol, with any modality, to further evaluate any finding, defines a positive screening examination, whether separate screening and diagnostic reports are issued or not. For example, a patient may undergo a screening breast MRI followed immediately by targeted ultrasound and diagnostic mammography for an MRI finding that is suspected to be a benign lymph node. The interpreting physician may wait until all images are produced and interpreted to report the examinations together. If so, the final combined report reflects a benign (category 2) assessment. However, the screening MRI portion of that combined assessment, for auditing purposes, is "need additional imaging evaluation" (BI-RADS category 0) and the diagnostic mammography and ultrasound portion "benign" (BI-RADS category 2). Thus, the screening MRI examination is positive, and the diagnostic examinations are negative for the purposes of the audit. It is acceptable for a single report to reflect only the final benign (BI-RADS category 2) assessment, but it is inappropriate and misleading for the MRI to be considered audit-negative. Auditing will be greatly facilitated if reporting software can prospectively recognize when diagnostic images are acquired and track separate assessments for reports that combine screening and diagnostic examinations.

It is crucial to understand the difference between BI-RADS assessments used to produce clear and unambiguous clinical reports and the performance metrics needed to ensure accurate, comparable audits. Ideally, the results of audits contribute to continuous improvement in patient care by increasing cancer detection and simultaneously decreasing recall rates. Audits also provide opportunities to study advances in technology and new modalities or update benchmarks of stable tests. The BI-RADS v2025 Manual refines objective and reproducible approaches to auditing breast imaging examinations for mammography, US and MRI. This version also recognizes the ongoing rapid development and proliferation of novel imaging techniques by providing a modality neutral platform for future audits and cross-comparison. The BI-RADS Manual, in accordance with the FDA, specifies the views constituting a screening mammogram. The protocols and images to be obtained with handheld ultrasound (HHUS), automated breast ultrasound screening (ABUS) and screening and diagnostic MRI are defined by ACR Practice Parameters and Technical Standards (https://www.acr.org/clinical-resources/clinical-tools-and-reference/practice-parameters-and-technical-standards). Local protocol variations may contribute to variations in performance and benchmarks. This version of the Audit and Outcomes Monitoring section includes the most current available data for comparisons. The ACR and its Committee on BI-RADS strongly encourage individuals, institutions, and regional and national research groups to publish anonymized audit results. Public disclosure of audit results from diverse practices and populations, especially through participation in registries and the National Mammography Database (NMD), facilitate rapid and accurate updates to performance benchmarks, at the pace of technological development, for the sake of our patients.

Audit data may be protected as peer-review privileged information pursuant to applicable state law or otherwise subject to institutional policies.

I. GLOSSARY

This is a glossary for the basic and comprehensive audit of a breast imaging practice, both of which are described in detail following the glossary:

1. Screening examination — any examination performed for people without any reported symptoms, clinical signs or imaging findings of breast cancer. Screening involves the binary decision of recommending action before the next interval screening versus recommending no action until the next interval screening. Specific to auditing and outcome monitoring, an examination should be considered a screening examination if it is performed on an asymptomatic person with any additional indication for screening listed below in Table 1.

2. Diagnostic examination — any examination applied to patients to further characterize or reassess any imaging findings or clinical signs or symptoms, that may or may not be malignant. Diagnostic examinations can be performed on the same day as the screening examination and within the same visit if desired; however, separate screening and diagnostic reports are recommended, and separate tracking for the audit is required. The recommendation for, or acquisition of, additional images beyond those prescribed by the standard screening protocol, to further evaluate a finding before conclusion of the standard interval, constitutes action and provides an objective and reproducible rule that defines the "positive" screening examination. This accomplishes objectivity and reproducibility by basing the auditing rule on something that does not rely on subjective review. Specific to auditing and outcome monitoring, an examination should be considered a diagnostic examination if it is performed for any of the indications for diagnostic imaging listed below in Table 1.

Table 1. Diagnostic and Screening Examinations Defined by Indication

Screening Examinations[a]	Diagnostic Examinations
Asymptomatic	Clinical findings that may suggest breast cancer
Personal history of breast cancer, screening after breast conservation therapy[b]	Further characterize or reassess findings on abnormal screening or other diagnostic examinations
Prior benign breast biopsy	Current breast cancer patient beginning or undergoing therapy
Prior breast augmentation	Probably benign findings requiring follow-up
Family history of breast cancer	Follow-up earlier than the standard interval for cancer patient treated with breast conservation therapy[b]
Elevated risk of breast cancer	Image(s) beyond the standard screening protocol permanently archived to further evaluate a finding
Dense breast tissue	

[a] Only the most common potential indications for screening are listed here. A "screening examination" is best defined as one performed on asymptomatic people to detect early, clinically unsuspected breast cancer. Screening involves the binary decision of recommending action before the next screening versus recommending no action until the next screening.

[b] At the interpreter's discretion, after completing the institutional period of follow-up earlier than the standard interval after breast conservation therapy, the patient may return to screening. That patient would thereafter undergo imaging in the *screening examinations* group under the indication of "personal history of breast cancer."

3. Tissue diagnosis — This is a pathologic diagnosis rendered after any type of interventional procedure (fine-needle aspiration cytology, core biopsy, incisional biopsy, excisional biopsy). *A tissue diagnosis is considered concordant if the cytological or histological diagnosis rendered by the pathologist fully accounts for the imaging findings of the biopsied abnormality. A tissue diagnosis is discordant if the cytological or histological diagnosis rendered by the pathologist does not account for the imaging findings of the biopsied abnormality.* Examples of discordant tissue diagnoses include histological diagnosis of fibroadenoma for a spiculated mass containing fine linear calcifications, and histological diagnosis of benign fibrofatty breast tissue for a circumscribed oval solid mass. Also included in the definition of tissue diagnosis is *diagnostic cyst aspiration*, performed to confirm the suspected diagnosis of cyst for cases in which mammographic and sonographic findings are not characteristically benign, with aspiration of cyst fluid accompanied by disappearance of the suspected cyst making it unnecessary to obtain a pathologic diagnosis. Note that *therapeutic cyst aspiration* is not included in the definition of tissue diagnosis. Such an aspiration, performed for characteristically benign cysts to provide symptomatic relief of focal pain or tenderness or to relieve patient anxiety, is not defined as tissue diagnosis because the interventional procedure is not recommended for diagnostic purposes.

4. Positive screening examination — This is a screening examination for which additional diagnostic imaging is recommended prior to the next interval screening examination to further evaluate a screening-detected finding whether or not the patient remains in the breast imaging facility (whether or not separate screening and diagnostic reports are issued); or for which tissue diagnosis is recommended. The unique aspects of screening mammography, breast US, and breast MRI examinations are considered in the following paragraphs that describe positive screening examinations but the positive assessments (BI-RADS category 0, 3, 4 and 5) remain consistent throughout.

    a. Mammography — A positive screening examination is most often related to a recall (BI-RADS category 0) for diagnostic breast imaging performed on a future date. However, a screening examination is also positive when additional diagnostic breast imaging is performed to further evaluate a screen-detected finding while the patient remains in the breast imaging facility (real time interpretation). The screening examination should still be counted positive (BI-RADS category 0) when the results of the screening and diagnostic examinations are combined into a single report on the same day, regardless of the final diagnostic BI-RADS category assessment. Recommending tissue diagnosis or short-term follow-up (BI-RADS categories 4 and 5 or BI-RADS category 3, respectively) directly from screening is specifically discouraged. Such screening examinations are considered positive for the purposes of the audit and count towards the recall rate while denying the patient and radiologist an opportunity for work-up and discussion of the significance of the findings. Note that this definition of a positive screening examination is different from that used in the *MQSA Final Rule* [1], for which "positive" examinations are limited to those for which tissue diagnosis is recommended.

        Also note that BI-RADS category 3 assessments should not be used for screening mammography examinations; rather, category 3 assessments should be used only after appropriate imaging work-up of screening-detected findings. Note that a screening examination assessed as BI-RADS category 3 with the recommendation for short-interval follow-up imaging is classified as a positive screening examination, and included in the recall rate calculation because additional imaging is recommended before the next interval screening.

    b. Breast US — The ACR Practice Parameters describe the standard protocol for screening examinations. As with screening mammography, a screening breast US examination is negative when the radiologist assigns a BI-RADS category 1 or 2 assessment. The BI-RADS 2 assessment includes findings that are classically benign, such as coarse calcifications on

mammogram and simple cysts on US, that do not require any additional diagnostic imaging. As with screening mammography, a screening breast US is positive when the examination is interpreted after the patient leaves the facility, and the final assessment is 0, 3, 4 or 5. A screening breast US is also positive when the interpreting radiologist performs, or directs a sonographer to perform, additional diagnostic breast US to further evaluate a potentially abnormal finding detected with screening US.

The ACR Practice Parameter and this Manual strongly recommend that sonographers or interpreting radiologists document diagnostic evaluations by acquiring and permanently archiving representative images. From an auditing perspective, this is identical to the acquisition of diagnostic mammography views, beyond the standard screening examination, to evaluate a mammographic finding while the patient remains at the facility for immediate results. This definition of a positive screening US examination is consistent with a modality neutral approach and applies to all examinations performed with a handheld transducer, whether the operator is the interpreting physician or an appropriately trained sonographer. As with online interpretation of a positive screening mammography examination, the acquisition of additional (diagnostic) images beyond those prescribed by the standard screening protocol, to further evaluate a finding *at the direction of the interpreting radiologist*, creates a diagnostic examination and converts the screening US examination to positive for auditing purposes, whether separate screening and diagnostic reports are issued.

The definition of a positive screening US examination is identical for automated screening breast US and handheld screening breast US if patients remain for results or depart the facility. When patients leave the facility and are recalled for additional diagnostic breast imaging examination(s) to further evaluate a potentially abnormal finding, this is, from an auditing perspective, identical to batch interpretation of a screening mammography examination for which the patient is recalled for additional diagnostic breast imaging (BI-RADS 0). Any type of screening US examination assessed as BI-RADS category 3, 4 or 5, is also a positive screening examination because additional action is recommended before the next screening.

c. Breast MRI — As with all other modalities, category 0, 3, 4 and 5 assessments on screening MRI are positive because additional action is recommended before the next screening. Unlike screening mammography and ultrasound, category 0 assessments for MRI should be rare, see page 703, and category 4 and 5 assessments are much more common for findings on screening breast MRI examinations. Historically, screening and diagnostic MRI protocols have been identical or nearly identical, allowing sufficient confidence for interpretation, assessment and recommendations for screen-detected findings without a separate additional diagnostic step. This remains within the acceptable standard of care. It is important for ongoing protocol development to separately audit breast MRI examinations performed for screening and/or diagnostic indications with full and/or abbreviated protocols to establish useful comparative benchmarks.

5. Positive diagnostic examination (all modalities) — This is a diagnostic examination for which tissue diagnosis is recommended (BI-RADS categories 4 and 5).

6. Negative diagnostic examination (all modalities) — This is a diagnostic examination for which tissue diagnosis is not recommended, that is, an examination assessed as negative, benign, or probably benign (BI-RADS category 1, 2, or 3 respectively). Note that a category 3 assessment is considered negative at diagnostic breast imaging (because tissue diagnosis is not recommended), whereas a category 3 assessment is considered positive at screening breast imaging (because it is associated with the recommendation for additional imaging before the next routine screening examination).

Table 2. Positive and Negative Examinations by BI-RADS® Assessment Category

Screening Examination		Diagnostic Examination	
Positive[a]	Negative	Positive[b]	Negative
BI-RADS categories 0, 3, 4, 5	BI-RADS categories 1, 2	BI-RADS categories 4, 5	BI-RADS categories 1, 2, 3

[a] A positive screening examination is defined as one for which additional diagnostic imaging or tissue diagnosis is recommended prior to the next screening examination. Note that the use of BI-RADS categories 3, 4, and 5 at screening mammography are discouraged.

[b] A positive diagnostic examination is one for which tissue diagnosis is recommended. Note that an incomplete (BI-RADS category 0) assessment should be made only rarely at diagnostic imaging due to inherent radiologist oversight of the examination, and category 0 assessments at diagnostic imaging are therefore not included in the audit. For further guidance, see the section *What Not to Audit*.

7. Cancer — This is tissue diagnosis of either ductal carcinoma in situ (DCIS), pleomorphic or florid lobular carcinoma in situ, or any type of primary (not metastatic) invasive breast carcinoma (Table 3).

8. Standard Ascertainment Interval — For auditing purposes, positive and negative truth are defined relative to the presence or absence of a tissue diagnosis of cancer within a standard ascertainment interval of time after breast imaging examination.

    a. Screening Ascertainment Interval — *In the definitions listed later in this section (true-positive, true-negative, etc.), as well as in the subsequent examples, the standard screening ascertainment interval is 1 year (365 days).* Breast imaging facilities with an alternate accepted local standard interval, such as 2 years, whether in the United States or elsewhere, should consistently replace the 1-year interval with their standard interval.

    b. Diagnostic Ascertainment Interval

        i. For diagnostic examinations performed as recall imaging (following BI-RADS category 0 assessment at screening), the ascertainment interval to cancer diagnosis begins on the date of the screening examination.

        ii. For diagnostic examinations performed for other indications not prompted by a recall from screening, such as a clinically detected lump, the ascertainment interval to cancer diagnosis begins on the date of the diagnostic examination. *The standard diagnostic interval is 1 year (365 days).*

    c. Probably Benign Ascertainment Interval — For initial BI-RADS category 3 assessments, the standard ascertainment interval is defined as the period routinely used by the breast imaging facility for total imaging surveillance of BI-RADS category 3 findings. In the U.S. the most common surveillance interval is 2 years, therefore, a positive outcome is a breast cancer diagnosis within 2 years of the initial BI-RADS category 3 assessment.

9. *True-Positive (TP)* — There is tissue diagnosis of breast cancer within one standard ascertainment interval after a positive examination (BI-RADS categories 0, 3, 4, or 5 for screening; BI-RADS categories 4 or 5 for diagnostic). BI-RADS category 3 assessments made at screening are positive examinations.

10. *True-Negative (TN)* — There is no known tissue diagnosis of breast cancer within one standard ascertainment interval of a negative examination (BI-RADS categories 1 or 2 for screening; BI-RADS categories 1, 2, or 3 for diagnostic).

11. *False-Negative (FN)* — There is tissue diagnosis of breast cancer within one standard ascertainment interval of a negative examination (BI-RADS category 1 or 2 for screening, BI-RADS category 1, 2, or 3 for diagnostic).

Table 3. Example Pathology Results for Correctly Auditing as True- and False-Positive for Sensitivity, Specificity, Cancer Detection Rate and Positive Predictive Values

TRUE-POSITIVE[a]	FALSE-POSITIVE[b]		
Malignant Mammary	**Malignant Non-mammary**	**Benign[c]**	
• Adenoid cystic carcinoma • Apocrine carcinoma • Carcinoma with endocrine differentiation • Ductal carcinoma in situ • Intracystic papillary carcinoma • Invasive ductal carcinoma • Invasive lobular carcinoma • Invasive mammary carcinoma • Inflammatory carcinoma • Invasive papillary carcinoma • Lobular carcinoma in-situ, pleomorphic • Lobular carcinoma in-situ, florid • Medullary carcinoma • Metaplastic carcinoma • Mucinous (colloid) carcinoma • Paget's disease (of the nipple) • Papillary carcinoma in-situ • Tubular carcinoma	• Angiosarcoma • Basal cell carcinoma • Fibrosarcoma • Hemangiopericytoma • Leiomyosarcoma • Liposarcoma • Leukemia • Lymphoma • Metastatic cancer to axillary lymph nodes, including metastatic breast cancer[d] • Metastatic cancer to the breast • Melanoma • Osteosarcoma • Plasmacytoma • Phyllodes, malignant • Squamous cell carcinoma	• Adenosis • Apocrine metaplasia • Atypical ductal hyperplasia • Atypical lobular hyperplasia • Benign cyst • Benign calcifications • Complex sclerosing lesion • Duct ectasia • Epidermal inclusion cyst • Fibroadenoma • Fibroadenomatoid change • Fibrocystic change • Fibrosis • Flat epithelial atypia • Galactocele • Granular cell tumor	• Gynecomastia • Hamartoma • Hemangioma • Inflammation • Intramammary lymph node • Lactating adenoma • Lipoma • Lobular carcinoma in-situ, classic • Normal breast tissue • Papilloma • Phyllodes, benign • Pleomorphic adenoma • Pseudoangiomatous stromal hyperplasia • Radial scar • Tubular adenoma • Usual ductal hyperplasia

[a] The concordant result of mammary (breast) malignancy is considered a positive pathology result. Imaging assessed as positive within the standard ascertainment interval of 1 year (365 days) prior to these diagnoses should be recorded as a true-positive. Imaging examinations that include findings of biopsy-proven pathology from the "True-Positive" column are appropriately assessed as BI-RADS assessment category 6, known malignancy.

[b] The concordant result of benign or non-mammary (non-breast) malignancy is considered a negative pathology result. Imaging assessed as positive within the standard ascertainment interval of 1 year (365 days) prior to these diagnoses should be recorded as a false-positive. Imaging examinations that include findings of biopsy-proven histology from the "False-Positive" columns are appropriately assessed as BI-RADS assessment category 2, benign.

[c] There are additional benign pathologies in the complete Data Dictionary maintained by the National Mammography Database (NMD) https://nrdrsupport.acr.org/support/solutions/articles/11000041537-nmd-data-dictionary

[d] Breast cancer in the axilla, diagnosed as a metastasis to an axillary lymph node is a false-positive. Breast cancer diagnosed as a primary cancer in the axilla, not involving a lymph node, is a true-positive.

12. *False-Positive (FP)* — There are three separate definitions:

    a. FP_1: No known tissue diagnosis of breast cancer within one standard ascertainment interval of a positive screening examination. This includes BI-RADS category 3 assessments made at screening.

    b. FP_2: No known tissue diagnosis of breast cancer within one standard ascertainment interval after recommendation for tissue diagnosis or surgical consultation (BI-RADS category 4 or 5).

    c. FP_3: Concordant benign tissue diagnosis (or discordant benign tissue diagnosis and no known tissue diagnosis of breast cancer) within one standard ascertainment interval after recommendation for tissue diagnosis (BI-RADS category 4 or 5).

    Note: TP + TN + FP + FN = Total number of examinations. This note refers to terms 9, 10, 11, and 12.

13. Positive Predictive Value (PPV) — There are three separate definitions:

    a. PPV_1 (abnormal findings at screening): The percentage of all positive screening examinations that result in a tissue diagnosis of breast cancer within one standard ascertainment interval. PPV_1 can be significantly different for each modality and accepted practice patterns. For example, nearly all positive screening mammography assessments constitute BI-RADS category 0. Screening assessments of BI-RADS categories 3, 4 or 5 are rare (use discouraged) for mammography but are possible. Positive breast MRI screening examinations, however, frequently receive a BI-RADS category 4 or 5 assessment and categories 0 and 3 are much less common.

    $$PPV_1 = TP / (\text{number of positive screening examinations})$$

    OR

    $$PPV_1 = TP / (TP + FP_1) \ (\text{see 12a for the definition of } FP_1)$$

    b. PPV_2 (biopsy recommended): The percentage of all diagnostic (or rarely, screening) examinations recommended for tissue diagnosis or surgical consultation (BI-RADS categories 4 and 5) that result in a tissue diagnosis of breast cancer within one standard ascertainment interval. Note that for breast MRI the difference between PPV_1 and PPV_2 will be small because positive breast MRI screening examinations frequently receive a BI-RADS category 4 or 5 assessment and categories 0 and 3 are much less common.

    $$PPV_2 = TP \Big/ \begin{pmatrix} \text{number of screening or diagnostic examinations} \\ \text{recommended for tissue diagnosis} \end{pmatrix}$$

    OR

    $$PPV_2 = TP / (TP + FP_2) \ (\text{see 12b for the definition of } FP_2)$$

    Note that PPV_2 is a metric designed to evaluate diagnostic imaging examinations. However, some published studies of mammography screening outcomes also report PPV_2 data. In the screening context, PPV_2 (or screening PPV_2) is based on a variant of the definition of FP_2, in which the positive examination includes the rare screening examination at which tissue diagnosis is recommended (BI-RADS categories 4 and 5), as well as the screening examination at which recall examination is recommended (BI-RADS category 0), followed by a diagnostic examination at which tissue diagnosis is recommended for the same finding (BI-RADS categories 4 and 5). Therefore, screening PPV_2 is meant to indicate the downstream outcomes of tissue diagnoses that result from positive screening examinations, even if the

recommendation for tissue diagnosis is made at the diagnostic imaging examination by a different interpreting physician than the screening interpreter who recommended only recall imaging. As such, screening PPV_2 is more pertinent as a measure of screening practice in general than as a direct measure of the performance of the interpreting physician who interpreted the screening examination.

c. PPV_3 (biopsy performed): The percentage of all known biopsies done as a result of positive diagnostic examinations (BI-RADS categories 4 and 5) that resulted in a tissue diagnosis of breast cancer within 1 standard ascertainment period. PPV_3 is also known as the Malignancy Yield of Biopsy or the Positive Biopsy Rate (PBR).

$$PPV_3 = TP/(\text{number of biopsies})$$

OR

$$PPV_3 = TP/(TP + FP_3)\,(\text{see 12c for the definition of } FP_3)$$

Note that although PPV_3 is a metric designed to evaluate diagnostic imaging examinations, it is occasionally used for mammography screening examinations, using similar definitions and for similar purposes as the use of PPV_2 at screening (see 13b).

14. Sensitivity — The probability of interpreting an examination as positive when cancer exists. This is measured as the number of positive examinations for which there is a tissue diagnosis of breast cancer within 1 standard ascertainment interval of the imaging examination, divided by all cancers present in the population examined within the same standard interval (Figure 1).

$$\text{Sensitivity} = TP/(TP + FN)$$

15. Specificity — The probability of interpreting an examination as negative when cancer does not exist. This is measured as the number of negative examinations for which there is no tissue diagnosis of breast cancer within 1 standard ascertainment interval of the examination, divided by all examinations for which there is no tissue diagnosis of cancer within the same standard interval (Figure 1).

$$\text{Specificity} = TN/(TN + FP)$$

16. Cancer Detection Rate (CDR) — The number of breast cancers detected at imaging per 1000 examinations

    a. This metric is only of value when calculated separately for screening and diagnostic examinations.

    b. This may also be calculated separately for "prevalent" breast cancers (those found at first-time screening examination) and for "incident" breast cancers (those found at subsequent screening examination performed at or close to the recommended screening interval).

$$\text{Cancer Detection Rate} = TP/(TP + FP + TN + FN)$$

17. Abnormal Interpretation Rate — The percentage of examinations interpreted as positive. For screening, positive examinations include all BI-RADS category 0, 3, 4 and 5 assessments (Table 2). For diagnostic imaging, positive examinations include all BI-RADS category 4 and 5 assessments (Table 2). These do not include examinations with BI-RADS category 6 assessments except for

		BIOPSY RESULTS	
		Positive = tissue diagnosis of cancer within 1 standard ascertainment interval (1 year)	Negative = concordant benign tissue diagnosis, or no tissue diagnosis of cancer within 1 standard ascertainment interval (1 year)
SCREENING	Breast imaging positive (BI-RADS categories 0, 3, 4, 5)	TP	FP
	Breast imaging negative (BI-RADS categories 1, 2)	FN	TN

Sensitivity = TP/(TP + FN)
Specificity = TN/(TN + FP)
PPV = TP/(TP + FP)

		BIOPSY RESULTS	
		Positive = tissue diagnosis of cancer within 1 standard ascertainment interval (1 year)	Negative = concordant benign tissue diagnosis, or no tissue diagnosis of cancer within 1 standard ascertainment interval (1 year)
DIAGNOSTIC	Breast imaging positive (BI-RADS categories 4, 5)	TP	FP
	Breast imaging negative (BI-RADS categories 1, 2, 3)	FN	TN

Sensitivity = TP/(TP + FN)
Specificity = TN/(TN + FP)
PPV = TP/(TP + FP)

Figure 1 – References for Biopsy Results — Screening and Diagnostic.

the purposes of auditing examinations performed specifically to assess the extent of disease. See the "Diagnostic Breast MRI Performed for Extent of Disease" in the *More Complete Audit* (section III) and the *What Not to Audit* (section V. A.) for additional guidance.

$$\text{Abnormal Interpretation Rate} = (TP + FP)/(TP + FP + TN + FN)$$

Note that many scientific publications describing screening mammography correctly assert that *Recall Rate (RR)* is equivalent to the Abnormal Interpretation Rate (AIR). Recall Rate is the specific term applied to AIR for *screening* examinations. Recall Rate is not the subset of screening examinations with final assessments of BI-RADS 0. (Examinations with temporary BI-RADS 0 assessments, such as technical repeats and requests for prior examinations, are not final.) Calculation of a RR is meaningful for screening mammography only if it represents the AIR. That is, only if *all* positive screening examinations, BI-RADS category 0, 3, 4, and 5 assessments, are counted, not just BI-RADS category 0. Screening is applied for the sole purpose of making the binary decision of recommending action before the next interval screening versus recommending no action until the next interval screening. BI-RADS category 0, 3, 4, and 5 assessments all recommend action within the next standard screening interval that defines the "positive" screening examination. This accomplishes objectivity and reproducibility (and overcomes subjectivity) by basing the auditing rule on something that does not require judgment.

II. THE BASIC CLINICALLY RELEVANT AUDIT

FDA regulations [1, 2] specify that mammography facilities "collect and review outcome data for all mammograms performed, including follow-up on the disposition of all positive mammograms and correlation of pathology results with the interpreting physician." Certain minimum raw data elements, defined below, should be collected and utilized to calculate important derived data that allow each interpreting physician to assess their overall performance in breast imaging interpretation. Only PPV, CDR and RR are required by the MQSA, and this applies only to mammography, so even a basic audit involves much more data collection and analysis than what is currently required by federal regulations [1].

The FDA and ACR consider diagnostic mammograms with a final assessment of suspicious (BI-RADS category 4) or highly suggestive of malignancy (BI-RADS category 5) to be positive. However, diagnostic examinations with category 0 assessments are neither positive nor negative (see *What Not to Audit* (section V. A.)). These are rare scenarios in which the diagnostic evaluation is incomplete, and a definitive assessment has yet to be rendered. However, screening examinations with final assessments of category 0 are considered positive for the ACR audit described in this Manual. The ACR asserts that a meaningful audit of screening examinations requires that a management recommendation for additional imaging evaluation (BI-RADS category 0) also be considered positive, and that facilities should collect and review outcome data on category 0 screening examinations.

DATA FOR THE BASIC CLINICALLY RELEVANT AUDIT

A. Raw data to be collected

1. Modality or modalities.
2. Dates of audit period and total number of examinations in that period.
3. Number of screening examinations; number of diagnostic examinations (separate audit statistics should be maintained for each).
4. Number of ACR BI-RADS category 0 assessments — "Need additional imaging evaluation."
5. Number of ACR BI-RADS category 3 assessments — "Probably benign."
6. Number of ACR BI-RADS category 4 assessments — "Suspicious" and category 5 assessments — "Highly suggestive of malignancy."
7. Tissue diagnosis results: positive or negative, for all ACR BI-RADS category 0, 3, 4 and 5 assessments (ACR suggests that you keep separate data for fine-needle aspiration/core biopsy cases and for surgical biopsy cases). MQSA Final Rule requires that an attempt is made to collect tissue diagnosis results for those mammography examinations for which tissue diagnosis is recommended [1].
8. Cancer staging: histologic type, invasive cancer size (single largest dimension), nodal status, tumor grade, and biomarker status when available.
9. MQSA Final Rule also requires analysis of any *known* false-negative mammography examinations by attempting to obtain surgical and/or pathology results and by review of false-negative mammography examinations [1].

B. Derived data to be calculated

1. True-positives (TP)
2. False-positives (FP_1, FP_2, FP_3)
3. Positive predictive value (PPV_1, PPV_2, PPV_3)
    a. In a screening/diagnostic facility, PPV may be obtained in one or more of three ways:
        1. PPV_1 — denominator includes all cases at screening examination recommended for anything other than breast cancer screening (BI-RADS categories 0, 3, 4, 5)
        2. PPV_2 — denominator includes all cases recommended for tissue diagnosis procedure (BI-RADS categories 4, 5)
        3. PPV_3 — denominator includes all cases of tissue diagnosis procedures performed, otherwise known as biopsy yield of malignancy or positive biopsy rate (PBR)
    b. If screening exclusively, obtain in only one way: PPV_1 — based on "positive" cases at screening examination, which includes recommendation for anything other than breast cancer screening (BI-RADS categories 0, 3, 4, 5)
4. Breast cancer detection rate
5. Percentage of invasive breast cancers that are node-negative
6. Percentage of breast cancers that are "minimal" (minimal cancer is defined as invasive cancer ≤ 1 cm, or ductal carcinoma in-situ or pleiomorphic or florid lobular carcinoma in-situ of any size)
7. Percentage of breast cancers that are stage 0 or I
8. Abnormal interpretation rate (aka recall rate) for screening examinations
9. Outcomes for initial BI-RADS category 3 assessments (new to the BI-RADS v2025 Manual, see text below)
    a. Frequency of initial BI-RADS category 3 assessments
    b. Percentage of screening examinations that result in an initial BI-RADS category 3 assessment at diagnostic imaging (calculated for screening examinations only)
    c. Percentage of initial BI-RADS category 3 assessments that result in a breast cancer diagnosis

Collection and calculation of all the data in the *Basic Clinically Relevant Audit* requires proper coding of the data elements for efficient retrieval, often requiring considerable effort. However, once collected and calculated, these data allow clinically relevant measurement of one's practice outcomes by providing quantifiable evidence in pursuit of the three major goals of breast cancer screening:

1. Find a high percentage of breast cancers that exist in a screening population (measurement: cancer detection rate).
2. Find these breast cancers within an acceptable range of recommendations for additional imaging and recommendations for tissue diagnosis, to minimize cost and morbidity (measurement: recall rate, abnormal interpretation rate, positive predictive values).
3. Find a high percentage of small, node-negative, early-stage breast cancers, which are more likely to be curable (measurement: percentages of node-negative, minimal, and stage 0 + I cancers).

FLOWCHART EXAMPLES FOR DERIVED DATA TO BE CALCULATED

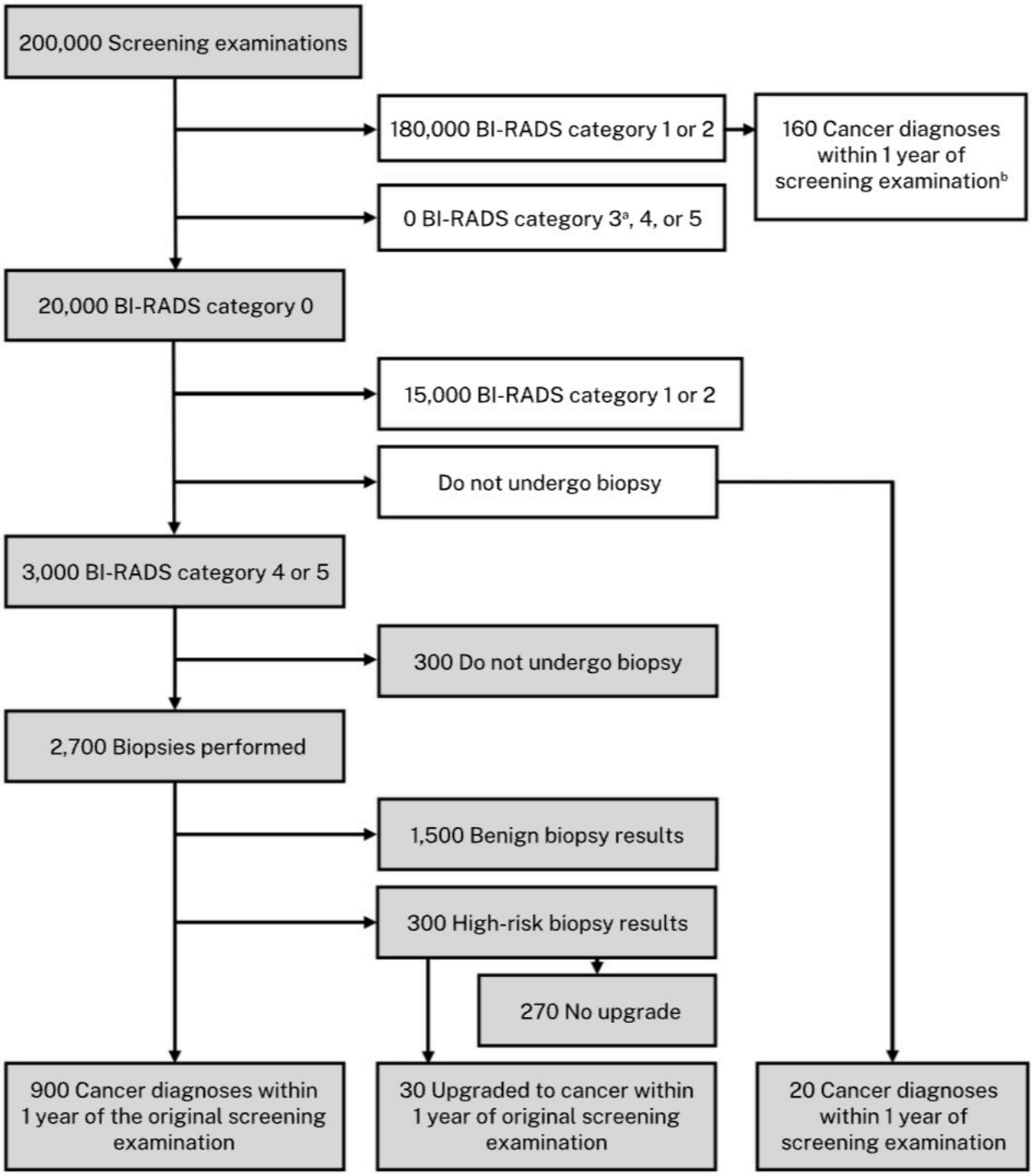

[a] Please refer to Figure 4 for a detailed explanation of how to audit BI-RADS category 3 findings.

[b] These screening examinations represent false-negatives and should be included within the *More Complete Audit* (if measurable).

Note: Gray-filled boxes indicate data used in audit calculations for screening. Numbers and outcomes above serve as an example based on performance benchmarks published in this Manual.

Figure 2 – Flowchart Example of Outcomes for 200,000 Screening Examinations and Subsequent *Basic Clinically Relevant Audit* Calculations for Screening.

Basic Clinically Relevant Audit Example for Screening: Cancer ascertainment period for this example is 1 year, the standard screening interval recommended by the ACR (Figure 2).

1. True-positives: Breast cancer diagnoses within one year of a positive screening examination (category 0, 3, 4, and 5).

$$\begin{array}{rr} \textit{Cancer diagnoses following category 0 recall} & 900 \\ \textit{Cancer diagnoses upgraded from high risk} & 30 \\ + \quad \textit{Cancer diagnoses prompted by category 3} & + \quad 20 \\ \hline \textit{TP} & 950 \end{array}$$

2. False-positives:

   FP_1 = No known tissue diagnosis of cancer within 1 standard interval (1 year in the U.S.) of a positive screening examination.

$$\begin{array}{rr} \textit{Positive screening examinations} & 20{,}000 \\ - \quad \textit{TP} & - \quad 950 \\ \hline \textit{FP}_1 & 19{,}050 \end{array}$$

   FP_2 and FP_3: Not calculated here because FP_2 and FP_3 are designed to evaluate the performance of the radiologist(s) who interpreted the diagnostic examinations who may not be the same radiologist(s) who interpreted the screening eaminations in question. A caveat to this is examinations for which there is no difference in the images recorded for a screening or diagnostic examination.

3. Positive predictive values:

   PPV_1 = Percentage of all positive screening examinations (category 0, 3, 4, and 5) that result in a tissue diagnosis of cancer within 1 standard interval (1 year in the U.S.)

$$= \frac{\textit{TP}}{\textit{Positive screening examinations}} \; \textit{OR} \; \frac{\textit{TP}}{\textit{TP} + \textit{FP}_1} = \frac{950}{20{,}000}$$

$$\textit{OR} \; \frac{950}{950 + 19{,}050} = 0.048 = 4.8$$

   PPV_2 and PPV_3: Not calculated here because FP_2 and FP_3 are designed to evaluate the performance of the radiologist(s) who interpreted the diagnostic examinations who may not be the same radiologist(s) who interpreted the screening eaminations in question. A caveat to this is examinations for which there is no difference in the images recorded for a screening or diagnostic examination.

4. Cancer detection rate (per 1,000 examinations):

$$= \frac{\textit{TP}}{\textit{Total screening examinations}} \times 1{,}000 = \frac{950}{200{,}000} \times 1{,}000 = 4.75$$

5. Percentage of invasive cancers that are node negative:

$$= \frac{\textit{Node negative invasive cancers}}{\textit{Total invasive cancers}} \times 100$$

6. Percentage of minimal cancers:

$$= \frac{\textit{Minimal cancers}}{\textit{TP}} \times 100 = \frac{\textit{DCIS} + \textit{fLCIS} + \textit{pLCIS} + \left(\textit{Invasive cancers} \leq 1.0 \textit{ cm}\right)}{\textit{TP}} \times 100$$

7. Percentage of stage 0 or I cancers:

$$= \frac{\textbf{Stage 0 cancers} + \textbf{stage I cancers}}{\textbf{TP}} \times 100$$

$$= \frac{\textbf{DCIS} + \textbf{fLCIS} + \textbf{pLCIS} + \textbf{stage I cancers}}{\textbf{TP}} \times 100$$

8. Abnormal interpretation (recall) rate (per 100 examinations):

$$= \frac{\textbf{Positive screening examinations (category 0, 3, 4 or 5)}}{\textbf{Total screening examinations}} \times 100$$

$$= \frac{20{,}000}{200{,}000} \times 100 = 10.0\%$$

Basic Clinically Relevant Audit Example for Diagnostic Imaging: Cancer ascertainment period for this example is 1 year, the standard screening interval recommended by the ACR (Figure 3).

Note: For diagnostic examinations performed as recall imaging (following BI-RADS category 0 assessment at screening), the interval to cancer diagnosis begins on the date of the screening examination. For diagnostic examinations performed for other indications, such as a new palpable lump, the interval to cancer diagnosis begins on the date of the diagnostic examination.

1. True-positives: Positive diagnostic examinations with a breast cancer diagnosis during the 1-year cancer ascertainment period (see above).

Cancer diagnoses following initial diagnostic examination	2,000
Cancer diagnoses upgraded from high risk	70
+ *Cancer diagnoses following biopsy recommendation after category 3*	+ 70
TP	2,140

2. False-positives:

   FP_1: Not included here because this metric is designed to evaluate screening performance.

   FP_2 = No known tissue diagnosis of cancer within 1 standard ascertainment interval (1 year in the U.S.) after recommendation for tissue diagnosis or surgical consultation on the basis of a positive examinaton (category 4 or 5).

Benign biopsies following initial diagnostic examination	4,000
Benign high risk without upgrade	630
Benign biopsies following biopsy recommendation after category 3	330
+ *Category 4 or 5 that did not undergo biopsy*	+ 800
FP_2	5,760

   FP_3 = Concordant benign tissue diagnosis (or discordant benign tissue diagnosis and no known tissue diagnosis of cancer) within 1 standard ascertainment interval (1 year in the U.S.) after recommendation for tissue diagnosis on the basis of a positive examination (category 4 or 5).

Benign biopsies following initial diagnostic examination	4000
Benign high risk without upgrade	630
+ *Benign biopsies following biopsy recommendation after category 3*	+ 330
FP_3	4960

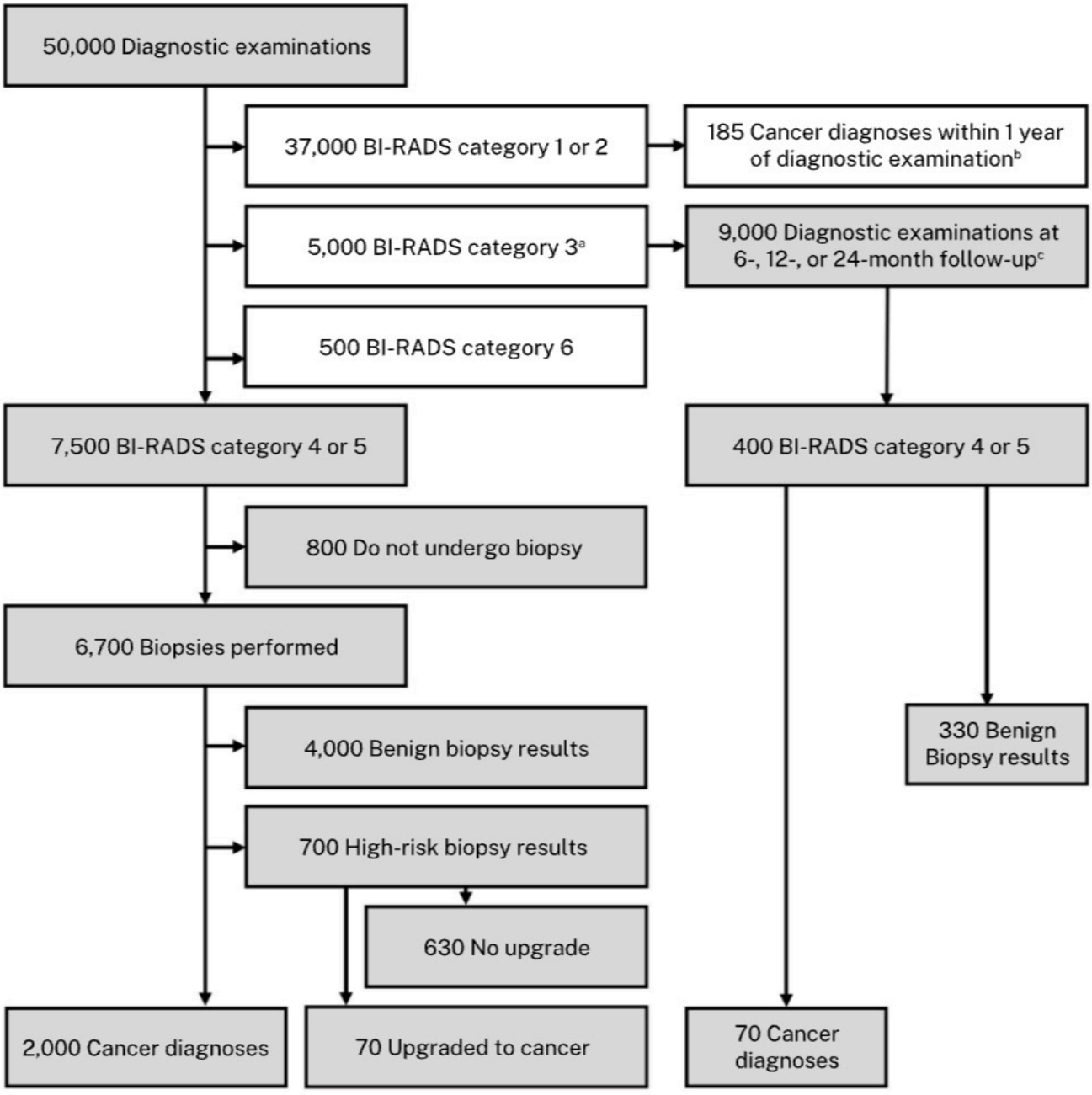

[a] Please refer to Figure 4 for a detailed explanation of how to audit BI-RADS category 3 findings. Also, for ease of understanding, this flowchart example assumes that no cancers were diagnosed by biopsy of a BI-RADS category 3 finding.

[b] These diagnostic examinations represent false-negatives and should be included within the *More Complete Audit* (if measurable).

[c] The standard ascertainment interval begins anew for each of these follow-up examinations, but for ease of understanding, these 9,000 examinations will be considered in conglomerate with the original examinations for the basic audit calculations that follow this flowchart.

Note: Gray-filled boxes indicate data used in audit calculations for diagnostic imaging. Numbers and outcomes are examples based on performance benchmarks published in this Manual.

Figure 3 – Flowchart Example of Outcomes for 50,000 Diagnostic Examinations and Subsequent *Basic Clinically Relevant Audit* Calculations for Diagnostic Imaging.

3. Positive predictive values:

   PPV_1: Not included here because this metric is designed to evaluate screening performance.

   PPV_2 = The percentage of all diagnostic examinations recommended for tissue diagnosis or surgical consultation (categories 4 and 5) that result in a diagnosis of cancer within 1 standard ascertainment interval (1 year in the U.S.).

$$= \frac{TP}{\text{Examinations recommended for tissue diagnosis}} \; OR \; \frac{TP}{TP + FP_2}$$

$$= \frac{2{,}140}{7{,}500 + 400} \; OR \; \frac{2{,}140}{2{,}140 + 5{,}760} = 0.271 = 27.1$$

   PPV_3 = The percentage of biopsied cases with a tissue diagnosis of cancer within 1 standard ascertainment interval (1 year in the U.S.) following a positive diagnostic examination (categories 4 and 5)

$$= \frac{TP}{\text{Total number of cases undergoing tissue diagnosis}} \; OR \; \frac{TP}{TP + FP3}$$

$$= \frac{2{,}140}{6{,}700 + 400} \; OR \; \frac{2{,}140}{2{,}140 + 4{,}960} = 0.301 = 30.1\%$$

4. Cancer detection rate (per 1000 diagnostic examinations):

$$= \frac{TP}{\text{Total diagnostic examinations}} \times 1{,}000 = \frac{2{,}140}{50{,}000 + 9{,}000 - 500 \text{ category 6}} \times 1{,}000 = 36.6$$

5. Percentage of invasive cancers that are node negative:

$$= \frac{\text{Invasive cancers that are node negative}}{\text{Total invasive cancers}} \times 100$$

6. Percentage of minimal cancers:

$$= \frac{\text{Minimal cancers}}{TP} \times 100 = \frac{DCIS + fLCIS + pLCIS + (\text{Invasive cancers} \leq 1.0 \text{ cm})}{TP} \times 100$$

7. Percentage of stage 0 or I cancers:

$$= \frac{\text{Stage 0 cancers} + \text{stage I cancers}}{TP} \times 100 = \frac{DCIS + fLCIS + pLCIS + \text{stage I cancers}}{TP} \times 100$$

8. Abnormal interpretation rate (per 100 examinations):

$$= \frac{\text{Positive diagnostic examinations (category 4 or 5)}}{\text{Total diagnostic examinations}} \times 100$$

$$= \frac{7{,}500 + 400}{50{,}000 + 9{,}000 - 500 \text{ category 6}} \times 100 = 13.5$$

A. BI-RADS CATEGORY 3 AUDITING

New to this version of the ACR BI-RADS Manual is complete outcomes monitoring of examinations with initial BI-RADS category 3 assessments. The purpose of monitoring BI-RADS category 3 outcomes is to encourage appropriate use. The literature has confirmed that BI-RADS category 3

is occasionally being used incorrectly for findings that should be assessed as category 2 or 4 resulting in unnecessary follow-up examinations or delays in appropriate tissue sampling [2–4]. Adherence to strict criteria for appropriate BI-RADS category 3 assessments is critical for patient safety. For example, data from the National Mammography Database (NMD) from 2009–2018 indicate that the majority of BI-RADS category 3 findings following screening mammography recall were downgraded to BI-RADS categories 1 or 2 before 24 months of total imaging surveillance, indirectly implying some inappropriate overuse of BI-RADS category 3 assessments for benign findings [5]. More appropriate BI-RADS category 3 use is desired. *Note that monitoring only the frequency of BI-RADS category 3 assessments and the percentage of initial BI-RADS category 3 assessments that result in a breast cancer diagnosis will not determine the extent to which benign and suspicious findings are being assessed as BI-RADS category 3; this is facilitated only by the additional auditing detailed in the* More Complete Audit *(section III. B. Derived Data to be Calculated #10).*

Only the initial BI-RADS category 3 assessments, first assigned either at screening (which is discouraged) or at initial diagnostic imaging (See above "Data to be collected" #5 and "Derived data to be calculated" #9), are included in the total denominator. Table 1 should be used to correctly designate examinations as either screening or diagnostic based on indication. The reason for including only initial BI-RADS category 3 assessments, rather than all BI-RADS category 3 assessments, is that the established likelihood of malignancy for BI-RADS category 3 mammogram findings of 2% or less was calculated by dividing the number of malignant BI-RADS category 3 examinations by the total number of initial BI-RADS category 3 examinations. Including all, rather than initial, BI-RADS category 3 assessments would count each finding more than once within this calculation, falsely increase the denominator, and yield an inaccurately low percentage of BI-RADS category 3 assessments that result in a breast cancer diagnosis. *Therefore, follow-up BI-RADS category 3 assessments repeated at diagnostic imaging after an initial BI-RADS category 3 assessment are tracked but not counted towards the denominator for the audit.* Stated simply, including only initial BI-RADS category 3 assessments allows for accurate correlation with the already established likelihood of malignancy for BI-RADS category 3 mammogram findings of 2% or less.

BI-RADS category 3 auditing should be performed separately for screening and diagnostic imaging. Moreover, initial BI-RADS category 3 assessments at diagnostic imaging prompted by a BI-RADS category 0 screening examination should be monitored apart from initial BI-RADS category 3 assessments at diagnostic imaging not prompted by a BI-RADS category 0 screening examination. This is similar to the separate auditing of diagnostic mammography examinations performed for work-up of abnormal screening mammograms and palpable findings.

BI-RADS category 3 is *not* an indeterminate category for a radiologist to invoke when undecided between BI-RADS assessment categories 2 (benign) and 4 (suspicious). *Moreover, category 3 assessments are not appropriate for screening mammography and should be assigned only after appropriate diagnostic imaging.* This allows for prompt verification of characteristically benign findings and timely diagnosis of some rapidly growing breast cancers [4]. Certain details and definitions must be understood for successful outcome monitoring of initial BI-RADS category 3 assessments:

1. In the U.S. the most common surveillance interval for a BI-RADS 3 finding is 2 years, therefore, a positive outcome is a breast cancer diagnosis within 2 years of the initial BI-RADS category 3 assessment. *Thus, positive "truth" for initial BI-RADS category 3 assessments is defined as a breast cancer diagnosis occurring during the cancer ascertainment period of 2 years.*

2. The audit of initial BI-RADS category 3 assessments should be performed no sooner than one year after completion of the cancer ascertainment period of 2 years.

3. Auditing initial BI-RADS category 3 assessments from diagnostic imaging in symptomatic patients is expected to reveal a higher likelihood of malignancy than auditing initial BI-RADS category 3 assessments prompted by screening in asymptomatic patients given the inherently higher pre-test probability of malignancy.
4. Robust literature delineating findings with a likelihood of malignancy of 2% or less supports BI-RADS category 3 assessment and periodic surveillance for specific mammographic and sonographic findings (see Mammography and Ultrasound sections). The scientific evidence for surveillance of specific MRI findings has not reached consensus and the use of BI-RADS category 3 for MRI is often based on radiologist experience. Thus, the BI-RADS category 3 audit for MRI for one facility may not be relevant for other facilities. Radiologists are encouraged to use BI-RADS descriptors appropriately and consistently to facilitate future investigation of imaging findings with a likelihood of malignancy of 2% or less.

Outcomes for initial BI-RADS category 3 assessments: Explained in detail within Figure 4 below.

BASIC CLINICALLY RELEVANT AUDIT CALCULATIONS FOR BI-RADS CATEGORY 3 AUDITING

It is also important to remember that the cancer ascertainment period for initial BI-RADS category 3 assessments is defined as the recommended total imaging surveillance of two years for BI-RADS category 3 findings.

1. Outcomes for initial BI-RADS category 3 assessments made at screening: The flowchart includes no initial BI-RADS category 3 assessments made at screening (strongly discouraged with screening mammography). Thus, two of three metrics below equal zero for this example.
   a) Frequency of initial BI-RADS category 3 assessments at screening:

$$= \frac{\textbf{\textit{Initial category 3 assessments}}}{\textbf{\textit{Total screening examinations}}} \times 100 = \frac{0}{200{,}000} \times 100 = 0\%$$

   b) Percentage of screening examinations that result in an initial BI-RADS category 3 assessment at diagnostic imaging:

$$= \frac{\textbf{\textit{Initial category 3 assessments at diagnostic imaging after a category 0 recall}}}{\textbf{\textit{Total screening examinations}}}$$

$$= \frac{2{,}000}{200{,}000} = 1\%$$

   c) Percentage of initial BI-RADS category 3 assessments at screening that result in a breast cancer diagnosis:

$$= \frac{\textbf{\textit{Malignant initial category 3 assessments}}}{\textbf{\textit{Total initial category 3 assessments}}} \times 100 = 0 \times 100 = 0\%$$

2. Outcomes for initial BI-RADS category 3 assessments made at diagnostic imaging prompted by a BI-RADS category 0 screening examination:
   a. Frequency of initial BI-RADS category 3 assessments at diagnostic imaging prompted by category 0 screening:

$$\frac{\textbf{\textit{Initial category 3 assessments}}}{\textbf{\textit{Total diagnostic examinations prompted by a category 0}}} \times 100 = \frac{2{,}000}{20{,}000} \times 100 = 10\%$$



Note: Gray-filled boxes indicate data included in the calculations for BI-RADS category 3 auditing. Blue-filled boxes indicate BI-RADS category 3 assessments that do not meet the definition of an initial BI-RADS category 3 assessment and are thus excluded from BI-RADS category 3 audit calculations. See the text below for more details. Numbers and rates in the above figure have been selected purely to illustrate the auditing process and should not be interpreted as benchmarks or performance standards.

Figure 4 – Flowchart Example of Outcomes for BI-RADS® Category 3 Examinations and Subsequent Basic Clinically Relevant Audit Calculations for BI-RADS Category 3.

b. Percentage of initial BI-RADS category 3 assessments at diagnostic imaging prompted by category 0 screening that result in a breast cancer diagnosis:

$$\frac{\textit{Malignant initial category 3 assessments}}{\textit{Total initial category 3 assessments}} \times 100 = \frac{1+19+5+5}{2{,}000} \times 100 = 1.5\%$$

3. Outcomes for initial BI-RADS category 3 assessments made at diagnostic imaging not prompted by a BI-RADS category 0 screening examination:

   a. Frequency of initial BI-RADS category 3 assessments at diagnostic imaging not prompted by category 0 screening:

$$\frac{\textit{Initial category 3 assessments}}{\textit{Total diagnostic examinations not prompted by a category 0}} \times 100 = \frac{3{,}000}{30{,}000} \times 100 = 10\%$$

   b. Percentage of initial BI-RADS category 3 assessments at diagnostic imaging not prompted by category 0 screening that result in a breast cancer diagnosis:

$$= \frac{\textit{Malignant initial category 3 assessments}}{\textit{Total initial category 3 assessments}} \times 100 = \frac{1+39+8+8}{3{,}000} \times 100 = 1.9\%$$

B. BENCHMARKS AND ACCEPTABLE RANGES

Auditing data are more clinically useful if the outcomes observed for a given breast imaging facility or for an individual interpreting physician are compared with standard performance parameters that have been designated as acceptable. To this end, for mammography the numbers obtained for each of the data elements to be calculated in (see Section II Derived data to be calculated, page 817) may be compared to:

1. Benchmarks reported by the Breast Cancer Surveillance Consortium (BCSC) and NMD (https://nrdr.acr.org/Portal/NMD), both of which include data from large numbers of screening and diagnostic mammography examinations that are likely to be representative of practice in the United States (Tables 4 and 7).
2. Recommendations derived by a panel of expert breast imaging interpreting physicians, based on critical analysis of scientific data published in the peer-reviewed literature (including BCSC data), as well as extensive personal experience.

Screening US benchmarks (Table 5) have been limited to multi-institutional trials representing practice in the United States and specifically conducted to prospectively establish the performance of US independent from mammography. Trials designed to establish the incremental benefit of screening US in addition to mammography have been excluded to remain consistent with the screening benchmarks for mammography and MRI. There are no published, peer-reviewed data to establish rigorous benchmarks for pure diagnostic ultrasound performed without diagnostic mammography.

Selected MRI benchmarks have been reported for screening breast MRI from clinical trials, from/across multiple-sites in the BCSC, and from single-site practice audits to be representative of practice in the United States. These include outcomes for different types of MRI (full-protocol, abbreviated) and for different patient populations (e.g., "high risk", dense breasts). Practices should compare their performance to the appropriate benchmarks most relevant to their program (Table 6). New data provide initial audit metrics and benchmarks for breast MRI performed with the specific indication to evaluate the extent of disease (EOD) following a new diagnosis of cancer (Table 8). Note this does not include breast MRI examinations performed to evaluate response to neoadjuvant treatment, short-interval follow-up or problem-solving indications. See MRI chapter for standard examination indications.

Table 4. Analysis of Medical Audit Data: BCSC and NMD Mammography Screening Benchmarks and Acceptable Ranges per Expert Consensus

	Breast Cancer Surveillance Consortium (BCSC)[c]		National Mammography Database (NMD)[d]	
	2D Digital Mammography Benchmarks, 2011–2018 [6]	Digital Breast Tomosynthesis (DBT) Benchmarks, 2011–2018 [6]	Benchmarks, 2008–2014 [7]	Acceptable Range [8]
Breast cancer detection rate (per 1,000 examinations)	5.3	5.8	3.74	≥ 2.5
Median size of invasive breast cancer (in mm)	13	12	NR	NR
Percentage of invasive breast cancers without nodal metastasis	72.2%	78.8%	NR	NR
Percentage minimal breast cancer[a]	55.6%	54.6%	NR	NR
Percentage stage 0 or I breast cancer	78.0%	79.6%	NR	NR
Recall rate[b]	10.3%	8.3%	9.6%	5–12%
PPV_1 (abnormal interpretation)	5.2%	6.9%	NR	3–8%
PPV_2 (recommendation for tissue diagnosis)	27.9%	32.2%	20%	20–40%
PPV_3 (biopsy performed)	31.7%	35.5%	29%	NR
Sensitivity (if measurable)[c]	87.6%	87.4%	NR	≥ 75%
Specificity (if measurable)[c]	90.2%	92.2%	NR	88–95%
False negative rate (per 1,000 examinations)	0.8	0.8	NR	NR

[a] Minimal breast cancer is invasive cancer ≤ 1 cm or carcinoma in situ.

[b] Recall rate is the abnormal interpretation rate for screening examinations and includes BI-RADS 0, 3, 4 and 5 examinations.

[c] Sensitivity and specificity are measured with reasonable accuracy only if outcomes data are linked to breast cancer data in a regional tumor registry.

[d] The percentage of 2D and DBT screening mammography examinations in the database for the 2008–2014 date range are not specified.

NR = not reported

Table 5. Analysis of Medical Audit Data: Breast US Screening Benchmarks

	ACRIN 6666 [9, 10] HHUS[d] Prevalent Screening (95% CI)	ACRIN 6666 [9, 10] HHUS[d] Incident Screening (95% CI)
Breast cancer detection rate (per 1,000 examinations)	9.0 (6.1–13.4)	7.1 (5.2–9.1)
Median size of invasive breast cancer (in mm)	NR	10 .0
Percentage of invasive breast cancers without nodal metastasis	NR	96%
Percentage minimal breast cancer[a]	NR	NR
Percentage stage 0 or I breast cancer	NR	NR
Recall rate	20.9% (19.4–22.5)	10.7% (9.8–11.6)
Short interval follow-up rate[b]	11.1% (10.0–12.4)	3.9% (3.4–4.5)
PPV_1 (abnormal interpretation)	4.3% (2.9–6.4)	6.6% (4.9–8.5)
PPV_2 (recommendation for tissue diagnosis)	8.6% (5.7–12.6)	10.9% (8.0–14.0)
PPV_3 (biopsy performed)	9.0% (6.0–13.4)	11.7% (8.4–15.1)
Sensitivity (if measurable)[c]	66.7% (50.3–79.8)	45.3% (34.2–56.4)
Specificity (if measurable)[b]	79.8% (78.2–81.2)	89.9% (89.8–91.6)
False negative (per 1,000 examinations)	NR	NR

[a] Minimal breast cancer is invasive cancer ≤ 1 cm or carcinoma in situ.

[b] Short interval follow-up rate is equivalent to BI-RADS category 3 assessment.

[c] Sensitivity and specificity are measured with reasonable accuracy only if outcomes data are linked to breast cancer data in a regional tumor registry to verify false-negative results.

[d] HHUS examinations in ACRIN 6666 (n = 2662 patients) were performed on patients with heterogeneously dense or extremely dense breast tissue in at least one quadrant and at elevated risk for breast cancer by physicians in expert-practice trained according to study protocol in 2004–2006. The results may not be directly comparable to non-expert-practice and/or examinations performed on average risk patients by personnel without formal training.

HHUS = handheld ultrasound screening; NR = not reported.

Note: Data for these benchmarks reflect published peer-reviewed results of standalone screening handheld breast ultrasound to be consistent with benchmarks for screening mammography (Table 4) and screening MRI (Table 6). There are no published peer reviewed results of standalone ABUS. Published peer reviewed results of the incremental benefit of screening breast ultrasound in addition to screening mammography were not included.

Table 6. Analysis of Medical Audit Data: Breast MRI Screening Benchmarks >

Table 6. Analysis of Medical Audit Data: Breast MRI Screening Benchmarks

	5 Prospective Trials, Patients at Increased Hereditary Risk, Expert-Practice [11–15]	BCSC 2005–2013, 8387 Exams, Retrospective, Any Screening Indication [16]	3 Ret Practic High-R Single
Breast cancer detection rate (per 1,000 examinations)	20–30	17	
Median size of invasive breast cancer (in mm)	TBD	10	
Percentage of invasive breast cancers without nodal metastasis	> 80%	88%	
Percentage minimal breast cancer[a]	> 50%	69%	
Percentage stage 0 or I breast cancer	TBD	87%	
Recall rate (%)	n/a	18.5%	
PPV_1 (abnormal interpretation)	n/a	9%	
PPV_2 (recommendation for tissue diagnosis)	15%	19%	
PPV_3 (biopsy performed)	20–50%	21%	
Sensitivity (if measurable)[b]	> 80%	81%	
Specificity (if measurable)[b]	85–90%	83%	

[a] Minimal breast cancer is invasive cancer ≤ 1 cm or carcinoma in situ.

[b] Sensitivity and specificity are measured with reasonable accuracy only if outcomes data are linked to

[c] Average risk, heterogeneously or extremely dense, MG with DBT

[d] Extremely dense, average risk

TBD = to be determined; NR = not reported.

rospective Clinical e Audits, Patients at Risk for Any Reason, -Institution [17–19]	EA1141[c] Prevalence Round, Abbreviated Protocol, 2016–2017, Multi-Site, 1444 Women [20]	DENSE Trial[d] - Prevalence Round 1, 2011–2016, RCT with 8061 Women [21]	DENSE Trial[d] - Incidence Round 2, 3436 Women [22]
13–22	15.2	16.5	5.8
NR	10.5	9.5	7
62–92%	96%	88.6%	100%
51–70%	NR	NR	NR
97%	NR	91.1%	100%
8–12%	7.5%	9.5%	3.2%
12–16%	NR	17.4%	18.2%
22–29%	NR	23.9%	21.7%
24–31%	19.6%	26.3%	23.8%
84%	95.7%	95.2%	NR
93%	86.7%	92%	NR

breast cancer data in a regional tumor registry.

Table 7. Analysis of Medical Audit Data: BCSC Diagnostic Mammography Benchmarks and Acceptable Ranges per Expert Consensus[a]

	All Diagnostic Examinations [23]	Palpable Findings [23]	Work-Up of Abnormal Screen [23]	Acceptable Range – Palpable [24]	Acceptable Range - Work-Up of Abnormal Screen [24]
Breast cancer detection rate (per 1,000 examinations)	34.7	64.5	45.8	≥ 40	≥ 20
Mean size of invasive breast cancer (in mm)	21.2	28.6	16.1	NR	NR
Percentage of invasive breast cancers without nodal metastasis	69.6%	58.6%	79.5%	NR	NR
Percentage minimal breast cancer[b]	45.6%	16.7%	58.8%	NR	NR
Percentage stage 0 or I breast cancer	63.4%	36.4%	77.2%	NR	NR
Abnormal interpretation rate	12.6%	18.7%	17%	10–25%	8–25%
PPV_2 (recommendation for tissue diagnosis)	27.5%	34.5%	26.9%	25–50%	15–40%
PPV_3 (biopsy performed)	30.4%	37.7%	29.2%	30–55%	20–45%
Sensitivity (if measurable)[c]	87.8%	92.3%	91.8%	≥ 85%	≥ 80%
Specificity (if measurable)[c]	90.5%	86.8%	86.9%	83–95%	80–95%
False-negative (per 1,000 examinations)	4.8	5.4	4.1	NR	NR

[a] Patients undergoing diagnostic mammography performed to evaluate palpable lumps have a higher probability of having breast cancer than all patients undergoing diagnostic mammography. This accounts for the differences in observed outcomes.

[b] Minimal breast cancer is invasive cancer ≤ 1 cm, or carcinoma in situ.

[c] Sensitivity and specificity are measured with reasonable accuracy only if outcomes data are linked to breast cancer data in a regional tumor registry.

NR = not reported

C. IMPORTANT CONSIDERATIONS

The evaluation of the interpretive performance of a breast imaging facility or individual interpreting physician should not be based on only one or two metrics, but rather on the combination of multiple metrics described for the *Basic Clinically Relevant Audit* outlined above or for the *More Complete Audit* (section III) as outlined below.

FDA regulations specify [1] that a facility's first audit analysis be *initiated* (end date of audit period established) no later than 12 months after the date the facility becomes certified. This audit analysis must be *completed* at the end of an additional 12 months. The additional 12 months accommodate the standard ascertainment interval, which begins with the screening examination, and are needed for performance of diagnostic procedures (including biopsies), for collection of outcomes data, and to allow sufficient time for determination of cancer status (See page 813). For example, an audit conducted at the *end* of 2023 would involve examinations performed during calendar year 2022 plus the additional 12-month allowance for ascertainment of TN and FN interpretations. Subsequent audit analyses must be conducted at least once every 12 months, also involving the additional 12 months to produce meaningful audit outcomes.

Data are typically collected and analyzed for 12-month periods. However, due to the random variation in the comparatively small number of cancers detected at screening in any individual practice audit and the demographic differences in patient populations served by individual practices, comparison of metrics from a single 12-month period with benchmark data may be less meaningful than assessing the trend of one's own performance over multiple 12-month intervals or assessing this trend in comparison to that of other members of the same practice. Moreover, for low-volume practices, and especially for individual interpreting physicians who work in low-volume practices, some metrics will lack precision and vary considerably from year to year because the number of cancers is small. An acceptable workaround, after the first-year audit is established, is to perform annual audits comprising data from the most recent 2, 3, or 4 years rather than just the most recent year [25]. For example, an audit analysis conducted at the end of 2023 may include data from 2020, 2021, and 2022; the following audit analysis at the end of 2024 may include data from 2021, 2022, and 2023, etc.

Whether data are being collected for the *Basic Clinically Relevant Audit* or for the *More Complete Audit* (section III) as outlined below, separate audit statistics should be maintained for screening and diagnostic examinations, as all the audit outcomes are significantly different [23, 24, 26–31]. However, some breast imaging practices may find it impractical or impossible to segregate screening from diagnostic examinations during an audit. In this situation, expected outcomes will vary depending on the relative contributions of screening and diagnostic examinations to the total. If the case mix can be estimated, simple mathematical modeling may be applied to combined screening and diagnostic audit data to derive suggested overall benchmark metrics [32].

Whether data are being collected for the *Basic Clinically Relevant Audit*, or for the *More Complete Audit* (section III) as outlined below, all audit data should be monitored for each interpreting physician and in the aggregate for the entire breast imaging facility.

Tissue diagnosis data for fine-needle aspiration cytology and core biopsy may be collected separately from surgical biopsy data but should be combined with surgical biopsy data for statistical calculations. Only biopsies performed for diagnostic purposes (benign versus malignant) should be counted. Surgical excisions performed to completely remove known cancer are not included in the audit.

Biopsy-proven histologies with an inherent risk of upgrade to DCIS, pleomorphic or florid LCIS, or invasive cancer, such as atypical ductal hyperplasia, are negative for the purposes of the audit. If subsequent surgical excision is not performed within the standard ascertainment interval or it does not yield DCIS, pleomorphic or florid LCIS, or invasive cancer, the diagnostic examination is classified as FP. However, if excisional biopsy reveals DCIS, pleomorphic or florid LCIS, and/or invasive carcinoma, the diagnostic examination should be classified as a TP. Note that the diagnostic examination would still be classified as TP even if there were many biopsies within the standard interval and only one of them yielded a cancer diagnosis.

Note that pleomorphic lobular carcinoma in situ (pLCIS) and florid lobular carcinoma in situ (fLCIS) have been newly added to the list of true-positive breast malignancies in the NMD and this revised version of the Manual (Table 3). The most recent benchmarks, updated for this version of the Manual, however, are based on data that did not include pLCIS or fLCIS as true-positive diagnoses (Tables 4, 5, 6 & 7). *There are no other changes to the list of true-positive diagnoses. Malignant phyllodes tumor, breast sarcoma, metastases to the breast, lymphoma, leukemia, etc. are malignancies that occur within the breast but are not breast cancer (Table 3) and remain negative for the purposes of the audit.*

Linkage of audit data with a regional or organizational tumor registry serving a captive, nonmobile patient population is uncommon but can provide FN and TN data to calculate sensitivity and specificity and facilitate receiver operating characteristic (ROC) analysis, a widely used approach to assess the important trade-offs between TP and FP outcomes. Most breast imaging facilities in the United States lack the resources and/or linkage to tumor registries to reliably ascertain complete

TN and FN results for their programs. Therefore, they cannot accurately calculate sensitivity or specificity nor does the MQSA Final Rule require it. For these practices, the NMD data provide the most appropriate and similar independent benchmarks [31]. Nevertheless, all breast imaging facilities may collect useful data on detected breast cancers (invasive cancer size, lymph node status, cancer stage), permitting successful evaluation of surrogate performance trade-offs assessed by ROC analysis. This alternative approach has the added benefit that tumor metrics may be more clinically relevant than sensitivity and specificity, because invasive cancer size, lymph node status, and breast cancer stage directly impact clinical cancer treatment. Furthermore, high sensitivity does not necessarily imply improved outcome. For example, sensitivity is consistently observed to be higher for mammography screening at 2-year intervals than at 1-year intervals, but this does not equate to improved outcomes. The longer interval allows breast cancers to grow and be more easily identified which raises sensitivity [33]. However, larger invasive breast cancers, more frequently positive lymph nodes, and later breast cancer stage at diagnosis equate to a poorer prognosis for patients.

The potential for under-ascertainment of true-positive examinations also exists. The MQSA Final Rule requires facilities to attempt to obtain histopathology results for mammography examinations for which tissue diagnosis is recommended. However, it may not be practical for some mammography facilities to identify as many breast cancers among positive examinations as are identified by facilities participating in the BCSC or other linkage to a tumor registry. Therefore, BCSC benchmarks, listed above in Tables 4 and 7, that depend on breast cancer ascertainment, especially breast cancer detection rate, will likely exceed the performance calculated for a screening facility without a registry linkage. The potential for under-ascertainment of true-positive examinations is higher for US and MRI because the FDA regulations [1] do not require breast imaging facilities to attempt to obtain tissue diagnosis results for US or MRI examinations for which tissue diagnosis is recommended.

Breast imaging practices that record only overall BI-RADS assessments for combined diagnostic mammography/US examinations performed concurrently should expect outcomes that are different from published benchmarks, which involve the performance of diagnostic mammography alone. Currently there are only sparse published data to guide benchmarks for overall mammography/US examinations performed concurrently. By recording separate assessments for the mammography and US components as well as the overall assessment, facilities may derive outcomes for each component examination as well as for the overall combined) examination. The same statements in this paragraph also apply to overall BI-RADS assessments made for other combinations of diagnostic breast imaging examinations performed concurrently (mammography/MRI and US/MRI and mammography/US/MRI).

III. THE MORE COMPLETE AUDIT

Although the *Basic Clinically Relevant Audit* (section II) provides nearly all the data needed to assess one's performance in interpreting breast imaging examinations, certain additional audit data may also be collected and utilized to calculate important metrics regarding breast imaging performance. The following comprise the complete data for such a comprehensive audit:

A. DATA TO BE COLLECTED

Bolded items indicate data included in the *Basic Clinically Relevant Audit* (section II) for mammography.

1. **Modality or modalities.**
2. **Dates of audit period and total number of examinations in that period (usually a 12-month period).**
3. Risk factors:
   - Patient's age at the time of the examination.
   - Breast and ovarian cancer history: personal or family (especially premenopausal breast cancer in first-degree relative).
   - Previous biopsy-proven cellular atypia, or lobular carcinoma in situ (LCIS).
   - Hormone replacement therapy.
   - Breast density as estimated or quantified at mammography.
   - Genetic mutations
   - Mantle radiation treatment
4. **Number and type of examinations: screening** (asymptomatic), **diagnostic** (evaluation of clinical symptoms or signs suggesting the possibility of breast cancer, evaluation of screening-detected findings, short-interval follow-up examinations). Separate audit statistics should be maintained for screening examinations and for each of the subtypes of diagnostic examinations [5, 23, 24, 26, 27, 29–31].
5. Baseline examination or not.
6. Number of examinations with overall assessments of:
   - **BI-RADS category 0 = Need additional imaging evaluation**
   - BI-RADS category 1 or 2 = Negative or Benign
   - **BI-RADS category 3 = Probably benign**
   - **BI-RADS category 4 or 5 = Suspicious or Highly suggestive of malignancy**
7. **Tissue diagnosis results: malignant or benign, for all ACR BI-RADS category 0, 3, 4 and 5 assessments** (keep separate data for fine-needle aspiration, core biopsy and surgical biopsy cases). MQSA Final Rule requires that an attempt is made to collect tissue diagnosis results only for mammography examinations for which tissue diagnosis is recommended [1].
8. Breast cancer data:
   - Imaging findings: mass, calcifications, other signs of malignancy (including architectural distortion and the several types of asymmetries), no signs of malignancy.

- Palpable or nonpalpable at time of imaging examination.
- **Cancer staging: histological type, invasive cancer size, nodal status, tumor grade, and biomarker status when available.**

9. **MQSA Final Rule also requires analysis of any known false-negative mammography examinations by attempting to obtain surgical and/or pathology results and by review of negative mammography examinations [1].**

B. DERIVED DATA TO BE CALCULATED

Bolded items indicate data included in the *Basic Clinically Relevant Audit* (section II) for mammography.

1. **True-positives, false-positives (three sub-definitions: FP_1, FP_2, FP_3)**, true-negatives (if measurable)[a], and false-negatives (if measurable)[a]. True-negatives, false-negatives, sensitivity, and specificity are measured with reasonable accuracy only if outcomes data are linked to breast cancer data in a regional tumor registry.
2. **Positive predictive value**
   a. **In a screening/diagnostic facility, PPV may be obtained in one or more of three ways:**
      - **PPV_1 — based on positive cases at screening examination, which includes recommendation for anything other than breast cancer screening (BI-RADS categories 0, 3, 4, 5).**
      - **PPV_2 — based on recommendation for tissue diagnosis (BI-RADS category 4, 5) — separately for screening and the subtypes of diagnostic examinations.**
      - **PPV_3 — based on results of biopsies performed (otherwise known as biopsy yield of malignancy or positive biopsy rate (PBR))** — separately for screening and the subtypes of diagnostic examinations.

   b. **If screening exclusively, obtain in only one way:**
      - **PPV_1 — based on positive cases at screening examination, which includes recommendation for anything other than breast cancer screening (BI-RADS categories 0, 3, 4, 5).**

3. Breast cancer detection rate
   - **Cancer detection rate for screening and diagnostic examinations**
   - Prevalent and incident cancer detection rates for screening examinations
   - Cancer detection rate for diagnostic examinations
   - Cancer detection rates within various age groups
4. Percentage of breast cancers that are nonpalpable — separately for screening and diagnostic examinations
5. **Percentage of invasive cancers that are node-negative** — separately for screening and diagnostic examinations
6. **Percentage of cancers that are "minimal" (minimal cancer is defined as node-negative invasive cancer ≤ 1 cm, or DCIS, pLCIS or fLCIS of any size)** — separately for screening and diagnostic examinations
7. **Percentage of cancers that are stage 0 or I** — separately for screening and diagnostic examinations
8. **Recall rate (aka abnormal interpretation rate) for screening examinations**

9. Abnormal interpretation rate of diagnostic examinations
10. Outcomes for initial BI-RADS category 3 assessments (new to the ACR BI-RADS v2025 Manual, see text below)
    a. **Frequency of initial BI-RADS category 3 assessments**
        i. **Prompted initially by screening examination recall**
        ii. **Prompted initially by diagnostic examination for palpable lump, sign or symptom**
    b. **Percentage of screening examinations that result in an initial BI-RADS category 3 assessment at diagnostic imaging (calculated for screening examinations only)**
    c. **Percentage of initial BI-RADS category 3 assessments that result in a breast cancer diagnosis**
    d. Percentage of initial BI-RADS category 3 assessments that result in a breast cancer diagnosis from a biopsy of the BI-RADS category 3 finding(s)
    e. Percentage of initial BI-RADS category 3 assessments downgraded to BI-RADS category 1 or 2 for decrease or disappearance of the finding(s) prior to completing the standard ascertainment interval of 2 years.
11. Sensitivity (if measurable)[a]
12. Specificity (if measurable)[a]

[a] True-negatives, false-negatives, sensitivity, and specificity are measured with reasonable accuracy only if outcomes data are linked to breast cancer data in a regional tumor registry.

Note: **Bolded** items indicate data included in the *Basic Clinically Relevant Audit* (section II) for mammography.

C. DIAGNOSTIC BREAST MRI PERFORMED FOR EXTENT OF DISEASE

A specific subset of diagnostic breast MRI examinations is performed to assess the extent of breast cancer before definitive local treatment, usually surgery (note this does not include breast MRI examinations performed to evaluate response to neoadjuvant treatment; see the section on Magnetic Resonance Imaging for standard examination indications). Although not included in previous versions of the BI-RADS Atlas, new data provide initial audit metrics and benchmarks (Table 8) for performance of diagnostic breast MRI to evaluate the extent of disease (EOD). These benchmarks impact patient care because they provide a reference to gauge radiologist performance. Identification of additional sites of disease can guide appropriate surgical treatment decisions (e.g. mastectomy for multicentric disease). However, additional evaluation for abnormal findings seen on EOD breast MRI can also increase procedures, demand for limited resources, costs, and unnecessarily delay definitive treatment. Breast imaging teams that perform and interpret breast MRI are now encouraged to audit their practice in reference to these benchmarks to facilitate continuous quality improvement.

As described above, for the purposes of the audit, metrics and benchmarks reflect the predictive accuracy and interpretive performance of *examination* assessments rendered *before* the diagnosis of breast cancer at any location in either breast within a standard time interval. However, all breast MRI EOD *examinations* are performed *after* the diagnosis of breast cancer and will include a BI-RADS category 6 assessment, which, by definition, will exclude it from the audit (See *What Not to Audit* (section V. A.), page 849). Thus, to audit breast MRI EOD examinations, new definitions of positive and negative truth for individual *findings*, independent from the known cancer, are required.

1. SPECIAL DEFINITIONS FOR DIAGNOSTIC EOD BREAST MRI
    a. Standard Interval — For auditing purposes, positive and negative truth are defined relative to the presence or absence of a tissue diagnosis of cancer for an individual finding

within a standard recommended interval of time after breast imaging examination. For diagnostic examinations, the interval to cancer diagnosis begins on the date of the diagnostic examination. *The standard diagnostic interval is 1 year (365 days) as recommended by the ACR.* Breast imaging facilities with an alternate accepted local standard interval, such as 2 years, whether in the United States or elsewhere, should consistently replace the 1-year interval with their standard interval.

b. True-Positive (TP) — There is tissue diagnosis of cancer for a positive *finding* (BI-RADS categories 4 or 5) within one standard ascertainment interval.

c. False Positive (FP) — There is no known tissue diagnosis of cancer for a positive *finding* (BI-RADS categories 4 or 5) within one standard ascertainment interval.

d. True-Negative (TN) — There is no known tissue diagnosis of cancer for a negative *finding* within one standard ascertainment interval.

e. False-Negative (FN) — There is tissue diagnosis of cancer for a negative *finding* within one standard ascertainment interval.

2. EOD BREAST MRI: DATA TO BE COLLECTED

Collection and calculation of all the data in the *More Complete Audit* for diagnostic EOD breast MRI in current cancer patients requires proper coding of the data elements for accurate and efficient retrieval, often requiring considerable effort. Additionally, outcomes can be difficult to ascertain, especially when the additional finding is ipsilateral to the known malignancy and image-guided biopsy is not performed prior to definitive local therapy. As an example, practice differences in reporting additional findings not requiring tissue sampling (BI-RADS category 6) vs separate adjacent findings requiring tissue sampling will result in heterogeneity of audit outcomes; clarification in the updated MRI chapter of this version should assist in consistency of this metric.

Linkage of audit data with a regional or organizational tumor registry can provide FN and FP data to calculate sensitivity and specificity and facilitate ROC analysis at the examination level. This is not a helpful strategy in the situation of a findings level audit, however, as the registry data cannot be traced back to the individual findings, and all patients undergoing EOD assessment will be malignant at the registry level. Thus, the ascertainment and calculation of metrics such as FN, FP, Sensitivity, and Specificity can only be performed through diligent internal tracking and correlation with all available data and adequate follow-up through standard intervals. These metrics are less relevant in the setting of a known malignancy and remain optional. The process for collecting the necessary data and calculating the metrics is described below.

A. <u>Examination Level Data</u>

1. Dates of audit period

2. Total number of diagnostic breast MRI EOD examinations performed in the defined audit period (usually 12 months). Note that examinations performed to evaluate response to neoadjuvant treatment should not be included in this audit.

3. Primary cancer staging:

a. Histologic type(s)

b. Invasive or in situ cancer size (single largest dimension)

c. Nodal status

d. Tumor grade

e. Biomarker status when available

4. Number of breast MRI EOD examinations with any BI-RADS Final Assessment category of 4 (suspicious) or 5 (highly suggestive of malignancy).

B. Finding Level Data

1. Although not required, the BI-RADS MRI chapter encourages a separate BI-RADS assessment for each breast and each *finding*. However, if the *More Complete Audit* of diagnostic breast MRI EOD examinations is planned, then a separate BI-RADS assessment for all *findings* is mandatory to facilitate the EOD audit.
2. Number of additional findings with BI-RADS category 4 or 5 assessments:
    a. Ipsilateral to known cancer
    b. Contralateral to known cancer
3. Tissue diagnosis results: malignant or benign, for all additional BI-RADS 4 and 5 findings (keep separate data for image-guided fine-needle aspiration, image-guided needle biopsy, and correlation with surgical resection pathology).
    a. Number of findings with BI-RADS 4 or 5 assessment that are malignant on fine needle aspiration or image-guided needle biopsy
        i. Ipsilateral to known cancer
        ii. Contralateral to known cancer
    b. Number of findings with BI-RADS 4 or 5 assessment that did not undergo fine needle aspiration or image-guided needle biopsy that are malignant on correlation with final surgical pathology (excisional biopsy, lumpectomy or mastectomy).
        i. Ipsilateral to known cancer
        ii. Contralateral to known cancer
4. Finding type:
    a. Mass
    b. Non-mass enhancement
5. Finding side:
    a. Ipsilateral to primary malignancy
    b. contralateral to primary malignancy

3. EOD BREAST MRI: DERIVED DATA TO BE CALCULATED

1. Abnormal Interpretation Rate — The percentage of diagnostic breast MRI EOD examinations interpreted as positive. For diagnostic imaging, positive examinations include any with a final assessment of BI-RADS category 4 or 5.

    Abnormal Interpretation Rate = (TP + FP EOD examinations / All EOD examinations)

    a. Overall (bilateral total)
    b. Ipsilateral
    c. Contralateral
2. Positive Predictive Value (PPV) — there are two separate definitions
    a. PPV_2 (tissue sampling recommended): The percentage of *all* distinct BI-RADS category 4 or 5 findings with a tissue diagnosis of cancer by *image-guided tissue*

sampling within one standard ascertainment interval. The denominator includes all BI-RADS category 4 and 5 findings, whether or not they were specifically targeted for image-guided tissue sampling. No BI-RADS category 4 or 5 findings are *excluded* from the denominator. No attempt is made to correlate surgical pathology results with MRI findings.

PPV_2 = (TP, BI-RADS category 4 or 5 findings as determined by preoperative image-guided tissue sampling) / (All findings assessed BI-RADS category 4 or 5)

i. Overall (bilateral total)

ii. Ipsilateral

iii. Contralateral

b. PPV_3 (Image-guided tissue sampling performed): The percentage of BI-RADS category 4 or 5 findings that undergo preoperative image-guided tissue sampling with a tissue diagnosis of cancer within one standard ascertainment interval. PPV_3 is also known as the Biopsy Yield of Malignancy or the Positive Biopsy Rate (PBR). The denominator *includes* only findings that underwent image-guided tissue sampling. The denominator *excludes* BI-RADS category 4 or 5 findings that did not undergo image-guided biopsy but were excised during surgery for correlation.

PPV_3 = (TP, BI-RADS category 4 or 5 findings as determined by preoperative image-guided tissue sampling) / (TP + FP BI-RADS category 4 or 5 findings undergoing preoperative image-guided tissue sampling)

i. Overall (bilateral total)

ii. Ipsilateral

iii. Contralateral

3. Additional Cancer Detection Rate — The number of additional cancers beyond the primary malignancy detected per diagnostic EOD breast MRI per 1,000 examinations.

ACDR = (all TP BI-RADS category 4 or 5 *findings*) / (all TP + FP + TN + FN breast MRI EOD *examinations*)

a. Overall (bilateral total)

b. Ipsilateral

c. Contralateral

Table 8. Analysis of Medical Audit Data: Breast MRI for Extent of Disease >

Table 8. Analysis of Medical Audit Data: Breast MRI for Extent of Disease[a]

	Onega BCSC[b] [34]	Houssami[c] [35]
Abnormal Interpretation Rate – examination level	22.6%	NR
Overall additional cancer detection rate (per 1,000 examinations) – examination level	99	NR
Additional cancer detection rate ipsilateral breast to primary malignancy (per 1,000 examinations) – breast level	76	160 median (range 60–340)
Additional cancer detection rate contralateral breast to primary malignancy (per 1,000 examinations) – breast level	25	NR
PPV_2 (TP for all BI-RADS category 4 or 5 findings)	NR	NR
PPV_3 (TP for BI-RADS category 4 or 5 findings undergoing preoperative image-guided biopsy)	NR	NR

[a] Diagnostic Breast MRI Benchmarks in current cancer patients undergoing extent of disease (Consensus. A literature search identified peer-reviewed research of breast MRI EOD perform which were approved by the full BI-RADS committee. The variable study designs produced he and performance of extent of disease examinations.

[b] 5455 MRIs, 2005–2017, note ascertainment period was 6 months

[c] Meta-analysis, ipsilateral only

[d] Meta-analysis, contralateral only

[e] Single institution, 592 patients, 2003–2007

[f] Small study but including chart reviewing other small studies

[g] Review

[h] Single institution, 1102 patients

[i] 969 patients, contralateral only

NR = not reported

Brennan[d] [36]	Gutierrez[e] [37]	Deurloo[f] [38]	DeMartini[g] [39]	Debald[h] [40]	Lehman ACRIN 6667[i] [41]
9.3%	26.7%	8–51%	NR	31.2%	13.9%
NR	120	40–280	NR	NR	NR
NR	NR	NR	160 mean (range 100–345)	202	NR
41	NR	NR	Mean 44 (range 27–235)	25	31
NR	NR	NR	NR	64.8%	NR
47.9%	44.1%	NR	NR	NR	24.8%

EOD) assessment before definitive surgical therapy: Acceptable Ranges per Expert
ance. The AOM committee reviewed the results and selected the most rigorous publications,
eterogeneous data which illustrate the need for a standardized approach to auditing the utility

IV. EXAMPLES OF HOW TO CLASSIFY EXAMINATIONS AS TRUE-POSITIVE, TRUE-NEGATIVE, FALSE-POSITIVE, AND FALSE-NEGATIVE

Remember, at screening examination BI-RADS categories 0, 3, 4, and 5 are positive assessments, whereas BI-RADS categories 1 and 2 are negative assessments. When online interpretation is made for screening mammography or screening breast US and additional image(s), above and beyond the standard screening protocol, are acquired and permanently archived, a diagnostic examination is created and the screening component of the examination *is audited as positive (the same as recall for additional imaging, BI-RADS category 0), whether or not separate screening and diagnostic reports are issued.* The rationale behind these definitions of positive and negative is that the interpretation of screening examinations involves the binary decision of recommending acquisition and permanently archiving additional imaging beyond the screening protocol prior to next interval screening (positive) versus recommending no additional action until next interval screening (negative). At diagnostic examination, BI-RADS categories 4 and 5 are positive assessments, whereas BI-RADS categories 1, 2, and 3 are negative assessments, based on the definition that a positive diagnostic examination is one for which tissue diagnosis is recommended. *True or false outcomes depend on whether there is a tissue diagnosis of breast cancer within the standard ascertainment interval of the breast imaging examination.* The ascertainment interval for asymptomatic patients recalled from screening begins with the date of the screening examination. The ascertainment interval for patients presenting with clinical signs or symptoms, after a previously negative screening examination, begins with the new diagnostic examination.

A. BI-RADS ASSESSMENT CONCORDANT WITH MANAGEMENT RECOMMENDATION

SCREENING ALONE

1. A patient has a screening examination that is read as negative or benign and no breast cancer is diagnosed within 1 year of the examination. The interpretation is negative, and because no cancer is diagnosed within 1 year of the screening, the examination is classified as *true-negative (TN).*
2. A patient has a screening examination and is recalled for additional imaging evaluation of a finding (BI-RADS category 0). The diagnostic breast imaging examination is read as suspicious (BI-RADS category 4) with a recommendation for tissue diagnosis. A biopsy is performed, and the tissue diagnosis is malignant. Both the screening and diagnostic interpretations are positive, and because cancer is diagnosed within 1 year of the screening, both examinations are classified as *true-positive (TP).*
3. A patient has a screening examination and is recalled for additional imaging evaluation of a finding (BI-RADS category 0). The diagnostic examination leads to a biopsy. The biopsy is concordantly benign, and breast cancer is not diagnosed within 1 year of the screening examination. The screening interpretation is positive (BI-RADS category 0). The diagnostic interpretation also is positive (BI-RADS category 4 or 5). Both the screening and diagnostic examinations are classified as *false-positive (FP)* because no breast cancer is diagnosed within 1 year of the screening.

4. A patient has a screening examination for which a benign calcified fibroadenoma is described (BI-RADS category 2). A palpable mass, unrelated to the fibroadenoma, develops within 1 year of examination, is biopsied, and is found to be malignant. The screening interpretation is classified as negative (BI-RADS category 1 or 2 assessments). However, because malignancy is diagnosed within 1 year of the screening, the examination is classified as *false-negative (FN).*

SCREENING AND DIAGNOSTIC

5. An asymptomatic patient has a diagnostic breast imaging examination following recall (BI-RADS category 0) for a noncalcified circumscribed mass identified at screening. Diagnostic mammography and targeted breast US examination show the mass to be consistent but not diagnostic of a benign cyst. The diagnostic examination is assessed as suspicious (BI-RADS category 4), and a diagnostic cyst aspiration is recommended. At US-guided aspiration, cyst fluid is obtained, and the finding is no longer visible at post-aspiration imaging. The cyst fluid is discarded. No breast cancer is diagnosed within 1 year of the screening. The screening interpretation is positive (BI-RADS category 0). The diagnostic interpretation also is positive (BI-RADS category 4), because tissue diagnosis is recommended. Both the screening and diagnostic mammogram and US are classified as *false-positive (FP)* because no breast cancer is diagnosed within 1 year. Note that diagnostic cyst aspiration, performed for the purpose of confirming the suspected diagnosis of cyst for cases in which mammographic and sonographic findings are not characteristically benign, is considered to represent a definitive diagnostic intervention despite the absence of a tissue retrieval and pathology analysis.

6. A patient with recent-onset focal unilateral breast pain has a diagnostic breast imaging examination. Diagnostic mammography and targeted breast US examination show a characteristically benign cyst at the symptomatic site. The diagnostic examination is assessed as benign (BI-RADS category 2) and routine mammography screening is recommended, but therapeutic cyst aspiration also is offered to provide symptomatic relief. At US-guided aspiration, cyst fluid is obtained, and the cyst is no longer visible at post-aspiration imaging. The cyst fluid is discarded. No breast cancer is diagnosed within 1 year. The diagnostic interpretation is negative (BI-RADS category 2). The diagnostic examination is classified as *true-negative (TN)* because no breast cancer is diagnosed within the year. Note that therapeutic cyst aspiration, performed for characteristically benign cysts to provide symptomatic relief of focal pain or tenderness, is not considered to represent a diagnostic intervention because the procedure is neither recommended nor required for diagnostic purposes.

CATEGORY 3 ASSESSMENT

7. A patient has a diagnostic breast imaging examination because of a clinically suspicious lump. This diagnostic examination is assessed as probably benign (BI-RADS category 3) with a recommendation for short-interval follow-up imaging. A biopsy of the area of clinical suspicion is performed within 1 year and the result is invasive ductal carcinoma. For the purposes of the audit, an initial BI-RADS category 3 assigned at diagnostic imaging is negative. Because malignancy is diagnosed within 1 year, this examination is classified as *false-negative (FN).*

8. A patient has a screening examination and is recalled for additional imaging evaluation of a finding (BI-RADS category 0). The diagnostic breast imaging examination is read as probably benign (BI-RADS category 3) with a recommendation for short-interval follow-up imaging. At 6 months, the second diagnostic examination shows a change, and tissue diagnosis is recommended (BI-RADS category 4). Malignancy is found. The screening interpretation is positive (BI-RADS category 0). The first diagnostic interpretation is negative (BI-RADS category 3). The second (6-month) diagnostic interpretation is positive (BI-RADS category 4). Breast cancer

indeed is diagnosed within 1 year of all three examinations. Thus, for the purposes of the general audit, the *screening* examination is classified as *true-positive (TP)*, the *first diagnostic* examination is classified as *false-negative (FN)*, and the *second diagnostic* examination is classified as *true-positive (TP)*.

9. A patient has a screening examination and is recalled for additional imaging evaluation of a finding (BI-RADS category 0). The diagnostic breast imaging examination is read as probably benign (BI-RADS category 3) with a recommendation for short-interval follow-up imaging. At 6 months, the second diagnostic examination shows a change, and tissue diagnosis is recommended (BI-RADS category 4). The biopsy result is concordantly benign, and no breast cancer is found within 1 year of the follow-up examination. Thus, the screening interpretation is positive, the first diagnostic interpretation is negative, and the second (6-month) diagnostic interpretation is positive. Because no breast cancer is found within 1 year of any of the examinations, for the general audit, the *screening* interpretation is classified as *false-positive (FP)*, the *first diagnostic* interpretation is classified as *true-negative (TN)*, and the *second diagnostic* interpretation is classified as *false-positive (FP)*.

10. A patient has a screening examination and is recalled for additional imaging evaluation of a finding (BI-RADS category 0). The diagnostic breast imaging examination is performed a few days later and is interpreted as probably benign (BI-RADS category 3) with a recommendation for short-interval follow-up imaging. At 6 months, the second diagnostic examination shows no change, and again is read as probably benign (BI-RADS category 3) with a recommendation for short-interval follow-up imaging. The patient returns for the next examination 7 months later, at which time a change is seen, tissue diagnosis is recommended (BI-RADS category 4), and malignancy is found. Thus, the screening interpretation is positive, the first diagnostic interpretation immediately following the screening examination is negative, the second (6-month) diagnostic examination is negative and the last (13-month) diagnostic interpretation is positive. Because no breast cancer is found within 1 year of the *screening* examination and the *first diagnostic* examination, these are classified as *false-positive (FP)* and *true-negative (TN)*, respectively for the purposes of the basic audit. Because breast cancer indeed is diagnosed within 1 year of the *second* (6-month) examination and the *last* (13-month) examination, these are classified as *false-negative (FN)* and *true-positive (TP)*, respectively. See also above Section II, The Basic Clinically Relevant Audit on page 816, BI-RADS Category 3 Auditing, page 822 and see below Section C, Auditing of Initial BI-RADS Category 3 Assessments, page 846.

11. A patient has a mammography screening examination that is assessed as probably benign (BI-RADS category 3) with a recommendation for short-interval follow-up imaging, despite the guidance provided in the BI-RADS Manual not to use category 3 assessments at mammography screening. At 6 months, diagnostic breast imaging examination shows the finding to be characteristically benign, resulting in a BI-RADS category 2 assessment. No breast cancer is diagnosed within 1 year of the screening examination. The screening assessment is positive (additional imaging recommended prior to next interval screening) and the diagnostic assessment is negative. Because no cancer is diagnosed within 1 year, the *screening* examination is classified as *false-positive (FP)* and the *diagnostic* examination is classified as *true-negative (TN)*. Note that proper classification of BI-RADS category 3 screening assessments as positive interpretations will not lower the recall rate (aka abnormal interpretation rate). In the clinical scenario illustrated here, the only effect of using a BI-RADS category 3 assessment at screening is a 6-month delay in the diagnostic breast imaging examination that results in a definitively benign diagnosis, thereby prolonging the period of uncertainty for the radiologist and the patient.

ONLINE EVALUATIONS

12. A patient has a mammography screening examination at a facility in which the examination is interpreted before the patient leaves the premises, so that additional imaging can be performed immediately if needed. A noncalcified asymmetry is seen in one breast, only on the craniocaudal view. The interpreting radiologist obtains a second craniocaudal view to clarify the significance of this asymmetry. The examination is then interpreted as negative because the asymmetry (judged to represent a summation artifact) is not visible on the repeat craniocaudal view. No breast cancer is found within 1 year of examination. This sequence of performing standard screening views with interpretation followed by acquisition of additional, non-standard views, represents a positive screening examination (BI-RADS category 0), for which the woman was recalled for additional diagnostic imaging that resulted in a negative (BI-RADS category 1) assessment. Thus, the screening component of this examination should be classified as *false-positive (FP)* and the diagnostic component of the examination should be classified as *true-negative (TN).* Note that whenever a screening examination is interpreted before the patient leaves the premises, the acquisition of additional views to clarify a mammographic finding identified on standard screening satisfies the definition of a separate diagnostic examination. Therefore, this single patient visit should be considered to have a positive screening interpretation (BI-RADS category 0) and a negative (BI-RADS category 1) diagnostic interpretation.

13. A patient has a breast US screening examination using a handheld transducer. Images are acquired and interpreted while the patient waits. The sonographer saves an image to document a focal area of posterior acoustic shadowing during the screening examination. The interpreting physician reviews the examination. The sonographer proceeds to scan the patient to further evaluate the finding and acquires and archives one or more images to demonstrate that the focal area of shadowing is normal and not reproducible. The completed examination is then interpreted as negative because the initially depicted finding is judged to be an artifact rather than a true abnormality. This sequence of performing a standard screening examination with interpretation, followed by acquiring additional, non-standard views, meets the precise definition of a positive screening examination followed by creation of a diagnostic examination. Therefore, this single patient visit should be considered to have a positive screening interpretation (BI-RADS category 0) and a negative (BI-RADS category 1) diagnostic interpretation. If breast cancer is not diagnosed within 1 year, the screening is audited as false-positive (FP), and the diagnostic examination is true-negative (TN).

14. A patient has a breast US screening examination using a handheld transducer. Images are acquired and interpreted while the patient waits. One of the screening images includes a finding that may represent a cyst or mass. The interpreting physician reviews the examination. The interpreting physician proceeds to scan the patient to further evaluate the finding and acquires and archives one or more images to demonstrate that it is a simple cyst. The completed examination is then interpreted as benign. This sequence of performing a standard screening examination with interpretation, followed by acquiring additional, non-standard views, meets the precise definition of a positive screening examination followed by creation of a diagnostic examination. Therefore, this single patient visit should be considered to have a positive screening interpretation (BI-RADS category 0) and a benign (BI-RADS category 2) diagnostic interpretation. If breast cancer is not diagnosed within 1 year, the screening is audited as false-positive (FP) and the diagnostic examination is true-negative (TN). Note that in the provided scenario, had the interpreting physician determined that the initially depicted finding was a characteristically benign simple cyst without additional evaluation or image acquisition, the completed screening examination would have contained only standard images, been assessed as negative (BI-RADS category 2), and therefore been audited as true-negative (TN). Also note that the approach of not permanently archiving additional

images upon rescanning may subject the interpreting physician to malpractice exposure if breast cancer subsequently is diagnosed at the site of the depicted finding and the only saved image depicts an abnormality.

15. A patient has a breast US screening examination using a handheld transducer. Images are acquired and interpreted while the patient waits. A finding that is characteristic of a simple cyst is visible on one of the standard images saved by the sonographer as part of the screening examination. The interpreting physician decides to immediately scan the patient and verifies that the finding indeed is a simple cyst but does not acquire or archive any additional images. The simple cyst is described in the screening report, and the completed examination is assessed as benign (BI-RADS category 2). No breast cancer is found within 1 year of examination. Because no additional (diagnostic) images were acquired or archived, the examination is audited purely as a screening examination and classified as true-negative (TN). Note that in standard clinical practice, the presence of one or more characteristically benign findings does not require full and permanent documentation by diagnostic imaging because 1) the likelihood of malignancy is essentially zero, and 2) the fully documented appearance of the finding(s) will not be needed for future comparison, because a) if the finding(s) again appear characteristically benign at a subsequent examination, interval change in size would be irrelevant, and b) if the finding(s) do not appear characteristically benign, biopsy would be recommended. Finally, note that even though characteristically benign finding(s) are depicted on standard screening view(s) in an asymptomatic patient, the interpreting physician may reasonably decide not to describe the finding(s) in the breast imaging report, instead rendering a negative (BI-RADS category 1) assessment.

OVERLAPPING SCREENING INTERVALS

16. A patient has a screening mammography examination that is interpreted as negative (BI-RADS category 1). Six months later, a biopsy is recommended for a suspicious (BI-RADS category 4 or 5) finding on supplemental screening with MRI or US. The pathology demonstrates invasive ductal carcinoma. The initial screening mammogram is classified as a *false-negative (FN)* because the patient had a diagnosis of cancer within 1 year of the screening mammography examination. The screening MRI or US examination is a *true-positive (TP).*

MULTIPLE FINDINGS

17. A patient presents with a palpable mass in the left breast that is suspicious (BI-RADS category 4 or 5) on diagnostic examination. There is a second mass on diagnostic examination in the contralateral (right) breast that is also suspicious (BI-RADS category 4 or 5) with a recommendation for bilateral tissue diagnosis. Both the palpable mass and the contralateral nonpalpable mass are biopsied. The palpable mass is benign, and the contralateral nonpalpable mass is malignant. The diagnostic interpretation, for the bilateral examination, is positive (BI-RADS category 4 or 5) and the diagnostic examination is classified as *true-positive (TP)* because malignancy is diagnosed within 1 year of the suspicious assessment. Note that the MQSA Final Rule requires only a single overall assessment for both breasts for all mammography examinations [1]. Therefore, for most mammography facilities, which do not capture separate breast assessments, this examination would be classified as *true-positive (TP).* However, the FDA has approved an alternative standard which, under certain circumstances, allows a mammography facility to report separate assessments for each breast rather than a combined assessment for both breasts [42]. Thus, mammography facilities that choose to report separate breast assessments under the alternative FDA standard would record more clinically meaningful although less favorable outcomes data.

18. A patient presents with a palpable mass in the left breast that is suspicious (BI-RADS category 4 or 5) on diagnostic examination. The diagnostic mammography examination is also suspicious (BI-RADS category 4 or 5) for a mass in the contralateral (right) breast. The palpable mass is biopsied and is found to be malignant. The right breast mass is biopsied, is found to be concordantly benign, and no breast cancer is diagnosed in this breast within 1 year of diagnostic examination. The diagnostic interpretation is positive (BI-RADS category 4) for the breast in which no breast cancer is found within 1 year of examination, and the interpretation also is positive (BI-RADS category 4 or 5) for the breast in which breast cancer indeed is diagnosed within 1 year. Thus, the diagnostic interpretation is classified as *false-positive (FP)* for the right breast and as *true-positive (TP)* for the left breast. Note that the MQSA Final Rule requires only a single overall assessment for both breasts for all mammography examinations [1]. Therefore, for most mammography facilities, which do not capture separate breast assessments, this examination would be classified as *true-positive (TP)* because the overall positive interpretation matches the subsequent cancer diagnosis. However, the FDA has approved an alternative standard which, under certain circumstances, allows a mammography facility to report separate assessments for each breast rather than a combined assessment for both breasts [42]. Thus, mammography facilities that choose to report separate breast assessments under the alternative FDA standard would record more clinically meaningful although less favorable outcomes data.

19. A patient has a finding on unilateral diagnostic mammography examination that is assessed as suspicious (BI-RADS category 4) and benign at biopsy, but an unsuspected cancer is palpated and diagnosed elsewhere in the same breast within 1 year of the diagnostic examination. All mammography facilities, including those that capture separate breast assessment data, would classify the first examination as *true-positive (TP)* because cancer was diagnosed within the breast within 1 year of the positive (BI-RADS category 4) assessment, even though interpretation of the suspicious but benign finding was *false-positive (FP)* and interpretation of the unrecognized finding of cancer was *false-negative (FN)*. The FDA does not allow individual assessments of abnormal findings to replace a breast-level assessment in the mammography report. However, if a mammography facility chooses to collect and audit finding-level data, the resultant audit outcomes will be more clinically meaningful, albeit less favorable.

B. BI-RADS ASSESSMENT DOES NOT MATCH MANAGEMENT RECOMMENDATION

All the previous clinical scenarios assume that the BI-RADS assessment category is concordant with the accompanying management recommendation in the breast imaging report. That is, category 1 and 2 assessments accompany recommendations for standard interval screening, category 3 assessments accompany recommendations for imaging surveillance, category 0 assessments accompany recommendations for additional imaging, and category 4 and 5 assessments accompany recommendations for tissue diagnosis. However, just as radiologists occasionally do not follow BI-RADS guidance (by making category 3 assessments at mammography screening, for example) so do they occasionally render breast imaging reports in which the BI-RADS assessment category is discordant with the accompanying management recommendation. There are numerous discordant combinations of assessment category and management recommendation. Two of these are described below to illustrate how to make proper assessments to *avoid such discordances*.

1. A patient has a screening examination assessed as probably benign (BI-RADS category 3) with a management recommendation of no action until the next screening examination. (This discordant approach is strongly discouraged and has no scientific support for mammography.)

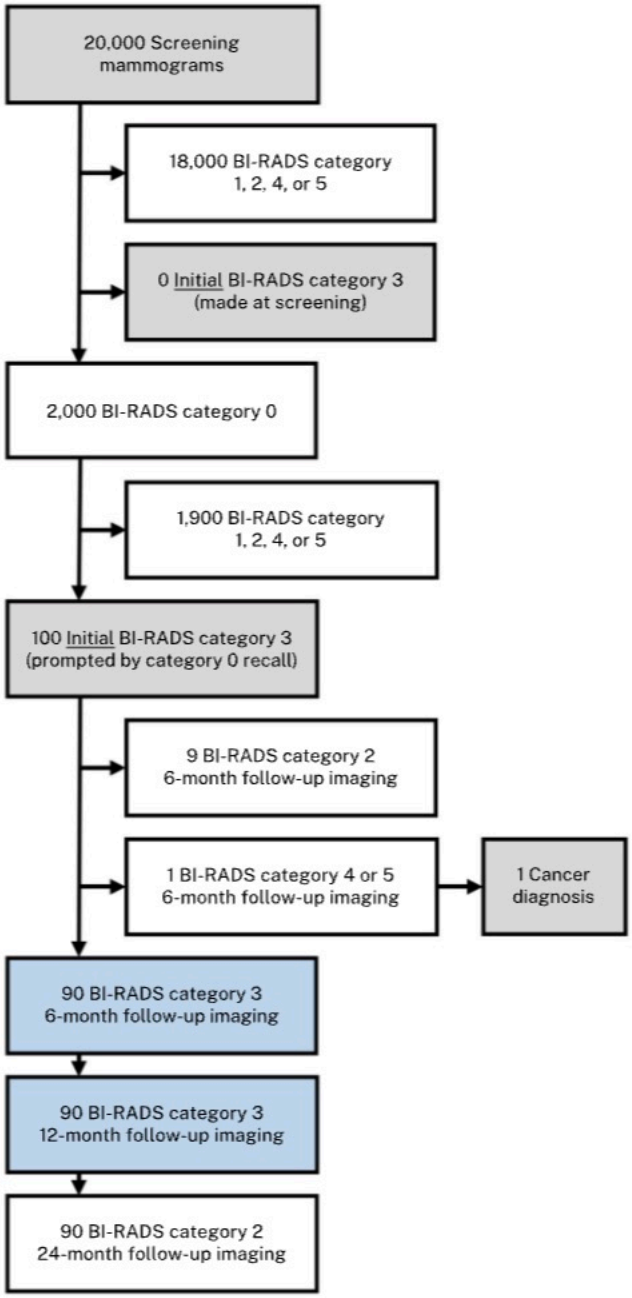

Note: Gray-filled boxes indicate data included in the calculations for BI-RADS category 3 auditing. Blue-filled boxes indicate BI-RADS category 3 assessments that *do not* meet the definition of an initial BI-RADS category 3 assessment and are thus *excluded* from BI-RADS category 3 audit calculations.

Figure 5 – Flowchart Example to Illustrate Correct and Incorrect Audit Calculations for Initial BI-RADS® Category 3 Assessments.

The discordant assessment and recommendation are troublesome for the audit. The screening examination assessment is classified as a positive (BI-RADS category 3), but the discordant recommendation is classified as negative because no additional imaging or action is recommended until completion of the next standard screening interval. In this discordant scenario, the correct assessment, for the purposes of the audit, is negative which aligns with the recommendation for no action until the next screening. Remember that if the interpreting radiologist had assessed the screening examination as probably benign (BI-RADS category 3) with a suggested management of short-interval follow-up (which is not a recommended practice without first performing a diagnostic examination), for auditing purposes, this would be classified as a positive screening examination and included in the calculation of recall rate because additional imaging was recommended before next interval screening.

2. A patient has a baseline mammography screening examination assessed as benign (BI-RADS category 2) with a management recommendation for short-interval follow-up imaging in 6 months because of the interpretive uncertainty produced by the availability of only the two standard-projection mammographic views for a finding judged to be very likely benign. For auditing purposes, this incorrectly assessed examination is classified as a positive screening examination because additional imaging is recommended before the next screening. In this scenario, the proper and concordant assessment is incomplete (BI-RADS category 0), recommend additional imaging evaluation, which likely permits a more confident and rapid (diagnostic) category 2 assessment and management recommendation of standard interval screening. Note that at screening, recall for additional imaging is recommended to complete a full diagnostic imaging work-up before confirming a BI-RADS category 3 assessment and recommending short-interval follow-up imaging.

C. AUDITING OF INITIAL BI-RADS CATEGORY 3 ASSESSMENT

Auditing initial BI-RADS category 3 assessments deserves mention here to minimize confusion about this new addition to the auditing process. Important points to remember include the following: 1) initial BI-RADS category 3 assessments are defined as those made at screening and those made at the initial round of diagnostic imaging, 2) for each patient, only the initial BI-RADS category 3 assessment is counted in the denominator—subsequent BI-RADS category 3 assessments at follow-up intervals are not included, and 3) the recommended cancer ascertainment period is 2 years for total imaging surveillance of BI-RADS category 3 findings. A true-positive for an initial BI-RADS category 3 assessment is thus defined as a breast cancer diagnosis occurring after an initial BI-RADS category 3 assessment and during the BI-RADS category 3 cancer ascertainment period. Please refer to the text entitled "BI-RADS category 3 Auditing" under the *Basic Clinically Relevant Audit* (section II) for more details. The following example illustrates how to audit initial BI-RADS category 3 examinations correctly and incorrectly (Figure 5).

Twenty thousand screening mammograms were performed, and 2000 were assessed as BI-RADS category 0 with the recommendation for diagnostic imaging (see figure 5). No screening mammogram was given a BI-RADS category 3 (thus, this example refers to auditing of initial BI-RADS category 3 assessments at diagnostic imaging prompted by a BI-RADS category 0 screening examination). Of the 2000 recalled mammograms, initial diagnostic imaging for 100 was assessed as BI-RADS category 3, and the following outcomes were recorded for those 100 patients:

One patient was diagnosed with breast cancer after 6-month follow-up imaging was assessed as a BI-RADS category 4. This patient had 1 initial BI-RADS category 3 assessment and no additional BI-RADS category 3 assessments.

Nine patients were assessed as BI-RADS category 2 at 6-month follow-up imaging that revealed decrease or resolution of the probably benign imaging finding. These 9 patients had 9 initial BI-RADS category 3 assessments and no additional BI-RADS category 3 assessments.

Ninety patients underwent follow-up imaging, and the findings were unchanged at 6, 12, and 24 months. They were given BI-RADS category 3 assessments at 6 and 12 months and were given BI-RADS category 2 assessments only at the 24-month examinations. These 90 patients had 90 initial BI-RADS category 3 assessments and 180 additional BI-RADS category 3 assessments (i.e., at 6 and 12 months).

1 + 9 + 90 = 100 initial BI-RADS category 3 assessments

1 + 9 + 90 + 180 = 280 total BI-RADS category 3 assessments

1. CORRECT CALCULATIONS:
   - The frequency of initial BI-RADS category 3 assessments is correctly calculated as initial BI-RADS category 3 assessments divided by number of diagnostic examinations prompted by a category 0 screening examination, i.e. 100/2,000 = 5%.
   - The percentage of initial BI-RADS category 3 assessments that result in a breast cancer diagnosis is correctly calculated as number of malignant initial BI-RADS category 3 assessments divided by initial BI-RADS category 3 assessments, i.e. 1/100 = 1%.
2. INCORRECT CALCULATIONS (NOT RECOMMENDED):
   - The frequency of initial BI-RADS category 3 assessments is incorrectly calculated as total BI-RADS category 3 assessments divided by number of diagnostic examinations prompted by a category 0 screening examination, i.e. 280/2,000 = 14%.
   - The percentage of initial BI-RADS category 3 assessments that result in a breast cancer diagnosis is incorrectly calculated as number of malignant initial BI-RADS category 3 assessments divided by total BI-RADS category 3 assessments, i.e. 1/280 = 0.4%.

   Note: Critical audit errors may falsely indicate appropriate utilization and performance if calculations are made with total BI-RADS category 3 assessments, rather than initial, BI-RADS category 3 assessments. Consider the following brief example where 40 initial BI-RADS category 3 assessments yield 76 additional BI-RADS category 3 assessments at follow-up diagnostic imaging and 2 breast cancer diagnoses. In this example, the percentage of initial BI-RADS category 3 assessments that result in a breast cancer diagnosis is *correctly* calculated as 2/40 = 5%, which exceeds the established 2% frequency of malignancy for BI-RADS category 3 findings. This correct calculation indicates *inappropriate* use of BI-RADS category 3 and should trigger internal review and practice adjustment for findings with a likelihood of malignancy of 2% or less. However, if the calculation is performed using total (40 + 76) BI-RADS category 3 assessments as the denominator, the resulting frequency of breast cancer diagnosis would be *incorrectly* calculated as 2/(40 + 76) = 1.7%. Auditors may falsely reaffirm *inappropriate* use of BI-RADS category 3 and fail to adjust their practice patterns.

V. AREAS OF CONFUSION IN THE DATA COLLECTION PROCESS

A. WHAT NOT TO AUDIT

The purpose of the audit is to assess appropriate interpretive performance. There are some examinations that should not be included in the audit, as they may skew audit results.

1. CATEGORY 0 — AWAITING PRIOR EXAMINATIONS FOR COMPARISON

   Screening or diagnostic examinations that must be interpreted before previous examinations are available for comparison may be assessed initially as incomplete (BI-RADS Category 0: Need comparison with prior studies). This interpretation is not to be included in the audit. When previous examinations become available for comparison, an addendum or new report should be issued with the new final assessment category. If previous examinations do not become available within 30 days, FDA regulation requires a new final assessment category be assigned as if the examination were a baseline study. The second interpretation replaces and supersedes the initial interpretation and is used for audit purposes. The initial BI-RADS category 0 assessment is not included in the audit as it is a temporary placeholder until a definitive final assessment is rendered. Note that only the second final assessment is used for audit purposes, regardless of whether the initial assessment was read by the same or different reader.

2. CATEGORY 0 — INCOMPLETE DIAGNOSTIC EXAMINATIONS

   On rare occasions, a diagnostic evaluation cannot be completed due to equipment failure, lack of available equipment or personnel, or the patient's departure from the facility, etc. Additional imaging is still recommended, management recommendations cannot be finalized, and the examination is assigned BI-RADS category 0. This situation is analogous to the screening examination assessed as incomplete (BI-RADS category 0) awaiting prior examination(s) for comparison. Final assessment of the diagnostic examination and management recommendation are deferred until the imaging evaluation is completed, at which time the initial BI-RADS category 0 assessment is *replaced* by a final (category 1–5) assessment. The initial BI-RADS category 0 assessment is not included in the audit as it is a temporary placeholder until a definitive final assessment is rendered. Note that only the second final assessment is used for audit purposes, regardless of whether the initial assessment was read by the same or different reader. If the patient does not return for additional evaluation within 30 days of an incomplete diagnostic examination, an addendum to the initial report indicating that the existing examination remains incomplete is recommended.

3. CATEGORY 0 — TECHNICAL REPEATS

   Additional mammographic views may be requested due to technically inadequate views during the initial screening mammogram (e.g. presence of motion/blur artifact). The screening mammogram may be read as BI-RADS category 0: incomplete: needs technical repeat imaging. These cases are like the previous example in that the second final assessment rendered at time of repeat imaging replaces and supersedes the initial BI-RADS category 0 assessment. The second final assessment, but not the first, is included in the BI-RADS audit.

4. CATEGORY 3 — EXAMINATIONS NOT QUALIFYING AS INITIAL BI-RADS CATEGORY 3 ASSESSMENTS

   Initial BI-RADS category 3 assessments are included in the audit and defined as those made at screening (although this practice is discouraged) and those made at initial diagnostic imaging.

These comprise the total denominator in the BI-RADS category 3 audit. *BI-RADS category 3 assessments made at follow-up imaging after an initial BI-RADS category 3 assessment are excluded from the BI-RADS category 3 audit.*

5. NON-CONTRAST MRI EXAMINATIONS

   These examinations, typically for implant evaluation, are not performed for the detection of breast cancer and are, therefore, not included in the audit. BI-RADS assessments should not be assigned to these examinations.

6. EXAMINATIONS ASSESSED AS KNOWN, BIOPSY-PROVEN MALIGNANCY (BI-RADS CATEGORY 6)

   Patients with known biopsy-proven malignancy may undergo additional breast imaging examinations, for instance to assess response to neoadjuvant chemotherapy. These examinations should not be included in the audit as these patients already have known malignancy that has not been definitively locally treated, usually with surgical resection; their inclusion in the audit would inappropriately skew audit results for certain audit outcomes (e.g., cancer detection rate, PPV and sensitivity). There is one exception to this rule, newly introduced in this version of the Manual, for audits of breast MRI examinations performed for the indication of assessing the EOD. See section III. The More Complete Audit (section III) page 833.

7. POST-PROCEDURE MAMMOGRAPHY EXAMINATION AFTER IMAGE-GUIDED BIOPSY OR LOCALIZATION

   These mammograms are performed as part of image-guided interventions (clip/marker placement after biopsy or wire/seed placement after localization). As they are not performed for diagnostic purposes, they are not included in the breast imaging audit.

8. SECOND OPINION OF COMPLETED IMAGING

   Second opinion interpretations are not included in the audit, regardless of whether the initial opinion was given at the same facility (by another radiologist) or at another facility. Only the initial assessment for each case is included in the audit for the original performing and interpreting facility.

B. DOUBLE READING

Which reader gets credit for interpreted cases?

For the facility-wide audit, the most practical approach is the simplest: count each examination once, based on the final assessment after double reading is completed. However, in attributing assessments to the individual radiologists who participate in double reading, the method of assigning responsibility should depend on the type of double reading used.

1. If the first radiologist performs thorough interpretations and the second radiologist performs "quick reads" with knowledge of the interpretations made by the first radiologist, looking only to change negative assessments to positive (or alternatively, to change positive assessments to negative), the first radiologist will assume responsibility for all examinations based on their individual assessments, but the second radiologist will assume separate responsibility only for those examinations for which they changed the final assessment.

2. If two radiologists interpret examinations independently and consensus is determined by predefined rules (for example, an examination is given a positive final assessment if either radiologist makes a positive individual assessment, or, alternatively, an examination is given a positive final assessment only if both radiologists make positive individual assessments), then each radiologist will assume separate responsibility for examinations based on their individual assessments.

3. If two radiologists interpret examinations independently but then arrive at consensus by reviewing examinations and coming to a joint decision, then each radiologist will assume separate responsibility for examinations based on the final assessment after double reading is completed.
4. If two radiologists interpret examinations together (simultaneously), then each radiologist will assume separate responsibility for examinations based on the joint assessment that they make.
5. If two radiologists interpret examinations independently but consensus is made by a third radiologist, then all three radiologists will assume separate responsibility for examinations, the first two readers based on their individual assessments and the consensus reader based on the final assessment that he or she makes.

Note that for all previous examples, the assignment of responsibility relates only to the performance of individual radiologists at audit (for quality assurance purposes), not in the clinical-care context that may have medicolegal consequences. The mammography facility that utilizes double reading may choose to adopt different approaches in deciding which radiologist(s) to name on double-read mammography reports.

C. THE "SCREENING" VERSUS THE "DIAGNOSTIC WORK-UP" RADIOLOGIST

If two radiologists in a mammography facility interpret the screening and diagnostic examinations for the same patient, who gets credit for finding a cancer when it is correctly identified?

The answer to this question is analogous to that provided in the previous discussion concerning double reading. When two radiologists interpret one or more examinations for the same patient, each radiologist should assume separate responsibility for the examination(s) that they interpret. If a screening and a diagnostic examination are each interpreted as positive, and there is a subsequent diagnosis of breast cancer within 1 year, then both the screening and diagnostic examinations are classified as *true-positive (TP)*, and each radiologist gets credit for their interpretation.

D. CANCER IDENTIFIED AT SCREENING EXAMINATION LESS THAN 1 YEAR AFTER THE PREVIOUS NEGATIVE SCREENING EXAMINATION

Is the person who interpreted the initial examination as negative charged with a false-negative (FN), or is the person who detected the cancer at the "early" second screening examination credited with a true-positive (TP)?

The answer is both. Because the first screening examination was interpreted as negative, but breast cancer was diagnosed within 1 year, this examination is classified as *false-negative (FN)*. Because the second screening examination was read as positive and breast cancer was diagnosed shortly thereafter, this examination is classified as *true-positive (TP)*.

For purposes of the audits of the two individual radiologists, each will assume responsibility for their individual assessment, the first radiologist for a *false-negative (FN)* interpretation, and the second radiologist for a *true-positive (TP)* interpretation.

It may appear to be unfair that the first radiologist is assigned a *false-negative (FN)* outcome when the only reason for this outcome is that the patient returned for screening sufficiently early that a breast cancer diagnosis was made less than 1 year after the previous examination. However, this scenario is rare and requires auditing rules to be consistently and uniformly applied to produce meaningful overall results. Therefore, subjectivity must be eliminated from

the process of determining outcomes, such as allowing one to decide whether what appears to be a *false-negative (FN)* outcome is the result of early subsequent screening (one then would need to examine the previous screening examination in retrospect to decide whether it should or should not have been interpreted as negative) or interpretive error.

E. THE GROUP OF EXAMINATIONS ASSESSED AS PROBABLY BENIGN (BI-RADS CATEGORY 3) WITH A RECOMMENDATION FOR SHORT-INTERVAL FOLLOW-UP AND SURVEILLANCE IMAGING

Should they be audited separately?

The BI-RADS v2025 Manual includes new detailed guidance for counting, tracking and auditing all initial BI-RADS category 3 assessments (Section III, see page 846) for screening, asymptomatic diagnostic evaluations and diagnostic examinations performed to evaluate clinical problems. Indeed, patients, radiologists and facilities would benefit from knowing how frequently examinations initially assessed as probably benign continue to demonstrate benign findings. If too many (i.e., > 2%) of these cases are found subsequently to represent breast cancer, this would indicate incorrect assessment of truly suspicious findings as being probably benign. Such an outcome would be identified only through a separate "category 3 audit." This would permit appropriate action to be taken by the radiologist(s) involved to modify the interpretive criteria being used to assess findings as probably benign. This version of the Manual describes how to audit BI-RADS category 3 examinations.

VI. FREQUENTLY ASKED QUESTIONS AND GUIDANCE CONCERNING BREAST IMAGING AUDITS

A. ALL BREAST IMAGING MODALITIES

1. *Is it necessary for a breast imaging facility to separate the medical audit into screening and diagnostic components?*

   FDA regulations [1] do not require auditing at the level of complexity described in parts of this section, including separate auditing of screening and diagnostic examinations. However, periodic auditing is sound medical practice and the best way for a breast imaging practice and individual radiologists to ascertain acceptable clinical performance. The ACR strongly recommends that screening and diagnostic examinations be audited separately because the outcomes of these two types of examinations differ substantially and adjustments in practice patterns, in response to the audit metrics, may significantly impact patient care and outcomes [5, 23, 24, 26, 27, 29–31]. For practices that are unable to segregate examinations by screening versus diagnostic indication, mathematical models have been developed to provide guidance on how to evaluate combined audit data [32].

2. *Published benchmarks for PPV_2 and PPV_3 are similar. Which one is the more accurate indicator of interpretive performance?*

   PPV_2 and PPV_3 are performance measures that relate primarily to diagnostic mammography examination. PPV_2 involves the positive predictive value calculation (percentage of positive examinations that are TP) based on the number of examinations for which tissue diagnosis is *recommended*, whereas PPV_3 involves the same calculation based on the number of examinations for which tissue diagnosis is *performed*. Because biopsies performed are more likely to yield a cancer diagnosis than biopsies not performed, one would expect the value of PPV_3 to be somewhat higher than that of PPV_2, and this is what is observed in almost all breast imaging audits. PPV_3 is the more accurate indicator of cancer status because definitive biopsy results may be obtained in virtually all cases. Furthermore, the data collected for the PPV_3 calculation are the same as what is required by the FDA regulations [1].However, the PPV_2 calculation directly reflects the performance of the interpreting radiologist (involving all examinations for which tissue diagnosis is recommended), whereas the interpreting radiologist has no control over the subset of PPV_2 cases that undergo biopsy and qualify for the PPV_3 calculation. Therefore, although PPV_3 is the more accurate indicator of cancer status, PPV_2 is the more meaningful indicator of interpretive performance.

3. *Why is it important to use more than one or two breast imaging audit metrics when evaluating performance?*

   A breast imaging audit is clinically relevant to the extent that it provides meaningful indicators of interpretive performance. The more data collected and analyzed, the more comprehensive an understanding one may derive about underlying interpretive performance [43]. Analysis of performance based on a single metric is of little value. For example, what useful information can one deduce from the recall rate alone? One can deduce simply that a given percentage of screened women are recommended for additional imaging evaluation, but nothing about how frequently biopsy is recommended, the likelihood of cancer when biopsy is recommended, the frequency of cancer detection, or whether detected cancers are clinically

occult or early in stage (hence favorable in prognosis). A similar, very limited amount of information may be derived from any other single performance metric or pair of metrics. Instead, the data collected in and derived from the *Basic Clinically Relevant Audit*, as described in Section II (see page 816) should provide sufficient insight into the interpretive performance of a breast imaging practice and its individual radiologists to improve patient care and outcomes. The *More Complete Audit* Section III (see page 833) should provide an even more comprehensive understanding of performance.

4. *In my practice, we perform approximately 30,000 screening mammography and approximately 5000 diagnostic mammography examinations per year in a major metropolitan area in the United States. We have state-of-the-art equipment and about half of our radiologists are fellowship trained. However, when we compare our audit outcomes with the Breast Cancer Surveillance Consortium (BCSC) benchmark outcomes listed in the current version of the BI-RADS Manual, our screening mammography performance for cancer detection rate, positive predictive value 1 (PPV_1), PPV_2 and PPV_3 is below average; only our recall rate is better than average performance. We had expected to do better. What should we do to improve?*

   The BCSC data should not be used as benchmarks to compare the performance of a group of radiologists at a mammography facility without linkage to a registry. The BCSC data are linked to tumor registry data, but most mammography facilities in the United States are not. Because of the registry linkage, there is more complete and reliable cancer ascertainment which leads to higher cancer detection rates and PPVs than an average practice in the United States. Except for the recall rate, the benchmarks reported by the BCSC are not likely to be achieved by a mammography facility in the United States [31].

5. *I consult regularly with a breast surgeon before we jointly decide whether a biopsy or surveillance is the best management recommendation. The Manual does not seem to address this situation. Should these images be reported as BI-RADS category 3, or category 4, or possibly category 0, in the interim? Category 0 specifies additional imaging, not a surgical consult. Is there a provision for "waiting for consult"?*

   No, there is no BI-RADS assessment category that includes "waiting for consult." The BI-RADS assessment category should align with the findings on imaging. "Waiting for consult" or "surgical consultation recommended" is not an assessment category; it is a recommendation. If the surgeon and/or the patient chooses a different management not aligned with the assessment category, that information can be mentioned in the impression of the report but is not necessary. Further reading in the sections titled, BI-RADS Assessment Concordant with Management Recommendation and the BI-RADS Assessment Does Not Match Management Recommendation may be helpful.

6. *Why is it that recall rate, PPV_1 and PPV_2 can be so different when comparing mammography, US and MRI?*

   The outcome parameters recall rate and PPV_1 relate only to purely screening examinations. Recall rate is the percentage of all screening examinations that are positive (BI-RADS categories 0, 3, 4, and 5). PPV_1 is the percentage of all positive screening examinations (BI-RADS categories 0, 3, 4, and 5) that result in a tissue diagnosis of cancer within 1 standard interval (1 year in the U.S.). PPV_2 represents the percentage of all diagnostic (or rarely, screening) examinations recommended for tissue diagnosis (BI-RADS categories 4 and 5) that result in a diagnosis of cancer within 1 standard interval (1 year in the U.S.). PPV_1 and PPV_2 can be significantly different for each modality and accepted practice patterns. For example, nearly all positive screening mammography assessments are BI-RADS category 0, among which fewer than half then are assessed as BI-RADS category 4 or 5 at diagnostic imaging. Screening assessments of BI-RADS category 3, 4 or 5 are rare and discouraged for mammography

but are possible. Positive breast MRI screening examinations, however, frequently receive a BI-RADS category 4 or 5 assessment and category 0 and 3 are much less common. For mammography, the difference between PPV_1 and PPV_2 is large because PPV_1 includes many BI-RADS category 0 results and PPV_2 includes only BI-RADS category 4 and 5 results. For breast MRI the difference between PPV_1 and PPV_2 will be small because positive MRI screening examinations frequently receive a BI-RADS category 4 or 5 assessment (include in both PPV_1 and PPV_2) and category 0 and 3 (included only in PPV_1) are much less common.

B. MAMMOGRAPHY

1. *Isn't it internally inconsistent to consider BI-RADS category 3 assessments positive at screening but negative at diagnostic imaging?*

   No, it is internally consistent. The binary management decision at screening involves recommending action before the next interval screening (positive) versus recommending no action until the next interval screening (negative). The management decision pertinent to diagnostic imaging involves recommending tissue diagnosis (positive) versus anything other than tissue diagnosis (negative). Also remember that, as stated previously, BI-RADS category 3 assessments are not recommended for use at screening mammography.

2. *BI-RADS allows for tracking outcomes of cross-modality studies both at the modality (mammography, ultrasound, MRI) level and the combined level. Does the Manual allow for separate tracking outcomes of digital breast tomosynthesis (DBT)?*

   Yes. See the benchmarks for DBT above in Table 4.

3. *We have several mobile mammography units, each accredited as a separate facility. FDA regulations require that each facility has a separate mammography medical outcomes audit. May we combine the mammography medical outcomes audits for these facilities and units?*

   Yes, the FDA has approved an alternative standard [42] allowing mobile unit operators to combine mammography medical outcomes audits under certain conditions. In situations where multiple mobile mammography facilities are under the same ownership, they may be treated collectively as a single facility for the purposes of meeting FDA audit requirements, if all the following conditions are met.

   Each facility must consist of a single mobile mammography unit.

   i. The same entity or group administers the operation of all included mobile facilities.

   ii. The same lead interpreting physician has the responsibility for assuring that all included mobile facilities meet FDA requirements.

   iii. The same group of radiologists interprets all images from all included mobile facilities.

   iv. All included mobile facilities provide services to the same patient population.

C. ULTRASOUND

1. *Why are handheld ultrasound screening (HHUS) examinations audited using an approach like that for mammography?*

   As explained in the Introduction to the Auditing and Outcomes Monitoring section, auditing must be based on objective and reproducible rules. Furthermore, auditing for all breast imaging modalities should utilize the same rules to facilitate cross-modality comparisons, except when the unique aspects of a given modality justify a different approach. Auditing procedures for mammography have been established for many years and clinically representative benchmarks using these auditing procedures have been published, so that an

individual mammography facility (or individual interpreting physician) may reliably compare observed outcomes with these benchmarks. The use of US and MRI for both screening and diagnostic breast imaging has become widespread. It is not only reasonable but also highly desirable to base the auditing of US and MRI examinations on the procedures used for mammography, whenever practical.

In defining positive screening examinations, mammography, US and MRI auditing utilize the objective and reproducible rule of whether action, such as acquiring additional images beyond the standard screening protocol or tissue sampling, is recommended by the interpreting radiologist and/or performed before completion of the standard screening interval. This rule is also applied to HHUS and ABUS auditing when the radiologist directs additional (nonstandard) sonographic image acquisition to further characterize findings at the time of HHUS or ABUS examinations. Each breast imaging facility is encouraged to adhere to the ACR Practice Parameter for Performance of Whole Breast Ultrasound for Screening and Staging. Facilities that deviate from the practice parameter should indicate in their policy and procedure manual what standard images should be recorded for normal (BI-RADS category 1 or 2) HHUS or ABUS examinations. Furthermore, the HHUS or ABUS report should indicate if standard screening images were permanently archived with or without additional, nonstandard (i.e. diagnostic) images. This will allow for objective and reproducible auditing, especially if HHUS or ABUS reports are created using an automated system to prospectively identify examinations with additional permanently archived diagnostic images as screening-positive and either diagnostic-positive or diagnostic-negative depending on the final assessment rendered.

2. *I do not understand why BI-RADS assessment category 3 is not recommended at screening for mammography but acceptable for US. Why this difference in recommendations?*

   BI-RADS assessment category 3 is not recommended at screening for mammography because a full diagnostic breast imaging work-up should be completed before rendering a category 3 assessment. This practice complies with the prospective data supporting the observation of specific findings when a diagnostic examination is completed [44]. There are two relevant scenarios for allowing a BI-RADS 3 related to screening US. During online screening, the interpreting radiologist may acquire or direct the sonographer to acquire additional images to further evaluate a finding. These additional images create a diagnostic examination and qualify the screening examination as BI-RADS assessment category 0 because action is taken before completing the next standard screening ascertainment interval. The imaging work-up is completed contemporaneously and the diagnostic examination assessed as BI-RADS category 3. The screening examination would be audited as positive (category 0) while the diagnostic examination would be audited as negative (if category 3) or positive (if category 4 or 5). If audited correctly as above, the patient appropriately receives a BI-RADS 3 assessment for the diagnostic examination acquired during the screening visit. A BI-RADS 3 may also be rendered for a screening US examination without completing a diagnostic work-up as described in the literature [45].

D. MRI

1. *I do not understand why BI-RADS assessment category 3 is not recommended at screening for mammography but accepted for screening MRI. Also, I see that a screening category 3 assessment should be considered positive, regardless of the modality. Why the differences in recommendations for use and why the similarity in how to audit screening category 3 assessments?*

   The first part of the answer is that data specifying the features of BI-RADS category 3 findings for mammography are well established and require complete diagnostic evaluation. However, the specific features of MRI findings that may be safely followed with a likelihood

of malignancy of 2% or less are neither definitively established nor differentiated by screening or diagnostic MRI protocols. Facilities currently elect whether or not to assess BI-RADS category 3 assessments at screening MRI at their discretion. The second part of the answer recognizes the differences between MRI and mammography. Screening and diagnostic mammography examinations are distinctly different, with additional specific and targeted images being obtained during diagnostic mammography. Both screening MRI and diagnostic MRI examinations likely contain all the imaging information required for interpretation without the need for added sequences. Hence, a category 3 assessment at screening MRI is acceptable, as the finding in question has been fully evaluated prior to rendering the assessment. The third part of the answer is that a BI-RADS category 3 assessment at screening is considered positive at auditing, independent of screening modality, because the management recommendation (short-interval follow-up) includes action before completion of the standard screening interval of 1 year.

For General FAQs (those that apply to multiple modalities), please see page 869.

VII. INITIAL METHOD OF DETECTION

INTRODUCTION

The American College of Radiology (ACR), U.S. Preventive Services Task Force (USPSTF) and American Cancer Society (ACS) agree that annual screening mammography beginning at age 40 will save the most lives [46–49]. However, the same organizations disagree over the balance of risks and benefits of screening mammography and recommend different frequencies and ages to initiate early detection of breast cancer in the U.S. The results of randomized controlled trials (RCTs), conducted between 1963 and 1990 from one U.S. and multiple international sources, provide strong evidence that screening mammography significantly reduces deaths from breast cancer [50, 51].

Shortly after the data from RCTs confirmed the benefits of early detection, many nations instituted population-wide breast cancer screening programs. Administrators of those programs had the foresight to track the initial method of detection (MOD), such as mammography screening or clinical examination, for every patient with a new diagnosis of breast cancer; this has been underway for decades. Administrators and physicians actively review patient-specific data from international programs at regular intervals, linking outcomes directly to MOD, to understand and adapt breast cancer care in those countries. In the U.S., lacking a centralized screening program or ability to link MOD to patients, this cannot be done.

KNOWLEDGE GAPS

Many national, state, and local databases in the U.S. such as the National Cancer Institute's Surveillance, Epidemiology and End Results (SEER) program, the Centers for Disease Control's National Program of Cancer Registries, the American College of Surgeons' National Cancer Database (NCDB) and the ACR's National Mammography Database (NMD) collect specific data for every patient with a new diagnosis of breast cancer. Without patient specific data on initial MOD, national organizations, such as the USPSTF, ACS, and American College of Physicians (ACP), when examining the impact of screening, still turn to models based on historic data and variable assumptions that are subject to bias [48, 49, 52]. The lack of contemporary, patient-specific information has permitted ongoing speculation and fostered disagreement about the risks and benefits of screening in the U.S. leading to conflicting recommendations, which confuse patients and providers and foster missed opportunities to save lives [51, 52].

DEFINING AND DETERMINING MOD

The initial MOD of breast cancer is defined as the first test or clinical event to trigger the work-up leading to the histologic diagnosis of breast cancer. Initial MOD can include image-based screening modalities such as full-field digital mammography (FFDM), digital breast tomosynthesis (DBT), ultrasound, MRI and other tests. Self-examination and clinical breast examination (CBE), which detect lumps, thickening or tenderness, can also be the initial MOD leading to a diagnosis. Patients may also trigger detection of breast cancer when they seek care for nipple discharge, erythema, pain, dimpling or skin ulceration. In addition, other imaging or laboratory tests not designed to evaluate the breast, such as abdominal CT or brain MRI, may also offer the initial findings of metastases that lead to a diagnosis of breast cancer.

BENEFITS OF COLLECTING MOD

If MOD can be assigned and collected accurately and without bias for each patient, we could have new primary data, rather than models based on historical data that may no longer accurately represent

the diversity of our screening-eligible population or advances in screening technologies. Concrete, patient-specific data could bring the ACR, USPSTF and ACS to consensus recommendations for screening. We could employ the MOD-inclusive data to answer numerous national population-based questions about how screening relates to efficacy, equity, treatment, and breast cancer, such as:

1. What are the relative contributions of screening and treatment to reducing mortality from breast cancer?
2. Do patients with screen-detected cancers have different treatment or mortality outcomes compared to patients whose cancers are detected clinically?
3. Do tumors that are screen-detected have different molecular signatures compared to tumors that are detected clinically?
4. Are there racial or ethnic disparities in screening that impact outcomes?
5. What percentage of breast cancers are not initially detected on screening, and how does this vary by personal risk, breast density, age, or other factors?
6. Are there differences in initial staging for breast cancers detected with image-based screening vs clinical or self-examination?
7. Do MOD and outcomes vary with geographic location, and can we use that information to improve access to screening at the local level?
8. Are supplemental screening options (MRI, ultrasound, etc.) improving treatment, morbidity, or mortality from breast cancer?
9. Should the treatment of stage I cancers detected at screening be the same as stage I cancers detected clinically?

BARRIERS TO NATIONAL COLLECTION OF MOD

The U.S. health care system provides cutting edge care with comparatively brief wait times and less regard to cost, but data collection is a patchwork of public and private entities funded by numerous private and public payors competing at the local and regional levels, stitched together with different electronic medical record databases of heterogeneous patient populations. Nearly every state has a tumor registry responsible for tracking valuable information such as incidence, stage, race, and mortality for every case of cancer diagnosed. Currently, patient data from some state registries are de-identified and then sent to SEER.

CATEGORIES OF MOD

MOD CATEGORY S: Detection of Breast Cancer from an Image-Based Screening Examination

MOD Category S includes imaging-based screening examinations performed specifically to detect breast cancer in an *asymptomatic* population. Screening involves the binary decision of recommending action before the next screening versus recommending no action until the next screening. When the initial finding of a possible breast cancer is detected on an image-based screening examination and additional action is recommended (i.e. BI-RADS category 0, 3, 4 or 5), that leads to a diagnosis of breast cancer, the MOD is category S. Subcategories are defined so that the first specific screening modality allowing the radiologist to detect the cancer can be captured and abstracted.

Category S: initial asymptomatic image-based screening detection

- Category Sma: screening full field 2D film or FFDM (no synthetic views or DBT)
- Category Sdbt: screening with DBT plus FFDM, synthetic 2D or both

- Category Sus: screening ultrasound
- Category Smri: screening MRI
- Category Scem: screening contrast enhanced mammography
- Category Snuc: screening Positron Emission Mammography (PEM) or Molecular Breast Imaging (MBI)
- Category So: other screening modality (CT, etc.)

MOD CATEGORY P: Patient or Provider Detected

MOD Category P includes all types of clinical presentations. When a patient discovers and seeks care for a lump or other breast concern or a provider detects the initial finding of a possible breast cancer on physical examination prompting orders for diagnostic imaging evaluation, then the appropriate MOD is category P. This includes the scenario in which a patient presents with signs or symptoms of breast cancer and the subsequently ordered imaging test shows an *incidental* suspicious finding that is completely distinct from the symptom (i.e. contralateral breast or clearly different location in the ipsilateral breast).

Category P: initial clinical presentation/detection

- Category Pat: patient first reported self-examination finding and/or symptom, whether or not also subsequently detected on clinical breast examination
- Category Pro: provider first detected finding on physical examination of asymptomatic patient
- Category Ppp: if it is impossible to determine if the patient or the provider detected it first

MOD CATEGORY N: All other means by which a diagnosis of breast cancer is first detected.

MOD Category N includes other pathways by which the diagnosis of breast cancer initially comes to clinical attention.

Category N: Not detected with image-based screening; not detected by provider or patient.

- Category N: other/incidental finding on non-breast imaging test (chest CT, thermography, PET/CT)
- Category N: other/incidental finding on prophylactic mastectomy or reduction surgery
- Category N: search for unknown primary cancer site

ASSIGNING MOD ACCURATELY

Abstractors employed by state, local and hospital registries currently gather information related to a new cancer diagnosis from clinical reports. Most of the information regarding cancer type, size, grade, and receptor status is quickly abstracted from succinct and standardized pathology reports. However, abstractors may resort to the tedious and time-consuming strategy of sifting through other clinical notes. We cannot expect abstractors to retrospectively read multiple radiology and pathology reports to recreate the clinical history to determine the MOD. In addition, if abstractors, or radiologists, already know the patient has breast cancer, will they be able to avoid unconscious bias when assigning MOD? It is imperative that the assignment of initial MOD be accurate, unbiased, easily discoverable by abstractors, and correctly transferred to registries for future scientific investigation.

With inclusion in the BI-RADS Manual, radiologists are strongly encouraged to *prospectively* add a single MOD to the diagnostic imaging report when rendering an assessment of BI-RADS 4 or 5 for each patient who does not already have a current, biopsy-proven diagnosis of breast cancer. The radiologist creating the diagnostic imaging report will need to review recent prior imaging, which is

part of the standard clinical process during the work-up, to determine the MOD. This diagnostic radiologist will have the expertise to understand the subtle nuances of the complete imaging, history and clinical information and be uniquely suited to accurately assign the initial MOD and avoid bias at the time of patient evaluation and report creation prospectively before the tissue diagnosis. The diagnostic radiologist will add a line at the end of the radiology report that reads:

The MOD is Sma/Sdbt/Sus/Smri/Scem/Snuc/So/Pat/Pro/Ppp/N.

The radiologist signs the report as usual, and patient care follows standard protocols. Placing a single initial MOD at the bottom of a positive (BI-RADS 4 or 5) diagnostic report is designed to facilitate discovery of the MOD by the abstractor. Rather than ask the abstractor to retrospectively sift through multiple radiology reports and recreate the sequence of events with clinical history to determine the MOD, we prospectively provide it in a single consistent location: after the impression of the diagnostic breast imaging report. This approach maximizes accuracy and minimizes the added burden on the abstractor.

ADDITIONAL METHODS OF DEMONSTRATION

It is essential to distinguish initial MOD from additional methods of demonstration (AMOD). AMOD are defined as any additional method, *following initial detection*, which further characterizes or redemonstrates a cancer. A cancer may be additionally demonstrated by any of the same classifications found in the MOD listed above. Initial MOD must be distinguished from subsequent AMOD. For example, a cancer initially may be detected on screening mammography and then further characterized on ultrasound and MRI. Ultrasound and MRI would be considered AMOD. AMOD are *not* added to the report.

GUIDANCE

MOD is assigned at the level of the patient. MOD is not specific to a breast or a targeted finding.

MOD CATEGORY S GUIDANCE

Category S includes several additional and important scenarios:

1. Two screening examinations are performed on the same day (e.g. screening mammogram and screening ultrasound) and *reported separately*, and only one exam is coded as BI-RADS category 0, prompting a recall and recommendation for biopsy. The MOD is the modality prompting the recall. Example: if a screening DBT mammogram and US are performed on the same day and a finding on the screening mammogram is given a BI-RADS category 0 assessment and the US is given a BI-RADS category 1 or 2 assessment, and biopsy is recommended at the subsequent work up, then the MOD in the diagnostic BI-RADS category 4 or 5 report is Sdbt.
2. Two screening examinations (e.g. screening mammogram and screening US or MRI) are performed on the same day and the finding is equally and independently identified on both examinations and both examinations are classified as BI-RADS category 0 in *separate reports.* A biopsy is recommended at subsequent work-up. In this case, the primary screening examination should be recorded as the MOD. Because screening mammography is the primary screening exam and US and MRI are considered supplemental, the mammogram is the MOD. Example: A 2D mammogram and MRI are performed on the same day and a BI-RADS category 0 is assigned to a finding seen equally on both modalities. The subsequent work-up with ultrasound and mammography confirms a suspicious finding. The MOD in the diagnostic BI-RADS category 4 or 5 report should be category Sma rather than Smri.

3. Two screening examinations are performed on the same day and *reported together but the finding is initially seen only on one of them.* Example: A suspicious mass is seen on screening US first and seen in retrospect on the DBT screening mammogram. A single report recommending additional imaging is issued. Subsequent work-up confirms a suspicious mass. The MOD in the diagnostic BI-RADS category 4 or 5 report is category Sus.

4. If two screening examinations are performed on separate days, the MOD is assigned for the modality on which the cancer was *initially* identified chronologically, regardless of whether the finding is identified on both exams or how it is seen at the time of diagnostic work-up.

5. Other types of special screening examinations, such as those described as "diagnostic" but performed on *asymptomatic* women following a clinical history of breast cancer or benign breast biopsy or breast augmentation, are included in the screening group for audit purposes. This is consistent with the audit guidelines in the BI-RADS Manual. Findings detected initially on these examinations in asymptomatic women should also be categorized as screening for the purposes of MOD. Example: A suspicious finding is initially detected on a yearly 2D mammogram (no DBT images) in an *asymptomatic* woman with an indication of prior history of breast cancer treated 3 years ago. The subsequent work-up confirms a suspicious finding. The MOD in the diagnostic BI-RADS category 4 or 5 report is category Sma.

6. BI-RADS category 3: If a BI-RADS category 3 finding is stable and benign and never progresses to BI-RADS category 4 or 5 assessment, and tissue sampling is never recommended, the MOD will never be assigned. But if a BI-RADS category 3 is reassessed as BI-RADS category 4 or 5 on diagnostic surveillance imaging, then the radiologist would code the MOD on that BI-RADS category 4 or 5 diagnostic report. MOD is based on complete review of imaging history back to initial screening or diagnostic examination that detected the finding and triggered the follow-up. Example: If the initial examination related to this finding was a BI-RADS category 3 when a 24-year-old patient presented with a palpable lump characterized as oval, parallel, circumscribed and homogeneously hypoechoic (presumed fibroadenoma), that grew at 12-month follow-up with biopsy now recommended, then it is coded Pat. If a baseline screening tomosynthesis mammogram with synthetic views was a BI-RADS category 0 for calcifications, followed by BI-RADS category 3 on the immediate recall diagnostic examination, and then BI-RADS category 4 at the 6-month short interval follow-up, then initial MOD is coded Sdbt for the first examination (Sdbt) that triggered the work-up and follow-up.

7. Initial MOD should be assigned to *screening* MRI or targeted ultrasounds after screening MRI only in patients without an active diagnosis of cancer. If a finding on screening MRI is assessed as BI-RADS category 4 or 5 and tissue sampling and targeted ultrasound are recommended, Smri should be assigned as the MOD. If the targeted ultrasound is negative (BI-RADS category 1) and MR-guided breast biopsy is recommended because the MRI finding is suspicious, the MOD will already have been assigned on the MRI (MOD could be carried over to the ultrasound as Smri but it is not required). If a finding on screening MRI is assessed as BI-RADS category 0 because the finding may be able to be definitively characterized as benign or suspicious on targeted ultrasound, MOD is *not* assigned in the MRI report. If the final assessment from the targeted ultrasound is BI-RADS category 4 or 5 and tissue sampling is recommended, then MOD should be assigned in the diagnostic ultrasound report as per usual guidelines which would be Smri.

8. MOD should not be assigned to examinations after tissue sampling has established the diagnosis of cancer. Any mammogram, ultrasound, MRI or other imaging modality employed to further evaluate the extent of disease or staging does not require an MOD. The diagnosis of cancer has already been established and MOD is no longer prospective.

9. MOD should not be assigned to an MRI performed to evaluate the extent of disease. The diagnosis of cancer has already been established and the assignment of MOD is no longer prospective. In the vast majority of cases, MOD will have been assigned on prior diagnostic examinations when tissue sampling was recommended.
10. To remain consistent, MOD should not be assigned to targeted ultrasound examinations recommended after MRI for extent of disease. The diagnosis of cancer has already been established and the assignment of MOD is no longer prospective. In the vast majority of cases, MOD will have been assigned on prior diagnostic examinations when tissue sampling was recommended.

MOD CATEGORY P GUIDANCE

Detection of Breast Cancer from a Clinical Presentation

1. If a patient presents with clinical signs and symptoms of breast cancer such as a palpable lump or nipple discharge, and the imaging test shows a suspicious finding, then the MOD in the diagnostic BI-RADS category 4 or 5 report is Pat.
2. If a patient presents with signs and symptoms of breast cancer and the imaging test shows *a finding that is completely distinct from the symptom (i.e. contralateral breast or clearly different location in the ipsilateral breast) and it is suspicious, then the MOD would still be category Pat because the patient's symptom triggered the work-up and the objective of tracking MOD is to understand the impact of screening mammography. The examination in this scenario is not a screening examination, therefore, a screening MOD cannot be applied.* Example: A woman presents with a palpable mass in the right breast which turns out to be a cyst. Diagnostic mammography shows a suspicious finding in the asymptomatic left (contralateral) breast, then the MOD in the BI-RADS category 4 or 5 report for the left breast is category Pat because the incidental finding prompting cancer diagnosis would not have been detected had it not been for the patient's symptom.
3. If a provider performing a clinical examination detects a sign (lump, retraction, ridge) in an asymptomatic patient, that prompts diagnostic work-up and tissue sampling is recommended, then MOD is Pro.
4. If it is unclear if the patient presented to a provider with a symptom or a provider first detected a sign on clinical exam or questioning, then the MOD, when the patient undergoes subsequent diagnostic imaging with a BI-RADS category 4 or 5 result, is Ppp.

MOD CATEGORY N GUIDANCE

If, after careful review of imaging and clinical data, MOD is Neither S nor P, then N should be assigned. Based on existing practice patterns, N should be assigned for a very small fraction of cases. Such cases might include work-up for cancer of unknown primary after detection of an incidental liver mass on CT or referral for work-up after thermography which is not an evidence-based screening test.

16. Lee JM, Ichikawa L, Valencia E, et al. Performance Benchmarks for Screening Breast MR Imaging in Community Practice. Radiology 2017;285:44–52.

17. Niell BL, Gavenonis SC, Motazedi T, et al. Auditing a breast MRI practice: performance measures for screening and diagnostic breast MRI. J Am Coll Radiol 2014;11:883–9.

18. Strigel RM, Rollenhagen J, Burnside ES, et al. Screening Breast MRI Outcomes in Routine Clinical Practice: Comparison to BI-RADS Benchmarks. Acad Radiol 2017;24:411–17.

19. Sippo DA, Burk KS, Mercaldo SF, et al. Performance of Screening Breast MRI across Women with Different Elevated Breast Cancer Risk Indications. Radiology 2019;292:51–59.

20. Comstock CE, Gatsonis C, Newstead GM, et al. Comparison of Abbreviated Breast MRI vs Digital Breast Tomosynthesis for Breast Cancer Detection Among Women With Dense Breasts Undergoing Screening. Jama 2020;323:746–56.

21. Bakker MF, de Lange SV, Pijnappel RM, et al. Supplemental MRI Screening for Women with Extremely Dense Breast Tissue. N Engl J Med 2019;381:2091–102.

22. Veenhuizen SGA, de Lange SV, Bakker MF, et al. Supplemental Breast MRI for Women with Extremely Dense Breasts: Results of the Second Screening Round of the DENSE Trial. Radiology 2021;299:278–86.

23. Sprague BL, Arao RF, Miglioretti DL, et al. National Performance Benchmarks for Modern Diagnostic Digital Mammography: Update from the Breast Cancer Surveillance Consortium. Radiology 2017;283:59–69.

24. Carney PA, Parikh J, Sickles EA, et al. Diagnostic mammography: identifying minimally acceptable interpretive performance criteria. Radiology 2013;267:359–67.

25. Burnside ES, Lin Y, Munoz del Rio A, et al. Addressing the challenge of assessing physician-level screening performance: mammography as an example. PLoS One 2014;9:e89418.

26. Lee CS, Bhargavan-Chatfield M, Burnside ES, Nagy P, Sickles EA. The National Mammography Database: Preliminary Data. AJR Am J Roentgenol 2016;206:883–90.

27. Carney PA, Sickles EA, Monsees BS, et al. Identifying minimally acceptable interpretive performance criteria for screening mammography. Radiology 2010;255:354–61.

28. Rosenberg RD, Yankaskas BC, Abraham LA, et al. Performance benchmarks for screening mammography. Radiology 2006;241:55–66.

29. Sickles EA, Miglioretti DL, Ballard-Barbash R, et al. Performance benchmarks for diagnostic mammography. Radiology 2005;235:775–90.

30. Dee KE, Sickles EA. Medical audit of diagnostic mammography examinations: comparison with screening outcomes obtained concurrently. AJR Am J Roentgenol 2001;176:729–33.

31. D'Orsi CJ, Sickles EA. 2017 Breast Cancer Surveillance Consortium Reports on Interpretive Performance at Screening and Diagnostic Mammography: Welcome New Data, But Not as Benchmarks for Practice. Radiology 2017;283:7–9.

32. Sohlich RE, Sickles EA, Burnside ES, Dee KE. Interpreting data from audits when screening and diagnostic mammography outcomes are combined. AJR Am J Roentgenol 2002;178:681–6.

33. Smith-Bindman R, Chu PW, Miglioretti DL, et al. Comparison of screening mammography in the United States and the United kingdom. JAMA 2003;290:2129–37.

REFERENCES

1. Department of Health and Human Services. Food and Drug Administration Mammography Quality Standards Act final rule. https://public-inspection.federalregister.gov/2023-04550.pdf. Accessed March 10, 2023.
2. Rosen EL, Baker JA, Soo MS. Malignant lesions initially subjected to short-term mammographic follow-up. Radiology 2002;223:221–8.
3. Lehman CD, Rutter CM, Eby PR, White E, Buist DS, Taplin SH. Lesion and patient characteristics associated with malignancy after a probably benign finding on community practice mammography. AJR Am J Roentgenol 2008;190:511–5.
4. Kerlikowske K, Smith-Bindman R, Abraham LA, et al. Breast cancer yield for screening mammographic examinations with recommendation for short-interval follow-up. Radiology 2005;234:684–92.
5. Berg WA, Berg JM, Sickles EA, et al. Cancer Yield and Patterns of Follow-up for BI-RADS Category 3 after Screening Mammography Recall in the National Mammography Database. Radiology 2020;296:32–41.
6. Lee CI, Abraham L, Miglioretti DL, et al. National Performance Benchmarks for Screening Digital Breast Tomosynthesis: Update from the Breast Cancer Surveillance Consortium. Radiology 2023; 307:e222499.
7. Lee CS, Sengupta D, Bhargavan-Chatfield M, Sickles EA, Burnside ES, Zuley ML. Association of Patient Age With Outcomes of Current-Era, Large-Scale Screening Mammography: Analysis of Data From the National Mammography Database. JAMA Oncology 2017;3:1134–36.
8. Lee CS, Moy L, Hughes D, et al. Radiologist Characteristics Associated with Interpretive Performance of Screening Mammography: A National Mammography Database (NMD) Study. Radiology 2021;300:518–28.
9. Berg WA, Bandos AI, Mendelson EB, Lehrer D, Jong RA, Pisano ED. Ultrasound as the Primary Screening Test for Breast Cancer: Analysis From ACRIN 6666. J Natl Cancer Inst 2016;108.
10. Berg WA, Zhang Z, Lehrer D, et al. Detection of breast cancer with addition of annual screening ultrasound or a single screening MRI to mammography in women with elevated breast cancer risk. Jama 2012;307:1394–404.
11. Kriege M, Brekelmans CT, Boetes C, et al. Efficacy of MRI and mammography for breast-cancer screening in women with a familial or genetic predisposition. N Engl J Med 2004;351:427–37.
12. Kuhl CK, Schrading S, Leutner CC, et al. Mammography, breast ultrasound, and magnetic resonance imaging for surveillance of women at high familial risk for breast cancer. J Clin Oncol 2005;23:8469–76.
13. Leach MO, Brindle KM, Evelhoch JL, et al. The assessment of antiangiogenic and antivascular therapies in early-stage clinical trials using magnetic resonance imaging: issues and recommendations. Br J Cancer 2005;92:1599–610.
14. Sardanelli F, Podo F. Breast MR imaging in women at high-risk of breast cancer. Is something changing in early breast cancer detection? Eur Radiol 2007;17:873–87.
15. Warner E, Plewes DB, Hill KA, et al. Surveillance of BRCA1 and BRCA2 mutation carriers with magnetic resonance imaging, ultrasound, mammography, and clinical breast examination. Jama 2004;292:1317–25.

34. Onega T, Zhu W, Kerlikowske K, et al. Preoperative MRI in breast cancer: effect of breast density on biopsy rate and yield. Breast Cancer Res Treat 2022;191:177–90.

35. Houssami N, Ciatto S, Macaskill P, et al. Accuracy and surgical impact of magnetic resonance imaging in breast cancer staging: systematic review and meta-analysis in detection of multifocal and multicentric cancer. J Clin Oncol 2008;26:3248–58.

36. Brennan ME, Houssami N, Lord S, et al. Magnetic resonance imaging screening of the contralateral breast in women with newly diagnosed breast cancer: systematic review and meta-analysis of incremental cancer detection and impact on surgical management. J Clin Oncol 2009; 27:5640–9.

37. Gutierrez RL, DeMartini WB, Silbergeld JJ, et al. High cancer yield and positive predictive value: outcomes at a center routinely using preoperative breast MRI for staging. AJR Am J Roentgenol 2011;196:W93–9.

38. Deurloo EE, Peterse JL, Rutgers EJ, Besnard AP, Muller SH, Gilhuijs KG. Additional breast lesions in patients eligible for breast-conserving therapy by MRI: impact on preoperative management and potential benefit of computerised analysis. Eur J Cancer 2005;41:1393–401.

39. DeMartini W, Lehman C. A review of current evidence-based clinical applications for breast magnetic resonance imaging. Top Magn Reson Imaging 2008;19:143–50.

40. Debald M, Abramian A, Nemes L, et al. Who may benefit from preoperative breast MRI? A single-center analysis of 1102 consecutive patients with primary breast cancer. Breast Cancer Res Treat 2015;153:531–7.

41. Lehman CD, Gatsonis C, Kuhl CK, et al. MRI evaluation of the contralateral breast in women with recently diagnosed breast cancer. N Engl J Med 2007;356:1295–303.

42. Administration USFaD. Mammography Quality Standards Act Regulations. U.S. Food and Drug Administration 2017.

43. Miglioretti DL, Ichikawa L, Smith RA, et al. Criteria for identifying radiologists with acceptable screening mammography interpretive performance on basis of multiple performance measures. AJR Am J Roentgenol 2015;204:W486–91.

44. Sickles EA. Periodic mammographic follow-up of probably benign lesions: results in 3,184 consecutive cases. Radiology 1991;179:463–8.

45. Berg WA. BI-RADS 3 on Screening Breast Ultrasound: What Is It and What Is the Appropriate Management? J Breast Imaging 2021;3:527–38.

46. Helvie MA, Bevers TB. Screening Mammography for Average-Risk Women: The Controversy and NCCN's Position. J Natl Compr Canc Netw 2018;16:1398–404.

47. Monticciolo DL, Newell MS, Hendrick RE, et al. Breast Cancer Screening for Average-Risk Women: Recommendations From the ACR Commission on Breast Imaging. J Am Coll Radiol 2017; 14:1137–43.

48. Oeffinger KC, Fontham ET, Etzioni R, et al. Breast Cancer Screening for Women at Average Risk: 2015 Guideline Update From the American Cancer Society. JAMA 2015;314:1599–614.

49. Siu AL, Force USPST. Screening for Breast Cancer: U.S. Preventive Services Task Force Recommendation Statement. Ann Intern Med 2016;164:279–96.

50. Marmot MG, Altman DG, Cameron DA, Dewar JA, Thompson SG, Wilcox M. The benefits and harms of breast cancer screening: an independent review. Br J Cancer 2013;108:2205–40.

51. Nelson HD, Fu R, Cantor A, Pappas M, Daeges M, Humphrey L. Effectiveness of Breast Cancer Screening: Systematic Review and Meta-analysis to Update the 2009 U.S. Preventive Services Task Force Recommendation. Ann Intern Med 2016;164:244–55.

52. Mandelblatt JS, Stout NK, Schechter CB, et al. Collaborative Modeling of the Benefits and Harms Associated With Different U.S. Breast Cancer Screening Strategies. Ann Intern Med 2016;164:215–25.



ACR BI-RADS® v2025

General Frequently Asked Questions

American College of Radiology™

New to this version of the BI-RADS Manual is a section of FAQs that apply across multiple modalities.

1. ***Why is it discouraged to use a BI-RADS 0- Incomplete: Need additional imaging evaluation on MRI screening exams but acceptable for mammography, CEM and ultrasound screening?***

   The MRI examination should contain all the information needed to make a final assessment and any further recommendations, no matter what the indication for the exam is, in the vast majority of cases. With mammography, CEM and ultrasound, additional evaluation with targeted images may be required before a conclusion can be made, necessitating recall. On rare occasions with MRI, additional imaging, usually with mammography and/or ultrasound, may be needed for further *characterization* of a finding that has a high likelihood of being benign but is not definitively specific. Examples include a probable lymph node that can be more accurately evaluated with ultrasound, or an area of enhancement suspected to be fat necrosis, which may be pathognomonically identified upon mammographic imaging. When using a BI-RADS 0 category in this scenario, the report should specify a contingency plan and assessment if the finding cannot be found or characterized by the additional imaging. A BI-RADS 0 assessment should not be used for a suspicious MRI finding where added imaging is obtained to facilitate biopsy planning.

2. ***Why should we target the center of a finding instead of its anterior aspect when measuring the distance from the nipple?***

   Given the increasing use of neoadjuvant systemic therapy before definitive cancer treatment, the size of a finding may change significantly between imaging encounters. Since most cancers that show treatment response decrease in size concentrically, measuring the distance from nipple to the center of the lesion will prove more reproducible. Note that for large findings and those that lie close to the nipple, inclusion of the anterior-posterior size dimension, as well as distance from anterior margin to the nipple, can be useful for surgical planning.

3. ***We see patients for whom we previously recommended surgical consultation for histology that is considered "high-risk," particularly radial scars. The patient and surgeon decide to follow rather than excise the finding and indicate that any changes on subsequent imaging will dictate management. The follow-up imaging 6 months post-biopsy demonstrates post-biopsy changes (e.g., distortion on mammogram often a little larger than the original area of distortion). What is the appropriate BI-RADS assessment category for an unresected high-risk lesion undergoing imaging follow up?***

   Institutional and national practices currently vary and will continue to evolve for the management of high-risk lesions. If the biopsy site of the unresected high-risk lesion looks more suspicious, then a BI-RADS category 4 assessment with the recommendation for a repeat biopsy or excision is recommended. If the biopsy site looks stable, or if new findings can be attributed definitively to post-biopsy changes, then a BI-RADS category 2 assessment is appropriate. A sentence can be included indicating that the patient has an unresected high-risk lesion undergoing surveillance to add clarity. Institutions are encouraged to develop a standardized evidence-based approach for the follow up of unexcised high-risk lesions, which can then be communicated to the multidisciplinary team.

4. ***For patients undergoing non-surgical management of DCIS or invasive cancer (i.e., active surveillance), what is the appropriate BI-RADS assessment category on subsequent imaging? What about patients with cancer who have close or positive margins after surgery who do not undergo further excision?***

   For patients with known malignancy who have not undergone definitive local therapy, a BI-RADS category 6 is appropriate. This assessment should be used if the cancer is unresected (or

untreated by other means considered definitive by the multidisciplinary team), even if surveillance imaging demonstrates long-term stability or disappearance. If patients have positive or close margins *after* surgery but no suspicious imaging findings, the BI-RADS final assessment should be based on the imaging presentation, so category 2 is appropriate in the case described above if no suspicious imaging findings are present. The differing approach to these two scenarios is based on the idea that in the first case, definitive treatment has not yet taken place. In the second scenario, it has.

5. Why was the prior lexicon term "lobular" changed to "lobulated" when it was returned to lexicon usage in this new version?

With the increasing use of patient portals, there was concern that the term lobular when used as a shape descriptor might be confused with the lobular subtype of breast cancer, creating unnecessary distress for patients reading their reports.

6. Do I have to use the new structured "indication for exam" categories for all types of breast imaging studies?

New to this version of the BI-RADS Manual are suggested structured categories for the major clinical indications used for breast imaging, with associated optional subcategories and relevant clinical histories (see below). Use of these structured categories is strongly encouraged but not required in reporting across all modalities. Use of these structured indications has many benefits, including facilitating auditing of outcomes according to the different major indication categories of screening versus non-screening examinations, which have different performance outcomes. Use of these categories will also greatly assist in determining the method of cancer detection, as described more fully in the Auditing and Outcomes Monitoring section of the Manual.

Structured Exam Indications

Major Indication	Optional Subcategory Indication	Relevant History to Report, if known
Asymptomatic Screening	• Elevated risk • Dense breasts • Prior breast cancer, treatment completed • Other	• Gene mutation • Estimated cancer risk • Prior breast cancer history
Diagnostic Work-up	• Clinical findings • Imaging findings • Follow-up category 3 • Follow-up after biopsy • Implant assessment • Other	• Clinical finding type • Imaging finding type
Diagnostic: Current Breast Cancer	• Extent of disease before treatment/ therapy • Response during or after neoadjuvant therapy • Other	• Location and size of cancer on prior imaging evaluation

7. ***Our institution uses cryoablation to treat breast cancers in certain settings. Can this be considered definitive therapy? Can we provide a BI-RADS 2 assessment instead of a BI-RADS 6 assessment if the imaging acquired one year after successful cryoablation appears benign?***

   Yes, in this version of the BI-RADS Manual, therapies other than surgery-based cancer removal can be considered definitive if viewed as such by the institutional clinical team. As a result, an exam that shows typical post-treatment changes without findings suspicious for residual/recurrent disease can accurately be assessed as category 2, benign.

8. ***What is the appropriate term for recommending diagnostic follow-up in one year?***

   The preferred term for recommending follow-up at one year is 'continued surveillance,' rather than 'short term follow-up'. Short term follow-up should be reserved for exams recommended to occur in less than the standard follow-up interval (one year).

ACR BI-RADS® v2025
Online Resources

American College of Radiology™

Please visit the ACR BI-RADS® Website for additional resources

BI-RADS page

https://www.acr.org/Clinical-Resources/Clinical-Tools-and-Reference/Reporting-and-Data-Systems/BI-RADS

Sample Lay Letters

Since 1999, it has been required that the interpreting physician send every patient who receives a mammogram a written mammography report expressed in terms easily understood by a lay person. Failure to comply with this reporting requirement will result in a citation by the FDA.

Samples are provided for your convenience; you may use these as is, modify them, or create your own lay reports.

https://www.acr.org/Clinical-Resources/Clinical-Tools-and-Reference/Screening-Resources/Breast-Imaging-Resources/Lay-Report-Letters

National Mammography Database - NMD and Data Dictionary

Use of an ACR-approved computer-based reporting software is required for participation in the ACR National Mammography Database (NMD)

(https://nrdr.acr.org/Portal/NMD/Main/page.aspx).

The NMD Data Dictionary describes all of the data elements for the National Mammography Database, including whether or not a field is required and what responses are valid.

https://nrdrsupport.acr.org/support/solutions/articles/11000041537